

AperTO - Archivio Istituzionale Open Access dell'Università di Torino

**Oral mucosa produces cytokines and factors influencing osteoclast activity and endothelial cell proliferation, in patients with osteonecrosis of jaw after treatment with zoledronic acid.**

**This is the author's manuscript**

*Original Citation:*

*Availability:*

This version is available <http://hdl.handle.net/2318/120331> since 2019-04-30T09:39:24Z

*Published version:*

DOI:10.1007/s00784-012-0800-7

*Terms of use:*

Open Access

Anyone can freely access the full text of works made available as "Open Access". Works made available under a Creative Commons license can be used according to the terms and conditions of said license. Use of all other works requires consent of the right holder (author or publisher) if not exempted from copyright protection by the applicable law.

(Article begins on next page)

This is the author's final version of the contribution published as:

Mozzati M; Martinasso G; Maggiora M; Scoletta M; Zambelli M; Carossa S; Oraldi M; Muzio G; Canuto RA. Oral mucosa produces cytokines and factors influencing osteoclast activity and endothelial cell proliferation, in patients with osteonecrosis of jaw after treatment with zoledronic acid.. CLINICAL ORAL INVESTIGATIONS. 17 (4) pp: 1259-1266.  
DOI: 10.1007/s00784-012-0800-7

The publisher's version is available at:

<http://link.springer.com/content/pdf/10.1007/s00784-012-0800-7>

When citing, please refer to the published version.

Link to this full text:

<http://hdl.handle.net/2318/120331>

1 Oral mucosa produces cytokines and factors influencing osteoclast activity and endothelial cell proliferation, in patients  
2 with osteonecrosis of jaw after treatment with zoledronic acid.

3

4 Marco Mozzati DDS<sup>a</sup>, Germana Martinasso PhD<sup>b</sup>, Marina Maggiora PhD<sup>b</sup>, Matteo Scoletta DDS<sup>a</sup>, Marta Zambelli  
5 DDS<sup>a</sup>, Stefano Carossa DDS<sup>a</sup>, Manuela Oraldi PhD<sup>b</sup>, Giuliana Muzio PhD<sup>b</sup>, Rosa Angela Canuto MD<sup>b</sup>

6

7 <sup>a</sup> Oral Surgery Unit, Dentistry Section, Department of Biomedical Sciences and Human Oncology, Dental School,  
8 University of Turin, Via Nizza 170, Turin, Italy

9 <sup>b</sup> Department of Experimental Medicine and Oncology, University of Turin, Corso Raffaello 30, 10125, Turin, Italy

10

11 e-mail of each author:

12 [marco.mozzati@libero.it](mailto:marco.mozzati@libero.it); [germana.martinasso@cpo.it](mailto:germana.martinasso@cpo.it); [marina.maggiora@unito.it](mailto:marina.maggiora@unito.it); [matteo.scoletta@libero.it](mailto:matteo.scoletta@libero.it);

13 [martaz11@hotmail.com](mailto:martaz11@hotmail.com); [stefano.carossa@unito.it](mailto:stefano.carossa@unito.it); [manuela.oraldi@unito.it](mailto:manuela.oraldi@unito.it); [giuliana.muzio@unito.it](mailto:giuliana.muzio@unito.it);

14 [rosangela.canuto@unito.it](mailto:rosangela.canuto@unito.it)

15

16

17 Address of corresponding author:

18 Prof. Rosa Angela Canuto

19 Dipartimento di Medicina ed Oncologia Sperimentale, Università di Torino

20 Corso Raffaello 30, 10125 TORINO (ITALY),

21 Phone n. +39 011 6707781, fax n. +39 011 6707753, e-mail [rosangela.canuto@unito.it](mailto:rosangela.canuto@unito.it)

22

1 **Abstract**

2 Objectives

3 The intravenous injection of bisphosphonates, currently used as treatment for osteoporosis, bone Paget's disease,  
4 multiple myeloma or bone metastases, can cause jaw bone necrosis especially in consequence of trauma.

5 The present research aimed to clarify the mechanisms underlying bone necrosis, exploring involvement of the oral  
6 mucosa "in vivo".

7 Patients and Methods

8 Specimens of oral mucosa were removed from bisphosphonate- treated patients with or without jaw bone necrosis. In  
9 mucosa specimens, expression was evaluated of: cytokines involved in the inflammatory process, factors involved in  
10 osteoclast activity, i.e. RANKL and osteoprotegerin, a factor involved in cell proliferation, namely  
11 hydroxymethylglutaryl coenzyme A reductase, and a factor involved in angiogenesis, namely VEGF.

12 Results

13 IL-6 and the RANK/osteoprotegerin ratio were significantly elevated in mucosa from patients with versus without jaw  
14 necrosis, whereas hydroxymethylglutaryl coenzyme A reductase and VEGF were significantly decreased.

15 Conclusion

16 Our results suggest that mucosa, stimulated by bisphosphonate released from the bone, can contribute to development  
17 of jaw necrosis, reducing VEGF and producing IL-6 in consequence of hydroxymethylglutaryl coenzyme A reductase  
18 reduction. In turn, IL-6 stimulates osteoclast activity, as shown by the increased RANKL/osteoprotegerin ratio.

19 **Clinical relevance**

20 The results of this study suggest the importance of evaluating during bisphosphonate treatment the production of IL-6,  
21 RANKL, osteoprotegerin and VEGF, in order to monitor the jaw osteonecrosis onset. To avoid repeated mucosa  
22 excisions, the determination of these factors could be carried out in crevicular fluid.

23

24 Key words: Bisphosphonates, osteonecrosis, jaw, cytokines, RANKL/OPG, HMGR

25

## 1 **Introduction**

2

3 Bisphosphonates (BPs) are currently used as first-line treatment for osteoporosis and Paget's disease of the bone, and  
4 are administered routinely in patients with multiple myeloma or metastatic bone disease [1]. The affinity of BPs for  
5 bone mineral, and their inhibitory effect on osteoclast cell function, result in a strong antiresorptive action, a reduction  
6 in the risk of osteoporotic fractures, and an improvement in the overall bone health in cancer patients [2].

7 Nitrogen-containing BPs (N-BPs), but not BPs lacking nitrogen, affect the function and survival of osteoclasts by  
8 inhibiting the farnesyl pyrophosphate synthase enzyme from the mevalonate pathway, which is responsible for  
9 cholesterol and farnesyl synthesis [1, 3].

10 BPs can be administered orally or by intravenous injection. Oral administration of BPs is affected by poor  
11 gastrointestinal absorption. After BPs enter the circulation, approximately 50% of the dose is incorporated into the bone.  
12 Most of the remainder is excreted unchanged in the urine, and only a negligible amount is transiently exposed to other  
13 tissues. During cycles of bone remodelling, BPs are slowly released and re-enter the systemic circulation unmetabolized  
14 [4].

15 In the case of the jaw bones, intravenous injection of BPs can cause bone necrosis spontaneously or in consequence of  
16 trauma. This bone lesion does not occur in other parts of the skeleton and is, by definition, a necrotic area free of  
17 metastatic elements [5]. The mechanisms whereby BPs induce bone necrosis are, at present, unclear. One view  
18 considers that BPs reduce bone turnover, reducing osteoclast and osteoblast activity, leading to areas of necrotic bone  
19 [6]. Another hypothesis supports the involvement of bone blood supply reduction, pointing to modifications of vascular  
20 endothelial growth factor (VEGF) and platelet-derived growth factor [7, 8]. On the contrary, histological examination of  
21 samples obtained from patients with osteonecrosis of the jaw (ONJ) induced by BPs showed patent vessels in the  
22 majority of patients, and no histological changes [9, 10].

23 Another hypothesis considers that BPs have a direct toxic action on the oral mucosa. As a result, oral pathogens are able  
24 to pass through defective or severely-damaged oral mucosa, and infect the bone, eventually leading to its necrosis [11].

25 A thorough knowledge of bone biology, and of the molecular mechanisms of normal bone remodelling, is important in  
26 order to understand bone health. Key factors in bone remodelling include the RANKL ligand (RANKL), which  
27 stimulates bone resorption, and osteoprotegerin (OPG), which inhibits bone resorption. The ratio between these two  
28 factors regulates osteoclast formation and activity. Very recently, an "in vitro" study on osteoblasts derived from human  
29 mesenchymal stem cells showed that nitrogen-containing BPs increased the expression of OPG [12]; similarly, another  
30 study evidenced that nitrogen-containing BPs caused a moderate enhancement of OPG gene expression, and a strongly

1 increase of RANKL. Interestingly, non-nitrogen-containing clodronate affected much less OPG and RANKL expression  
2 [13]

3 In the light of the above observations, this research aimed to explore the involvement of the oral mucosa in ONJ,  
4 examining the production of cytokines implicated in the inflammatory process, factors involved in osteoclast activity,  
5 i.e. RANKL and OPG, a factor involved in cell proliferation, namely hydroxymethylglutaryl coenzyme A reductase  
6 (HMGR), and a factor involved in angiogenesis, namely VEGF.

7

8

## 9 **Patients and Methods**

### 10 Patients

11 Thirty patients with bone metastases from solid tumors or multiple myeloma, and in therapeutic treatment with  
12 intravenous BP (zoledronic acid) entered the study. The patients received 4 mg intravenous zoledronic acid (Zometa®;  
13 Novartis Pharma SpA, Basel, Switzerland) every 4 weeks for 12 months. The patients did not receive radiotherapy at  
14 the head and neck region, and they did not receive any chemotherapeutical medications during BP treatment. Informed  
15 consent was obtained from all patients. The study protocol was approved by the Ethics Committee of Turin University  
16 (approval number of local ethical board: CEI/396; protocol number 0010469). Patients treated with BPs for  
17 osteoporosis were excluded.

18 After 12 months of BP treatment and after 1 month from the last BP medication, the patients were observed for the  
19 absence or presence of ONJ, and then subdivided into two groups:

20 1) ONJ negative group (ONJ-). This group included 11 women and 5 men, with mean age  $68.56 \pm 6.30$  years.

21 2) ONJ positive group (ONJ+). This group included 10 women and 4 men, with mean age  $65.29 \pm 5.24$  years.

### 22 Surgical Protocol

23 In the ONJ- group, tooth extraction was performed under locoregional anaesthesia (mepivacaine 2%), through luxation  
24 and avulsion with clamp. In all cases, 3-0 silk sutures were used to suture the alveolar mucosa; they were removed after  
25 7 days. Patients were given antibiotic (amoxicillin every 8 hours for 6 days) and oral anti-inflammatory treatment  
26 (Ibuprofen every 12 hours for 3 days). Mucosa specimens were taken from area corresponding to the maxillary  
27 protuberance before the tooth extraction; excision was half-thickness, to avoid removing the periosteum and exposing  
28 the bone. One simple suture was placed. All specimens were placed in RNA Later solution (Qiagen, Milan, Italy), and  
29 maintained at  $-80^{\circ}\text{C}$  until use.

30 In the ONJ+ group, the patients were treated by resection of the necrotic bone with primary closure of the mucosa over  
31 the bony defect using plasma rich in growth factors (PRGF), as described in Mozzati et al. [14]. Mucosa specimens

1 were excised as described above, in an area distant from the necrotic area, and before the surgical procedure for  
2 removing ONJ; the specimens were placed in RNA Later solution (Qiagen, Milan, Italy), and maintained at  $-80^{\circ}\text{C}$  until  
3 use. Panoramic radiography and computed tomography were performed before and after surgery.

#### 4 Radiographic analysis

5 All patients were monitored through dental panoramic radiography and computed tomography (CT), to evaluate the  
6 presence or absence of ONJ.

#### 7 Biological factor analysis

8 Mucosa specimens were analyzed to determine expression of inflammatory (interleukin (IL)- $1\beta$ , IL-6, IL-8 and TNF- $\alpha$ ),  
9 osteoclastogenic (RANKL and OPG), and proliferation parameters (HMGR and VEGF), using real-time polymerase  
10 chain reaction (PCR).

11 Total RNA was extracted from specimens using the NucleoSpin RNA II Kit (Macherey-Nagel GmbH & Co. KG, Düren,  
12 Germany), as previously reported [15]. Real-time PCR was run with single-stranded cDNA prepared from total RNA (1  
13  $\mu\text{g}$ ) using a High-Capacity cDNA Archive kit (Applied Bio Systems, Foster City, CA).

14 The forward (FW) and reverse (RV) primers shown in Table 1 were designed using Beacon Designer<sup>®</sup> software (Bio-  
15 Rad, Hercules, CA). Twenty-five  $\mu\text{l}$  of a PCR mixture containing cDNA template equivalent to 40 ng of total RNA, 5  
16 pmoles each of forward and reverse primers, and  $2\times$  IQ SYBR Green SuperMix (Bio-Rad, Hercules, CA) were  
17 amplified using an iCycler PCR instrument (Bio-Rad, Hercules, CA) with an initial melt at  $95^{\circ}\text{C}$  for 10 min, followed  
18 by 35-40 cycles at  $95^{\circ}\text{C}$  for 40 s, annealing temperature for each primer set for 40 s, and  $72^{\circ}\text{C}$  for 40 s. A final  
19 extension of 7 min at  $72^{\circ}\text{C}$  was applied. Each sample was tested in duplicate, and threshold cycle (Ct) values from each  
20 reaction were averaged. GAPDH was used as house-keeping gene. The changes in expression were defined as those  
21 detected in the mucosa specimens taken from ONJ- or ONJ+ patients versus those detected in the mucosa specimens  
22 taken from normal subjects, and calculated as  $2^{-\Delta\Delta\text{Ct}}$ , where  $\Delta\text{Ct} = \text{Ct}_{\text{sample}} - \text{Ct}_{\text{GAPDH}}$  and  $\Delta\Delta\text{Ct} = \Delta\text{Ct}_{\text{T sample}} - \Delta\text{Ct}_{\text{T normal}}$ .  
23 Mucosa specimens from normal subjects were taken during tooth extraction, after obtaining informed consent.

#### 24 Statistical analysis

25 For each biological factor examined in ONJ- and ONJ+ groups, descriptive analysis of data were performed. For visual  
26 representation, box plots were created by SPSS software package.

27

## 28 **Results**

### 29 Patients

30 Table 2 reports the number, the sex and the age of patients enrolled in this study, and that the distribution of primary  
31 diseases. The analysis of the latter parameter showed that 47% of ONJ- patients had breast cancer, 40% prostate cancer  
32 and 13% multiple myeloma; 50% of ONJ+ patients had breast carcinoma, 25% multiple myeloma, 17% prostate cancer  
33 and 8% kidney cancer. As regards ONJ + patients, ONJ affected the lower jaw in the 62% of cases, and the upper jaw in  
34 the 38% (data not shown).

1 Both ONJ- and ONJ+ patients, at 8 months after tooth extraction or ONJ removing, showed no signs of osteonecrosis,  
2 as evidenced by dental panoramic radiography and CT imaging.

### 3 Radiographic analysis

4 All patients enrolled were monitored through dental panoramic radiography; since this was found to be of limited use in  
5 assessing BP-associated ONJ, they were followed by the more informative CT imaging. This is in line with previous  
6 findings [16].

### 7 Biological factor analysis

8 Analysis of the biological factors involved in the inflammation process, namely IL-1 $\beta$ , IL-6, IL-8 and TNF- $\alpha$ , is shown  
9 in Figure 1. No variation in cytokines was observed between the mucosa specimens taken from the two groups (ONJ-  
10 and ONJ+), with the exception of IL-6, which was higher in the ONJ+ group than in the ONJ- group.

11 Figure 2 shows the variation of RANKL and OPG between specimens of mucosa taken from the ONJ- and ONJ+  
12 patients. RANKL was higher in the mucosa from ONJ+ patients versus ONJ- patients. On the contrary, OPG was lower  
13 in the mucosa from ONJ+ patients than ONJ- patients. However, the RANKL/OPG ratio was very much higher in  
14 ONJ+ than in ONJ- ( $9.85 \pm 9.82$  vs  $2.18 \pm 2.14$ ).

15 As regards factors involved in cell proliferation, i.e. HMGR, and in endothelial cell proliferation, i.e. VEGF, Figure 3  
16 shows that both these factors were lower in the mucosa from ONJ+ patients than in that from ONJ- patients.

17

## 18 **Discussion**

19

20 The present study aimed to evaluate involvement of the mucosa in inducing ONJ, since the pathogenetic mechanisms  
21 underlying the development of ONJ are still unclear. With this aim, specimens of mucosa were removed from two  
22 groups of patients in order to identify any differences in gene expression profiling, in the presence or absence of ONJ;  
23 all patients were examined after 12 months of zoledronic acid treatment.

24 BPs have become an important component in treating both bone metastases from solid tumors and multiple myeloma.  
25 Their efficacy has been proven in large randomized clinical trials [17, 18]. Intravenous injection of BPs is now the  
26 standard of care for the treatment and prevention of skeletal complications associated with bone metastases [18].  
27 However, the use of BPs in oncology has been the subject of debate, due to their association, in the presence of other  
28 risk factors, with the development of ONJ, a serious adverse event that can negatively affect the patient's quality of life  
29 [19, 20]. It is known that invasive dental interventions during BP treatment are one of the main risk factors for ONJ  
30 development [21]. It is also been reported that ONJ can also arise spontaneously [22]. Moreover, BP treatment is also



1 intensely debated, due both to the limited knowledge of the etiology and pathogenesis of ONJ, and to the lack of  
2 alternative therapeutic options available for patients with metastatic bone disease.

3 In this study, ONJ occurred especially in the lower jaw (more than 50%) than in upper jaw. This observation is in  
4 agreement with the data reported by literature, which affirm that lower jaw location is more common, because it has  
5 more areas with thin mucosa than the upper jaw [23]

6 It is noteworthy that the ONJ- patients, at 8 months after tooth extraction, showed no signs of ONJ; this seems to be the  
7 consequence of the fact that the inflammatory and osteoclastogenic factors were produced in different amount by  
8 mucosa in this patient group in comparison with the ONJ+ group.

9 As regards inflammatory factors, IL-6 was found to be increased in the mucosa from ONJ+ patients, whereas the other  
10 cytokines tested, such as TNF- $\alpha$ , were not increased. At first sight, this appears to be in contrast with the well-known  
11 observation that BPs, and in particular the aminobisphosphonates such as zoledronic acid, have a number of side-effects  
12 [24]. These include a rise in body temperature and accompanying flu-like symptoms that resemble a typical acute-phase  
13 response. These clinical features occur in over a third of patients receiving treatment for the first time. However,  
14 cytokine production is maximal within 28–36 h of intravenous administration, and disappears 2–3 days later, despite  
15 continuing treatment. This production is characterized by increased circulating levels of IL-6, TNF and interferon  
16 [25]. Our determinations were on mucosa from patients after the 12th dose of zoledronic acid. It is thus unlikely that the  
17 increased IL-6 expression was correlated with a general inflammatory response. It was more probably linked to local  
18 mucosal inflammation and bone necrosis, thus being the consequence of the induction of osteoclast differentiation and  
19 activity, due to the increased RANKL/OPG ratio. IL-6 is considered to be an osteoclastogenic cytokine, and thus an  
20 important mediator of bone loss [26, 27]. “In vitro” experiments have shown that zoledronic acid stimulates  $\gamma\delta$  T cells,  
21 with consequent production of cytokines; BPs appear to activate these cells by inhibiting farnesyl pyrophosphate (FPP)  
22 synthase. Inhibition of the mevalonate pathway leads to an accumulation of metabolic intermediates, including  
23 isopentenyl pyrophosphate, which is a potent activator of human peripheral blood  $\gamma\delta$  T cells [28]. Moreover, this latter  
24 study found a correlation between the mevalonate pathway and  $\gamma\delta$  T cell activation by statin administration: statins  
25 inhibited the activation of human peripheral blood  $\gamma\delta$  T cells in response to endogenous non-sterol mevalonate products.

26 In the mucosa of ONJ+ patients, HMGCoA expression was decreased; these results thus agree with the observation  
27 reported above, and suggest that this decrease could be responsible for inducing cells present in the mucosa to produce  
28 IL-6. In its turn, IL-6 induced osteoclast activity, as shown by the increase of RANKL and RANKL/OPG ratio.

29 At this point, the following question may be asked: since, in the bone, BPs inhibit osteoclast activity in order to reduce  
30 bone loss, why, in the jaw, do they induce osteoclast activity, and thus cause bone necrosis? Our answer is that BPs are  
31 known to accumulate in the bone and that, in consequence of minor trauma (dentures or dental prostheses, caries and

1 periodontal disease) [29], they are released from the bone into the environment. In the case of the jaw, the environment  
2 is the mucosa, where epithelial cells, fibroblasts and lymphocytes are present. In this context, BPs induce these cells to  
3 produce cytokines by inhibiting HMGCoA. IL-6 in contact with alveolar bone stimulates osteoclast activity.  
4 Moreover, other studies have reported that increased IL-6, induced by pro-inflammatory stimuli, is also accompanied by  
5 down-regulation of markers of osteoblastic differentiation [30, 31] The production of IL-6 is not correlated with the  
6 general acute-phase response, which comes about after the initial infusion of BP; rather it may be considered the  
7 consequence of the local inflammation induced in the mucosa by the release of BP from the alveolar bone. This means  
8 that, for the first time, the mucosa comes into contact with BP, setting off cytokine IL-6 production. IL-6 induces the  
9 above described events, i.e. the induction of osteoclasts. Moreover, the reduction of VEGF production in mucosa  
10 specimens, evidenced in this research, could also contribute to the development of ONJ, blocking bone synthesis and  
11 healing. This agrees with antiangiogenic effect of BPs demonstrated by other authors with “in vitro” experiments,  
12 animal models and human studies on BP-treated patients with advanced solid cancer and bone metastasis [32, 33]. In  
13 fact, the anti-angiogenic action, with reduced capillary formation and inhibition of endothelial and vascular growth  
14 factors leading to avascular necrosis, is considered one of the mechanism for ONJ onset. However, there is no evidence  
15 in literature for this effect of bisphosphonates in bone: the angiogenesis during bone formation seems to be unaltered by  
16 bisphosphonates. However. another recent hypothesis stated that bisphosphonates accumulate in bone in concentrations  
17 sufficient to be directly toxic to the oral epithelium, resulting in the failure of healing of soft tissue lesions [33].

18  
19 In conclusion, we hypothesize that the mucosa, possibly stimulated by BP released from the bone, can cause ONJ,  
20 producing IL-6 in consequence of HMG-CoA reduction; IL-6, in turn, stimulates osteoclast activity, evidenced by the  
21 increased RANKL/OPG ratio. ONJ may also in part be due to the reduction of VEGF expression.

### 22 **Conflicts of interest**

24 The authors declared no conflicts of interest.

25  
26 **Acknowledgments:** The work was supported by grants from Regione Piemonte and University of Turin, Italy.



1   **References**

2

- 3   [1]   Pazianas M (2011) Osteonecrosis of the jaw and the role of macrophages. *J Natl Cancer Inst* 103:232-240
- 4   [2]   Mehrotra B 2009 Bisphosphonates-role in cancer therapies. *J Oral Maxillofac Surg* 67:19-26
- 5   [3]   Dunford JE, Kwaasi AA, Rogers MJ et al (2008) Structure-activity relationships among the nitrogen containing  
6       bisphosphonates in clinical use and other analogues: time-dependent inhibition of human farnesyl pyrophosphate  
7       synthase. *J Med Chem* 51:2187-2195
- 8   [4]   Marcus R, Feldman D, Nelson D et al (2008) Bisphosphonates: pharmacology and use in the treatment of  
9       osteoporosis. In: Marcus R, Feldman D, Nelson D, Rosen C (eds) *Osteoporosis*, 3rd edn. Elsevier, Burlington,  
10      MA, pp 1725-1742
- 11   [5]   Frei M, Bornstein MM, Schaller B et al (2010) Bisphosphonate-related osteonecrosis of the jaw combined with  
12      jaw metastasis of prostate adenocarcinoma: report of a case. *J Oral Maxillofac Surg* 68:863-867
- 13   [6]   Treister NS, Sook-Bin W (2009) Bisphosphonate-associated osteonecrosis of the jaws. In: Rosen CJ, Compston  
14      JE, Lian JB (eds) *Primer on the Metabolic Bone Diseases and Disorders of Mineral Metabolism*, 7th edn. John  
15      Wiley & Sons, Hoboken, NJ, pp 505-509
- 16   [7]   Santini D, Vincenzi B, Dicuonzo G et al (2003) Zoledronic acid induces significant and long-lasting  
17      modifications of circulating angiogenic factors in cancer patients, and by “in vitro” research. *Clin Cancer Res*  
18      9:2893-2897
- 19   [8]   Fournier P, Boissier S, Filleur S et al (2002) Bisphosphonates inhibit angiogenesis in vitro and testosterone-  
20      stimulated vascular regrowth in the ventral prostate in castrated rats. *Cancer Res* 62:6538-6544
- 21   [9]   Hansen T, Kunkel M, Weber A et al (2006) Osteonecrosis of the jaws in patients treated with bisphosphonates-  
22      histomorphologic analysis in comparison with infected osteoradionecrosis. *J Oral Pathol Med* 35:155-160
- 23   [10]   Hellstein JW, Marek CL (2005) Bisphosphonate osteochemonecrosis (bis-phossy jaw): is this phossy jaw of the  
24      21st century? *J Oral Maxillofac Surg* 63:682-689
- 25   [11]   Reid IR (2009) Osteonecrosis of the jaw: who gets it, and why? *Bone* 44:4-10
- 26   [12]   Ohe JY, Kwon YD, Lee HW (2011) Bisphosphonates modulate the expression of OPG and M-CSF in hMSC-  
27      derived osteoblasts. *Clin Oral Investig* [Epub ahead of print]
- 28   [13]   Koch FP, Merkel C, Ziebart T et al (2012) Influence of bisphosphonates on the osteoblast RANKL and OPG  
29      gene expression in vitro. *Clin Oral Investig* 16:79-86
- 30   [14]   Mozzati M, Gallesio G, Arata V et al (2012) Platelet-rich therapies in the treatment of intravenous  
31      bisphosphonate-related osteonecrosis of the jaw: A report of 32 cases. *Oral Oncol* 48:469-74

- 1 [15] Mozzati M, Martinasso G, Cocero N et al (2011) Influence of superpulsed laser therapy on healing processes  
2 following tooth extraction. *Photomed Laser Surg* 29:565-571
- 3 [16] Bianchi SD, Scoletta M, Cassione FB et al (2007) Computerized tomographic findings in bisphosphonate-  
4 associated osteonecrosis of the jaw in patients with cancer. *Oral Surg Oral Med Oral Pathol Oral Radiol Endod*  
5 104:249-258
- 6 [17] Pavlakis N, Schmidt R, Stockler M (2005) Bisphosphonates for breast cancer. *Cochrane Database Syst Rev*  
7 3:CD003474
- 8 [18] Aapro M, Abrahamsson PA, Body JJ et al (2008) Guidance on the use of bisphosphonates in solid tumours:  
9 recommendations of an international expert panel. *Ann Oncol* 19:420-432
- 10 [19] La Verde N, Bareggi C, Garassino M et al (2008) Osteonecrosis of the jaw (ONJ) in cancer patients treated with  
11 bisphosphonates: how the knowledge of a phenomenon can change its evolution. *Support Care Cancer* 16:1311-  
12 1315
- 13 [20] Ruggiero S, Gralow J, Marx RE et al (2006) Practical guidelines for the prevention, diagnosis, and treatment of  
14 osteonecrosis of the jaw in patients with cancer. *J Oncol Pract* 2:7-14
- 15 [21] Vandone AM, Donadio M, Mozzati M et al (2011) Impact of dental care in the prevention of bisphosphonate-  
16 associated osteonecrosis of the jaw: a single-center clinical experience. *Ann Oncol* 23:193-200
- 17 [22] Lo JC, O'Ryan FS, Gordon NP et al (2010) Prevalence of osteonecrosis of the jaw in patients with oral  
18 bisphosphonate exposure. *J Oral Maxillofac Surg* 68:243-53
- 19 [23] Shannon J, Shannon J, Modelevsky S et al (2011) Bisphosphonates and Osteonecrosis of the Jaw. *J Am Geriatr*  
20 *Soc.* doi: 10.1111/j.1532-5415.2011.03713.x
- 21 [24] Russell RG, Croucher PI, Rogers MJ (1999) Bisphosphonates: pharmacology, mechanisms of action and clinical  
22 uses. *Osteoporos Int* 9:S66-80
- 23 [25] Santini D, Vincenzi B, Caraglia M et al (2007) A hitherto unreported high incidence of zoledronic acid-induced  
24 acute phase reaction in patients with cancer treatment-induced bone loss. *Ann Oncol* 18:201-202.
- 25 [26] Rufo A, Del Fattore A, Capulli M et al (2011) Mechanisms inducing low bone density in Duchenne muscular  
26 dystrophy in mice and humans. *J Bone Miner Res.* doi:10.1002/jbmr.410
- 27 [27] Jimi E, Furuta H, Matsuo K et al (2010) The cellular and molecular mechanisms of bone invasion by oral  
28 squamous cell carcinoma. *Oral Dis.* doi:10.1111/j.1601-0825.2010.01781.x
- 29 [28] Hewitt RE, Lissina A, Green AE et al (2005) The bisphosphonate acute phase response: rapid and copious  
30 production of proinflammatory cytokines by peripheral blood  $\gamma\delta$  T cells in response to aminobisphosphonates is  
31 inhibited by statins. *Clin Exp Immunol* 139:101-111

- 1 [29] Woo SB, Hellstein JW, Kalmar JR (2006) Narrative review: bisphosphonates and osteonecrosis of the jaws. *Ann*  
2 *Intern Med* 144:753–761
- 3 [30] Kraus D, Deschner J, Jäger A et al (2011) Human  $\beta$ -defensins differently affect proliferation, differentiation, and  
4 mineralization of osteoblast-like MG63 cells. *J Cell Physiol*. doi:10.1002/jcp.22808
- 5 [31] Krishnan V, Shuman LA, Sosnoski DM et al (2011) Dynamic interaction between breast cancer cells and  
6 osteoblastic tissue: Comparison of Two- and Three-dimensional cultures. *J Cell Physiol* 226:2150-2158
- 7 [32] Landesberg R, Woo V, Cremers S et al (2011) Potential pathophysiological mechanisms in osteonecrosis of the  
8 jaw. *Ann N Y Acad Sci* 1218:62-79. doi:10.1111/j.1749-6632.2010.05835.x
- 9 [33] Rustemeyer J, Bremerich A (2010) Bisphosphonate-associated osteonecrosis of the jaw: what do we currently  
10 know? A survey of knowledge given in the recent literature. *Clin Oral Investig* 14:59-64



1 **Captions**

2

3 **Figure 1.** Boxplot graph showing cytokine mRNA content in mucosa specimens from ONJ- and ONJ+ patients.

4

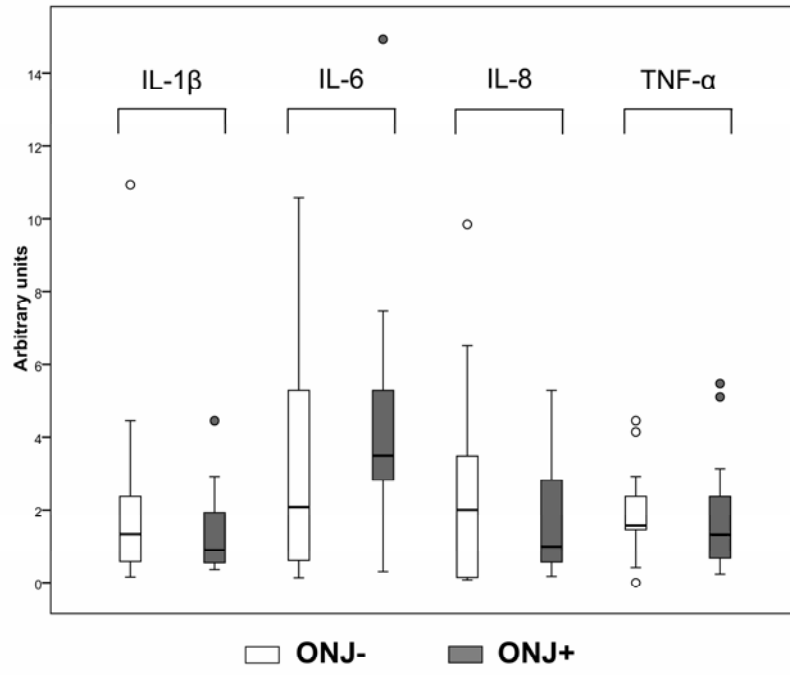
5 **Figure 2.** Boxplot graph showing RANKL and OPG mRNA content in mucosa specimens from ONJ- and ONJ+  
6 patients.

7

8 **Figure 3.** Boxplot graph showing VEGF and HMGR mRNA content in mucosa specimens from ONJ- and ONJ+  
9 patients.

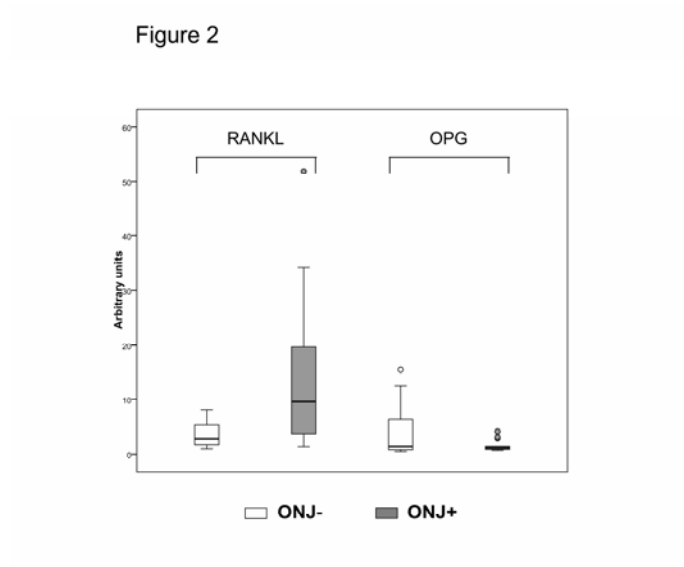


Figure 1



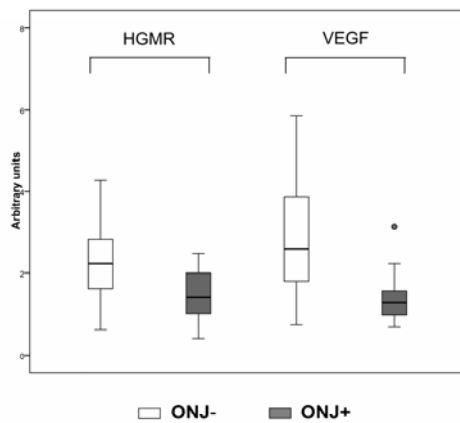
1

1



2

Figure 3



1

1 **Table 1.** Forward and reverse primers for real-time PCR analysis.

Gene	Sequence	T annealing
Acc. N°	FW : forward RV : reverse	# cycles
Human GAPDH	FW-5'-TGA AGG TCG GAG TCA ACG GAT TTG GT-3'	52°C
NM_002046	RV-5'-CAT GTG GGC CAT GAG GTC CAC CAC-3'	35
Human IL-1beta	FW-5'-GCA CCT TCT TTC CCT TCA TCT TT-3'	52°C
AF043335	RV-5'-GCG TGC AGT TCA GTG ATC GTA-3'	35
Human IL-6	FW-5'-CCA GTA CCC CCA GGA GAA GAT T-3'	52°C
M14584	RV-5'-GTC AAT TCG TTC TGA AGA GGT GAG-3'	35
Human IL-8	FW-5'-AGC TGG CCG TGG CTC TCT-3'	52°C
NM_000584	RV-5'-TTA GCA CTC CTT GGC AAA ACT G-3'	35
Human TNF-alpha	FW-5'-CTC TGG CCC AGG CAG TCA-3'	52°C
AF043342	RV-5'-GGA GCT GCC CCT CAG CTT-3'	35
Human RANK-L	FW-5'-CAC AGC ACT TCA GAG CAG AG-3'	58°C
NM_033012	RV-5'-ACA GAC TCA CTT TAT GGG AAC C-3'	40
Human OPG	FW-5'-CAG CGG CAC ATT GGA C-3'	55°C
NM_002546	RV-5'-CGT GCA TTA GGC CCT T-3'	30
Human HMGR	FW-5'-CTT GTG TGT CCT TGG TAT TAG AGC TT-3'	56°C
NM_000859	RV-5'-TAA TCA TCT TGA CCC TCT GAG TTA CAG-3'	35
Human VEGF	FW-5'-AGA CGG ACA GAA AGA CAG-3'	54°C
NM_1025366	RV-5'-AAG CAG GTG AGA GTA AGC-3'	35

2

1 **Table 2. Characteristics of ONJ – and ONJ + patients.**

	ONJ -	ONJ +
<b>Number of patients</b>		
· Women	11	10
· Men	5	4
<b>Age</b>	68.56 ± 6.30	65.29 ± 5.24
<b>Primary disease</b>		
· Breast cancer	47 %	50 %
· Multiple myeloma	40 %	25 %
· Prostate cancer	13 %	17 %
· Kidney cancer		8 %

2 The percentages of primary disease refer to the total of patients enrolled in ONJ – (16)  
 3 and ONG + (14) groups.

4