

AperTO - Archivio Istituzionale Open Access dell'Università di Torino

Transanal endoscopic microsurgery vs. laparoscopic total mesorectal excision for T2N0 rectal cancer

This is the author's manuscript

Original Citation:

Availability:

This version is available <http://hdl.handle.net/2318/120803> since

Published version:

DOI:10.1007/s11605-012-2046-8

Terms of use:

Open Access

Anyone can freely access the full text of works made available as "Open Access". Works made available under a Creative Commons license can be used according to the terms and conditions of said license. Use of all other works requires consent of the right holder (author or publisher) if not exempted from copyright protection by the applicable law.

(Article begins on next page)

This is the author's final version of the contribution published as:

Allaix M.E.; Arezzo A.; Giraud G.; Morino M.. Transanal endoscopic microsurgery vs. laparoscopic total mesorectal excision for T2N0 rectal cancer. JOURNAL OF GASTROINTESTINAL SURGERY. 16 (12) pp: 2280-2287.

DOI: 10.1007/s11605-012-2046-8

The publisher's version is available at:

<http://www.springerlink.com/index/pdf/10.1007/s11605-012-2046-8>

When citing, please refer to the published version.

Link to this full text:

<http://hdl.handle.net/2318/120803>

Transanal Endoscopic Microsurgery vs. Laparoscopic Total Mesorectal Excision for T2N0 Rectal Cancer

- Marco Ettore Allaix, Alberto Arezzo, Giuseppe Giraudo, Mario Morino

¹Digestive, Colorectal, Oncologic and Minimal Invasive Surgery, University of Torino, Torino, Italy.

Abstract

Objective

The aim was to compare transanal endoscopic microsurgery (TEM) and laparoscopic resection (LR) in terms of short-term and oncologic outcomes in patients with a preoperatively diagnosed T2N0 extraperitoneal rectal cancer.

Methods

We conducted a retrospective analysis of a prospective database. All patients with a preoperatively staged T2N0 extraperitoneal rectal adenocarcinoma were considered for LR. Patients refusing LR or medically unfit for LR were considered for TEM, which was associated with neoadjuvant RT in the last cases. Only patients with a minimum follow-up of 36 months were included.

Results

Seventy-eight patients were included. TEM was indicated or preferred in 43 patients; of these, 11 underwent neoadjuvant RT. Morbidity was significantly lower after TEM ($p < 0.001$). The median follow-up was 70 (36–140) months. A higher local recurrence rate was noted after TEM (26 %), compared to neoadjuvant RT + TEM (0 %) and LR (9 %) ($p = 0.070$). Overall, 5-year survival rate was 76 % after TEM, 77.8 % after RT + TEM, and 96 % after LR, respectively ($p = 0.134$).

Conclusions

While TEM alone may only be considered a palliative treatment, it might allow similar oncologic results to abdominal resection in responders to neoadjuvant RT. Large prospective randomized trials are awaited to confirm these findings.

Keywords

Transanal endoscopic microsurgery Neoadjuvant radiotherapy Laparoscopy Total mesorectal excision Rectal cancer

No funds, grants or support was received to complete the study.

Introduction

The goal of oncologic surgery is primarily to achieve the best cancer control and secondly to preserve function and quality of life in the field of rectal malignant neoplasms. Total mesorectal excision (TME) represents the best curative treatment, with very low local recurrence rates reported after neoadjuvant radiochemotherapy.^{1–3}

Nevertheless, both anterior resection (AR) and abdominoperineal resection (APR) are associated with high rates of genitourinary and sexual dysfunction (30–40 %),^{4–7} anastomotic leakage (5–17 %),⁸ and long-term functional bowel disturbance.⁹ Up to 40 % of patients experience perineal wound complications and long-term discomfort following APR, while stoma and stoma appliance-related complications occur in up to 66 %, associated with change in body image and depression in 30 %.¹⁰

A transanal approach to rectal malignant neoplasms, if suitable, would lower risks and improve functional results. For more than 25 years, transanal endoscopic microsurgery (TEM) had revolutionized technique and outcome of transanal surgery, becoming first the standard of treatment for large rectal adenomas,^{11–13} then offering a possible curative treatment to early rectal cancer,^{14,15} and finally, generating discussion on the potential role in the treatment of T2 rectal cancer in combination with neoadjuvant treatments in selected cases, such as in elderly and unfit patients for major surgery and in those who refuse the risk of a temporary or definitive stoma.^{16–19} The aim of this study was to compare TEM to laparoscopic resection (LR) in terms of short-term and oncologic outcomes in patients affected by a T2N0 extraperitoneal rectal cancer.

Materials and Methods

This study is a retrospective analysis of a prospective database. All patients admitted to our institution with histologically proven adenocarcinoma of the mid and lower rectum, preoperatively staged T2N0, were referred for LR. Patients refusing abdominal surgery or medically unfit for major surgery because of severe comorbidities were considered for TEM.

The preoperative workup included clinical evaluation, total colonoscopy, chest and upper abdominal computed tomography (CT) scan, endoscopic ultrasound (EUS), and pelvic CT scan until 2003 and then pelvic magnetic resonance imaging (MRI). A tumor was considered extraperitoneal if located within 12 cm from the anal verge on the anterior wall and 15 cm on the lateral and posterior walls, corresponding to the estimated limits of the insertion of the peritoneum at rigid rectoscopy.

In most recent cases, neoadjuvant radiotherapy (RT) was discussed in a multidisciplinary setting for patients considered for TEM. RT consisted of 45 Gy along 6–8 weeks.

All patients underwent endoscopic tattoo of the rectal lesion prior to neoadjuvant therapy. Patients were reevaluated with clinical examination, rigid rectoscopy, EUS, and CT or MRI 4 weeks after the completion of the treatment. Only responders, defined as those in whom clinical downstaging or downsizing was observed, were indicated for TEM. All the others were referred for LR or underwent TEM with palliative intent. Downstaging was defined as a lower T staging at the imaging studies, while downsizing was defined as reduction of tumor diameter greater than 50 % at rigid rectoscopy. In all cases, the surgical procedure was performed 6 weeks after the completion of neoadjuvant treatment.

The postoperative strategy in patients who underwent a TEM procedure (abdominal surgery, adjuvant RT, or a strict follow-up) was decided individually in a multidisciplinary setting including surgeon, medical and radiation oncologist, and patient based on the anatomopathological findings and the clinical conditions of the patient.

Only patients with a minimum follow-up of 36 months were included. Clinical analyzed parameters included patient's characteristics (age and gender), length of operative procedure, conversion rate to laparoscopy or laparotomy, pathological examination (stage of disease according to the tumor-node-metastasis-TNM-classification, number of lymph nodes harvested, lymphovascular invasion, and longitudinal and radial margins of excision), length of hospital stay, morbidity at 30 days according to Dindo,²⁰ and oncologic outcome. Follow-up consisted of digital examination, rectoscopy, and tumor markers every 3 months for the first 2 years and then every 6 months; a full colonoscopy was performed at 12 months and then every 3 years; and a chest and abdominopelvic CT scan at 6 and

12 months and then annually. Data were collected prospectively from the time of diagnosis using a custom-written computerized data base.

Statistics

Quantitative data are given as median and range. Chi-square tests were used to compare proportions. Univariate analysis of survival was performed using the Kaplan–Meier method and the evaluation of differences between groups was performed with the logrank test. All survival analyses were performed on an “intention-to-treat” basis, i.e., those patients that did not demonstrate downstaging or downsizing after RT, although undergoing abdominal surgery, were considered part of the TEM group. A level of 5 % was set as the criterion for statistical significance. The data was collected in an Excel spreadsheet. The statistical analysis was performed using SYSTAT Version 10 (Copyright © SPSS, Inc., 2000).

Results

Between April 1999 and April 2009, 289 patients with extraperitoneal rectal cancer were admitted to our institution: 78 had preoperatively staged T2N0 lesion. Thirty-five (45 %) of them were eligible for LR. TEM was indicated in the remaining 43 (55 %) patients for the following reasons: 31 patients refused the risk of temporary or definitive stomas and 12 were judged unfit for abdominal resection due to severe comorbidities. Out of 31 patients who refused abdominal surgery, 11 underwent neoadjuvant RT (Fig. 1).

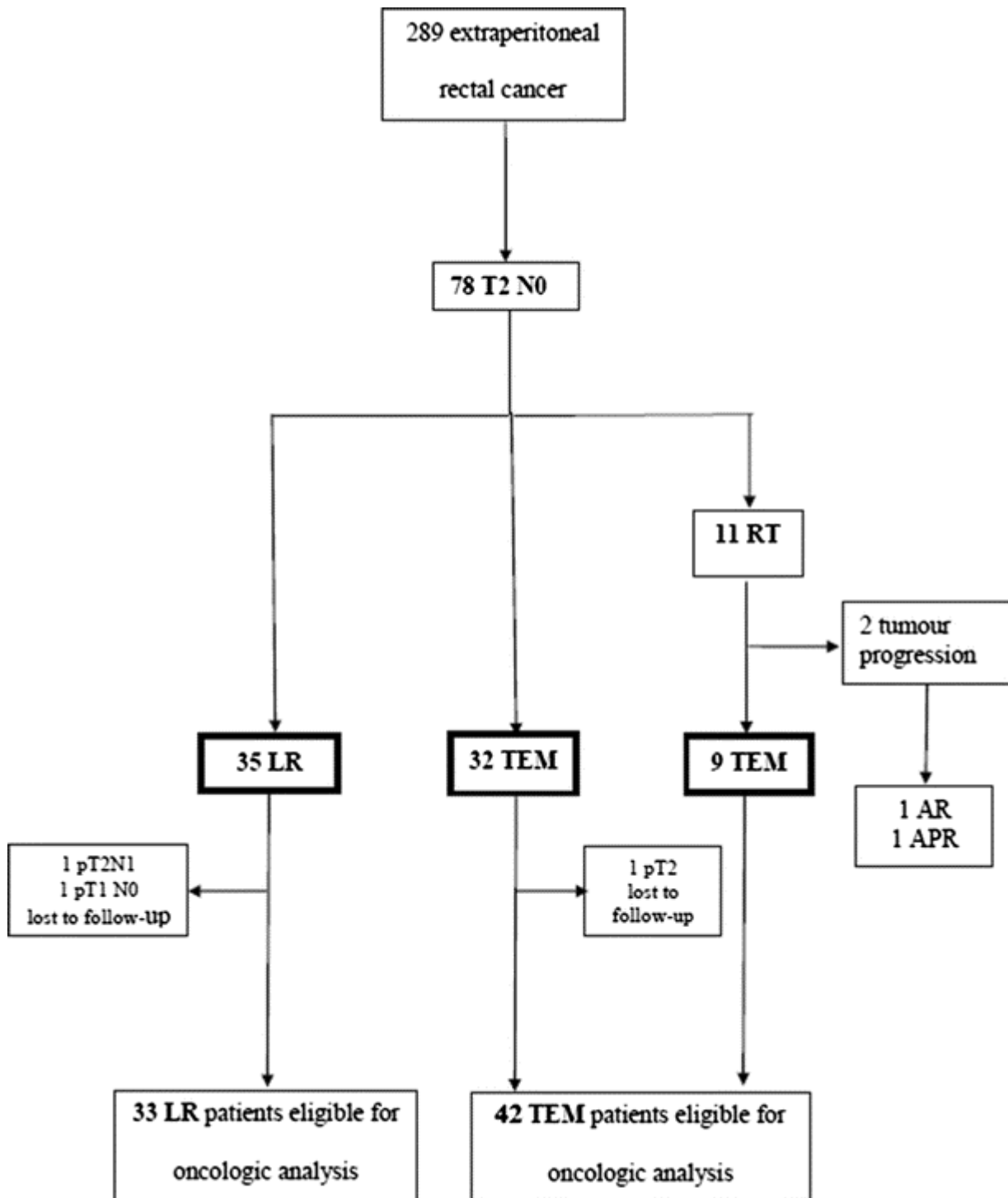


Fig. 1

Flow chart of patients in the study. *RT* radiotherapy, *LR* laparoscopic resection, *TEM* transanal endoscopic microsurgery, *AR* anterior resection, *APR* abdominoperineal resection

Among the 11 patients who received neoadjuvant RT, side effects of RT consisted of skin erythema in five (45 %) patients and cystitis in two (18 %) patients. All patients completed the course of RT. A response to RT in terms of downsizing was observed in nine (82 %) cases, and among them, four also showed downstaging (36 %). In two cases (18 %), a local tumor progression was observed, for which both patients underwent open surgery (one AR and one APR).

No statistically significant difference was observed between groups for patients' characteristics, except for a higher incidence of cardiopulmonary comorbidities in the TEM group ($p < 0.001$) (Table 1). Particularly, no significant differences were noted in terms of distance of the tumor from

the anal verge in the RT + TEM, TEM, and LR groups: 6 (range, 3–9), 6.5 (range 5–11), and 5 (range, 1–12) cm ($p = 0.274$).

Table 1

Main patients' characteristics

	TEM ($n = 41$)	LR ($n = 35$)	<i>P</i> value
Gender			
Male: <i>n</i> (%)	16 (39)	16 (45.7)	0.721
Age (years): Median, range	72 (38–91)	65 (34–90)	0.198
Number of comorbidities: Median, range	2 (0–4)	1 (0–2)	<0.001
Distance from the anal verge (cm): median, range	6 (3–11)	5 (1–12)	0.243
Tumour size (cm): median, range	3 (1–4)	4(2–6)	0.422
Tumour location, <i>n</i> (%):			
Anterior	7 (17.1)	6 (17.1)	0.760
Lateral	21 (51.2)	20 (57.1)	0.777
Posterior	13 (31.7)	9 (25.8)	0.755

LR laparoscopic resection, TEM transanal endoscopic microsurgery

Intraoperative Results

The median operative time was 75 (range, 30–240) min in the TEM group and 195 (range, 120–300) min in the LR group ($p < 0.001$). Median intraoperative blood loss was significantly lower in the TEM group (30 vs. 100 ml; $p < 0.001$). No patient required intraoperative blood transfusion in the TEM group, compared to two (5.7 %) in the LR group ($p = 0.396$). Conversion rate to open surgery was nil in the TEM group and 2.8 % in the LR group because of severe obesity (one case) ($p = 0.953$). No stoma was required in the TEM group, whereas a stoma was performed in all cases in the LR group ($p < 0.001$): in 28 patients, a temporary stoma after AR and in seven patients, a definitive stoma after APR (Table 2).

Table 2

Perioperative results

	TEM ($n = 41$)	TEM only ($n = 32$)	RT + TEM ($n = 9$)	LR ($n = 35$)	<i>P</i> value ^a
Operative time (min): Median, range	75 (30–240)	90 (30–240)	60 (45–50)	195 (120–300)	<0.001
Intraoperative blood loss (ml): Median, range	30 (10–75)	30 (10–75)	30 (20–50)	100 (50–700)	<0.001
Conversion to open surgery (%)	0	0	0	1 (2.8)	0.953
Stoma, <i>n</i> (%)	0	0	0	35(100)	<0.001
Stools (day): Median, range	3 (2–5)	3 (2–4)	3 (2–5)	4 (2–9)	<0.001
Hospital stay (day): Median, range	5 (3–8)	5 (3–8)	5 (3–7)	10 (5–25)	<0.001

TEM transanal endoscopic microsurgery, RT radiotherapy, LR laparoscopic resection

^aTEM group vs. LR group

Postoperative Results

Return to a normal bowel function occurred earlier in the TEM group than the LR group ($p < 0.001$) (Table 2). The median hospital stay was 5 (range, 3–8) days in the TEM group and 10 (range, 5–25) days in the LR group ($p < 0.001$).

Morbidity is reported in Table 3. Incidence (14.6 % vs. 37.1 %, $p = 0.046$) and severity were significantly lower in the TEM group. No suture dehiscence was observed in the RT + TEM group. In no case after TEM further surgery for complications was required, while following LR, five patients required further surgery (two small bowel obstructions, two stoma stenosis, and one anastomotic leakage); two patients, a percutaneous drainage of a pelvic abscess; and three patients, an endoscopic balloon dilation of anastomotic stricture. Twenty-five out of 28 (89.3 %) patients with a temporary loop ileostomy underwent a reversal of the stoma, with no complication. TEM after neoadjuvant RT was not associated with an increased morbidity rate (Table 3). There was no postoperative 30-day mortality.

Table 3
Postoperative morbidity according to Dindo classification

	TEM ($n = 41$)	TEM only ($n = 32$)	RT + TEM ($n = 9$)	LR ($n = 35$)	<i>P</i> value ^a
Postoperative complications, <i>n</i> (%)	6 (14.6)	5 (15.6)	1 (11.1)	13 (37.1)	0.046
Grade I	0	0	0	2 (5.7)	0.396
Grade II	6 (14.6)	5 (15.6)	1 (11.1)	1 (2.9)	0.174
Grade III	0	0	0	10 (28.6)	<0.001
IIIa				5 (14.3)	1
IIIb				5 (14.3)	
Grade IV	0	0	0	0	
Grade V	0	0	0	0	

TEM transanal endoscopic microsurgery, RT radiotherapy, LR laparoscopic resection

^aTEM group vs. LR group

Pathology Results and Staging

No significant differences were noted on the preoperative biopsy in terms of distribution of well (27.3 % vs. 25 % vs. 28.6 %; $p = 0.947$), moderately (54.5 % vs. 53.1 % vs. 57.1 %; $p = 0.946$), and poorly differentiated (18.2 % vs. 21.9 % vs. 14.3 %; $p = 0.721$) tumors among RT + TEM, TEM and LR groups. Lymphovascular invasion was noted in one (3.1 %) patient of the TEM group and in one (2.9 %) patient in the LR group.

The definitive histopathological examination of the nine T2N0 rectal adenocarcinomas resected by TEM after neoadjuvant RT showed a downstaging in four (44 %) patients (ypT0 in two cases and ypT1 sm2 in the other two cases), while ypT2 diagnosis was confirmed in five patients. In all cases, resection margins were clear, the resection was judged full thickness, and no specimen fragmentation occurred. No lymphovascular invasion was observed. No perirectal lymph nodes were detected.

Among the other 32 patients who underwent TEM without neoadjuvant RT, the postoperative staging was as follows: 6 pT1 sm3, 24 pT2, and 2 pT3. Lymphovascular invasion was detected in two (6.3 %) cases. Invaded lateral resection margins were reported in four (12.5 %) patients. No deep margin invasion was detected. Occasionally, a lymph node metastasis was demonstrated in two pT2 specimens (one with lymphovascular invasion).

The definitive histopathological examination of the 35 patients treated by LR confirmed a pT2N0 adenocarcinoma in 33 cases, whereas it demonstrated a pT2 N1 in two cases, with no evidence of lymphovascular invasion. Lymphovascular invasion was present in three specimens. The median number of lymph nodes harvested was 13 (range, 4–23). No involvement of distal and circumferential resection margins occurred.

Oncologic Outcome

During a median follow-up of 70 (range, 36–140) months, one (2.4 %) patient (pT2) was lost to follow-up in the TEM group and two (6.6 %) in the LR group (one pT1 N0 and one pT2 N1), and none in the RT + TEM group (Fig. 1). Both patients who had a local tumor progression during neoadjuvant RT and underwent open surgery died of distant metastases at 15 and 17 months, without local recurrence.

All other patients in the RT + TEM group are disease-free. No patient has been reoperated.

Of the 31 patients primarily treated by TEM, two pT2N1 and one pT3 patients accepted a further surgical treatment consisting, in all cases, of TME at a median time of 40 days after TEM. No perioperative complications occurred. Residual tumor cells were found in the muscular layer in the resected specimen in two cases, while a perirectal lymph node metastasis was present in one case. All patients are disease-free 36, 40, and 45 months after TEM, respectively.

Ten patients (one pT1 sm3, one pT2 with positive margins, seven pT2 with negative margins, and one pT3) underwent adjuvant RT. The recurrence rate was 30 % (3/10): one patient died of liver metastases at 58 months while two are disease-free after further surgery for local recurrence at 44 months and 48 months, respectively.

The remaining 18 patients (five pT1 sm3, and 13 pT2) either refused (seven patients) or were deemed ineligible (11) for any adjuvant treatment on account of age or comorbidity. Among them, five (28 %) patients experienced local recurrences. All underwent abdominal surgery: four are disease-free at 19, 23, 28, and 31 months, while one died of the disease at 42 months.

In the LR group, only the pT2 N1 patient underwent postoperative chemotherapy. A recurrence was observed in three (9 %) patients: one patient died of a spread disease at 28 months, while two patients are disease-free after abdominal surgery for local relapse at 31 and 35 months, respectively.

Overall, a trend toward a higher local recurrence rate was observed in the 31 patients primarily treated by TEM (26 %), compared to patients who underwent LR (9 %) or neoadjuvant RT followed by TEM (0 %) ($p=0.070$); the overall 5-year survival rates were 76 %, 96 %, and 77.8 %, respectively ($p=0.134$) (Fig. 2).

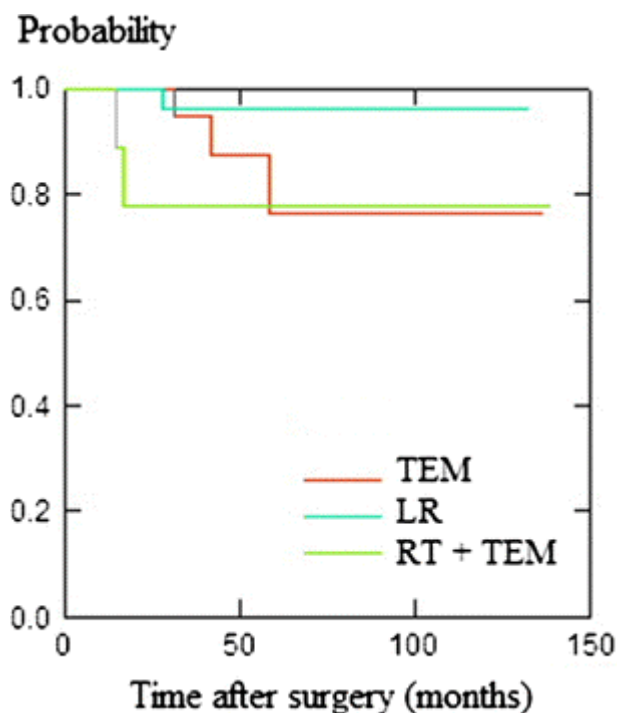


Fig. 2 Overall survival rate of T2N0 cancer patients submitted to TEM, LR or RT + TEM ($P=0.134$; logrank test). *TEM* transanal endoscopic microsurgery, *LR* laparoscopic resection, *RT* radiotherapy

Discussion

Abdominal surgery has long been considered the appropriate surgical treatment for rectal neoplasms. Nevertheless, it is burdened by consistent morbidity and mortality rates. Classical transanal surgery with retractors, although less invasive, is associated with a high incidence of local recurrence, especially for tumors of the mid rectum.^{21–24}

Almost 30 years ago, the introduction of TEM afforded the advantage of combining a less invasive transanal approach with low recurrence rates thanks to enhanced visualization of the surgical field which allowed more precise dissection. Initially proposed as a technique for excision of benign rectal neoplasms, TEM indications were extended to include “low risk” pT1 rectal adenocarcinomas²⁵ with curative intent²⁶ and more invasive rectal adenocarcinomas with palliative intent.

Today, the role of TEM in the treatment of invasive rectal cancer is controversial. A critical issue of transanal excision concerns lymph node sampling. The incidence of lymph node metastasis is very low for T1 sm1-2, but for T1 sm3 and for T2, it rises up to 25%.²⁷ All preoperative staging methods seem insufficiently reliable in determining node involvement. Even if EUS appears to be the most accurate preoperative diagnostic tool for investigating the tumor invasion of the rectal wall and MRI for the lymph node involvement,²⁸ there is a consistent discrepancy between preoperative and definitive histological staging of the tumors.^{28,29}

Recent advances in radiation therapy have led to an improvement in local control of rectal cancer. RT allows reduction of the diameter of the lesion and sterilization of mesorectal lymph nodes,^{30–33} thus reducing the local recurrence rate. RT can induce a complete pathological response in 10% to 30% of patients, which is burdened by a risk of 5% to 10% of lymph node metastases, compared to 30% to 64% in the case of less radiosensitive tumors.³⁴ During the past decade, major efforts have been done towards more individualized and tailored management strategies of patients with rectal cancer. In the case of complete clinical response after neoadjuvant treatment, a “wait and see” strategy has been proposed.³ However, the correlation between complete clinical response and pathological response is poor. Recently, Smith et al.³⁵ evaluated the significance of residual

mucosal abnormalities after neoadjuvant therapy for rectal cancer. They found that residual mucosal abnormalities less than 3 cm were strongly associated with ypT0-1 and a lower rate (2 %) of lymph node metastases. The authors concluded that this subgroup of patients could be offered a local excision as an oncologically adequate treatment.

In this era of individualized and tailored treatment modalities, there is a growing interest in the applicability of neoadjuvant therapy even to patients with a preoperatively staged T2N0 rectal cancer in referral centers where the risk of overstaging and understaging by EUS is reduced.³⁶ The aim of this study was to evaluate short-term and long-term outcomes of TEM and LR for T2N0 extraperitoneal rectal cancer. The design of the present study was limited in that patients were retrospectively evaluated and the follow-up period was relatively short. However, the two groups of patients showed no statistically significant differences in terms of clinical characteristics. Our short-term results confirm, even in invasive cancer patients, the short term benefits of TEM in terms of operative time, blood loss, morbidity, and length of hospital stay compared to LR.

One of the key factors in avoiding local recurrence after removal of rectal cancer is complete excision with sufficient tumor-free margins. Even if TEM allows better exposure, maintaining a constant view of the margin and reducing the risk of piecemeal tumor excision increase the risk of invaded margins with a more advanced tumor stage.³⁷ A precise preoperative T staging is, therefore, crucial also from the technical point of view, as margin invasion in pT1 cancers is occasional.³⁸ Furthermore, an effort to increase the rate of free margins must be done to allow a radical local excision in the case of more advanced rectal cancers. Lezoche et al.¹⁶ have proposed a tattooing of the lesion margins at the moment of diagnosis before neoadjuvant treatment in T2N0 neoplasms.

In the present series, 11 patients who refused abdominal surgery underwent preoperative RT. In the patients with remarkable response to the neoadjuvant treatment, TEM allowed a safe and complete excision of the tumor with free surgical margins, without increased intraoperative and postoperative morbidity rates. Concerns have been raised regarding rectal suture healing in patients undergoing TEM after neoadjuvant treatment.^{17,39,40} While we did not observe suture dehiscences, complication rates related to the rectal wound reported in the literature range from 11 %¹⁷ to 25.6 %.⁴⁰ Most frequent symptoms were significant rectal pain and bleeding. Most cases have been treated conservatively, and late complications occurred in 9 %³⁹ to 21 %⁴⁰ of cases. Based on the data currently available, no definitive conclusions can be drawn concerning the relationship between neoadjuvant therapy and rectal wound dehiscence after TEM. Further larger studies with longer follow-up periods are needed to investigate also functional and oncologic outcomes in these patients.

In terms of oncologic outcomes, no local recurrence occurred. Nevertheless, we have to report in our series a failure rate of 18.2 %, due to two patients who had tumor progression during neoadjuvant treatment. Both patients developed distant metastasis and died of disease spread. The same oncologic results were obtained in the limited group of patients who underwent an immediate abdominal reoperation after TEM because of lymph node metastases in the TEM specimen or because of a pT3 cancer. Of the three patients who underwent immediate abdominal surgery, residual tumor cells were found in the muscular layer in the resected specimen in two cases (66.6 %). Lymph node metastases were confirmed in one case.

The main concern when performing a TME after a full thickness TEM is that the perirectal fat might be compromised by tumor implantation or, in any case, would be affected by a fibrotic scar making dissection of the correct planes more challenging. In order to minimize this potential negative effect, it is our policy to perform abdominal surgery 4 to 8 weeks after TEM to allow for a healing process of the mesorectum. In our experience, no intraoperative complications occurred. Our oncologic findings in this subgroup of patients, even though limited to few cases, are in line with the long-term results of Borschitz et al.¹⁹ They showed that both local recurrence and distant metastases rates were reduced as a result of immediate reoperation within 4 weeks after TEM.

The oncologic results of TEM for T2N0 rectal cancer are quite disappointing in the remnant patients of our series with a postoperative diagnosis of pT1sm3-T2-3Nx. Among patients who underwent postoperative radiotherapy, the recurrence rate was 30 %, not significantly different from that of patients who refused any adjuvant treatment after TEM (27.8 %). Nevertheless, secondary radical surgery seems to be effective in these patients, as only two patients out of 28 (7.1 %) died from recurrence.

Based on the results of our series, we propose an algorithm for the treatment of T2N0 rectal cancer (Fig. 3), where TEM is part of a multimodality strategy that relies on a careful clinical assessment, endoscopic and radiologic evaluation by EUS and MRI, and histopathological examination by dedicated pathologists.

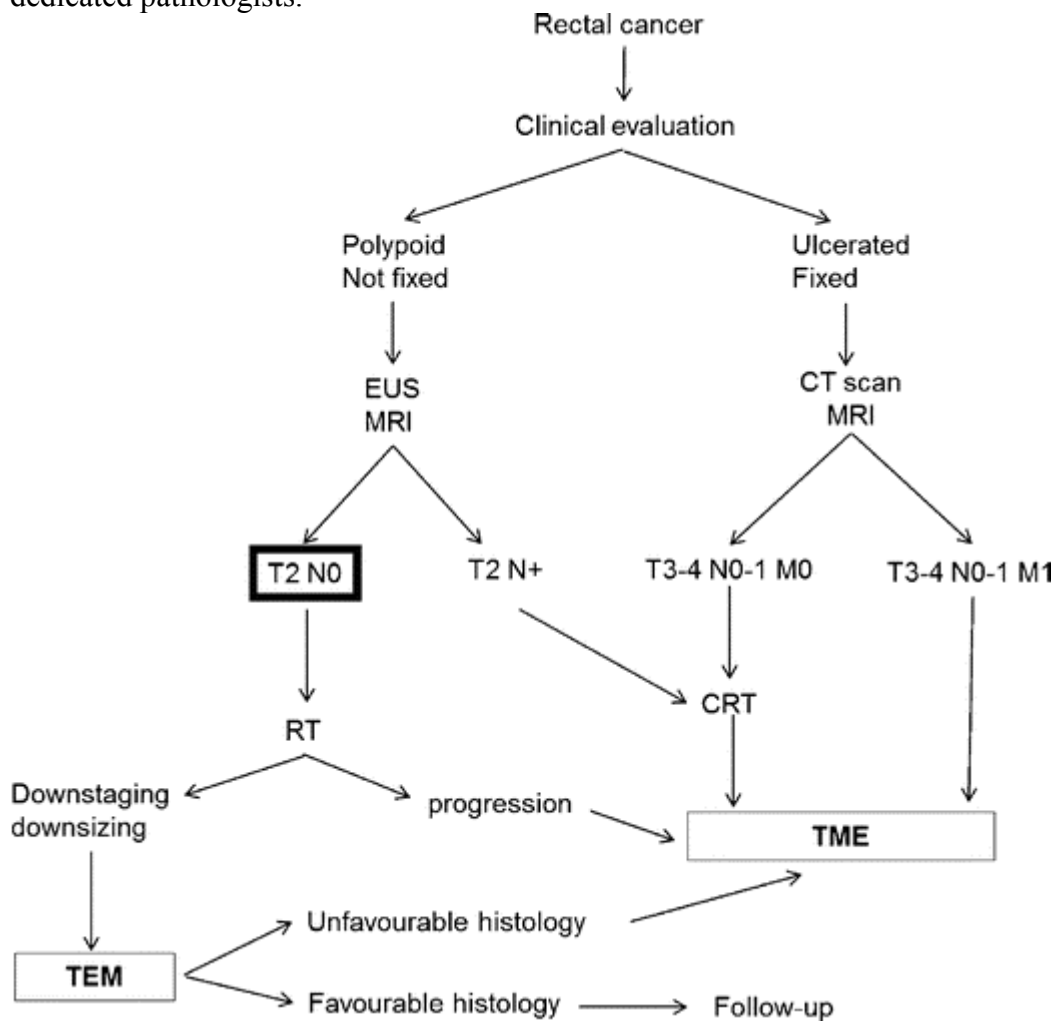


Fig. 3

Algorithm for management of T2N0 rectal cancer. *EUS* endoscopic ultrasound, *CT* computed tomography, *MRI* magnetic resonance imaging, *TEM* transanal endoscopic microsurgery, *TME* total mesorectal excision

Conclusion

The present study shows that:

- TEM for T2N0 rectal cancer is superior to LR in terms of quality of early postoperative course;
- TEM alone does not represent an adequate therapy for T2N0 rectal carcinoma, being burdened by a significantly higher recurrence rate compared to LR;

- Neoadjuvant RT followed by TEM in the case of tumor downstaging or downsizing seems to be an effective therapeutic strategy, supporting the data recently published by Lezoche et al.¹⁷; and
- The poor oncologic results obtained with abdominal surgery in nonresponders to neoadjuvant RT suggest caution before a wide application of this curative strategy.

These conclusions are biased by the small numbers and should be considered with caution. Nevertheless, these results may fuel the current debate regarding the use of neoadjuvant therapy and local excision for selected T2N0 rectal carcinomas. Further large prospective randomized trials are necessary to evaluate this treatment strategy.

References

1.

Kapiteijn E, Marijnen CA, Nagtegaal ID, Putter H, Steup WH, Wiggers T, Rutten HJ, Pahlman L, Glimelius B, van Krieken JH, Leer JW, van de Velde CJ; Dutch Colorectal Cancer Group. Preoperative radiotherapy combined with total mesorectal excision for resectable rectal cancer. *N Engl J Med* 2001;345:638–646.

2.

Wong RK, Tandan V, De Silva S, Figueredo A. Pre-operative radiotherapy and curative surgery for the management of localized rectal carcinoma. *Cochrane Database of Systematic Reviews* 2007, Issue 2. Art. No.: CD002102. DOI: [10.1002/14651858.CD002102.pub2](https://doi.org/10.1002/14651858.CD002102.pub2).

3.

Habr-Gama A, Perez RO. Non-operative management of rectal cancer after neoadjuvant chemoradiation. *Br J Surg* 2009;96:125–127.

4.

Morino M, Parini U, Allaix ME, Monasterolo G, Brachet Contul R, Garrone C. Male sexual and urinary function after laparoscopic total mesorectal excision. *Surg Endosc* 2009;23:233–240.

5.

Marijnen CA, Kapiteijn E, van de Velde CJ, Martijn H, Steup WH, Wiggers T, Kranenbarg EK, Leer JW; Cooperative Investigators of the Dutch Colorectal Cancer Group. Acute side effects and complications after short-term preoperative radiotherapy combined with total mesorectal excision in primary rectal cancer: report of a multicenter randomized trial. *J Clin Oncol* 2002;20: 817–825.

6.

Wallner C, Lange MM, Bonsing BA, Maas CP, Wallace CN, Dabhoiwala NF, Rutten HJ, Lamers WH, Deruiter MC, van de Velde CJ; Cooperative Clinical Investigators of the Dutch Total Mesorectal Excision Trial. Causes of fecal and urinary incontinence after total mesorectal excision for rectal cancer based on cadaveric surgery: a study from the

Cooperative Clinical Investigators of the Dutch total mesorectal excision trial. *J Clin Oncol* 2008;26:4466–4472.

7.

Hendren SK, O'Connor BI, Liu M, Asano T, Cohen Z, Swallow CJ, Macrae HM, Gryfe R, McLeod RS. Prevalence of male and female sexual dysfunction is high following surgery for rectal cancer. *Ann Surg* 2005;242:212–223.

8.

Morino M, Parini U, Giraud G, Salval M, Brachet Contul R, Garrone C. Laparoscopic total mesorectal excision: a consecutive series of 100 patients. *Ann Surg* 2003;237:335–342.

9.

Ho P, Law WL, Chan SC, Lam CK, Chu KW. Functional outcome following low anterior resection with total mesorectal excision in the elderly. *Int J Colorectal Dis* 2003; 18:230–233.

Williams NS, Johnston D. The quality of life after rectal excision for low rectal cancer. *Br J Surg* 1983;70:460–462.

10.

Buess G, Hutterer F, Theiss J, Böbel M, Isselhard W, Pichlmaier H. A system for a transanal endoscopic rectum operation. *Chirurg* 1984; 55:677–680.

11.

Dias AR, Nahas CS, Marques CF, Nahas SC, Ceconello I. Transanal endoscopic microsurgery: indications, results and controversies. *Tech Coloproctol* 2009; 13:105–111.

12.

Allaix ME, Arezzo A, Cassoni P, Famiglietti F, Morino M. Recurrence after transanal endoscopic microsurgery for large rectal adenomas. *Surg Endosc* 2012;26:2594–2600.

13.

Endreseth BH, Myrvold HE, Romundstad P, Hestvick UE, Bjerkeset T, Wibe A; Norwegian Rectal Cancer Group. Transanal excision vs. major surgery for T1 rectal cancer. *Dis Colon Rectum* 2005; 48:1380–1388.

14.

Morino M, Allaix ME, Caldart M, Scozzari G, Arezzo A. Risk factors for recurrence after transanal endoscopic microsurgery for rectal malignant neoplasm. *Surg Endosc* 2011;25:3683–90.

15.

Lezoche E, Guerrieri M, Paganini AM, Baldarelli M, De Sanctis A, Lezoche G. Long-term results in patients with T2-3 N0 distal rectal cancer undergoing radiotherapy before transanal endoscopic microsurgery. *Br J Surg* 2005;92:1546–1552.

16.

Lezoche G, Baldarelli M, Guerrieri M, Paganini AM, De Sanctis A, Bartolacci S, Lezoche E. A prospective randomized study with a 5-year minimum follow-up evaluation of transanal endoscopic microsurgery versus laparoscopic total mesorectal excision after neoadjuvant therapy. *Surg Endosc*. 2008;22:352–358.

17.

Duek SD, Issa N, Hershko DD, Krausz MM. Outcome of transanal endoscopic microsurgery and adjuvant radiotherapy in patients with T2 rectal cancer. *Dis Colon Rectum* 2008; 51:379–384.

18.

Borschitz T, Heintz A, Junginger T. Transanal endoscopic microsurgical excision of pT2 rectal cancer: results and possible indications. *Dis Colon Rectum* 2007;50:292–301.

19.

Dindo D, Demartines N, Clavien PA. Classification of Surgical Complications. A New Proposal With Evaluation in a Cohort of 6336 Patients and Results of a Survey. *Ann Surg* 2004;240:205–213.

20.

Sakamoto GD, MacKeigan JM, Senagore AJ. Transanal excision of large, rectal villous adenomas. *Dis Colon Rectum* 1991;34:880–885.

21.

Mellgren A, Sirivongs P, Rothenberger DA, Madoff RD, García-Aguilar J. Is local excision adequate therapy for early rectal cancer? *Dis Colon Rectum* 2000; 43:1064–1074.

22.

Parks AG, Stuart AE. The management of villous tumours of the large bowel. *Br J Surg* 1973;60:688–695.

23.

Nivatvongs S, Balcos EG, Schottler JL, Goldberg SM. Surgical management of large villous tumors of the rectum. *Dis Colon Rectum* 1973;16:508–514.

24.

Hermanek P, Gall FP. Early (microinvasive) colorectal carcinoma. Pathology, diagnosis, surgical treatment. *Int J Colorectal Dis* 1986;1:79–84.

25.

Mentges B, Buess G, Raestrup H, Manncke K, Becker HD. TEM results of the Tuebingen group. *Endosc Surg Allied Technol* 1994;2:247–250.

26.

Sengupta S, Tjandra JJ. Local excision of rectal cancer: what is the evidence? *Dis Colon Rectum* 2001;44:1345–1361.

27.

Påhlman L, Torkzad MR. Rectal cancer staging: is there an optimal method? *Future Oncol* 2011;7:93–100.

28.

Ashraf S, Hompes R, Slater A, Lindsey I, Bach S, Mortensen N, Cunningham C; on behalf of the Association of Coloproctology of Great Britain and Ireland Transanal Endoscopic Microsurgery (TEM) Collaboration. A critical appraisal of endorectal ultrasound and transanal endoscopic microsurgery and decision-making in early rectal cancer. *Colorectal Dis* 2012;14:821–826.

29.

Wichmann MW, Müller C, Meyer G, Strauss T, Hornung HM, Lau-Werner U, Angele MK, Schildberg FW. Effect of preoperative radiochemotherapy on lymph node retrieval after resection of rectal cancer. *Arch Surg* 2002;137:206–210.

30.

Kaminsky-Forrett MC, Conroy T, Luporsi E, Peiffert D, Lapeyre M, Boissel P, Guillemin F, Bey P. Prognostic implications of downstaging following preoperative radiation therapy for operable T3-T4 rectal cancer. *Int J Radiat Oncol Biol Phys* 1998;42:935–941.

31.

Bouzourene H, Bosman FT, Seelentag W, Matter M, Coucke P. Importance of tumor regression assessment in predicting the outcome in patients with locally advanced rectal carcinoma who are treated with preoperative radiotherapy. *Cancer* 2002;94:1121–1130.

32.

Willett CG, Warland G, Hagan MP, Daly WJ, Coen J, Shellito PC, Compton CC. Tumor proliferation in rectal cancer following preoperative irradiation. *J Clin Oncol* 1995; 13:1417–1424.

33.

Smith FM, Waldron D, Winter DC. Rectum-conserving surgery in the era of chemoradiotherapy. *Br J Surg* 2010;97:1752–1764.

34.

Smith FM, Chang KH, Sheahan K, Hyland J, O’Connell PR, Winter DC. The surgical significance of residual mucosal abnormalities in rectal cancer following neoadjuvant chemoradiotherapy. *Br J Surg* 2012;99:993–1001.

35.

Marusch F, Ptok H, Sahm M, Schmidt U, Ridwelski K, Gastinger I, Lippert H. Endorectal ultrasound in rectal carcinoma—do the literature results really correspond to the realities of routine clinical care? *Endoscopy* 2011;43:425–431.

36.

Bach SP, Hill J, Monson JR, Simson JN, Lane L, Merrie A, Warren B, Mortensen NJ; Association of Coloproctology of Great Britain and Ireland Transanal Endoscopic Microsurgery (TEM) Collaboration. A predictive model for local recurrence after transanal endoscopic microsurgery for rectal cancer. *Br J Surg* 2009;96:280–290.

37.

Allaix ME, Arezzo A, Caldart M, Festa F, Morino M. Transanal endoscopic microsurgery for rectal neoplasms: experience of 300 consecutive cases. *Dis Colon Rectum* 2009;52:1831–1836.

38.

Perez RO, Habr-Gama A, São Julião GP, Proscurshim I, Scanavini Neto A, Gama-Rodrigues J. Transanal Endoscopic Microsurgery for residual rectal cancer after neoadjuvant chemoradiation therapy is associated with significant immediate pain and hospital readmission rates. *Dis Colon Rectum* 2011;54:545–551.

39.

Marks JH, Valsdottir EB, DeNittis A, Yarandi SS, Newman DA, Nweze I, Mohiuddin M, Marks GJ. Transanal endoscopic microsurgery for the treatment of rectal cancer: comparison of wound complication rates with and without neoadjuvant radiation therapy. *Surg Endosc* 2009; 23:1081–1087.