

AperTO - Archivio Istituzionale Open Access dell'Università di Torino

**Retrospective comparison between minimally invasive plate osteosynthesis and open plating for tibial fractures in dogs**

**This is the author's manuscript**

*Original Citation:*

*Availability:*

This version is available <http://hdl.handle.net/2318/123789> since 2016-10-03T16:29:26Z

*Published version:*

DOI:10.3415/VCOT-11-07-0097

*Terms of use:*

Open Access

Anyone can freely access the full text of works made available as "Open Access". Works made available under a Creative Commons license can be used according to the terms and conditions of said license. Use of all other works requires consent of the right holder (author or publisher) if not exempted from copyright protection by the applicable law.

(Article begins on next page)



UNIVERSITÀ DEGLI STUDI DI TORINO

This is an author version of the contribution published on:

Boero Baroncelli A, Peirone B, Winter MD, Reese DJ, Pozzi A  
Retrospective comparison between minimally invasive plate osteosynthesis  
and open plating for tibial fractures in dogs

VETERINARY AND COMPARATIVE ORTHOPAEDICS AND  
TRAUMATOLOGY (2012) 5

DOI: 10.3415/VCOT-11-07-0097

The definitive version is available at:

<http://www.schattauer.de/index.php?id=1214&doi=10.3415/VCOT-11-07-0097>

# Retrospective comparison between minimally invasive plate osteosynthesis and open plating for tibial fractures in dogs

A. Boero Baroncelli<sup>1</sup>; B. Peirone<sup>1</sup>; M. D. Winter<sup>2</sup>; D. J. Reese<sup>2</sup>; A. Pozzi<sup>2</sup>

<sup>1</sup>Department of Animal Pathology, College of Veterinary Medicine, University of Turin, Grugliasco (TO), Italy; <sup>2</sup>Department of Small Animal Clinical Sciences, College of Veterinary Medicine, University of Florida Gainesville, FL, USA

## Keywords

Minimally invasive plate osteosynthesis, indirect reduction, fracture healing, tibial fractures, internal fixation

## Summary

**Objectives:** To compare fracture healing in diaphyseal tibial fractures stabilized using either minimally invasive plate osteosynthesis (MIPO) or open reduction and internal fixation (ORIF).

**Methods:** Dogs in each group were matched for type of fracture, age and body weight. Stage of healing was measured blindly every four weeks postoperatively until complete healing. Outcome variables including fracture length, plate length, plate bridging ratio, plate working length, healing grading, and fracture reduction were compared between groups using the Mann-Whitney test. Significant difference was set at  $p < 0.05$ .

**Results:** Based on the definition of clinical union, at 30 days five out of eight dogs managed with MIPO had healed, while two of the eight of dogs managed with ORIF had healed. We did not find any significant differences in the other outcome measures. No complications were reported in the MIPO group whereas one major complication was reported in the ORIF group.

**Clinical significance:** All dogs treated by MIPO healed rapidly without any complications, nevertheless the difference in radio-graphic healing between the two groups was not significant.

## Introduction

Minimally invasive plate osteosynthesis (MIPO) is the most recent evolution of biological osteosynthesis because the fracture site is not exposed and the bone fragments are reduced with indirect reduction techniques (1, 2). These techniques rely on aligning fragments by distracting the bone ends instead of directly manipulating the bone at the fracture site (3, 4). This method results in minimal disturbance to the fracture haematoma and preservation of the periosteal blood supply to the bone (5). After performing small surgical approaches at the most proximal and distal parts of the bone and creating an epiperiosteal tunnel using a blunt instrument, the plate is advanced through the resulting skin incisions. Screws are applied at the ends of the plate through the insertion incisions, or if necessary, through additional stab incisions (6, 7). Although successful application of MIPO in

dogs has been described in several studies, comparative studies evaluating MIPO and other techniques are lacking (6–13). In a recent study, the healing times based on radiographic and ultrasonographic examination of radial fractures were compared between two groups of dogs treated by MIPO or by open reduction and internal fixation (ORIF) (14). The authors concluded that dogs treated with MIPO healed in half of the time and with significantly more callus formation than dogs treated with ORIF (14). All dogs healed in less than three months without any complications, suggesting that both techniques could result in successful outcome after radial fractures repair.

The purpose of this retrospective study was to compare time to radiographic and clinical union in tibial diaphyseal fractures treated by MIPO or ORIF techniques. Our hypothesis was that MIPO would result in faster healing times and fewer complications than ORIF.

## **Material and methods**

The clinical records of twenty-two dogs, which were admitted between April 2007 and September 2010 to the Veterinary Teaching Hospital at the College of Veterinary Medicine, University of Turin, Italy (VTH-A) or the Small Animal Hospital at the College of Veterinary Medicine, University of Florida, USA (VTH-B), with a tibial diaphyseal fracture that was subsequently treated with the MIPO technique together with radiographic follow-up of bone healing were evaluated. Eight dogs (5 from VTH-A, 3 from VTH-B) with complete radiographic follow-up were selected for a cohort study. The dogs were re-examined at 30, 60 and 90 days after surgery. If the fracture was healed at 30 days, the dogs were not re-examined at 60 and 90 days. For each one of the eight dogs managed with MIPO, a matched case treated with ORIF was identically analysed. This control cohort was chosen by matching cases having the same type of fracture and the same body weight as the dogs of the MIPO group (15). In order to match cases with similar ages, dogs were divided into four groups (16). Group 1: dogs under three-months-old; group 2: dogs from three- to six-months-old; group 3: dogs from six- to 12-months-old; and group 4: dogs over one-year-old. All the patients underwent MIPO or ORIF within five days from the trauma. The selection of the cases was done by one author (ABB) who chose the best possible matched case from a pool of consecutive cases with complete follow-up that were treated with ORIF in our hospitals and in another affiliated referral clinic, Affiliated Veterinary Specialists in Jacksonville, Florida, USA (Fig. 1A and Fig. 1B).

### **Surgical technique**

Methadone (0.2 mg/kg, IM) was administered for pre-medication. General anaesthesia was induced by administration of propofol (1–2 mg/kg, IV) and maintained with 1.5–2% isoflurane in oxygen. Cefazolin (20 mg/kg IV) was administered at induction and every 90 minutes during the procedure. The limb was prepared for aseptic surgery in a routine fashion.

Open reduction and internal fixation was performed with an open approach, direct reduction and application of plate and screws as previously described (17). A medial approach to the tibia was used in all cases (18). The length of the plate as

well as the number and position of the screws were selected at the surgeon's discretion. Bone graft was used in one dog. For the MIPO group, indirect fracture reduction was achieved by means of skeletal traction in dogs treated at the VTH-A. An external fixator along with intramedullary pins or point reduction forceps were used percutaneously in the others dogs treated at the VTH-B.

For intraoperative skeletal traction, a dedicated surgical table was used with the patient positioned in dorsal recumbency as previously described (4). In the cases where skeletal traction was not used, indirect reduction using an intramedullary pin was accomplished by inserting a Steinmann pin proximo-to-distal in a normograde fashion. The size of the pin ranged between 30% and 50% of the tibial medullary canal diameter. Bone-holding forceps applied to the distal fragment through the distal incision or percutaneously were used to align the fracture fragments while inserting the intramedullary pin. In one case a single block circular external fixator with two arches was used.

Alignment was assessed by fluoroscopy. Intraoperative radiology was used in patients treated with skeletal traction to evaluate fracture alignment and reduction (Fig. 2). Direct palpation of the medial aspect of the tibia was also used to assess reduction in simple and mildly comminuted fractures by evaluating the alignment of the medial cortex of the tibia. After insertion of the intramedullary pin to the level of the fracture, the distal fragment was aligned with the proximal fragment under fluoroscopic visualization. In six of the eight cases, a pre-contoured plate was used to reduce and align the fracture fragments in the frontal plane. Plate pre-contouring was achieved preoperatively using the cranio-caudal radiographic view of the contralateral tibia.

After reducing the fracture, proximal and distal insertion incisions were made to approach the tibia, as previously described (9, 13). An epiperiosteal tunnel was prepared using straight Metzemaum scissors to preserve the periosteum. The plate was inserted and then fixed temporarily with the 'pinstoppers' or with a 'push-pull device' (Fig. 3). This temporary fixation allowed evaluation of the limb alignment and implant position using fluoroscopy or intra-operative radiographs. Adjustments to plate contouring and plate position were made before fixing the plate with screws. When using LCP plates, non-locking screws were used first to reduce the distance between the plate and the bone. Then, after re-assessing the limb alignment, locking screws were placed through the insertion incisions.

Additional locking screws were added through stab incisions in some cases. The proximal and the distal incisions were sutured and a modified Robert-Jones bandage was applied for 24 hours postoperatively.

After discharge the owners of the dogs included in both groups were encouraged to perform passive range-of-motion and cold compression therapy on the injured limb for the first two weeks. Non-steroidal anti-inflammatory drugs were prescribed for two weeks postoperatively. The dogs were allowed to walk on a leash for 10–15 minutes duration several times a day for the first four weeks. Following the first re-evaluation, the duration of the walk was increased to 20–30 minutes. Owners were advised to confine their dogs to a cage when unsupervised until the fracture had obtained radiographic signs of union.

## Outcome measures

Orthogonal radiographs of the tibia were obtained in all cases preoperatively, postoperatively, and at each scheduled re-examination. Each fracture was evaluated for alignment, reduction, and stage of healing. To assess the frontal plane alignment, the mechanical medial proximal and distal tibial angles (mMPTA and mMDTA) were measured on postoperative radiographs and compared to previously reported values (19). Sagittal plane alignment was assessed by measuring the tibial plateau angle (TPA) on the medio-lateral view (19). Torsional alignment was defined as 'acceptable' when the metatarsal angulation was visually within  $10^\circ$  from the sagittal plane and 'non acceptable' when it was greater than  $10^\circ$  (13). Fracture reduction was measured as a percentage of cortical translation in the frontal and sagittal planes using an image-viewing software on the immediate post-operative films. Translational malalignment was determined as a ratio of the maximal displacement to the width of the diaphysis on both the medio-lateral and cranio-caudal views (20). The plate type, length and size were reported for each case. The plate bridging ratio was measured on radiographs and expressed as a percentage of the total tibial length, as measured from the eminences to the malleolus in the medio-lateral view (13). The plate working length was considered as the distance between the innermost screws and reported as a percentage of the plate length (21). The fracture length was measured as the distance between the fracture ends, and recorded as a percentage of the tibial length.

The radiographs were reviewed blindly by two radiologists (MDW, DJR) who graded by consent the stage of healing at 30 and 60 days postoperatively. Radiographic union and progression of fracture healing at the re-evaluation visits were graded using a previously described radiographic grading system (22) (Table 1). A healed fracture was defined as being complete with iso opaque bridging of two cortices or a grade of 2 or lower according to the grading system (22). In addition to measuring radiographic union, we evaluated clinical union. Clinical union has been previously used as an outcome measure in a study reporting MIPO for tibial fractures in dogs (13). Clinical union was defined as the presence of a bridging callus or a callus 50% of the tibial diameter at the level of the fracture site on three of four cortices on two orthogonal views.

Minor complications were defined as those which resolved with medical therapy and without a second surgical treatment. A complication was considered major when it required a revision surgery under anaesthesia for resolution. Clinical outcome was assessed by the clinician at the 30 and 60 days follow-up re-evaluation.

## Statistical analysis

The mean healing grading of radiographic union and the implant variables (plate bridging ratio, fracture length, plate length and plate working length) were compared between treatment groups using a Mann-Whitney test. A non-parametric test was selected based on the small sample size of the treatment groups. Significant difference was set at  $p < 0.05$ .

The mean  $\pm$  SD age, body weight and outcome measures of the MIPO and ORIF cohorts are reported in Tables 2 and 3. In both groups there were an equal number

of comminuted fractures (6 dogs) and simple fractures (2 dogs). One fracture in the MIPO group was open and classified as a Gustillo grade 1 (23). Mean ages at the time of injury in the MIPO group ( $60 \pm 51$  months) and in the ORIF group ( $57 \pm 44$  months) were not significantly different. Mean body weight in the MIPO group ( $28.5 \pm 9.9$  kg) and in the ORIF group ( $26.6 \pm 11.1$  kg) were not significantly different.

The implants used for fracture fixation are summarized in Table 3.

At 30 days after surgery, clinical union was observed in five of the eight fractures in the MIPO group and in two of the eight fractures in the ORIF group. At 60 days all of the eight fractures in the MIPO group were healed while seven of the eight fractures in the ORIF group were healed. When comparing healing grading we did not find any significant difference between groups at 30 days ( $p = 0.95$ ). Statistical analysis could not be performed at 60 days because the dogs that were healed at 30 days did not return for additional radiographic evaluation.

Postoperative mean  $\pm$  SD mMPTA and mMDTA of dogs managed with MIPO were  $96.4^\circ \pm 4.0^\circ$  and  $93.1^\circ \pm 3.9^\circ$ , respectively. For the dogs managed with ORIF mean  $\pm$  SD mMPTA and mMDTA were  $91.3^\circ \pm 5.8^\circ$  and  $95.2^\circ \pm 2.7^\circ$ . Postoperative mean  $\pm$  SD TPA were  $23.4^\circ \pm 4.7^\circ$  in the MIPO group and  $25.4^\circ \pm 4.1^\circ$  in the ORIF group. Torsional alignment was considered acceptable in all dogs of both groups.

Regarding fracture reduction, the mean bone segment translation of the MIPO was  $9.1 \pm 10.4\%$  on the medio-lateral view and  $10.8 \pm 10.5\%$  on the cranio-caudal view. For the ORIF, the mean bone segment translation was  $13.8 \pm 16.9\%$  in the frontal plane and  $13.8 \pm 10.6\%$  in the sagittal plane. The mean  $\pm$  SD healing grading, plate length, plate bridging ratio, fracture length, plate working length and segment traslation as well as statistical comparisons are listed in Table 4.

In one dog from the ORIF group, a 90-day radiographic follow-up was performed because the fracture was not healed at 60 days. Clinical follow-up performed 30 days postoperatively showed an excellent limb function, without any signs of lameness in all the patients of the MIPO cohort. All dogs managed with MIPO healed without complications. One dog managed with ORIF was presented 60 days postoperatively with acute non-weight bearing lameness. Proximal rod migration had occurred and was successfully treated with rod removal under sedation. In this case, plate and screw removal was also performed 90 days after surgery due to screw pull-out from the proximal segment. The other seven dogs of the ORIF group had good limb function at the 30 days follow-up. No minor complications were recorded in the ORIF group.

## Discussion

Based on our results we rejected the hypothesis that dogs managed with MIPO healed faster than dogs managed with ORIF in this pilot cohort study. Although most dogs managed with MIPO were healed by the 30 days re-evaluation, there was no significant difference in the healing grading found between the two treatment groups. It is important to interpret our results cautiously considering the limitations of the study. More frequent and consistent radiographic evaluations are needed to accurately define the time to radiographic union. Additionally, the criteria used to define union of the fracture may have influenced our results. The grading score from Hammer et al. evaluates callus and fracture line, thus it may not be appropriate for evaluation of simple fractures. These fractures probably healed by primary bone healing, thus making it difficult to define the exact time to radiographic union.

Although MIPO offers several theoretical advantages over ORIF, few clinical studies to date have shown a difference in healing time between fractures treated with the two surgical techniques (5, 13). Our results are similar to a recent study in humans which compares MIPO and ORIF techniques for the treatment of distal tibia fractures (24). The authors concluded that compared to MIPO and intramedullary nailing, ORIF should be considered the gold standard for distal tibia fracture management (24). Because of the limitations of our study we cannot provide guidelines regarding selection of MIPO or ORIF for diaphyseal fractures. Instead, our study should be considered a pilot for a future prospective study evaluating MIPO and ORIF for diaphyseal fractures. In addition to time to healing, functional outcome should also be evaluated because minimally invasive surgery may allow an earlier return to function than open fracture fixation (25).

In this study we did not intend to compare specific implants. The choice of implant was dictated by the surgeon and included both locking and non-locking plates. Most of the plates used in the MIPO cases were Fixin plates. Based on our experience, the design of Fixin plates is suited for the application of the MIPO technique (26). The screw holes are placed at each plate ends to allow screw insertion through the skin incisions while the central part of the plate without holes is useful for bridging comminuted fractures. The other locking plate used in this study was the Synthes LCP. This plate has specific features that can be advantageous for MIPO application. The tapered plate ends allow for easier plate insertion through the epiperiosteal tunnel. Conventional cortical bone screws can be initially placed in each fragment to reduce the distance between bone and plate or for indirect reduction. However in those cases an anatomical plate contouring based on the contralateral unaffected limb is required. Locking screws can then be inserted to improve fragment stability using the LCP as an angle fixed implant. Alternatively, the push-pull device can be used to reduce the fracture and temporarily stabilize the plate to the bone before placing the screws (27).

Postoperative fracture alignment and reduction were acceptable in both treatment groups. Postoperative mMPTA and mMDTA, and mean TPA of both groups were



within the 95% confidence interval reported for normal dogs (19). These findings suggest that MIPO is effective in restoring limb alignment on the frontal and sagittal planes when compared to an open approach. There was not any significant difference found in fracture reduction between the two groups suggesting that both intra-operative fluoroscopy and radiology are effective techniques for assessing reduction, alignment, and implant position in tibial fractures. However, the benefits of intraoperative fluoroscopy should be carefully weighed against potential safety concerns, particularly during the learning phase of minimally invasive techniques. In this study we did not find any significant differences in mean plate length, plate bridging ratio and working length between the two groups. Furthermore, the types of fractures were similar, as suggested by comparing fracture length and fracture pattern. These findings suggest that mechanical factors such as the implant and fracture gap were similar between groups. In a recent study comparing MIPO and ORIF of radial and ulnar fractures, the difference in healing time was probably influenced by differing application of the plates (14). In dogs managed with MIPO, which healed faster than dogs treated with ORIF, most fractures were stabilized with more flexible plates than the other treatment group. The authors suggested that a more flexible fixation may have allowed faster healing in the dogs managed by MIPO. In our study long plates with a long working length were used in both treatment groups. This approach may explain the lack of difference in healing time between MIPO and ORIF, confirming that mechanical factors do have a major influence on fracture healing.

Although we chose to perform a cohort design to make a direct comparison of MIPO to ORIF, several limitations should be considered when interpreting our results. Sparse follow-up re-examinations were an important limitation of this study. Because of the lack of 30 and 60 days follow-ups in some cases, only a small number of dogs treated with MIPO could be included in the cohort. Although it was not possible to statistically demonstrate that the MIPO technique allowed for faster fracture healing, we found that most of the fractures managed with MIPO were healed at 30 days or had advanced fracture remodelling at 60 days. More frequent and consistent radiographic evaluations are needed to accurately define the time to radiographic union. Another important limitation is the lack of functional outcome. The final clinical evaluation was performed at the last recheck, which varied among cases. Although this study focused on radiographic evaluations of paired cases, a more precise assessment of the limb function with gait analysis would provide more information, especially regarding the early postoperative period.

Another limitation that should be considered is the low statistical power. Because of the small size of the treatment groups and the low statistical power, our results may not be correct. Reaching a power of 0.8 with the reported difference of means would require 23 dogs in each group, thus a larger study would probably detect a difference between treatments.

This is the first retrospective study in veterinary literature reporting a direct comparison of MIPO and ORIF techniques for tibial fractures between two groups of dogs with similar characteristics. Although all dogs treated by MIPO healed rapidly without any and with no complications, the difference in healing grading between the MIPO and the ORIF cohorts was not significant. Further investigations with a larger sample and more frequent follow-up examinations should be

considered to compare the efficacy of MIPO and ORIF surgical techniques for tibial fractures.

## **Acknowledgements**

The authors wish to acknowledge the following people for their help and contributions: Prof. Dan Lewis, Stanley Kim, Caleb Hudson, Fulvio Cappellari, and Kevin Drygas.

## **Conflict of interest**

None declared.

## **References**

1. Krettek C, Muller M, Miclau T. Evolution of minimally invasive plate osteosynthesis (MIPO) in the femur. *Injury* 2001; 32: 14–23.
2. Farouk O, Krettek C, Miclau T, et al. Minimally invasive plate osteosynthesis: does percutaneous plating disrupt femoral blood supply less than the traditional technique. *J Orthop Trauma* 1999; 13: 401–406.
3. Johnson AL. Current concepts in fracture reduction. *Vet Comp Orthop Traumatol* 2003; 16: 59–66.
4. Leunig M, Hertel R, Siebenrock KA, et al. The evolution of indirect reduction techniques for the treatment of fractures. *Clin Orthop Relat Res* 2000; 375: 7–14.
5. Rovesti GL, Margini A, Cappellari F, et al. Clinical application of intraoperative skeletal traction in the dog. *Vet Comp Orthop Traumatol* 2006; 19: 14–19.
6. Schmokel H, Hurter K, Schawalder P. Percutaneous plating of tibial fractures in two dogs. *Vet Comp Orthop Traumatol* 2003; 16: 191–195.
7. Schmokel HG, Stein S, Radke H, et al. Treatment of tibial fractures with plates using minimally invasive percutaneous osteosynthesis in dogs and cats. *J Small Anim Pract* 2007; 48: 157–160.
8. Hudson C, Pozzi A, Lewis DD. Introduction to minimally invasive plating osteosynthesis in dogs. *Vet Comp Orthop Traumatol* 2009; 22: 175–182.
9. Pozzi A, Lewis DD. Surgical approaches for minimally invasive plating osteosynthesis in dogs. *Vet Comp Orthop Traumatol* 2009; 22: 316–320.
10. Dejardin LM, Cabassu JP. Femoral fractures in young dogs. *AO Dialogue* 2008; 3: 39–43.
11. Haaland PJ, Sjöström L, Devor M, et al. Appendicular fracture repair in dogs using the locking compression plate system: 47 cases. *Vet Comp Orthop Traumatol* 2009; 22: 309–315.
12. Witsberger TH, Hulse DA, Kerwin SC, et al. Minimally invasive application of a radial plate following placement of an ulnar rod in treating antebrachial fractures. *Vet Comp Orthop Traumatol* 2010; 6: 459–467.
13. Guiot LP, Dejardin LM. Prospective evaluation of minimally invasive plate osteosynthesis in 36 non-articular tibial fractures in dogs and cats. *Vet Surg* 2011; 40: 171–182.

14. Pozzi A, Risselada M, Winter MD. Ultrasonographic and radiographic assessment of fracture healing after minimally invasive plate osteosynthesis and open reduction and internal fixation of radius-ulna fractures in dogs. *J Am Vet Med Assoc* 2012; in press.
15. Montavon P, Unger PM, Heim UFA. Classification of fractures of long bone in dogs and cats: introduction and clinical application. *Vet Comp Orthop Traumatol* 1990; 3: 41–50.
16. Piermattei DL, Flo G, DeCamp C. *Handbook of Small Animal Orthopedics and Fracture Repair*, Fourth Edition. Philadelphia: W.B. Saunders Company; 2006. pg. 25–159.
17. Schwarz G. Fracture of the tibial diaphysis. In: Johnson AL, Houlton JEF, Vannini R, editors. *AO Principles of Fracture Management in the Dog and Cat*. Stuttgart: AO Publishing / Georg Thieme Verlag; 2005. pg. 337–350.
18. Piermattei DL. Approach to the tibial diaphysis. In: *An atlas of Surgical Approaches to the Bones and Joints of the Dog and Cat*, 3<sup>rd</sup> ed. Philadelphia: W.B.Saunders Company; 1993. pg. 298–301.
19. Dismukes DI, Tomlinson JL, Fox DB, et al. Radiographic measurement of the proximal and distal mechanical joint angles in the canine tibia. *Vet Surg* 2007; 36: 699–704.
20. Anderson GM, Lewis DD, Radasch RM, et al. Circular external skeletal fixation stabilization of ante-brachial and crural fractures in 25 dogs. *J Am Anim Hosp Assoc* 2002; 39: 479–498.
21. Miller DL, Goswami T. A review of locking compression plate biomechanics and their advantages as internal fixators in fracture healing. *Clin Biomech* 2007; 22: 1049–1062.
22. Hammer RRR, Hammerby S, Lindholm B. Accuracy of radiologic assessment of tibial shaft fracture union in humans. *Clin Orthop* 1985; 199: 233–238.
23. Gustilo RB, Anderson JT. Prevention of infection in the treatment of one thousand and twenty-five open fractures of long bones: Retrospective and prospective analyses. *J Bone Joint Surg (Am)* 1976; 58: 453–458
24. Cheng W, Li Y, Manyi W. Comparison study of two surgical options for distal tibia fracture—minimally invasive plate osteosynthesis vs. open reduction and internal fixation. *Internat Orthop* 2010; 35: 737–742.
25. Kreder HJ, Hanel DP, McKee J AM, et al. Indirect reduction and percutaneous fixation versus open reduction and internal fixation for displaced intra-articular fractures of the distal radius: a randomized controlled trial. *J Bone Joint Surg (Br)* 2005; 87-B: 829–836.
26. Petazzoni M, Urizzi A, Verdonck B, et al. Fixin internal fixator. Concept and technique. *Vet Comp Orthop Traumatol* 2010; 23: 250–253.
27. Gautier E, Sommer C. Guidelines for the clinical application of the LCP. *Injury* 2003; 34: 63–76.

**Table 1**

Healing score system used by Hammer et al (22).

<b>Grade:</b>	<b>1</b>	<b>2</b>	<b>3</b>	<b>4</b>	<b>5</b>
<b>Callus formation</b>	Homogenous bone structure	Massive Bone trabeculae crossing the fracture line	Apparent Bridging of the fracture line	Trace No bridging of the fracture line	No callus formation
<b>Fracture line</b>	Obliterated	Barely discernible	Discernible	Distinct	Distinct
<b>Stage of union</b>	Achieved	Achieved	Uncertain	Not achieved	Not achieved

**Table 2**

Cross-classification of matching variables (age, body weight, fracture pattern) of dogs treated by minimally invasive plate osteosynthesis (MIPO) and open reduction and internal fixation (ORIF). Each case number corresponds to a pair of dogs treated by MIPO and by ORIF.

<b>Pairs</b>	<b>Minimally invasive plate osteosynthesis (MIPO)</b>				<b>Open reduction and internal fixation (ORIF)</b>			
	<b>Age (months)</b>	<b>Weight (kg)</b>	<b>Fracture pattern</b>	<b>Clinical union (days)</b>	<b>Age (months)</b>	<b>Weight (kg)</b>	<b>Fracture pattern</b>	<b>Clinical union (days)</b>
1	>12	46	42-C3	30	>12	46	42-C3	90
2	>12	25	42-C2	30	>12	20	41-C2	30
3	3 to 6	28	43-A1	30	3 to 6	28	43-A1	30
4	>12	36	42-C3	60	>12	36	42-C3	60
5	3 to 6	27	42-B1	30	3 to 6	25	42-B2	60
6	>12	11	42-B1	60	>12	8	42-A1	60
7	>12	25	42-C3	60	>12	25	42-C3	60
8	>12	30	42-A2	30	>12	25	42-A3	60
Mean ± SD	60 ± 51	28.5 ± 9.9			57 ± 44	26.6 ± 11.1		

**Table 3**

Implants used in the study.

<b>Pairs</b>	<b>Minimally invasive plate osteosynthesis (MIPO)</b>			<b>Open reduction and internal fixation (ORIF)</b>		
	<b>Plate type</b>	<b>Size</b>	<b>IM pin</b>	<b>Plate type</b>	<b>Size</b>	<b>IM pin</b>
<b>1</b>	LCP	3.5 mm, 13-hole, broad		DCP	3.5 mm, 14-hole, broad	3.0 mm
<b>2</b>	FIXIN	3.5 mm, V3304		DCP	3.5 mm, 8-hole	3.0 mm

4	LCP	3.5 mm, 14-hole, broad		DCP	3.5 mm, 11-hole, broad	
5	FIXIN	3.5 mm, V3305		LCP	3.5 mm, 12-hole	3.0 mm
6	LC-DCP	2.7 mm, 12-hole	2.0 mm	LCP	2.4 mm, 10-hole	
7	LCP	3.5 mm, 14-hole	2.5 mm	DCP	3.5 mm, 14-hole	3.0 mm
8	LC-DCP	3.5 mm, 12-hole, broad		DCP	3.5 mm, 12-hole	

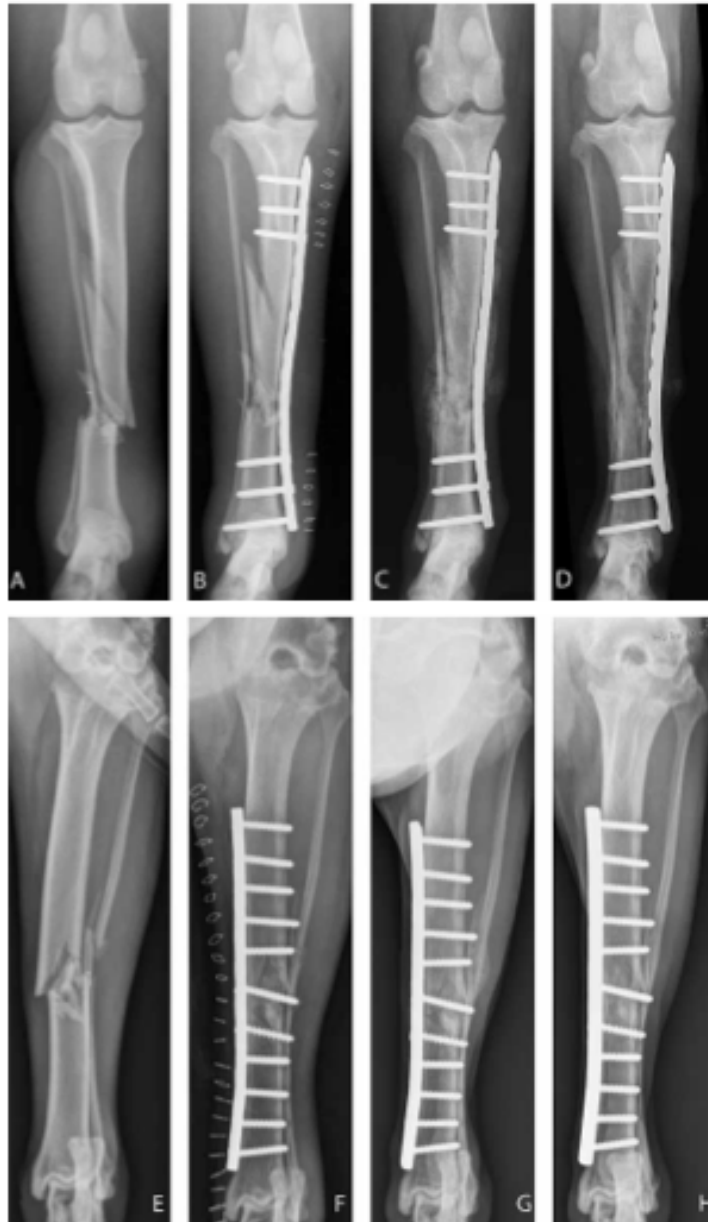**Table 4**

Mean  $\pm$  SD for outcome measures (fracture healing and implant) associated parameters for dogs in the MIPO (minimally invasive plate osteosynthesis) or ORIF (open reduction and internal fixation) groups.

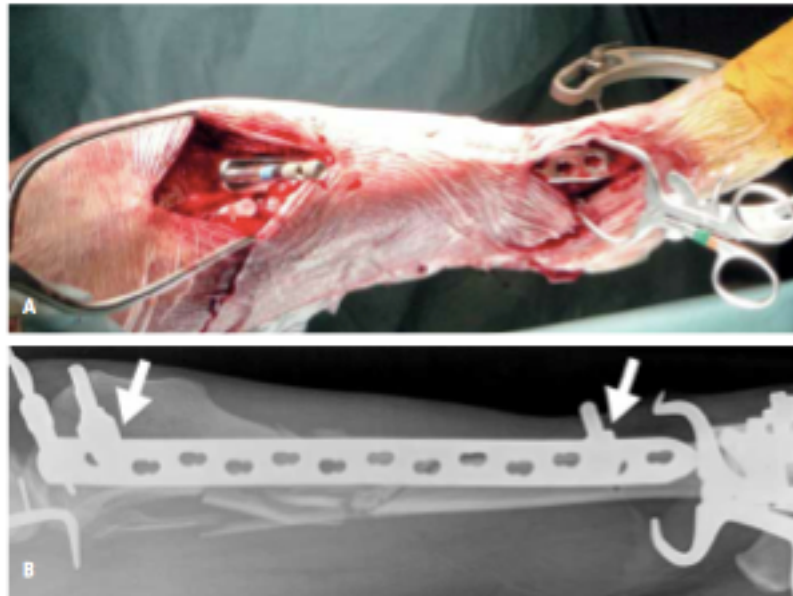
Outcome measures	MIPO group	ORIF group	p-value	Power
Healing grading (30 days)	3.5 $\pm$ 0.9	3.5 $\pm$ 0.7	0.95	0.05
Plate length (%)	76.4 $\pm$ 10.4	83.3 $\pm$ 5.3	0.32	0.34
Plate bridging ratio (%)	83.3 $\pm$ 5.3	76.4 $\pm$ 10.4	0.32	0.34
Fracture length (%)	29.4 $\pm$ 10.7	22.8 $\pm$ 11.4	0.29	0.22
Plate working length (%)	56.5 $\pm$ 8.8	42.3 $\pm$ 19.1	0.11	0.42
Translation cranio-caudal (%)	13.0 $\pm$ 10.6	10.8 $\pm$ 10.5	0.59	0.08
Translation medio-lateral (%)	13.8 $\pm$ 16.9	9.1 $\pm$ 10.5	0.59	0.11

**Key:** MIPO = minimally invasive plate osteosynthesis; ORIF = open reduction and internal fixation.

**Fig.1** Radiographic sequence (A-D) of a 10-year-old German Shepherd dog (pair 4 in the minimally invasive plate osteosynthesis group) presented with a comminuted fracture of the tibia (A). The fracture was stabilized with a 14-hole broad LCP secured with three locking screws in each bone segment (B). Radiographic follow-up at (C) 30 and (D) 60 days shows the progression towards complete fracture healing. (E-H) Radiographic sequence of a 10-year-old mixed breed dog (pair number 4; open reduction and internal fixation group) presented with a comminuted fracture of the tibia (E). The fracture was stabilized with an 11-hole broad DCP secured with eleven cortical screws (H). Radiographic follow-up at (G) 30 and (H) 60 days shows progression of fracture healing.



**Fig 2:** Intra-operative photography (A) and radiograph (B) of a 10-year-old German Shepherd presented with a comminuted fracture of the tibia (pair 1; minimally invasive plate osteosynthesis group). Indirect reduction of the fracture was achieved with skeletal traction. After the insertion of the 14-hole broad LCP (A) from the proximal incision, two push-pull devices (white arrows) were used for temporary fixation of the plate before insertion of the plate screws.



**Fig. 3** Radiographs (E, F, G), intra-operative fluoroscopic images (A, B, C) and intra-operative photography (D) of a seven-year-old mixed breed dog presented with an isolated long oblique fracture of the tibia (pair 8; minimally invasive plate osteosynthesis group). The fracture was reduced using bone reduction forceps (A) applied percutaneously and Kirschner wires (B) to maintain the reduction while applying the plate. After inserting a 12-hole, broad 3.5 mm dynamic compression plate, the plate was stabilized to the proximal and distal fragments with a screw and the push-pull device, respectively (C and D). Alignment was restored using the pre-contoured plate to reduce the fragments. Clinical union was documented 30 days postoperatively (G).



