

AperTO - Archivio Istituzionale Open Access dell'Università di Torino

Minimally Invasive Plate Osteosynthesis Fracture Reduction Techniques in Small Animals

This is the author's manuscript

Original Citation:

Availability:

This version is available <http://hdl.handle.net/2318/126359> since 2016-11-25T14:43:59Z

Published version:

DOI:10.1016/j.cvsm.2012.06.002

Terms of use:

Open Access

Anyone can freely access the full text of works made available as "Open Access". Works made available under a Creative Commons license can be used according to the terms and conditions of said license. Use of all other works requires consent of the right holder (author or publisher) if not exempted from copyright protection by the applicable law.

(Article begins on next page)



UNIVERSITÀ DEGLI STUDI DI TORINO

This Accepted Author Manuscript (AAM) is copyrighted and published by Elsevier. It is posted here by agreement between Elsevier and the University of Turin. Changes resulting from the publishing process - such as editing, corrections, structural formatting, and other quality control mechanisms - may not be reflected in this version of the text. The definitive version of the text was subsequently published in [*insert name of publication, volume number, issue number, date, and digital object identifier link*].

Peirone B1, Rovesti GL, Baroncelli AB, Piras L

Minimally invasive plate osteosynthesis fracture reduction techniques in small animals

Vet Clin North Am Small Anim Pract. 2012 Sep;42(5):873-95,

v. doi: 10.1016/j.cvsm. 2012.06.002.

You may download, copy and otherwise use the AAM for non-commercial purposes provided that your license is limited by the following restrictions:

- (1) You may use this AAM for non-commercial purposes only under the terms of the CC-BY-NC-ND license.
- (2) The integrity of the work and identification of the author, copyright owner, and publisher must be preserved in any copy.
- (3) You must attribute this AAM in the following format: Creative Commons BY-NC-ND license (<http://creativecommons.org/licenses/by-nc-nd/4.0/deed.en>), [+ *Digital Object Identifier link to the published journal article on Elsevier's ScienceDirect® platform*]

Minimally Invasive Plate Osteosynthesis Fracture Reduction Techniques in Small Animals

Bruno Peirone, DVM, PhD^{a,*}, Gian Luca Rovesti, DVM, Ecvs^b,
Alessandro Boero Baroncelli, DVM, PhD^a, Lisa Piras, DVM, PhD^a

KEYWORDS

• MIPO • Fracture • Reduction • Alignment • Traction • Distractor

KEY POINTS

- Anatomic fracture reduction is not typically achieved with minimally-invasive fracture repair in small animals.
- Indirect fracture reduction is used with minimally invasive plate osteosynthesis to restore limb's length and alignment.
- Indirect fracture reduction preserves soft tissue attachment to fracture fragments, speeding healing and reducing complications.
- Many techniques are available to facilitate fracture reduction, including hanging the limb, manual traction, distraction table, external fixators, and a fracture distractor.

INTRODUCTION

Minimally invasive plate osteosynthesis (MIPO) in small animals involves the application of a bone plate, typically in a bridging fashion, without performing a surgical approach to expose the fracture site.¹

Treatment of a diaphyseal fracture with MIPO does not usually require the anatomic reduction of the fracture. Functional reduction is the goal; it restores bone length and correct alignment in the frontal, sagittal, and axial planes. Indirect reduction is used to obtain functional fracture reduction without opening the fracture site. This method allows the fracture fragments to remain connected to the adjacent soft tissues. This is the key to improve bone healing because viable bone rapidly unites by callus formation.²

^a Dipartimento di Patologia Animale, Facoltà di Medicina Veterinaria, via Leonardo da Vinci 44, Grugliasco, Turin 10095, Italy; ^b Clinica Veterinaria Miller - Via della Costituzione 10, 42025 Cavriago, Reggio Emilia, Italy

* Corresponding author.

E-mail address: bruno.peirone@unito.it

Indirect reduction is the "blind" repositioning of bone fragments using some form of distraction and translation. This method relies on aligning fragments and restoring bone length by distracting the bone ends instead of manipulating the fracture site. It is achieved using a remote instrument so that there is no disturbance of the soft tissues around the fracture site. Indirect reduction may require exposure to apply the reduction devices, but not for visualization of the fracture site.

The general principle involved in indirect reduction is the use of the soft-tissue envelope to help stabilize and reduce the fracture fragments indirectly. This can be achieved through forces applied either on the adjacent bone segments or on the epiphyseal or metaphyseal regions of the fractured bone. The former is commonly referred to as ligamentotaxis.³ Traction table and limb hanging techniques are prime examples. In the latter, the tension on the soft tissues surrounding the fracture site guides the fragments into alignment as the bone ends are distracted. Intramedullary (IM) pinning, temporary application of a linear or circular external skeletal fixator, bone-holding forceps, bone distractor, or the plate itself are examples of this. These techniques can be used as a sole method of reduction or in any combination.

Fracture reduction can be accomplished completely closed or with the help of small incisions (portals). Proximal and distal incisions are needed to insert the plate and screws when using MIPO technique. A small third portal (observation portal) can be used to view the fracture zone to facilitate placement of an IM pin (see later discussion). It should be emphasized that manipulation of the fracture fragments should be avoided when using an observation portal. If fracture reduction is unsuccessful using the following techniques, the surgeon should consider using a technique described by Hulse as "open but don't touch."⁴ A long incision is made over the length on the bone, but the fracture fragments are not manipulated. This more generous approach allows an improved view of the fracture, facilitating indirect reduction of the fracture.

SKELETAL TRACTION TABLE

Traction tables are commonly used in human trauma patients and standardized reproducible techniques are routinely used for fracture reduction. These techniques include proper patient positioning, specific instrumentation, and application of intraoperative skeletal traction (IST).^{5,6} The rationale behind fracture reduction by IST is counteracting the muscle contraction and regaining the original limb length. In this way, the bone segments are not overlapped and easily fit each other. When fragmentation is present, the fragments are pulled back in the area they came from by their muscular attachments, which exert a centripetal force. This philosophy of reduction, called ligamentotaxis, has the main objective of achieving fracture reduction by a minimally invasive or close approach.

Recently, a skeletal traction table (Ergomed 99, Ad Maiora, Cavriago, Italy) was specifically designed for veterinary traumatology.⁷ This table allows IST to be consistently applied in small animals with safe application of opposition and anchorage points.⁸

The opposition points are defined as the points on the body where stabilization can be applied to counteract the traction forces and avoid translation, without injuring the patient. Anchorage points are defined as the points where traction can be applied distal to the fractured skeletal segment, without damaging the bone or the soft tissues (Fig. 1).

Indications

The veterinary traction table has been used to apply IST and reduce different fracture patterns of the appendicular skeleton.⁷ It is mandatory to thoroughly follow the




Fig. 1. Skeletal traction table and patient positioning for the craniomedial approach to the antebrachium in a cadaver. Traction is applied via coupled bands connected to the elongating stand (*black arrow*). The animal's body is held in position by two nylon bands crossed over the sternum (*red arrow*).

suggested steps in applying the technique. It is a powerful technique that can be potentially dangerous if applied in the wrong way.

Application of IST with Traction Table

The anchorage devices used for application of traction are represented by anchorage belts for the antebrachium and tibia and a traction stirrup attached to a transcondylar Kirschner wire (K-wire) in the humerus and femur.

The belts are coupled, to evenly distribute the traction forces to both sides of the limb, and then applied in the metacarpal or metatarsal area.

The traction stirrup is used in conjunction with a transosseous K-wire through the condylar region of the humerus or the femur, in a position that is compatible with the site of fracture and the proposed osteosynthesis technique. The wire ends are connected to the stirrup arms by means of bolts. Once secured, the wire is tensioned by the stirrup lever mechanism. This tensioning avoids wire bending and prevents soft tissues from being cut by the bent wire.

The traction is exerted by means of a micrometric traction stand that can be lengthened by up to 20 cm.

The traction stand has an L shape: the long component has a micrometric movement that allows stand elongation. One end of the stand is attached to the table rails with a clamp. The short component has three pins that allow the connection to either of the belts or the stirrup.

Traction is applied progressively and incrementally increased at a rate of about 50 N every 2 minutes and more traction is applied as needed to maintain the scheduled force. The amount of load applied is related to the patient body weight, muscular strength, and time between trauma and surgery, but especially to the quality of fracture alignment obtained. The fracture distraction and alignment achieved can be judged by palpation of the fractured site and or with intraoperative imaging.

During the application of traction, the maximal traction load is measured using a dynamometer. For safety reasons, the maximum load applied to each limb is never allowed to exceed 250 N. If the reduction is not achieved with this amount of load, some kind of interference should be suspected. A reduced approach to the fracture

area can be considered to help in the reduction process by local direct manipulation. The duration of traction should be recorded. A shorter traction time reduces the potential damage to tissues subjected to traction.

The positioning for the traction of each bone segment is as follows.

Patient Positioning

Antebrachium

The animal is positioned in lateral recumbency with the affected limb lowermost and the contralateral forelimb maintained against the thoracic wall with the shoulder flexed. The neck is extended. The limb that is to be subjected to traction is positioned with the midshaft of the humerus at the edge of the table. The traction stand is attached to the table caudal to the forelimb, with the short component oriented crani-ally so that traction can be exerted with the craniomedial region of the radius remaining completely unobstructed.

Opposition points Two bands are crossed over the sternum. A dorsal stabilizer is used on the dorsal area of the neck. The band crossing the upper side surface of the neck region is passed over the stabilizer so that excessive pressure on the base of the neck by this band is avoided.

Anchorage points For this traction technique, traction belts applied to the carpometacarpal region of the forelimb are usually used. A transosseous K-wire can also be inserted through the distal epiphyseal region of the radius or through the metacarpal bones for anchorage in the case of older, displaced, or overriding fractures.

Humerus

Lateral plate application The animal is positioned in lateral recumbency with the affected limb uppermost. The contralateral forelimb is flexed at the elbow and secured with the carpus under the animal's muzzle. The traction stand is placed caudal to the forelimb with the short component oriented caudally to exert axial traction on the humerus.

Opposition points A single band is passed circumferentially around the thorax in the region caudal to the axilla. Sometimes the application of a second K-wire and traction stirrup to the proximal metaphysis of the humerus is required. This approach is adopted because humeral traction applied with a single distal stirrup causes significant distal translation of the scapula without obtaining satisfactory alignment of the fracture segments.

Anchorage points For this technique, the traction stirrup is used. A K-wire is inserted with lateromedial direction across the condylar region or, instead, across the proximal ulna just following the humeral axis. Traction exerted with the bands applied to the carpometacarpal region can damage the distal structures before exerting a useful traction on the humerus because the musculature surrounding the humerus is usually very strong.

Medial and caudomedial plate application The patient is positioned similar to that used for the antebrachium. The body of the patient is slightly tilted by interposition of sand bags between the thorax and the table. In all other respects, traction stand position and opposition points are the same as for the antebrachium (Fig. 2).

Anchorage points These are the SAME as described for the humeral lateral approach.

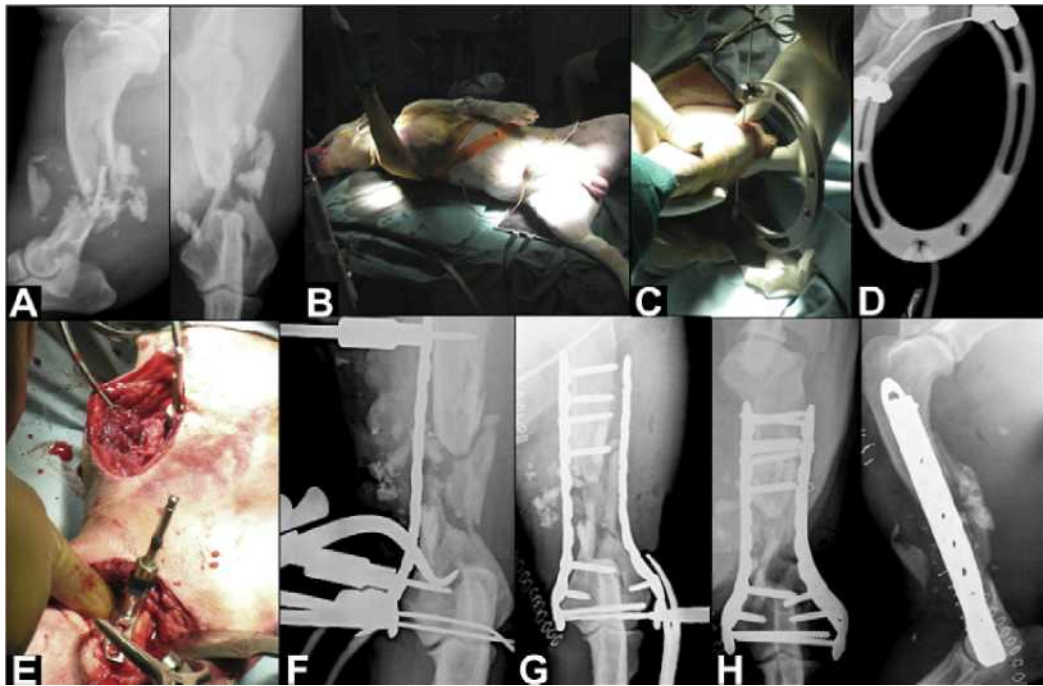


Fig. 2. (A) Preoperative radiographs of a comminuted humeral fracture. (B) Patient positioning. (C) Anchorage point: K-wire inserted in the proximal ulna and connected to an arch. (D) Intraoperative radiograph. (E) Temporary plate stabilization with push-pull devices on the medial side. (F) Intraoperative radiograph. (G) Intraoperative radiograph of temporary plate stabilization on the lateral side. (H) Immediate postoperative radiographs.

Tibia

Medial plate application: lateral recumbency The animal is positioned in lateral recumbency with the affected limb lowermost and the contralateral hindlimb secured caudally with the stifle flexed and the hip extended. The limb that is to be subjected to traction is positioned with the midpoint of the femoral diaphysis overlying the border of the table. The traction stand is positioned caudal to the limb, with the shorter component of the stand oriented cranially, to keep the craniomedial aspect of the tibia completely unobstructed.

Medial plate application: dorsal recumbency This positioning is very useful because allows a better assessment of the limb alignment on the frontal plane. The animal is positioned in dorsal recumbency. The limb being subjected to traction is extended caudally, with a support placed in the popliteal region. The contralateral hindlimb is positioned in abduction with the joints flexed and secured such that the calcaneus is as close as possible to the ischiatic tuberosity. The traction stand is connected to the end of the table. Usually, a dorsal positioner is put underneath the thoracic region to maintain this position during traction.

Opposition points For the craniomedial approach to the tibia, two nylon bands are applied. One band is passed over the uppermost ilium, across the inguinal region, and under the scrotum of male animals, and then secured to the table caudodorsally. It is useful to add a protective polyurethane cushion to this band, to prevent any harm to the patient. The second band is passed circumferentially around the caudal region of the abdomen and both ends are secured to the table dorsally.

For the craniomedial approach with dorsal recumbency, the oppositional forces are applied to the caudal part of the thigh by means of a limb rest placed in the popliteal region.

Anchorage points Coupled nylon bands are applied to the tarsometatarsal region of the limb for traction to evenly distribute the forces along the longitudinal axis of the tibia. The traction stirrup can be anchored to a transosseous K-wire inserted in the distal epiphysis of the tibia (Fig. 3) or to the metatarsal bones in cases of distal, overriding fractures.

Femur

The animal is positioned in lateral recumbency with the limb being subjected to traction uppermost. The contralateral limb is secured to the table caudally with the stifle flexed and the calcaneus positioned close to the ischiatic tuberosity. The traction stand is attached to the table cranial to the limb, with the shorter component oriented caudally to exert the traction along the longitudinal axis of the femur. A limb rest is used to support the tarsus to maintain the limb in a horizontal plane.

Opposition points A band is passed across the abdomen caudally, just under the iliac wing, then across the inguinal region and under the scrotum of male animals. It is useful to add a protective polyurethane cushion to this band, to prevent any harm to the patient. The band is secured caudodorsally to the table. A second band is passed around the caudal region of the abdomen and both ends of this band are secured to the table dorsally.

Anchorage points For this traction technique, the traction stirrup anchored to a transcondylar K-wire placed at distal end of the femur is used, because of the strength of the thigh muscles.

Procedure Technique

Traction modalities vary in each case, mostly based on fracture location.

Usually, the animals affected by radius-ulna and tibia closed fractures are positioned on the traction table and traction is applied before the limb is scrubbed. Once the fracture segments are realigned, the fracture reduction is confirmed by digital palpation, radiology, fluoroscopy, or a combination of them. In this setting, the reduction procedure is performed without scrubbing of the limb. Once the fracture is satisfactorily realigned, the limb is maintained in traction, scrubbed, and prepared for surgery as usual. With this traction modality, the traction devices are nonsterile and are not included in the surgical field.

For open fractures stabilization, the limb is prepared for surgery, as usual, and traction is applied in a sterile surgical field.

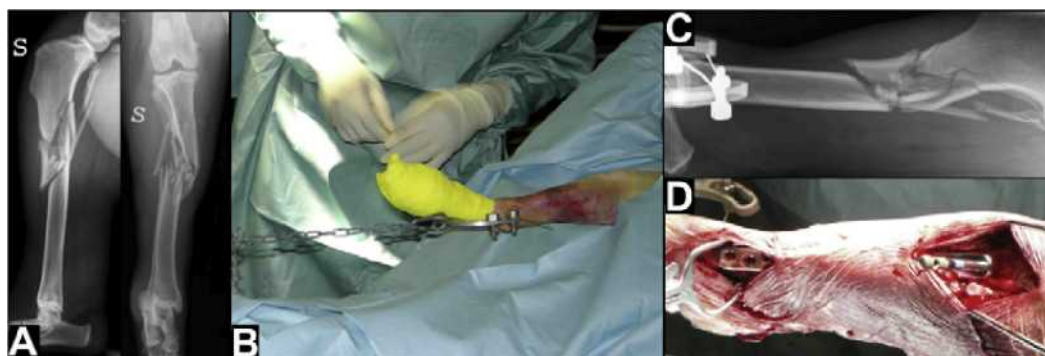


Fig. 3. (A) Preoperative radiographs of a comminuted tibial fracture. (B) IST. (C) Intraoperative medio-lateral radiograph showing the fracture indirect reduction. (D) Plate insertion in MIPO fashion. S, Sinistra (Left, in Italian).

For fractures of the humerus and femur, the limb is first scrubbed and prepared for surgery as usual. After performing the surgical approaches, the transcondylar K-wire is inserted and the sterile traction stirrup is applied and then connected to the micro-metric traction stand with a small sterile chain. The end of this chain connected to the stirrup is kept sterile, while the end connected to the dynamometer and distraction stand becomes contaminated. An unscrubbed operating room assistant, who sets the load on the surgeon's request, applies the load required to distract the fracture segments. Contamination of the surgical field is avoided, because the assistant can set the traction stand from its top, far from the surgical field, while the portion of the traction stand close to the surgical field remains covered by sterile towels.

Correction of malalignment

Correction of intraoperative angular malalignment of fractures is performed entirely by the unscrubbed assistant who moves the traction stand under the direction of the surgeon, as described above.⁶ Correction of varus or valgus malalignment is achieved by rotating the short portion of the traction stand in a clockwise or counterclockwise direction, after temporarily loosening the lock of the clamp holding this bar. In this way, the tip of the bar is moved higher or lower than the starting point. For example, elevation of the tip of the bar results in correction of a valgus malalignment of the tibia with the animal in lateral recumbency and the operated limb in lowermost position. However, the direction of the correction in relation to the animal's position should be evaluated. For example, when the animal is in dorsal recumbency, the correction of valgus or varus deformity is performed by loosening the clamp and sliding the entire traction stand, along the lateral rail of the table, either in a medial or lateral direction. To correct procurvatum or recurvatum malalignment, for all the positions but for the tibia with the animal in dorsal recumbency, the clamp is loosened and the entire traction stand is pushed horizontally along the lateral rail of the table. The clamp and the connected traction stand are pushed toward the cranial part of the animal for the correction of procurvatum and toward the caudal part for the correction of recurvatum. For the approach to the tibia with the animal in dorsal recumbency, the upward or downward rotation of the shorter part of the traction stand is used for the correction of procurvatum and recurvatum malalignment, respectively.

Potential Complications

This system of skeletal traction for fracture reduction has some elasticity that is inherent to the animal's tissues and the anchoring and opposition bands, which renders the process nonlinear during the initial stages. Although the application of opposition and anchorage belts is relatively simple, slippage of these belts may also contribute to this problem⁷ or result in local tissue injury. On the other hand, the traction applied with a traction stirrup results in negligible elastic drop and does not cause any compressive soft tissue injury. It is important to use the opposition points that were developed from the cadaver study⁷ and to monitor duration and magnitude of the loading force to avoid any tissue damage.

Excessive traction also potentially results in compromise of the nervous and vascular systems. In circumstances in which an elevated load must be applied, it may be prudent to minimize its duration to reduce the likelihood of complications. When the procedure cannot be completed in a sufficiently brief period, it is preferable to consider temporary stabilization of the fracture (ie, long oblique fracture) with either a point-reduction forceps or a K-wire applied percutaneously, releasing the traction to allow tissues to be better perfused, and then resuming traction after a short period.

Proper patient positioning and the use of skeletal traction are easily learned techniques that can rapidly become standard procedure. Although the time required for setting up of the table, positioning of the patient, and performing traction is somewhat lengthy, this time is regained during the osteosynthesis phase. In fact, plate application in an MIPO fashion is greatly simplified once the desired reduction is achieved because the osseous segments are steadily maintained in correct alignment for the necessary amount of time.

However, the technique may be potentially dangerous and, therefore, should be applied cautiously to avoid iatrogenic trauma. It is imperative that the application of opposition and anchorage points is correct, and prolonged and unnecessary loading is avoided.

LIMB HANGING

Suspending the limb from an infrastructure or from the ceiling orients the limb in a vertical position. By lowering the surgical table the animal's own weight distracts the fracture and helps aligning the joint surfaces.^{9,10} Intraoperative imaging is greatly facilitated because both frontal and sagittal planes are unobstructed and the C-arm or portable radiograph machine can be freely moved around the patient.

Indications

This technique is mostly indicated for comminuted fractures of the antebrachium and tibia when used alone.

The subsequent application of a temporary circular or linear external fixator can greatly improve the stability of the fracture reduction.

Procedure Technique

The animal is positioned for surgery in dorsal recumbency, with the affected limb suspended and draped. The anchorage point should be exactly over the limb, to exert a linear traction along the long axis of the fractured bone (Fig. 4). The use of a sterile snap-hook system allows the surgeon to disconnect the limb from the anchorage point to evaluate joints' flexion and plane of motion after temporary plate application.⁹

Potential Complications

The weight of the animal restricts the achievement of the fracture reduction.

This technique does not provide control over the horizontal plane. It is, therefore, important to verify rotational alignment after temporary fixation by disconnecting the




Fig. 4. (A B) Hanging limb technique for tibial fracture treatment: patient positioning. (C) A nonsterile pulley system is used to suspend the limb. (D) A sterile snap-hook system is secured to the paw. (E) The paw and the pulley system are wrapped with sterile self-adherent tape, (F) allowing the surgeon to disconnect the leg during the procedure.

limb from the suspending hook and flexing and extending the adjacent joints. In tibial fractures, traction applied to the pes frequently results in a caudal translation of the distal fragment. This phenomenon must be taken into account before plate positioning.

IM PINNING

An IM pin used as a distraction device is an effective method to overcome muscle resistance and gradually restoring length and axial alignment of a fractured bone.⁹

The IM pin placed near the neutral axis of the bone is very resistant to bending forces and, therefore, capable of maintaining axial alignment.¹¹

Advantages in using an IM pin for indirect reduction in MIPO include:

1. An additional surgical approach is usually not required for normograde pin insertion
2. Pin progression in the distal fragment allows fracture distraction by overcoming the muscles contraction
3. The bone surface is free for further plate application
4. Plate application is easier owing to partial stabilization and alignment of the fracture
5. Proper limb alignment can be confirmed by observing joint orientation during flexion and extension of the proximal and distal joints.

Indication

All long-bone fractures can be treated with indirect reduction achieved by means of an IM pin but, in the case of a radius fracture, the IM pin would be inserted in the ulna.

Long oblique and comminuted fractures with a large fracture gap are suitable for IM pin reduction. Pin progression in the distal bone segment is especially simple in the case of comminuted fractures, because usually there is no overriding of the main segments.

If the fracture pattern is characterized by a small proximal or distal segment it will be more challenging to obtain and temporarily maintain a correct axial alignment. This is due to the small bone stock and consequent inadequate pin-bone purchase.

Short oblique or transverse fractures are more demanding. Muscle contraction produces large fracture dislocation and segment overriding is always present. Gradual and progressive traction has to be applied over a period of time to overcome muscle contraction and achieve fracture alignment. Elevating and distracting the fractured bone ends using bone-holding forceps through the surgical approaches reduces segment overriding and allows pin progression in the distal fragment.⁹

Smooth pins with tips at one or both ends are used, and their size normally ranges from 1.2 to 4 mm in diameter. Correct pin selection is related to bone diameter and determined from preoperative radiographs during surgical planning. The diameter of the pins used should be approximately 30% to 50% of the diameter of the bone's medullary cavity.⁴

Procedure Technique

Surgical proximal and distal approaches, as described for MIPO application in animals, have to be performed before IM pin insertion.^{1,12}

The proximal intact bone segment is secured with a bone-holding forceps and the pin is advanced distally. If the pin is properly aligned, it progresses easily in the medullary cavity. In case of difficult progression, the pin is penetrating the cortex and should be redirected.

The pin tip is cut and the pin passed carefully through the fragmented area of the bone. To cut the distal tip of the pin two options are available:

1. Withdraw the inserted pin, cut the tip, and reinsert it with the same direction
2. Proceed with pin insertion until the tip emerges from the distal approach, then cut the tip.

The pin can be advanced by drill, pushed through using the drill with the motor stopped,¹⁰ or by hand using a mallet.

Without the pointed tip, the distal part of the IM pin leans against the metaphyseal bone of the distal segment, distracting the fracture gap while restoring bone length and aligning the main bone segments.^{4,13}

Long pins left out from the entrance point help in the intraoperative evaluation of pin direction.

A second pin with the same length can be used to evaluate IM pin depth in the distal segment's medullary canal.

Holding the distal segment with point-reduction forceps percutaneously, or with bone-holding forceps applied through the distal approach, helps in maintaining the correct axial alignment during pin progression. To achieve adequate stability, the pin must be seated in the cancellous bone of the distal metaphyseal region.

Once in place, the IM pin assists in maintaining the axial alignment of the bone in both frontal and sagittal planes. However, because it does not effectively counteract torsional forces, it is important to check torsional alignment before plate application, especially in comminuted fractures.

Proper pin positioning and bone alignment can be assessed clinically, but thorough intraoperative diagnostic imaging is recommended, especially in proximal bone segments. Once correct pin placement is confirmed, the IM pin can be left in place to function as a plate-rod construct or removed when the plate has been sufficiently secured to the major bone segments.^{4,12} If the pin is left in place, the proximal portion could be cut close to its exit from the bone. More commonly, if the diameter of the pin allows it, the pin is bent at its exit from the proximal segment and cut to allow its removal following fracture healing.

Humerus

Lateral approach The lateral approach is mainly used in proximal and middle-third fractures.

The patient is positioned in lateral recumbency with the affected limb uppermost. The proximal approach is performed on the medial aspect of the greater tubercle. The curvature of the bone and the level of the shaft fracture determine the point for insertion of the pin on the cranial crest of the greater tubercle. A point-reduction forceps can be used to hold the proximal segment during pin insertion.

The IM pin is driven from the proximal segment by entering the bone on the lateral slope of the ridge of the greater tubercle near its base.^{10,11} Initial drilling is done with the pin held perpendicular to the bone surface. After tip penetration of the outer cortex, the pin is redirected distally into the medullary canal to shift parallel to the caudomedial cortex. The pin must be seated just proximal to the supratrochlear foramen.¹⁰

Medial approach This approach is mainly used in distal-third fractures.

The patient is positioned in lateral recumbency with the affected limb lowermost and the contralateral retracted caudally. The distal approach is performed along the caudal cortex of the medial epicondyle and soft tissue dissection is performed, being mindful

of the ulnar nerve, which should be identified and retracted cranially. Bone-holding forceps can be used to secure the distal fragment during pin insertion. The IM pin enters the bone just distally to the square corner of the medial portion of the condyle, directed parallel to its caudal cortex. Proper pin size must be determined on preoperative radiographs so that it can pass along the medullary canal of the medial epicondyle. The pin progresses through the fracture site and advances proximally along the cranial cortex of the proximal segment.¹⁴

Femur

The patient is positioned in lateral recumbency with the affected limb uppermost.

Once the proximal approach has been performed, the pin is inserted through the subcutaneous fat and the gluteal muscles until the top of the great trochanter is felt with the tip of the pin. During pin insertion, the proximal femur is held with a bone-holding forceps at the angle and rotation of the normal standing position.¹⁰ Maintaining the same axis as the femur, the pin is gently moved medially off the trochanter into the trochanteric fossa, where it will center itself with some pressure. To avoid slippage, the tip of the pin is first seated into the metaphyseal bone of the trochanteric fossa in a cranial direction. Once penetration begins, the pin is aligned with the long axis of the proximal femoral segment.

Tibia

The patient is positioned in dorsal recumbency with the stifle flexed at a right angle.

The proximal approach is performed on the medial aspect of the proximal tibia over the medial collateral ligament and slightly extended proximally to the medial aspect of the stifle joint (**Fig. 5**).

The pin is then inserted along the medial border of the patellar ligament, entering the proximal end of the tibia between the cranial surface of the tibial tubercle and the medial condyle of the tibia.¹⁰

Radius and ulna

Fractures affecting the antebrachium can be reduced both with retrograde and normograde IM pinning of the ulna.

The size of the pin should be as large as it can fit in the distal medullary canal of the ulna. The patient is positioned in dorsal recumbency, allowing an easy approach to the radius by extending the elbow and to the ulna by flexing the elbow joint. With minimal soft tissue dissection, the deep flexor muscles on the caudal aspect of the ulna are

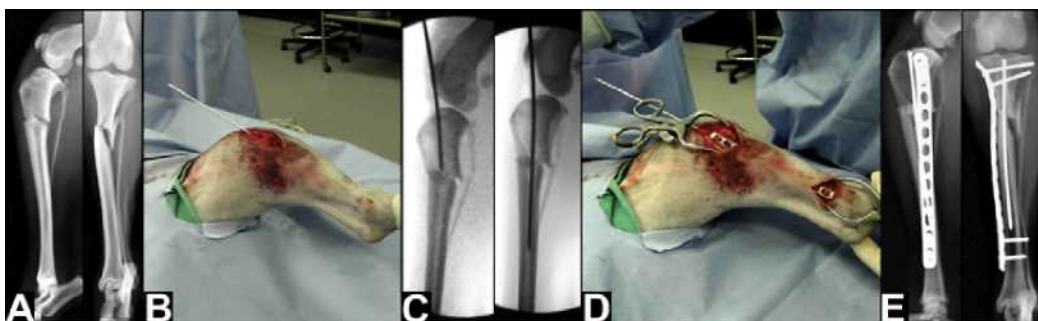

Fig. 5. (A) Preoperative radiographs of a mildly comminuted proximal tibia and fibula fracture. (B) Normograde IM pinning of the tibia. (C) Intraoperative fluoroscopy images showing the indirect reduction of the fracture. (D) Plate insertion through medial proximal and distal incisions using a MIPO technique. (E) Immediate postoperative radiographs. (Courtesy of A. Pozzi, Gainesville, FL.)

elevated to expose the fractured ends of the ulna. The pin is retrograde inserted in the proximal segment to exit at the olecranon. The ulnar fracture is reduced and the pin normograde driven across the fracture site and ideally seated in the distal metaphysis of the ulna.¹⁵ Normograde pin insertion is also possible, but more challenging (**Fig. 6**).

Potential Complications

If a plate and rod technique is selected to treat the fracture, the IM pin can interfere with bicortical screw insertion, especially in the diaphyseal region.

Joint penetration could be possible during pin progression in the distal segment, but is unlikely to occur once the tip has been severed.

When a plate and rod construct is applied, pin migration can occur during the post-operative period and pin removal is, therefore, recommended.⁴

LINEAR EXTERNAL FIXATION

Full pin frames allow correction of angular deformity and maintenance of bone length. This technique requires shorter setup times, provides complete access to the bone, and allows complete manipulation of the limb, thereby facilitating plate application while avoiding the use of excessive traction because the reduction force is applied solely to the bone and not across the proximal and distal joints.

Indication

Linear external fixation is indicated in fractures of the antebrachium and tibia because of the relative paucity of soft tissues surrounding them. Humerus and femur are not recommended because of the large muscle bellies.

Procedure Technique

During the surgical positioning of the patient, the affected limb is securely suspended from a ceiling hook and draped. Using a sterile hook system allows the surgeon to disconnect the leg during the procedure.⁹ Transfixating full-threaded pins are placed in the proximal and distal metaphyses of each bone segment. Their diameter must not exceed 20% to 30% of the width of the medullary canal.¹⁶ The pins are centered in the bone on the sagittal plane and parallel to their respective joint surface. The proximal pin should be placed sufficiently posterior so as not to interfere with plate positioning.¹⁷ It is mandatory to place fixation elements only in safe soft tissues

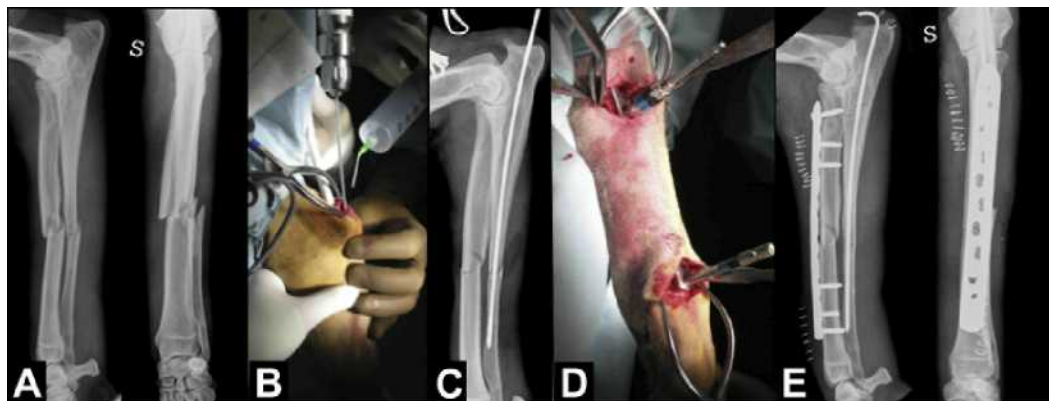


Fig. 6. (A) Preoperative radiographs of a comminuted radius and ulna fracture. (B) Normograde IM pinning of the ulna. (C) Intraoperative radiograph. (D) Temporary plate stabilization with push-pull devices. (E) Immediate postoperative radiographs. S, Sinistra (Left, in Italian).

corridors.¹⁸ Care must be taken before pin insertion to avoid multiple attempts that would increase the risk of iatrogenic fracture or bone necrosis. Intraoperative radiographic control or fluoroscopy is used to assess correct pin placement.

The table is then lowered or a pulley system used to raise the limb, suspending the patient by the fractured limb. The weight of the patient distracts the fracture and helps aligning the joint surfaces. If necessary, manual distraction on the threaded pin can improve alignment. The connecting bars are placed and limb alignment clinically evaluated. Intraoperative fluoroscopy or radiology is valuable in the assessment of correct alignment.⁹

Only after good reduction and alignment have been achieved the plate can be inserted and secured to the bone.

Potential Complications

Special care is needed to avoid intraarticular pin placement and to ensure that the pins are effectively parallel to the proximal and distal joint surfaces to prevent malalignment.

It is important to avoid pin placement into fissures or superficial cortical areas, possibly resulting in fractures.

Attention must be paid to avoid nerve or vessel injury during pin insertion, respecting safe corridors.

Leaving empty holes is not ideal because this can lead to subsequent bone fracture, probably because of the stress riser effect caused by creating a defect in the cortical bone. Placing a hole too close to one cortex, eccentrically, rather than penetrating the bone in its middle area could also create a stress riser.

CIRCULAR EXTERNAL FIXATION

Tensioned small diameter wires and circular rings can be used with a simple, efficient technique, described by Jackson and colleagues,¹⁷ which allows for precise reduction, length restoration, excellent control of rotation, and easy access for imaging. Once held at the correct length, the frame construct will resist shortening and, perhaps, distraction forces during plate positioning. The application of the frame is straightforward and may be rapidly accomplished and the insertion of fine wires is minimally invasive, causing little tissue trauma.

Indication

Circular external fixation indirect reduction technique is indicated in tibia, radius and ulna fractures. Humerus and femur fractures are less commonly reduced by this technique because of the large muscle bellies and the impingement given by the thorax and the abdomen. When used for those segments, half-rings are used.

This method is particularly useful in fragmented or segmental fractures where the reduction is difficult to maintain. It is challenging in proximal and distal-third fractures, where the frame can interfere with proper plate positioning and fixation. When this is the case, the reduction can be maintained by a transarticular frame.

Procedure Technique

The frame is preassembled with two rings or arches (partial rings) arranged in a single block configuration for the proximal and distal fragment. When arches are used, the proximal one is oriented with the open portion cranially for the radius and caudally for the tibia to avoid interference with elbow or stifle flexion. The distal arch is oriented with the open portion caudally for the radius and cranially for the tibia to avoid

interference with the carpus and hock flexion. This frame construct allows for a better limb alignment evaluation during the surgical procedure.

The surgeon must choose a ring or arch size that can be placed around the animal's limb while still having enough space between the skin and the inner margin of the ring to position the plate.

The rings or arches are connected using two threaded rods, positioned to avoid interference with safe corridors and subsequent plate application.

The transosseous wire size is selected according to established guidelines.¹⁹

A standard hanging limb preparation is performed with the animal in dorsal recumbency in a way that retains the possibility of attaching and detaching the limb from the hanging support.

The first transosseous wire is placed in the proximal radius or tibia, parallel to the mediolateral axis of the elbow or stifle joint and perpendicular to the longitudinal axis of the proximal segment. The proximal wire should be placed sufficiently posterior so as not to interfere with plate positioning.¹⁷

The preassembled frame is passed over the limb and connected to the proximal wire. The distal transosseous wire is inserted in a direction that is parallel to the antebrachio-carpal, or hock joint, and perpendicular to the longitudinal axis of the distal segment.

It is recommended that fixation elements be placed only in safe soft tissue corridors. Care must be taken before wire insertion to avoid multiple attempts that would increase the risk of iatrogenic fracture or bone necrosis.

Proper placement of the wires is confirmed through intraoperative radiographs or fluoroscopy. The distal wire is then connected to the frame. The wires are tensioned to a maximum of 30 kg to avoid arch deformation.¹⁹

Fracture reduction is achieved by gentle and progressive distraction of the rings or arches. Distraction is applied by turning the nuts on the threaded rods. By ensuring that the two wires are inserted perpendicular to the longitudinal axis and parallel to each other in both frontal and sagittal planes, correction of alignment and rotation will be achieved because bone length is restored (**Fig. 7**).

Reduction and axial alignment can be improved by modifying the frame's spatial alignment, using the following methods²⁰:

- The angled bar technique. This is used with systems that do not have hemispheric nuts and washers available and consists of changing the angle of a threaded bar between the rings or arches. This bar is connected to the rings or arches, offset by the amount of the deformity to be corrected but in the opposite direction. When the nuts on the previous straight connecting bars are loosened and the nuts on this angled bar are tightened, the angled bar becomes perpendicular to the rings, rotating the bone segment in the direction opposite to that of the deformity.
- Hemispheric nuts and washer technique. This method can be used with systems in which hemispheric nuts and washers are available. The nuts are loosened, the distal ring or arch is rotated in the direction opposite to the deformity, and the nuts are tightened again after deformity correction, leaving the threaded bars at an angle to the rings. Hemispheric nuts and washers can also be used to correct angular deformities. For example, if a valgus deformity is present, the length of the lateral threaded bar connecting the rings may be increased, while the nuts of the threaded bar on the medial side may be released to avoid them holding the rings in the previous position, preventing the frame construct from moving.
- Shifting of the bone along the wire. If a dislocatio ad latum is present, it can be corrected by shifting the bone along the wire, thus changing its position on the horizontal plane.

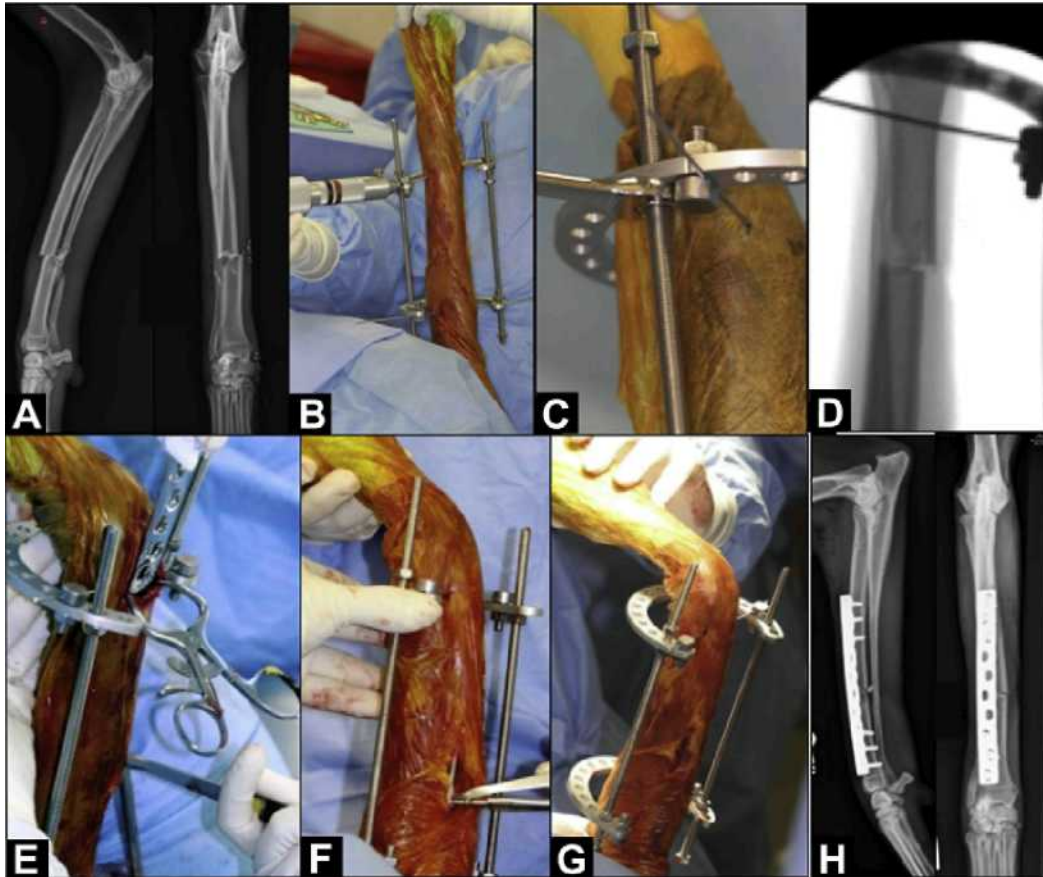


Fig. 7. (A) Preoperative radiographs of a comminuted radius and ulna fracture. (B) Application of the circular fixator (Imex Veterinary Inc, Longview, TX, USA). (C) Fracture distraction applied by turning the nut. (D) Intraoperative fluoroscopy showing fracture reduction. (E) Plate insertion in an MIPO fashion. (F) Screw insertion. (G) Limb alignment evaluation. (H) Immediate postoperative radiographs. (Courtesy of A. Pozzi, Gainesville, FL.)

- Rotation of the bone along the fulcrum of the wire. Once distraction of the fracture segments has been achieved, a residual angular deformity may still be present. The bone segment may be aligned using the wire as a fulcrum, thus changing its axis. For this procedure to be performed, it is mandatory that just one wire is inserted in each segment. If more than one wire is inserted in the bone segment, it will be locked.

Potential Complications

Special care has to be put to avoid intraarticular wire placement¹⁸ and to ensure that the wires are effectively parallel to the proximal or distal joint surfaces respectively to prevent malalignment. It is important to avoid the placing of the transfixation pin into fissures or superficial cortical areas, possibly resulting in fractures. Care must be put to avoid nerve or vessel injury during wire insertion.

The use of small-size wires leaves a very small empty hole, diminishing the risk of stress riser effect and secondary fractures.

BONE-HOLDING FORCEPS

Small bone-holding forceps inserted far from the fracture site through the proximal and distal surgical approaches can be used to align the fracture.²¹ The most distal and proximal parts of the bone segments are secured with the bone-holding forceps and the segments are distracted and manipulated to reduce the fracture.

This method is most successful in radius-ulna and tibia fractures in which the reduced muscle mass allows more accurate palpation and easier reduction.^{1,10}

Nevertheless, a forceps is a space-occupying device and should be applied to the bone in a position that allows subsequent plate application. For example, in a tibial fracture the bone-holding forceps grip the cranial and caudal bone aspects to allow medial plate placement.

It should also be noted that bone-holding forceps are passive devices, requiring an assistant to maintain reduction until plate fixation is completed.

In humerus and femur fractures it is often more challenging to achieve and maintain proper fracture reduction with this method because of the large surrounding muscle. Therefore, in such cases, bone-holding forceps are mostly used in combination with other reduction techniques, such as IM pinning.

For example, in a femoral fracture the bone-holding forceps could be applied through the proximal surgical approach at the level of the subtrochanteric region to hold and maintain the proximal segment in a levered position during pin insertion (Fig. 8). A second bone-holding forceps, applied through the distal surgical approach at the level of the supratrochlear region, can be used to distract and manipulate the distal segment allowing pin insertion and progression.

Bone-holding forceps can also be used as an aid to further improve segment alignment when other indirect reduction techniques are used.

Occasionally, a point-reduction forceps can be used percutaneously (Fig. 9) to approximate a severely displaced fragment or long oblique fractures.²¹

FRACTURE DISTRACTOR

The fracture distractor is a mechanical device that applies the forces directly to the bone segments. It is composed of a threaded spindle that is fixed on one end while the other end features a sliding carriage that can be moved proximally or distally by tightening the two nuts placed above and below the carriage.

Adjacent parts of the body remain unobstructed. The fracture distractor allows easy distraction of the bone segments, even when severe muscle contraction is present.

Dynamizable linear fixators (Ad Maiora, Cavriago, Italy) that can exert distraction and compression are now available. They work like a temporary fracture distractor if plating is the scheduled procedure, or like a definitive stabilization device if more pins are added once the fracture reduction is achieved. The special clamps allow bone segment movement in all the planes, thus facilitating reduction maneuvers (Fig. 10).

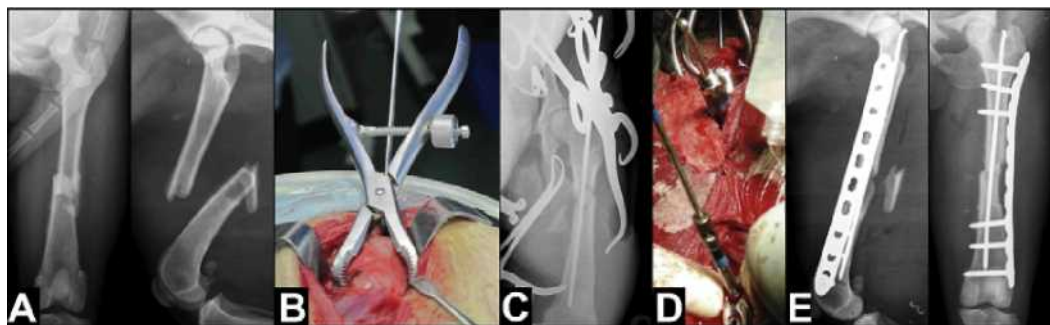


Fig. 8. (A) Preoperative radiographs of a butterfly femoral fracture. (B) The forceps holds the proximal segment during normograde IM pinning. (C) Intraoperative radiograph. (D) Temporary plate stabilization with push-pull devices. (E) Immediate postoperative radiographs.

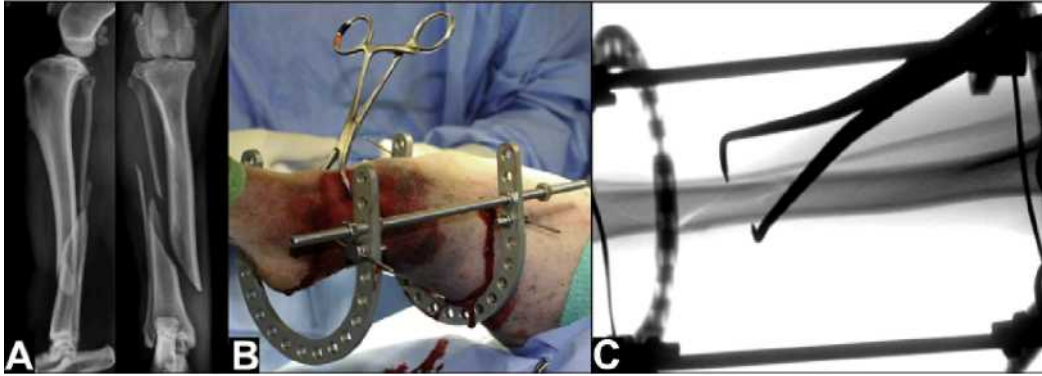


Fig. 9. (A) Preoperative radiographs of a long oblique tibia and fibula fracture. (B) The point-reduction forceps is used percutaneously to approximate the fracture. (C) Intraoperative fluoroscopy. (Courtesy of A. Pozzi, Gainesville, FL.)

In very unstable fractures, or when the plate could be potentially weak because of the features of the fracture or the patient's temperament, it can be used like a temporary ancillary stabilization device, to be removed after the early bony callus developed.

Indication

The fracture distractor is generally reserved for use in femur fractures in very large animals, with significant muscle contraction and fragment overriding, or in old fractures in which callus and muscle contracture must be overcome. The extensible linear fixator can be used in almost all sizes of patients.

Procedure Technique

Two threaded pins are inserted in the metaphyseal area of both the proximal and distal segments.

The fracture distractor is then attached to the pins and the sliding carriage can then be moved distally, distracting the fracture. The offset position of the distractor allows the surgeon to access the fracture site for implant application. Varus, valgus, or rotational malalignment are corrected before pin placement and fracture distraction, using fluoroscopy to confirm proper alignment.

The technique is similar for the dynamizable linear fixator, but it does not require that the angular and torsional deformities be corrected before pin placement because the clamps allow the bone segments connected to the pins to be moved in every plane to achieve fracture reduction. When used like an ancillary temporary device, the distance from the bone and the clamp should be reduced to increase its stiffness, until the plate is secured to the bone.

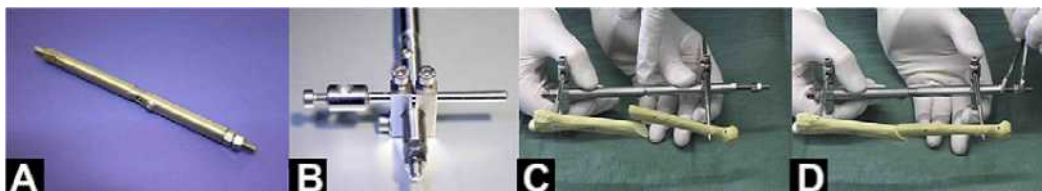


Fig. 10. (A) The dynamizable linear fixator. (B) Fixator clamp that allows multiplanar fracture segment adjustment. (C) Application of the dynamizable fixator to a plastic model simulating an overlapped fracture. Note the central part of the fixator body that is almost closed. (D) After fracture reduction, the central part of the fixator body is larger than before distraction. The clamps can now be set to better adjust the fracture reduction.

Potential Complications

Although the fracture distractor can be used to indirectly reduce comminuted fractures, it can be difficult to apply bridging plates in an MIPO fashion with the distractor in place.⁸

The dynamizable linear fixator should be used with long pins, to avoid interference with plate positioning. It should also be placed so that it does not interfere with plate positioning. For example, if a craniomedial plate is scheduled, it should be placed laterally.

REDUCTION THROUGH PLATE APPLICATION

The use of anatomically precontoured standard or locking plates in MIPO treatment of diaphyseal fractures helps to ensure proper reduction and correct limb alignment.²²

Indication

This technique should be combined with one of the previously described methods of indirect reduction, to restore the correct bone length before plate application.

Only small displacements and angulations on both the frontal and the sagittal planes can be corrected while maintaining stability as the reduction occurs.¹

Procedure Technique

Plate precontouring

The orthogonal radiographic views of the contralateral intact limb are used to select the adequate plate whole length and to contour the plate preoperatively.²¹

Plate length is evaluated on the mediolateral view and should be close to the length of the whole bone. Schmokel recommends the use of a long plate in MIPO applications to dissipate the stress on the construct.²³ Furthermore, longer plates with a limited number of screws positioned at the plate ends have shown to sustain greater loads before failing than shorter plates with a screw placed in each plate hole.²⁴

Accurate plate precontouring is usually performed on the craniocaudal view to ensure proper axial alignment of the main fragments and correct bone length.²³

Plate bending and twisting are performed to adapt plate ends to the shape of both the proximal and the distal metaphyseal regions of the fractured bone.

Standard plates

With standard bone plates, screw tightening produces frictional forces between the plate and the bone and, during weight bearing, the shearing load is transferred directly from the bone to the plate.²⁵ Therefore, accurate anatomic plate contouring is mandatory to maintain primary fracture reduction during screw tightening.²⁶

After plate insertion, the proximal plate end is positioned on the center of the bone and fixed with a cortical screw inserted perpendicular to the cortex. This screw is not fully tightened to allow movement of the distal plate end. Bone-holding forceps can be used to center the plate over the bone or to achieve plate-bone contact. The bone cortex of the distal segment is then exposed and the plate end centered over the bone and fixed with a second cortical screw. Plate position is then checked by means of intraoperative imaging, after which both screws are tightened and fracture reduction is controlled before the final fixation.

If the axial alignment is not satisfactory, another cortical screw should be inserted closer to the fracture site through a separate stab incision, to act as a reduction screw. This allows the displaced segment to be pulled against the plate and reduced in a more anatomically correct position.²⁷

Locking plates

With locking plates, a rigid connection between the plate hole and the screw is achieved; therefore, no frictional forces are produced between the plate and the bone.²⁵

The advantage of locking plates is the minimal contouring required for their application in comparison to standard plates. The locking plate acts as an internal fixator and, therefore, does not displace the fracture segments during locking-screw tightening, regardless of the precision of contouring.²⁶

To provide stable fixation, proper locking of the screw is essential. Temporary stable plate fixation to the bone is recommended before the insertion of the first locking screws.

The push-pull device (Synthes, Solothurn, Switzerland) is a temporary reduction device applied through a plate hole to hold the locking compression plate against the bone (**Fig. 11**). This device is self-drilling and connects with the quick coupling for power insertion. After monocortical insertion, the flange is turned clockwise until it pulls the plate securely against the bone. Once the plate is secured by the other screws, the push-pull device is removed and a screw can be inserted in the same hole.²⁸

Another temporary reduction device is the pin-stopper, part of the Fixin system (Traumavet, Rivoli, Italy). The pin-stopper is a perforated stainless steel cylinder that can be inserted over a smooth pin and locked with a small screw nut (**Fig. 12**). The pin is inserted in the plate hole through a dedicated conical drill guide. Bicortical pin insertion is recommended to improve torsional stability. Pin insertion progresses until the stainless steel cylinder reaches the top of the conical drill guide and consequently pushes the plate against the bone. The use of a threaded pin can improve this action once the threaded tip enters the bone cortex.²⁹

With a properly contoured implant, positioning temporary reduction devices in a hole that is further away from the ends of the plate allows better plate-bone contact and consequently more accurate fracture reduction (See **Fig. 12**).

Potential Complications

Inadequate plate contouring may result in loss of primary reduction and axial malalignment during cortical screw tightening or temporary plate fixation.

Axial malalignment can also occur, if bone length is not completely restored and segment overlapping is still present before plate application.

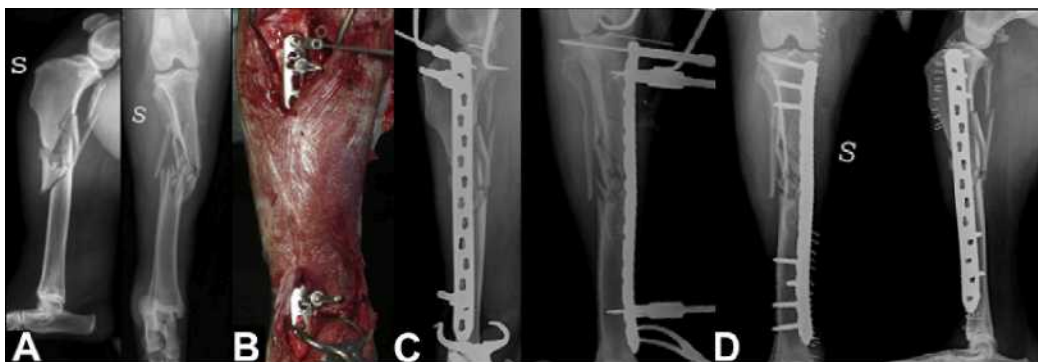

Fig. 11. (A) Preoperative radiographs of a comminuted tibial fracture (see **Fig. 3**). (B) Temporary plate stabilization with two push and pull devices. (C) Intraoperative radiographs showing the indirect reduction of the fracture. (D) Immediate post-operative radiographs. S, Sinistra (Left, in Italian).

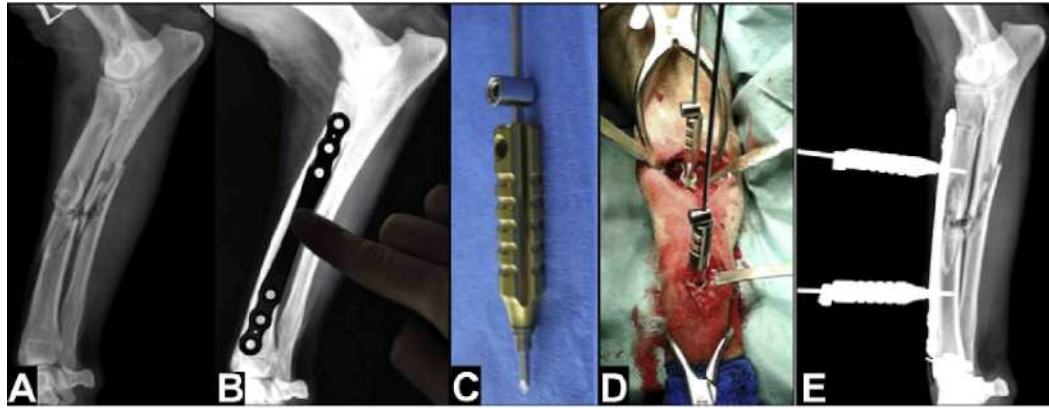


Fig. 12. (A) Preoperative mediolateral radiograph of a comminuted radius and ulna fracture. (B) Plate length assessment on the contralateral limb. (C) Pin-stopper with dedicated guide. (D) Two pin stoppers are inserted through the plate. (E) Intraoperative mediolateral radiograph showing indirect fracture reduction and temporary plate fixation.

If the proximal and distal screws are not inserted into the center of the bone, because of the plate being offset, or if their direction is not perpendicular to the cortical surface, segment rotation and translation may occur at the fracture site.²⁷

Care must be taken during tightening of the first screws. The insertion torque applied could still result in dislocation of the bone segments. Therefore, palpation and assessment through visual or intraoperative imaging is recommended to avoid poor fracture reduction.

ASSESSMENT OF ALIGNMENT

After fracture indirect reduction has been achieved, care must be taken to carefully assess limb alignment. Malalignment is the most common complication associated with MIPO, because the fracture site is not exposed and the surgeon cannot rely on direct visualization of correct reduction to restore alignment.

It must be underlined that a loss of length or a moderate malalignment on the sagittal plane (procurvatum or recurvatum) does not affect the patient's functional outcome, whereas malalignment on the frontal (varus or valgus) or axial plane can severely compromise limb function.

Limb alignment can be assessed both by clinical evaluation and intraoperative fluoroscopy or radiology.

Proper patient positioning and surgical draping are mandatory to allow correct alignment evaluation. The limb should still be completely visible in both sagittal and frontal planes after draping, and the distalmost and proximalmost joints should be evaluated in their range of motion. This setting will allow the identification of anatomic landmarks, which is fundamental for clinical evaluation. Familiarity with the normal relationship between external anatomic landmarks is as essential as in depth knowledge of bone anatomy in preventing malalignment.³⁰

The availability of a sterile bone model in the operating room can also help the surgeon to recognize these landmarks on the fractured limb.

Clinical evaluation can easily be performed on the antebrachium and crus, but it can be challenging for the arm and thigh, due to the presence of large muscle bellies.

Therefore, for the proximal bone segments, reliance on intraoperative diagnostic imaging is strongly recommended.

Access to a C-arm should be ensured to provide complete visualization of the proximal and distal joints in both frontal and sagittal planes. If fluoroscopy is not available,

intraoperative radiographs can be obtained with a portable radiograph machine. Intraoperative radiographs are satisfactory for distal limb segments but suboptimal for proximal ones. Furthermore, the issue of radioprotection for the personnel is raised by the latter technique.

Clinical Evaluation

Tibia

The rotational and frontal alignment are subjectively evaluated with the stifle and hock joints flexed at 90°, by aligning the patella, the tibial crest, and the long axis of the III and IV metatarsal bones, and by reestablishing the sagittal plane of the hind limb. Furthermore, the position of the calcaneus can be assessed during flexion and extension of the stifle. If internal tibial torsion is present, the calcaneus appears to be displaced laterally, whereas, with external tibial torsion, it appears to be displaced medially. Moreover, observing the orientation of the pes with respect to the sagittal plane of the crus while palpating the malleoli is very helpful.³⁰

Antebrachium

The same clinical assessment described for the tibia is used to evaluate the alignment of the forearm. The humeral condyle, the radius, and the long axis of the III and IV metacarpal bones are used to reestablish the sagittal plane of the forearm. The position of the flexed manus is useful to assess axial malalignment. A medial position indicates an external radial torsion, whereas a lateral position suggest an internal radial torsion.

Femur

The anatomic relationship between bone landmarks can also be reestablished in the femur, though it is more difficult.

Rotational alignment can be judged by palpation or by direct visualization of the greater trochanter and femoral trochlea through the proximal and distal approaches. The lateral aspect of the femoral trochlea can be palpated or observed through a stifle miniarthrotomy. The distal part of the femur is then held in a true lateral position. The position of the greater trochanter is then inspected through the proximal approach. If the femur is correctly aligned on the axial plane the greater trochanter should be slightly caudal compared with long axis of the bone. According to Dejardin and Guiot,³⁰ with the femur in a true lateral position, the midpoint of the greater trochanter should be slightly caudal to the coronal plane with the distal aspect of the line of origin of the vastus lateralis muscle aligned with the coronal plane.

Furthermore, in a correctly aligned femur, the surgeon can perform a 90° external and 45° internal rotation of the hip. This method is recommended only if the plate has been temporarily secured to the bone.

Humerus

The anatomic landmarks used for clinical evaluation are the humeral epicondyles, the greater tubercle, and the bicipital groove. These landmarks can be used to roughly evaluate humeral axial alignment. When holding the humeral epicondyles in a true mediolateral position, it should be possible to palpate the greater tubercle cranially and the bicipital groove medially.

Intraoperative Diagnostic Imaging

As previously stated, reliance on intraoperative diagnostic imaging is mandatory in the case of proximal limb fractures but generally suggested for all bone segments.

The anatomic details and relationship with the adjacent bones are evaluated through two orthogonal projections. These must include the whole bone segment and the proximal and distal joints. Comparison with the contralateral unaffected limb is also useful, if the required projections have been previously obtained.

Intraoperative fluoroscopy enables several quick spot projections of all the above-mentioned structures and is, therefore, the most useful method of assessing bone alignment.

SUMMARY

Indirect fracture reduction is used to align diaphyseal fractures in small animals when using minimally-invasive fracture repair. Indirect reduction achieves functional fracture reduction without opening the fracture site. The limb is restored to its previous length and spatial alignment is achieved to ensure proper angular and rotational alignment. Fracture reduction can be accomplished using a variety of techniques and devices, including hanging the limb, manual traction, distraction table, external fixators, and a fracture distractor.

REFERENCES

1. Hudson CC, Pozzi A, Lewis DD. Minimally invasive plate osteosynthesis: applications and techniques in dogs and cats. *Vet Comp Orthop Traumatol* 2009;22: 175-82.
2. Luenig M, Hertel R, Siebenrock KA, et al. The evolution of indirect reduction techniques for the treatment of fractures. *Clin Orthop Relat Res* 2000;375:7-14.
3. Bone L. Indirect fracture reduction: a technique for minimizing surgical trauma. *J Am Acad Orthop Surg* 1994;2:247-54.
4. Reems MR, Beale B, Hulse DA. Use of plate and rod constructs and principles of biological osteosynthesis for repair of diaphyseal fractures in dogs and cats: 47 cases (1994-2001). *J Am Vet Med Assoc* 2003;223(3):330-5.
5. King KF, Rush J. Closed intramedullary nailing of femoral shaft fractures. A review of one hundred and twelve cases treated by the Kuntscher technique. *J Bone Joint Surg Am* 1981;63:1319-23.
6. Wu CC. An improved surgical technique to treat femoral shaft malunion: revised reamed intramedullary nailing technique. *Arch Orthop Trauma Surg* 2001; 121: 265-70.
7. Rovesti GL, Margini A, Cappellari G, et al. Intraoperative skeletal traction in the dog. A cadaveric study. *Vet Comp Orthop Traumatol* 2006;19:9-13.
8. Rovesti GL, Margini A, Cappellari G, et al. Clinical application of intraoperative skeletal traction in the dog. *Vet Comp Orthop Traumatol* 2006;19:14-9.
9. Johnson AL. Current concepts in fracture reduction. *Vet Comp Orthop Traumatol* 2003;16:59-66.
10. Piermattei DL, Flo G, DeCamp C. Fracture: Classification, Diagnosis and Treatment. In: *Handbook of small animal orthopedics and fracture repair*. 4th edition. Philadelphia: W.B. Saunders Company; 2006. p. 227-660.
11. Rudy RL. Principles of intramedullary pinning. *Vet Clin North Am* 1975;5:209-28.
12. Pozzi A, Lewis DD. Surgical approaches for minimally invasive plating osteosynthesis in dogs. *Vet Comp Orthop Traumatol* 2009;22(4):316-20.
13. Johnson AL, Hulse DA. Fracture reduction. In: Fossum TW, editor. *Small animal surgery*. 2nd edition. St. Louis (MO): Mosby Yearbook Inc; 2002. p. 889-93.
14. DeJardin L, Guiot L. "MIO in diaphyseal humeral fractures". Lectures abstracts booklet. Las Vegas (NV): Small Animal MIO Traumatology Course; 2011.

15. Witzberger TH, Hulse DA, Kerwin SC, et al. Minimally invasive application of a radial plate following placement of an ulnar rod in treating antebrachial fractures. *Vet Comp Orthop Traumatol* 2010;23:459-67.
16. Edgerton BC, An KN, Morrey BF. Torsional strength reduction due to cortical defects in bone. *J Orthop Res* 1990;8:851-5.
17. Jackson M, Topliss CJ, Atkins RM. Technical tricks: fine wire frame assisted intramedullary nailing of the tibia. *J Orthop Trauma* 2003;17(3):222-4.
18. Marti JM, Miller A. Delimitation of safe corridors for the insertion of external fixator pins in the dog 2: Forelimb. *JSAP* 1994;35:78-85.
19. Ferretti A. The application of the Ilizarov technique to veterinary medicine. In: Maiocchi AB, Aronson J, editors. *Operative principles of Ilizarov*. Baltimore (MD): Williams & Wilkins; 1991. p. 551-70.
20. Rovesti GL, Bosio A, Marcellin-Little DJ. Management of 49 antebrachial and crural fractures in dogs using circular external fixators. *JSAP* 2007;48:194-200.
21. Guiot LP, Dejardin LM. Prospective evaluation of minimally invasive plate osteosynthesis in 36 nonarticular tibial fractures in dogs and cats. *Vet Surg* 2011;40:171-82.
22. Eidelman M, Ghayeb N, Katzman A, et al. Submuscular plating of femoral fractures in children: the importance of anatomic plate precontouring. *J Pediatr Orthop B* 2010;19:424-7.
23. Schmokel HG, Hurter K, Schawalder P. Percutaneous plating of tibial fractures in two dogs. *Vet Comp Orthop Traumatol* 2003;16:191-5.
24. Sanders R, Haidukewych GJ, Milne T, et al. Minimal versus maximal plate fixation techniques of the ulna: the biomechanical effect of number of screws and plate length. *J Orthop Trauma* 2002;16:166-71.
25. Miller DL, Goswami T A review of locking compression plate biomechanics and their advantages as internal fixators in fracture healing. *Clin Biomech* 2007;22:1049-62.
26. Wagner M. General principles for the clinical use of the LCP *Injury* 2003;34(2):B31-42.
27. On Tong G. Suthorn Bavonratanavech. *AO manual of fracture management - Minimally Invasive Plate Osteosynthesis (MIPO)*. Davos Platz (Switzerland): AO publishing; 2007.
28. Haaland PJ, Sjostrom L, Devor M, et al. Appendicular fracture repair in dogs using the locking compression plate system: 47 cases. *Vet Comp Orthop Traumatol* 2009;22:309-15.
29. Petazzoni M, Urizzi A, Verdonck B, et al. Fixin internal fixator: concept and technique. *Vet Comp Orthop Traumatol* 2010;23:250-3.
30. Dejardin L, Guiot L. "Limit and complications of MIO". *Lectures abstracts booklet*. Las Vegas (NV): Small Animal MIO Traumatology Course; 2011.