

AperTO - Archivio Istituzionale Open Access dell'Università di Torino

Biology, diagnosis and treatment of canine appendicular osteosarcoma: Similarities and differences with human osteosarcoma

This is the author's manuscript

Original Citation:

Availability:

This version is available <http://hdl.handle.net/2318/127045> since

Published version:

DOI:10.1016/j.tvjl.2010.08.014

Terms of use:

Open Access

Anyone can freely access the full text of works made available as "Open Access". Works made available under a Creative Commons license can be used according to the terms and conditions of said license. Use of all other works requires consent of the right holder (author or publisher) if not exempted from copyright protection by the applicable law.

(Article begins on next page)



UNIVERSITÀ DEGLI STUDI DI TORINO

This Accepted Author Manuscript (AAM) is copyrighted and published by Elsevier. It is posted here by agreement between Elsevier and the University of Turin. Changes resulting from the publishing process - such as editing, corrections, structural formatting, and other quality control mechanisms - may not be reflected in this version of the text. The definitive version of the text was subsequently published in Vet J. 2011 Sep;189(3):268-77. doi: 10.1016/j.tvjl.2010.08.014

You may download, copy and otherwise use the AAM for non-commercial purposes provided that your license is limited by the following restrictions:

- (1) You may use this AAM for non-commercial purposes only under the terms of the CC-BY-NC-ND license.
- (2) The integrity of the work and identification of the author, copyright owner, and publisher must be preserved in any copy.
- (3) You must attribute this AAM in the following format: Creative Commons BY-NC-ND license (<http://creativecommons.org/licenses/by-nc-nd/4.0/deed.en>), <http://www.sciencedirect.com/science/article/pii/S1090023310002881>

Biology, diagnosis and treatment of canine appendicular osteosarcoma: Similarities and differences with human osteosarcoma

Emanuela Morello *, Marina Martano, Paolo Buracco

School of Veterinary Medicine, Department of Animal Pathology, via Leonardo da Vinci 44, 10095 Grugliasco, Italy

*Corresponding author. Tel.: +39 011 6709062; fax: +39 011 6709165. E-mail address: emanuela.morello@unito.it

Keywords:

Osteosarcoma

Canine

Human

Aetiology

Diagnosis

Treatment

A B S T R A C T

Osteosarcoma (OSA) is the most common primary bone tumour in dogs. The appendicular locations are most frequently involved and large to giant breed dogs are commonly affected, with a median age of 7-8 years. OSA is a locally invasive neoplasm with a high rate of metastasis, mostly to the lungs. Due to similarities in biology and treatment of OSA in dogs and humans, canine OSA represents a valid and important tumour model. Differences between canine and human OSAs include the age of occurrence (OSA is most commonly an adolescent disease in humans), localisation (the stifle is the most common site of localisation in humans) and limited use of neoadjuvant chemotherapy in canine OSA.

Introduction

Spontaneous tumours in dogs may serve as models for human cancer biology and translational cancer therapeutics, having greater similarity than many current experimental tumour models. Canine osteosarcoma (OSA) is a suitable model for OSA in humans due to the relatively high incidence of the tumour in dogs, similarities in biological behaviour, common molecular features, large body size of breeds more frequently affected and sharing of the same environment. The lack of specific chemotherapeutic drugs in veterinary medicine and the sometimes prohibitive costs of treatment for the management of cancer in dogs allow early access to novel therapeutics. Dogs have a naturally shorter life span, with more rapid progression and early metastatic failure of cancer, permitting more rapid completion of clinical trials in this species compared to human patients. This paper gives an overview of the biology and treatment options of OSA in dogs and humans.

Clinical presentation of appendicular osteosarcoma

Canine OSA accounts for 85-98% of all canine bone tumours (Liptak et al., 2004b; Dernell et al., 2007). Appendicular locations are more common (75%), but OSA can also affect the axial skeleton (24%) and, occasionally, soft tissues (1%). Appendicular OSA is a locally aggressive malignant neoplasm which destroys bone locally, extends into surrounding soft tissues and has a high rate of metastasis. Metastasis occurs mainly to the lungs via the haematogenous route, as well as to other bones, visceral organs, the brain, subcutaneous tissue and skin (Gorman et al., 2006; Dernell et al., 2007). Lymph nodes are involved less commonly, with reported frequencies of 4.4-9.0% (Brodey and Abt, 1976; Spodnick et al., 1992; Hillers et al., 2005). The use of chemotherapy as part of standard curative-intent treatment is associated with an increase in the rate of bone and soft tissue metastases (Dernell et al., 2007).

In dogs, appendicular OSAs most often affect the metaphyses of long bones. The fore limbs are affected twice as often as the hind limbs, with the distal radius and proximal humerus being the most frequent sites, followed by the distal femur and proximal and distal tibia (Straw et al., 1990; Dernell et al., 2007). Large and giant breeds are more commonly affected; only 5% of OSAs occur in dogs <15 kg (Dernell et al., 2007). Greyhounds, Rottweilers, Great Danes, Saint Bernards, Doberman Pinschers, Irish Setters, Golden Retrievers and German Shepherds have an increased risk of developing OSA, even though the predisposition seems to be related to size rather than breed (Ru et al., 1998; Rosenberger et al., 2007). A familial pattern of

occurrence has been observed in the Saint Bernard, Rottweiler and Scottish Deerhound (Misdorp, 1980; Phillips et al., 2007). Males are more often affected than females (ratio 1.5:1), but this finding is not consistent among publications (Brodey and Abt, 1976; Mauldin et al., 1988; Shapiro et al., 1988; Kraegel et al., 1991; Spodnick et al., 1992). Affected females mainly belong to the Great Dane, Saint Bernard and Rottweiler breeds. The age at presentation has a bimodal distribution; a first peak is reported at 18-24 months, but most dogs are 7-9 years old (Dernell et al., 2007). Neutered dogs have twice the risk of developing OSA compared with sexually intact dogs (Ru et al., 1998). A study on 683 Rottweilers undergoing gonadectomy before 1 year of age found a strong inverse association between lifetime exposure to gonadal hormones and incidence of OSA, suggesting that sex hormones may play a role in tumour development (Cooley et al., 2002).

Human OSA is the most common primary solid bone tumour in childhood and adolescence (Carrle and Bielack, 2006; Ta et al., 2009). The incidence is higher in the second decade of life, during periods of rapid bone turnover, with a median age of 16 years (Ta et al., 2009). After 10 years of age, males are more frequently affected than females. A second peak in incidence occurs in older patients, usually associated with underlying bone pathology, such as Paget's disease, medullary infarcts or prior irradiation (Ta et al., 2009). The metaphysis of long bones is the primary site in more than 80% of cases. OSAs develop most commonly at sites of rapid bone turnover, such as the distal femur, proximal tibia and proximal humerus (Messerschmitt et al., 2009).

Metastases are clinically detectable in approximately 20% of human patients on initial presentation (O'Day and Gorlick, 2009) and metastatic spread is usually by the haematogenous route. The lungs are the most common metastatic site (80-85%), followed by bone (10%), which is usually involved only after pulmonary metastasis (Federman et al., 2009). Less frequent sites of metastases include lymph nodes (<10%), liver, adrenal glands, central nervous system, muscle and skin (Ta et al., 2009). Patients without clinically detectable metastases are presumed to have micrometastatic disease (Messerschmitt et al., 2009).

Aetiology and risk factors for osteosarcoma

The aetiology of most OSAs remains unknown both in humans and dogs. Some factors have been identified as possibly being involved in development of canine OSA.

Dogs

Ionising radiation

In both therapeutic and experimental settings, exposure to ionising radiation can induce OSA. Beagles administered aerosols containing plutonium dioxide developed OSAs in the lungs, skeleton and liver, beginning about 3 years after exposure (Muggenburg et al., 1996). Skeletal malignancies, most of which were OSAs, were documented among 234 young adult beagles given single intravenous injections of monomeric ²³⁹Plutonium citrate (Lloyd et al., 1993). In another experimental study, 36/117 young adult beagles injected with ²⁴¹Americium developed OSA (Lloyd et al., 1994).

Several reports of OSA as a late complication of radiation therapy in dogs have been described. A vertebral OSA occurred in a dog 5 years after ⁶⁰Cobalt teletherapy for a spinal cord tumour (Dickinson et al., 2001). Secondary OSAs developed within the field of megavoltage irradiation 1.7-5 years after treatment in 3/87 (3.4%) of spontaneous tumour-bearing dogs irradiated for soft tissue sarcomas (Gillette et al., 1990). OSA has also been reported after orthovoltage irradiation of oral acanthomatous epulis (Thrall, 1984; White et al., 1986). In an experimental study, 21% of dogs undergoing intra-operative radiation therapy (>25 Gy) to the vertebral column, followed in some cases by external beam radiation, developed OSA 4-5 years post-treatment (Powers et al., 1989).

Minor chronic trauma

Long-standing metallic implants (e.g. Jonas intramedullary splints and older generation tibial plateau levelling osteotomy plates) after orthopaedic procedures have been associated with the development of OSA (Sinibaldi et al., 1976, 1982; Murphy et al., 1997; Boudrieau et al., 2005; Harasen and Simko, 2008). Hypotheses to explain this phenomenon include a direct effect of metal implants, infection, instability of the implant and corrosion (Stevenson, 1991). However, given the large number of orthopaedic surgical implants routinely applied and the fact that no conclusions have been drawn on the role of metallic implants in sarcoma development, the occurrence of malignant lesions at the same site may be no more than a coincidence (Murphy et al., 1997). Underlying diseases, such as spontaneous or post-orthopaedic surgery bone infarcts and osteochondritis dissecans, have also been reported as possible causative factors in dogs (Riser et al., 1972; Dubielzig et al., 1981; Marcellin-Little et al., 1999; Holmberg et al., 2004). A study by Gellasch et al. (2002) on two groups of dogs of different sizes (<15 kg; >25 kg) failed to demonstrate increased microdamage in the distal metaphyseal radius in the large size group, suggesting that microdamage is unlikely to be an important risk factor for OSA.

Genetic alterations

In one study, 27 p53 tumour suppressor gene mutations (20 point mutations and 7 deletions) were observed in 24/59 (40.7%) canine OSAs (Kirpensteijn et al., 2008). Cases of OSA with mutated p53 had a decreased survival time compared to dogs without p53 alterations (Kirpensteijn et al., 2008). In two other studies, p53 was over-expressed in the majority of canine OSAs and alterations in its expression correlated with highly aggressive tumour behaviour and higher tumour grade (Sagartz et al., 1996; Loukopoulos et al., 2003). Mutations in p53 have also been observed in other studies of canine OSA by van Leeuwen et al. (1997) and Mendoza et al. (1998).

Over-expression of erb-B2, which encodes human epidermal growth factor receptor 2 (HER-2), was observed in 86% and

40% of canine OSA cell lines and tissue samples, respectively (Flint et al., 2004). Deletions, mutations and down-regulation of the PTEN tumour suppressor gene have also been detected in OSA cell lines and tumour samples (Levine et al., 2002). Hepatocyte growth factor (HGF) and its receptor c-Met were expressed in most OSA samples (Ferracini et al., 2000; De Maria et al., 2009; Fieten et al., 2009). A role for insulin-like growth factor-1 (IGF-1) and its receptor (IGF-1R) in cell growth and invasion in OSA canine cell lines has been demonstrated (MacEwen et al., 2004). Matrix metalloproteinases 2 and 9, which may contribute to local disease progression and metastatic spread, are expressed in OSA cell lines and tissues (Lana et al., 2000; Loukopoulos et al., 2004). Similarly, ezrin, a membrane cytoskeleton linker also potentially involved in metastasis, was detected in 83% of primary canine OSAs and its presence was associated with a shorter median disease-free interval compared to OSAs with low ezrin expression (Khanna et al., 2004). Constitutive activation of signal transducer and activator of transcription 3 (STAT3) was present in a subset of canine OSA tumours and cell lines, but not in normal canine osteoblasts (Fossey et al., 2009).

Humans

Factors associated with the development of OSA in humans include the faster growth rate of bone at puberty, exposure to chemicals such as beryllium, cytogenetic abnormalities, hereditary retinoblastoma (mutations in the *RB* gene), Li-Fraumeni syndrome (mutations in the *p53* gene), Bloom syndrome, Rothmund-Thomson syndrome and Werner's syndrome (Mueller et al., 2007; Ta et al., 2009). Radiation-induced OSAs are rare and typically occur in adults because of the long interval (5-20 years) between radiation exposure and neoplastic transformation (Mala-wer et al., 2008; Ta et al., 2009).

In human OSAs, tumorigenesis has been associated with alterations in tumour suppressor proteins (*p53*, *Rb*, *PTEN*), alterations in oncogene expression (*erbB-2*, *MET*) and dysregulated cell signalling and kinase pathways, such as vascular endothelial growth factor (*VEGF*), platelet-derived growth factor (*PDGF*), *mTOR*, *c-Kit*, metalloproteinases and ezrin (Mueller et al., 2007; O'Day and Gorlick, 2009; Ta et al., 2009).

History and physical examination

Dogs

Dogs with appendicular OSA are referred for the onset of progressive lameness and leg swelling (Dernell et al., 2007). Lameness is usually intermittent and initially mild, but progresses to become persistent and severe. The mass at the primary site is usually firm and often painful on palpation. Acute non-weight bearing lameness is typically associated with a pathological fracture.

Humans

Human patients with OSA present with pain of several months' duration (2-4 months before diagnosis), usually related to strenuous exercise or trauma, and the pain interferes with sleep. On clinical examination, a visible swelling with a hard painful mass, decreased joint mobility or localised warmth or erythema may be present. Approximately 5-10% of patients with OSA present with a pathological fracture (Messerschmitt et al., 2009; Ta et al., 2009).

Diagnosis and staging

Dogs

A diagnosis of primary malignant bone tumour is often suggested by clinical presentation and radiographic findings. Initial diagnosis can be attempted by fine needle aspiration and cytology (Loukopoulos et al., 2005; Reinhardt et al., 2005; Britt et al., 2007). Alkaline phosphatase (ALP) staining of cytology samples is useful for differentiating between OSA and other primary bone tumours (Britt et al., 2007). Bone biopsy can be performed via closed (Jamshidi needle or Michelle's trephine) or open techniques (Powers et al., 1988). The diagnostic quality of cytological or histological bone samples can be improved by image-guided techniques (Vignoli et al., 2004; Britt et al., 2007).

Diagnostic imaging plays an important role in diagnosis and staging of dogs with OSA. Cranio-caudal and latero-medial radiographic views of the primary lesion, including the joint above and below the affected bone, are required. The radiographic appearance of OSA in long bones includes cortical bone lysis and/or a proliferative sunburst pattern, periosteal proliferation, sub-periosteal new bone formation and soft tissue swelling, with calcification extending into surrounding soft tissue.

Several studies have been performed to evaluate the accuracy of radiography, bone scintigraphy, computed tomography (CT) and magnetic resonance imaging (MRI) in assessing the local extent of appendicular OSA (LaRue et al., 1986; Berg et al., 1990; Hahn et al., 1990). In one study, MRI was recognised as the best modality for preoperative assessment of intramedullary extent of appendicular OSA when limb-sparing was an option (Wallach et al., 2002). Another study comparing radiographs, MRI and CT in 10 post-amputation OSA cases failed to identify a superior modality in predicting extent of tumour infiltration (Davis et al., 2002). Nuclear scintigraphy overestimated the local extent of OSA more than radiography, providing a larger

margin of safety when determining the site of the proximal osteotomy, but also decreasing candidates for limb-sparing surgery (Leibman et al., 2001).

Thoracic radiographs are performed to evaluate metastatic spread to the lungs. Only a few patients (<5-10%) are positive for radiographic lung metastasis at presentation, but OSA is considered to be a tumour with a high metastatic potential, since approximately 90% of dogs with OSA treated by amputation only die of metastatic disease, usually to the lung, within 1 year of diagnosis (Dernell et al., 2007). CT of the thorax is superior to radiography in detecting smaller lung lesions (Nemanic et al., 2006). Using nuclear scintigraphy, the incidence of occult bone metastasis at the time of diagnosis of the primary tumour is 7.9%; lesions appear as non-specific areas of increased uptake of radiopharmaceutical that should be verified by radiographs or biopsy (Jankowski et al., 2003).

Humans

In humans, at least two orthogonal radiographic views are required when a bone lesion is suspected. The classical radiographic appearance is of ill-defined borders, an osteoblastic and/or osteolytic lesion and an associated soft tissue mass. MRI represents the primary mode of evaluation of OSA in humans and can clearly demonstrate the extent of tumour invasion of the surrounding soft tissue, neurovascular involvement, extent of bone marrow replacement and presence of discontinuous metastases (Federman et al., 2009). MRI is also useful to assess the possibility of limb salvage. CT-guided core biopsy is frequently used for tissue biopsy for histopathological diagnosis (Federman et al., 2009). A CT scan of the chest and a nuclear scintigraphy bone scan are recommended to rule out metastasis to the lungs and bone. Interest in the use of positron-emission tomography (PET) for staging OSAs and monitoring treatment is increasing (Federman et al., 2009).

Treatment

Dogs

Dogs with appendicular OSA can be managed with either palliative- or curative-intent therapy. Curative-intent treatment is aimed at local tumour control and prevention or delay of metastatic disease.

Limb amputation

Limb amputation remains the current standard of care for local management (Brodey and Abt, 1976; Spodnick et al., 1992). It avoids the risk of pathological fracture, eliminates pain and is a well tolerated procedure, with minimal complications; even large breed dogs show good functional results and the majority of owners are satisfied with the pet's quality of life (Carberry and Harvey, 1986; Kirpensteijn et al., 1999). Contraindications to amputation may be severe obesity or concurrent debilitating orthopaedic or neurological diseases; however, each case needs to be evaluated on an individual basis.

Limb-sparing surgery

Limb-sparing in dogs can be achieved with surgical and/or radiation techniques. Good results have been reported with reconstructive limb-sparing procedures for OSA of the distal radius, whereas limb-sparing surgery at other sites is associated with a higher complication rate and poor limb function (Kuntz et al., 1998; Morello et al., 2001). Conversely, a lower complication rate and good restoration of limb function have been reported after ablative limb-sparing techniques for OSA in the ulna, scapula, metacarpus, metatarsus and ischium.

Several surgical techniques have been used to preserve the limb and they represent a valid alternative to amputation. After surgical resection of the OSA, the defect may be filled with a frozen cortical allograft (LaRue et al., 1989; Morello et al., 2001; Liptak et al., 2004a), an endoprosthesis (Liptak et al., 2006) (Fig. 1) or with the resected neoplastic bone after it has been pasteurised (Buracco et al., 2002; Morello et al., 2003) (Fig. 2), autoclaved (Massin et al., 1995; Yamamoto et al., 2002) or irradiated (Yamamoto et al., 2002; Liptak et al., 2004c; Boston et al., 2007). Bone or metallic implants are fixed in position with a bone plate and screws, and arthrodesis of the adjacent joint is performed. A combination of allograft and prosthesis has been used to preserve the limb for OSA of the proximal femur (Liptak et al., 2005). The more common complications associated with cortical allograft, pasteurised autograft and endoprosthesis include local tumour recurrence (15-28%), infection (31-60%) and implant failure or loosening (11-40%) (LaRue et al., 1989; Straw and Withrow, 1996; Morello et al., 2001, 2003; Liptak et al., 2006).

After excision of OSAs from the distal radius or tibia, large surgical defects have been replaced by vascularised, viable, regenerated bone by single (Fig. 3) or double transport osteogenesis (Tommasini-Degna et al., 2000; Rovesti et al., 2002; Ehrhart, 2005). Transverse ulnar bone transport osteogenesis has also been investigated experimentally (Jehn et al., 2007). These procedures can achieve good limb function and absence of infection, but problems include local tumour recurrence, owner compliance in distracting the apparatus several times per day and apparatus failure. Limb-sparing surgery has also been performed by rolling the distal ulna into the distal radial defect after tumour excision, thus using the ulna as a vascularised transposition autograft (Seguin et al., 2003). However, the procedure is more likely to have biomechanical complications compared to the standard cortical allograft technique (Pooya et al., 2004).

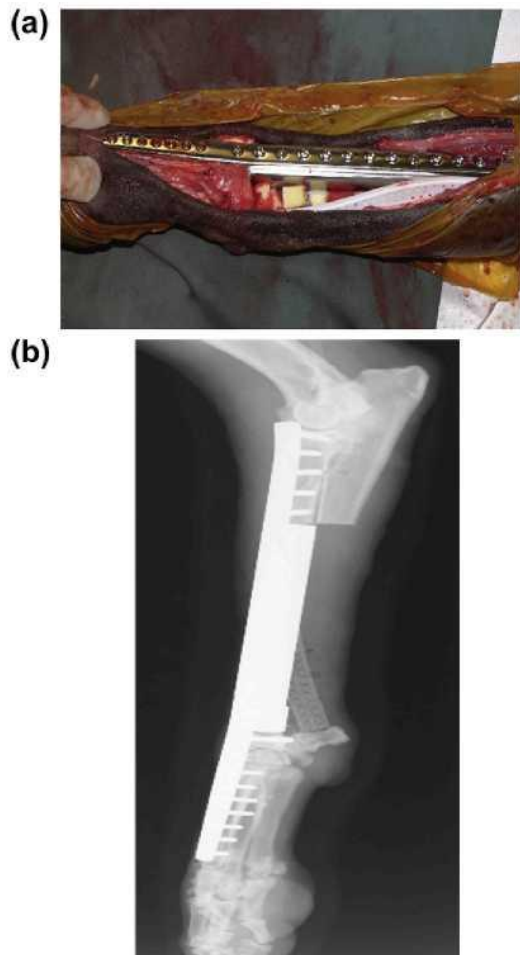


Fig. 1. Distal aspect of the radius of a dog with osteosarcoma treated by limb-sparing surgery with an endoprosthesis. (a) Intra-operative view showing the biodegradable cisplatin-impregnated open-cell polylactic acid implant and closed continuous suction drain. (b) Post-operative lateral radiograph. Images courtesy of Dr. Julius M. Liptak.

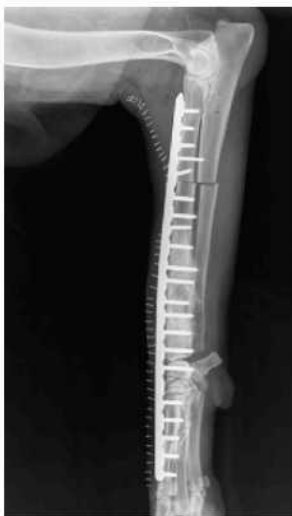


Fig. 2. Post-operative lateral radiograph of a dog with osteosarcoma treated by limb-sparing surgery after pasteurised autograft replacement and plate fixation.

Surgery alone is considered to be palliative. The reported mean survival time after surgery alone is 103-175 days (Brodey and Abt, 1976; Mauldin et al., 1988; Shapiro et al., 1988; Straw et al., 1991 ; Thompson and Fugent, 1991; Berg et al., 1992; Spodnick et al., 1992). The 1- and 2-year survival is 11-20% and 2-4%, respectively (Straw et al., 1991; Thompson and Fugent, 1991; Berg et al., 1992; Spodnick et al., 1992). There are no statistical differences in survival between amputation and limb-sparing surgery if

adequate systemic chemotherapy is given (Straw and Withrow, 1996). An improvement in survival with limb-sparing is only evident if the surgical field becomes infected; the median survival time for dogs with infected surgical sites after limb-sparing is 685 days compared to 289 days in the absence of infection (Lascelles et al., 2005; Liptak et al., 2006). Similar findings have also been reported in humans with limb-sparing surgery (Jeys et al., 2007).

Chemotherapy

Adjuvant chemotherapy can improve survival of dogs with OSA when associated with surgery and/or radiotherapy. Chemotherapy protocols include doxorubicin, cisplatin, carboplatin and lobaplatin used alone or in combination (Table 1). A local cisplatin delivery system has been described (Straw et al., 1994; Withrow et al., 2004; Mehl et al., 2005). Administration of chemotherapy in addition to surgery and/or radiotherapy increases the median survival time from 103-175 days to 262-450 days. The 1- and 2-year survival rates with chemotherapy range from 31-48% to 10-26%, respectively. Survival times for dogs treated with single agent platinum compounds are similar to those reported with combined protocols (Dernell et al., 2007). The most efficacious chemotherapeutic agent and the ideal timing to start adjuvant chemotherapy have not been identified. However, there is no substantial advantage in early post-operative chemotherapy (Berg et al., 1997; Dernell et al., 2007), so it is better to wait an adequate time to allow the patient to recover from surgery and early healing of the surgical wound (Berg et al., 1997). Chemotherapy is usually less effective in the presence of macroscopic metastatic disease (Ogilvie et al., 1993). The efficacy of aerosol-delivered gemcitabine has been investigated by Rodriguez et al. (2010) in dogs with pulmonary metastatic OSA. Pulmonary metastatectomy resulted in significantly prolonged survival in selected patients (O'Brien et al., 1993).

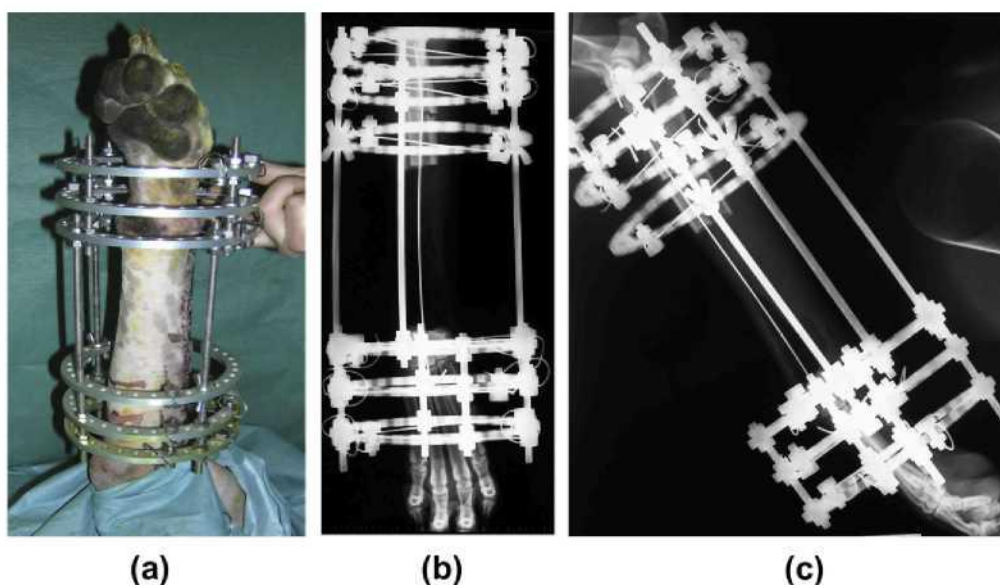


Fig. 3. Single bone transport osteogenesis limb-sparing surgery in the distal radius of a dog with osteosarcoma. Post-operative image of the circular fixator (a). Post-operative lateral (b) and cranio-caudal (c) radiographs of distal radius.

Table 1. Chemotherapeutic agents used for dogs with appendicular osteosarcoma.

Drug	Median survival time (days)	1-year survival (%)	2-year survival (%)
<i>Cisplatin</i>			
Thompson and Fugent (1991)	290	33	NR ^a
Shapiro et al. (1988)	301	NR	NR
Straw et al. (1991)	262	38	18
Kraegel et al. (1991)	413	62	NR
Berg et al. (1992)	325	45.5	20.9
<i>Cisplatin + doxorubicin</i>			
Chun et al. (2005)	300	NR	NR
Mauldin et al. (1988)	300	36.8	26.3
Berg et al. (1997)	345	48	28
<i>Doxorubicin</i>			
Berg et al. (1995)	366	50.5	9.7
Moore et al. (2007)	240	35	17
<i>Carboplatin</i>			
Bergman et al. (1996)	321	35.4	NR
Phillips et al. (2009)	307	36.8	18.7
<i>Carboplatin + doxorubicin</i>			
Bacon et al. (2008)	258	NR	NR
Bailey et al. (2003)	235	NR	NR
Kent et al. (2004)	320	48	18
<i>Carboplatin + doxorubicin + piroxicam</i>			
Langova et al. (2004)	450	NR	NR
<i>Lobaplatin</i>			
Kirpensteijn et al. (2002b)	NR	31	NR

NR, not reported.

Immunotherapy

Immunotherapy has been combined with chemotherapy to enhance anti-tumour effects without increasing toxicity. Anti-tumour activity was observed when the immunomodulatory agent L-muramyl tripeptide-phosphatidylethanolamine (L-MTP-PE) was administered to dogs with OSA after limb amputation or limb-sparing surgery and completion of cisplatin treatment (MacEwen et al., 1994; Kurzman et al., 1995). L-MTP-PE administered with doxorubicin enhanced canine monocyte activation induced by doxorubicin or L-MTP-PE alone (Shi et al., 1993) and induced cytotoxic activity of pulmonary alveolar macrophages against OSA cells when compared to dogs treated with doxorubicin or L-MTP-PE alone (Kurzman et al., 1999).

Radiotherapy

Radiation therapy has a role in curative-intent local treatment of canine appendicular OSA. Walter et al. (2005) proposed a full-course fractionated external beam protocol in conjunction with cisplatin, but there was no substantial improvement over a palliative protocol. A single fraction of 70 Gy given intra-operatively after exteriorisation of the tumoral bone segment has been used in combination with chemotherapy (Liptak et al., 2004c; Boston et al., 2007). Post-operative complications may be high (69%) and include deep infection, fracture of irradiated bone, implant failure and local recurrence. This procedure should only be performed in dogs bearing appendicular OSAs at sites in which limb-sparing techniques are not an option.

A stereotactic radiosurgery protocol has also been used, in which dogs are irradiated with a single large targeted dose (30-50 Gy), with or without chemotherapy (Farese et al., 2004). This allows normal tissue to be spared and avoids the need for surgery in some cases, although pathological fractures may occur.

Palliative-intent treatment

The aim of palliative-intent treatment is to alleviate pain. Radiation therapy is a valid method of palliation for appendicular OSA, inducing relief of pain, reduced lameness and improving quality of life, whereas radiation-induced acute side effects are rare. Radiation therapy protocols include a two-fraction protocol (Ramirez et al., 1999), three-fraction protocols (Bateman et al., 1994; Ramirez et al., 1999; Mueller et al., 2005), four-fraction protocol (Green et al., 2002) and expedited protocol (Knapp-Hoch et al., 2009). The effectiveness and duration of analgesia among these protocols range from 50-93% and 53-180 days, respectively. Most dogs died or were euthanased because of local disease progression, metastatic disease or pathological fractures.

It is not clear if dogs with OSA benefit from more durable pain relief when chemotherapy is combined with radiotherapy (Ramirez et al., 1999; Mueller et al., 2005). Boston et al. (2006) re-reported that longer survival (median survival time 130 days) can be achieved in dogs with metastatic (stage III) appendicular OSA using palliative radiation compared with surgery alone. Palliative-intent treatment for canine OSA has also been attempted by intravenous administration of ¹⁵³Samarium (Barnard et al., 2007).

Bisphosphonates have been proposed for palliative-intent treatment in dogs with OSA. Clinical applications include therapy for tumour-related hypercalcaemia, inhibition of bone metastasis and pain relief. Zoledronic acid (Spugnini et al., 2009), pamidronate (Fan et al., 2005, 2007) and alendronate (Tomlin et al., 2000) provided pain palliation in some treated dogs.

However, when combined with chemotherapy, pamidronate did not improve pain alleviation (Fan et al., 2009). Some success in providing pain palliation in dogs with metastatic appendicular OSA has been achieved using metronomic chemotherapy with doxycycline, piroxicam and cyclophosphamide (Liptak et al., 2004b).

Humans

In humans, multimodality treatment is recommended for OSA. For high grade OSAs, preoperative (neoadjuvant) chemotherapy, wide surgical resection and post-operative chemotherapy are used. The most effective chemotherapeutic agents are doxorubicin, cisplatin, methotrexate and ifosfamide. Combined treatment serves to avoid chemoresistance and to increase the degree of tumour necrosis. There is usually a delay of 3-4 weeks after the last administration of neoadjuvant chemotherapy before the tumour is excised. Adjuvant chemotherapy is usually started 2 weeks after surgery.

Tumour necrosis after administration of preoperative chemotherapy is an important factor in determining the post-operative chemotherapy regimen (O'Day and Gorlick, 2009). Patients with $\geq 90\%$ tumour necrosis at the time of surgery (good responders) will usually receive the same treatment regimen post-operatively as pre-operatively. In patients with $< 90\%$ tumour necrosis (poor responders), post-surgery treatment usually includes a salvage regimen, either an increased dose or duration of the same chemotherapeutic agents or a different protocol, but neither have been shown to improve survival (Messerschmitt et al., 2009).

Amputation and limb-sparing procedures are the two principal surgical options in humans. No significant differences in survival rates and local recurrence (2.8-6%) are reported when amputation or limb-sparing surgery are used. Limb salvage is possible in more than 85% of human appendicular OSAs (Federman et al., 2009; Messerschmitt et al., 2009), but is contraindicated when resection with wide surgical margins is not feasible, in cases of neurovascular involvement or with pathological fractures. The options available for limb salvage include tumour removal and endoprosthetic replacement, rotationplasty, allografts and autografts. Limb-sparing complications include infection (11%) and implant failure. Tumour excision usually includes resection of both primary and metastatic sites; excision of all clinically detectable tumours is associated with a 5-fold increase in survival compared with excision of the primary tumour alone.

In humans, 5-year survival of 10-20% has been reported after amputation without chemotherapy, whereas a 5-year survival rate of 60-78% has been reported for non-metastatic patients when surgery is combined with systemic multi-agent chemotherapy (Malawer et al., 2008). Despite multimodality treatment, 30-40% of OSA patients still experience relapses within 3 years of treatment.

An increase in 5-year survival has been obtained by combining L-MTP-PE immunotherapy with chemotherapy in non-metastatic patients. Radiation therapy is mainly used as palliation for unresectable tumours, as well as for incompletely resected tumour excision margins (Federman et al., 2009). Pain palliation has also been achieved by use of radiopharmaceuticals such as $^{153}\text{Samarium}$ (O'Day and Gorlick, 2009). Extracorporeal irradiation, including stereotactic radiosurgery or surgically exposed, irradiated and reimplanted bone, are among the more innovative and promising curative-intent uses of radiation therapy (Federman et al., 2009; Ta et al., 2009).

Prognostic factors

Dogs

Negative prognostic indicators associated with a shorter survival time in dogs with appendicular OSA include young age (Spodnick et al., 1992; Loukopoulos and Robinson, 2007), elevated pre-treatment total and bone-specific serum ALP activities (Ehrhart et al., 1998; Garzotto et al., 2000; Kirpensteijn et al., 2002a), metastatic spread to regional lymph nodes (Hillers et al., 2005), high histological grade (grade III) (Kirpensteijn et al., 2002a; Loukopoulos and Robinson, 2007), stage III OSA (distant metastases to bone and/or other sites) (Boston et al., 2006), proximal humeral, rib or scapular involvement (Bergman et al., 1996), higher body weight (Hammer et al., 1995; Ru et al., 1998), incompleteness of excision (Hammer et al., 1995) and tumour volume (Misdorp and Hart, 1979). Percent tumour necrosis induced by chemotherapy or radiation therapy is predictive of local tumour control (Powers et al., 1991).

Humans

In humans, negative prognostic factors include metastases at presentation, metastatic spread to lymph nodes, poor response to preoperative chemotherapy, large tumour volume, increased activities of ALP and lactate dehydrogenase (LDH) in serum, primary localisation in the axial skeleton and inadequate surgical margins (Bacci et al., 2006; Malawer et al., 2008; Messerschmitt et al., 2009; Ta et al., 2009). In one study, time to relapse was longer in patients treated by neoadjuvant chemotherapy than in those given adjuvant chemotherapy (Ta et al., 2009).

Conclusions

Dogs with OSA represent a unique model for OSA in humans due to their similar clinical presentation and molecular features, along with the relatively high number of dogs diagnosed with OSA each year. Differences and similarities between human and canine OSA are summarised in Table 2. Improvements in diagnostic and imaging techniques, chemotherapy and surgical procedures have improved outcomes in both human and canine patients. However, there is still a need for effective

treatment of OSA, mainly to control metastatic disease. Important comparative advances have been made in the study of tumour biology and progression, risk factors and the evaluation of novel cancer strategies. There is likely to be increasing interest from the human cancer drug industry in conducting clinical trials in dogs with OSA before or concomitantly with trials in human patients.

Table 2. Similarities and differences between human and canine appendicular osteosarcomas.

Variables	Dog	Human
Incidence in USA	>8000 cases/year	600 cases/year
Median age	Middle-aged to older dogs Peak of incidence 7–9 years Second small peak at 18–24 months Median peak age at 7 years	Adolescent disease Peak of incidence at 10–20 years Median peak age at 16 years
Race/breed	Large/giant breeds Familiar pattern in Saint Bernard, Rottweiler and Scottish Deerhound	None
Sex	Males slightly more than females: Ratio 1.1–1.5:1	Males more than females: Ratio 1.6:1
Site	75% appendicular skeleton, metaphysis of long bones, mainly distal radius, proximal humerus, distal femur and proximal and distal tibia	Metaphysis or diaphysis of long bones (80–90%) Bones of the knee joint (50%) Proximal humerus (25%)
Aetiology	Not completely known	Not completely known
Histopathological grade	High grade	High grade
Molecular and genetic alterations	p53: Mutated IGF-1/IGF-1R: Over-expressed; Poor clinical outcome HGF/c-Met: Over-expressed; Contributes to malignant phenotype ErbB-2/HER-2: Over-expressed; Poor clinical outcome PTEN: Mutated or down-regulated Ezrin: Detected; Contributes to malignant phenotype Matrix metalloproteinases: Expressed PDGF- β : Expressed VEGF: Expressed P-gp: Expressed	p53: Mutated IGF-1/IGF-1R: Over-expressed; Poor clinical outcome HGF/C-Met: Over-expressed; Contributes to malignant phenotype ErbB-2/HER-2: Over-expressed; Poor clinical outcome PTEN: Mutated or down-regulated Ezrin: Detected; Contributes to malignant phenotype Matrix metalloproteinases: Expressed PDGF- β : Expressed VEGF: Expressed P-gp: Expressed
Clinical signs	Pain Swelling Hard painful mass Uncommon pathological fracture (3%)	Pain Leg swelling Hard painful mass Uncommon pathological fracture
Metastatic site	10% of cases with metastasis at diagnosis: Lung, bone (7.4%) Regional lymph node metastasis (4.4–9.0%)	20% of cases with metastasis at diagnosis: Lung, bone Regional lymph node metastasis < 10%
Treatment	Amputation Limb-sparing techniques Adjuvant chemotherapy: Doxorubicin, platinum	Limb-sparing techniques (90% cases) Amputation (rare) Neoadjuvant chemotherapy: Doxorubicin, methotrexate, isofosfamide, platinum and adjuvant post-surgery
Survival	60% survival at 1 year with chemotherapy	70% survival at 5 years with chemotherapy
Negative prognostic indicators	Metastasis at diagnosis: Lungs, bones, lymph nodes High serum ALP, LDH activities Tumour volume Tumour grade Age: Young dogs	Metastasis at diagnosis: Lungs, bones, lymph nodes High serum ALP, LDH activities Tumour volume Tumour grade Age: Youngest affected Poor response to neoadjuvant chemotherapy: % tumour necrosis
Positive prognostic indicators	Post-operative limb-sparing infection High percentage of tumor necrosis induced by chemotherapy or radiotherapy	Post-operative limb-sparing infection High percentage of tumor necrosis induced by chemotherapy or radiotherapy

IGF-1, insulin-like growth factor-1 ; IGF-1R, IGF-1 receptor; HGF, hepatocyte growth factor, HER-2, human epidermal growth factor receptor 2; PTEN, phosphatase and tensin homolog, PDGF-b, platelet-derived growth factor-b; VEGF, vascular endothelial growth factor; P-gp, P-glycoprotein; ALP, alkaline phosphatase; LDH, lactate dehydrogenase.

Conflict of interest statement

None of the authors of this paper has a financial or personal relationship with other people or organisations that could inappropriately influence or bias the content of the paper.

References

- Bacci, G., Longhi, A., Versari, M., Mercuri, M., Briccoli, A., Picci, P., 2006. Prognostic factors for osteosarcoma of the extremity treated with neoadjuvant chemotherapy. *Cancer* 106,1154-1161.
- Bacon, N.J., Ehrhart, N.P., Dernell, W.S., Lafferty, M., Withrow, S.J., 2008. Use of alternating administration of carboplatin and doxorubicin in dogs with microscopic metastases after amputation for appendicular osteosarcoma: 50 cases (1999-2006). *Journal of the American Veterinary Medical Association* 232, 1504-1510.
- Bailey, D., Erb, H., Williams, L., Ruslander, D., Hauck, M., 2003. Carboplatin and doxorubicin combination chemotherapy for the treatment of appendicular osteosarcoma in the dog. *Journal of Veterinary Internal Medicine* 17,199-205.
- Barnard, S.M., Zuber, R.M., Moore, A.S., 2007. Samarium Sm 153 lexidronam for the palliative treatment of dogs with primary bone tumors: 35 cases (1999-2005). *Journal of the American Veterinary Medical Association* 230,1877-1881.
- Bateman, K.E., Catton, P.A., Pennock, P.W., Kruth, S.A., 1994. 0-7-21 radiation therapy for the palliation of advanced cancer in dogs. *Journal of Veterinary Internal Medicine* 8, 394-399.
- Berg, J., Lamb, C.R., O'Callaghan, W., 1990. Bone scintigraphy in the initial evaluation of dogs with primary bone lesions. *Journal of the American Veterinary Medical Association* 196, 917-920.
- Berg, J., Gebhardt, M.C., Rand, W.M., 1997. Effect of timing of postoperative chemotherapy on survival of dogs with osteosarcoma. *Cancer* 79,1343-1350.
- Berg, J., Weinstein, M.J., Shelling, S.H., Rand, W.M., 1992. Treatment of dogs with osteosarcoma by administration of cisplatin after amputation and limb sparing: 22 cases (1987-1990). *Journal of the American Veterinary Medical Association* 200, 2005-2008.
- Berg, J., Weinstein, M.J., Springfield, D.S., Rand, W.M., 1995. Results of surgery and doxorubicin chemotherapy in dogs with osteosarcoma. *Journal of the American Veterinary Medical Association* 206,1555-1560.
- Bergman, P.J., MacEwen, E.G., Kurzman, I.D., Henry, C.J., Hammer, A.S., Knapp, D.W., Hale, A., Kruth, S.A., Klein, M.K., Klausner, J., Norris, A.M., McCaw, D., Straw, R.C., Withrow, S.J., 1996. Amputation and carboplatin for treatment of dogs with osteosarcoma: 48 cases (1991-1993). *Journal of Veterinary Internal Medicine* 10, 76-81.
- Boston, S.E., Ehrhart, N.P., Dernell, W.S., Lafferty, M., Withrow, S.J., 2006. Evaluation of survival time in dogs with stage III osteosarcoma that undergo treatment: 90 cases (1985-2004). *Journal of the American Veterinary Medical Association* 228, 1905-1908.
- Boston, S.E., Duerr, F., Bacon, N., LaRue, S., Ehrhart, E.J., Withrow, S., 2007. Intraoperative radiation for limb sparing of the distal aspect of the radius without transcarpal plating in five dogs. *Veterinary Surgery* 36, 314-323.
- Boudrieau, R.J., McCarthy, R.J., Sisson, R.D., 2005. Sarcoma of the proximal portion of the tibia in a dog 5.5 years after tibial plateau leveling osteotomy. *Journal of the American Veterinary Medical Association* 227,1613-1617.
- Britt, T., Clifford, C., Barger, A., Moroff, S., Drobotz, K., Thacher, C., Davis, G., 2007. Diagnosing appendicular osteosarcoma with ultrasound-guided fine-needle aspiration: 36 cases. *Journal of Small Animal Practice* 48,145-150.
- Brodey, R.S., Abt, D.A., 1976. Results of surgical treatment in 65 dogs with osteosarcoma. *Journal American Veterinary Medical Association* 168, 1032-1035.
- Buracco, P., Martano, M., Morello, E., Vasconi, M.E., 2002. Pasteurized tumoral autograft as a novel procedure of limb sparing in dogs: a clinical report in a canine distal radial osteosarcoma. *Veterinary Surgery* 31, 525-532.
- Carberry, C.A., Harvey, H.J., 1986. Owner satisfaction with limb amputation in dogs and cats. *Journal of the American Animal Hospital Association* 23, 227-232.
- Carrle, D., Bielack, S.S., 2006. Current strategies of chemotherapy in osteosarcoma. *International Orthopaedics* 30, 445-451.
- Chun, R., Garret, L.D., Henry, C., Wall, M., Smith, A., 2005. Toxicity and efficacy of cisplatin and doxorubicin combination chemotherapy for the treatment of canine osteosarcoma. *Journal of the American Animal Hospital Association* 41, 382-387.

- Cooley, D.M., Beranek, B.C., Schlittler, D.L., Glickman, N.W., Glickman, L.T., Waters, D.J., 2002. Endogenous gonadal hormone exposure and bone sarcoma risk. *Cancer Epidemiology Biomarkers and Prevention* 1, 1434-1440.
- Davis, G.J., Kapatkin, A.S., Craig, L.E., Heins, G.S., Wortman, J.A., 2002. Comparison of radiography, computed tomography, and magnetic resonance imaging for evaluation of appendicular osteosarcoma in dogs. *Journal of the American Veterinary Medical Association* 220,1171-1176.
- De Maria, R., Miretti, S., Iussich, S., Olivero, M., Morello, E., Bertotti, A., Christensen, J.G., Biolatti, B., Levine, R.A., Buracco, P., Di Renzo, M.F., 2009. *Met* oncogene activation qualifies spontaneous canine osteosarcoma as a suitable pre-clinical model of human osteosarcoma. *Journal of Pathology* 218, 399-408.
- Dernell, W.S., Ehrhart, N.P., Straw, R.C., Vail, D.M., 2007. Tumors of the skeletal system. In: Withrow, S.J., Vail, D.M. (Eds.), *Withrow and MacEwen's Small Animal Clinical Oncology*. Saunders, Elsevier, St. Louis, MI, USA, pp. 540-582.
- Dickinson, P.J., McEntee, M.C., Lipsitz, D., Keel, K., LeCouteur, R.A., 2001. Radiation induced vertebral osteosarcoma following treatment of an intradural extramedullary spinal cord tumor in a dog. *Veterinary Radiology and Ultrasound* 42, 463-470.
- Dubielzig, R.R., Biery, D.N., Brodey, R.S., 1981. Bone sarcomas associated with multifocal medullary bone infarction in dogs. *Journal of the American Veterinary Medical Association* 79, 64-68.
- Ehrhart, N., Dernell, W.S., Hoffmann, W.E., Weigel, R.M., Powers, B.E., Withrow, S.J., 1998. Prognostic importance of alkaline phosphatase activity in serum from dogs with appendicular osteosarcoma: 75 cases (1990-1996). *Journal of the American Veterinary Medical Association* 213,1002-1006.
- Ehrhart, N., 2005. Longitudinal bone transport for treatment of primary bone tumors in dogs: technique description and outcome in 9 dogs. *Veterinary Surgery* 34, 24-34.
- Fan, T.M., de Lorimer, L.P., Charney, S.C., Hintermesister, J.G., 2005. Evaluation of intravenous pamidronate administration in 33 cancer-bearing dogs with primary or secondary bone involvement. *Journal of Veterinary Internal Medicine* 19, 74-80.
- Fan, T.M., de Lorimier, L.P., O'Dell-Anderson, K., Lacoste, H.I., Charney, S.C., 2007. Single-agent pamidronate for palliative therapy of canine appendicular osteosarcoma bone pain. *Journal of Veterinary Internal Medicine* 21, 431-439.
- Fan, T.M., Charney, S.C., de Lorimier, L.P., Garrett, L.D., Griffon, D.J., Gordon-Evans, W.J., Wypij, J.M., 2009. Double-blind placebo-controlled trial of adjuvant pamidronate with palliative radiotherapy and intravenous doxorubicin for canine appendicular osteosarcoma bone pain. *Journal of Veterinary Internal Medicine* 23,152-160.
- Farese, J.P., Milner, R., Thompson, M.S., Lester, N., Cooke, K., Fox, L., Hester, J., Bova, F.J., 2004. Stereotactic radiosurgery for treatment of osteosarcomas involving the distal portions of the limbs in dogs. *Journal of the American Veterinary Medical Association* 225,1567-1572.
- Federman, N., Bernthal, N., Eilber, F.C., Tap, W.D., 2009. The multidisciplinary management of osteosarcoma. *Current Treatment Options in Oncology* 10, 82-93.
- Ferracini, R., Angelini, P., Cagliero, E., Linari, A., Martano, M., Wunder, J., Buracco, P., 2000. MET oncogene aberrant expression in canine osteosarcoma. *Journal of Orthopedic Research* 18, 253-256.
- Fieten, H., Spee, B., Ijzer, J., Kik, M.J., Penning, L.C., Kirpensteijn, J., 2009. Expression of hepatocyte growth factor and the proto-oncogenic receptor c-Met in canine osteosarcoma. *Veterinary Pathology* 46, 869-877.
- Flint, A.F., U'Ren, L., Legare, M.E., Withrow, S.J., Dernell, W.S., Hanneman, W.H., 2004. Overexpression of the *erbB-2* proto-oncogene in canine osteosarcoma cell lines and tumors. *Veterinary Pathology* 41, 291-296.
- Fossey, S.L., Liao, A.T., McCleese, J.K., Bear, M.D., Lin, J., Li, P.K., Kisseberth, W.C., Cheryl, A., London, C.A., 2009. Characterization of STAT3 activation and expression in canine and human osteosarcoma. *BMC Cancer* 9,1-15.
- Garzotto, C.K., Berg, J., Hoffmann, W.E., Rand, W.M., 2000. Prognostic significance of serum alkaline phosphatase activity in canine appendicular osteosarcoma. *Journal of Veterinary Internal Medicine* 14, 587-592.
- Gellasch, K.L., Kalscheur, V.L., Clayton, M.K., Muir, P., 2002. Fatigue microdamage in the radial predilection site for osteosarcoma in dogs. *American Journal of Veterinary Research* 63, 896-899.

- Gillette, S.M., Gillette, E.L., Powers, B.E., Withrow, S.J., 1990. Radiation-induced osteosarcoma in dogs after external beam or intraoperative radiation therapy. *Cancer Research* 50, 54-57.
- Gorman, E., Barger, A.M., Wypij, J.M., Pinkerton, M.E., 2006. Cutaneous metastasis of primary appendicular osteosarcoma in a dog. *Veterinary Clinical Pathology* 35, 358-361.
- Green, E.M., Adams, W.M., Forrest, L.J., 2002. Four fraction palliative radiotherapy for osteosarcoma in 24 dogs. *Journal of the American Animal Hospital Association* 38, 445-451.
- Hahn, K.A., Hurd, C., Cantwell, H.D., 1990. Single-phase methylene diphosphate bone scintigraphy in the diagnostic evaluation of dogs with osteosarcoma. *Journal of the American Veterinary Medical Association* 196,1483-1486.
- Hammer, A.S., Weeren, F.R., Weisbrode, S.E., Padgett, S.L., 1995. Prognostic factors in dogs with osteosarcomas of the flat or irregular bones. *Journal of the American Animal Hospital Association* 31, 321-326.
- Harasen, G.L.G., Simko, E., 2008. Histiocytic sarcoma of the stifle in a dog with cranial cruciate ligament failure and TPLO treatment. *Veterinary and Comparative Orthopaedics and Traumatology* 21, 375-377.
- Hillers, K.R., Dernell, W.S., Lafferty, M., Withrow, S.J., Lana, S.E., 2005. Incidence and prognostic importance of lymph node metastases in dogs with appendicular osteosarcoma: 228 cases (1986-2003). *Journal of the American Veterinary Medical Association* 226, 1364-1367.
- Holmberg, B.J., Farese, J.P., Taylor, D., Uhl, E.W., 2004. Osteosarcoma of the humeral head associated with osteochondritis dissecans in a dog. *Journal of the American Animal Hospital Association* 40, 246-249.
- Jankowski, M.K., Steyn, P.F., Lana, S.E., Dernell, W.S., Blom, C.M., Uhrig, J.L., Lafferty, M., Withrow, S.J., 2003. Nuclear scanning with ^{99m}Tc-HDP for the initial evaluation of osseous metastasis in canine osteosarcoma. *Veterinary and Comparative Oncology* 1,152-158.
- Jehn, C.T., Lewis, D.D., Farese, J.P., Ferrell, E.A., Conley, W.G., Ehrhart, N., 2007. Transverse ulnar bone transport osteogenesis: a new technique for limb salvage for the treatment of distal radial osteosarcoma in dogs. *Veterinary Surgery* 36, 324-334.
- Jeys, L.M., Grimer, R.J., Carter, S.R., Tillman, R.M., Abudu, A., 2007. Post operative infection and increased survival in osteosarcoma patients: are they associated? *Annals of Surgical Oncology* 14, 2887-2895.
- Kent, M.S., Strom, A., London, C.A., Seguin, B., 2004. Alternating carboplatin and doxorubicin as adjunctive chemotherapy to amputation or limb-sparing surgery in the treatment of appendicular osteosarcoma in dogs. *Journal of Veterinary Internal Medicine* 18, 540-544.
- Khanna, C., Wan, X., Bos, S., Cassaday, R., Olomu, O., Mendoza, A., Yeung, C., Gorlick, R., Hewitt, S.M., Helman, L.J., 2004. The membrane cytoskeleton linker ezrin is necessary for osteosarcoma metastasis. *Nature Medicine* 10,182-186.
- Kirpensteijn, J., van den Bos, R., Endenburg, N., 1999. Adaptation of dogs to the amputation of a limb and their owners' satisfaction with the procedure. *Veterinary Record* 144, 115-118.
- Kirpensteijn, J., Kik, M., Rutteman, G.R., Teske, F., 2002a. Prognostic significance of a new histologic grading system for canine osteosarcoma. *Veterinary Pathology* 39, 240-246.
- Kirpensteijn, J., Teske, E., Kik, M., Klenner, T., Rutteman, G.R., 2002b. Lobaplatin as an adjuvant chemotherapy to surgery in canine appendicular osteosarcoma: a phase II evaluation. *Anticancer Research* 22, 2765-2770.
- Kirpensteijn, J., Kik, M., Teske, E., Rutteman, G.R., 2008. TP53 gene mutations in canine osteosarcoma. *Veterinary Surgery* 37, 454-460.
- Knapp-Hoch, H.M., Fidel, J.L., Sellon, R.K., Gavin, P.R., 2009. An expedited palliative radiation protocol for lytic or proliferative lesions of appendicular bone in dogs. *Journal of the American Animal Hospital Association* 45, 24-32.
- Kraegel, S.A., Madewell, B.R., Simonson, E., Gregory, C.L., 1991. Osteogenic sarcoma and cisplatin chemotherapy in dogs: 16 cases (1986-1989). *Journal of the American Veterinary Medical Association* 199,1057-1059.
- Kuntz, C.A., Asselin, T.L., Dernell, W.S., Powers, B.E., Straw, R.C., Withrow, S.J., 1998. Limb salvage surgery for osteosarcoma of the proximal humerus: outcome in 17 dogs. *Veterinary Surgery* 27, 417-422.

- Kurzman, I.D., MacEwen, E.G., Rosenthal, R.C., Fox, L.E., Keller, E.T., Helfand, S.C., Vail, D.M., Dubielzig, R.R., Madewell, B.R., Rodriguez, C.O., Obradovich, J., Fidel, J., Rosemberg, M., 1995. Adjuvant therapy for osteosarcoma in dogs: results of randomized clinical trials using combined liposome-encapsulated muramyl tripeptide and cisplatin. *Clinical Cancer Research* 1,1595-1601.
- Kurzman, I.D., Shi, F., Vail, D.M., MacEwen, E.G., 1999. In vitro and in vivo enhancement of canine pulmonary alveolar macrophage cytotoxic activity against canine osteosarcoma cells. *Cancer Biotherapy and Radiopharmaceuticals* 14,121-128.
- Lana, S.E., Ogilvie, G.K., Hansen, R.A., Powers, B.E., Dernell, W.S., Withrow, S.J., 2000. Identification of matrix metalloproteinases in canine neoplastic tissue. *American Journal Veterinary Research* 61, 111-114.
- Langova, V., Straw, R., Mutsaers, A.J., Thamm, D., 2004. Treatment of eight dogs with nasal tumours with alternating doses of doxorubicin and carboplatin in conjunction with oral piroxicam. *Australian Veterinary Journal* 82, 676-680.
- LaRue, S.M., Withrow, S.J., Wrigley, R.H., 1986. Radiographic bone surveys in the evaluation of primary bone tumors in dogs. *Journal of the American Veterinary Medical Association* 188, 514-516.
- LaRue, S.M., Withrow, S.J., Powers, B.E., Wrigley, R.H., Gillette, E.L., Schwarz, P.D., Straw, R.C., Ritcher, S.L., 1989. Limb-sparing treatment for osteosarcoma in dogs. *Journal of the American Veterinary Medical Association* 195, 1734-1744.
- Lascelles, B.D., Dernell, W.S., Correa, M.T., Lafferty, M., Devitt, C.M., Kunz, C.A., Straw, R.C., Withrow, S.J., 2005. Improved survival associated with postoperative wound infection in dogs treated with limb-salvage surgery for osteosarcoma. *Annals of Surgical Oncology* 12,1073-1083.
- Leibman, N.F., Kunz, C.A., Steyn, P.F., Fettman, M.J., Powers, B.E., Withrow, S.J., Dernell, W.S., 2001. Accuracy of radiography, nuclear scintigraphy, and histopathology for determining the proximal extent of distal radius osteosarcoma in dogs. *Veterinary Surgery* 30, 240-245.
- Levine, R.A., Forest, T., Smith, C., 2002. Tumor suppressor PTEN is mutated in canine osteosarcoma cell lines and tumors. *Veterinary Pathology* 39, 372-378.
- Liptak, J.M., Dernell, W.S., Straw, R.C., Jameson, V.J., Lafferty, M.H., Rizzo, S.A., Withrow, S.J., 2004a. Intercalary bone grafts for joint and limb preservation in 17 dogs with high-grade malignant tumors of the diaphysis. *Veterinary Surgery* 33, 457-467.
- Liptak, J.M., Dernell, W.S., Ehrhart, N.P., Withrow, S.J., 2004b. Canine appendicular osteosarcoma: diagnosis and palliative treatment. *Compendium of Continuing Education for the Practising Veterinarian* 26,172-182.
- Liptak, J.M., Dernell, W.S., Lascelles, B.D., LaRue, S.M., Jameson, V.J., Powers, B.E., Huber, D.J., Withrow, S.J., 2004c. Intraoperative extracorporeal irradiation for limb sparing in 13 dogs. *Veterinary Surgery* 33, 446-456.
- Liptak, J.M., Pluhar, G.E., Dernell, W.S., Withrow, S.J., 2005. Limb-sparing surgery in a dog with osteosarcoma of the proximal femur. *Veterinary Surgery* 34, 71-77.
- Liptak, J.M., Dernell, W.S., Ehrhart, N., Lafferty, M.H., Monteith, G.J., Withrow, S.J., 2006. Cortical allograft and endoprosthesis for limb-sparing surgery in dogs with distal radial osteosarcoma: a prospective clinical comparison of two different limb-sparing techniques. *Veterinary Surgery* 35, 518-533.
- Lloyd, R.D., Taylor, G.N., Angus, W., Bruenger, F.W., Miller, S.C., 1993. Bone cancer occurrence among beagles given ²³⁹Pu as young adults. *Health Physics* 64, 45- 51.
- Lloyd, R.D., Taylor, G.N., Angus, W., Miller, S.C., Boecker, B.B., 1994. Skeletal malignancies among beagles injected with ²⁴¹Am. *Health Physics* 66,172-177.
- Loukopoulos, P., Robinson, W.F., 2007. Clinicopathological relevance of tumour grading in canine osteosarcoma. *Journal of Comparative Pathology* 136, 65-73.
- Loukopoulos, P., Thornton, J.R., Robinson, W.F., 2003. Clinical and pathologic relevance of p53 index in canine osseous tumors. *Veterinary Pathology* 40, 237-248.
- Loukopoulos, P., O'Brien, T., Ghoddsu, M., Mungall, B.A., Robinson, W.F., 2004. Characterization of three novel canine osteosarcoma cell lines producing high level of matrix metalloproteinases. *Research in Veterinary Science* 77, 131-141.

- Loukopoulos, P., Rozmanec, M., Sutton, R.H., 2005. Cytological versus histopathological diagnosis in canine osteosarcoma. *Veterinary Record* 157, 784.
- MacEwen, E.G., Kurzman, I.D., Helfand, S., Vail, D., London, C., Kisseberth, W., Rosenthal, R.C., Fox, L.E., Keller, E.T., Obradovich, J., Madewell, Rodriguez, C., Kitchell, B., Fidel, J., Susaneck, S., Rosenberg, M., 1994. Current studies of liposome muramyl tripeptide (CGP 19835A lipid) therapy for metastasis in spontaneous tumors: a progress review. *Journal of Drug Targeting* 2, 391-396.
- MacEwen, E.G., Pastor, J., Kutzeke, J., Tsan, R., Kurzman, I.D., Thamm, D.H., Wilson, M., Radinsky, R., 2004. IGF-1 receptor contributes to the malignant phenotype in human and canine osteosarcoma. *Journal of Cellular Biochemistry* 92, 77-91.
- Malawer, M.M., Helman, L.J., O'Sullivan, B., 2008. Sarcomas of bone. In: DeVita, V.T., Lawrence, T.S., Rosenberg, S.A. (Eds.), *DeVita, Hellman and Rosenberg's Cancer Principles and Practice of Oncology*. Lippincott Williams and Wilkins, Philadelphia, PA, USA, pp. 1794-1833.
- Marcellin-Little, D.J., DeYoung, D.J., Thrall, D.E., Merrill, C.L., 1999. Osteosarcoma at the site of bone infarction associated with total hip arthroplasty in a dog. *Veterinary Surgery* 28, 54-60.
- Massin, P., Bocquet, L., Hutten, D., Badelon, O., Duparc, J., 1995. Radiographic and histologic observations of autoclaved and non autoclaved allografts in the distal femoral metaphysis in dogs. *Revue de chirurgie orthopedique et reparatrice del l'appareil moteur* 81,189-197.
- Mauldin, G.N., Matus, R.E., Withrow, S.J., Patnaik, A.K., 1988. Canine osteosarcoma treatment by amputation versus amputation and adjuvant chemotherapy using doxorubicin and cisplatin. *Journal of Veterinary Internal Medicine* 2,177-180.
- Mehl, M.L., Seguin, B., Dernell, W.S., Lafferty, M., Kass, P.H., Withrow, S.J., 2005. Survival analysis of one versus two treatments of local delivery cisplatin in a biodegradable polymer for canine osteosarcoma. *Veterinary and Comparative Oncology* 3, 81-86.
- Mendoza, S., Konishi, T., Dernell, W.S., Withrow, S.J., Miller, C.W., 1998. Status of the p53, Rb and MDM2 genes in canine osteosarcoma. *Anticancer Research* 18, 4449-4453.
- Messerschmitt, P.J., Garcia, R.M., Abul-Karim, F.W., Greenfield, E.M., Getty, P.J., 2009. Osteosarcoma. *Journal of the American Academy of Orthopaedic surgeons* 17, 515-527.
- Misdorp, W., 1980. Skeletal osteosarcoma. Animal model: Canine osteosarcoma. *American Journal of Pathology* 98, 285-288.
- Misdorp, W., Hart, A.A., 1979. Some prognostic and epidemiologic factors in canine osteosarcoma. *Journal of the National Cancer Institute* 62, 537-545.
- Moore, A.S., Dernell, W.S., Ogilvie, G.K., Kristal, O., Elmslie, R., Kitchell, B., Susaneck, S., Rosenthal, R., Klein, M.K., Obradovich, J., Legendre, A., Haddad, T., Hahn, K., Powers, B.E., Warren, D., 2007. Doxorubicin and BAY 12-9566 for the treatment of osteosarcoma in dogs: a randomized, double-blind, placebo-controlled study. *Journal of Veterinary Internal Medicine* 21, 783-790.
- Morello, E., Buracco, P., Martano, M., Peirone, B., Capurro, C., Valazza, A., Cotto, D., Ferracini, R., Sora, M., 2001. Bone allografts and adjuvant cisplatin as treatment of canine appendicular osteosarcoma: 18 dogs (1991-1996). *Journal of Small Animal Practice* 42, 61-66.
- Morello, E., Vasconi, E., Martano, M., Peirone, B., Buracco, P., 2003. Pasteurized tumoral autograft and adjuvant chemotherapy for the treatment of canine distal radial osteosarcoma: 13 cases. *Veterinary Surgery* 32, 539-544.
- Mueller, F., Poirier, V., Melzer, K., Nitzl, D., Roos, M., Kaser-Hotz, B., 2005. Palliative radiotherapy with electrons of appendicular osteosarcoma in 54 dogs. *In Vivo* 19, 713-716.
- Mueller, F., Fuchs, B., Kaser-Hotz, B., 2007. Comparative biology of human and canine osteosarcoma. *Anticancer Research* 27,155-164.
- Muggenburg, B.A., Guilmette, R.A., Mewhinney, J.A., Gillett, N.A., Mauderly, J.L., Griffith, W.C., Diel, J.H., Scott, B.R., Hahn, F.F., Boecker, B.B., 1996. Toxicity of inhaled plutonium dioxide in beagle dogs. *Radiation Research* 145, 361-381.
- Murphy, S.T., Parker, R.B., Woodard, J.C., 1997. Osteosarcoma following total hip arthroplasty in a dog. *Journal of Small Animal Practice* 38, 263-267.

- Nemanic, S., London, C.A., Wisner, E.R., 2006. Comparison of thoracic radiographs and single breath-hold helical CT for detection of pulmonary nodules in dogs with metastatic neoplasia. *Journal Veterinary Internal Medicine* 20, 508-515.
- O'Brien, M.G., Straw, R.C., Withrow, S.J., Powers, B.E., Jameson, V.J., Lafferty, M., Ogilvie, G.K., LaRue, S.M., 1993. Resection of pulmonary metastases in canine osteosarcoma: 36 cases (1983-1992). *Veterinary Surgery* 22, 105-109.
- O'Day, K., Gorlick, R., 2009. Novel therapeutic agents for osteosarcoma. *Expert Reviews in Anticancer Therapy* 9, 511-523.
- Ogilvie, G.K., Straw, R.C., Jameson, V.J., Walters, L.M., Lafferty, M., Powers, B.E., Withrow, S.J., 1993. Evaluation of single agent chemotherapy for treatment of clinically evident osteosarcoma metastases in dogs: 45 cases (1987-1991). *Journal of the American Veterinary Medical Association* 202, 304-306.
- Phillips, J.C., Stephenson, B., Hauck, M., Dillberger, J., 2007. Heritability and segregation analysis of osteosarcoma in the Scottish deerhound. *Genomics* 90, 354-363.
- Phillips, B., Powers, B.E., Dernel, W.S., Straw, R.C., Khanna, C., Hogge, G.S., Vail, D.M., 2009. Use of single agent carboplatin as adjuvant or neoadjuvant therapy in conjunction with amputation for appendicular osteosarcoma in dogs. *Journal of the American Animal Hospital Association* 45, 33-38.
- Pooya, H.A., Séguin, B., Mason, D.R., Walsh, P.J., Taylor, K.T., Kass, P.H., Stover, S.M., 2004. Biomechanical comparison of cortical radial graft versus ulnar transposition graft limb-sparing techniques for the distal radial site in dogs. *Veterinary Surgery* 33, 301-308.
- Powers, B.E., LaRue, S.M., Withrow, S.J., Straw, R.C., Richter, S.L., 1988. Jamshidi needle biopsy for diagnosis of bone lesions in small animals. *Journal of the American Veterinary Medical Association* 193, 205-210.
- Powers, B.E., Gillette, E.L., McChesney, S.L., LeCouteur, R.A., Withrow, S.J., 1989. Bone necrosis and tumor induction following experimental intraoperative irradiation. *International Journal Radiation Oncology, Biology and Physics* 17, 559-567.
- Powers, B.E., Withrow, S.J., Thrall, D.E., 1991. Percent tumor necrosis as a predictor of treatment response in canine osteosarcoma. *Cancer* 67, 126-134.
- Ramirez III, O., Dodge, R.K., Page, R.L., Price, G.S., Hauck, M.L., LaDue, T.A., Nutter, F., Thrall, D.E., 1999. Palliative radiotherapy of appendicular osteosarcoma in 95 dogs. *Veterinary Radiology and Ultrasound* 40, 517-522.
- Reinhardt, S., Stockhaus, C., Teske, E., Rudolph, R., Brunnberg, L., 2005. Assessment of cytological criteria for diagnosing osteosarcoma in dogs. *Journal of Small Animal Practice* 46, 65-70.
- Riser, W.H., Brodey, R.S., Biery, D.N., 1972. Bone infarctions associated with malignant bone tumors in dogs. *Journal of the American Veterinary Medical Association* 160, 414-421.
- Rodriguez, C.O., Crabbs, T.A., Wilson, D.W., Cannan, V.A., Skorupski, K.A., Gordon, N., Koshkina, N., Kleinerman, E., Anderson, P.M., 2010. Aerosol gemcitabine: preclinical safety and in vivo antitumor activity in osteosarcoma bearing dogs. *Journal of Aerosol Medicine and Pulmonary Drug Delivery* 23, 197-206.
- Rosenberger, J.A., Pablo, N.V., Crawford, P.C., 2007. Prevalence of and intrinsic risk factors for appendicular osteosarcoma in dogs: 179 cases (1996-2005). *Journal of the American Veterinary Medical Association* 23, 1076-1080.
- Rovesti, G.L., Bascucci, M., Schmidt, K., Marcellin-Little, D.J., 2002. Limb sparing using a double bone-transport technique for treatment of a distal tibial osteosarcoma in a dog. *Veterinary Surgery* 31, 70-77.
- Ru, G., Terracini, B., Glickman, L.T., 1998. Host related risk factors for canine osteosarcoma. *The Veterinary Journal* 156, 31-39.
- Sagartz, J.E., Bodley, W.L., Gamblin, R.M., Couto, C.G., Tierney, L.A., Capen, C.C., 1996. P53 tumor suppressor protein overexpression in osteogenic tumors of dogs. *Veterinary Pathology* 33, 213-221.
- Seguin, B., Walsh, P.J., Mason, D.R., Wisner, E.R., Parmenter, J.L., Dernel, W.S., 2003. Use of an ipsilateral vascularized ulnar transposition autograft for limb-sparing surgery of the distal radius in dogs: an anatomic and clinical study. *Veterinary Surgery* 32, 69-79.
- Shapiro, W., Fossum, T.W., Kitchell, B.E., Couto, C.G., Theilen, G.H., 1988. Use of cisplatin for treatment of appendicular osteosarcoma in dogs. *Journal of the American Veterinary Medical Association* 192, 507-511.

- Shi, F., MacEwen, E.G., Kurzman, I.D., 1993. In vitro and in vivo effect of doxorubicin combined with liposome-encapsulated muramyl tripeptide on canine monocyte activation. *Cancer Research* 53, 3986-3991.
- Sinibaldi, K.R., Rosen, H., Liu, S.K., DeAngelis, M., 1976. Tumors associated with metallic implants in animals. *Clinical Orthopaedics and Related Research* 118, 257-266.
- Sinibaldi, K.R., Pugh, J., Rosen, H., Liu, S.K., 1982. Osteomyelitis and neoplasia associated with use of the Jonas intramedullary splint in small animals. *Journal of American Veterinary Medical Association* 181, 885-890.
- Spodnick, G.J., Berg, J., Rand, W.M., Schelling, S.H., Couto, C.G., Harvey, H.J., Henderson, R.A., MacEwen, G., Mauldin, N., MacCaw, D.L., Moore, A.S., Morrison, W., Norris, A.M., O'Bradovich, J., O'Keefe, D.A., Page, R., Ruslander, D., Klausner, J., Straw, R.C., Thompson, J.P., 1992. Prognosis for dogs with appendicular osteosarcoma treated by amputation alone: 162 cases (1978-1988). *Journal of the American Veterinary Medical Association* 200, 995-999.
- Spugnini, E.P., Vincenzi, B., Caruso, G., Baldi, A., Citro, G., Santini, D., Tonini, G., 2009. Zoledronic acid for the treatment of appendicular osteosarcoma in a dog. *Journal of Small Animal Practice* 50, 44-46.
- Stevenson, S., 1991. Fracture-associated sarcomas. *Veterinary Clinics of North America Small Animal Practice* 21, 859-872.
- Straw, R.C., Withrow, S.J., 1996. Limb-sparing surgery versus amputation for dogs with bone tumors. *Veterinary Clinics of North America Small Animal Practice* 26, 135-143.
- Straw, R.C., Withrow, S.J., Powers, B.E., 1990. Management of canine appendicular osteosarcoma. *Veterinary Clinics of North America Small Animal Practice* 20, 1141-1161.
- Straw, R.C., Withrow, S.J., Richter, S.L., Powers, B.E., Klein, M.K., Postorino, N.C., LaRue, S.M., Ogilvie, G.K., Vail, D.M., Morrison, W.B., McGee, M., Dickinson, K., 1991. Amputation and cisplatin for treatment of canine osteosarcoma. *Journal of Veterinary Internal Medicine* 5, 205-210.
- Straw, R.C., Withrow, S.J., Doulple, E.B., Brekke, J.H., Cooper, M.F., Schwarz, P.D., Greco, D.S., Powers, B.E., 1994. The effect of cis-diamminedichloroplatinum II released from D,L,-polylactic acid implanted adjacent to cortical allografts in dogs. *Journal of Orthopaedic Research* 12, 871-877.
- Ta, H.T., Dass, C.R., Choong, P.F.M., Dunstan, D.E., 2009. Osteosarcoma treatment: state of the art. *Cancer Metastasis Reviews* 28, 247-263.
- Thompson, J.P., Fugent, M.J., 1991. Evaluation of survival times after limb amputation, with and without subsequent administration of cisplatin, for treatment of appendicular osteosarcoma in dogs: 30 cases (1979-1990). *Journal of the American Veterinary Medical Association* 200, 531-533.
- Thrall, D.E., 1984. Orthovoltage radiotherapy of acanthomatous epulides in 39 dogs. *Journal of the American Veterinary Medical Association* 184, 826-829.
- Tomlin, J.L., Sturgeon, C., Pead, M.J., Muir, P., 2000. Use of the bisphosphonate drug alendronate for palliative management of osteosarcoma in two dogs. *Veterinary Record* 29, 129-132.
- Tommasini-Degna, M., Ehrhart, N., Ferretti, A., Buracco, P., 2000. Bone transport osteogenesis for limb salvage following resection of primary bone tumors: experience with six cases (1991-1996). *Veterinary Comparative Orthopaedic and Traumatology* 13, 18-22.
- van Leeuwen, I.S., Cornelisse, C.J., Misdorp, W., Goedegebuure, S.A., Kirpensteijn, J., Rutteman, G.R., 1997. P53 gene mutations in osteosarcomas in the dog. *Cancer Letters* 111, 173-178.
- Vignoli, M., Ohlerth, S., Rossi, F., Pozzi, L., Terragni, R., Corlazzoli, D., Kaser-Hotz, B., 2004. Computed tomography-guided fine-needle aspiration and tissue-core biopsy of bone lesions in small animals. *Veterinary Radiology and Ultrasound* 45, 125-130.
- Yamamoto, T., Hitora, T., Marui, T., Akisue, T., Nagira, K., Kawamoto, T., Yoshiya, S., Kurosaka, M., 2002. Reimplantation of autoclaved or irradiated cortical bones invaded by soft tissue sarcomas. *Anticancer Research* 22, 3685-3690.
- Wallach, S.T., Wisner, E.R., Werner, J.A., Walsh, P.J., Kent, M.S., Fairley, R.A., Hornof, W.J., 2002. Accuracy of magnetic resonance imaging for estimating intramedullary osteosarcoma extent in pre-operative planning of canine limb-salvage procedures. *Veterinary Radiology and Ultrasound* 43, 432-441.

Walter, C.U., Dernell, W.S., Larue, S.M., Lana, S.E., Lafferty, M.H., Ladue, T.A., Withrow, S.J., 2005. Curative-intent radiation therapy as a treatment modality for appendicular and axial osteosarcoma: a preliminary retrospective evaluation of 14 dogs with the disease. *Veterinary and Comparative Oncology* 3, 1-7.

White, R.A., Jefferies, A.R., Gorman, N.T., 1986. Sarcoma development following irradiation of acanthomatous epulis in two dogs. *Veterinary Record* 118, 668.

Withrow, S.J., Liptak, J.M., Straw, R.C., Dernell, W.S., Jameson, V.J., Powers, B.E., Johnson, J.L., Brekke, J.H., Duple, E.B., 2004. Biodegradable cisplatin polymer in limb-sparing surgery for canine osteosarcoma. *Annals of Surgical Oncology* 11, 705-713.