

AperTO - Archivio Istituzionale Open Access dell'Università di Torino

Mycophenolate mofetil as steroid-sparing treatment for elderly patients with giant cell arteritis: report of three cases.

This is the author's manuscript

Original Citation:

Availability:

This version is available <http://hdl.handle.net/2318/128513> since

Published version:

DOI:10.1007/BF03325257

Terms of use:

Open Access

Anyone can freely access the full text of works made available as "Open Access". Works made available under a Creative Commons license can be used according to the terms and conditions of said license. Use of all other works requires consent of the right holder (author or publisher) if not exempted from copyright protection by the applicable law.

(Article begins on next page)



UNIVERSITÀ DEGLI STUDI DI TORINO

The final publication is available at Springer via
<http://link.springer.com/article/10.1007/BF03325257>

Title Page

Mycophenolate mofetil as steroid sparing treatment for elderly patients with giant cell arteritis: report of three cases

Savino Sciascia¹ MD, Doloretta Piras² MD, Simone Baldovino¹ MD, Alessandra Russo¹ MD, Carla Naretto¹ MD, Daniela Rossi¹ MD, Mirella Alpa¹ MD, Dario Roccatello¹ MD.

¹ Dipartimento di Malattie Rare, Immunologiche, Ematologiche ed Immunopatologiche, Centro di Ricerche di Immunopatologia e Documentazione su Malattie Rare (CMID), Struttura Complessa a Direzione Universitaria di Immunologia Clinica Ospedale Torino Nord Emergenza San G. Bosco ed Università di Torino, Italy.

²Dipartimento di Nefrologia, Dialisi e Trapianto, Azienda Ospedaliera G. Brotzu, Cagliari, Italy

Key words:

Giant cell arteritis, mycophenolate mofetil, steroid sparing agent

Address for correspondence:

Dario Roccatello, Centro di Ricerche di Immunopatologia e Documentazione su Malattie Rare (CMID), Struttura Complessa a Direzione Universitaria di Immunologia Clinica, Ospedale Torino Nord Emergenza San G. Bosco ed Università di Torino,

Piazza del Donatore di Sangue 3, 10154, Torino, Italy

Email: dario.roccatello@unito.it

Phone 00390112402053 Fax 00390112402052

ABSTRACT

BACKGROUND:

Glucocorticoids have never been studied in a placebo-controlled manner in giant cell arteritis (GCA) but their effectiveness is well established. However evidence for efficacy for the use of immunosuppressant drug as steroid-sparing in this disease is highly desirable, especially in elderly patients.

OBJECTIVES:

We report the use of mycophenolate mofetil (MMF) as steroid sparing agent in three patients (mean age 78 years) with GCA at high risk for long-term high dose glucocorticoids because of type II mellitus diabetes, obesity, hypertension and osteoporosis.

DESIGN and SETTINGS:

Clinical monitoring and assessment of laboratory parameters were done weekly (first month) and then patients were seen in the clinic every 2 weeks. Vascular lesions also were monitored at the onset and during the follow-up by using Doppler ultrasonography (every 3 months).

RESULTS:

All the three patients showed clinical benefit, and they were also able to taper steroid use in a more rapid regimen compared to the recently suggested steroid reduction approach. MMF was well tolerated, and no signs of toxicity were observed in a mean 21.6 months (12-29) of follow-up.

CONCLUSION:

Mycophenolate mofetil may be considered a steroids-sparing agent in elderly patients with GCA but before results of controlled trials become available, it may be considered only for patients who do not improve or stabilize with

conventional therapy or in subjects in whom a reduction of steroid dose is largely auspicious.

INTRODUCTION

Giant cell arteritis (GCA), also known as temporal arteritis, is a vasculitis of medium and large vessels (1). Many of the most concerning features of the disease result from vascular inflammation involving cranial branches of the arteries that originate from the aortic arch (2,3). Glucocorticoids have never been studied in a placebo-controlled manner in GCA but their effectiveness is well established. Glucocorticoids may predispose to, or worsen preexisting conditions, as osteoporosis or mellitus diabetes Type II (DM). This is a particular concern because the disease affects postmenopausal women and aged men. However evidence for efficacy for the use of immunosuppressant drugs as steroid-sparing in this disease is lacking. The results of RCTs of Methotrexate (MTX) in GCA have led to somewhat divergent conclusions (4,5,6). Thus, additional work toward the identification of effective prednisone-sparing agents is highly desirable.

We report our experience in the treatment with MMF as a steroid-sparing agent of three elderly subjects with new-onset GCA at high-risk for the use of long-term high dose glucocorticoids because of DM, obesity, hypertension and osteoporosis.

MMF was reported as a safe and tolerated treatment in other autoimmune disorders affecting older population. (7)

The diagnosis of new-onset GCA was made according to American College of Rheumatology criteria (8) and all the patients underwent to a biopsy of the temporal artery. (Fig.1). All the patients gave written informed consent.

Oral MMF (2 g/d) was given to three patients in two divided doses.

Patients were evaluated at baseline and after treatment according to the following criteria: 1) presence of headache, abrupt onset of visual disturbances or Jaw claudication ; 2) systemic symptoms including fever not attributable to infection, polyarthralgias, and polymyalgias; and 3) elevated Erythrocyte Sedimentation Rate (ESR), C-Reactive Protein (CRP).

Clinical evaluation and assessment of laboratory parameters were done weekly during the first month of treatment. Thereafter, patients were seen in the clinic every 2 weeks.

Vascular lesions were also qualitatively assessed by using Doppler UltraSonography (DUS) of the temporal artery every 3 months during the follow-up (12-29 months).

Clinical Characteristics at Baseline

Baseline clinical characteristics are shown in Tab.1. All the patients had a clinical history of DM in oral therapy (metformin) and hypertension needing at least three anti-hypertensive drugs (ramipril, amlodipine, and hydrochlorothiazide); two patients were obese (patient 2 and 3, Body Mass Index 32 and 41 respectively); one of them suffered from osteoporosis (T score -2.9 at Dual energy X-ray Absorptiometry) and she was given alendronate sodium (70mg/weekly).

Clinical Outcome

Patient responses to MMF therapy are summarized in Tab.1.

No signs of clinical relapse was detected over a mean of 21.6 months (12-29) of follow-up.

Patient 1

The patient's systemic symptoms resolved 2 weeks after initiation of therapy, and his ESR rapidly decreased (Fig.1). Starting prednisone therapy was 50 mg/day associated to MMF, both administered immediately after the histological confirmation of the diagnosis. After 1 month of MMF therapy, the prednisone dose could be tapered to the dose of 15 mg/day. Prednisone could be tapered to 7.5 mg/d after three months. After 12 months of follow-up, the patient remains in stable clinical condition with no instrumental evidence of disease progression. Headache or jaw claudication attacks never recurred. DUS performed after 9 months from the CGA diagnosis, showed the resolution of the previously described vascular lesions. DM and hypertension were under control and no therapy adjustment was needed. At the last observation (10 months after diagnosis) the patient was given 5 mg/d prednisone and 2 g/day MMF.

Patient 2

2 weeks after initiation of therapy (starting dose 50 mg/day of prednisone associated to MMF), systemic symptoms and headaches resolved. Laboratory markers of inflammation were shown in Fig.1 . The steroid dose was halved from the initial dose after 3 weeks of therapy with MMF. An ultrasonogram obtained by DUS showed no deterioration of the previously described vascular lesions during the 24 months of follow-up. The prednisone was tapered to a daily dose of 10 mg within 4 months. The patient felt so well and no change in diabetic or anti-hypertensive therapy was needed. At the last observation (24 months after diagnosis) the patient was given 7.5 mg/d prednisone and 2 g/d MMF.

Patient 3

Systemic symptoms resolved 3 weeks after initiation of therapy (starting dose 25 mg/day of prednisone associated to MMF). Laboratory markers of inflammation were shown in Fig.1 Fever disappeared and never relapsed during the follow-up. After 1 month of MMF therapy given after the histological confirmation of the diagnosis, the prednisone dose could be tapered at the dose of 12.5 mg in 1 month, and after a 29 months of follow-up a dose of prednisone of 5 mg was reached. Headache never recurred. DUS performed after 9 months from the diagnosis, showed the resolution of the previously described vascular lesions. DM and hypertension were under control and no therapy adjustment was needed. At the last observation (27 months after diagnosis) the patient was given 5 mg/d prednisone and 2 g/d MMF.

Side Effects

All patients tolerated MMF without any major toxicity.

DISCUSSION

Therapeutic decisions in GCA are often guided by individual patient variables including location and severity of arterial lesions, availability of collateral circulation, nature and intensity of symptoms, and the risks of drug toxicity.

The present report showed that MMF therapy was well tolerated, could control GCA activity disease, and also allow to taper prednisone dose in a more rapid regimen compared to the recently suggested steroid reduction approach (Fig.1) (9).

After 1 month of MMF, the prednisone dose could be tapered at the mean dose of 17.5 mg (12.5-25 mg), with a first month-mean reduction of more than

a half of initial dose. Instead, referring to the recent guidelines (9), no steroid reduction is suggested in the 3-4 weeks of glucocorticoids treatment; moreover a comparable reduction of more than a half of the initial dose was reached only after at least 7 weeks from the starting of the therapy (Fig.1).

MMF allowed a significant decrease in the level of ESR and CRP values.

Glucocorticoids constitute the first-line treatment for active arterial inflammation and an initial daily dose of 40-60 mg of prednisone or its equivalent in single or divided doses is adequate in almost all cases of GCA (10). Some patients respond to doses as low as 20 mg/day, but this dose is seldom used, primarily because of concern for the potential consequences of undertreatment (11). Although remission is achieved in nearly all cases, (12,13), relapses during glucocorticoids tapering may occur. Moreover, the use of glucocorticoids may also predispose to, or worsen preexisting conditions, as osteoporosis, DM, hypertension and obesity such in cases we proposed. This is a particular concern because these diseases mainly affect postmenopausal women and older men. Therefore, other immunosuppressive drugs may be potentially added to glucocorticoids with the aim of curbing disease progression and reducing disease and glucocorticoids-related morbidity.

MTX is an immunosuppressant proposed for GCA treatment. The results of RCTs of MTX in GCA have led to somewhat divergent conclusions (4-6) and taken together, the results of these trials are difficult to reconcile entirely and they have recently been the subject of a formal meta-analysis (14). According to this analysis, adjunctive methotrexate treatment for GCA reduced the risk of both a first and a second relapse (hazard ratios 0.65 and 0.49,

respectively). By contrast, MTX would not appear to act quickly, and cannot thus be recommended as a replacement for glucocorticoids at disease onset. In such a context, additional work toward the identification of effective prednisone-sparing agents is largely desirable. (15)

MMF has been used most often in transplant recipients and the rationale for using MMF in patients with GCA is supported by the drug's immunosuppressive properties and its unique action in preventing lymphocyte-mediated vascular damage; moreover, several evidences about the use of MMF in large vessel vasculitis (e.g. Takayasu arteritis) are reported in literature (16). Its good safety profile may also prove valuable for steroid-sparing potential effect.

We based our definition of disease activity on clinical and serologic parameters. Ultrasonographic evaluation was also performed. However, the evaluation of the clinical response in GCA is difficult to assess because no accurate definition of disease activity and remission is available; although subjective symptoms, laboratory data, and angiographic changes have been proposed to evaluate disease status, none of them are specific.

Therefore, this is a preliminary report of three patients in whom we believed the use of GC at the conventional dose was not recommended for the high metabolic risk due to co-existent DM, hypertension, osteoporosis and obesity. Moreover, although the clinical setting recommended a rapid therapeutic decision, in our opinion the absence of catastrophic events (such as visual disturbances/visual loss) permitted us to avoid the use of high dose of glucocorticoids, potentially linked with complications in such patients; the use of a steroid-sparing agent was so widely recommended.

All three patients reported a subjective benefit. During the observation period, none experienced new-onset of headache or jaw claudication; clinical examination showed no evidence of tenderness of temporal arteritis. None of them had fever, and all systemic symptoms resolved. In all patients, tapering of steroid therapy was achieved. Three patients completely resumed lifestyles they had long abandoned because of their illness. Diabetes and hypertension was under control during the follow-up. Anyway, GCA is a remitting and relapsing disease; therefore, we cannot exclude the possibility that our patients' positive response may be due to spontaneous remission rather than the effect of the drug. However, the concomitant subjective benefit and normalization of laboratory data should be consistent with the hypothesis that the clinical improvement was due to therapy with MMF associated to glucocorticoids. A longer follow-up period is needed to assess duration of remission.

In our experience, MMF proved to be safe and well tolerated. None of the patients had leucopenia, thrombocytopenia, elevated liver enzyme levels, or gastrointestinal discomfort; therefore, the dosage of 2 g/d could be maintained.

However, the follow-up may have been too short for more serious adverse effects to have developed.

CONCLUSION

MMF may be considered a steroids-sparing agent in patients with GCA. Before results of controlled trials become available, MMF should be considered only for patients who do not improve or stabilize with conventional therapy or in subjects in whom a reduction of steroid dose is largely

auspicious for co-existing conditions such as DM, osteoporosis, hypertension and obesity.

ACKNOWLEDGMENT

All the Authors declare not to have any financial or other relationships that might lead to a conflict of interest. This manuscript has been read and approved by all Authors. The manuscript has not been published or submitted elsewhere.

No sponsors had a role in the design, methods, subject recruitment, data collections, analysis or preparation of this paper.

References

1. Hunder, GG: Textbook of Rheumatology: Giant cell arteritis and polymyalgia rheumatic. 5th ed., Philadelphia, WB Saunders, 1996:898.
2. Evans JM, Bowles CA, Bjornsson J, Mullany CJ, Hunder GG. Thoracic aortic aneurysm and rupture in giant cell arteritis. A descriptive study of 41 cases. *Arthritis Rheum* 1994; 37:1539-47.
3. Klein RG, Hunder GG, Stanson AW, Sheps SG. Large artery involvement in giant cell (temporal) arteritis. *Ann Intern Med* 1975; 83: 806-12.
4. Jover JA, Hernandez-Garcia C, Morado IC, Vargas E, Banares A, Fernandez-Guitierrez B. Combined treatment of giant-cell arteritis with methotrexate and prednisone: a randomized, double blind, placebo-controlled trial. *Ann Intern Med* 2001;134:106–1
5. Hoffman GS, Cid MC, Hellmann DB, Guillevin L, Stone JH, Schousboe J, et al. A multicenter, randomized, double-blind, placebo-controlled trial of adjuvant methotrexate treatment for giant cell arteritis. *Arthritis Rheum* 2002;46:1309-18.
6. Spiera RF, Mitnick HJ, Kupersmith M, Richmond M, Spiera H, Peterson MG, et al. A prospective, double-blind, randomized, placebo controlled trial of methotrexate in the treatment of giant cell arteritis (GCA). *Clin Exp Rheumatol* 2001;19:495–501
7. Bédane C, Doffoel Hantz V. Mucous membrane pemphigoid: A review. *Ann Dermatol Venereol.* 2011; 138:201-208.

8. Hunder GG, Bloch DA, Michel BA, Stevens MB, Arend WP, Calabrese LH, et al. The American College of Rheumatology 1990 criteria for the classification of giant cell arteritis. *Arthritis Rheum* 1990;33:1122-8.
9. Dasgupta B, Borg FA, Hassan N, Alexander L, Barraclough K, Bourke B, et al. BSR and BHPR Standards, Guidelines and Audit Working Group. BSR and BHPR guidelines for the management of giant cell arteritis. *Rheumatology (Oxford)* 2010;49: 1594-7.
10. Hunder GG, Sheps SG, Allen GL, Joyce JW. Daily and alternate-day corticosteroid regimens in treatment of giant cell arteritis: comparison in a prospective study. *Ann Intern Med* 1975; 82:613-8.
11. Myles AB, Perera T, Ridley MG. Prevention of blindness in giant cell arteritis by corticosteroid treatment. *Br J Rheumatol* 1992;31:103-5.
12. Salvarani C, Macchioni PL, Tartoni PL, Rossi F, Baricchi R, Castri C, et al. Polymyalgia rheumatica and giant cell arteritis: a 5-year epidemiologic and clinical study in Reggio Emilia, Italy. *Clin Exp Rheumatol* 1987,5:205-15.
13. Lundberg I, Hedfors E. Restricted dose and duration of corticosteroid treatment in patients with polymyalgia rheumatica and temporal arteritis. *J Rheumatol* 1990;17:1340-5.
14. Mahr AD, Jover JA, Spiera RF, Hernández-García C, Fernández-Gutiérrez B, Lavalley MP, et al. Adjunctive methotrexate to treat giant cell arteritis: an individual patient data meta-analysis. *Arthritis Rheum.* 2006;56:2789–2797.
15. Pipitone N, Salvarani C. Improving therapeutic options for patients with giant cell arteritis. *Current Opinion in Rheumatology* 2008;20:17–22

16. Daina E, Schieppati A, Remuzzi G. Mycophenolate mofetil for the treatment of Takayasu arteritis: report of three cases. *Ann Intern Med* 1999;130:422-6.

Figures

Figure 1 - Serologic and histopathology assessment, and therapy regimen of the patients.

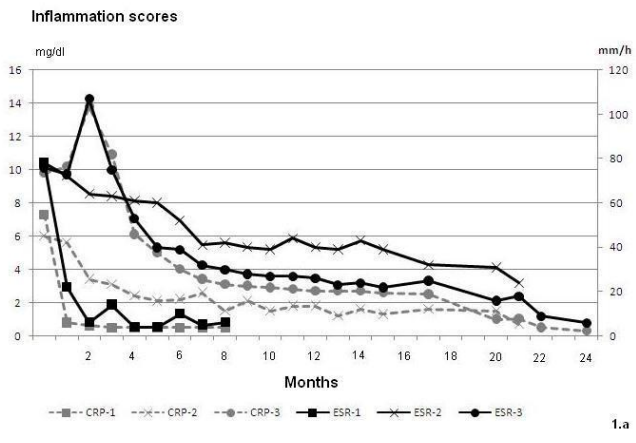
1.a Inflammation scores, Erythrocyte Sedimentation Rate (ESR) and C-Reactive Protein (CRP), of the three patients during the follow up.

1.b. Steroid tapering regimen: the chart shows mean prednisone dose in our experience in comparison to the dosage recently suggested. MMF allowed a more rapid prednisone tapering ($p < 0.001$, with paired two-sample t-tests) compared to conventional steroid dosage suggested by Dasgupta et co-workers. (Dasgupta B, Borg FA, Hassan N, Alexander L, Barraclough K, Bourke B, et al. BSR and BHRP Standards, Guidelines and Audit Working Group. BSR and BHRP guidelines for the management of giant cell arteritis. *Rheumatology (Oxford)* 2010;49: 1594-7.)

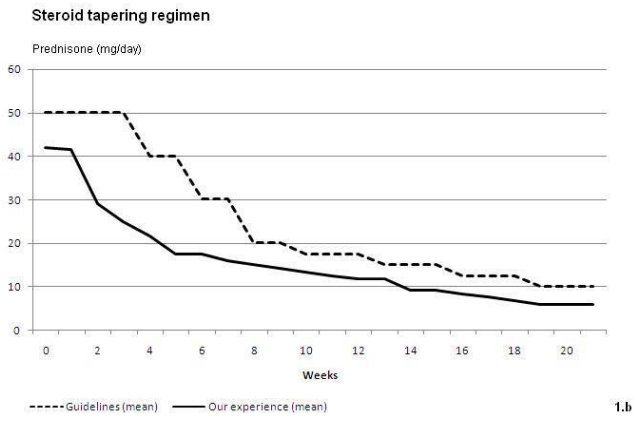
1.c. Histopathology findings in temporal artery: chronic inflammatory infiltrates consisting of monocytes, lymphocytes were present associated with sporadic giant cells (arrow) and fragmentation of internal elastic lamina.

Tables

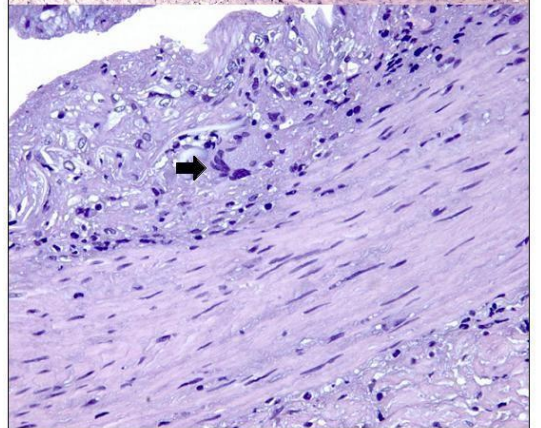
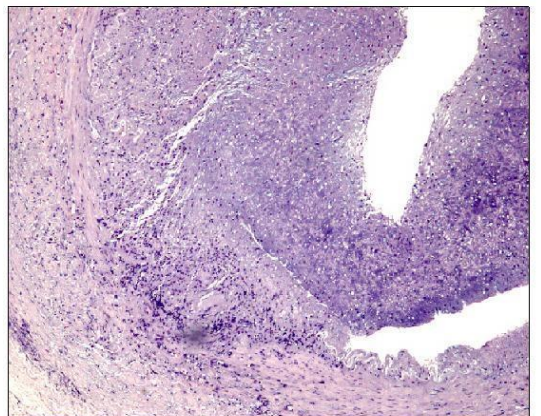
Table 1 - Characteristics of 3 Patients with GCA at onset of disease and while treatment with MMF at the end of follow-up.



1.a



1.b



1.c

Figure 1.

Tab.1. Characteristics of 3 Patients with GCA at onset of disease and while treatment with MMF at the end of follow-up.

Onset										
Patient	Age (years)	Sex	Onset of Disease (biopsy)	Disease Characteristic			Inflammation score at onset		Doppler ultrasonography	Risk factor for long term high dose use of steroids
				Headache	Jaw claudication	Systemic symptoms	ESR, mm/h	CRP (mg/dl) (normal value <0.5 mg/dl)		
1	75	M	14/12/09	Yes	Yes	Yes (fever not attributable to infection; polyarthralgias)	78	7.3	hypoechoogenic halo sign	DM, hypertension
2	69	F	15/11/08	Yes	Yes	Yes (fever not attributable to infection, polyarthralgias polymyalgias)	60	2.7	features as stenosis or occlusion	DM, obesity, hypertension, osteoporosis
3	90	M	13/06/08	Yes	No	Yes (asthenia, fever not attributable to infection, polyarthralgias)	76	8.0	hypoechoogenic halo sign	DM, obesity, hypertension
While treatment with MMF at the end of follow-up										
Patient	Month of follow up	Prednisone Starting Dosage/ Final Dosage (mg/d)	Disease Characteristic			Inflammation score		Response to therapy		
			headache	Jaw claudication	Systemic symptoms	ESR (mm/h)	CRP (mg/dl) (normal value <0.5 mg/dl)			
1	10	50/ 5	No	No	No	6	<0.5	Yes		
2	22	50/ 7.5	No	No	No	24	0.7	Yes		
3	27	25/ 5	No	No	No	6	<0.5	Yes		

