

AperTO - Archivio Istituzionale Open Access dell'Università di Torino

Morphological parameters of flat epithelial atypia (FEA) in stereotactic vacuum-assisted needle core biopsies do not predict the presence of malignancy on subsequent surgical excision.

This is the author's manuscript

Original Citation:

Availability:

This version is available <http://hdl.handle.net/2318/129298> since

Published version:

DOI:10.1007/s00428-012-1279-y

Terms of use:

Open Access

Anyone can freely access the full text of works made available as "Open Access". Works made available under a Creative Commons license can be used according to the terms and conditions of said license. Use of all other works requires consent of the right holder (author or publisher) if not exempted from copyright protection by the applicable law.

(Article begins on next page)



UNIVERSITÀ DEGLI STUDI DI TORINO

The final publication is available at Springer via <http://dx.doi.org/10.1007/s00428-012-1279-y>

Morphological parameters of flat epithelial atypia (FEA) in stereotactic vacuum-assisted needle core biopsies do not predict the presence of malignancy on subsequent surgical excision

Simonetta Bianchi¹, Benedetta Bendinelli², Isabella Castellano³, Quirino Piubello⁴,
Giuseppe Renne⁵, Maria Grazia Cattani⁶, Domenica Di Stefano⁷, Giovanna Carrillo⁸,
Licia Laurino⁹, Alessandra Bersiga¹⁰, Carmela Giardina¹¹, Stefania Dante¹², Carla Di Loreto¹³,
Carmela Quero¹⁴, Concetta Maria Antonacci¹⁵, Domenico Palli², VANCB Study Group

¹ Division of Pathological Anatomy, Department of Medical and Surgical Critical Care, AOU Careggi, University of Florence, Largo G.A. Brambilla 3, 50134 Florence, Italy
e-mail: simonetta.bianchi@unifi.it

² Molecular and Nutritional Epidemiology Unit, Cancer Research and Prevention Institute (ISPO), Florence, Italy

³ Division of Pathological Anatomy, Department of Biomedical Sciences and Human Oncology, University of Turin, Turin, Italy

⁴ Pathological Anatomy Unit, OCM, Azienda Ospedaliera Universitaria Integrata di Verona, Verona, Italy

⁵ Division of Pathology and Laboratory Medicine, European Institute of Oncology, Milan, Italy

⁶ Pathological Anatomy Unit, Bellaria Hospital, Bologna, Italy

⁷ Division of Pathological Anatomy, Department of Neurological Sciences, St Andrea Hospital, "La Sapienza" University, Rome, Italy

⁸ Pathological Anatomy Unit, AORN Cardarelli Hospital, Naples, Italy

⁹ Pathological Anatomy Unit, General Hospital of Treviso, Treviso, Italy

¹⁰ Pathological Anatomy Unit, Istituti Ospitalieri di Cremona, Cremona, Italy

¹¹ Department of Pathological Anatomy, University of Bari, Bari, Italy

¹² Pathological Anatomy Unit, Hospital of Vicenza, Vicenza, Italy

¹³ Division of Pathological Anatomy, Department of Medical and Biological Sciences, University of Udine, Udine, Italy

¹⁴ Department of Pathology, National Cancer Institute Giovanni Paolo II, Bari, Italy

¹⁵ Pathological Anatomy Unit, Sacco Hospital, Milan

Abstract

Flat epithelial atypia (FEA) may represent the earliest precursor of low-grade breast cancer and often coexists with more advanced atypical proliferative breast lesions such as atypical ductal hyperplasia (ADH) and lobular intraepithelial neoplasia (LIN). The present study aims to investigate the association between morphological parameters of FEA and presence of malignancy at surgical excision (SE) and the clinical significance of the association of FEA stereotactic 11-gauge vacuum-assisted needle core biopsy (VANCB), reporting a diagnosis of FEA, ADH or LIN with subsequent SE from 14 pathology departments in Italy.

Available slides were reviewed, with 114 (19.4 %) showing a malignant outcome at SE. Among the 190 cases of pure FEA, no statistically significant association emerged between clinical–pathological parameters of FEA and risk of malignancy. Logistic regression analyses showed an increased risk of malignancy according to the extension of ADH among the 275 cases of FEA associated with ADH ($p=0.004$) and among the 34 cases of FEA associated with ADH and LIN ($p=0.02$). In the whole series, a statistically significant increased malignancy risk emerged according to mammographic R1–R3/R4–R5 categories (OR 1.56; $p=0.04$), extension (OR 1.24; $p=0.04$) and grade (OR 1.94; $p=0.004$) of cytological atypia of FEA. The presence of ADH was associated with an increased malignancy risk (OR 2.85; $p<0.0001$). Our data confirm the frequent association of FEA with ADH and/or LIN. A diagnosis of pure FEA on VANCB carries a 9.5 % risk of concurrent malignancy and thus warrants follow-up excision because none of the clinical–pathological parameters predicts which cases will present carcinoma on SE.

Keywords: Breast . Flat epithelial atypia . Stereotactic vacuum-assisted needle core biopsy . Surgical excision . Malignancy

Introduction

Widespread implementation of mammography screening programmes and the introduction of digital mammography in the pre-clinical diagnosis of breast lesions have led to an increasing number of core biopsies (CB) performed for nonpalpable nodules and microcalcifications. In the diagnostic assessment of microcalcifications, stereotactic 11-gauge vacuum-assisted needle core biopsy (VANCB) has a lower underestimation rate for malignancy than stereotactic 14-gauge needle core biopsy (NCB) ¹. On CB performed for indeterminate or suspicious microcalcifications, a lesion designated as flat epithelial atypia (FEA) is frequently diagnosed.

FEA, for which the term ductal intraepithelial neoplasia grade 1a (DIN1a) is also used, was introduced by the World Health Organization (WHO) Working Group on the Pathology and Genetics of Tumors of the Breast ² with the aim of unifying columnar cell lesions with low-grade of cytological atypia, characteristically without complex architectural atypia in the form of arcades, bars, Roman bridges, tufts or micropapillae that are essential in distinguishing this lesion from atypical ductal hyperplasia (ADH or DIN1b).

For FEA, a variety of terms has been proposed ³. Azzopardi ⁴ introduced the term clinging carcinoma in situ for this lesion, which can be mistaken for either normal breast tissue or fibrocystic breast change. Although the biological and clinical significance of FEA is still far from completely understood, emerging histological and molecular evidence suggests that FEA may represent the earliest morphologically identifiable non-obligatory precursor of low-grade breast cancer ^{5,6}. In fact, FEA often coexists with more advanced atypical proliferative breast

lesions such as ADH and atypical lobular hyperplasia (LIN1/ALH) or low-grade ductal carcinoma in situ (DCIS, particularly micropapillary and cribriform type), lobular carcinoma in situ (LIN2/LCIS), tubular carcinoma and invasive lobular carcinoma (ILC) [7–12]. Otherwise, the possibility that columnar cell lesions in general and FEA in particular significantly elevate breast cancer risk is at the moment not well supported ^{13, 14}. From a clinical point of view, a diagnosis of FEA on CB, pure or in association with more advanced atypical proliferative breast lesions, impacts on the management of these patients. Based on the underestimated malignancy rates of patients with a CB diagnosis of FEA, the prevailing recommendation remains surgical excision (SE) ¹⁵.

The aims of our study were to evaluate: (1) if morphological parameters of pure FEA can predict malignancy (DCIS or invasive carcinoma) in subsequently performed SE, (2) the frequency of association of FEA with more advanced atypical proliferative breast lesions such as ADH

and/or lobular intraepithelial neoplasia (LIN) and (3) the clinical significance of ADH and or LIN associated with FEA in terms of finding DCIS or invasive carcinoma in subsequently performed SE.

Materials and methods

The study population of a large Italian multi-institutional series of stereotactic VANCB, performed using an 11-gauge stereotactic vacuum-assisted device (Mammotome®, Ethicon Endo-Surgery, Breast Care, Norderstedt, Germany), has been previously reported¹. Of 22 institutions participating in that study, 14 agreed to proceed with a histological review

of all VANCB and SE specimens: eight from Northern Italy, three from Central Italy and three from Southern Italy. Institutional review board approvals were obtained for the study from each participating centre.

Pathology departments participating in the study were asked to retrieve from their archival files all available slides of consecutive B3 cases from VANCB specimens related to the study period¹ and reported in the original histological diagnosis as FEA, atypical epithelial proliferation of ductal type/ADH and LIN. In all participating pathology departments, once a diagnosis of FEA was considered, at least three additional levels of sectioning of VANCB, generally taken approximately at 25 µm apart, were routinely performed in view of the possibility of coexisting more advanced atypical proliferative breast lesions such as ADH and LIN1/ALH. Only VANCB cases with subsequent SE were included in this study.

Radiology departments participating in the study were asked to provide for each case the age of patient, mammographic pattern (microcalcifications versus other patterns), mammographic category according to BIRADS (Breast Imaging Reporting and Data System) five-point (R1-R5) classification system¹⁶, number of tissue cores obtained (12, 13–20, 21+) and presence of residual microcalcifications on post-stereotactic VANCB radiograms.

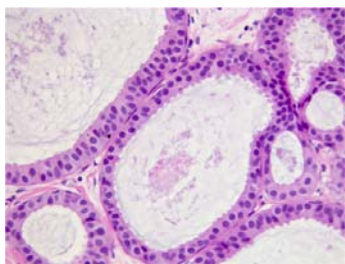


Fig. 1 Pure flat epithelial atypia: dilated acinar unit lined by a single cell layer of columnar epithelial cells that show mild cytological atypia characterized by relatively round and monotonous nuclei

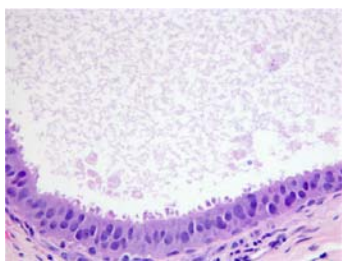


Fig. 2 Pure flat epithelial atypia formed from columnar cells showing mild (left and right) to moderate (centre) nuclear atypia with an increased nuclear-cytoplasmic ratio

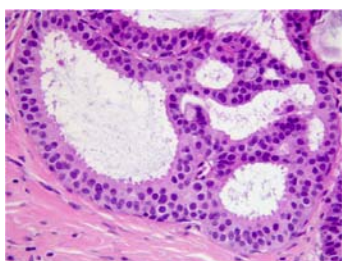


Fig. 3 Atypical ductal hyperplasia arising in a background of flat epithelial atypia: part of the acinus is lined by only a few layers of atypical cells (left); on the right, the acinus shows a more complex architectural atypia with formation of bridges and fenestrations. Atypical ductal hyperplasia is composed of cells cytologically identical to those in the areas of flat epithelial atypia

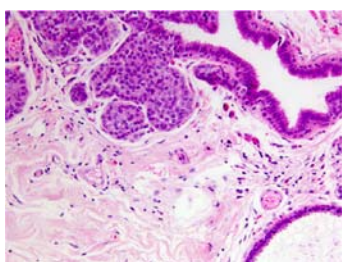


Fig. 4 Terminal duct lobular unit concurrently affected by lobular intraepithelial neoplasia (left), columnar cell change (centre and right) and flat epithelial atypia (lower right)

Table 1 Distribution of the final histological outcomes after surgical excision and percentages of malignancy according to the VANCB-reviewed histological diagnoses among 589 study cases of pure or associated FEA. Heterogeneity p value <0.0001

Mention of FEA at VANCB	Diagnosis at surgical excision				Total
	Benign, N	Atypia, N	Malignancy		
			N	%	
Pure FEA	73	99	18	9.5	190 (32.2 %)
FEA + ADH	72	128	75	27.3	275 (46.7 %)
FEA + LIN	17	60	13	14.4	90 (15.3 %)
FEA + ADH + LIN	5	21	8	23.5	34 (5.8 %)
Total	167 (28.4 %)	308 (52.3 %)	114 (19.4 %)		589 (100 %)

An electronic spreadsheet to record clinical, radiological and histological data was used. Each pathologist participating in the study reviewed all haematoxylin & eosin (H&E) and immunohistochemically stained slides, when routinely obtained, of his/her own VANCB cases. The following morphological parameters were evaluated: (a) presence of determinant microcalcifications within the index lesion, (b) presence of unrelated microcalcifications, (c) patterns of FEA (cystically dilated glands, blunt duct adenosis (BDA) resembling pattern on low power, presence of apocrine features as reported by Kunju et al. ¹¹), (d) grade of cytological atypia of FEA: mild atypia (characterized by relatively round or ovoid rather than elongated nuclei with a slight increase in the nuclear/cytoplasmic ratio, finely dispersed chromatin or slight margination of chromatin, variably prominent nucleoli and loss of polarity) or moderate atypia

(characterized by enlarged, more oval nuclei with cytologically atypical features including mild to moderate pleomorphism, prominent nucleoli, some clumping of chromatin and increased nuclear/cytoplasmic ratio) as described by Pinder et al. ^{17,18}, (e) patterns of ADH (cribriform, micropapillary, solid or with presence of apocrine features) according to Kunju et al. ¹¹, (f) patterns of LIN (LIN1/ALH or LIN2/LCIS), (g) presence of chronic inflammation and (h) presence of stromal changes including fibrosis and myxoid change.

FEA was diagnosed according to strict morphological criteria ^{2,19}: variably distended acini lined by one to several layers of monotonous, mildly or moderately atypical, cuboidal to columnar cells growing in an exclusively flat pattern in the complete absence of architecturally atypical intraluminal proliferations. The presence of a single atypical intraluminal structure as arcade, bar, Roman bridge, tuft or micropapillary formation was considered enough for

a diagnosis of FEA associated with concomitant ADH.

ADH was diagnosed using combined histological and cytological criteria as established by Page and Rogers ²⁰: a proliferative lesion that fulfils some but not all qualitative criteria for a diagnosis of intraductal carcinoma, i.e. evenly spaced cells with hyperchromatic nuclei coexisting with patterns of usual ductal hyperplasia or columnar cell changes, producing a partial involvement of glandular structure by neoplastic cells. In CB histology, technical issues hamper the application of quantitative criteria in diagnosing ADH ²¹.

In the histological revision, LIN was subdivided into atypical lobular hyperplasia (LIN1/ALH) and lobular carcinoma in situ (LIN2/LCIS). LIN1/ALH was defined by filling and distension of fewer than half of the terminal duct units of a lobule with uniform small dyscohesive cells,

evenly spaced, with round nuclei and minimal pleomorphism. LIN2/LCIS was diagnosed when more than half of the acini in the terminal duct units were completely filled or distended ²². The presence of a single lobule with morphological characteristics of LIN1 or LIN2 was considered sufficient for a diagnosis of FEA associated with LIN. The extent of involvement was determined by evaluating the number of large ducts and/or terminal duct lobular units affected by FEA, ADH and LIN as described by Ely et al. ²³ and Wagoner et al. ²⁴. Cases were divided according to the number of foci affected in: (a) cases confined to one focus, (b) cases limited to two foci, (c) cases limited to three foci and (d) cases with four or more foci. The reviewed VANCB final diagnoses were coded into seven categories as follows: pure FEA, pure ADH, pure LIN, FEA + ADH, FEA + LIN, ADH + LIN, FEA + ADH + LIN.

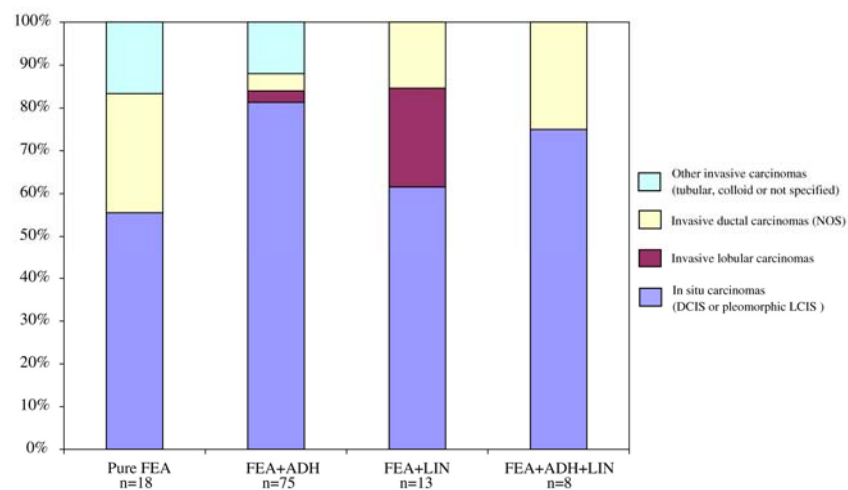


Fig. 5 Percentage distribution of the histological types and grade (nuclear grade for DCIS and histological grade for invasive carcinomas) of malignancies, as diagnosed at surgical excision, according to VANCB diagnosis

Table 2 Distribution of 190 patients with a VANCB diagnosis of pure FEA according to the final histological outcome at surgical excision (malignancy yes/no) and several FEA-related variables. ORs from logistic analyses (95 % CIs and p values) for each variable as estimate of malignant breast cancer risk are also reported based on a model including terms for age and grade of cytological atypia of FEA

		Malignancy at surgical excision			Logistic analysis		
		Yes	No	p value	OR	95 % CI	p
Mammographic category ^a	R2–R3	8	105		1		
	R4–R5	10	67	0.17	2.15	0.78–5.77	
Mammographic pattern	Microcalcifications ^b	18	167				
	Other	0	5	1.00c			
Determinant microcalcifications	Yes	15	158		1		
	No	3	14	0.21c	2.57	0.64–10.43	0.19
Number of cores	12	3	33				
	13–20	14	135				
	>20	1	4	0.52c	1.14d	0.34–3.81	0.83
Chronic inflammation	Yes	2	21		1		
	No	16	151	1.00c	1.33	0.82–6.39	0.72
Stromal changes	Yes	6	63		1		
	No	12	109	0.78	1.40	0.49–4.01	0.53
Pattern of FEA	BDA resembling pattern (reference)	7	52		1		
	Cystically dilated glands	11	105				
	Apocrine features	0	15	0.46c			
FEA with apocrine features	Yes	0	15		1		
	No	18	157	0.37c			
Extension of FEA	1 focus	3	36				
	2 foci	2	40				
	3 foci	6	44				
	4+ foci	7	52	0.59c	1.23d	0.78–1.94	0.37
Extension of FEA (dichotomous)	1–2 foci	5	76		1		
	3+ foci	13	96	0.18	1.99	0.67–5.91	0.21
Cytological atypia of FEA	Mild grade	9	123		1		
	Moderate grade	9	49	0.06	2.41	0.90–6.45	0.08

^a R2 mammographic category was reported in 1 case (0.5 %) and R5 mammographic category was reported in 4 cases (2.1 %)
^b In 48 cases (25.9 %), complete removal of microcalcifications was obtained; among them, two cases of malignancy were assessed at surgical excision
^c p values from Fisher exact tests
^d Variable included as an ordinal term in the logistic model.

In each pathology department participating in the study, histology reports and slides of subsequent SE were collected. Each local pathologist reviewed all H&E slides of subsequent SE of his/her VANCB cases included in the study and reported them as: (a) malignant lesions specifying histotype, histological grade, size and lymph node status for invasive carcinoma, nuclear grade and size for DCIS and size for pleomorphic lobular carcinoma in situ, (b) atypical lesions specifying if FEA, ADH, ALH, LCIS were pure or in association and (c) benign lesions. Pathologists were asked to select for each VANCB case one or more representative H&E stained slides and, where appropriate, IHC-stained slides of the lesion to be reviewed jointly by the panel of 14 pathologists participating in the study. The selected slides of all VANCB cases included in the study were reviewed during a meeting organized at the Division of Pathological Anatomy of the University of Florence in September 2010 to obtain concordance on the diagnosis on each VANCB. Slides were reviewed using the Leica DMD108 digital microscope (Leitz Microsystems, Wetzlar, Germany) connected to a high-resolution data projector. In cases for which concordance was not reached, a majority diagnosis was established. No information about SE followup was provided during the panel revision. For the present analyses, only cases with a VANCB diagnosis of FEA (pure FEA, FEA + ADH, FEA + LIN, FEA + ADH + LIN) were considered.

Table 3 Frequency of several FEA- and ADH-related variables among 275 patients with a VANCB diagnosis of combined FEA and ADH according to histological outcome at surgical excision (malignant yes/no). ORs from logistic analyses (95 % CIs and p values) for each variable as estimate of malignant breast cancer risk are also reported

		Malignancy at surgical excision		p value	Logistic analysis		
		Yes	No		OR ^b	95 %	CI p
Mammographic category ^a	R3	31	102		1		
	R4–R5	44	98	0.15	1.52	0.86–2.68	0.15
Mammographic pattern	Microcalcifications ^d	75	193		1		
	Other	0	7		0.20 ^e		
Determinant microcalcifications	Yes	96	188		1		
	No	6	12	0.59 ^e	1.54	0.51–4.69	0.45
Number of cores	12	11	33				
	13–20	62	158				
	>20	2	8	0.81 ^e	0.91 ^c	0.46–1.79	0.78
Chronic inflammation	Yes	15	36		1		
	No	60	164	0.70	0.83	0.40–1.71	0.61
Stromal changes	Yes	29	74		1		
	No	46	126	0.80	0.95	0.53–1.71	0.87
Pattern of FEA	BDA resembling pattern (reference)	28	83		1		
	Cystically dilated glands	45	114		1.15	0.64–2.06	0.64
	Apocrine features	2	3	0.68 ^e	2.83	0.40–20.21	0.30
FEA with apocrine features	Yes	2	3		1	0.06–2.24	0.27
	No	73	197	0.62 ^e	0.38	0.06–2.66	0.33
Extension of FEA	1 focus	8	34				
	2 foci	14	53				
	3 foci	15	38				
	4+ foci	38	75	0.16	1.17 ^c	0.88–1.56	0.28
	1–2 foci	22	87		1		

(dichotomous)							
	3+ foci	53	113	0.03	1.35	0.71–2.56	0.36
Cytological atypia of FEA	Mild grade	45	138		1		
	Moderate grade	30	62	0.16	1.50	0.84–2.67	0.17
Pattern ADH	Cribriform (reference)	31	103		1		
	Micropapillary	41	86		1.72	0.97–3.07	0.06
	Solid	2	7		1.07	0.20–5.67	0.94
	Apocrine features	1	4	0.40 ^e	1.24	0.13–12.4	0.85
ADH with apocrine features	Yes	1	4		1		
	No	74	196	1.00 ^e	2.69	0.21–34.56	0.45
Extension of ADH	1 focus	15	64				
	2 foci	22	66				
	3 foci	13	38				
	4+ foci	25	32	0.01	1.45 ^c	1.12–1.86	0.004
Extension of ADH (dichotomous)	1–2 foci	37	130		1		
	3+ foci	38	70	0.02	1.85	1.06–3.23	0.03

^a R5 mammographic category was reported in six (2.2 %) cases, while no cases were reported as R2 mammographic category

^b Adjusted for age, grade of cytological atypia of FEA, pattern of ADH, extension of ADH

^c Variable included as an ordinal term in the logistic model

^d In 50 (18.7%) cases, complete removal of microcalcifications was obtained; among them, five cases of malignancy were assessed after surgical excision

^e p values from Fisher exact test

Statistical analysis

The distribution of the histological diagnoses reported for the 859 VANCB specimens was calculated. The distribution of the histological diagnoses after SE (benign, atypical or malignant lesion) was also established as well as the percentage of cases with malignancy (according to each specific diagnosis at VANCB).

For all cases with a diagnosis of FEA (pure or associated with other lesions), the distribution according to the following variables was calculated: mammographic category (R2–R3, R4–R5), mammographic pattern (microcalcifications, other), determinant microcalcifications (yes, no), number of cores (12, 13–20, >20), chronic inflammation (yes/no), stromal changes (yes/no), pattern of FEA (blunt duct adenosis resembling pattern, cystically dilated glands, apocrine features), extension of FEA (one focus, two foci, three foci, four foci or more), grade of cytological atypia of FEA (mild, moderate), pattern of ADH (cribriform, micropapillary, solid or with presence of apocrine features), extension of ADH (one focus, two foci, three foci, four foci or more), pattern of LIN (ALH/LIN1 or LCIS/LIN2), extension of LIN (one focus, two foci, three foci, four foci or more). P values from chi-square test or Fisher exact test were also calculated. Mean age at VANCB diagnosis according to malignant outcome (p values from between-mean comparison t tests) was also calculated. Logistic regression models were used to compute odd ratios (ORs) and 95 % confidence intervals (95 % CIs) for each FEA-related variable as estimate of malignant breast cancer risk. Logistic regression analyses were performed separately for a diagnosis on VANCB of pure FEA, of FEA + ADH, of FEA + LIN and of FEA +ADH + LIN. Logistic models were adjusted for age at VANCB diagnosis of the cases, grade of cytological atypia of FEA, pattern and extension of ADH or LIN or both, respectively.

Logistic regression analyses were also performed for all cases including a VANCB diagnosis of FEA (pure FEA or FEA + ADH or FEA + LIN or FEA + ADH +LIN). Logistic models were adjusted for age at VANCB diagnosis, grade of cytological atypia of FEA and copresence of ADH or LIN.

Results

A total of 859 histologically reviewed VANCB cases with a subsequent SE were available including pure FEA (Figs. 1 and 2) (N0190, 22.1 %), pure LIN (N0149, 17.3 %), pure ADH (N0108, 12.6 %), FEA associated with ADH (Fig. 3) (N0275, 32.0 %), FEA associated with LIN (Fig. 4) (N090, 10.5 %), ADH associated with LIN (N013, 1.5 %) and FEA associated with both ADH and LIN (N034, 4.0 %). Of 589 (68.6 %) cases with FEA (190 pure FEA and 399 FEA associated with ADH or LIN or ADH + LIN), 167(28.3 %) had a benign, 308 (52.3 %) an atypical (including LIN1 and LIN2) and 114 (19.4 %) a malignant outcome diagnosed on subsequent SE. A total of 18 malignancies among pure FEA, 75 malignancies among FEA + ADH, 13 malignancies among FEA + LIN and 8 malignancies among FEA + ADH + LIN were diagnosed on SE, resulting in underestimation rates of 9.5, 27.3, 14.4 and 23.5% respectively (Table 1; heterogeneity p value <0.0001). As shown in Fig. 5, DCIS was the most frequent malignancy at SE among all the types of VANCB diagnosis. The median age of patients with pure FEA was 50.7 years, 51.9 years for FEA + ADH, 49.9 years for FEA + LIN and 52.6 years for FEA + ADH +LIN (data not shown).

In Tables 2, 3, 4 and 5, the distribution of cases with a VANCB diagnosis of pure FEA, FEA + ADH, FEA + LIN and FEA + ADH + LIN, respectively, according to malignancy upon SE, and several FEA and/or ADH and/or LIN related variables is reported together with the results of multivariate analyses. The risk of malignancy in women with moderate cytological atypia showed a trend towards being increased (Table 2) compared with that of women with mild cytological atypia (χ^2 test, p00.06). The suggestion was confirmed by logistic regression analysis (OR 2.41; p00.08). The suggestion that complete removal of microcalcifications was less frequently associated with malignancy (two cases out of 48 or 4.2 % showing malignancy at surgery) than incomplete removal was not statistically significant (16 out of 142 or 11.3 %).

In Table 3 (FEA + ADH), an increased risk of malignancy according to the extension of ADH emerged in a model adjusted for age, grade of cytological atypia of FEA and pattern of ADH (OR 1.45, p value 0.004).

In Table 4 (FEA + LIN), an increased risk of malignancy in patients with a moderate grade of cytological atypia of FEA compared to patients with a mild grade of cytological atypia emerged (OR 5.22, p value 0.03). In Table 5 (FEA + ADH + LIN), an increased risk of malignancy according to the extension of ADH emerged (OR 6.71, p value 0.02).

According to Table 6, women in the mammographic category R4–R5 had an increased risk of malignancy compared with those in R2–R3 category (OR 1.56, 95 % CI 1.01–2.39, p value 0.04). Women with an extension of FEA of three foci or more had an increased risk of malignancy compared with those with one or two foci (OR 1.73, 95 % CI 1.10–2.73, p value 0.02). Women with moderate grade of cytological atypia had an increased risk of malignancy compared with those with mild grade of cytological atypia (OR 1.94, 95 % CI 1.24–3.04, p 0.004). While the association of LIN with FEA at VANCB (FEA + LIN or FEA + ADH + LIN) did not modulate the risk of a malignant outcome, the association of ADH (FEA + ADH or FEA + ADH + LIN) was a strong predictor of malignancy at SE (OR 2.85, 95 % CI 1.78–4.58, p<0.0001). The mean age of women with malignancy at SE was significantly higher than that of women with a non-malignant outcome (53.4 vs 50.7 years, p00.001).

Table 4 Frequency of several FEA- and LIN-related variables among 90 patients with a VANCB diagnosis of FEA associated with L IN according to histological outcome at surgical excision (malignant yes/no). ORs from logistic analyses (95 % CIs and p values) for each variable as estimate of malignant breast cancer risk are also reported

		Malignancy at surgical excision			Logistic analysis		
		Yes	No	p value	OR ^b	95 % CI	p
Mammographic category ^a	R3	6	42		1		
	R4–R5	7	35	0.57	1.58	0.42–5.95	0.5
Mammographic pattern	Microcalcifications ^d	11	73		1		
	Other	2	4	0.21 ^e	4.57	0.61–34.52	0.14
Determinant microcalcifications	Yes	12	58		1		
	No	1	9	0.28 ^e	0.16	0.02–1.63	0.12
Number of cores	12	2	7				
	13–20	9	63				
	>20	23	7	0.47 ^e	1.70 ^c	0.32–9.20	0.54
Chronic inflammation	Yes	3	7		1		
	No	10	70	0.15 ^e	0.38	0.07–2.08	0.27
Stromal changes	Yes	4	28		1		
	No	9	49	0.77 ^e	1.06	0.25–4.46	0.94
Pattern of FEA	B DA resembling pattern (reference)	2	29		1		
	Cystically dilated glands	8	48	3.52		0.61–20.35	0.16
	Apocrine features	3	0	0.002 ^e			
FEA with apocrine features	Yes	3	0		1		
	No	10	77	0.002 ^e			
Extension of FEA	1 focus	6	27				
	2 foci	1	21				
	3 foci	2	12				
	4+ foci	4	17	0.50 ^e	0.92 ^c	0.53–1.58	0.75
Extension of FEA (dichotomous)	1-2 foci	7	48		1		
	3+ foci	6	29	0.56	1.06	0.29–3.85	0.93
Cytological atypia of FEA	Mild grade	9	70		1		
	Moderate grade	4	7	0.05 ^e	5.22	1.16–23.53	0.03
Pattern of LIN	LIN1/ALH	10	42		1		
	LIN2/LCIS	3	35	0.22 ^e	0.38	0.09–1.53	0.17
Extension of LIN	1 focus	3	22				
	2 foci	3	19				
	3 foci	3	14				
	4+ foci	4	22	0.98 ^e	1.26 ^c	0.73–2.19	0.41
Extension of LIN (dichotomous)	1–2 foci	6	41		1		
	3+ foci	7	36	0.64	1.58	0.45–5.58	0.48

^a R5 mammographic category was reported in one (1.1 %) case, while no cases were reported as R2 mammographic category

^b Adjusted for age, cytological atypia of FEA, pattern of LIN, extension of LIN

^c variable included as an ordinal term in the logistic model.

^d In 17 (20.2 %) cases, complete removal of microcalcifications was obtained; among them, no cases of malignancy were assessed after surgical excision

^e p values from Fisher exact tests

Table 5 Frequency of several FEA-, ADH- and LIN-related variables among 34 patients with a ANCB diagnosis of FEA associated with ADH and LIN according to histological outcome after surgical excision (malignant yes/no). ORs from logistic analyses (95 % CIs and p values) for each variable as estimate of malignant breast cancer risk are also reported

		Malignancy at surgical excision			Logistic analysis		
		Yes	No	p value	OR ^b	95 % CI	p
Mammographic category ^a	R3	4	12		1		
	R4	4	14	1.00 ^e	1.51	0.08–28.34	0.78
Mammographic pattern	Microcalcification ^d	8	25		1		
	Other	0	1	1.00			
Determinant microcalcifications	Yes	7	19		1		
	No	1	7	0.64 ^e	2.89	0.09–89.38	0.54
Number of cores	12	1	3				
	13–20	6	21				
	>20	1	2	1.00 ^e	0.85 ^c	0.09–7.97	0.88
Chronic inflammation	Yes	1	1		1		
	No	7	25	0.42 ^e	1.09	0.003–474.86	0.98
Stromal changes	Yes	3	5		1		
	No	5	21	0.36 ^e	0.05	0.001–2.23	0.12
Pattern of FEA	BDA-resembling pattern (reference)	3	8		1		
	Cystically dilated glands	4	16		0.47	0.02–10.90	0.64
	Apocrine features	1	2	0.72 ^e			
Apocrine features of FEA	Yes	1	2		1		
	No	7	24	1.00 ^e	0.06	0.001–3.40	0.17
Extension of FEA	1 focus	2	8				
	2 foci	0	7				
	3 foci	1	2				
	4+ foci	5	9	0.31 ^e	0.59 ^c	0.16–2.19	0.43
Extension of FEA (dichotomous)	1–2 foci	2	15		1		
	3+ foci	6	11	0.22 ^e	0.60	0.03–10.36	0.72
Cytological atypia of FEA	Mild grade	5	22		1		
	Moderate grade	3	4	0.32 ^e	1.35	0.11–17.24	0.82
Pattern ADH	Cribriform (reference)	3	11		1		
	Micropapillary	3	10	4.79		0.14–170.30	0.39
	Solid	1	1				
	Apocrine features	1	4	0.85 ^e			

Apocrine features of ADH	Yes	1	4		1		
	No	7	22	1.00 ^e	0.16	0.01–4.29	0.27
Extension of ADH	1 focus	2	15				
	2 foci	0	6				
	3 foci	1	2				
	4+ foci	5	3	0.02 ^e	6.71 ^c	1.30–34.77	0.02
Extension of ADH (dichotomous)	1–2 foci	2	21		1		
	3+ foci	6	5	0.007 ^e	86.38	2.26–>999.9	0.02
Pattern of LIN	LIN1/ALH	3	16		1		
	LIN2/LCIS	5	10	0.42 ^e	3.12	0.33–29.64	0.32
Extension of LIN	1 focus	1	6				
	2 foci	3	6				
	3 foci	0	5				
	4+ foci	4	9	0.51 ^e	0.46 ^c	0.13–1.61	0.23
Extension of LIN (dichotomous)	1–2 foci	4	12	1			
	3+ foci	4	14	1.00 ^e	0.04	0.001–1.68	0.09

^a No cases were reported as R2 or R5 mammographic category

^b Adjusted for age, cytological atypia of FEA, pattern of ADH, extension of ADH, pattern of LIN, extension of LIN

^c variable included as an ordinal term in the logistic model.

^d In 12 (36.4 %) cases, complete removal of microcalcifications was obtained; among them, two cases of malignancy were assessed after surgical excision

^e p values from Fisher exact tests

Discussion

Our study, although limited by its retrospective design, to the best of our knowledge, represents the largest series published to date of FEA, pure or in association with more advanced lesions such as ADH and or LIN, diagnosed on stereotactic 11-gauge VANCB with subsequent follow-up surgical excision. It may contribute to the assessment of the clinical and biological significance of pure FEA and to the management of patients with VANCB diagnosis of pure FEA. All VANCB cases were histologically reviewed and diagnoses were agreed by the panel of 14 pathologists participating in the study using non-ambiguous terminology^{25, 26}.

Pure FEA

On CB performed for indeterminate or suspicious microcalcifications, a lesion designated as flat epithelial atypia is increasingly recognized and diagnosed¹. The preoperative histological diagnosis of FEA poses a management dilemma for the clinician. Although there is no definitive agreement at present on the clinical management of FEA (underestimation rates for CB diagnosis of pure FEA reported in the literature vary from 0 to 67 %¹³), the currently prevailing recommendation is that it warrants follow-up surgical excision^{1, 27}. A few studies in the published literature support the follow-up observation for the management of pure FEA^{26, 28, 29}. A recent review¹⁵ reported a pooled underestimation rate of 12 % for FEA in VANCB (in good agreement with our 12.7 %¹) compared to 17 % in studies restricted to NCB (difference not statistically significant). Consequently, the authors concluded that surgical excision should be considered. On the other hand, the data reported mostly concern small series (range 1–60

cases), partly published only in abstract form, mostly lacking standardized terminology (including pure FEA and FEA with ADH and or LIN). No single or a combination of clinical, radiological or pathological criteria clearly identified a subset of pure FEA cases at low risk of malignancy. Thus, our results and other recent data ²⁷ justify the conclusion that the presence of pure FEA on VANCB warrants follow-up excision.

The identification of FEA also poses a diagnostic challenge to the pathologist, particularly in CB, because FEA with mild cytological atypia may be subtle and care should be taken not to overlook the lesion or to over-diagnose it and reporting as atypical any columnar cell lesion ^{17, 18}.

Our results confirm previous reports ^{11, 25-27} that almost all patients (185/190, 97.4 %) with pure FEA are asymptomatic and that microcalcifications are the main determinant in 91 % (173/190) of cases. As earlier studies reported ¹¹, we found moderate to severe chronic inflammation in 12 % of pure FEA cases (23/190) and stromal changes, including myxoid change and fibrosis in 36.3 % (69/190), of which the significance remains to be clarified.

Table 6 Frequency of several FEA-related variables among 589 patients with a mention of FEA in the VANCB diagnosis (pure FEA or FEA associated with ADH or LIN or ADH + LIN) according to histological outcome after surgical excision (malignant yes/no). ORs from logistic analyses (95 % CIs and p values) for each variable as estimate of malignant breast cancer risk are also reported

		Malignancy at surgical excision			Logistic analysis		
		Yes	No	p value	ORb	95 % CI	p
Mammographic category ^a	R2-R3	49	261		1		
	R4-R5	65	214	0.02	1.56	1.01-2.39	0.04
Mammographic pattern	Microcalcifications ^d	112	458		1		
	Other	2	17	0.55 ^e	0.55	0.12-2.52	0.44
Determinant microcalcifications	Yes	103	423		1		
	No	11	52	0.69	1.01	0.49-2.10	0.98
Pattern of FEA	BDA-resembling pattern (reference)	40	172		1		
	Cystically dilated glands	68	283	1.18		0.75-1.86	0.48
Apocrine features of FEA	Apocrine features	6	20	0.88	1.90	0.68-5.29	0.22
	Yes	6	20		1		
Extension of FEA	No	108	455	0.62	0.59	0.22-1.56	0.28
	1 focus	19	105				
Extension of FEA (dichotomous)	2 foci	17	121				
	3 foci	24	96				
	4+ foci	54	153	0.01	1.24 ^c	1.02-1.50	0.04
	1-2 foci	36	226		1		
Cytological atypia of FEA	3+ foci	78	249	0.002	1.73	1.10-2.73	0.02
	Mild grade	68	353		1		
Number of cores	Moderate grade	46	122	0.02	1.94	1.24-3.04	0.004
	12	17	76				
	13-20	91	377				
Chronic inflammation	>20	6	21	0.9	1.05 ^c	0.63-1.74	0.85
	Yes	21	65		1		
Stromal changes	No	93	410	0.2	0.79	0.44-1.39	0.41
	Yes	42	170		1		

	No	72	305	0.83	0.96	0.61–1.49	0.84
Association with ADH	Yes	83	226		1		
	No	31	249	<0.0001	2.85	1.78–4.58	<0.0001
Association with LIN	Yes	21	103		1		
	No	93	372	0.44	1.32	0.75–2.33	0.34

^a R2 Adjusted for age, cytological atypia of FEA, co-presence of ADH and/or LIN

^c variable included as an ordinal term in the logistic model.

^d In 127 (22.3 %) cases, complete removal of microcalcifications was obtained; among them, nine cases of malignancy were assessed after surgical excision

^e p values from Fisher exact tests

FEA associated with ADH

Although FEA may occur as pure lesion, a large proportion (275/589 or 46.7 %) is associated with ADH, in agreement with earlier reports^{11, 12, 26, 27, 30}. The association of FEA with ADH has an important impact on clinical management as for ADH on CB the need for surgical excision is unanimously recognized³¹. The positive predictive value for malignancy of FEA associated with ADH on CB significantly increases when compared to that of pure FEA^{11, 26}. We found that 27.3 % (75/275) of FEA associated with ADH showed a malignancy at follow-up SE. Our study confirms the strong association between FEA and ADH on CB. Our data, together with data from other observational²⁶ and molecular studies^{5–6} support the hypothesis that FEA represents the earliest precursor of low-grade ductal carcinoma, both in situ and invasive¹⁹.

FEA associated with LIN Some investigators have reported the coexistence of FEA and LIN in the same surgical specimen, particularly in cases of tubular carcinoma^{7, 32, 33}. Recently, Abdel-Fatah et al.⁸ found that columnar cell lesions, predominantly FEA, and LIN coexist in 60 % of cases of ILC, suggesting that the loss of E-cadherin expression may switch on the development of lobular differentiation, and proposed an evolutionary pathway of ILC through columnar cell lesions on the basis of histological evidence and common genetic changes.

We found FEA associated with LIN in 15.3 % (90/589) of cases, in agreement with data reported by Levoue et al.²⁷, which results in a malignancy underestimation rate of 14.4 %.

FEA associated with ADH and LIN

In 5.8 % (34/589) of our cases, we found FEA associated both with ADH and LIN, resulting in an underestimation rate of malignancy of 23.5 %, which is closer to the underestimation rate of FEA + ADH (27.3 %) than that of FEA + LIN (14.4 %). This indicates that ADH determines the natural history of the lesion. In FEA associated with both ADH and LIN, the extension of ADH seems to be strongly associated with the risk of malignancy.

Taken together, in our series 19.4 % (114/589) of cases with a mention of FEA (pure FEA and/or FEA associated to ADH and/or LIN) showed a malignancy at subsequent SE.

The risk of malignancy increased along with the mammographic category, the extension of FEA and the grade of cytological atypia of FEA, while the association with ADH was a strong predictor of malignancy. The median age of patients with pure FEA was slightly younger than that of patients with FEA + ADH and FEA + ADH + LIN (50.7, 51.9 and 52.6 years, respectively) but slightly older compared to those with FEA + LIN (49.9 years, as reported earlier) [11, 26].

Conclusion

None of the studied parameters of pure FEA can predict the risk of malignancy in a subsequent SE. A trend was found only for the grade of cytological atypia (mild versus moderate) and incomplete removal of microcalcifications.

In FEA associated with ADH or ADH and LIN, the risk of malignancy increases along with increasing extension of ADH. In FEA associated with LIN, the risk of malignancy is higher in case of moderate cytological atypia of FEA. The risk of malignancy in FEA increased according to mammographic category, extension of FEA and grade of cytological atypia of FEA.

A diagnosis of pure FEA on VANCB warrants SE because, on the basis of clinical–pathological parameters, it is impossible to predict which cases are associated with carcinoma.

The absence of residual microcalcifications on post-VANCB mammography does not exclude the presence of an associated malignancy at SE: we found malignancy in 4 % (2/48), 10 % (5/50) and 16.7 % (2/12) of cases with complete removal of microcalcifications by VANCB in pure FEA, FEA + ADH and FEA + ADH + LIN, respectively.

We therefore confirm the frequent association of FEA with more advanced atypical proliferative breast lesions such as ADH and/or LIN [17–19, 34] and support the recommendation proposed by several authors^{25, 30} that deeper levels of CB with pure FEA should be examined in order to detect or exclude the co-existence of more advanced breast lesions. The findings concerning the frequent association of FEA with more advanced atypical proliferative breast lesions support the hypothesis that FEA, together with ADH and LIN, belongs to the family of precursor lesions of low grade in situ and invasive breast cancer [5, 8] as the earliest precursor recognized to date.

Acknowledgments

Pathologists contributing to VANCB Study Group: Antonacci CM (Milano), Bersiga A (Cremona), Bianchi S (Firenze), Carrillo G (Napoli), Castellano I (Torino), Cattani MG (Bologna), Dante S (Vicenza), Di Loreto C (Udine), Di Stefano D (Roma), Ferrero G (Cremona), Giardina C (Bari), Laurino L (Treviso), Piubello Q (Verona), Querzoli P (Ferrara), Renne G (Milano), Sapino A (Torino), Vezzosi V (Firenze). Radiologists contributing to VANCB Study Group: Amadori S (Milano), Ambrogetti D (Firenze), Balestrieri N (Treviso), Bazzocchi M (Udine), Bodini MT (Cremona), Cassano E (Milano), Durando M (Torino), Festa R (Napoli), Guerrieri AM (SARIS, Bari), Maggian P (Vicenza), Mariscotti G (Torino), Mattei M (Roma), Montemezzi S (Verona), Saguatti G (Bologna), Scalabrin U (Vicenza), Trasente I (Napoli), Ventrella V (Bari)

Funding source This work was supported by a grant from the “Ente Cassa di Risparmio” of Florence-Italy.

Conflict of interest The authors declare that they have no conflict of interest.

References

1. Bianchi S, Caini S, Renne G et al (2011) Positive predictive value for malignancy on surgical excision of breast lesions of uncertain malignant potential (B3) diagnosed by stereotactic vacuumassisted needle core biopsy (VANCB): a large multi-institutional study in Italy. *Breast* 20:264–270

2. Tavassoli FA, Hoefler H, Rosai J et al (2003) Intraductal proliferative lesions. In: Tavassoli FA, Devilee P (eds) Pathology and genetics of tumours of the breast and female genital organs. IARC, Lyon, pp 63–73
3. Monfair F (2010) Flat ductal intraepithelial neoplasia of the breast. A review of diagnostic criteria, differential diagnoses, molecular genetic findings, and clinical relevance. It is time to appreciate the Azzopardi concept. *Arch Pathol Lab Med* 133:879–892
4. Azzopardi JP (1979) Problems in breast pathology. Saunders, London, pp 193–203
5. Simpson PT, Gale T, Reis-Filho JS et al (2005) Columnar cell lesions of the breast: the missing link in breast cancer progression? A morphological and molecular analysis. *Am J Surg Pathol* 29:734–746
6. Bombonati A, Sgroi DC (2011) The molecular pathology of breast cancer progression. *J Pathol* 223:307–317
7. Brogi E, Oyama T, Koerner FC (2001) Atypical cystic lobules in patients with lobular neoplasia. *Int J Surg Pathol* 9:201–206
8. Abdel-Fatah TMA, Powe DG, Hodi Z et al (2007) High frequency of coexistence of columnar cell lesions, lobular neoplasia, and low grade ductal carcinoma in situ with invasive tubular carcinoma and invasive lobular carcinoma. *Am J Surg Pathol* 31:417–426
9. Collins LC, Achacoso NA, Nekhlydov L et al (2007) Clinical and pathologic features of ductal carcinoma in situ associated with the presence of flat epithelial atypia: an analysis of 543 patients. *Mod Pathol* 20:1149–1155
10. Leibl S, Regitnig P, Monfair F (2007) Flat epithelial atypia (DIN 1a, atypical columnar change): an underdiagnosed entity very frequently coexisting with lobular neoplasia. *Histopathology* 50:859–865
11. Kunju LP, Kleer CG (2007) Significance of flat epithelial atypia on mammotome core needle biopsy: should it be excised? *Hum Pathol* 38:35–41
12. Lee TYJ, MacIntosh RF, Rayson D et al (2010) Flat epithelial atypia on breast needle core biopsy: a retrospective study with clinical–pathological correlation. *Breast J* 16:377–383
13. Boulos FI, Dupont WD, Simpson JF et al (2008) Histologic associations and long-term cancer risk in columnar cell lesions of the breast. A retrospective cohort and a nested case–control study. *Cancer* 113:2415–2421
14. Aroner SA, Collins LC, Schnitt SJ et al (2010) Columnar cell lesions and subsequent breast cancer risk: a nested case–control study. *Breast Cancer Res* 12:R61, <http://breast-cancer-research.com/content/12/4/R61>
15. Verschuur-Maes AHJ, Van Deurzen CHM, Monnikhof EM et al (2012) Columnar cell lesions on breast needle biopsies: is surgical excision necessary? A systematic review. *Ann Surg* 255:259–265
16. Lazarus E, Mainiero MB, Schepps B et al (2006) BI-RADS lexicon for US and mammography: interobserver variability and positive predictive value. *Radiology* 239:385–391
17. Pinder SE, Reis-Filho JS (2007) Non-operative breast pathology: columnar cell lesions. *J Clin Pathol* 60:1307–1312
18. Pinder SE, Provenzano E, Reis-Filho JS (2007) Lobular in situ neoplasia and columnar cell lesions: diagnosis in breast core biopsies and implications for management. *Pathology* 39:208–216
19. Schnitt SJ, Vincent-Salomon A (2003) Columnar cell lesions of the breast. *Adv Anat Pathol* 10:113–124

20. Page DL, Rogers LW (1992) Combined histologic and cytologic criteria for the diagnosis of mammary atypical ductal hyperplasia. *Hum Pathol* 23:1095–1097
21. Rosen PP, Hoda SA (2010) *Breast pathology: diagnosis by needle core biopsy*. Lippincott Williams & Wilkins, Philadelphia
22. Cangiarella J, Guth A, Axelrod D et al (2008) Is surgical excision necessary for the management of atypical lobular hyperplasia and lobular carcinoma in situ diagnosed on core needle biopsy? A report of 38 cases and review of the literature. *Arch Pathol Lab Med* 32:979–983
23. Ely KA, Carter BA, Jensen RA et al (2001) Core biopsy of the breast with atypical ductal hyperplasia. A probabilistic approach to reporting. *Am J Surg Pathol* 25:1017–1021
24. Wagoner MJ, Laronga C, Acs G (2009) Extent and histologic pattern of atypical ductal hyperplasia present on core needle biopsy specimens of the breast can predict ductal carcinoma in situ in subsequent excision. *Am J Clin Pathol* 131:112–121
25. Martel M, Barron-Rodriguez P, Tolgay Ocal I et al (2007) Flat DIN 1 (flat epithelial atypia) on core needle biopsy: 63 cases identified retrospectively among 1751 core biopsies performed over an 8-year period (1992–1999). *Virchows Arch* 451:883–891
26. Piubello Q, Parisi A, Eccher A et al (2009) Flat epithelial atypia on core needle biopsy: which is the right management? *Am J Surg Pathol* 33:1078–1084
27. Lavoué V, Roger CM, Poilblanc M et al (2011) Pure flat atypia (DIN 1a) on core needle biopsy: study of 60 biopsies with follow-up surgical excision. *Breast Cancer Res Treat* 125:121–126
28. Senetta R, Campanino PP, Mariscotti G et al (2009) Columnar cell lesions associated with breast calcifications on vacuum-assisted core biopsies: clinical, radiographic, and histological correlations. *Mod Pathol* 22:762–769
29. Noel JC, Buxant F, Engohan-Aloghe C (2010) Immediate surgical resection of residual microcalcifications after a diagnosis of pure flat epithelial atypia on core biopsy: a word of caution. *Surg Oncol* 19:243–246
30. Chivukula M, Bhargava R, Tseng G et al (2009) Clinicopathologic implications of “flat epithelial atypia” in core needle biopsy specimens of the breast. *Am J Clin Pathol* 131:802–808
31. Sudarshan M, Meguerditchian AN, Mesorulle B et al (2011) Flat epithelial atypia of the breast: characteristics and behaviours. *Am J Surg* 201:245–250
32. Rosen PP (1999) Columnar cell hyperplasia is associated with lobular carcinoma in situ and tubular carcinoma. *Am J Surg Pathol* 23:1561
33. Sahoo S, Recant WM (2005) Triad of columnar cell alteration, lobular carcinoma in situ, and tubular carcinoma of the breast. *Breast J* 11:140–142
34. Lerwill MF (2008) Flat epithelial atypia of the breast. *Arch Pathol Lab Med* 132:615–621