

AperTO - Archivio Istituzionale Open Access dell'Università di Torino

Surgical scar endometriosis.

This is the author's manuscript

Original Citation:

Availability:

This version is available <http://hdl.handle.net/2318/130014> since

Published version:

DOI:10.1007/s00595-012-0459-3

Terms of use:

Open Access

Anyone can freely access the full text of works made available as "Open Access". Works made available under a Creative Commons license can be used according to the terms and conditions of said license. Use of all other works requires consent of the right holder (author or publisher) if not exempted from copyright protection by the applicable law.

(Article begins on next page)



UNIVERSITÀ DEGLI STUDI DI TORINO

This is an author version of the contribution published on:

Questa è la versione dell'autore dell'opera:

Surgery Today (2014) 44:767–772 - Surgical scar endometriosis -

Massimiliano Mistrangelo, Nicholas Gilbo, Paola Cassoni, Salvatore Micalef, Riccardo Faletti, Claudio Miglietta, Raffaele Brustia, Gisella Bonnet, Gianluca Gregori, Mario Morino

The definitive version is available at:

La versione definitiva è disponibile alla URL:

<http://link.springer.com/article/10.1007%2Fs00595-012-0459-3>

Surgical scar endometriosis

Massimiliano Mistrangelo, Nicholas Gilbo, Paola Cassoni, Salvatore Micalef, Riccardo Faletti, Claudio Miglietta, Raffaele Brustia, Gisella Bonnet, Gianluca Gregori, Mario Morino

Abstract

Endometriosis is a common disorder in females of reproductive age. Surgical scar endometrioma after cesarean section develops in 1–2 % of patients, and usually presents as a tender and painful abdominal wall mass. The diagnosis is suggested by pre or perimenstrual pelvic pain and is often established only by histology. In this retrospective observational cohort study, we reviewed the medical records of five patients with a histopathological diagnosis of scar endometriosis. A scar mass was found on a previous Pfannenstiel incision in four patients and in a median cesarean section in one patient. The mean age at diagnosis (38.6 years, median 38) was older than reported elsewhere. A histological examination of the surgical specimen confirmed the diagnosis of explorative abdominal laparoscopy may be indicated to exclude the intraperitoneal spread of the disease in symptomatic patients.

Keywords: Abdominal wall endometriosis, Scar endometriosis, Extrapelvic endometriosis, Cutaneous endometriosis

Introduction

Endometriosis is a benign disease in which functioning endometrial tissue is present outside the endometrium and the myometrium. A common disorder in females of reproductive age, it affects up to 22 % of all females [1], though an estimated prevalence of 5–10 % in the general female population is widely accepted [2]. Endometriosis is usually confined to the peritoneal and serosal surfaces of intra-abdominal organs (ovaries, fallopian tubes, peritoneum, and recto-vaginal septum). Less common sites include the bowel, bladder, surgical scars, episiotomy, umbilicus, hernia sacs, lungs and pleura, kidneys, and extremities [3]. The ectopic tissue responds to ovarian hormonal stimulation and tends to proliferate when stimulated by cyclic estrogens, seeming “to menstruate”, as described by the German pathologist Carl von Rokitansky [4], who found endometrial glands in the myometrium and designated this finding as “cystosarcoma adenoids endometriosis in all cases. During the follow-up period (mean 34.6 months), local recurrence (n = 1) and pelvic recurrence (n = 1) were treated surgically. Surgery is the treatment of choice for surgical scar endometriosis. Excision with histologically proven free surgical margins of 1 cm is mandatory to prevent recurrence. As scar endometriosis may be associated with pelvic localization, explorative abdominal laparoscopy may be indicated to exclude the intraperitoneal spread of the disease in symptomatic patients.

Endometriosis is a benign disease in which functioning endometrial tissue is present outside the endometrium and the myometrium. A common disorder in females of reproductive age, it affects up to 22 % of all females [1], though an estimated prevalence of 5–10 % in the general female population is widely accepted [2]. Endometriosis is usually confined to the peritoneal and serosal surfaces of intra-abdominal organs (ovaries, fallopian tubes, peritoneum, and recto-vaginal septum). Less common sites include the bowel, bladder, surgical scars, episiotomy, umbilicus, hernia sacs, lungs and pleura, kidneys, and extremities [3]. The ectopic tissue responds to ovarian hormonal stimulation and tends to proliferate when stimulated by cyclic estrogens, seeming “to menstruate”,

as described by the German pathologist Carl von Rokitansky [4], who found endometrial glands in the myometrium and designated this finding as “cystosarcoma adenoides uterinum”. Extrapelvic endometriosis is a rare entity in which disease frequently localizes to scar tissue and is often asymptomatic. Generally, abdominal wall endometriosis is confined to the peritoneal surface, in which event it is mainly associated with cesarean section (incidence 1–2 %), but it may also result from a previous surgical procedure [5].

Methods

In this retrospective observational cohort study, we reviewed the medical records of patients with a histopathological diagnosis of surgical scar endometriosis. Endometriosis was considered to be present when endometrial tissue was found in fibrous connective or skeletal muscle tissue in areas of focal hemorrhage or of active chronic endometriosis with fibrosis. The cohort was compared for the following parameters: age, parity, previous surgery, symptoms, number of lesions, diameter of the mass, site of the scar endometriosis, initial diagnosis, surgical procedure, eventual opening of the peritoneum, eventual associated laparoscopy, recurrences, and follow-up.

Results

The study cohort comprised five females referred to our institution because of abdominal pain at a surgical scar [Pfannestiel incision (n = 4) and median cesarean section (n = 1)] with a palpable mass which was tender when compressed on physical examination. The patient characteristics are reported in Table 1.

Table 2 reports the presenting symptoms. No symptoms suggestive of pelvic endometriosis were recorded in any of the five cases, the past medical history included previous abdominal surgery (n = 2) [appendectomy and breast cyst excision (n = 1) and laparoscopic cholecystectomy (n = 1)] and was otherwise unremarkable. All five patients underwent ultrasonography which demonstrated a hypoechogenic or dishomogeneous mass in the subcutaneous layer extending to the peritoneum in two cases. Magnetic resonance imaging (MRI) to further investigate the extension of the disease in these two patients aroused suspicion of ovarian micro-foci of endometriosis in one patient, and confirmed the presence of a mass in the right rectus abdominis muscle extending to the peritoneum in the other (Fig. 1). The preoperative exam reports stated a suspected diagnosis of granuloma (n = 2), abdominal scar endometrioma (n = 2), and hernia (n = 1).

All five patients underwent wide-margin surgical excision (Table 3). The patient with suspected micro-foci of ovarian endometriosis according to the MRI findings underwent explorative laparoscopy, which was negative for intraperitoneal disease. Explorative laparoscopy to exclude intra-abdominal foci of endometriosis was also performed in the other patient with a preoperative diagnosis of abdominal scar endometriosis. The wrong preoperative diagnosis in the remaining three patients precluded any further surgery.

Local resection with direct reconstruction of the muscular fascia was performed in two patients. The postoperative course was uneventful, and both were discharged a few days after the operation.

In all five patients, the histological examination of the surgical specimen showed irregular endometrial glands surrounded by stroma with hemosiderin-laden macrophages and chronic inflammation (Figs. 2, 3, 4) with disease free margins.

The mean duration of follow-up was 34.6 months (range 24–48). Local recurrence of disease developed in one patient at 12 months after surgery, when she complained of premenstrual lower abdominal pain. Endo-ultrasonography (EUS) demonstrated four hypoechogenic areas on the rectus abdominis muscles and abdominal fascia. After consultation with the patient's gynecologist and endocrinologist, we elected a medical approach (Gestrinone twice a week for 4 months). As the pain was unresponsive to medical therapy, the patient was readmitted for surgical treatment. Intraoperative EUS revealed three masses within the rectus muscles but no evidence of the fourth mass previously reported. The peritoneum was opened for radical excision of the nodular masses (diameter 2–3 cm). A histological examination of the surgical specimens confirmed the diagnosis of endometriosis. The patient was discharged after an uneventful hospital course. The patient is

currently disease free 2 years after the second operation, no further lesions or recurrences have been found on follow-up computed tomography (CT) or EUS studies.

During the follow-up period, another patient reported the reappearance of lower abdominal pain 18 months after surgical excision of the subcutaneous lesion. EUS and MRI showed an endometriotic lesion of the left ovary that was confirmed by laparoscopy and wedge resection of the ovary. A histological exam confirmed the diagnosis of endometriosis. This patient had not undergone explorative laparoscopy because of an erroneous preoperative diagnosis (granuloma). This patient is also currently free of disease.

Table 1 Patient characteristics

Characteristics	No. of patients (%)
Age (years)	
Median	38
Range	37–40
Parity	
Mean	1.75
Range	1–3
Previous Pfannenstiel incision	4 (80 %)
Cesarean section	1 (20 %)

Table 2 Patient symptoms and characteristics of the lesions

	No. of patients (%)
Asymptomatic period (years)	6.2 (range 3–12)
Duration of symptoms (months)	9.6 (range 5–12)
Symptoms	
Abdominal pain	5 (100)
Cyclic pain	3 (60)
Noncyclic pain	2 (40)
Number of masses	
Solitary	3 (60)
Multiple	2 (40)
Mass diameter (cm)	3.64 (range 3–4.2)
Mass location	
In scar	4 (80)
Away from scar	1 (20)
Initial diagnosis	
Accurate	2 (40)
Wrong	3 (60)

Fig. 1 Inside the right rectus abdominis muscle extending to the anterior soft tissue there were two nodules with hypointense signals in T2 W images (a, b, arrows) and with hyperintense signal spots in T1 W fat suppressed images (A, B, arrows). Intense contrast enhancement is shown in both lesions (c, C)

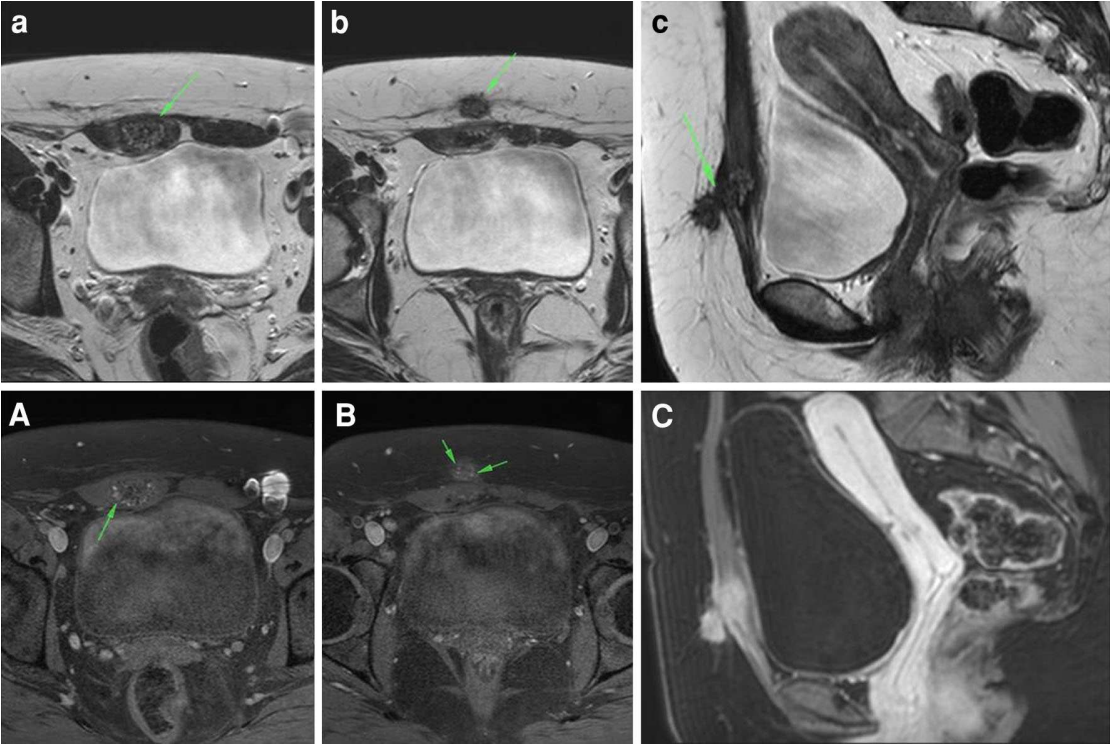


Fig. 2 Endometriosis of the abdominal wall (macroscopic view)

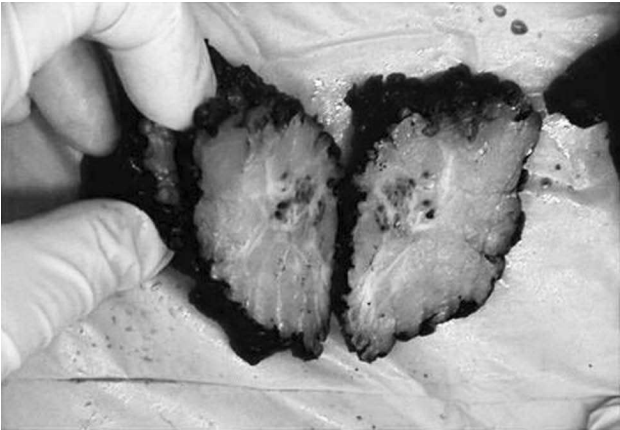
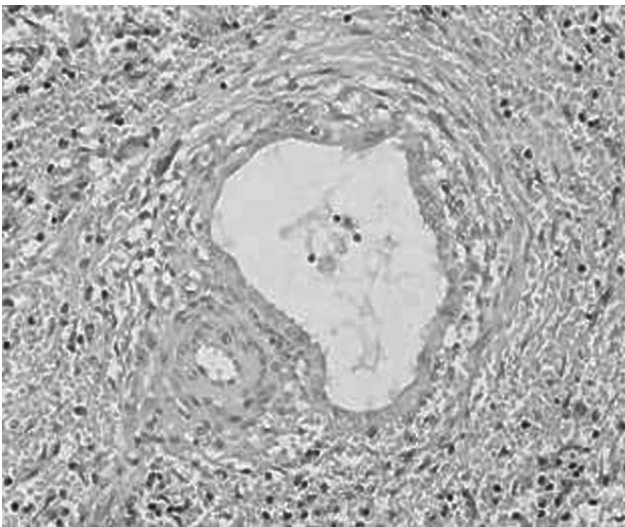


Fig.3 Histological appearance of endometriosis (2 x 1)

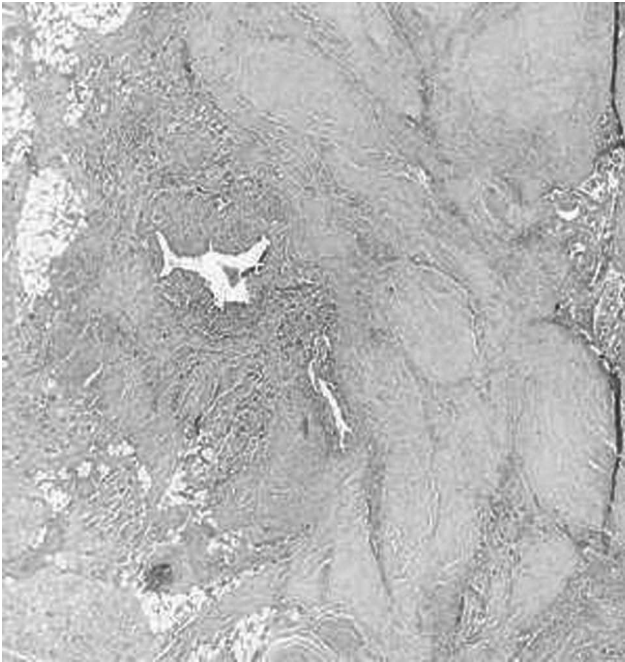

Fig.4 Histological appearance of endometriosis(10 x 2)



Discussion

Endometriosis is a common disorder, but patients rarely present to general surgeons. It has been reported that 75 % of symptomatic patients are between 25-and 45-years-old [3]. The reported incidence of endometriosis varies widely from 1 to 15 %. Williams reported an incidence of 15 % in a prospective study of 1000 females undergoing laparoscopy for benign disease at the Mayo Clinic [6]. Endometriosis generally occurs following obstetric or gynecological procedures such as hysterectomy, episiotomy, cesarean section, amniocentesis, and laparoscopic procedures [7]. The most common location is the pelvis, while the intestinal tract is probably the most common extragenital site, accounting for at least 5 % of all cases of endometriosis [3]. Seydel [5] found 78 reported cases of cesarean section scar endometriosis; its frequency after lower abdominal surgery is estimated to be 1–2 %, while Singh [8] reported an incidence of 0.2 % in 3330 caesarian sections and 24 abdominal wall endometriomas over a 10-year period. Wilson [9] estimated an incidence of 1.06 % for scar endometriosis after hysterotomy (12/1129) and 0.03 % after cesarean section (1/3736), similar to Minaglia [10], who reported an overall incidence of 0.08 % for incisional endometriomas following cesarean section over a 30-year period. A recent review reported a total of 445 cases of abdominal wall endometriosis [11].

We herein reported five cases of surgical scar endometriosis. In our cohort, the mean age at diagnosis was 38.6 years (median 38), which is older than that in other published studies [8, 11, 12]. The pathophysiological processes underlying endometriosis are unclear and three theories (tubal regurgitation, celomic metaplasia, and vascular spread) have been advanced to explain it. A widely accepted explanation for the variety of unusual sites (e.g., lungs, brain, and incisional scars) is that the endometrial cells are transported via hematogenous, lymphatic or iatrogenic routes. Oosterlynck et al. [13] suggested that natural killer activity and/or altered peritoneal macrophage maturation may play a role in its pathogenesis.

The pathogenesis of abdominal wall endometriosis is perhaps best explained by a combination of theories: direct implantation during a surgical procedure on the endometrium [14] or transportation to a cesarean section scar via lymphatic or hematogenous routes [15]. The tissue implant either proliferates under the same hormonal stimulation as the endometrium in the uterus, or induces metaplasia of the surrounding fascial tissue to form an endometrioma.

Bergqvist [16] suggested that scar endometriosis occurs more frequently after intervention on the healthy endometrium. According to de Oliveira [17], a risk factor for scar endometriosis is an early hysterotomy in pregnancy compared with cesarean delivery at full-term during pregnancy: the endometrium from early pregnancy is more favorable for implantation than the endometrium from a late pregnancy. Endometrial inoculation after cesarean section can be prevented with the accurate and comprehensive cleaning of the abdominal wound, particularly at both corner sites (especially on the surgeon's side) [14].

The clinical manifestations of endometriosis are various, and some patients may even be asymptomatic. The lesion typically presents as a tender mass within or adjacent to a surgical scar or cesarean section scar. Generally, the mass develops between the skin and the abdominal fascia and does not grow in the peritoneum (one case in our series). Patients presenting with endometriosis often refer to dysmenorrhea, dyspareunia, irregular menstruation, chronic pelvic or back pain and infertility. A history of previous cesarean section, the presence of a lump increasing in size in the scar, symptoms of pain, bleeding, and skin discoloration can be diagnostic clues for scar endometriosis; rarely, cesarean scar endometriosis can present as an acute abdomen [18]. Cyclic symptoms including bleeding or drainage from the surgical scar during menstruation are not seen in all cases, when present they are pathognomonic for scar endometriosis [19]. In our series, only three patients reported noticing pre or perimenstrual worsening of abdominal pain; otherwise, the referred symptoms were comparable to those described in other studies [11, 20].

The suspected diagnosis is based on findings from the patient's clinical history and physical examination; ordinarily, no further studies are necessary in patients with a classical presentation [21]. Among imaging studies, ultrasound is useful for demonstrating the solid or cystic nature of the

mass and its relationship with the fascia and skin [22]. Doppler sonography may help to establish a reliable preoperative diagnosis [23], and CT can aid in the diagnosis when the mass shows up on the scan as a solid, well-circumscribed lesion, thus establishing its exact dimensions and excluding intra-abdominal extension of the mass [24]. MRI, because of its high spatial resolution, may be more useful for small lesions, and it allows for a better distinction between muscles and the subcutaneous tissue than CT [25]. Griffin suggested the use of fine needle aspiration biopsy (FNA) to confirm the diagnosis and rule out a malignant tumor [26], as has sometimes been reported in the literature [27–29]. Mol et al. [30] suggest that investigational serum marker (CA-125) measurement is limited in the diagnosis of endometriosis of grades I/IV, but it is better for grades III/IV.

Nevertheless, the diagnosis is established with a definitive histological examination in the majority of cases. The differential diagnosis should include an abscess, suture granuloma, neoplasm, hernia, sebaceous cyst, neuroma, soft tissue sarcoma, desmoid tumors, lymphadenopathy, lymphoma, lipoma, hematoma, or metastatic cancer.

Medical therapy is a first-line treatment and can be administered in combination with surgical treatment for pain. Medical therapy involves hormone suppression to downregulate the hypothalamus-pituitary-ovarian pathway [31], but it is generally ineffective for surgical scar endometriosis. However, Rivlin et al. [32] reported a case with cesarean scar endometriosis in which Leuprolide acetate administration was associated with an improvement in the symptoms, but not in reducing the lesion size.

Surgical resection of the scar endometrioma remains the mainstay of treatment even for a recurrence of disease.

Because of the possible recurrence (4.3 % after surgery)

[11] and malignant degeneration (0.3–1 %) [33] of this condition, a local wide excision with at least a 1 cm resection margin is currently considered the best clinical practice [34–37], although no studies have so far evaluated whether the surgical margin width affects the recurrence rate [11].

Scar endometriosis incorporated into the musculature of the abdominal wall requires an en bloc resection of the underlying myofascial elements. As a result, surgeons should, therefore, be prepared for the possibility of a coexisting hernia, and patients should be counseled that mesh repair may be necessary [38, 39]. In our experience, resection of the muscle and fascial elements was necessary in only two patients, but direct reconstruction without patching or grafting was possible.

Scar endometriosis recurred in one patient 12 months after surgery, but no correlation between this event and the surgical resection margin was found. The patient underwent surgical re-intervention with the local excision of the lesion, and is currently disease free after 2 years of follow-up.

Laparoscopy is considered by far the best aid in the diagnosis of pelvic endometriosis and to evaluate the extent of disease [38]. As pelvic localization is associated with scar endometriosis in only 24 % of cases [7], Seydel [5] suggested that, for this particular subset of patients, explorative laparoscopy should only be performed when associated symptoms are suggestive of pelvic extension. In our patients, preoperative ultrasound demonstrated features suggesting involvement of the peritoneal layer in two patients. Subsequent MRI revealed possible ovarian and peritoneal extension of the disease, leading us to choose a laparoscopic approach. In both patients, the abdominal exploration was negative for pelvic localization or extensive involvement of the peritoneal layer, confirming laparoscopy's superior diagnostic resolution over ultrasound or MRI imaging.

Conclusions

Abdominal scar endometriosis, a common condition in extrapelvic endometriosis, generally presents as a painful mass that may worsen pre or perimenstrually. The diagnosis is based on findings obtained from accurate history-taking and clinical examination. Medical therapy is often ineffective. Wide-margin excision with a free surgical margin of 1 cm is the treatment of choice to prevent recurrence. Laparoscopy may also be useful to exclude the synchronous intraperitoneal spread of the disease in symptomatic patients.

Conflict of interest None.

References

- 1 Moen MH, Muus KM. Endometriosis in pregnant and nonpregnant women at tubal sterilization. *Hum Reprod.* 1991;6: 699–702.
- 2 Lu PY, Ory SJ. Endometriosis: current management. *Mayo Clin Proc.* 1995;70:453–63.
- 3 Brenner C, Wohlgemuth S. Scar endometriosis. *Surg Gynecol Obstet.* 1990;170(6):538–40.
- 4 Rokitansky K. Ueber Uterusdrüsen-Neubildung. *Z Gesellschaft Aerzte (Wien).* 1860;16:577–81.
- 5 Seydel AS, Sickel JZ, Warner ED, Sax HC. Extrapelvic endometriosis: diagnosis and treatment. *Am J Surg.* 1996;171:239–41.
- 6 Williams TJ, Pratt JH. Endometriosis in 1000 consecutive celiotomies: incidence and management. *Am J Obstet Gynecol.* 1977;129(3):245–50.
- 7 Chatterjee SK. Scar endometriosis: a clinicopathologic study of 17 cases. *Obstet Gynecol.* 1980;56(1):81–4.
- 8 Singh KK, Lessels AM, Adam DJ, Jordan C, Miles WF, Macintyre IM, Greig JD. Presentation of endometriosis to general surgeon: a 10 years experience. *Br J Surg.* 1995;82:1349–51.
- 9 WilsonJR, Carrington ER, Ledger WJ. Endometriosis in obstetrics and gynecology. 7th ed. St Louis: The CV Mosby CO; 1983. p. 107–16.
- 10 Minaglia S, Mishell DR Jr, Ballare CA. Incisional endometriomas after caesarean: a case series. *J Reprod Med.* 2007;52:630–4.
- 11 Horton JD, Dezee KJ, Ahnfeldt EP. Abdominal wall endometriosis: a surgeon's perspective and review of 445 cases. *Am J Surg.* 2008;196:207–12.
12. Agarwal A, Fong YF. Cutaneous endometriosis. *Singapore Med J.* 2008;49(9):704–9.
- 13 Oosterlynck DJ, Cornillie FJ, Waer M, Vandeputte M, Koninckx PR. Women with endometriosis show a defect in natural killer activity resulting in a decreased cytotoxicity to autologous endometrium. *Fertil Steril.* 1991;56:45–51.
- 14 Wasfie T, Gomez E, Seon S, Zado B. Abdominal wall endometrioma after cesarean section: a preventable complication. *Int Surg.* 2002;87(3):175–7.
- 15 Witz CA. Current concepts in the pathogenesis of endometriosis. *Clin Obstet Gynecol.* 1999;42:566–85.
- 16 Bergqvist A. Different types of extragenital endometriosis: a review. *Gynecol Endocrinol.* 1993;7(3):207–21.

- 17 de Oliveira MA, de Leon AC, Freire EC, de Oliveira HC. Risk factors for abdominal scar endometriosis after obstetric hysterotomies: a case control study. *Acta Obstet Gynecol.* 2007;86: 73–80.
- 18 Gajjar KB, Mahendru AA, Khaled MA. Cesarean scar endometriosis presenting as an acute abdomen: a case report and review of literature. *Arch Gynecol Obstet.* 2008;277:167–9.
- 19 Steck WD, Helwig EB. Cutaneous endometriosis. *JAMA.* 1965; 191:101–4.
- 20 Bektas H, Bilsel Y, Sari YS, Ersoz F, Koc O, Deniz M, Boran B, Huq GE. Abdominal wall endometrioma; a 10-year experience and brief review of the Literature. *J Surg Res.* 2010;164:e77–81.
- 21 Nirula R, Greaney GC. Incisional endometriosis: an underappreciated diagnosis in general surgery. *J Am Coll Surg.* 2000; 190:404–7.
- 22 Hensen JH, Van Breda Vriesman AC, Puylaert JB. Abdominal wall endometriosis: clinical presentation and imaging features with emphasis on sonography. *AJR Am J Roentgenol.* 2006;186: 616–20.
- 23 Francica G, Giardiello C, Angelone G, Cristiano S, Finelli R, Tramontano G. Abdominal wall endometriomas near cesarean delivery scars: sonographic and color Doppler findings in a series of 12 patients. *J Ultrasound Med.* 2003;22(10):1041–7.
- 24 Amato M, Levitt R. Abdominal wall endometrioma: CT findings. *J Comput Assist Tomogr.* 1984;8:1213–4.
- 25 Balleyguier C, Chapron C, Chopin N, He´le´non O, Menu Y. Abdominal wall and surgical scar endometriosis. Results of magnetic resonance imaging. *Gynecol Obstet Invest.* 2003;55(4): 220–4.
- 26 Griffin JB, Betsill WL. Subcutaneous endometriosis diagnosed by fine needle aspiration cytology. *Acta Cytol.* 1985;29:584–8.
- 27 Madsen H, Hansen P, Andersen OP. Endometrioid carcinoma in an operation scar. *Acta Obstet Gynecol Scand.* 1980;59:475–6.
- 28 Leng J, Lang J, Guo L, Li H, Liu Z. Carcinosarcoma arising from atypical endometriosis in a caesarean section scar. *Int J Gynecol Cancer.* 2006;16(1):432–5.
- 29 Miller DM, Schouls JJ, Ehlen TG. Clear cell carcinoma arising in extragonadal endometriosis in a caesarean section scar during pregnancy. *Gynecol Oncol.* 1998;70:127–30.
- 30 Mol BW, Bayram N, Lijmer JG, Wiegerinck MA, Bongers MY, van der Veen F, Bossuyt PM. The performance of CA125 measurement in the detection of endometriosis: a meta-analysis. *Fertil Steril.* 1998;70:1101–8.
- 31 Rodgers AK, Falcone T. Treatment strategies for endometriosis. *Expert Opin Pharmacother.* 2008;9:243–55.

- 32 Rivlin ME, Das SK, Patel RB, Meeks GR. Leuprolide acetate in the management of cesarean scar endometriosis. *Obstet Gynecol.* 1995;85:838–9.
- 33 Heaps JM, Nieberg RK, Berek JS. Malignant neoplasm arising in endometriosis. *Obstet Gynaecol.* 1990;75:1023–8.
- 34 Honore GM. Extrapelvic endometriosis. *Clin Obstet Gynaecol.* 2009;42:699–711.
- 35 Frilas A, Soi A. Max M Abdominal incision endometriosis. *Am Surg.* 1954;60:259–61.
- 36 Patterson GK, Winburn GB. Abdominal wall endometriosis: report of 8 cases. *Am Surg.* 1999;65:36–9.
- 37 Purvis RS, Tying SK. Cutaneous and subcutaneous endometriosis Surgical and hormonal therapy. *J Dermatol Surg Oncol.* 1994;20:693–5.
- 38 Pretice A. Endometriosis. *BMJ.* 2001;323:93–5.
- 39 Blanco RG, Parithivel VS, Shah AK, Gumbs MA, Schein M, Gerst PH. Abdominal wall endometriomas. *Am J Surg.* 2003; 185(6):596–8.