

AperTO - Archivio Istituzionale Open Access dell'Università di Torino

TransAnal Minimally Invasive Surgery (TAMIS) with SILS™ Port versus Transanal Endoscopic Microsurgery (TEM): a comparative experimental study

This is the author's manuscript

Original Citation:

Availability:

This version is available <http://hdl.handle.net/2318/132078> since

Published version:

DOI:10.1007/s00464-013-2962-z

Terms of use:

Open Access

Anyone can freely access the full text of works made available as "Open Access". Works made available under a Creative Commons license can be used according to the terms and conditions of said license. Use of all other works requires consent of the right holder (author or publisher) if not exempted from copyright protection by the applicable law.

(Article begins on next page)



UNIVERSITÀ DEGLI STUDI DI TORINO

This is an author version of the contribution published on:

Questa è la versione dell'autore dell'opera:

[Surgical Endoscopy, 27(10), 2013, DOI:10.1007/s00464-013-2962-z]

ovvero [autore, volume, editore, anno, pagg.XXXX-XXXX]

The definitive version is available at:

La versione definitiva è disponibile alla URL:

<http://link.springer.com/article/10.1007%2Fs00464-013-2962-z>

TransAnal Minimally Invasive Surgery (TAMIS) with SILS™ Port versus Transanal Endoscopic Microsurgery (TEM): a comparative experimental study

Roberto Rimonda¹, Alberto Arezzo², Simone Arolfo², Alessandro Salvai² and Mario Morino²

(1)

Department of Surgery, ASLCN1, Mondovì (CN) Hospital, 12084 Mondovì, CN, Italy

(2)

Department of Surgical Sciences, University of Torino, Turin, Italy

Abstract

Background

TransAnal Minimally Invasive Surgery (TAMIS) has been proposed as an alternative to Transanal Endoscopic Microsurgery (TEM) for resection of benign polyps and early cancers of rectum. Since clinical application has begun in the absence of any experimental validation, we assessed its feasibility and efficacy *ex vivo* in a pilot study.

Methods

In a dedicated trainer box for transanal procedures, 10 surgeons with no experience in transanal surgery were asked to perform a dissection/suture task using both TAMIS and TEM in randomly allocated order. Surgeons were asked to dissect two identically drawn lesions of ~3 cm in larger diameter. Precision of dissection was assessed using a quantitative photographic method, while the time needed for dissection and suturing was considered a measure of quantitative evaluation. Each participant expressed a subjective opinion regarding difficulty with dissection, difficulty with suturing, vision quality, and conflict between instruments on a scale from 1 to 5.

Results

No difference was observed between the two techniques regarding the accuracy of dissection as the margin was interrupted along 4.1 % of the circumference in the TEM group compared with 2.48 % in the SILS group ($P = 0.271$). Dissection and suturing were significantly quicker in the TEM group [04:30 vs. 06:35 min ($P = 0.049$) and 14:34 versus 19:18 min ($P = 0.003$)]. In three cases in the SILS group, completing the suture was not considered possible, and the procedures were terminated by TEM. Subjective evaluation revealed a better appreciation of TEM in all proposed comparisons: dissection (2.6 vs. 3.5, $P = 0.004$), suturing difficulty (3.1 vs. 4.6, $P < 0.001$), quality of vision (2.3 vs. 2.8, $P = 0.18$), and instrument conflicts (3.1 vs. 4.0, $P = 0.054$).

Conclusions

In the *ex vivo* setting, both techniques were comparable for achieving a good dissection, although TAMIS failed to prove effective in suturing the rectal wall. Moreover, TEM was significantly quicker despite the small groups and was better appreciated by the surgeons.

Keywords

Transanal surgery Transanal endoscopic microsurgery Transanal mini-invasive surgery Transanal single-port surgery

Since its introduction in the early 1980 s by Gerhard Buess in Germany [[1](#), [2](#)], Transanal Endoscopic Microsurgery (TEM) has become the treatment of choice for benign lesions [[3](#), [4](#)] that are not amenable to flexible endoscopic excision and for early cancers [[5](#), [6](#)] throughout the rectum. In the era of minimally invasive surgery and natural orifice transluminal endoscopic surgery (NOTES), TEM represents the most common method for transluminal procedures with surgical access (SA-NOS) [[7](#)]. It has the advantages of minimally invasive local treatment with large full-thickness local resection and improved visualization.

However, several peculiarities have limited widespread adoption of TEM, including the need for specialized expensive instruments and a steep learning curve [[8](#)]. Recently, a new surgical technique has been proposed in literature, which combines single-port access with the principles of transanal excision. A confusing nomenclature for the technique, including different acronyms such

as TransAnal Mini-Invasive Surgery (TAMIS) [9, 10], Transanal Single-Port Microsurgery (TSPM) [11], Transanal Endoscopic Video-Assisted surgery (TEVA) [12], and SILSTEM [13], has been adopted. In all these procedures, a single-incision laparoscopic surgery port is introduced into the anal canal, followed by transanal excision using standard laparoscopic instruments. The supposed benefits of a cheaper technique induced the publication of several case series which reported technical feasibility and low morbidity.

To our knowledge there have been 13 case series reports (Table 1), involving 109 patients, in which this approach was utilized to excise rectal lesions. In these series the most commonly used device was the SILS™ Port (Covidien, Mansfield, MA, USA) and the procedures were performed with standard laparoscopic instrumentation. Criteria for the selection of patients included either benign or malignant polyps situated in the mid-rectum. The operative time, which was between 30 and 90 minutes, was considered acceptable, although procedures longer than 3 h were reported, and concern about feasibility of completing the procedure under SILS conditions was also reported [14, 15]. There were no major morbidities except for one case of bleeding, which was treated conservatively.

Table 1

TAMIS series reported in the literature

Authors	Year	No. cases	Diagnosis	Single-port device	Median distance from anal (range)	Operative time (range or SD) (min)	Morbidity
Atallah et al. [9]	2010	6	3AD, 2AC, 1 carcinoid	SILS™ Port	9.5 (6–13)	57.5 (43–192)	–
Lorenz et al. [11]	2010	3	1AD, 2AC	SILS™ Port	–	–	0 %
Khoo [20]	2010	1	AD	SILS™ Port	10	–	1/1 urinary retention
Dardamanis et al. [21]	2011	1	AD	SILS™ Port	9	45	0 %
Hayashi et al. [13]	2011	1	AC	SILS™ Port	8	140	0 %
Lorenz et al. [22]	2011	13	–	SILS™ Port–Tri Port™	–	–	0 %
Van der Boezem et al. [23]	2011	12	–	SILS™ Port	– 2 conversions	55 (40–80)	0 %
Lim et al. [10]	2012	16	4 NET, 11AC, 1 mucocele	SILS™ Port	7.5 (4–10)	85 (33–160)	0 %
Ragupathi et al. [12]	2012	20	14AD, 6AC	SILS™ Port	10.6	79.8 ± 25.1	0 %
Smith et al. [14]	2012	1	AC	SILS™ Port	7	–	0 %
Barendse et al. [18]	2012	13	7AD, 4AC, 1 carcinoid, 1 fibrosis	SSL™	–	57 ± 39	7.7 % bleeding

Authors	Year	No. cases	Diagnosis	Single-port device	Median distance from anal (range)	Operative time (range or SD) (min)	Morbidity
Carrara et al. [17]	2012	8	5AD, 3AC	Glove Port	6.5 (1.5–12)	–	0 %
Hompes et al. [15]	2012	14	8AD, 6AC	Glove Port	5 (2–10)	93 (30–120)	0 %

SILS™ Port (Covidien, Mansfield, MA); Tri-Port™ (Olympus America Inc, Center Valley, PA); SSL™ (Single Site Laparoscopic Access System, Ethicon Endo-Surgery, Cincinnati, OH)

AD adenoma, AC adenocarcinoma, NET neuroendocrine tumor, SD standard deviation

Nevertheless, despite the encouraging results from initial clinical experience, experimental proof of the safety and efficacy of the technique is still lacking and there are concerns about the stability of the surgical platform that have not been resolved yet. For these reasons, we believe that a serious preclinical assessment is mandatory and the present pilot study can be considered a first step in this direction. The aim of the experiment was to collect data from a direct comparison of TEM and TAMIS in simulated procedures in order to establish whether single-port access techniques in transanal surgery can really be considered without any increased risk to the patient affected by rectal neoplasms.

Materials and methods

A specially designed trainer box was developed for the purpose of the study at the Research and Training Center of the Department of Surgical Sciences of the University of Torino. On the base of the simulator for Transanal Endoscopic Operation (TEO®) surgery (Karl Storz Endoskope GmbH & Co. KG, Tuttlingen, Germany) there were two different settings for transanal microsurgery, simulating TEM and TAMIS procedures. In the first setting, a rectoscope for TEO® surgery was fixed to the box (Fig. 1), while in the second setting a SILS™ Port was introduced into the simulated anus (Fig. 2). Internally, a 30-cm-long double-layer polymeric bowel model (Limbs & Things, UK) representing a rectum was fastened to the surgical device. On the mid-part of each plastic bowel the shape of a polyp was drawn in almost identical fashion so that the procedure comprised a full-thickness excision of the “polyp” and suturing the resulting defect. The box was connected to a laparoscopic station complete with an analog camera/monitor system and a light source for laparoscopic surgery (Karl Storz Endoskope GmbH). Ten participants were selected. They were all senior residents and specialists with no experience in TEM procedures in order to avoid bias in the collection of data. Each one had to perform one procedure with each of the two settings. In the TAMIS group a second participant was involved to hold the camera.




Fig. 1
Simulator for Transanal Endoscopic Microsurgery (TEM)



Fig. 2
Simulator for TransAnal Minimally Invasive Surgery (TAMIS)

Dissection

The first part of the experiment consisted of excision of the rectal polyp with the two systems after randomization of the order of the procedures. The participants were asked to perform the exercise with particular attention paid to maintaining the integrity of the polyp and a 5-mm free margin all around as done for oncologic dissection. Time needed to finish was recorded and considered an objective evaluation of the level of difficulty of dissection. After finishing, a quantitative analysis was conducted using the photographs and a precise measure of accuracy was obtained.

Suture

The second part consisted of suturing the rectal defect similar to what is done in real procedures. The thread was fixed proximally and distally with laparoscopic clips to avoid the need for intra- or extracorporeal knots. The time needed was considered an objective quantitative parameter to assess the grade of difficulty of the surgical maneuver. A 30-min limit was set; if suturing was not

completed within 30 min, the procedure were considered a failure and had to be completed with the other technique to prove feasibility.

Subjective evaluation of participants

After conclusion of each procedure the participants were asked to give their personal opinion on four issues: (1) difficulty in dissection, (2) difficulty in suturing, (3) quality of vision, and (4) conflict between laparoscopic instruments during surgery. The assessments were made using a numeric scale from 1 (very good) to 5 (very bad).

End points

The efficacy of the final rectal suture was selected to be the primary end point of the study, defined as the ability to complete one or more running sutures with stitches <5 mm apart and <5 mm from the defect margin. Accuracy of dissection and procedural time were considered secondary end points as was the subjective opinion of the participants on different technical aspects. The χ^2 test for Boolean variables and Student's t test for paired groups were used for statistical analysis, for which significance was assessed as $P < 0.05$.

Results

The experiments were conducted at the Training Center of the Department of Surgical Sciences of the University of Torino between September and November 2012. Results are summarized in Table 2.

Table 2

Results of dissection and suture phases

Procedural order	TEM				TAMIS			
	Dissection			Suture	Dissection			Suture
	Polyp invasion (%)	Margin invasion (%)	Time (hh:mm:ss)	Time (hh:mm:ss)	Polyp invasion (%)	Margin invasion (%)	Time (hh:mm:ss)	Time (hh:mm:ss)
TEM-TAMIS	0	6.3	00:06:15	00:21:28	0	3.0	00:05:50	Not finished
TAMIS-TEM	0	0	00:05:55	00:18:50	0	0	00:07:49	Not finished
TAMIS-TEM	0	0	00:03:41	00:12:36	0	0	Not finished	00:26:40
TAMIS-TEM	0	5.6	00:04:01	00:12:32	0	2.7	00:05:49	Not finished
TEM-TAMIS	0	0	00:05:57	00:13:13	0	0	00:04:19	00:19:12
TEM-TAMIS	0	1.5	00:03:27	00:09:16	0	0.1	00:02:35	00:07:13
TEM-TAMIS	3.3	27.4	00:04:08	00:13:20	0	14.8	00:08:30	00:08:49
TAMIS-TEM	0	0	00:04:28	00:15:10	0	0.1	00:06:54	00:20:22

Procedural order	TEM				TAMIS			
	Dissection			Suture	Dissection			Suture
	Polyp invasion (%)	Margin invasion (%)	Time (hh:mm:ss)	Time (hh:mm:ss)	Polyp invasion (%)	Margin invasion (%)	Time (hh:mm:ss)	Time (hh:mm:ss)
TEM–TAMIS	0	0	00:03:40	00:09:23	0	0	00:04:02	00:17:01
TAMIS–TEM	0	0.2	00:03:28	00:04:52	1.7	4.3	Not finished	00:11:03
Mean		4.1	00:04:30	00:14:34		2.5	00:06:35	00:19:18
SD		±8.5	±0.01	±0.04		±4.6	±0.01	±0.01
P value		0.27	0.049	0.003				

SD standard deviation

The photographic analysis of the specimens and rectal tracts (Fig. 3) allowed us to see that the polyps were completely excised in all cases but one per each group. For statistical comparison, the percentage of polyp accidentally resected was quantified as 3.4 % with TEM versus 1.7 % with TAMIS (P = 0.34), where the percentage represents the amount of remnant polyp tissue. Similarly, the overall rate of interrupted margin was assessed with the same methodology, resulting in 4.10 % in the TEM group versus 2.49 % in the TAMIS group (P = 0.271). TEM scored a significantly shorter procedural time (04:30 vs. 06:35 min, P = 0.049).

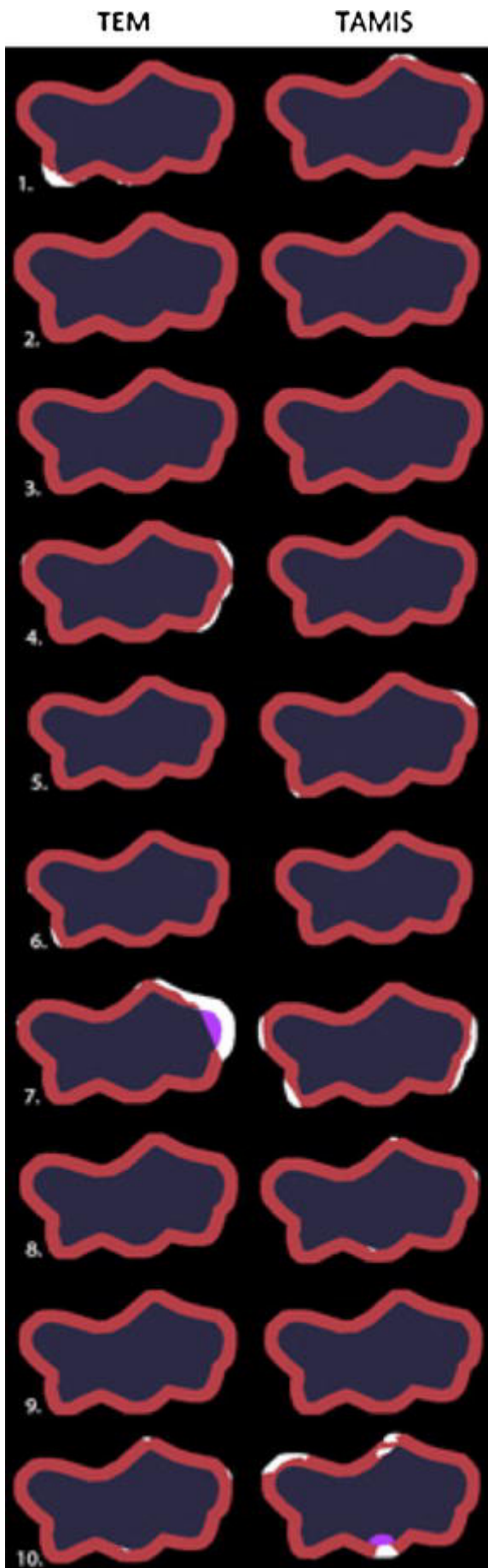


Fig. 3
Photographic analysis of dissected polyps. White area portion of interrupted margin

The suturing (Fig. 4) with TEM instrumentation was significantly quicker (14:34 vs. 19:18 min, $P = 0.003$). Suturing was completed in all cases in the TEM group, while it failed to be completed in three cases in the TAMIS group ($P < 0.001$). In these three cases the suture was successfully completed by TEM. This failure event occurred independent of the procedural sequence (Table 2).

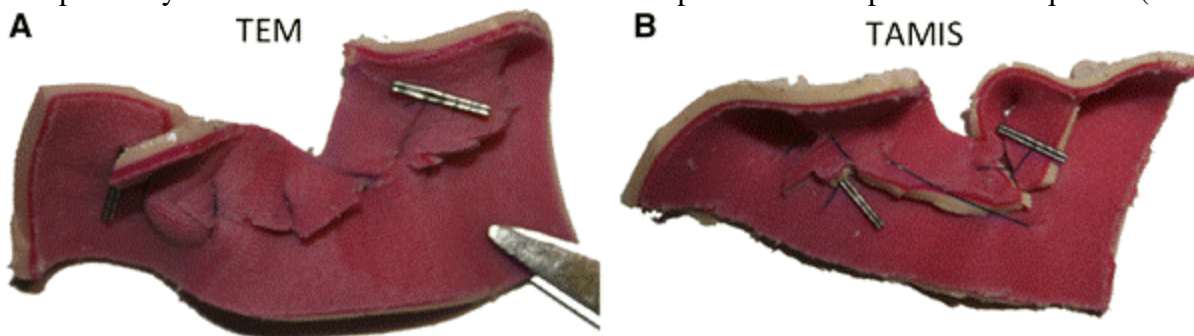


Fig. 4

Examples of suture of the defect on the bowel model A TEM, B TAMIS

The subjective opinion of the participants showed that they favored TEM in all fields of interest. TEM was preferred for dissection (2.6 TEM vs. 3.5 TAMIS, $P = 0.003$) and suture (3.1 TEM vs. 4.6 TAMIS, $P < 0.001$), better quality of vision (2.3 TEM vs. 2.8 TAMIS, $P = 0.18$), and minor instrument conflict (3.1 TEM vs. 4.0 TAMIS, $P = 0.05$).

Discussion

Since its introduction into clinical practice in 1983 by Gerhard Buess, TEM has progressively become the gold standard for treatment of benign polyps and early neoplasms in the extraperitoneal rectum. In the last 2 years, after the introduction of single-port laparoscopic surgery, an alternative surgical technique, usually referred to as TAMIS, has been proposed for transanal surgery. The new strategy is based on the transanal application of a single-site port and the consequent excision/suture of the rectal wall with standard laparoscopic instruments. The rationale of this new technique was a supposed reduction of TEM costs and challenges in order to extend indications for the transanal surgical endoscopic approach for rectal pathologies to those centers not equipped with a TEM armamentarium. The new method has been introduced into clinical management without proper validation. The purpose of the present study was to perform a pilot test on this topic.

For dissection, TAMIS appeared to be as effective and safe as TEM, with two polyp margins infiltrated, one per group, which shows that there is similar accuracy for both techniques. However, dissection took significantly longer under TAMIS conditions, showing a significantly higher level of difficulty, which supposedly correlates with a lower standard of safety, in contrast to what the published data suggest. The higher complexity was confirmed by participants, who preferred TEM not only because dissection was less difficult, with the difference being statistically significant, but also because of a trend toward better vision and reduced conflict between instruments.

The two procedures differ in several substantial aspects, including the need for a second surgeon on the TAMIS team to hold the camera, while TEM is a one-surgeon procedure with the rectoscope holding the optics in a fixed position and giving stable vision. If necessary, the operator can adjust the surgical field by pointing the rectoscope toward the target. From looking at the participants' comments, we found that while performing TAMIS the potential superiority offered by the free movement of the 30° scope turns into a disadvantage with an increased stumbling block effect and interference. Only when there is great coordination between two really experienced operators does this aspect decrease the influence on clinical practice but specific training is needed.

The most critical issue is suturing. Other authors recently reported difficulties in repairing the excision defect so that different methods have been proposed, including use of an endo-GIA stapler [9], intracorporeal suture-tying [11, 12], or interrupted sutures with extracorporeal knots that are secured with a knot-pusher [10]. In any case, the maneuver is very challenging and an ideal

technique has not been described yet. In the present study, an intracorporeal running suture secured by laparoscopic clips was realized in both groups in order to facilitate the maneuver as much as possible. Nevertheless, the suturing procedure appears difficult for different reasons. First, the clashing instruments forces the operator to repeatedly handle the needle and not always with success. Second, adequate tension on the suture is very difficult to maintain so that the repair of the rectal wall is suboptimal. In in vivo conditions these factors might result in a decrease in safety for the patient, and thus a higher morbidity rate, which would not be permissible. Compared to TEM, TAMIS took longer and had a consistent failure rate, as high as 30 %, requiring completion of the suturing with a different technique. This raises serious concern about the safety of the procedure. In fact, this only confirms what has already been reported [16, 17], forcing a center that performs TAMIS to also have TEM equipment, thus wiping out the advantage of TAMIS of reduced costs for instrumentation. This, in addition to the fact that TAMIS is a two-surgeon procedure, negates any argument in favor of TAMIS in terms of cost-effectiveness.

Since this study was a pilot experiment, we must note that it has some limitations and does not allow any definitive conclusion to be made on the feasibility of the procedure. The ex vivo setting and the low number of surgeons recruited imply a reduced statistical power of results; however, its strict reproducibility allowed us to obtain clear and comparable data. Also, the choice of a complex exercise instead of a baseline laparoscopic setup can be considered a limitation in the reproducibility of the results. However, it is justified by the aim of the study which was a realistic simulation of a transanal procedure. Even the choice of a unique single-site port (SILS™ Port) to be compared to TEM, even if justified by recent literature [18], is questionable and requires further investigation. Moreover, another important aspect of the procedure cannot be evaluated in a simulated context, i.e., the efficacy of port insertion into the anal canal and the adequate maintenance of pneumorectum. Finally, the ideal location of the polyp in the rectum has not been investigated enough, even if recent studies reported that TAMIS cannot reach neoplasms lower than 6 cm for anal verge for technical reasons [17].

On the other hand, it is obvious that small case series are not enough to demonstrate any evidence when introducing a novel technique. There are serious concerns that the conclusions of the published articles on TAMIS as a valid alternative to TEM are too optimistic. In fact, 30 years after its introduction into the clinical setting, TEM is not only the standard surgical treatment for benign polyps and early cancers of the rectum, it has also demonstrated several other features such as efficacy in achieving endoluminal circumferential resections up to complete colorectal procedures [19]. Until clinical trials on the topic are available and the safety of TAMIS is confirmed, TEM remains an unequaled tool for rectal surgeons.

In conclusion, the present study investigated, in a comparative trial, the results of an alternative technique to transanal endoscopic surgery, recently proposed, i.e., TAMIS. Despite several limitations related to the experimental setting, the research showed in the TAMIS group there was an increased level of difficulty and a higher failure rate, especially while suturing the rectal defect. Believing that these results may reflect a lower level of safety, we suggest caution in the application of TAMIS in clinical practice. In the era of technological innovation, the rapid development of newly conceived devices for single-site transanal surgery with specific and more efficient application is certainly desirable. Until this new generation of surgical devices is ready for clinical application, further experimental studies and clinical trials are mandatory to establish whether TAMIS can be an effective alternative to the TEM procedure.

References

1.

Buess G, Hutterer F, Theiss J, Böbel M, Isselhard W, Pichlmaier H (1984) A system for a transanal endoscopic rectum operation. *Chirurg* 55:677–680

2.
Buess G (1993) Transanal endoscopic microsurgery (TEM). *J R Coll Surg Edinb* 38:239–245
3.
Casadesus D (2009) Surgical resection of rectal adenoma: a rapid review. *World J Gastroenterol* 15:3844–3851
4.
Allaix ME, Arezzo A, Caldart M, Festa F, Morino M (2009) Transanal endoscopic microsurgery for rectal neoplasms: experience of 300 consecutive cases. *Dis Colon Rectum* 52:1831–1836
5.
Suppiah A, Maslekar S, Alabi A, Hartley JE, Monson JR (2008) Transanal endoscopic microsurgery in early rectal cancer: time for a trial? *Colorectal Dis* 10:314–327
6.
Bach SP, Hill J, Simson JN, Lane L, Merrie A, Warren B, Mortensen NJ, Association of Coloproctology of Great Britain and Ireland Transanal Endoscopic Microsurgery (TEM) Collaboration (2009) A predictive model for local recurrence after transanal endoscopic microsurgery for rectal cancer. *Br J Surg* 96:280–290
7.
Vettoretto N, Arezzo A (2010) Human natural orifice transluminal endoscopic surgery: on the way to two different philosophies? *Surg Endosc* 24:490–492
8.
Middleton PF, Sutherland LM, Maddern GJ (2005) Transanal endoscopic microsurgery: a systematic review. *Dis Colon Rectum* 48:270–284
9.
Atallah S, Albert M, Larach S (2010) Transanal minimally invasive surgery: a giant leap forward. *Surg Endosc* 24:2200–2205
10.
Lim SB, Seo SI, Lee JL, Kwak JY, Jang TY, Kim CW, Yoon YS, Yu CS, Kim JC (2012) Feasibility of transanal minimally invasive surgery for mid-rectal lesions. *Surg Endosc* 26:3127–3132
11.
Lorenz C, Nimmegern T, Back M, Langwieler TE (2010) Transanal single port microsurgery (TSPM) as a modified technique of transanal endoscopic microsurgery (TEM). *Surg Innov* 17:160–163
12.
Ragupathi M, Haas EM (2011) Trans-anal endoscopic video-assisted excision: application of single-port access. *JSLs* 15:53–58
13.
Hayashi S, Takayama T, Yamagata M, Matsuda M, Masuda H (2013) Single-incision laparoscopic surgery used to perform transanal endoscopic microsurgery (SILSTEM) for T1 rectal cancer under spinal anesthesia: report of a case. *Surg Today* 43(3):325–328
14.
Smith RA, Anaya DA, Albo D, Artinyan A (2012) A stepwise approach to transanal endoscopic microsurgery for rectal cancer using a single-incision laparoscopic port. *Ann Surg Oncol* 19:2859
15.
Hompes R, Ris F, Cunningham C, Mortensen NJ, Cahill RA (2012) Transanal glove port is a safe and cost-effective alternative for transanal endoscopic microsurgery. *Br J Surg* 99:1429–1435
16.
Barendse RM, Doornebosch P, Bemelman W, Fockens P, Dekker E, de Graaf E (2012) Transanal employment of single access ports is feasible for rectal surgery. *Ann Surg* 256:1030–1033

17.

Carrara A, Mangiola D, Motter M, Tirone A, Ghezzi G, Silvestri M, Zappalà O, Gasparetti F, Tirone G (2012) Glove port technique for transanal endoscopic microsurgery. *Int J Surg Oncol* 2012:438450

18.

Barendse RM, Doornebosch PG, Bemelman WA, Fockens P, Dekker E, de Graaf EJ (2012) Transanal single-port surgery: selecting a suitable access port in a porcine model. *Surg Innov* 19:323–326

19.

Whiteford MH, Denk PM, Swanström LL (2007) Feasibility of radical sigmoid colectomy performed as natural orifice transluminal endoscopic surgery (NOTES) using transanal endoscopic microsurgery. *Surg Endosc* 21:1870–1874

20.

Khoo RE (2010) Transanal excision of a rectal adenoma using single-access laparoscopic port. *Dis Colon Rectum* 53:1078–1079

21.

Dardamanis D, Theodorou D, Theodoropoulos G, Larentzakis A, Natoudi M, Doulami G, Zoumpouli C, Markogiannakis H, Katsaragakis S, Zografos G (2011) Transanal polypectomy using single incision laparoscopic instruments. *World J Gastrointest Surg* 3:56–58

22.

Lorenz C, Nimmesgern T, Langwieler TE (2011) Transanal endoscopic surgery using different single-port devices. *Surg Technol Int* 21:107–111

23.

Van den Boezem PB, Kruyt PM, Stommel MW, Tobon Morales R, Cuesta MA, Siestes C (2011) Transanal single-port surgery for the resection of large polyps. *Dig Surg* 28:412–416