

AperTO - Archivio Istituzionale Open Access dell'Università di Torino

Oncocytic Adrenocortical Tumors: Diagnostic Algorithm and Mitochondrial DNA Profile in 27 Cases.

This is the author's manuscript

Original Citation:

Availability:

This version is available <http://hdl.handle.net/2318/132955> since

Published version:

DOI:10.1097/PAS.0b013e31822da401

Terms of use:

Open Access

Anyone can freely access the full text of works made available as "Open Access". Works made available under a Creative Commons license can be used according to the terms and conditions of said license. Use of all other works requires consent of the right holder (author or publisher) if not exempted from copyright protection by the applicable law.

(Article begins on next page)



UNIVERSITÀ DEGLI STUDI DI TORINO

This is an author version of the contribution published on:

Questa è la versione dell'autore dell'opera:

*[American journal of surgical pathology, 35 (12), 2011, DOI
10.1097/PAS.0b013e31822da401]*

*ovvero [Duregon E, Volante M, Cappia S, Cuccurullo A, Bisceglia M, Wong DD,
Spagnolo DV, Szpak-Ulczok S, Bollito E, Daffara F, Berruti A, Terzolo M, Papotti
M., 35 (12), [Lippincott, Williams & Wilkins](#), 2011, pagg.1882-1893]*

The definitive version is available at:

La versione definitiva è disponibile alla URL:

[<http://journals.lww.com/ajsp/pages/articleviewer.aspx?year=2011&issue=12000&article=00016&type=abstract>]

**ONCOCYTIC ADRENOCORTICAL TUMORS:
DIAGNOSTIC ALGORITHM AND MITOCHONDRIAL DNA PROFILE IN 27 CASES**

Eleonora Duregon, MD, Marco Volante, MD, Susanna Cappia, BSc(Med), Alessandra Cuccurullo, PhD, Michele Bisceglia, MD,” Daniel D. Wong, BSc(Med), MBBS,# Dominic V. Spagnolo, MBBS, FRCPA,# Sylwia Szpak-Ulczok, MD,^ Enrico Bollito, MD, Fulvia Daffara, MD, Alfredo Berruti, MD,§ Massimo Terzolo, MD,* Mauro Papotti, MD.*

Divisions of Pathology, §Medical Oncology and *Internal Medicine of the Department of Clinical and Biological Sciences, University of Turin at San Luigi Hospital, Orbassano, Torino, Italy. “Department of Pathology, IRCCS Casa Sollievo della Sofferenza Hospital, San Giovanni Rotondo, Italy. #Department of Anatomical Pathology, PathWest Laboratory Medicine WA, Nedlands, Western Australia, Australia. ^Department of Nuclear Medicine and Oncological Endocrinology, Maria Sklodowska-Curie Memorial Cancer Center and Institute of Oncology, Gliwice, Poland

Running title: Oncocytic adrenocortical tumors

Work supported by grants from the Italian Ministry of University (PRIN, #20085P5SC49 to MT), the Italian Association for Cancer Research (AIRC, Milan, grant no. IG/10795/2010 to MP) and from the Regione Piemonte (Progetto Ricerca Sanitaria Finalizzata, D.G.R. n. 35-4231 dated 06.11.2006 to MV)

Address for correspondence:

Marco Volante, MD

Department of Clinical & Biological Sciences, University of Turin at San Luigi Hospital, Regione Gonzole 10, 10043 Orbassano, Torino, Italy

Phone +390116705464; fax +390116705432, email : marco.volante@unito.it

ABSTRACT

The pathological diagnosis of adrenocortical carcinoma (ACC) relies on microscopic features that are sometimes equivocal in special variants, including oncocytic adrenocortical tumors (OACT). We report a series of 27 unpublished OACT (15 pure, 12 mixed or focal) and assess for the first time in OACT the diagnostic use of an algorithm recently proposed by our group ("reticulin" algorithm) for conventional ACC, based on a combination of reticulin staining and assessment of only 3 Weiss parameters. Overall, 12 cases were malignant according to the Lin-Weiss-Bisceglia (L-W-B) system for pure and the original Weiss system for mixed or focal tumors; extensive or focal disruption of the reticulin network was found in 16/27 OACT, and was associated with either high mitotic index, presence of necrosis and/or vascular invasion in 14 of these, thus considered malignant according to our algorithm. From a clinical standpoint, OACT, at least in the pure forms are "low grade" lesions with low mean Weiss score, mitotic and Ki-67 indices, uncommon capsular or vascular invasion and generally pursue an indolent clinical course, even including unequivocal morphologically malignant cases. In addition, the 4977 bp mitochondrial DNA "common deletion" was detected using Real Time PCR in 54% of cases from the present and an additional validation series of 23 OACT, with a heterogeneous (heteroplasmic) intratissue and intracellular distribution, as detected by a modified FISH procedure, and a marked association with the presence of intact reticulin framework.

KEY WORDS: adrenal cancer, oncocytic variant, mitochondrial DNA, reticulin framework, classification.

INTRODUCTION

Adrenocortical carcinoma (ACC) is an extremely rare (less than two cases per million individuals per year) and highly aggressive malignant tumor of the adrenal gland (6) (18) (25)(61) (62). A large fraction of cases presents with metastatic disease at diagnosis and the behavior is unpredictable, even in cases that underwent radical surgery (6) (25) (61). Progressing or advanced cases may benefit from chemotherapy (5), including new protocols based on mitotane (56), or by multi-agent therapy (6) (26) (40) (54). Disease relapse is however a major problem in many cases and to date, only radical surgery offers some prospect for better disease control (10) (48). Molecular studies have identified several genes, either related to control of tumor cell growth (cyclin D, IGF2, β -catenin) or to other cell functions which are differentially regulated in ACC compared to adenomas (ACA) or borderline tumors. Most of these may play a role in malignant progression, but so far none has proven sufficiently specific or sensitive for diagnostic purposes (2) (22) (24) (25) (39) (50) (51).

Further, the correct classification of borderline adrenocortical tumors incompletely expressing the classical Weiss parameters is problematic and there is the concrete risk of over- or under-estimating the real biological potential of individual cases. In this respect, oncocytic adrenocortical tumors (OACT) represent the most challenging group, since some of the classical Weiss parameters, such as eosinophilic cytoplasm, nuclear atypia and diffuse growth are intrinsically present in the vast majority of these cases irrespective of their biological and clinical behavior. Therefore, the presently accepted cut-off value for malignancy, ie. Weiss score 3 (64) and subsequent modifications (3) may not be as accurate for OACT as in conventional ACC. In fact, at least a proportion of such cases would be overdiagnosed as carcinomas, since a Weiss score 3 is easily attained due to the innate morphology of OACT.

This issue has been extensively discussed in the literature (35) and alternative classification systems have been proposed, of which the Lin-Weiss-Bisceglia system (L-W-B) is nowadays the most widely accepted (11) (34) (35) (45) (65). The L-W-B system is a modified Weiss scoring system for OACT (7) (8) (35) (65) based on major and minor criteria to more accurately classify these tumours as either benign, of borderline malignant, or frankly malignant potential. There are still some controversies in regard to this group of tumors. One is the existence of a borderline diagnostic category which – according to some (35) - largely reflects the scarcity of clinical information relating to the biologic behaviour. A second is the issue of any clear cell component in such tumors, specifically its pathobiological and clinical significance (7) (8). Further, OACTs are very

uncommon, with an unknown incidence worldwide and with only a total of 110 cases recorded so far (65).

Recently, an algorithmic approach, the “reticulin” algorithm, was proposed for the diagnosis of conventional ACC (60), based on the combination of reticulin staining and three malignancy-related parameters (mitotic index, necrosis, vascular invasion), all of which had already been considered in the classical Weiss system, and none belonging to those intrinsically present in OACT, irrespective of their malignant potential. The performance of this algorithmic approach has never been tested specifically in OACT.

Moreover, the molecular features of OACT, namely the presence of cytogenetic or mitochondrial DNA (mtDNA) alterations reported in oncocytic tumors of other locations (21) (23) (36) (37) (42) (44) (55) (59), have never been investigated in OACT.

Therefore, the aims of this study were two-fold: i) to describe the clinicopathological features – including reticulin staining and the potential application of the newly proposed diagnostic algorithm - in an unpublished series of 27 adrenocortical tumors having more or less extensive oncocytic features; and ii) to determine the presence and tissue distribution of the most frequent mtDNA alteration, the 4977bp “common deletion”, examine its relationship to pathological and clinical parameters in individual tumors comprising these 27 cases, and to compare the findings to those in an external control series of OACT, most of which have been previously published (8) (65).

We show that OACTs represent an heterogeneous group of tumors with morphological features resembling those of oncocytic neoplasms of other locations, including the presence of the mtDNA 4977bp “common deletion”; and confirm OACT, in the pure form, as low grade tumors with a more indolent clinical course compared to conventional ACC.

MATERIALS AND METHODS

OACT Turin series (Table 1) – 194 consecutive adrenocortical tumors having a Weiss score ≥ 3 (63) (64) collected between 1990 and 2010 from the pathology files of the University of Turin, were reviewed independently by three of us (ED, MV, MP) using a mean of five haematoxylin and eosin (H&E)-stained slides per case (range 1-22). This series included 35 cases resected at San Luigi Hospital, 24 cases originally collected by one of us (MP) at the San Giovanni Hospital of Turin from 1993 to 2003 and 135 cases received in consultation from different hospitals. The majority of these patients were treated at our Institution, which serves as a referral center for adrenocortical carcinoma in Italy. The histopathological features of 92 conventional ACC and 14 cases of the

myxoid variant belonging to this data set have already been reported (47) (60). Moreover, a series of 116 ACA, all resected at San Luigi Hospital between 1994 and 2008, with paraffin material and follow up information available was also reviewed.

From this review, 27 cases were identified as OACT, of which, according to the criteria of Bisceglia *et al* (7), 15 were purely oncocytic (>90% oncocytes), while the remaining had a variable oncocytic component (30-80% oncocytes) combined with areas of conventional ACC or adenoma (10 were classified as mixed OACTs and 2 as focal OACT; **Table 2**). These 27 cases formed the basis of the current study. For all cases, the clinicopathological data (including information on treatment and outcome) were obtained and analysed. Six additional cases with oncocytic features accounting for <10% of the neoplasm were excluded. The study received ethical approval from the local Review Board of our Institution.

OACT validation series (Table 3) and control cases – With the aim of verifying the prevalence of the mtDNA “common deletion” (see below), a separate validation series of 23 OACT classified using the L-W-B scoring system (8) retrieved from the files of the Casa Sollievo della Sofferenza Hospital of San Giovanni Rotondo (Italy) and PathWest Laboratory Medicine WA (Australia) was also investigated. This series included 16 pure oncocytic, 4 mixed, and 3 focal OACT cases. The clinicopathological features of some of these tumors (#16 – 15 pure and 1 mixed OACTs) had been previously reported [cases B6-B9 and B23 (7) (8), and W1-W3, W5, W10-W16 (65)] and thus were not further considered in this study.

In addition, the mtDNA status was also investigated in a series of control cases including 18 normal adrenal glands obtained from nephrectomy specimens, 13 adrenocortical adenomas (none having oncocytic features with the exception of three showing <10% oncocytic changes) and 50 conventional ACC.

All the pathological material from the Turin, validation and control series was de-identified and coded by a pathology staff member not involved in the study prior to any type of analysis, to make all specimens anonymous to the investigators.

Immunohistochemistry and histochemistry – Five µm thick paraffin sections serial to those used for conventional H&E staining were obtained for immunohistochemical and reticulin stains from one or two representative tissue blocks of all cases. The following antibodies were employed: melan A (DakoCytomation, Glostrup, Denmark; clone A103, diluted 1/50), alpha-inhibin (Diamedix, Miami, Florida; clone R1, diluted 1/75) and Ki-67 (Dako, clone MIB-1, diluted 1/150). A biotin-free, dextran chain-based detection system (EnVysion, Dako) was used according to a standard

protocol and using diaminobenzidine as the chromogen. Reticulin histochemical staining was performed to define the status of the reticulin framework using a commercially available silver impregnation-based kit (Bio Optica, Milan, Italy). Disruption of the reticulin/basal membrane network was defined as the loss of continuity of the reticular fibre network evaluated at high magnification (400x) in more or less extensive tumor areas, as previously described (60).

Mitochondrial DNA deletion screening by PCR – Molecular analysis was performed in all but five cases lacking informative material from the residual paraffin embedded tissue. Total DNA of OACT cases was obtained from macrodissected oncocytic areas by scraping five 10 µm-thick dewaxed sections into an Eppendorf tube using a sterile scalpel blade. A DNA extraction kit (QIAamp DNA Mini kit, Qiagen srl Italy, Milan, Italy) was used to isolate the DNA according to the manufacturer's recommendations. PCR primers used to detect a range of mtDNA deletions in the deletion-prone region (P1 and P2) and a mtDNA conserved sequence (P3 and P4) are listed in **Table 4**. PCR was performed using Maxima Hot Start Polymerase (Fermentas, Part of ThermoFisher Scientific, Waltham, MA, USA) and EvaGreen Dye, 20X in water (Biotium, Hayward, CA, USA) on the Rotor-Gene Q (Qiagen) apparatus. The cycling conditions were as follows: one cycle at 95°C for 5 minutes; 40 cycles at 95°C for 60 seconds, 56°C for 30 seconds, 72°C for 90 seconds; 1 cycle at 72°C for 7 minutes; 5 cycles of fluorescence acquisition at 60°C; and one melt ramp from 65°C to 95°C. Whereas P3 and P4 primers generated the specific PCR product in all cases, samples with wild type mtDNA were not amplifiable using P1 and P2 primers that yielded the specific 380 bp PCR product only in the presence of the mtDNA common deletion.

Mitochondrial DNA fluorescent in situ hybridization (FISH) analysis - FISH analysis was performed in all cases analyzed by means of PCR. To assess the mtDNA status, a two-color FISH procedure was performed as follows. Probes specific for both the deletion-prone and the rarely deleted regions of mtDNA were generated by means of PCR using a Long Template PCR System (Roche, Mannheim, Germany) according to the manufacturer's recommendations, using total DNA extracted from human umbilical cord fibroblasts. Primer sequences for FISH are listed in **Table 4**. The first probe ('COM') bound to mtDNA at a rarely deleted region, and the second probe ('DEL') bound in the vicinity of the deletion-prone region. PCR products were purified in Quantum Prep PCR Kleen Spin Columns (Bio-Rad Lab, Hercules, CA, USA) and 1 µg was labeled with digoxigenin (COM probe) or biotin (DEL probe) using a nick-translation labeling kit (Roche). The probes were tested prior to use on cultured human fibroblasts. FISH experiments were carried out on dewaxed 5 µm-thick sections according to Lewis *et al.* (36) and van de Corput *et al.* (58), with minor modifications. Slides were pretreated in a pressure cooker for five minutes at 125°C,

followed by a 10 second step at 90°C using citrate buffer (pH 6). They were then digested with 0.1% (w/v) pepsin (Sigma, Steinheim, Germany) for 20 minutes at 37°C. RNase A digestion (0.1 mg/ml in PBS, Sigma) followed for one hour at 37°C, subsequently blocked in PBS. Finally, the sections were fixed in 1% formaldehyde in PBS for 20 minutes at room temperature, dehydrated in 70%, 90% and 100% ethanols and air-dried. Both the digoxigenin-labeled COM and the biotinylated DEL probes were diluted in equal amount to a final concentration of 5 ng/μl in LSI/WCP Hybridization Buffer (Abbott Molecular, Des Plaines, IL, USA), then applied to sections and covered with a glass coverslip sealed with rubber cement. Negative control sections included omission of the probe from the hybridization mixture. Target DNA and probe were denatured simultaneously on an 80°C hot plate for five minutes and then incubated overnight at 37°C in a ThermoBrite System (Abbot Molecular, Des Plaines, IL, USA). Coverslips were carefully removed and slides were washed three times for five minutes each in 2X SSC and three times for 10 minutes each in TNT [100 mM Tris±HCl, 150 mM NaCl (pH 7.5), 0.05% Tween-20] at 45°C. Prior to probe detection, slides were incubated with a blocking solution (0.5% bovine serum albumin in 4X SSC) for 45 minutes at 37°C. The slides were then incubated simultaneously with anti-digoxigenin-fluorescein Fab fragments (Roche, Mannheim, Germany) diluted 1/250, and with Streptavidin Alexa Fluor 594 (Molecular Probes, Invitrogen, Eugene, OR, USA) diluted 1/200 in blocking buffer, for 45 min at 37°C. Finally, sections were washed three times (10 minutes each) in TNT, dehydrated in 70%, 90% and 100% ethanols, air-dried and counterstained with DAPI (Abbott Molecular, Des Plaines, IL, USA). Sections were analysed using an Olympus BX61 fluorescence microscope and images were captured using the Cytovision 4.02 software package (Olympus Italia srl, Milan, Italy). Using this detection system, the green fluorescent probe (COM) bound all mtDNA molecules, whilst the red fluorescent probe (DEL) bound the deletion-prone region of mtDNA only in the absence of the deletion. Therefore, wild type mtDNA was defined by the presence of distinct yellow fluorescent dots or a ratio 1:1 of green and red dots, whereas the presence of an excess (at least 2:1 ratio) of green dots indicated the occurrence of the mtDNA deletion.

Statistical analysis – Clinical and pathological variables were compared to mtDNA status and patient outcome by Fisher's exact or Chi-square and Student's t tests. A level of $p < 0.05$ was considered statistically significant. All data were analyzed with STATISTICA for Windows software version 6.1 (StatSoft Italia, Vigonza, Padova, Italy).

RESULTS

Clinicopathological data of OACT Turin series.

The 27 OACTs affected 7 males and 20 females, with a median age of 48 years (range 28-68). The tumors were located in the right adrenal gland in 10 cases and in the left gland in 16, while in the remaining case the location was not reported. The hormonal status was known for all patients, of whom a functioning tumor was found in 13 (48%). Cortisol production was the most common event (eight patients), aldosteron production was observed in two cases, hypertension was present in two cases and androgen secretion in the remaining case (**Table 1**). Adjuvant mitotane treatment was administered in five patients who subsequently showed no disease progression, whilst first line chemotherapy (EDP protocol or mitotane alone) (6) was employed in four further cases at the time of disease progression.

The tumors were generally large, with a mean diameter of 10 cm (range 1.6 to 23 cm). The mean weight of the 20 tumors for which this information was available was 141,5 gms (range 8–1300). The neoplastic oncocytes were similar in all cases, meeting their definition as cells with homogeneously deeply eosinophilic and granular cytoplasm. They had frequently atypical or bizarre nuclei with prominent nucleoli (Fuhrman grade 3 or 4), and eosinophilic nuclear pseudoinclusions were common. Since these Turin cases exhibited a more or less extensive population of oncocytes, two subgroups could be identified.

Pure OACT (15 cases). This main subgroup included OACTs (cases #1 to 15) in which oncocytes accounted for more than 90% of the tumor area (**Figure 1**). The tumor cells were arranged predominantly or entirely in a diffuse, “patternless pattern”, with trabecular, alveolar, and microcystic areas occasionally observed as a minor component. A variable cell size was observed, with 4/15 cases (cases 8, 9, 12, 13) being composed predominantly of small oncocytes. These cells had a deeply eosinophilic cytoplasm, but a reduced volume and small, centrally located, mildly atypical nuclei. Bizarre multinucleated giant cells, patchy mononuclear inflammatory cell infiltrates and fibromyxoid stroma were occasionally observed. One tumor was associated with a myelolipomatous component. Additional pathological parameters included necrosis in seven, whereas mitotic index was $<5/50\text{HPF}$ in 14 cases and only in one case (# 15) there was a relatively high mitotic count (15/50 HPF) with atypical mitotic figures. Invasion of vessels and/or capsule was a feature of five and three cases, respectively. As a result, based on the proposed L-W-B system for OACT (which excludes the so-called “definitional criteria” of the classical Weiss parameters), a diagnosis of malignancy was confirmed in six tumors only. These all manifested ≥ 1 of the “major criteria” of the L-W-B system (mitotic rate $> 5/50\text{HPF}$, atypical mitoses and venous invasion). The remaining cases were classified eight as OACT of UMP, since one or more “minor criteria”

(necrosis, capsular invasion, sinusoidal invasion, diameter >10 cm and/or weight >200 gms) only were identified, and one benign case. Five of the UMP cases defined by L-W-B were benign using the “reticulin” algorithm (see below).

Mixed and Focal OACT (12 cases). This second subgroup included 12 cases (#16 to 27), in which oncocytes constituted 30-80% of the tumor area. The cytoarchitectural features of the oncocytic component were comparable to the pure OACT. The oncocytic cell population was either separate from, or intermingled with the non-oncocytic component (**Figure 1e**). At variance with pure OACT cases, a prevalence of medium-small sized oncocytes was observed. The non-oncocytic cell population was composed of pleomorphic atypical cells having a diffuse growth pattern, as seen in conventional ACC. Since the L-W-B system was originally devised for pure OACT only and could not be applied to this mixed/focal oncocytic tumor subgroup, we applied the classical Weiss scoring system here, that recognized six benign and six malignant cases. Using the “reticulin” algorithm, 7 cases were scored benign and the remaining 5 were qualified as malignant (see below).

Immunohistochemical and histochemical features

Immunoprofile and Tumor Proliferation Fraction - All tumors in this series shared the expression of at least one of the more reliable markers of the adrenal cortex, namely melan A and alpha-inhibin. The mean Ki-67 proliferation index was 5.6% in the subgroup of pure OACT (range 1% - 20%), with mean values of 1% for the benign case, 2% for borderline tumors and 6.5% for malignant ones, while among mixed/focal OACTs it was 6.8% (range 1-40%), being 1.3% for benign and 12.3% for malignant cases.

Evaluation of reticulin framework and application of the “reticulin” diagnostic algorithm - As recently reported by our group (60), a histochemical stain for reticulin was performed in each case. This demonstrated disruption of the stromal framework in 16/27 (11/15 pure and 5/12 mixed) OACT cases of the Turin series, and in 19/23 (15/16 pure and 4/7 mixed and focal) cases of the validation cohort (**Table 1 and 3**). The reticulin disruption was either focal (13 cases) or extensive. In mixed/focal OACT, disruption of the reticulin network was more evident in conventional (non-oncocytic) carcinoma components, whereas an intact reticulin framework, if present, was mostly recognized in the oncocytic component (**Figure 1**).

An intact reticulin framework in the present series was observed in 11 cases (4 pure OACT, 7 mixed OACT), all composed of large sized oncocytes. Three out of four pure OACT with intact reticulin framework were classified as being of UMP by L-W-B criteria but as benign according to the “reticulin” algorithm. In addition, one mixed OACT was classified as malignant by the classical

Weiss scoring system and benign by the “reticulin” algorithm. Thus, all cases with intact reticulin were benign by the “reticulin” algorithm, and indeed, this finding was associated to a non-malignant condition in our cases. However, it should be noted that in this series of OACT, apparently at variance with conventional ACC, some malignant cases had only focal reticulin disruption that might be under-estimated or missed in single sections. Using the reticulin stain as an inclusion criterion of the “reticulin” algorithm in the Turin series only, 13 cases (6 pure and 7 mixed OACT) were categorized as benign and 14 as malignant (disrupted reticulin framework together with at least one of the following criteria: necrosis, high mitotic rate and vascular invasion). Two cases with reticulin disruption but lacking any of the additional criteria for malignancy were classified as benign (**Table 1**).

Mitochondrial DNA alterations

Prevalence of mtDNA “common deletion” as detected by PCR. The presence of the mtDNA “common deletion” was successfully analysed by means of real-time PCR in OACT cases having informative tissue available. In the Turin series, it was present in 12/22 cases (54%), including 6/13 pure and 6/9 mixed cases (**Figure 2**). A similar positive proportion was observed in the validation cohort: 8/23 cases (35%), including 5/16 pure and 3/7 mixed (2) or focal (1) tumors. Overall in the two series, according to the L-W-B classification for pure OACT or the Weiss system for the mixed and focal OACT, the mtDNA deletion was found in 15 benign or UMP cases and only 5 malignant OACT. When compared to the reticulin staining, 12/14 cases (86%) with intact reticulin framework had the mtDNA common deletion, whereas a lower proportion of the reticulin-disrupted cases harboured the deletion (8/31, 26%); the difference was statistically significant (Fisher’s test $p=0.0003$). In control cases of non-oncocytic adrenal tissues/tumors, the mtDNA common deletion was detected in 4/18 normal adrenal, 5/13 adrenocortical adenomas, but in none of 50 conventional ACC.

Tissue patterns and distribution of mtDNA “common deletion” by means of FISH. FISH analysis was performed in all PCR-tested cases, and the results were reliable in all but seven cases (mostly due to poor tissue preservation). There was 100% concordance between an altered FISH pattern and the PCR detection of the mtDNA common deletion (**Figure 2**). The tissue and cellular distribution of such mtDNA alterations were not present uniformly in all tumor cells in any individual case. Rather, the alteration was limited to only a fraction of neoplastic cells in the majority of cases (intratissue heteroplasmy), nor was it present in all mitochondria of deletion-bearing oncocytes (intracellular heteroplasmy). Interestingly, the presence of intracellular heteroplasmy was more

commonly associated with a diagnosis of “malignancy”, whereas all 11 cases with intracellular homoplasmy were classified as benign or UMP, according to the L-W-B criteria.

Correlation of OACT classification and mtDNA alterations with clinical outcome

Follow-up data were available for all 27 cases in the Turin series. Although the number of cases is too small for survival analysis, the disease status was compared using the alternate classification systems (to test their ability to identify cases following a clinically malignant behavior), as well as with reticulin staining alone and with the presence of the mtDNA “common deletion”. Two clinically aggressive cases were classified as being of UMP, rather than malignant, using the L-W-B proposal for OACT classification. When the reticulin stain alone or the “reticulin” algorithm were applied, a specificity of 57% and 62% were observed, respectively, but both methods were 100% sensitive in identifying cases with recurrence or disease-related deaths. A statistical correlation between the reticulin algorithm and the L-W-B system could not be performed due to possible selection bias and small sample size. However the “reticulin” algorithm, which was initially proposed for conventional ACC (60), appeared to be diagnostically applicable also in the oncocytic group of adrenocortical lesions. By contrast, the presence of the mtDNA “common deletion” was not invariably associated with a more favourable clinical outcome, also having been detected in a single patient who died of disease 20 months after diagnosis.

DISCUSSION

In the present paper, we reviewed the pathological features of an unpublished series of 27 adrenocortical tumors the large majority having more or less extensive oncocytic features, and confirmed the diagnostic value of reticulin staining and of a diagnostic algorithm recently proposed by our group (60) in distinguishing clinically malignant from benign OACT. In addition, we traced the mitochondrial DNA deletion commonly described in oncocytic tumors of other organs in a proportion of OACT, mostly in cases with an intact reticulin framework, although rare clinically aggressive cases also bore the deletion.

Diagnostic features of OACT. A large series of 194 ACC and 116 ACA was reviewed to search for oncocytic features, and 27 cases (approximately 10% of the whole series) met the classic morphological criteria for the diagnosis of oncocytic tumors of other organs (4) (12), and adrenal gland, in particular (7) (8) (35) (65).

These include a tumor cell population of large cells with eosinophilic and granular cytoplasm, generally showing a diffuse growth pattern and high grade nuclear atypia (7) (8) (35) (65). By

definition (pure) OACT were composed (almost) exclusively (>90%) of oncocytic cells; however a minor proportion of cases (12 of 20 in the Turin series and 7 of 23 in the validation group) showed a variable component of (non-oncocytic) adrenocortical clear tumor cells (mixed OACT and focal OACT). Interestingly, a number of cases, all pure OACT, were composed of predominantly small cells, an occurrence which had been already observed (8) (65), and that, in contrast to the findings reported in poorly differentiated oncocytic carcinomas of the thyroid gland (46), did not predict for a different behavior in the OACT. Further unusual findings were: i. the presence of stromal myxoid foci, which were seen in a single case of the Turin series though not to the extent to allow their classification as the OACT counterpart of the myxoid variant of conventional ACC (47); ii. the presence of a myelolipomatous component in a case of pure OACT. Both fibromyxoid stromal foci and a lipomatous component in pure OACT were also described in the validation series (65).

The definition of malignancy in OACT is problematic if the classical Weiss criteria are applied for classification, as first suspected by Lin *et al* (38). In fact, 20/27 cases from the Turin series, having significant numbers of cells with eosinophilic cytoplasm, nuclear atypia and diffuse growth (“definitional criteria” (7) (8)), achieved the minimal Weiss score 3 for a diagnosis of malignancy, thus suggesting a risk of overestimating potential malignancy in the OACT tumor group if the Weiss scoring system is employed as a diagnostic tool. Therefore, following our recent proposal of a newly designed algorithm for the diagnosis of conventional ACC (60), we tested its diagnostic usefulness in the group of OACT. The recognition of the presence of a disrupted reticulin network together with the presence of any of 3 clear-cut morphological signs of malignancy (high mitotic index, necrosis and vascular invasion) was able to segregate clinically benign from malignant cases with optimal performance, with no cases in the “benign” group following an aggressive course included, provided that an accurate search for even focal reticulin disruption was performed. Indeed, while in conventional adrenocortical tumors, all malignant (i.e. Weiss score ≥ 3) cases had disrupted reticulin framework (60), in OACT the reticulin pattern was more heterogeneous, possibly due to the association with (residual?) low grade “oncocytoma” areas in a fraction of cases. Reticulin distribution pattern or loss in OACT (both pure, mixed, and focal) likely deserves the same attention pathologists devote when they examine difficult or equivocal tumoral hepatocellular lesions. Thus a careful search for even focal reticulin disruption is necessary in more than one paraffin block, before reliably excluding any reticulin alteration. Notably, in the mixed and focal OACT, reticulin disruption was more evident in conventional ACC areas, whereas in some cases the oncocytic component showed a preserved reticulin framework. In any case, this simplified algorithmic approach has the advantage of reducing the evaluation of multiple Weiss parameters,

which in OACT are either not applicable (“definitional criteria” according to the L-W-B scheme), or may be of equivocal and/or subjective definition (such as sinusoidal and capsular invasion).

Apart from these practical diagnostic considerations, it should be stressed that pure OACT are “low grade” lesions, with a low mean Weiss score, frequent preservation of the reticulin network, low mitotic and Ki67 proliferation indices, and uncommon capsular or vascular invasion. Even considering unequivocally morphologically malignant cases only, most tumors followed an indolent clinical course. Although a direct comparison with conventional ACC was not possible due to the limited number of OACT cases, a better outcome was observed, with only three of 14 pure OACT in our series developing recurrence or metastases (though in 2 cases follow-up is still short, <24 months). These outcomes approximate those of “oncocytomas” of some other organs (kidney and salivary gland) which generally follow an indolent course and are in any case associated with a lower grade than their conventional carcinoma counterparts. These data are in accordance with the previous study of Wong et al (65) who provided the first preliminary statistical evidence of an improved prognosis of malignant OACT as compared to conventional ACC (overall median survival of 58 months versus 14-32 months).

By contrast, whether mixed and focal OACT share the same favorable behaviour remains to be proven, though we strongly suspect this will not be the case. In our very limited data set of 5 malignant cases with follow-up (all from Turin; range 16-165 months) 3 patients died of disease within 20-97 months, two of whom died in less than 24 months.

Prevalence of mitochondrial DNA “common deletion” in OACT. The identification of pathological and clinical similarities with oncocytic tumors of other organs led us to question whether OACT may also display molecular abnormalities in the mitochondrial DNA. We focused on the analysis of the presence of the mtDNA 4977 bp “common deletion” by means of two alternative methods, a PCR based technique and a FISH procedure to establish the cell and tissue localization of the molecular changes. The “common deletion” is the most common somatic mtDNA abnormality detected in oncocytic tumors of various organs (37) (42) (59). It occurs between two 13-bp direct repeats (at positions 13447–13459 and 8470–8482) of the human mtDNA. This portion of mtDNA encompasses five tRNA genes and seven genes encoding subunits of cytochrome c oxidase, complex I and ATPases (53). By means of PCR, the mtDNA “common deletion” was detected in approximately 50% of cases, both in the Turin cases and in the external validation cases. Interestingly, such mtDNA alteration was slightly more prevalent in pure OACT and in cases classified as benign or of UMP, according to both the L-W-B classification and the “reticulin” algorithm, but, although these findings are of potential pathogenetic interest, to date the analysis of the presence of the mtDNA “common deletion” has no practical diagnostic value.

Further, to answer the question whether the “common deletion” of mtDNA was a feature of all cells of individual oncocytic tumors (as a result of a “clonal” event) or an heterogeneous event, FISH analysis was performed with probes specific for the preserved (green) and the deleted regions (red), as previously described in the Warthin tumor model of salivary glands (36). The concordance between PCR and FISH methods was 100%. There was a relatively high degree of intercellular and intracellular heteroplasmy, with the deletion being detected in some, but not other tumor areas, and heterogeneously within single tumor cells in most cases. This observation probably indicates that this feature is not clonally transmitted to all neoplastic cells and probably represents an early change in the mtDNA which is maintained in a subpopulation of oncocytes only, and likely has no role in malignant progression. Rather, it could act as a tumor suppression mutation (17). In support of this hypothesis, the same mtDNA alteration was detected at a comparable rate in control cases of normal adrenal cortex and adrenocortical adenoma, but not in conventional ACC. It should be noted that such mtDNA deletion is not specific for oncocytic tumors, but has also been reported in normal tissues and in several pathological conditions not specifically associated with an oncocytic phenotype, including non-neoplastic (9) (14) (15) (19) (27) (28) (30) (31) (41) (49) (66) and neoplastic conditions (13) (1) (16)(20) (29) (32) (33) (43) (52) (57).

In conclusion, a) OACT represent an heterogeneous group of tumors with morphological features resembling those of oncocytic neoplasms of other locations; b) the “reticulin” diagnostic algorithm seems to well recognize clinically aggressive cases and to overcome the risk of under-estimating malignancy in this tumor group; c) malignant OACT, especially in their pure form, are low grade tumors with a more indolent clinical course as compared to conventional ACC; d) the mitochondrial DNA “common deletion” described in other oncocytic human tumors is also present in a fraction of OACT (approximately 50%); e) such mtDNA alteration is also present in normal adrenal cortex and in adrenocortical adenomas, but has never been identified in conventional ACC.

REFERENCES

1. Abnet CC, Huppi K, Carrera A, et al. Control region mutations and the 'common deletion' are frequent in the mitochondrial DNA of patients with esophageal squamous cell carcinoma. *BMC Cancer*. 2004;4:30.
2. Assie G, Guillaud-Bataille M, Ragazzon B, et al. The pathophysiology, diagnosis and prognosis of adrenocortical tumors revisited by transcriptome analyses. *Trends Endocrinol Metab*. 2010;21:325-334.
3. Aubert S, Wacrenier A, Leroy X, et al. Weiss system revisited: a clinicopathologic and immunohistochemical study of 49 adrenocortical tumors. *Am J Surg Pathol*. 2002;26:1612-1619.
4. Baloch ZW, LiVolsi VA. Oncocytic lesions of the neuroendocrine system. *Semin Diagn Pathol*. 1999;16:190-199.
5. Berruti A, Fassnacht M, Baudin E, et al. Adjuvant therapy in patients with adrenocortical carcinoma: a position of an international panel. *J Clin Oncol*. 2010;28:e401-402; author reply e403.
6. Berruti A, Terzolo M, Sperone P, et al. Etoposide, doxorubicin and cisplatin plus mitotane in the treatment of advanced adrenocortical carcinoma: a large prospective phase II trial. *Endocr Relat Cancer*. 2005;12:657-666.
7. Bisceglia M, Ben-Dor D, Pasquinelli G. Oncocytic adrenocortical tumors. *Pathology Case Reviews*. 2005;10:228-242.
8. Bisceglia M, Ludovico O, Di Mattia A, et al. Adrenocortical oncocytic tumors: report of 10 cases and review of the literature. *Int J Surg Pathol*. 2004;12:231-243.
9. Botto N, Berti S, Manfredi S, et al. Detection of mtDNA with 4977 bp deletion in blood cells and atherosclerotic lesions of patients with coronary artery disease. *Mutat Res*. 2005;570:81-88.
10. Brix D, Allolio B, Fenske W, et al. Laparoscopic versus open adrenalectomy for adrenocortical carcinoma: surgical and oncologic outcome in 152 patients. *Eur Urol*. 2010;58:609-615.
11. Cham E, Watkin W, Goldschmidt R, et al. Fine needle aspiration cytology of adrenocortical oncocytic neoplasm: a case report. *Acta Cytol*. 2010;54:627-634.
12. Chang A, Harawi SJ. Oncocytes, oncocytosis, and oncocytic tumors. *Pathol Annu*. 1992;27 Pt 1:263-304.
13. Chen T, He J, Shen L, et al. The mitochondrial DNA 4,977-bp deletion and its implication in copy number alteration in colorectal cancer. *BMC Med Genet*. 2011;12:8.

14. Cortopassi GA, Arnheim N. Detection of a specific mitochondrial DNA deletion in tissues of older humans. *Nucleic Acids Res.* 1990;18:6927-6933.
15. Cortopassi GA, Shibata D, Soong NW, et al. A pattern of accumulation of a somatic deletion of mitochondrial DNA in aging human tissues. *Proc Natl Acad Sci U S A.* 1992;89:7370-7374.
16. Dai JG, Xiao YB, Min JX, et al. Mitochondrial DNA 4977 BP deletion mutations in lung carcinoma. *Indian J Cancer.* 2006;43:20-25.
17. Dani SU, Dani MA, Simpson AJ. The common mitochondrial DNA deletion delmtDNA(4977): shedding new light to the concept of a tumor suppressor mutation. *Med Hypotheses.* 2003;61:60-63.
18. Fassnacht M, Libe R, Kroiss M, et al. Adrenocortical carcinoma: a clinician's update. *Nat Rev Endocrinol.* 2011.
19. Fuke S, Kametani M, Kato T. Quantitative analysis of the 4977-bp common deletion of mitochondrial DNA in postmortem frontal cortex from patients with bipolar disorder and schizophrenia. *Neurosci Lett.* 2008;439:173-177.
20. Futyma K, Putowski L, Cybulski M, et al. The prevalence of mtDNA4977 deletion in primary human endometrial carcinomas and matched control samples. *Oncol Rep.* 2008;20:683-688.
21. Gasparre G, Porcelli AM, Bonora E, et al. Disruptive mitochondrial DNA mutations in complex I subunits are markers of oncocyctic phenotype in thyroid tumors. *Proc Natl Acad Sci U S A.* 2007;104:9001-9006.
22. Gaujoux S, Grabar S, Fassnacht M, et al. beta-catenin activation is associated with specific clinical and pathologic characteristics and a poor outcome in adrenocortical carcinoma. *Clin Cancer Res.* 2011;17:328-336.
23. Geyer FC, de Biase D, Lambros MB, et al. Genomic profiling of mitochondrion-rich breast carcinoma: chromosomal changes may be relevant for mitochondria accumulation and tumour biology. *Breast Cancer Res Treat.* 2011.
24. Giordano TJ, Kuick R, Else T, et al. Molecular classification and prognostication of adrenocortical tumors by transcriptome profiling. *Clin Cancer Res.* 2009;15:668-676.
25. Giordano TJ, Thomas DG, Kuick R, et al. Distinct transcriptional profiles of adrenocortical tumors uncovered by DNA microarray analysis. *Am J Pathol.* 2003;162:521-531.
26. Hermsen IG, Fassnacht M, Terzolo M, et al. Plasma Concentrations of o,p'DDD, o,p'DDA, and o,p'DDE as predictors of tumor response to mitotane in adrenocortical carcinoma: results of a retrospective ENS@T Multicenter Study. *J Clin Endocrinol Metab.* 2011.

27. Holt IJ, Harding AE, Cooper JM, et al. Mitochondrial myopathies: clinical and biochemical features of 30 patients with major deletions of muscle mitochondrial DNA. *Ann Neurol.* 1989;26:699-708.
28. Holt IJ, Harding AE, Morgan-Hughes JA. Deletions of muscle mitochondrial DNA in patients with mitochondrial myopathies. *Nature.* 1988;331:717-719.
29. Hubbard K, Steinberg ML, Hill H, et al. Mitochondrial DNA deletions in skin from melanoma patients. *Ethn Dis.* 2008;18:S2-38-43.
30. Ieremiadou F, Rodakis GC. Correlation of the 4977 bp mitochondrial DNA deletion with human sperm dysfunction. *BMC Res Notes.* 2009;2:18.
31. Iwai K, Miyao M, Wadano Y, et al. Dynamic changes of deleted mitochondrial DNA in human leucocytes after endurance exercise. *Eur J Appl Physiol.* 2003;88:515-519.
32. Kamalidehghan B, Houshmand M, Ismail P, et al. Delta mtDNA4977 is more common in non-tumoral cells from gastric cancer sample. *Arch Med Res.* 2006;37:730-735.
33. Kamenisch Y, Wenz J, Metzler G, et al. The mitochondrial DNA common deletion is present in most basal and squamous cell carcinoma samples isolated by laser capture microdissection but generally at reduced rather than increased levels. *J Invest Dermatol.* 2007;127:486-490.
34. Lack E. Adrenal cortical carcinoma. Tumours of the adrenal gland and paraganglia. . In: Silverberg S, ed. *AFIP Atlas of Tumor Pathology, Series 4* Washington DC: Armed Forces Institute of Pathology; 2007:131-155.
35. Lau SK, Weiss LM. The Weiss system for evaluating adrenocortical neoplasms: 25 years later. *Hum Pathol.* 2009;40:757-768.
36. Lewis PD, Baxter P, Paul Griffiths A, et al. Detection of damage to the mitochondrial genome in the oncocytic cells of Warthin's tumour. *J Pathol.* 2000;191:274-281.
37. Lewis PD, Fradley SR, Griffiths AP, et al. Mitochondrial DNA mutations in the parotid gland of cigarette smokers and non-smokers. *Mutat Res.* 2002;518:47-54.
38. Lin BT, Bonsib SM, Mierau GW, et al. Oncocytic adrenocortical neoplasms: a report of seven cases and review of the literature. *Am J Surg Pathol.* 1998;22:603-614.
39. Lombardi CP, Raffaelli M, Pani G, et al. Gene expression profiling of adrenal cortical tumors by cDNA macroarray analysis. Results of a preliminary study. *Biomed Pharmacother.* 2006;60:186-190.
40. Malandrino P, Al Ghuzlan A, Castaing M, et al. Prognostic markers of survival after combined mitotane- and platinum-based chemotherapy in metastatic adrenocortical carcinoma. *Endocr Relat Cancer.* 2010;17:797-807.

41. Markaryan A, Nelson EG, Hinojosa R. Quantification of the mitochondrial DNA common deletion in presbycusis. *Laryngoscope*. 2009;119:1184-1189.
42. Maximo V, Soares P, Lima J, et al. Mitochondrial DNA somatic mutations (point mutations and large deletions) and mitochondrial DNA variants in human thyroid pathology: a study with emphasis on Hurthle cell tumors. *Am J Pathol*. 2002;160:1857-1865.
43. Maximo V, Soares P, Seruca R, et al. Microsatellite instability, mitochondrial DNA large deletions, and mitochondrial DNA mutations in gastric carcinoma. *Genes Chromosomes Cancer*. 2001;32:136-143.
44. Maximo V, Sobrinho-Simoes M. Mitochondrial DNA 'common' deletion in Hurthle cell lesions of the thyroid. *J Pathol*. 2000;192:561-562.
45. Ohtake H, Kawamura H, Matsuzaki M, et al. Oncocytic adrenocortical carcinoma. *Ann Diagn Pathol*. 2010;14:204-208.
46. Papotti M, Torchio B, Grassi L, et al. Poorly differentiated oxyphilic (Hurthle cell) carcinomas of the thyroid. *Am J Surg Pathol*. 1996;20:686-694.
47. Papotti M, Volante M, Duregon E, et al. Adrenocortical tumors with myxoid features: a distinct morphologic and phenotypical variant exhibiting malignant behavior. *Am J Surg Pathol*. 2010;34:973-983.
48. Porpiglia F, Fiori C, Daffara F, et al. Retrospective evaluation of the outcome of open versus laparoscopic adrenalectomy for stage I and II adrenocortical cancer. *Eur Urol*. 2010;57:873-878.
49. Ro LS, Lai SL, Chen CM, et al. Deleted 4977-bp mitochondrial DNA mutation is associated with sporadic amyotrophic lateral sclerosis: a hospital-based case-control study. *Muscle Nerve*. 2003;28:737-743.
50. Ronchi CL, Sbiera S, Kraus L, et al. Expression of excision repair cross complementing group 1 and prognosis in adrenocortical carcinoma patients treated with platinum-based chemotherapy. *Endocr Relat Cancer*. 2009;16:907-918.
51. Sbiera S, Schull S, Assie G, et al. High diagnostic and prognostic value of steroidogenic factor-1 expression in adrenal tumors. *J Clin Endocrinol Metab*. 2010;95:E161-171.
52. Shao JY, Li YH, Gao HY, et al. High frequency of common deletion (4981 bp) in mitochondrial DNA in nasopharyngeal carcinoma and its correlation with patient age and clinical stages. *Cancer Biol Ther*. 2004;3:1270-1274.
53. Shen L, Fang H, Chen T, et al. Evaluating mitochondrial DNA in cancer occurrence and development. *Ann N Y Acad Sci*. 2010;1201:26-33.

54. Sperone P, Ferrero A, Daffara F, et al. Gemcitabine plus metronomic 5-fluorouracil or capecitabine as a second-/third-line chemotherapy in advanced adrenocortical carcinoma: a multicenter phase II study. *Endocr Relat Cancer*. 2010;17:445-453.
55. Tallini G, Hsueh A, Liu S, et al. Frequent chromosomal DNA unbalance in thyroid oncocytic (Hurthle cell) neoplasms detected by comparative genomic hybridization. *Lab Invest*. 1999;79:547-555.
56. Terzolo M, Angeli A, Fassnacht M, et al. Adjuvant mitotane treatment for adrenocortical carcinoma. *N Engl J Med*. 2007;356:2372-2380.
57. Tseng LM, Yin PH, Tsai YF, et al. Association between mitochondrial DNA 4,977 bp deletion and NAD(P)H:quinone oxidoreductase 1 C609T polymorphism in human breast tissues. *Oncol Rep*. 2009;21:1169-1174.
58. van de Corput MP, van den Ouweland JM, Dirks RW, et al. Detection of mitochondrial DNA deletions in human skin fibroblasts of patients with Pearson's syndrome by two-color fluorescence in situ hybridization. *J Histochem Cytochem*. 1997;45:55-61.
59. Vivekanandan P, Daniel H, Yeh MM, et al. Mitochondrial mutations in hepatocellular carcinomas and fibrolamellar carcinomas. *Mod Pathol*. 2010;23:790-798.
60. Volante M, Bollito E, Sperone P, et al. Clinicopathological study of a series of 92 adrenocortical carcinomas: from a proposal of simplified diagnostic algorithm to prognostic stratification. *Histopathology*. 2009;55:535-543.
61. Volante M, Buttigliero C, Greco E, et al. Pathological and molecular features of adrenocortical carcinoma: an update. *J Clin Pathol*. 2008;61:787-793.
62. Weiss LM, Bertagna X, Chrousos GP. Adrenal Cortical Carcinoma. In: DeLellis RA, Lloyd RV, Heitz PU, eds. *World Health Organization Classification of Tumors, Pathology and Genetics, Tumors of Endocrine Organs*. Lyon: IARC Press 2004:139-142.
63. Weiss LM. Comparative histologic study of 43 metastasizing and nonmetastasizing adrenocortical tumors. *Am J Surg Pathol*. 1984;8:163-169.
64. Weiss LM, Medeiros LJ, Vickery AL, Jr. Pathologic features of prognostic significance in adrenocortical carcinoma. *Am J Surg Pathol*. 1989;13:202-206.
65. Wong DD, Spagnolo DV, Bisceglia M, et al. Oncocytic adrenocortical neoplasms - a clinicopathologic study of 13 new cases emphasizing the importance of their recognition. *Hum Pathol*. 2011.
66. Zhang J, Montine TJ, Smith MA, et al. The mitochondrial common deletion in Parkinson's disease and related movement disorders. *Parkinsonism Relat Disord*. 2002;8:165-170.

LEGENDS FOR FIGURES

FIGURE 1. Oncocytic adrenocortical tumors (OACT). (A, B, case #4) Pure form with homogeneous growth of large atypical cells. In a serial section (B), the reticulin framework appears entirely preserved. The tumor has a low proliferative index (1%, inset). This case was scored as UMP according to Lin-Weiss-Bisceglia (L-W-B) classification. A malignant OACT according to L-W-B is shown in C and D (case #13), where a diffuse growth of medium/small sized oncocytes (C) is associated with a reticulin network disruption (D). The proliferative index was 10% (C, inset). In mixed OACT (E, F, case #22) two cell populations coexist, with oncocytic cells (E, bottom left) having a very low proliferative index (E, inset bottom left) adjacent to conventional carcinoma areas (E, top right) with a proliferative index up to 40% (E inset, top right). These two components have a different reticulin framework pattern, appearing intact in oncocytic areas (F, bottom left) and disrupted in conventional carcinomas ones (F, top right). In pure OACTs, either classical, large, granular oncocytes (G case #4) or small, mildly atypical oncocytes (H, case #13) can be observed. [Hematoxylin & Eosin, original magnification 200x in A, C, E; 400x in G, H. Insets: immunoperoxidase for Ki67; original magnification 400x in A, C; 200x in E. Histochemical reticulin stain, original magnification 200x in B, D, F].

FIGURE 2. Assessment of the mitochondrial DNA (mtDNA) 4977 bp “common deletion” in oncocytic adrenocortical tumors. In A and B a non deleted case is shown (case #10), while in C and D, an example of mtDNA deletion is represented (case #4). By PCR, P3 and P4 primers against a mtDNA conserved region generated the specific PCR product (green curve) in both cases (A, C) while P1 and P2 primers yielded the specific 380 bp PCR product (red curve) only in the presence of the mtDNA “common deletion” (C) [see also Materials and Methods]. By FISH analysis, the green fluorescent probe (COM) bound all mtDNA molecules, whilst the red fluorescent probe (DEL) bound the deletion-prone region of mtDNA only in the absence of the deletion. A prevalence of distinct yellow fluorescent dots corresponding to a 1:1 ratio of green and red dots (B) confirmed the presence of normal mtDNA, whereas the excess (at least 2:1 ratio) of green dots (D) confirmed the occurrence of the 4977 bp “common deletion”.

Table 1. Clinico-pathologic and mitochondrial DNA alterations in 27 OACT.

	Sex/ Age	Hormone production	Location/ Weight (gr) Size (cm)	Oncocytic area (%)	Classification System	Reticulin stain	Reticulin Algorithm	PCR mtDNA deletion	FISH mtDNA pattern	Follow up (mos)
Pure OACT					LWB classification					
1	F/45	contisol	L/9/3	>90	benign	intact	ACA	YES	deleted	NED 36
2	F/47	not funct	R/30/ 3	>90	UMP	intact	ACA	NO	normal	NED 72
3	F/45	not funct	R/ NA/ 5.5	>90	UMP	intact	ACA	YES	deleted	NED 24
4	F/45	not funct	R/NA/ 4	>90	UMP	intact	ACA	YES	deleted	NED 36
5	F/61	androgens	L/1252/ 17	>90	UMP	disrupted	ACA	YES	deleted	alive 60
6	F/49	not funct	L/400/13	>90	UMP	disrupted§	ACA	NO	normal	alive 124
7	F/61	not funct	L/400/12	>90	UMP	disrupted§	ACC (necrosis)	YES	deleted	NED 165
8	F/41	not funct	L/NA/ 11	>90 ^	UMP	disrupted	ACC (necrosis)	NO	normal	AWD 72
9	F/42	not funct	L/530/16	>90 ^	UMP	disrupted	ACC (necrosis)	NO	na	DOD 15
10	F/31	hypertens.	L/255/ 9.5	>90	malignant	disrupted§	ACC (venous invasion)	NO	normal	alive 113
11	M/60	not funct	L/8/ 1.6	>90	malignant	disrupted§	ACC (mitoses)	NO	normal	NED 48
12	F/68	not funct	R/NA/ 17	>90 ^	malignant	disrupted§	ACC (necrosis, venous invasion)	NO	normal	NED 36
13	F/66	not funct	NA	>90 ^	malignant	disrupted	ACC (necrosis, venous invasion)	YES	deleted	NED 11
14	M/46	not funct	L/950/18	>90	malignant	disrupted	ACC (necrosis, venous invasion)	nd	nd	NED 4
15	M/32	not funct	R/NA/ 23	>90	malignant	disrupted	ACC (necrosis, mitoses , venous invasion)	nd	nd	DOD 24
Mixed / Focal OACT					Classical WSS					
16	F/53	hypertens	L/135/8	60	benign	intact	ACA	YES	deleted	NED 108
17	F/66	aldosteron	R/52/5	60	benign	intact	ACA	YES	deleted	NED 72
18	M/50	cortisol	L/18/4	50	benign	intact	ACA	YES	deleted	NED 92
19	F/55	cortisol	R/86/11	50	benign	intact	ACA	NO	normal	NED 55
20	F/37	cortisol	L/7.3/2.8	50	benign	intact	ACA	YES	deleted	NED 47
21	F/40	aldosteron	R/10/4	30	benign	intact	ACA	YES	deleted	NED 43
22	F/44	cortisol	R/NA/ 8	60	malignant	disrupted	ACC (necrosis)	NO	normal	DOD 90
23	M/35	not funct	L/40/8	50	malignant	intact	ACA	nd	nd	NED 60
24	F/67	cortisol	L/1050/15	60	malignant	disrupted	ACC (necrosis, venous invasion)	NO	normal	NED 156
25	M/44	cortisol	R/1300/20	40	malignant	disrupted	ACC (necrosis, venous invasion)	YES	deleted	DOD 20
26	F/46	not funct	L/270/ 9.9	70	malignant	disrupted	ACC (necrosis, mitoses , venous invasion)	nd	nd	NED 64
27	M/28	cortisol	L/210/11	80	malignant	disrupted	ACC (necrosis, mitoses , venous invasion)	nd	nd	DOD 23

Abbreviations: M: male, F: female; not funct: non functioning; hypertens: hypertension; L: left; R: right; NA: not available; LWB: classification for pure OACT according to Lin-Weiss-Bisceglia; WSS:Weiss scoring system. UMP: uncertain malignant potential; ACC: adrenocortical carcinoma;

ACA: adrenocortical adenoma; mtDNA: mitochondrial DNA; nd: not done; na: not adequate; mos: months; NED: no evidence of disease; AWD: alive with disease; DOD: died of disease. ^: small size oncocytes predominant; §: focal reticulin disruption

Table 2. Selection criteria of currently investigated OACT, according to the proposed classification system (7) (8) (65)

Composition	Pure OACT (%)	Mixed OACT (%)	Focal OACT (%)	(Pure) Conventional ACT (%)*
Oncocytic	> 90	50 - 90	10 - <50	< 10
Clear cell	< 10	10 - < 50	50 - 90	> 90

Abbreviations: ACT: Adrenocortical tumor; OACT: Oncocytic adrenocortical tumor
*: excluded from the study

Table 3. Validation cohort of 23 OACT investigated for reticulin status and mitochondrial DNA alterations.

	Classification System	Oncocytic area (%)	Reticulin stain	PCR mtDNA deletion	FISH mtDNA pattern
<u>Pure OACT</u>	LWB classification				
W1	benign	>90	disrupted	NO	na
W2	benign	>90	disrupted §	YES	deleted
W3	UMP	>90	intact	YES	na
W4	UMP	>90	disrupted §	NO	na
W5	UMP	>90	disrupted §	YES	deleted
B6	UMP	>90	disrupted	NO	normal
B7	malignant	>90	disrupted*	NO*	na
B8	malignant	>90	disrupted	NO	normal
B9	malignant	>90	disrupted §	NO	na
W10	malignant	>90	disrupted*	NO*	normal
W11	malignant	>90	disrupted	YES	deleted
W12	malignant	>90	disrupted	NO	normal
W13	malignant	>90	disrupted	NO	normal
W14	malignant	>90	disrupted	NO	normal
W15	malignant	>90	disrupted*	YES*	deleted
W16	malignant	>90	disrupted §*	NO*	normal
<u>Mixed / Focal OACT</u>	Classical WSS				
W17	benign	60	intact	YES	deleted
W18	benign	10	intact	YES	deleted
W19	malignant	60	intact	YES	deleted
W20	malignant	60	disrupted §	NO	normal
W21	malignant	70	disrupted	NO	normal
W22	malignant	40	disrupted	NO	na
B23	malignant	75	disrupted	NO	normal

Abbreviations: LWB: classification for pure OACT according to Lin-Weiss-Bisceglia; UMP: uncertain malignant potential; mtDNA: mitochondrial DNA; na: not adequate; WSS: Weiss scoring system.

*: In these cases, tissue from recurrence (B7, W10, W16) and metastasis (W15) was also tested with similar results as in the primary tumor, except for mtDNA detection of case W15 which was restricted to the primary;

§: focal reticulin disruption.

Table 4. PCR primers [mtDNA accession number NC-012920]

Detection of mtDNA common deletion by means of PCR

P1	nucleotides	8286-8305	5'-TCTAGAGCCCCTGTAAAG-3'
P2	nucleotides	13662-13643	5'-GTTAGTAAGGGTGGGGAAGC-3'
P3	nucleotides	4504-4526	5'-CCATCTTTGCAGGCACACTCATC-3'
P4	nucleotides	4955-4977	5'-ATCCACCTCAACTGCCTGCTATG-3'

Primers for the generation of FISH probes

COM	probe	forward	nucleotides	13972-13949	5'-CCTATCTAGGCCTTCTTACGAGCC-3'
COM	probe	reverse	nucleotides	4468-4440	5'-AGTACGGGAAGGGTATAACCAACATTTTC-3'
DEL	probe	forward	nucleotides	8848-8873	5'-TTATGAGCGGGCACAGTGATTATAGG-3'
DEL	probe	reverse	nucleotides	12864-12839	5'-ACGGTTGTATAGGATTGCTTGAATGG-3'

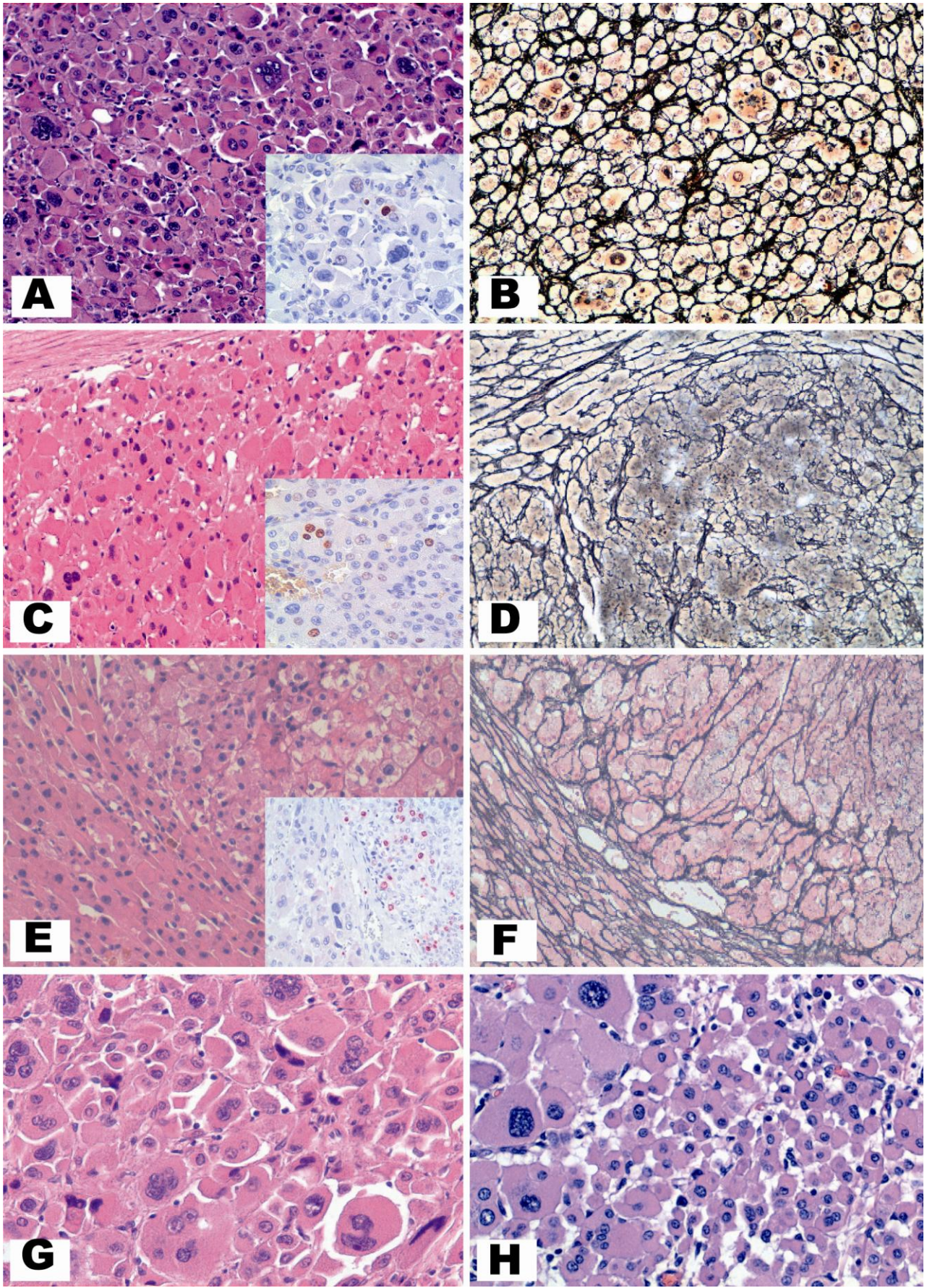


FIGURE 1

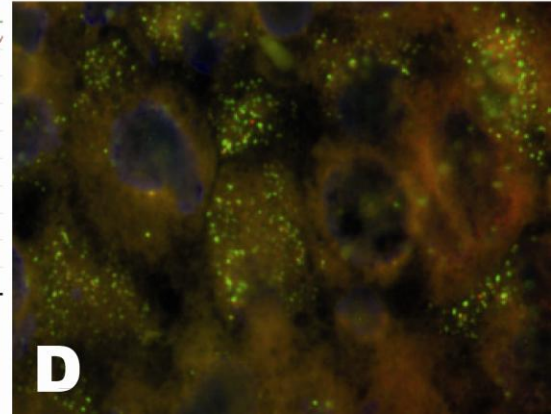
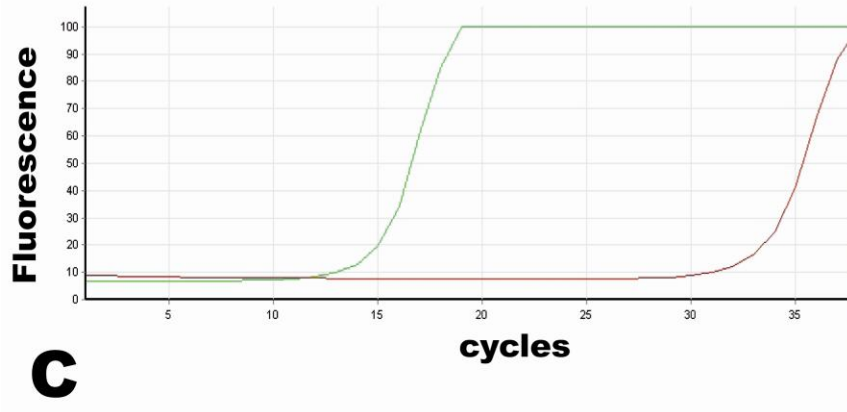
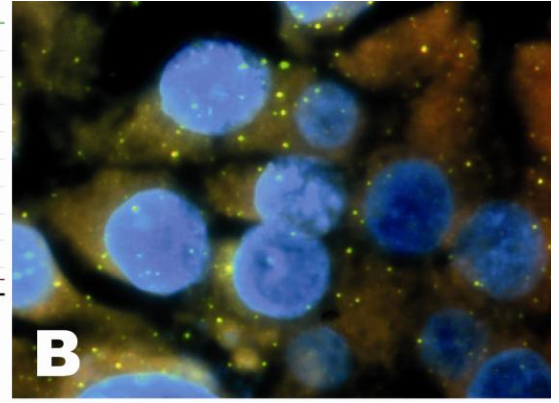
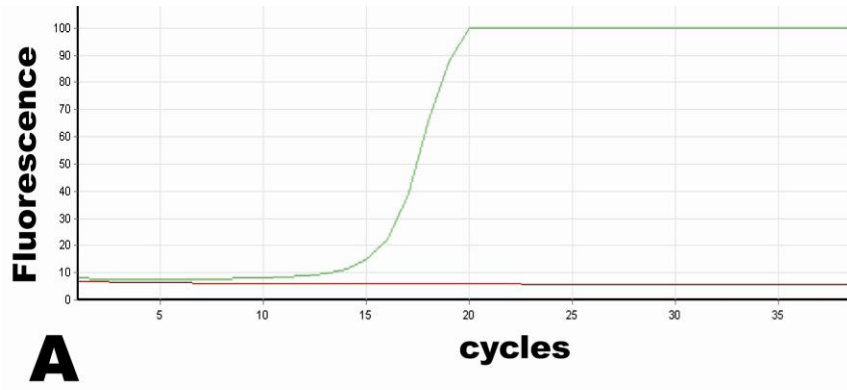


FIGURE 2