

AperTO - Archivio Istituzionale Open Access dell'Università di Torino

Soft tissue changes after maxillo-mandibular advancement in OSAS patients: a three-dimensional study.

This is a pre print version of the following article:

Original Citation:

Availability:

This version is available <http://hdl.handle.net/2318/134461> since

Published version:

DOI:10.1016/j.jcms.2013.02.004

Terms of use:

Open Access

Anyone can freely access the full text of works made available as "Open Access". Works made available under a Creative Commons license can be used according to the terms and conditions of said license. Use of all other works requires consent of the right holder (author or publisher) if not exempted from copyright protection by the applicable law.

(Article begins on next page)



UNIVERSITÀ DEGLI STUDI DI TORINO

This Accepted Author Manuscript (AAM) is copyrighted and published by Elsevier. It is posted here by agreement between Elsevier and the University of Turin. Changes resulting from the publishing process - such as editing, corrections, structural formatting, and other quality control mechanisms - may not be reflected in this version of the text. The definitive version of the text was subsequently published in:

[Journal of cranio-maxillo-facial surgery, Volume 42, Issue 1, January 2014, DOI: 10.1016/j.jcms.2013.02.004]

You may download, copy and otherwise use the AAM for non-commercial purposes provided that your license is limited by the following restrictions:

(1) You may use this AAM for non-commercial purposes only under the terms of the CC-BY-NC-ND license.

(2) The integrity of the work and identification of the author, copyright owner, and publisher must be preserved in any copy.

(3) You must attribute this AAM in the following format: Creative Commons BY-NC-ND license (<http://creativecommons.org/licenses/by-nc-nd/4.0/deed.en>), [+ Digital Object Identifier link to the published journal article on Elsevier's ScienceDirect® platform]

**SOFT TISSUE CHANGES AFTER MAXILLO-MANDIBULAR ADVANCEMENT
IN OSAS PATIENTS: A THREE-DIMENSIONAL STUDY.**

Giovanni Gerbino MD, DDS^a, Francesca Antonella Bianchi, MD^a, Laura Verze', MD^b, and
Guglielmo Ramieri, MD, DDS^a.

^a Division of Maxillofacial Surgery (Head: Prof. S. Berrone, MD, DDS), Department of
Head and Neck Surgery, San Giovanni Battista Hospital, University of Turin, Turin, Italy.

^b Department of Anatomy, Pharmacology and Legal Medicine, (Head:) University
of Turin, Turin, Italy.

Corresponding Author:

Giovanni Gerbino, Corso A.M. Dogliotti 14, 10126 - Torino - Italy

Phone / Fax: +39116335125

e-mail: giovanni.gerbino@unito.it

SUMMARY

Introduction: Maxillo-mandibular advancement (MMA) is the most successful surgical treatment for OSAS. This study prospectively evaluated soft tissue changes in typical OSAS patient before and after MMA.

Material and Methods: Ten patients with severe OSAS, who underwent MMA, were considered. Age, BMI, polysomnographic recordings and cephalometric data were examined. Facial surface data acquired using a 3D laser scanner before (T0) and one year (T1) after surgery were pooled by electronic surface averaging to obtain the mean T0 and T1 facial model. A virtual optimal face (V) was used as control group. Mean T0, T1 and V models were compared.

Results: The mean AHI improved from 69.8 ± 35.2 to 17.3 ± 16.7 . The mean maxillary advancement was $9.2 \text{ mm} \pm 1.2$ and the mean mandibular advancement was $10.4 \text{ mm} \pm 2.2$. The comparison between T0 and T1 showed an overall increase of the sagittal projection of the cheeks, lips and of the chin. The comparison between T1 and V showed a transversal increase of the cheeks at the cross section through ch (cheilon).

Conclusion: MMA is a highly effective treatment for OSAS. The evaluations of 3D laser scanning showed that surgery in OSAS patients didn't cause an impairment of the facial appearance.

KEYWORDS: Maxillo-mandibular advancement, Obstructive sleep-apnea syndrome, soft-tissue, three-dimensional surface laser scanner.

INTRODUCTION

The obstructive sleep apnea syndrome (OSAS) is a well- recognized disorder that affects at least 4% of the population. OSAS is characterized by repetitive upper airway collapse or narrowing which causes daytime sleepiness, cardiovascular derangements, neurocognitive impairment and decline in quality of life. Pathogenesis of upper airway collapse in OSAS is complex and multi- factorial. In addition to lifestyle modifications, several treatments are recommended to OSAS patients on the basis of the underlying abnormality that narrows or obstructs the airway. The main therapeutic options include: cPAP which is generally accepted as a first line treatment of OSAS, oral appliances and surgical procedures. Surgery is indicated when applicable conservative therapies are unsuccessful or for patients which are non compliant to conservative treatment and in patients with an underlying specific surgically correctable abnormality (Prinsell+ 7).

The MMA is the most successful, excluding tracheostomy, surgical treatment for OSAS, with a therapeutic efficacy comparable with cPAP (Prinsell12).

MMA is used routinely to treat OSAS patients with either dento-facial deformities or normal facial morphology (Brevi), with a success rate exceeding of 90 %.

Most surgeons now agree that the best functional results are achieved by advancing the jaws as much as possible maintaining a stable occlusion and an acceptable esthetic appearance. Currently an important complaint for patients and surgeons is esthetic implications of MMA, particularly in patients without disproportional facial features and occlusal discrepancies.

While the soft tissue changes after orthognathic surgery have been studied for several years with increasingly sophisticated methods, little is actually known about the changes in facial

appearance after MMA in patients with OSAS.

The present prospective study performed a three-dimensional (3D) analysis of the soft tissue changes in typical OSAS patients before and after MMA, in order to improve treatment planning and increase predictability of the esthetic outcome.

MATERIAL AND METHODS

From January 2007 to July 2011, 27 patients with severe OSAS underwent MMA surgery at the Division of Maxillofacial Surgery, San Giovanni Battista Hospital, University of Turin, Turin, Italy. The criteria for inclusion in the present study were as follows: male Caucasian, middle age (range 30-60 years), I° obesity (BMI > 25), normal cephalometric measurements (SNA°: 82 ± 3.5 ; SNB°: 80.9 ± 3.4), severe OSAS (AHI > 30) requiring MMA for OSAS treatment (on the basis of the clinical evaluation, fiberoptic pharyngoscopy, Muller test, radiological findings and sleep endoscopy). All the patients were not compliant with ventilation devices.

Patients with dento-skeletal discrepancies leading to facial deformity (mainly severe class II deformities), in which occlusion correction and pre-operative orthodontic treatment were incorporated in the treatment plan, were not included in the study. Thus, 10 patients were enrolled in the present study.

All the patients underwent a similar surgical procedure, by the same surgeon, consisting in a MMA (standardized surgical treatment consisting of a LeFort I osteotomy and bilateral sagittal split-ramus osteotomies), with skeletal advancement planned between 10 and 12 mm.

All the procedure were completed following the “mandibular first” sequence (Ellis, Arnett). Additional procedures included septoplasty, anterior nasal spine and pyriform rim recontouring, alar cinch suture.

Variables examined include: age, BMI, respiratory disturbance index (RDI), oxigen desaturation index (ODI), hypoapnea-apnea index (AHI), cephalometric data (Table I). Soft-tissue 3D data were also obtained before and 1 year after surgery. Patients’ satisfaction with facial appearance after surgery was subjectively evaluated by a questionnaire.

Informed consent was obtained from all participants.

This study was performed in agreement with local institutional review board. We followed the Helsinki Declaration guidelines.

Polysomnography (PSG)

Before and 6 months after surgery, polysomnographic recordings were performed and scored with standard criteria (Table I).

Cephalometric Measurements

Before and 1 year after surgery Postero-Anterior (PA) and Lateral (L) cephalograms were traced by 1 examiner using the software Dolphin 11.0 Premium (Dolphin Imaging, Chatsworth, CA). The following measurements were obtained to assess skeletal movements and modifications of the PAS, using modified Arnett-Gunson analysis (Table I): SNA (angle measurement from sella S to nasion N to point A subspinale), SNB (angle measurement from S to N to point B supramentale), MP-H (distance from mandibular plane MP to hyoid bone H), PAS (distance between the base of the tongue and the posterior pharyngeal wall). Maxillary movements were also traced from anterior nasal spine (ANS) displacement with respect to the S-N axis and to its perpendicular through S; mandibular

movements were traced from point B. Forward movements were expressed with positive values.

A subsample of 20 randomly selected radiographs were retraced and digitized 1 month later to calculate the systematic errors. All the angular and linear measurements were compared between the 2 time sets by paired t test. All the measurements presented no significant difference at retracing.

Facial Scan and Data Processing

Facial surface data were acquired, before and one year after surgery, using a Head and Face Color 3D Scanner (3030RGB; Cyberware, Inc, Monterey, CA). All subjects were registered with the head in natural position (NHP), the eyes closed, and teeth in occlusion. The scanning method took into consideration previous observations concerning the positioning of the subject and environmental conditions. The detailed protocol to reduce the artifacts was previously described. The acquired data were transferred to a graphics workstation for viewing and elaboration with Cyberware Echo software (Cyberware, Inc). Scanned data sets were first restricted to the facial area and then reduced from around 160,000 to 30,000 points. Facial surface reconstruction, multiple scan alignment, and measurements were carried out using *RapidForm* 2004 software (INUS Technologies Inc, Seoul, South Korea).

Facial scans at T0 and T1 were pooled together by electronic surface averaging to obtain the mean facial model before (T0) and after treatment (T1). 3D average surfaces were constructed using the software *Morphostudio* (Biomodelling Solutions, UK) and a mesh framework algorithm based on 9 anatomic landmarks.

A virtual optimal face V was constructed by averaging the scans of 40 healthy adult men.

T0-T1, T0-V and T1-V were registered on homologous points. Reference vertical (midline through glabella) and horizontal (through right and left endocanthion) planes were constructed on the models (Figure 2).

Different linear and angular measurements and point-to-point distances at axial and sagittal cross sections were then calculated for comparison of the mean T0 and T1 models using 13 landmarks taken from classical anthropometry (Table II). The landmarks were as follows: enr, right endocanthion; enl, left endocanthion; zyr, right zygion; zyl, left zygion; alr, right alar crest point; all, left alar crest point; sn, sub-nasale; chr, right cheilion; chl, left cheilion; ls, labialis superior; li, labialis inferior; pg, pogonion; and me, menton.

The mean post-surgical face was also compared with V.

Questionnaire

The questionnaire submitted 12 months post-op subjectively assessed the perceptions of patients regarding their facial appearance. The responses were listed as: favorable (more attractive and/or more youthful), neutral (no more or no less attractive and no more or no less youthful), unfavorable (less attractive).

RESULTS

Ten patients fulfilled inclusion criteria for the study: all the patients were Caucasian adult subjects (mean age 44.9 years, range 33-60 years), with severe OSAS (AHI: 69.8 ± 35.2), with normal cephalometric measurements ($SNA^\circ: 82.5 \pm 2.9$; $SNB^\circ: 78.2 \pm 3.2$) and I° obesity (BMI: 31.6 ± 5.5). Clinical, mean cephalometric and polysomnographic pre/post-op data are summarized in Table I.

Eight out of the 10 patients were cured based on the polysomnographic results. Infact, PSG showed a significant decrease in the mean values of RDI, ODI and AHI (Table I).

In the pre-op L cephalograms none of the patients presented disproportional facial features (Table I); post-op L-cephalograms documented an important variation of the facial skeletal framework due to MMA: the mean maxillary change was $+ 9.2 \pm 1.2$ mm and the mean mandibular change was $+ 10.4 \pm 2.2$ mm.

All of the patients had improvement of either the PAS or the distance from MP to H based on the cephalometric analysis (Table I).

BMI decreased from 31.6 ± 5.5 to 28 ± 1.4 (Table I).

The comparison of measurements of the cutaneous landmark distances on T0 and T1 revealed an increase of inter-cheilion width. Increased bulking of the upper lip was also observed. Despite to the great maxillary advancement, our patients didn't present alar flaring (Table II).

The comparison between T0 and T1 showed a post-op overall increase of the sagittal projection of soft tissue A point, B points, lips and of the chin (Figure 3 A-B-C). Examination of the axial sections through alar crest point (right-left), demonstrated forward displacement of the alar base position from T0 to T1, with minimal enlargement (Figure 3 D-E).

Axial sections through cheilion revealed a good superimposition between T0-T1 (Figure 3 F-G).

The comparison between T1 and V in the sagittal cross sections reveled only a minimal defference at soft tissue A point; no differences were observed at the other levels (Figure 4 A-B-C).

Examination of the axial sections through alar crest point revealed a good superimposition (Figure 4 D-E); instead examination of axial sections through cheilion demonstrated a post-op transversal increase of cheeks (Figure 4 F-G).

At the questionnaire, six out of the ten patients gave favorable responses to their facial changes (i.e., that they appeared either more attractive or younger; four patients felt neutral regarding their facial esthetic results. None of the patients responded unfavorably).

DISCUSSION

MMA to treat OSAS has become widely accepted since the end of the 1970s.

Although the surgical techniques and technical refinements are similar, planning criteria and treatment goals differs for MMA as orthognathic surgery vs OSAS correction (Prisnell).

The amount of skeletal advancement is significantly greater in OSAS patients, leading to abnormal cephalometric measurements, particularly in OSAS patients with normal facial features and without a severe occlusal discrepancies. For instance in patients with normal profile with hypopharyngeal narrowing is requested to advance the MMC between 10 and 14 mm in order to achieve an optimal functional result. This can potentially create an unesthetic facial biprotrusion.

Therefore, an aspect of the debate concerning the use of MMA for OSAS correction remains the dilemma that optimal functional result is not made at the cost of an unacceptable poor cosmetic facial appearance.

The esthetic results and the soft tissue response to orthognathic surgery have been studied for years and in the literature many reports are available on the esthetic and facial effects of

orthodontic and maxillo-facial surgical treatment. Instead limited information is available on the esthetic outcome after MMA performed for the correction of OSAS.

Li *et al.*, in two different studies, assessed the subjective patient's perception of the facial appearance after MMA surgery for OSAS by means of a questionnaire which was mailed to each patients between 6 and 12 months after surgery. Despite significant maxillo-mandibular protrusion based on the post-op cephalometric analysis, most of the patients gave either a neutral or a favorable response to their facial esthetic results. Conley *et al.* evaluated the horizontal and vertical facial soft tissue changes occurring after MMA for OSAS patients using a "best-fit" templating cephalometric technique. Louis *et al.* evaluated the horizontal and vertical soft tissue changes that occur with maxillary advancement surgery with concomitant anatomic reorientation of the nasolabial musculature.

Even considering studies concerning soft tissue response to MMA for orthognathic surgery, limited data are available. Ryckman *et al.* quantified anteroposterior and transverse facial soft-tissue changes with respect to underlying skeletal movements after MMA by using cone-beam computed tomography.

Patient physical characteristics may influence facial soft tissue changes after skeletal surgery. In the present study we selected a typical OSAS population for gender, age, weight and facial features which greatly differs from a typical orthognathic surgery sample (young females Conley).

Pre and post-operative L cephalograms and 3D facial surface data were studied to assess objectively hard and soft tissue changes after MMA in cephalometrically normal patients with severe OSAS. In addition a questionnaire was administered to assess patients' facial esthetic perception.

In L cephalograms, the direct measurements of maxillary and mandibular movements, respectively traced from ANS and point B, showed a great forward displacement (mean maxillary change was $+ 9.2 \pm 1.2$ mm and the mean mandibular change was $+ 10.4 \pm 2.2$ mm). The anterior sagittal displacement of the MMC is confirmed by the variation between mean SNA/SNB pre-op and mean SNA/SNB post-op. Infact the post-op polysomnographic recordings (RDI, ODI, AHI) and the self-reported mood and sleepiness symptoms clearly showed the effectiveness of MMA in the treatment of OSAS.

Pre-op BMI was indicative of I° obesity (mean value 31.6 ± 5.5). One year after surgery the BMI decreased statistically significant (mean value 28 ± 1.4) however the patients fell in the overweight category, not in the normal size. Usually the greater drop in weight occurs in the first post-op month and then patients gradually tend to regain some weight.

3D facial surface data has been widely utilized and validated to objectively evaluating the changes of the facial soft tissues after skeletal repositioning surgery.

In the present study, a mean pre-surgical face (T0) and post-surgical face (T1) were created and compared with a virtual optimal face (V). The comparison of measurements of the cutaneous landmark distances on T0 and T1 revealed no modification in the upper region of the face and that the major post-surgical changes were in the lower face. In the frontal view, an increase in the intercommissural distance and in the support of the lips were shown. In all examined subjects, the alar crest point resulted correctly repositioned and symmetric and a good control of alar flaring was achieved. This effect was also demonstrated with the examination of the axial sections through alar crest point (right-left). The very limited, increase of the interalar distance and forward projection of the nasal tip should not affect esthetic outcome in most patients. A modified alar cinch suture, that was always performed,

had probably limited the adverse esthetic effects of the maxillary surgery such as alar flaring, upturning of the nasal tip, shortening of the columella, reduced vermilion exposure and flattening of the lip.

The sagittal cross section showed that MMA leads to a sagittal projection of both the lips and chin.

The comparison of facial surface at T1 and V documented an overall increase in transversal projection of the cheeks. All orthognathic surgical procedures will produce post-operative edema. Generally this edema is expected to resolve by 6 months after surgery. In this study patients underwent facial scan one year after surgery. Therefore this finding was not due to post-op edems or to a direct effect of the surgical approach. The same transversal increase of the cheeks was also evident comparing T0 and V. This effect may be attributable to the specific facial appearance of a typical OSAS patient that is middle age, with laxity of soft tissue and thick facial envelope.

The studies of Li *et al.* revealed that the soft-tissue changes caused by maxillo-mandibular protrusion in this patient population appeared to resulting in rejuvenation of the face. This corresponds to the results of the questionnaire administred to our patients which in the majority of cases felt younger.

Aging results in soft tissue descent with loss of lip and cheek prominence. Bimaxillary advancement leads to skeletal expansion which increases the soft tissue support with a positive esthetic effect similar to face lift. The augmentation of facial projection due to MMA possibly has a positive/ neutral effect on facial esthetic despite of the creation of abnormal cephalometric measurements. (Rosen H 1992) Moreover the laxity of soft tissue and the thick facial envelope of the typical OSAS patient should partially mask the effect of

the skeletal advancement.

In our sample, scanner soft tissue data evidenced an acceptable facial appearance despite an important bone repositioning in patients with normal cephalometric measurements.

According to our data patients did not present post-operatively disproportionate facial features which affect social relationships and quality of life.

This confirms that MMA is a therapeutic option even in OSAS patients with normal facial proportion. A thorough understanding of the soft-tissue response to underlying skeletal movement is mandatory for treatment planning, prediction, patient education and informed consent.

CONCLUSIONS

MMA is a highly effective treatment for OSAS.

Although the sample of this study has to be enlarged, the evaluations of 3D laser scanning showed that surgery in OSAS patients didn't cause an impairment of the facial appearance. This may be attributed to the facial features of a typical OSAS patients who is middle-age, with soft-tissues laxity and with thick facial soft tissue envelope that is able to mask the underlying skeletal protrusion and to the positive esthetic effect of skeletal expansion with increase of soft tissue support. Therefore, MMA can be considered as a therapeutic option in OSA patients, even if they have normal cephalometric measurements.

In conclusion, further 3D studies are needed to correlate the degree of soft tissue changes to the amount of underlying skeletal movements in selected population.

REFERENCES

1. Baik HS, Kim SY: Facial soft-tissue changes in skeletal Class III orthognathic surgery patients analyzed with 3-dimensional laser scanning. *Am J Orthod Dentofacial Orthop* 138:167-178, 2010.
2. Brevi BC, Toma L, Pau M, Sesenna E: Counterclockwise rotation of the occlusal plane in the treatment of obstructive sleep apnea syndrome. *J Oral Maxillofac Surg* 69:917-923, 2011.
3. Conley SR, Boyd SB. Facial soft tissue changes following maxillomandibular advancement for treatment of obstructive sleep apnea: *J oral Maxillofac Surg* 65:1332-1340, 2007.
4. Goodday R: Diagnosis, treatment planning and surgical correction of obstructive sleep apnea: *J Oral Maxillofac Surg* 67: 2183-2196, 2009.
5. Kim SJ, Kim YS, Park JH, Kim SW: Cephalometric predictors of therapeutic response to multilevel surgery in patients with obstructive sleep apnea. *J Oral Maxillofac Surg* 70: 1404-1412, 2012.
6. Li KK, Tiley RW, Powell NB, Guilleminault C: Patient's perception of the facial appearance after maxillomandibular advancement for obstructive sleep apnea syndrome. *J Oral MAXillofac Surg* 59:377-380, 2001.
7. Louis PJ, Austin B, Waite P, Mathews CS: Soft tissue changes of the upper lip associated with maxillary advancement in obstructive sleep apnea patients. *J Oral Maxillofac Surg* 59: 151-156, 2001.
8. McCance AM, Moss JP, Fright WR, et al: A three dimensional analysis of soft and hard tissue changes following bimaxillary orthognathic surgery in skeletal III

- patients. *J Oral Maxillofac Surg* 30:305-312, 1992.
9. Moss JP, McCance AM, Fright WR, et al: A three-dimensional soft tissue analysis of fifteen patients with class II, division 1 malocclusions after bimaxillary surgery. *Am J Orthod Dentofacial Orthop* 105:430-437, 1994.
 10. O'Grady KF, Antonyshyn OM: Facial asymmetry: three-dimensional analysis using laser surface scanning. *Plast Reconstr Surg* 104:928-937, 1999.
 11. Pirklbauer K, Russmueller G, Stiebellehner L, Nell C, Sinko K, Millesi G, Klug C: Maxillomandibular advancement for treatment of obstructive sleep apnea syndrome: a systematic review. *J Oral Maxillofac Surg* 69:e 165-176, 2011.
 12. Powell NB: Contemporary surgery for obstructive sleep apnea syndrome. *Clin Exp Otorhinolaryngol* 2 (3): 107-114, 2009.
 13. Prinsell J: Primary an secondary telegnathic maxillomandibular advancement, with or without adjunctive procedures, for obstructive sleep apnea in adults: a titerature review and treatment recommendations. *J Oral Maxillofac Surg* 70(7):1659-77, 2011.
 14. Schendel S, Powell N, Jacobson R: Maxillary, mandibular and chin advancement: treatment planning based on airway anatomy in obstructive sleep apnea. *J Oral Maxillofac Surg* 69:663-676, 2011.
 15. Susarla SM, Thomas RJ, Abramson ZR, Kaban LB: Biomechanics of the upper airway: changing concepts in the pathogenesis of obstructive sleep apnea. *Int J Oral Maxillofac Surg* 39: 1149-1159, 2010.
 16. Ramieri GA, Spada MC, Nasi A, et al: Reconstruction of facial morphology from laser scanned data. Part I: reliability of the technique. *Dentomaxillofac Radiol*

35:158-164, 2006.

- 17.** Ramieri GA, Nasi A, Dell'acqua A, et al: Facial soft tissue changes after transverse palatal distraction in adult patients. - *Int J Oral Maxillofac Surg* 37:818, 2008.
- 18.** Ryckman M, Harrison S, Oliver D, Sander C, Boryor AA, Hohmann AA, Kilic F, Kim KB: Soft-tissue changes after maxillomandibular advancement surgery assessed with cone-beam computed tomography. *Am J Orthod Dentofacial Orthop* 137:S86-93, 2010.

Table I. Comparison between pre and post-op BMI, polysomnographics and cephalometrics measurements.

	Normal values	PRE-op	POST-op	
BMI (kg/m²)	18.5-24.9	31.6 ± 5.5	28 ± 1.4	
PSG	RDI (hr)	74.1 ± 34.4	10.3 ± 7.2	
	ODI (%)	59.5 ± 25.3	9.1 ± 8	
	AHI (events/hr)	< 5	69.8 ± 35.2	17.3 ± 16.7
L- cephalometry	SNA (°)	82 ± 3.5	82.5 ± 2.9	87.7 ± 3.7
	SNB (°)	80.9 ± 3.4	78.7 ± 1.2	82.1 ± 3
	MP-H (mm)	15.4 ± 3	27 ± 3.6	23.2 ± 2.7
	PAS (mm)	12.8 ± 3.2	6.7 ± 2	14.1 ± 1.9

Abbreviations: PSG, polysomnography recordings; BMI, body mass index; RDI, respiratory disturbance index; ODI, oxygen desaturation index; AHI, apnea-hypopnea index; SNA, angle from Sella-Nasion-point A; SNB, angle from Sella-Nasion-point B; MP-H, distance from mandibular plane to hyoid bone; PAS, posterior airway space.

Table II. Point to point distances of the landmarks considered.

Distances		V	T0	T1
Symmetry	en r-al r	38.17	38.31	38.89
	en l-al l	38.90	38.62	39.21
	en r-ch r	68.98	68.54	69.73
	en l-ch l	69.09	68.63	70.02
	al r-ch r	33.31	32.88	34.15
	al l-ch l	33.28	32.11	34.65
	sn-ch r	40.81	40.02	41.08
sn-ch l	40.96	40.74	40.89	
Vertical	al r-X	38.16	37.30	37.03
	al l-X	38.54	37.19	37.76
	ch r-X	68.30	66.06	68.96
	ch l-X	68.42	66.70	69.13
	sn-ls	15.87	17.62	15.30
	ls-li	18.76	14.57	19.77
	li-pg	22.38	26.39	24.85
sn-pg	54.80	56.98	55.21	
Transversal	ch r-sn-ch l	86.31	80.03	81.94
	ch r-pg-ch l	83.87	81.73	85.80
	al r-Y	36.55	36.85	36.70
	al l-Y	36.67	36.01	36.35
	al r- al l	32.08	34.60	35.01
	ch r-Y	31.96	29.48	32.63
	ch l-Y	31.20	29.71	32.15
ch r- ch l	52.80	54.72	57.09	
Angles	naso-labial angle	134.57	131.91	131.43
	labial-mental angle	139.06	130.95	141.85
	al _r - prn- al _l	86.75	87.69	92.43

Values are in millimeters (or degrees for angles).
Y, vertical reference plane; r, right; l, left.

X indicates horizontal

(Differences of linear measurement major of one millimeter and angular measurements superior to 3 grades were considered significant).

CAPTIONS TO ILLUSTRATIONS

Figure 1. Averaged faces at T0, T1, and V with horizontal and vertical reference planes.

Figure 2. Sections of the mean facial surfaces at T0 (green) and T1 (red) at the subsequent different levels.

A-B-C: sagittal sections showing forward projection of soft tissue A point, B point and of the chin.

D1 (right)-D2 (left): axial sections taken on the plane through ac_r - ac_l (alar crest point right and left). Surface examination demonstrate forward displacement of the alar base position from T0 to T1, with minimal enlargement.

E1 (right)-E2 (left): axial sections taken on the plane through ch_r - ch_l (cheilion right and left).



Figure 3. Sections of the mean facial surfaces at V (green) and T1 (red) at the subsequent different levels.

A-B-C: sagittal sections showing minimal forward projection of soft tissue A point; no differences at the other levels (B point and chin).

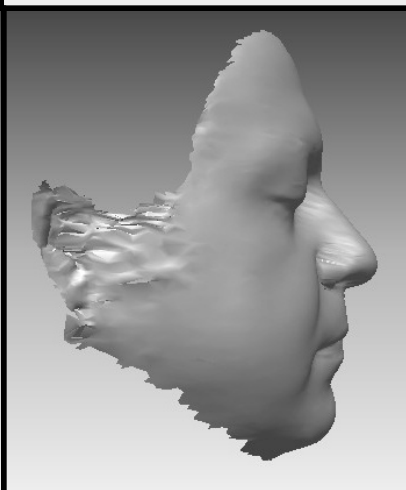

D1 (right)-D2 (left): axial sections taken on the plane through ac_r - ac_l revealed a good superimposition.

E1 (right)-E2 (left): axial sections taken on the plane through ch_r - ch_l demonstrated a post-op transversal increase of cheeks.

T0



T1



V

