

AperTO - Archivio Istituzionale Open Access dell'Università di Torino

Systemic AA amyloidosis as a unique manifestation of a combined mutation of TNFRSF1A and MEFV genes.

This is the author's manuscript

Original Citation:

Availability:

This version is available <http://hdl.handle.net/2318/134604> since 2016-10-20T16:43:59Z

Published version:

DOI:10.3109/13506129.2013.775119

Terms of use:

Open Access

Anyone can freely access the full text of works made available as "Open Access". Works made available under a Creative Commons license can be used according to the terms and conditions of said license. Use of all other works requires consent of the right holder (author or publisher) if not exempted from copyright protection by the applicable law.

(Article begins on next page)

This is the author's final version of the contribution published as:

Mereuta OM;Baldovino S;Errichiello E;Binello GB;Restagno G;Battaglia GG;Mazzucco G;Roccatello D. Systemic AA amyloidosis as a unique manifestation of a combined mutation of TNFRSF1A and MEFV genes.. AMYLOID. 20 (2) pp: 122-126.

DOI: 10.3109/13506129.2013.775119

The publisher's version is available at:

<http://www.tandfonline.com/doi/full/10.3109/13506129.2013.775119>

When citing, please refer to the published version.

Link to this full text:

<http://hdl.handle.net/2318/134604>

Systemic AA amyloidosis as a unique manifestation of a combined mutation of TNFRSF1A and MEFV genes

Oana M. Mereuta¹, Simone Baldovino¹, Edoardo Errichiello², Giovanni B. Binello¹, Gabriella Restagno², Giovanni G. Battaglia³, Gianna Mazzucco⁴, and Dario Roccatello¹

¹CMID, Center of Research on Immunopathology and Rare Diseases, Ospedale S. Giovanni Bosco and University of Torino, Torino, Italy, ² Molecular Genetics Unit, Department of Clinical Pathology, A.S.O. O.I.R.M.-S. Anna, Torino, Italy, ³ Renal Unit, Ospedale Santa Marta e Santa Venera, Acireale, Catania, Italy, and ⁴ Department of Medical Sciences, University of Torino, Torino, Italy

Abstract

We report the case of a 22-year-old Caucasian woman presenting with a new-onset nephrotic syndrome with normal renal function during the 35th week of pregnancy. AA (secondary) amyloidosis was further diagnosed at the renal biopsy. Extensive genetic testing revealed that the patient was heterozygous for both TNFRSF1A p.R92Q and MEFV p.M694I mutations leading to an autoinflammatory syndrome characterized by amyloid deposition as the sole manifestation.

Keywords: Autoinflammatory syndromes, DNA sequencing, nephrotic syndrome, secondary amyloidosis, serum amyloid A protein.

Introduction

The incidence of systemic AA (reactive, secondary) amyloidosis is decreasing in developing countries due to lowering of chronic infectious diseases, such as tuberculosis, and the development of novel pharmacologic approaches to chronic inflammatory diseases associated with a sustained acute phase response, including rheumatoid arthritis and inflammatory bowel diseases. However, autoinflammatory syndromes still represent a significant cause of AA amyloidosis. Tumor necrosis factor receptor 1 (TNFRSF1A) and Mediterranean Fever (MEFV) mutations have been associated with two major autoinflammatory disorders: tumor necrosis factor (TNF) receptor-associated periodic syndromes (TRAPS) and Familial Mediterranean Fever (FMF), respectively. The most common long-term complication of FMF and TRAPS is AA amyloidosis which may cause renal pathology. FMF is an autosomal-recessive inherited inflammatory disease caused by mutations in the MEFV gene encoding a protein called pyrin (also known as marenostatin). A multicenter study published by Touitou et al. [1] found an overall prevalence of AA amyloidosis in FMF patients of 11.4%. The incidence varied depending on the country of residence and M694V homozygosity. TRAPS is caused by heterozygous mutations in the TNFRSF1A gene which encodes the TNF receptor 1. Mutations found so far are localized in the first two N terminal cysteine-rich domain (CRD1 and 2) of the extracellular part of TNFRSF1A and affect residues that play crucial roles in the structure and function of the receptor [2]. The prevalence of AA amyloidosis among the patients with TRAPS is variable. Aksentijevich et al. [3] found that up to 14% of TRAPS patients developed amyloidosis whereas in other series a significantly higher risk for this complication (14%–25%) was reported [4,5]. Moreover, mutations in the cysteine residues are generally associated with a more severe disease phenotype (93% versus 82% for noncysteine residue substitutions) and carry the greatest risk of amyloidosis (24% versus 2% for non-cysteine residue substitutions) [4,6]. The R92Q substitution in CRD2 is considered to be a low-penetrance mutation, rather than a benign polymorphism, because it is found at higher frequency among TRAPS patients than in the general population [3]. It was identified in TRAPS patients suffering from renal amyloidosis but its role as a

factor favoring AA amyloidosis as well as its influence on susceptibility to inflammation still needs to be established [2,6].

We present a patient with heterozygous TNFRSF1A p.R92Q and MEFV p.M694I mutations associated with several MEFV polymorphisms who developed a nephrotic syndrome due to AA amyloidosis as the sole manifestation. Differentiation of the underlying renal disease in patients with autoinflammatory conditions presenting with nephrotic syndrome is difficult, often requiring further diagnostic studies to identify the etiology.

Case description

A 22-year-old Romanian woman living in South Italy presented with a new-onset nephrotic syndrome with normal renal function during the 35th week of pregnancy. She had no previous illness except for hepatitis C virus (HCV) infection and when she was 3-year-old, an esophageal burn by caustic soda treated surgically. Neither she nor any family member had a history of recurrent abdominal pain and/or fever. The patient presented with significant leg edema. Initial laboratory investigations included serum creatinine 0.5 mg/dl, total protein 5.6 g/dl, albumin 2.1 g/dl, cholesterol 328 mg/dl and elevated serum C-reactive protein (CRP) level 17 mg/dl. Daily urinary total protein excretion ranged between 3.6 g and 5.1 g. Delivery had been induced prematurely in the 36th week. Kidney biopsy was performed three weeks after delivery. Abundant Congo red positive material in the blood vessel walls of arteries and arterioles in conjunction with glomerular and tubulointerstitial deposition was evidenced. The amyloid deposition in the kidney was also detected by thioflavin T fluorescence microscopy. Renal amyloid deposits were not typed, and the patient was referred 2 months later to our tertiary Center for additional diagnostic studies. Physical examination was unremarkable. Laboratory evaluation showed normal serum creatinine, cholesterol, immunoglobulins and liver enzymes, proteinuria of 2.3 g/24 h with total serum protein of 5.8 g/dl and 2.6 g/dl of albumin, CRP 1.06 mg/dl. Serum amyloid A protein (SAA) was found to be increased (591 ng/ml). Serum N-terminal portion of natriuretic peptide type B (NT-proBNP) concentration was normal (109 pg/ml). Sero-immunological workup was unremarkable for autoimmune diseases (normal C3, C4 and negative anti-nuclear antibodies and anti-DNA, antineutrophil cytoplasmatic antibodies, cryoglobulin determination and rheumatoid factor). Tuberculin skin test and Quantiferon test were negative, while serum protein electrophoresis and immunofixation excluded gammopathies. Since the renal tissue specimen was no more available for amyloid typing, subcutaneous abdominal fat and rectal submucosa biopsies were performed. Paraffin sections were prepared for Congo red staining. Subcutaneous abdominal fat was found to be negative for amyloid deposition. Conversely, rectal biopsy was diagnostic for AA amyloidosis. Congo red staining evidenced the amyloid presence in the blood vessel walls with typical birefringence under polarized light (Figure 1A, B). The nature of the amyloid deposits was characterized on frozen rectal submucosa sections by immunofluorescence using antibodies directed against kappa and lambda immunoglobulin light chains, serum amyloid P component (SAP) and SAA (Figure 1C, D). A strong positive staining with anti-SAP and SAA antibodies was evidenced in the blood vessel walls.

The amyloid deposits were negative for anti-kappa and antilambda light chain antibodies staining. Workup of the patient was extended in search of an underlying disorder. Computer tomography of chest was negative. No laboratory, echocardiographic signs or ECG abnormalities suggestive for a cardiac involvement were seen. Mild peripheral neuropathy, possibly due to amyloid deposition, was detected at the electrophysiologic examination. The patient refused a sural nerve biopsy. Finally, genetic analysis was performed. Informed consent was obtained from the patient. The family members, who lived in Romania, were unavailable for DNA testing. Primer pairs used for DNA amplification are summarized in Table 1. DNA

analysis evidenced the co-existence of the TNFRSF1A p.R92Q and MEFV p.M694I mutations, both in heterozygosity as shown in Figure 2. Several MEFV and TNFRSF1A polymorphisms (R314R, c.1356 p 44A4G, E474E, Q476Q, D510D, c.1610 p 96C4T, c.1760-30A4T, P588P and c.473-33C4T, c.625 p 10A4G, respectively) were also detected which could increase the proinflammatory signals. No ApoA1 gene mutation was revealed. Subsequently, the patient was followed-up for 2 months by nephrologists who had referred us the case, waiting for the completion of genetic results. By this time she became pregnant, refused any further management, and was lost from the follow-up. So additional information was not available.

Discussion

In most series of AA amyloidosis, the underlying disorder appears to be unknown or not well characterized in 1%–5% of patients [2]. Genetic diseases, like FMF and TRAPS, mainly with a sporadic presentation in patients from non-ancestral populations, could be responsible and should be recognized and diagnosed. We report a rare case of TNFRSF1A/MEFV signaling alteration leading to AA systemic amyloidosis as the sole manifestation. The patient's age and occurrence of kidney involvement together with the apparent lack of any underlying inflammatory disorder were consonant with the diagnosis of autoinflammatory syndrome-associated AA amyloidosis. Definitive characterization of the amyloidosis, which was not typed at the renal biopsy, was essential in our patient. This was achieved by an appropriate panel of tissue stains on the additional biopsy of the rectal submucosa. Finally, the underlying autoinflammatory syndrome was diagnosed by means of extensive genetic testing. Although allelic variants in TRAPS and FMF genes are not major susceptibility factors for AA amyloidosis in chronic inflammatory disease, low-penetrance variants of MEFV and TNFRSF1A may have clinically significant proinflammatory effects [7]. The genotypes including two mutations located within mutational "hot-spots" (codons 680 or 694) of the MEFV gene are associated with severe phenotypes, high penetrance and risk of amyloidosis, whereas mild phenotypes are associated with some other mutations [8]. Patients, who had no FMF family background and were heterozygous for M694V and M694I mutations, suffering from renal AA amyloidosis have been reported. In these cases, genotype did not explain the occurrence of the clinical manifestation unless a second mutation was identified [2]. On the other hand, it has been postulated that TNFRSF1A non-cysteine mutations were not associated with amyloidosis [4], whereas several studies have suggested R92Q mutation as a possible risk factor for the development of AA amyloidosis. The R92 residue is located in the loop 3 of the CRD2 domain in a region of hydrogen bonds important for the stabilization of the domain structure. It has been also suggested that this amino acid might be subjected to a mutational "hot-spot" [2]. Most patients with TRAPS who have the R92Q mutation do not have impaired TNF- α receptor shedding. Consequently, other mechanisms could influence the observed phenotype or secondary genetic and environmental factors might be involved in the development of amyloidosis in these patients. A number of patients with heterozygous mutations in two autoinflammatory genes have been previously described. In addition to MEFV and TNFRSF1A [9–11], such combinations have been detected in mevalonate kinase (MVK) and TNFRSF1A [12–14] and cold-induced autoinflammatory syndrome 1 (CIAS1) and MEFV [15]. The role of the R92Q mutation in FMF was previously assessed. Despite sharing common biochemical pathways, the similar frequency of R92Q in the FMF patients and controls supports the notion that an interaction between TNFRSF1A and MEFV is minimal or nonexistent [16]. Our case suggests that amyloid deposition can occur in otherwise asymptomatic carriers of TRAPS causing mutations. Similarly, in FMF, amyloidosis can occur as the sole manifestation and is defined as phenotype II.

Although the spleen, adrenal glands and liver are frequent sites of AA amyloid deposition, renal involvement dominated the clinical course in our patient. The patient had no evidence of clinically

significant liver amyloidosis or amyloid cardiomyopathy as confirmed by normal serum alkaline phosphatase concentration and NT-proBNP level and echocardiographic aspect, respectively. The presence of a mild peripheral neuropathy is consistent with previous data reporting that neurological involvement is occasionally seen in these patients and there are likely to be other multiple metabolic factors contributing to the neuropathic symptoms. Another important finding for the diagnosis was the increased level of SAA as serological parameter of inflammation. Some authors believe normal pregnancy to be a state of mild systemic inflammation due to the cytokines derived from placenta and extraplacental membranes [17]. We can speculate that pregnancy itself perhaps in conjunction with the chronic HCV infection operated as an amyloidprecipitating factor. Furthermore, the non-typical course of the disease (i.e. the lack of fever or signs of chronic inflammation) was a diagnostic hurdle and the diagnosis could not be made without DNA sequencing. Finding mutations in patients is important for managing the disease and therapeutic orientation that is different between FMF and TRAPS. The diagnosis enables genetic counseling and appropriate management to prevent or mitigate amyloidosis. We conclude that the R92Q TNFRSF1A mutation might be the dominant pathological variant causing the autoinflammatory syndrome and the development of secondary amyloidosis in our case. The combination of the heterozygous MEFV p.M694I mutation with R92Q may lead to an increased inflammatory state whereas other common polymorphisms and environmental factors could add more proinflammatory signals.

Declaration of interest : The authors declare no conflicts of interest

References

1. Touitou I, Sarkisian T, Medlej-Hashim M, Tunca M, Livneh A, Cattan D, Yalcinkaya F, et al. Country as the primary risk factor for renal amyloidosis in Familial Mediterranean Fever. *Arthritis Rheum* 2007;56:1706–12.
2. Dode C, Hazenberg B, Pecheux C, Cattan D, Moulin B, Barthelemy A, Gubler MC, et al. Mutational spectrum in the MEFV and TNFRSF1A genes in patients suffering from AA amyloidosis and recurrent inflammatory attacks. *Nephrol Dial Transplant* 2002;17: 1212–17.
3. Aksentijevich I, Galon J, Soares M, Mansfield E, Hull K, Oh HH, Goldbach-Mansky R, et al. The tumor-necrosis-factor receptor-associated periodic syndrome: new mutations in TNFRSF1A, ancestral origins, genotype-phenotype studies, and evidence for further genetic heterogeneity of periodic fevers. *Am J Hum Genet* 2001;69:301–14.
4. Hull KM, Drewe E, Aksentijevich I, Singh HK, Wong K, McDermott EM, Dean J, et al. The TNF receptor-associated periodic syndrome (TRAPS): emerging concepts of an autoinflammatory disorder. *Medicine (Baltimore)* 2002;81:349–68.
5. Masson C, Simon V, Hoppe E, Insalaco P, Cisse I, Audran M. Tumor necrosis factor receptor-associated periodic syndrome (TRAPS): definition, semiology, prognosis, pathogenesis, treatment, and place relative to other periodic joint diseases. *Joint Bone Spine* 2004;71:284–90.
6. Ravet N, Rouaghe S, Dode C, Bienvenu J, Stirnemann J, Levy P, Delpech M, Grateau G. Clinical significance of P46L and R92Q substitutions in the tumour necrosis factor superfamily 1A gene. *Ann Rheum Dis* 2006;65:1158–62.

7. Aganna E, Hawkins PN, Ozen S, Pettersson T, Bybee A, McKee SA, Lachmann HJ, et al. Allelic variants in genes associated with hereditary periodic fever syndromes as susceptibility factors for reactive systemic AA amyloidosis. *Genes Immun* 2004;5:289–93.
8. Touitou I. The spectrum of Familial Mediterranean Fever (FMF) mutations. *Eur J Hum Genet* 2001;9:473–83.
9. Cigni A, Ledda F, Satta AE. A complex case of renal amyloidosis with a rare co-occurrence of 2 mutations in separate hereditary periodic fever syndrome-related genes. *J Nephrol* 2006;19:543–9.
10. Granel B, Serratrice J, Dode C, Grateau G, Disdier P, Weiller PJ. Overlap syndrome between FMF and TRAPS in a patient carrying MEFV and TNFRSF1A mutations. *Clin Exp Rheumatol* 2007;25: 93–5.
11. Cantarini L, Baldari CT, Rossi Paccani S, Lucherini OM, Laghi Pasini F, Galeazzi M. Saturday night fever: bizarre recurrence of fever attacks in a patient carrying a mutation in both the MEFV and TNFRSF1A genes. *Clin Exp Rheumatol* 2008;26:128–9.
12. Stojanov S, Lohse P, Lohse P, Hoffmann F, Renner ED, Zellerer S, Kery A, et al. Molecular analysis of the MVK and TNFRSF1A genes in patients with a clinical presentation typical of the hyperimmunoglobulinemia D with periodic fever syndrome: a low-penetrance TNFRSF1A variant in a heterozygous MVK carrier possibly influences the phenotype of hyperimmunoglobulinemia D with periodic fever syndrome or vice versa. *Arthritis Rheum* 2004; 50:1951–8.
13. Hoffmann F, Lohse P, Stojanov S, Shin YS, Renner ED, Kery A, Zellerer S, Belohradsky BH. Identification of a novel mevalonate kinase gene mutation in combination with the common MVK V377I substitution and the low-penetrance TNFRSF1A R92Q mutation. *Eur J Hum Genet* 2005;13:510–12.
14. Arkwright PD, McDermott MF, Houten SM, Frenkel J, Waterham HR, Aganna E, Hammond LJ, et al. Hyper IgD syndrome (HIDS) associated with in vitro evidence of defective monocyte TNFRSF1A shedding and partial response to TNF receptor blockade with etanercept. *Clin Exp Immunol* 2002;130:484–8.
15. Singh-Grewal D, Chaitow J, Aksentijevich I, Christodoulou J. Coexistent MEFV and CIAS1 mutations manifesting as familial Mediterranean fever plus deafness. *Ann Rheum Dis* 2007;66:1541.
16. Marek-Yagel D, Berkun Y, Padeh S, Lidar M, Shinar Y, Bar-Joseph I, Reznik-Wolf H, et al. Role of the R92Q TNFRSF1A mutation in patients with Familial Mediterranean Fever. *Arthritis Care Res* 2010;62:1294–8.
17. Kovacevic A, Hammer A, Sundl M, Pfister B, Hrzenjak A, Ray A, Ray BK, et al. Expression of serum amyloid A transcripts in human trophoblast and fetal-derived trophoblast-like choriocarcinoma cells. *FEBS Lett* 2006;580:161–7.

Figure 1. Immunohistochemical typing of the amyloid deposits in the rectal submucosa. (A) Congo red staining and (B) polarizing microscopy showing amyloid deposition in the blood vessel walls (arrow) with a characteristic yellow-green birefringence. Fluorescence microscopy showing positive staining with anti-amyloid P and A components antibodies (C and D, respectively). Original magnifications were $\times 20$ (A), $\times 10$ (B) and $\times 40$ (C, D).

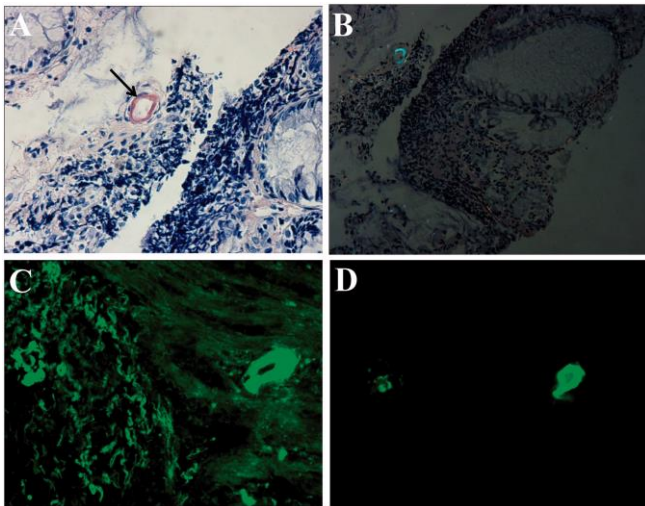
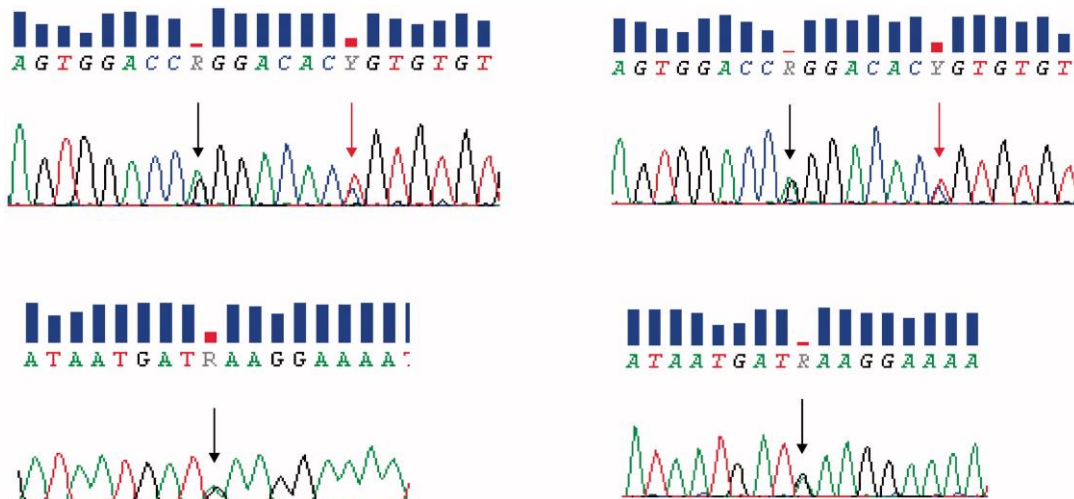


Figure 2. MEFV and TNFRSF1A genes mutations detection. DNA sequence electropherograms showing the heterozygous R92Q (c.362 G > A) substitution in exon 4 of TNFRSF1A (black arrow on the top) and the heterozygous M694I (c.2082 G > A) mutation in exon 10 of MEFV (black arrow on the bottom). All genetic alterations identified in the forward sequence (on the left) were confirmed in the reverse sequence (on the right). Close to the R92Q, the synonymous T94T (c.369C > T) variant (red arrow) with no deleterious effects.



Gene	Exon	Forward primer	Reverse primer	Product coordinates	Product size (bp)
MEFV	1	aaactgcctttcttctca	Cactcagcactggatgagga	chr16:3306271-3306675	405
	2	aaacttaatatccaaggggattc	Ttctctgagccgataaaagta	chr16:3304117-3304887	771
	3	gaactcgcacatctcaggc	Aaggcccagtggtccaagtc	chr16:3299373-3299887	515
	4	ttggcaccagctaaagatggc	Tctccctacagggatgagc	chr16:3298737-3299067	331
	5	tatcgctcctctctggaatc	Cactgtgggtccaagaccaag	chr16:3296871-3297396	526
	6	tccaggagcccagaagtagag	Ttccctatcaaatccagag	chr16:3296355-3296631	277
	7	agaatgtagttcattccagc	Cattctgaaagcaggggtt	chr16:3294267-3294672	406
	8-9	acctaacccagctctctctgc	Agttctctggaacgtggtag	chr16:3293783-3294328	546
	10 A	ccagaagaactaccctgtccc	Agagcagctggcgaatgat	chr16:3293246-3293793	548
	10 B	gaggtgaggttgagacaaa	Tctctctgaaatccatgg	chr16:3292908-3293521	614
TNFRSF1A	1	aggccgtgatctctatgccc	Tggctgaggttaggactgc	chr12:6450796-6451135	340
	2	tccctctttagtggtctcc	Cagactgagggcattcacc	chr12:6443219-6443452	234
	3	ttcttggttctcaccgag	Tcaagaccgctgactctc	chr12:6442865-6443078	214
	4	aggatgcaggactcataccc	Aaaggaagtgccccgcatgg	chr12:6442454-6442721	268
	5	tcacttctctgtctctgtgg	Aatggtccccaccagtcacc	chr12:6442163-6442384	222
	6	gtgttctccaatgtaggg	Aagcaggtgtgtcagaggg	chr12:6439887-6440144	258
ApoA1	3	ccacctcaaggagcccagctcgg	Taggtgaggactcggcagctcgg	chr11:116707628-116707883	256
	4 A	cagccctcaacctctgtctcacc	Cagatcgctgcgacgctccaca	chr11:116706767-116707158	392
	4 B	agctgcaagagaagctgagccact	Aacgtttattctgagcaccgggaag	chr11:116706480-116706849	370

Table 1. Characteristics of primer pairs used to amplify MEFV, TNFRSF1A and ApoA1 genes.