

AperTO - Archivio Istituzionale Open Access dell'Università di Torino

Surgical treatment of buccal soft tissue recessions around single implants: 1-year results from a prospective pilot study

This is the author's manuscript

Original Citation:

Availability:

This version is available <http://hdl.handle.net/2318/139234> since

Published version:

DOI:10.1111/clr.12149

Terms of use:

Open Access

Anyone can freely access the full text of works made available as "Open Access". Works made available under a Creative Commons license can be used according to the terms and conditions of said license. Use of all other works requires consent of the right holder (author or publisher) if not exempted from copyright protection by the applicable law.

(Article begins on next page)



UNIVERSITÀ DEGLI STUDI DI TORINO

This is an author version of the contribution published on:

[Clinical oral implants research, vol. 25,issue 6,2014, DOI: 10.1111/clr.12149]

The definitive version is available at:

<http://onlinelibrary.wiley.com/doi/10.1111/clr.12149/abstract>

Surgical treatment of buccal soft tissue recessions around single implants: 1-year results from a prospective pilot study.

Mario ROCCUZZO^{1,2}, Luigi GAUDIOSO¹, Marco BUNINO¹, Paola DALMASSO³.

¹ Private Practice Torino, Italy

² Department of Maxillofacial Surgery, University of Torino, Italy.

³ Department of Public Health and Microbiology, University of Torino, Italy

Correspondence to:

Dr. Mario ROCCUZZO

Corso Tassoni, 14

10143 Torino, Italy

Tel & Fax: +39. 011. 7714732

E-mail: mroccuzzo@iol.it

Key words: dehiscence, dental implants, keratinized mucosa, maintenance, mucogingival surgery, peri-implant mucosa, peri-implant tissues, recession, surgical coverage

Abstract

Aim: The aim of this study was to evaluate the outcome of a soft tissue dehiscence coverage technique, at single non-submerged implant sites, presenting shallow isolated buccal mucosal recession.

Material and methods: Sixteen patients were included in this prospective study. A connective tissue graft (CTG) was harvested from the maxillary tuberosity. The donor soft tissue was de-epithelialized and trimmed with a mucotome for an optimal adaptation to the collar of the implant.

Results: Surgery and healing proceeded with no complications and minimal post-operative discomfort. One-year follow-up demonstrated clinical and esthetic improvements. Treatment resulted in $89.6\pm 13.1\%$ mean coverage, and complete implant soft tissue coverage was achieved in nine of 16 cases, corresponding to a 56.3%. The VAS esthetic analysis showed a significant improvement from 3.6 ± 0.2 to 8.5 ± 0.3 .

Conclusions: These positive preliminary results suggest that, by means of the surgical technique presented, buccal soft tissue dehiscences around single implants can be successfully treated. Additional Randomized controlled trials (RCTs) should be encouraged to assess the most effective variation to the technique in the various clinical situations and around implants of different designs.

Introduction

Over the years, implant therapy has become a common practice to replace lost or irreversibly damaged teeth and will probably gain in popularity during the near future. At the same time, esthetic demands have tremendously increased, especially if anterior teeth have to be replaced in patients with a high lip line.

From an esthetic point of view, the grey color of titanium may create a major problem, even after successful osseointegration, when becoming visible due to peri-implant soft tissue recession (Marinello et al. 1997; Glauser et al. 2004; Kohal et al. 2008). Even though soft tissue dehiscences around implants have been observed in the last years, the prevalence of this condition is not known (Bengazi et al. 1996).

Oates et al. (2002) reported the long-term changes in the position of the facial soft tissue margins following restoration of 106 one-stage ITI implants in 39 patients, in both maxillary and mandibular anterior regions. After 2 years, a ≥ 1 mm mid-facial soft tissue recession was present in 61% of the cases. Of the 39 patients assessed, 24 showed a loss of 1 mm or more of the soft tissue levels around the implants. The authors suggested that the potential for significant changes in soft tissue levels, after completion of restorative therapy, should be considered in esthetic areas. It must be noted that the risk of soft tissue recession may be higher for implants placed in fresh extraction sockets with both a submerged and non-submerged approach as found by Cordaro et al. (2009).

Unlike teeth where a minimal recession of 1-2 mm does not always produce esthetic discomfort, even a minimal amount of titanium exposure can

jeopardize the overall treatment, as it may be unacceptable by the patient. Ideally, clinicians should select the technique for treating these situations, on the base of the best available evidence. Unfortunately, most systematic reviews on mucogingival therapy (Roccuzzo et al. 2002; Oates, et al. 2003; Cairo, et al. 2008a; Chambrone et al. 2009) have not presented information regarding the treatment of peri-implant soft tissues dehiscences. The most common outcome variable, included in these reviews, is recession reduction, which represents the mean percentage of root coverage. Depending on the surgical technique utilized, it is within the 50–90% range, the latter value considered clinically satisfying. In implant dentistry, on the other hand, the position of the coronal portion of soft tissue margin, at the level of the crown, is the most important outcome in patients with esthetic requests. Very often, the recession is the only visible part when the patient smiles; therefore, the persistence, after therapy, of even a shallow recession must be considered an esthetic failure.

At the 6rd European Workshop on Periodontology, Cairo et al. (2008b) presented a narrative review, based mainly on expert opinions, case reports and case series. Literature analysis showed that (i) the width of KT did not influence the survival rate of dental implants; (ii) there is no evidence to recommend a specific technique to preserve/augment KT; and (iii) factors including bone level, KT and implant features have not been shown to be associated with future mucosal recession around dental implants. The only possible conclusion, approved by the Consensus Report (Palmer & Cortellini 2008), was that although scientific evidence in most part is lacking, soft tissue augmentation at implant sites may be considered in some clinical situations.

However, the outcomes of these procedures have not been evaluated in prospective studies.

One prospective cohort study (Burkhardt et al. 2008) tried to evaluate the outcome of soft tissue dehiscence coverage around single-implant restoration. Coronal advanced flap (CAF) with connective tissue graft (CTG) techniques were used to treat 10 patients and evaluated the healing up to 6 months. After one month, the mean of soft tissue dehiscence coverage was 75%, 70% at 3 months and 66% at 6 months. The authors concluded that a clinically significant improvement of soft tissue dehiscence was obtained with a combination of CAF and CTG, but complete “recession” coverage was not possible.

For the second consensus conference organized by The European Association for Osseointegration, a systematic review on soft tissue augmentation techniques was presented by Thoma et al. (2009). The authors concluded that for soft tissue volume augmentation, only limited data are available favoring subepithelial CTGs over free gingival grafts, but with no data regarding esthetic outcome. In the Consensus statements (Klinge & Flemming 2009) it was reported that “in some cases, there is a clinical need for soft tissue augmentation at implants in order to improve esthetics and patient comfort”, but with no indication about the possible surgical techniques. Only a few single case reports were published in the last decade. Shibli et al. (2004) described the use of a subepithelial CTG to recontour a soft tissue margin discrepancy for a single implant crown in the anterior maxilla. Lai et al. (2010) presented a resubmerged implant technique with connective tissue grafting for implant coverage around a maxillary left central incisor of a 39-

year-old woman. Mareque-Bueno (2011) described a surgical procedure for coronally advancing the peri-implant mucosa to treat a soft tissue dehiscence in a single-tooth implant-supported restoration. The results reported the possibility of achieving only partial soft tissue coverage over an implant-supported restoration with the combined use of an acellular dermal matrix and a coronally positioned flap.

In a very recent study on 20 patients, Zucchelli et al. (2012) presented a treatment consisting in removal of the implant supported crown, reduction in the implant abutment, coronally advanced flap in combination with CTG and final restoration. At 1-year mean coverage was 96.3%, and complete coverage was achieved in 75% of the treated sites.

Esposito et al. (2012) attempted a systematic review for the Cochrane collaboration group, but he was not able to find a single acceptable RCT in the world literature to provide recommendations on which are the best incision/suture techniques/materials to correct/augment peri-implant soft tissues. The authors suggested properly designed and conducted RCTs to provide reliable answers to these questions. It must be said however that, from both a practical and an ethical point of view, RCTs should not be initiated before clinical case series and/or prospective cohort studies provide preliminary positive results on a particular technique.

The aim of this prospective study is to assess whether CTG, taken from the maxillary tuberosity, could be effective in the esthetic treatment of shallow buccal soft tissue dehiscence at single maxillary implants and to monitor the peri-implant conditions over time. This report focuses on surgical feasibility and post-surgical transmucosal healing. Clinical and esthetic results after 1

year are presented.

Materials and methods

Patient population

From June 2007 to December 2010, 16 patients (three men and 13 women, mean age: 53.1 ± 11.7 years; three smokers), who presented a peri-implant buccal soft tissue recession and consequent exposure of the collar of the implant, were consecutively enrolled from those attending the principal investigator's private practice (Fig.1a). Patients had been treated, in the previous years, by means of non-submerged dental implants with smooth collars of two different lengths, that is, 2.8 or 1.8 mm, (Straumann Tissue Level Implants, Straumann AG, Basel, Switzerland). All implants supported cemented fixed dental prostheses. Patients had been recalled at various intervals, depending on the initial diagnosis and the results of the therapy (Mombelli & Lang 1998), for supporting periodontal therapy. Patients had been placed on an individually tailored maintenance care program: motivation, reinstruction, instrumentation and treatment of sites were performed as needed (Roccuzzo et al, 2012).

Only one implant per patient was included in the study. The baseline demographic and clinical characteristics of the patients are represented in Table 1.

The inclusion criteria for the study were one implant-supported tooth in the maxillary area displaying an apical displacement of the soft tissue margin with no significant interproximal bone loss and/or adjacent papillae recession (Fig.1b,c). The exclusion criteria at the screening visit were all the systemic diseases that could interfere with implant therapy, patients who had not complied with the recall program, multiple adjacent recessions, interproximal

soft tissue recession, probing depth (PD) ≥ 5 mm at the interproximal sites of adjacent teeth, heavy smoking (>15 cigarettes/day).

Each patient was provided with a detailed description of the procedure. They were also informed that their data would be used for statistical analysis and gave their informed consent to the treatment. No ethical committee approval was sought to start this observational study, as it was not required by national law or by ordinance of the local inspective authority. The prospective study was performed in accordance with the principles stated in the Declaration of Helsinki and the Good Clinical Practice Guidelines.

Subjects were clinically and radiographically monitored at baseline. Full-mouth plaque score (FMPS) and full-mouth bleeding score (FMBS) were calculated. Soft tissue recession (REC) was measured from the implant shoulder to the coronal margin of the mucosa, by means of a Castroviejo Caliper Short, (Salvin Dental Specialties, Inc., Charlotte, NC, USA) and rounded off to the nearest $\frac{1}{2}$ millimeter, immediately before surgery and 12 months post-operatively, by a calibrated examiner (LB). He also collected the following parameters by means of a periodontal probe (XP23/UNC 15, Hu-Friedy, Chicago, IL, USA): PD, presence of dental plaque (PI), bleeding on probing (BoP) at the mesial, distal, buccal, and palatal/lingual aspects of each implant. Figures were rounded off to the nearest millimeter (Roccuzzo et al. 2012). The esthetic outcome was evaluated using a visual analog scale (VAS) (0= poor, 10= excellent) by three independent clinicians.

Following selection, all patients received appropriate initial therapy, consisting, depending on the cases, in motivation, proper oral hygiene instruction, scaling and root planning with the aim to create optimal conditions.

They were also instructed to brush using the roll-stroke technique. No surgery was performed before the assurance of excellent motivation and compliance from each single patient (FMPS<15%; FMBS<15%).

Surgical procedures

All surgeries were performed by one surgeon (M. R.) with 20 years of experience in periodontal surgery. A thick gingival cuff of the maxillary tuberosity area was selected as the donor site. After local anesthesia of the recipient and donor sites with mepivacaine plus epinephrine 1:100,000, an intracrevicular incision was performed, and a partial thickness flap was elevated (Fig.1d). After preparing the recipient site, the gingival cuff was excised by a gingivectomy from the tuberosity area (Jung et al. 2008). The donor soft tissue was de-epithelialized and trimmed with a mucotome to give a U shape (Fig.1e) to facilitate an optimal adaptation to the collar of the implant (Fig.2f). The prepared connective tissue was placed in the recipient bed and immobilized by 6-0 Vicryl sutures (Ethicon Inc., Johnson & Johnson, Pomezia, Italy). The flap was sutured by means of 5-0 Vicryl sutures, to cover the graft with minimal tension. To achieve this, the muscle insertions were eliminated to allow for its coronal displacement (Fig. 2g).

Each patient was administered amoxicillin plus clavulanic acid, 2 g one hour prior and 1 g 6 hours after surgery. The patient was recalled for checkup and post-operative care, as needed. After 4-8 months, a gingivoplasty was performed by means of a rotating diamond burr, when needed, to reduce the bulky volume and/or color mismatch (Fig. 2h).

Postsurgical Care

Patients were instructed to take non-steroidal analgesics, as needed. Immediately after surgery, the patients applied ice packs at the treated area, and it was recommended that these be kept in place for at least 4 hours. Patients were advised to discontinue tooth brushing and to avoid trauma at the site of surgery for 3 weeks. They were also instructed to use 0.2% chlorhexidine digluconate rinse for 1 minute three times a day for the same period of time. Patients were seen after 7 days and then weekly for the first month to monitor healing. The sutures were removed after 14 days. After the healing phase, patients were placed on an individually tailored maintenance care program. Motivation, reinstruction, supragingival instrumentation and antiseptic therapy were performed as needed.

Statistical Analysis

Each patient contributed with one lesion and was, therefore, regarded as the statistical unit. Data were expressed as mean \pm SD or percentages. A Statistical Application Software (Stata 12) was used for the statistical analysis. The statistical distribution of the quantitative measures was found to be non-gaussian (Shapiro-Wilk test), and nonparametric tests were used. Pre- and post-surgery recordings were conducted using exact Wilcoxon matched-pairs signed-rank test or McNemar exact test, as appropriated. All the tests were two tailed. The level of significance was set at 5%.

Results

In all patients, healing proceeded without complications and with minimal post-operative discomfort (Fig. 2j). No patient dropout and no implant loss were registered, during the first year of observation. The clinical data of the 16 implants, at baseline and at 1-year follow-up, are listed in Table 2. Mean recession significantly decreased from 2.0 ± 0.7 mm to 0.3 ± 0.3 mm ($p=0.0004$). Complete coverage was achieved in nine of the 16 cases (56.3%).

After one year FMPS varied, not significantly, from $18.5 \pm 9.1\%$ to $17 \pm 7.5\%$. At baseline, bleeding on probing was found around $17.4 \pm 7.6\%$ of the total surfaces, and it did not change significantly ($16.8 \pm 8.4\%$) at the 12-month examination. Baseline PD was 2.7 ± 0.4 mm, while 1-year PD was 3.1 ± 0.5 mm. This increase was statistically significant.

Regarding the esthetic outcome, the average scores of the three measurements varied from 3.6 ± 0.2 (min 2, max 5) to 8.5 ± 0.3 (min 6, max 10), with a highly significant difference ($p < 0.0001$).

Discussion

The aim of this study is to present the preliminary results of prospective analysis on the influence of the quality of the mucosa on the long-term implant outcomes, recruited from a private clinic. The benefit, in accordance with the Consensus Report of 6th European Workshop on Periodontology (Lindhe & Meyle 2008) is that subjects recruited from private or public dental clinics, rather than university clinics, provide information on the 'effectiveness' rather than 'efficacy' in implant therapy. Unlike teeth where a minimal recession of 1-2 mm does not always produce esthetic discomfort, the titanium exposure can jeopardize the overall treatment as it may be unacceptable. This is the reason because complete coverage is the only outcome of interest for the clinicians. In this group of patients, complete coverage was achieved in nine of 16 cases, while in six cases a < 1mm of metal was still present. Incidentally, the one case which presented, at the 1-year evaluation, a residual recession of about 1 mm, was re-treated with the same technique to further augment the tissue thickness, and an optimal final result was achieved, even though the outcome is not included in this analysis.

The slight increase of 0.4 mm in PD, similarly to what reported by Zucchelli et al. (2012) is statistically significant, but does not appear to have any clinical consequence, even though a definitive answer is not available, yet.

At this time, no definitive conclusions can be drawn on the protective role of KT around implants in humans, particularly in the prevention of the occurrence of soft tissue recession. Prospective longitudinal controlled clinical trials will have to be performed to further elucidate the potential role of a sealing effect of masticatory mucosa on peri-implant stability.

The intervention outcomes at implant sites regarding soft tissue recession coverage are scarce and not well documented. This study was designed as a proof of principle to evaluate the efficacy of the proposed technique around the specific implant design. It represents a first important step forward in the definition of the optimal surgery to be searched in future studies. More years of observation are, however, necessary to verify whether soft tissue stability can be maintained, over a long period of time. Ideally randomized-controlled clinical studies would be preferable to evaluate the effectiveness of various soft tissue augmentation procedures for different clinical indications and, in particular, in esthetic areas with substantial tissue defects. However, this may be a challenging situation, for ethical reasons, as it may be difficult to recruit patients with these characteristics because most of them would like to receive some form of augmentation procedure and not to act as an untreated control (Wiesner et al. 2010). Nevertheless, these preliminary results provide an ethical base to perform RCTs to compare various methods for tissue grafting. In the meantime, the clinical decision of whether implant recessions should be treated may be based on several factors, including the fact that, by means of the surgical technique presented, complete implant soft tissue dehiscence coverage could be achieved in a high percentage of cases.

Unlike the two previous similar studies, (Burkhardt et al. 2008; Zucchelli et al. 2012) the present technique did not include vertical incisions. This procedure has the advantage not to interrupt blood supply and to reduce the risk of scar tissues. On the other hand, it does not allow the possibility to move the flap as far coronally as sometime needed. It therefore may be indicated only in cases where the recession is not too deep and the interproximal tissue is intact.

One important aspect in the described technique is the choice of the donor site. The retromolar maxillary area is very often thick and dense, with no fat tissues as it is usually found in the palatal area. Moreover, the soft tissue bulk, after de-epithelialization, needs to be trimmed with a mucotome to give a U shape in order to facilitate the optimal adaptation to the collar of the implant.

The overall recession reduction, in the present investigation, is slightly less than to the one reported by Zucchelli et al. (2012), and complete coverage was achieved in 56.3% of the treated cases compared with 75% of the other study. Conversely, the results were more successful with respect to those reported by Burkhardt et al. (2008).

One of the advantages of the proposed surgical therapy is that no additional prosthetic treatment is necessary, as indicated by Zucchelli et al. (2012) with reduction in treatment time and cost for the patient.

The value of this study is that, even though the number of patients included is somehow limited, it has been performed with only one non-submerged implant system. As the shape of the implant is going to play an important role in the selection of the proper treatment, it may be possible that different procedures may be indicated with various implant systems.

From a clinical point of view, this result seems to be quite interesting, as it is, to the best of our knowledge, the first of this type. It is not possible to draw definitive conclusions, but these positive preliminary results encourage further investigation with a similar protocol. In particular, future research should be encouraged to investigate whether vertical incisions may play a beneficial role and when modifications of the prosthetic crown are necessary.

Acknowledgement: The authors wish to thank Dr. Luca Bonino, Ms. Silvia Gherlone, RDH and Ms. Silvia Lissona for their precious help in the study.

Conflict of interest: The authors declare they have no potential conflict of interests related to the publication of this paper.

Source of funding: The study was self-funded, and no external funding was received by any of the authors.

References

Bengazi, F., Wennstrom, J. L. & Lekholm, U. (1996) Recession of the soft tissue margin at oral implants. A 2-year longitudinal prospective study. *Clinical Oral Implants Research* **7**: 303-310.

Burkhardt, R., Joss, A. & Lang, N. P. (2008) Soft tissue dehiscence coverage around endosseous implants: A prospective cohort study. *Clinical Oral Implants Research* **19**: 451-457.

Cairo, F., Pagliaro, U. & Nieri, M. (2008a) Treatment of gingival recession with coronally advanced flap procedures: A systematic review. *Journal of Clinical Periodontology* **35**: 136-162.

Cairo, F., Pagliaro, U. & Nieri, M. (2008b) Soft tissue management at implant sites. *Journal of Clinical Periodontology* **35** (Suppl 8): 163-7.

Chambrone, L., Sukekava, F., Araujo, M. G., Pustiglioni, F. E., Chambrone, L. A. & Lima, L. A. (2009) Root coverage procedures for the treatment of localised recession-type defects. *Cochrane Database Systematic Reviews* doi: 10.1002/14651858.CD007161

Cordaro, L., Torsello, F. & Roccuzzo, M. (2009) Clinical outcome of submerged vs. non-submerged implants placed in fresh extraction sockets. *Clinical Oral Implants Research* **20**: 1307–1313.

Esposito, M., Maghaireh, H., Grusovin, M.G, Ziounas, I. & Worthington HV. (2012) Interventions for replacing missing teeth: management of soft tissues for dental implants *Cochrane Database Systematic Reviews* doi: 10.1002/14651858.CD006697

Glauser, R., Sailer, I., Wohlwend, A., Studer, S., Schibli, M & Schärer, P. (2004) Experimental zirconia abutments for implant-supported single-tooth restorations in esthetically demanding regions: 4-year results of a prospective clinical study. *International Journal of Prosthodontic* **17** (Suppl 3): 285-290.

Jung, U.W., Um, Y.J. & Choi, S.H. (2008) Histologic observation of soft tissue acquired from maxillary tuberosity area for root coverage. *Journal of Periodontology* **879**: 934–940.

Klinge, B & Flemming, TF (2009) Tissue augmentation and esthetic. *Clinical Oral Implants Research* **20** (Suppl 4):166-70.

Kohal, R.J., Att, W., Bachle, M & Butz, F. (2008) Ceramic abutments and ceramic oral implants. An update. *Periodontology 2000* **4**: 224-43.

Lai, Y. L., Chen, H. L., Chang, L. Y. & Lee, S. Y. (2010) Resubmergence technique for the management of soft tissue recession around an implant:

Case report. *International Journal of Oral and Maxillofacial Implants* **25**:201-204.

Lindhe, J. & Meyle, J. (2008) Peri-implant diseases: consensus report of the sixth european workshop on periodontology. *Journal of Clinical Periodontology* **35** (Suppl 8):282-285.

Mareque-Bueno, S. (2011) A novel surgical procedure for coronally repositioning of the buccal implant mucosa using acellular dermal matrix: A case report. *Journal of Periodontology* **82**: 151-156.

Marinello, CP. Meyenberg, KH, Zitzmann, N., Luthy, H., Soom, U. & Imoberdorf, M. (1997) Single-tooth replacement: some clinical aspects. *Journal of Esthetic Dentistry* **9** (Suppl 4): 169-78.

Mombelli, A. & Lang, NP. (1998) The diagnosis and treatment of peri-implantitis. *Periodontology 2000* **17**:63-76.

Oates, T. W., Robinson, M. & Gunsolley, J. C. (2003) Surgical therapies for the treatment of gingival recession. A systematic review. *Annals of Periodontology* **8**: 303-320.

Oates, T. W., West, J., Jones, J., Kaiser, D. & Cochran, D.L. (2002) Long-term changes in soft tissue height on the facial surface of dental implants. *Implant Dentistry* **11**: 272-9.

Palmer, RM. & Cortellini, P. (2008) Periodontal tissue engineering and regeneration: Consensus Report of the Sixth European Workshop on Periodontology. *Journal of Clinical Periodontology* **35**: 83–86.

Roccuzzo, M., Bonino, F., Aglietta, M. & Dalmaso, P. (2012) Ten-year results of three arms prospective cohort study on implants in periodontally compromised patients. Part 2: clinical results. *Clinical Oral Implants Research* **23**: 389-95.

Roccuzzo, M., Bunino, M., Needleman, I. & Sanz, M. (2002) Periodontal plastic surgery for treatment of localized gingival recessions: A systematic review. *Journal of Clinical Periodontology* **29** (Suppl 3): 178-194.

Shibli, J. A., d'Avila, S. & Marcantonio, E., Jr. (2004) Connective tissue graft to correct periimplant soft tissue margin: A clinical report. *Journal of Prosthetic Dentistry* **91**: 119-122.

Thoma, DS., Benic, GI., Zwahlen, M., Hammerle, CH. & Jung, RE. (2009) A systematic review assessing soft tissue augmentation techniques. *Clinical Oral Implant Research* **20** (Suppl 4): 146-65.

Wiesner, G., Esposito, M., Worthington, H. & Schlee, M. (2010) Connective tissue grafts for thickening peri-implant tissues at implant placement. One-

year results from an explanatory split.mouth randomized controlled clinical trial. *European Journal of Oral Implantology* **3** (Suppl 1): 27-35.

Zucchelli G, Mazzotti C, Mounssif I, Mele M , Stefanini M, Montebugnoli L. (2012) A novel surgical–prosthetic approach for soft tissue dehiscence coverage around single implant. *Clinical Oral Implant Research* doi:10.1111/clr.12003.x [Epub ahead of print]

Table 1. Data on patients, defect location, implant type, months in function

n	Sex	Age	Smoking	Site	Implant type	Months in function	Recession Pre-op mm	Recession Post-op mm
1	F	55		1.4	S, \varnothing 4.1 x 10 mm	38	3	0.5
2	F	51		2.3	TE, \varnothing 4.1 x 10 mm	30	1.5	0
3	F	41		2.4	S, \varnothing 4.1 x 12 mm	70	1.5	0
4	F	54		1.5	S, \varnothing 4.1 x 12 mm	120	2	0
5	F	39		1.6	SP, \varnothing 3.3 x 10 mm	26	1	0
6	F	40		1.3	TE, \varnothing 3.3 x 12 mm	96	2	0
7	M	70		1.1	TE, \varnothing 4.1 x 12 mm	35	3	1
8	F	65		1.4	TE, \varnothing 4.1 x 12 mm	46	2.5	0.5
9	M	67	Yes	1.5	S, \varnothing 4.1 x 6 mm	20	2.5	0.5
10	F	50	Yes	2.4	SP, \varnothing 3.3 x 10 mm	14	1	0
11	F	28		1.5	S, \varnothing 4.1 x 10 mm	64	1	0
12	F	61		2.5	S, \varnothing 4.1 x 12 mm	31	2	0
13	M	57		2.1	TE, \varnothing 3.3 x 12 mm	60	2	0.5
14	F	50		2.4	SP, \varnothing 3.3 x 10 mm	20	3	0.5
15	F	55	Yes	2.2	SP, \varnothing 4.1 x 12 mm	38	2	0
16	F	67		1.3	SP, \varnothing 3.3 x 10 mm	18	1.5	0.5

Table 2. Baseline and 1-year clinical parameters in N= 16 (means \pm SD).

	Pre-op	Post-op	Δ (95% CI)	<i>p</i>
Recession (mm)	2.0 \pm 0.7	0.3 \pm 0.3	-1.7 (-2.0,-1.4)	0.0004
VAS	3.6 \pm 0.2	8.5 \pm 0.3	4.9 (4.5, 5.3,)	<0.0001
Local BoP	3 / 16	1 / 16	2/16 (-0.1, 0.4)	0.63
Probing depth (mm)	2.7 \pm 0.4	3.1 \pm 0.5	1.4 (0.3, 0.5)	0.0004
FMPS (%)*	18.5 \pm 9.1	17.5 \pm 7.5	1.0 (-3.2, 1.2)	0.38
FMBS (%)†	17.4 \pm 7.6	16.8 \pm 8.4	0.6 (-2.4, 1.1)	0.40

* Full-mouth plaque score
† Full-mouth bleeding score

Legends to illustrations

Fig.1

- a) Upper left premolar ceramic crown on an implant placed 8 years before showing buccal soft tissue dehiscence.
- b) Lateral view. No signs of inflammation, even though a soft tissue concavity is detectable.
- c) Periapical radiograph showing stable interproximal bone level, with no signs of peri-implantitis.
- d) Split-thickness flap with no releasing vertical incisions.
- e) Connective tissue grafts taken from the maxillary tuberosity and U shaped.

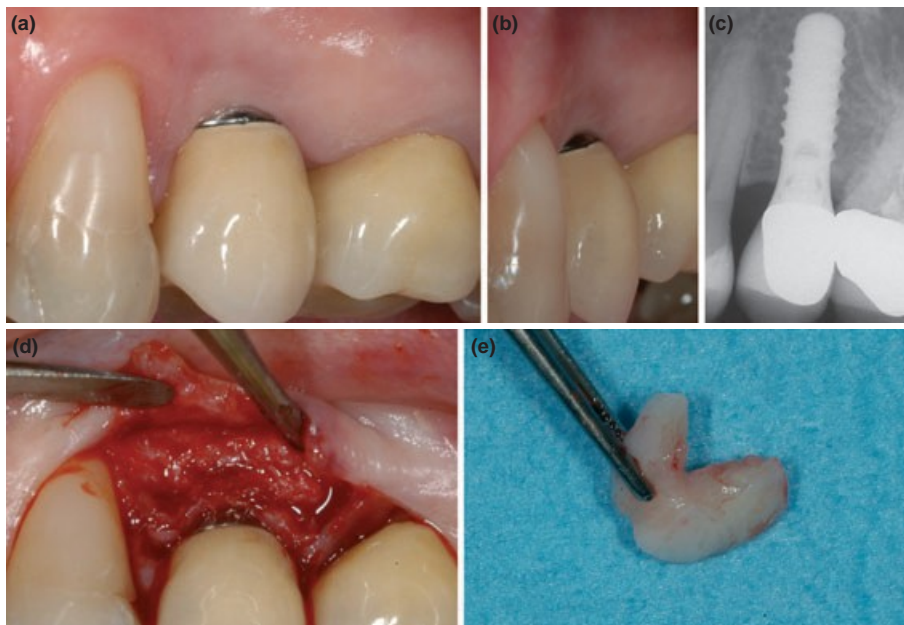


Fig.2

a) Adaptation of the graft to the recipient site and around the smooth collar of the implant.

b) The covering flap was sutured with interrupted Vycril sutures.

c) One year post-op: complete coverage of the dehiscence and increase of soft tissue thickness.

d) Lateral view, when the patient is smiling, shows the esthetic improvement.

