

AperTO - Archivio Istituzionale Open Access dell'Università di Torino

Benefits and drawbacks of open partial horizontal laryngectomies, Part A: Early-intermediate stage glottic carcinoma

This is the author's manuscript

Original Citation:

Availability:

This version is available <http://hdl.handle.net/2318/151933> since 2017-05-16T11:01:56Z

Published version:

DOI:10.1002/hed.23997

Terms of use:

Open Access

Anyone can freely access the full text of works made available as "Open Access". Works made available under a Creative Commons license can be used according to the terms and conditions of said license. Use of all other works requires consent of the right holder (author or publisher) if not exempted from copyright protection by the applicable law.

(Article begins on next page)



UNIVERSITÀ DEGLI STUDI DI TORINO

This is an author version of the contribution published on:

Questa è la versione dell'autore dell'opera:

Benefits and drawbacks of open partial horizontal laryngectomies, Part A: Early- to intermediate-stage glottic carcinoma.

Head Neck. 2016 Apr;38 Suppl 1:E333-40. doi: 10.1002/hed.23997.

The definitive version is available at:

La versione definitiva è disponibile alla URL:

<http://onlinelibrary.wiley.com/doi/10.1002/hed.23997/abstract>

Benefits and drawbacks of open partial horizontal laryngectomies, Part A: Early-intermediate stage glottic carcinoma

Giovanni Succo, MD¹, Erika Crosetti, MD², Andy Bertolin, MD³, Marco Lucioni, MD³,
Alessandra Caracciolo, MD¹, Valentina Panetta, MSc⁴, Andrea Elio Sprio, PhD⁵,
Giovanni Nicolao Berta, PhD⁵, and Giuseppe Rizzotto, MD³

Affiliations:

¹Otorhinolaryngology Service, Department of Oncology, San Luigi Gonzaga Hospital, University of Turin, Turin, Italy

²Otorhinolaryngology Service, Martini Hospital, Turin, Italy

³Otorhinolaryngology Service, Vittorio Veneto Hospital, Vittorio Veneto, Treviso, Italy

⁴L'altrastatistica srl, Consultancy and Training, Biostatistics Office, Rome, Italy

⁵Department of Clinical and Biological Sciences, University of Turin, Turin, Italy

Running title: Open partial horizontal laryngectomies

Key words: Open partial laryngectomy, supracricoid partial laryngectomy, supratracheal partial laryngectomy, glottis cancer, laryngeal cancer, TNM staging

Author to whom correspondence should be sent:

Erika Crosetti MD

ENT Department, Martini Hospital, Via Tofane 71, 10141 Turin, Italy

This article has been accepted for publication and undergone full peer review but has not been through the copyediting, typesetting, pagination and proofreading process which may lead to differences between this version and the Version of Record. Please cite this article as an 'Accepted Article', doi: 10.1002/hed.23997

This article is protected by copyright. All rights reserved.

Tel.: + 39 011-70952305

Fax: + 39 011-70952252

E-mail: erikacro73@yahoo.com

Acknowledgements

Sincere thanks to Professor AR Antonelli and Professor G Peretti for valuable suggestions and encouragement to continue research in the field of laryngeal oncology. AE Sprio was supported by private grants generously funded by “Ordre International des Anyssetiers, Commanderie du Piemont”.

Conflict of interest: There are no competing interests for this article

Author Contributions

Giovanni Succo, surgeon who performed the surgical procedures, study conception and design, drafting the article, final approval of the version to be published; Erika Crosetti, surgeon who performed the surgical procedures, study conception and design, final approval of the version to be published; Andy Bertolin, study conception and design, data collection; Marco Lucioni, surgeon who performed the surgical procedures, study conception and design; Alessandra Caracciolo, data collection; Valentina Panetta, data

analysis, statistical analysis; Andrea E. Sprio, data analysis, statistical analysis, drafting the article; Giovanni N. Berta, drafting the article, final approval of the version to be published; Giuseppe Rizzotto, surgeon who performed the surgical procedures, study conception and design, final approval of the version to be published.

Accepted Article

Abstract

Background. Laryngeal squamous cell carcinoma (SCC) accounts for 1.9% of cancers worldwide. Most of these are diagnosed in the early stages (T1-T2, N0). For these, a larynx preserving/conserving option is preferable. Beyond transoral laser microsurgery (TLM), open partial horizontal laryngectomy (OPHL) is a function-sparing surgical technique used to treat laryngeal SCC.

Methods. We retrospectively analyzed the clinical outcomes of 216 patients who underwent OPHL for glottic cT2 laryngeal cancer.

Results. Five-year overall survival, disease-specific survival, locoregional control, local control, laryngeal function preservation, and laryngectomy-free survival rates were 93.1%, 98.0%, 97.1%, 97.5%, 97.8% and 98.5%, respectively. Disease controls were significantly affected by previous treatment and type of surgery employed.

Conclusions. Although TLM for cT2 laryngeal cancer with unimpaired vocal cord mobility still represents a sound option, OPHL offers higher local control and laryngeal preservation rates for selected patients with impaired mobility of vocal cords combined with involvement of the paraglottic space.

Introduction

Laryngeal squamous cell carcinoma (SCC) accounts for 1.9% of cancers worldwide. Most of these are glottic (51%) of which a great many (up to 60%) are diagnosed in the early stages (T1-T2, N0, M0) as a result of noticeable voice changes that underlie lesions in true vocal cords.²⁻⁴ For these locally spread laryngeal tumors, a laryngeal function preserving option is preferable. As a consequence, the National Comprehensive Cancer Network Guidelines recommend the use of either radiotherapy or partial laryngectomy. However, Misono et al. recently highlighted greater overall survival and disease-specific survival in patients whose treatment included local surgery with respect to those who received radiotherapy alone. In particular, the surgical option includes either open neck partial laryngectomy and/or transoral laser microsurgery (TLM). The greater part of the former, especially in Europe, is represented by open partial horizontal laryngectomy (OPHL),⁵ whereas the latter is usually performed by carbon dioxide laser.⁶ The choice between an open neck or transoral approach is very challenging because of the extreme heterogeneity of the lesions and the range of patient-specific variables.

OPHL is able to partially spare laryngeal function without compromising locoregional control^{8, 9} reaching a good compromise between oncological radicality and functional outcome. To standardize the procedure, the European Laryngological Society recently proposed a classification of the more commonly adopted OPHL according to extent of resection (Type I – supraglottic, Type II – supracricoid, and Type III – supratracheal).

On the other hand, the advantages of TLM in terms of laryngeal preservation rate and early and faster recovery of laryngeal functions have already been reported, as well as the negative impact on local control for T3 lesions extending laterally to the thyroarytenoid (TA) muscle, with involvement of the paraglottic space (PGS).^{7, 11-14}

The heterogeneity in terms of local extent and prognosis of glottic cT2 tumors is well known. In particular, impaired vocal cord mobility remains a crucial issue in therapeutic planning. Even though accurately performed by new technologies, endoscopic evaluation is subjective and debated among specialists when distinguishing the different causes of vocal cord impairment such as bulky tumor, vocal muscle infiltration, PGS involvement, and crico-arytenoid joint invasion. Moreover, early assessment of PGS involvement represents another hot topic in the staging of glottic cancer, even with the most sophisticated imaging studies.

Therefore, when comparing clinical and pathological staging, according to the UICC/AJCC classification, a significant number of cases show an upstaging of the primary tumor from cT2 to pT3, resulting in false negatives at preoperative imaging. In light of this, in 2005, Peretti and colleagues proposed to sub-classify cT2 tumors into five pT subcategories in relation to the size, site, and patterns of superficial and submucosal diffusion analyzed by clinical, radiologic, surgical and pathological examinations.¹⁵ They demonstrated that unimodal endoscopic laser resection provides a good oncological outcome in the majority of cT2; in contrast, tumors upstaged as pT3 for involvement of the PGS, represent a completely different disease, which negatively influences prognosis.¹⁵

Based on these observations, we followed the staging policy and the sub-classification of cT2 proposed by Peretti and colleagues in a cohort of patients treated by OPHL, with the aim of emphasizing the role of OPHL in patients affected by T2 and selected T3, and comparing the oncological and functional outcomes with those obtained by TLM.

Hence, a multicentric retrospective outcomes analysis of 216 patients with glottic laryngeal SCC classified as cT2 and managed by Type II–III OPHLs is presented. The analysis was conducted over a 16-year period during which TLM or radiotherapy were applied as alternative therapeutic options.^{6, 16}

Material and methods

Patients

All patients were from the Hospital of Vittorio Veneto (Treviso) or the Martini Hospital of Turin (Italy). Selection was based on a routinely performed clinical assessment lasting 3 weeks prior to surgery, in order to evaluate the superficial and depth extent of the tumor, as previously described.⁸

Inclusion criteria were: histological diagnosis of glottic cT2 laryngeal SCC, with Karnofsky index higher than 80 (Table 1). Exclusion criteria were severe diabetes mellitus, severe bronchopulmonary chronic obstructive disease, neurological problems impairing the ability to expectorate and/or swallow, or severe cardiac disease. Advanced age, an important cut-off for relative surgical indication¹⁸, has not been considered, in itself, as an exclusion criterion.

After informed consent had been obtained, 216 patients with glottic squamous cell carcinoma, classified as cT2 according to the 2002 TNM classification system,¹⁹ underwent a modular function sparing surgical approach between 1 January 1995 and 31 December 2011. Thirty-nine patients (18.1%) included in the present analysis had been treated previously for laryngeal carcinoma by TLM (20/39, 51.3%), radiation therapy (12/39, 30.8%) or cordectomy (7/39, 17.9%).

Vocal fold mobility assessment resulted in 71 cases with normal vocal cord mobility, and 145 cases with impaired vocal cord mobility and mobile cricoarytenoid joint.

All patients were submitted to neck computed tomography (CT) or magnetic resonance imaging (MRI) to rule out infiltration of the cartilaginous framework and evaluate the extent of the pre-epiglottic space and/or paraglottic space.

The preoperative records, radiologic images as well as all surgical specimens were retrospectively reviewed to allow the reclassification of all cases, according to the

UICC/AJCC classification. Moreover, after the final histology, the entire cohort of cT2 were divided into five subtypes as suggested by Peretti and colleagues (Fig. 1).¹⁵

Surgery

Open neck procedures were classified according to the European Laryngological Society Classification: Type IIa (supracricoid partial laryngectomy/cricohyoidoepiglottopexy) = 76/216 (35.2%), Type IIa + ARY = 102/216 (47.2%), Type IIb (supracricoid partial laryngectomy/cricohyoidopexy) = 12/216 (5.55%), Type IIb + ARY = 12/216 (5.55%), Type IIIa (supratracheal partial laryngectomy/tracheohyoidoepiglottopexy) = 1/216 (0.5%), Type IIIa + CAU = 13/216 (6.0%), where “+ARY” represents the removal of one arytenoid and “+CAU” the removal of one cricoarytenoid unit.

The indications adopted for Type II OPHLs were the classical ones, applied according to tumor extent, now being accepted and advocated by numerous authors.^{5, 20-24} Although definitions for the Type III OPHLs were only recently introduced, the precise indications for tumors at the cT2 classification were lesions with anterior or lateral subglottic extension, spreading downward above the conus elasticus and reaching the cricoid ring.

In all patients, resection margins were examined intraoperatively with frozen sections: when positive, the resection was expanded until the margins were negative. The margins of the surgical specimen were always checked again upon definitive pathology. The interventions were conducted using the principles of a modular approach. The resection is always prepared in standard mode and the larynx is opened from the side less affected by disease. At this point, under visual control, the subsites involved are removed and the resection can be enlarged as follows: (1) Type IIa/b → Type IIa/b + ARY; (2) Type IIIa → Type IIIa + CAU; (3) Type IIa → Type IIb; (4) Type IIa + ARY → Type IIIa + CAU.

Neck dissection (ND), graded according to the American Academy of Otolaryngology – Head and Neck Surgery Foundation classification, was performed in 204 patients (94.4%),

and was monolateral in 168/204 (82.4%) and bilateral in 36/204 (17.6%) cases. ND was elective (ND levels II–IV) in 198 cN0 patients (97.1%) and curative (ND levels II–V + Internal Jugular Vein in one case) in 6 cN>0 patients (2.9%). In nine patients, whole level VI or unilateral paratracheal lymph node clearance was added. No ND was performed in an additional 12/216 patients (5.55%, elderly and/or cN0 disease or in previously treated neck) (Table 1).

Postoperative care

All patients were monitored for early complications (local and general) and late sequelae. Patients underwent the same rehabilitation protocol, apart from those with serious early complications. The postoperative protocol was in accordance with our previous report. Briefly, this was: (1) insertion of an uncuffed tracheal cannula and beginning of phonation (days 1 to 4); (2) intermittent occlusion of the tracheostomy with saline-soaked gauze and starting of feeding without the tracheal cannula in position (days 4 to 6); (3) nasogastric (NG) tube removal as soon as a good level of swallowing of both solids and liquids was achieved (day 6 onwards). Postoperative aspiration was graded in accordance with Pearson's Scale (0 = none; I = occasional cough but no clinical problems; II = constant cough worsening with meal or swallowing; III = pulmonary complications).²⁶

Adjuvant treatments

On the basis of pathological findings (pN+ and/or extracapsular spread extension, positive margins), 9 patients (4.2%) were subjected to adjuvant radiotherapy. The indications for adjuvant therapy were: 5 N+ (1 pN1 and 4 pN2, all with extracapsular spread) and 4 cases with positive margins.

A large volume encompassing the primary site and all draining lymph nodes was irradiated with a dose of up to 54 Gy/2 Gy. Regions at higher risk for malignant dissemination

received a 12-Gy boost (total 66 Gy/2 Gy – range 62–68 Gy). Six of 9 patients (5 pN+ with extracapsular spread, and 1 multiple positive margins toward cricoid) also received 100 mg/m² cisplatin on days 1, 22, and 43 of the course of radiotherapy.²⁷

● *Larynx oncologic and functional assessment*

All patients were followed for a mean period of 5.71 years with periodic videolaryngoscopic examinations, scheduled every 3 months in the first 3 years and with decreasing frequency in the subsequent period.

During the 5 postoperative years, Pearson's Scale evaluation was repeated and larynx functional status was evaluated with the Performance Status Scale.²⁸ The latter is a simple, practical, clinician-rated assessment tool consisting of three subscales: speech comprehension, normalcy of diet and eating in public, graduated from 0 to 100 on the basis of predefined parameters.

Statistical methods

Overall survival (OS), disease-free survival (DFS), disease-specific survival (DSS), locoregional control (LRC), local control (LC), laryngectomy-free survival (LFS) and laryngeal function preservation (LFP), were assessed by means of Kaplan-Meier curves. Log-rank and Gehan-Breslow-Wilcoxon tests (for early events) were used to compare Kaplan-Meier estimates between groups (cT2 subtypes, clinical history of previous treatment, type of surgery, and age). The end points considered were obtained as the length of time from the date of diagnosis to: OS) the date of death; DFS) the date of the first recurrence; DSS) the date of death from the disease; LRC) the date of the first locoregional recurrence; LC) the date of the first local recurrence; LFS) the date of total laryngectomy; LFP) the date of total laryngectomy or presence of tracheostomy, NG tube, gastrostomy feeding, or non-intelligible voice.

All analyses were performed with GraphPad Prism version 5.00 (GraphPad Software, San Diego, CA, USA), with $p < 0.05$ as the statistically significant cut-off.

RESULTS

Pathology, survival and disease control

Comparison between clinical findings (CT-scan or MRI) and pathological staging proved up-staging on the primary tumor from cT2 to pT3 in 36 cases (16.7%). The review of radiologic images after the definite histology showed a suspect PGS involvement in only 21 patients. Pathology reports indicated close margins (<2 mm) in 9/216 cases (4.2%) and positive margins in 4/216 cases (1.9%). Six patients (2.8%) developed recurrence between 11 and 33 months. The recurrences were observed in 5 out of 180 pT2 (2.8%) and 1 out of 36 pT3 (2.8%).

In particular, in subtype I, no recurrences were observed. In subtype II, one local recurrence was observed among 13 patients. The patient was successfully treated by TLM and was free from recurrence at 46 months. In the subtype III, 3 out of 40 patients (7.5%) experienced local (1), regional (1), or locoregional (1) recurrences. Salvage therapy for local recurrence included total laryngectomy and adjuvant chemoradiation therapy. The first patient died of other disease 15 months later; the second patient showed a second recurrence 22 months later and died of the disease 8 months later, while the third is free of disease at 32 months. Among the patients with regional recurrence (neck), both were previously classified as pN0. At the time of primary resection, both received monolateral neck dissection. One recurrence was observed at the VI level. Recurrences in the neck were treated with surgery and radiation therapy; one patient died as a result of regional recurrences 22 months later, and one is alive and disease-free. In the subtype IV, 1 out of 116 patients (0.9%) experienced both local and regional recurrences. The patient was

previously classified as pN0 and was treated with surgery, including total laryngectomy, and radiation therapy; the patient died as a result of distant metastases. In the subtype V (cT2/pT3), among 36 patients, there was 1 patient (previously classified as pN0) suffering from both local and regional recurrences (2.7%). Salvage therapy included total laryngectomy and adjuvant chemoradiation therapy, but the patient died of the disease 14 months later. Overall, lymph node metastases were detected in 9/204 patients (4.4%), of whom 4 (2.0%) had multiple metastases.

The 5-year OS, DSS, LRC and LC were 93.1%, 98.0%, 97.1%, and 97.5%, respectively (Fig. 2). A total of 13 patients had died: 4 of them for the laryngeal cancer and 9 from unrelated causes (Table 2). As DFS and LRC were overlapping in our patient cohort, we only reported LRC in our analyses.

Although DSS prevalence 5 years after surgery was not affected by any of the variables analyzed, the history of previous treatment and the employment of more invasive surgery provided small but significant impairments in both local and regional control (the former also as an early event, $p < 0.01$, Gehan-Breslow-Wilcoxon test) (Fig. 3).

Postoperative course and morbidity

Overall acute complications during hospitalization occurred in 18 out 216 patients (8.3%) and there were no perioperative deaths. The mean hospitalization time for patients with acute complications was 29 ± 6 days, which was significantly longer than that for patients without acute complications (19 ± 4 days). Late sequelae following discharge were observed in 26 out of 216 cases (12.0%) (Table 3). All were successfully treated with TLM (8/10, 80%), and injective laryngoplasty using Vox-implants, which successfully treated dysphagia (2/10, 20%).

Laryngeal function preservation

At 5 years after surgery, LFP was maintained in 97.8% of patients whereas the use of total laryngectomy was avoided in 98.5% (Fig. 4). In addition, we evaluated whether pT subtypes, previous treatment, age, and the type of surgery could affect LFP or even the use of total laryngectomy (Table 4). None of these variables were able to significantly affect the preservation of laryngeal function. Nevertheless, the history of previous treatment induced a slight but significant early enhancement in the number of total laryngectomies within the first 2 years after the OPHL ($p < 0.05$, Gehan-Breslow-Wilcoxon test).

After the first post-operative month, normal swallowing (Pearson's scale Grade 0) was achieved in 134 patients (62.0%), Grade I and II were observed in 43 (19.9%) and 35 (16.2%) patients, respectively, while aspiration pneumonia (AP) (Pearson's Grade III) was recorded in 4 patients (1.9%). After the second year, a satisfactory degree of laryngeal function (i.e. List's scale: eating in public >50 , understandability of speech >50 , normalcy of diet >70)²⁸ was achieved in 179 out of 211 patients without local disease (84.8%). Out of the 211 patients evaluated for subjective aspiration with the Pearson's Scale,²⁶ 95 (45.0%) had no aspiration (Grade 0), 94 (44.5%) had occasional cough without clinical problems (Grade I), 20 (9.5%) had constant cough that worsened during meals (Grade II), and 2 patients (0.9%) had frequent pulmonary complications (Grade III). All patients had the NG tube or gastrostomy removed. The NG tube remained in place for an average of 18.5 days (range 9–130 days).

Overall, AP was observed in 6/216 cases (2.8%), 4 cases during hospitalization and 2 cases during follow-up. Completion of total laryngectomy for persistent aspiration was not required in any patient. Two patients were subjected to the endoscopic procedure of injective laryngoplasty using Vox implants, which successfully resolved the dysphagia.

The mean time to intermittent occlusion of the tracheostomy was 22.6 days (range 5–166 days), and the average time to tracheostomy closure was 71.4 days (range 21–198 days).

In our protocol, progressive closure of the tracheostomy is preferred, and occurs spontaneously in the majority of patients following occlusion. For patients, especially in the first weeks after discharge, this leads to a sensation of greater safety concerning minor episodes of food inhalation, which are relatively frequent. When the tracheostomy has almost closed, minor plastic surgery can then be performed.

DISCUSSION

In the early 1970s, by systematically applying whole organ sections in the study of total laryngectomy specimens, Kirchner, Oloffson and colleagues well described the patterns of spread of laryngeal cancer.^{30, 31} PGS invasion is a critical point of weakness, above all when the lesion reaches the base and roof of the ventricle: this constitutes the gateway for the tumor spreading toward the thyroarytenoid space and cricoarytenoid joint. These lesions, even though clinically defined as cT2, are actually pT3, showing a more aggressive behavior.

According to the literature on transoral laser treatment for intermediate staged glottic cancer (T2/T3), TLM has shown a significant increase of recurrences in those cases with involvement of PGS and impairment and/or fixation of the true vocal cords.¹³⁻¹⁵ In a study of 55 patients with glottic cT2, Peretti et al.¹⁵ concluded that TLM can be considered effective when the pT2 stage has been confirmed. By contrast, in cT2/pT3 patients, after the first transoral resection that allows the correct pT staging, additional treatment should always be considered. In a cohort of 167 patients treated by TLM, Ambrosch⁶ reported a local control rate of 74% and a laryngectomy rate of 13.4% in 97 patients staged pT2 while a 5-year local control rate of 68% and laryngectomy rate of 14.3% was observed in 70 patients staged pT3. Canis et al. reported a retrospective study of 391 previously untreated patients affected by glottic cT2/T3: they noted a 93% larynx preservation rate among pT2a and 83% among pT2b and pT3 tumors.⁷

Preoperative under-staging, in the glottic cT2 category, occurs with some frequency because of misinterpretation of radiologic data among patients with suspected involvement of PGS; the lack of sensitivity on early PGS involvement is greater using CT-scan compared to MRI.

● Therefore, intermediate stage glottic cancer requires patients for TLM to be selected very carefully, reserving open neck surgery or non-surgical treatments for patients in whom an up-staging of the lesion is presumed.

In our series, upstaging of cT2 to pT3 was found in specimens from 16.7% of cases, in whom early invasion of the PGS was not detected by imaging before the operation. The misdiagnosis of selected cT2 lacking the assessment of the PGS may possibly explain the gap in terms of local control between OPHLs and TLM as therapeutic options.

Our data show that the outstanding oncological outcomes obtained by OPHL reproduced by other authors^{31,32} justify the open-neck procedures in terms of local control, particularly in selected pT3 lesions. In fact, in this cohort, any variables analyzed have shown a negative impact on the end points evaluated.

In contrast, in some cases after OPHL, the functional outcomes in terms of complication rates and hospitalization times are negatively influenced. Persistent slight dysphagia and aspiration pneumonia still represent major complications in patients undergoing OPHLs, especially Type III, while voice is significantly deteriorated, and generally quite hoarse and breathy.^{20, 21, 23} Moreover, the functional outcome of OPHLs, especially for extended interventions (Type IIb, Type III), is generally associated with slower recovery and longer hospitalization compared to TLM.

For this reason, despite the excellent oncological results, the surgeon faced with intermediate staged tumors must consider TLM as alternative for all pT2, especially in elderly and fragile patients not fit for OPHL. In the case of high risk lesions (subtype V → cT2/pT3), TLM could play a role as a definitive staging procedure with outstanding

precision in microscopically detecting deep neoplastic invasion and consequently, possible patterns of cancer progression.

When discussing conservative surgical options with the patient affected by a cT2 tumor with unimpaired mobility of vocal cords, he should be clearly informed that TLM is equally as safe as open neck surgery, with a more rapid recovery and with less impact on quality of life, even though further procedures, for example, re-resection and/or open neck surgery should be kept in mind in the case of upstaging to pT3.

In conclusion, our results demonstrate that, in every case of glottic cT2, OPHL with a modular approach can be considered to be a very safe option. Bearing in mind that OPHLs lead to more dysfunctional sequelae compared to TLM, the open-neck options should essentially be aimed at carefully selected patients affected by glottic cT2 with impaired mobility of vocal cords and suspected extension to the PGS.



References

1. Ferlay J, Soerjomataram I, Ervik M, et al. GLOBOCAN 2012 v1.0. In: Cancer Incidence and Mortality Worldwide: IARC CancerBase No 11 [Internet]. Lyon, France: International Agency for Research on Cancer; 2013.
2. Hoffman HT, Porter K, Karnell LH, et al. Laryngeal cancer in the United States: changes in demographics, patterns of care, and survival. *Laryngoscope* 2006;116:1-13.
3. Misono S, Marmor S, Yueh B, Virnig BA. Treatment and survival in 10,429 patients with localized laryngeal cancer: a population-based analysis. *Cancer* 2014;120:1810-7.
4. Feng Y, Wang B, Wen S. Laser surgery versus radiotherapy for T1-T2N0 glottic cancer: a meta-analysis. *ORL J Otorhinolaryngol Relat Spec* 2011;73:336-42.
5. Rizzotto G, Succo G, Lucioni M, Pazziaia T. Subtotal laryngectomy with tracheohyoidopexy: a possible alternative to total laryngectomy. *Laryngoscope* 2006;116:1907-17.
6. Ambrosch P. The role of laser microsurgery in the treatment of laryngeal cancer. *Curr Opin Otolaryngol Head Neck Surg* 2007;15:82-8.
7. Canis M, Martin A, Ihler F, et al. Transoral laser microsurgery in treatment of pT2 and pT3 glottic laryngeal squamous cell carcinoma - results of 391 patients. *Head Neck* 2014;36:859-66.
8. Rizzotto G, Crosetti E, Lucioni M, et al. Oncological outcomes of supratracheal laryngectomy: A critical analysis. *Head Neck* 2014.
9. Schindler A, Fantini M, Pizzorni N, et al. Swallowing, voice, and quality of life after supratracheal laryngectomy: Preliminary long-term results. *Head Neck* 2014.
10. Succo G, Peretti G, Piazza C, et al. Open partial horizontal laryngectomies: a proposal for classification by the working committee on nomenclature of the European Laryngological Society. *Eur Arch Otorhinolaryngol* 2014;271:2489-96.
11. Blanch JL, Vilaseca I, Caballero M, Moragas M, Berenguer J, Bernal-Sprekelsen M. Outcome of transoral laser microsurgery for T2-T3 tumors growing in the laryngeal anterior commissure. *Head Neck* 2011;33:1252-9.
12. Hartl DM, Ferlito A, Brasnu DF, et al. Evidence-based review of treatment options for patients with glottic cancer. *Head Neck* 2011;33:1638-48.
13. Lee HS, Chun BG, Kim SW, et al. Transoral laser microsurgery for early glottic cancer as one-stage single-modality therapy. *Laryngoscope* 2013;123:2670-4.
14. Peretti G, Piazza C, Del Bon F, et al. Function preservation using transoral laser surgery for T2-T3 glottic cancer: oncologic, vocal, and swallowing outcomes. *Eur Arch Otorhinolaryngol* 2013;270:2275-81.
15. Peretti G, Piazza C, Mensi MC, Magnoni L, Bolzoni A. Endoscopic treatment of cT2 glottic carcinoma: prognostic impact of different pT subcategories. *Ann Otol Rhinol Laryngol* 2005;114:579-86.
16. Chen AY, Schrag N, Hao Y, et al. Changes in treatment of advanced laryngeal cancer 1985-2001. *Otolaryngol Head Neck Surg* 2006;135:831-7.
17. Karnofsky DA, Burchenal JH. The clinical evaluation of chemotherapeutic agents in cancer. In: MacLeod CM, editor. Evaluation of chemotherapeutic agents. New York: Columbia University Press; 1949. p. 191-205.
18. Schindler A, Favero E, Capaccio P, Albera R, Cavalot AL, Ottaviani F. Supracricoid laryngectomy: age influence on long-term functional results. *Laryngoscope* 2009;119:1218-25.
19. TNM Classification of Malignant Tumours. Sixth ed. New York: Wiley-Liss; 2002.
20. de Vincentiis M, Minni A, Gallo A, Di Nardo A. Supracricoid partial laryngectomies: oncologic and functional results. *Head Neck* 1998;20:504-9.

21. Laccourreye O, Brasnu D, Biacabe B, Hans S, Seckin S, Weinstein G. Neo-adjuvant chemotherapy and supracricoid partial laryngectomy with cricothyroidopexy for advanced endolaryngeal carcinoma classified as T3-T4: 5-year oncologic results. *Head Neck* 1998;20:595-9.
22. Lima RA, Freitas EQ, Dias FL, et al. Supracricoid laryngectomy with cricothyroidopexy for advanced glottic cancer. *Head Neck* 2006;28:481-6.
23. Pinar E, Imre A, Calli C, Oncel S, Katilmis H. Supracricoid partial laryngectomy: analyses of oncologic and functional outcomes. *Otolaryngol Head Neck Surg* 2012;147:1093-8.
24. Rizzotto G, Crosetti E, Lucioni M, Succo G. Subtotal laryngectomy: outcomes of 469 patients and proposal of a comprehensive and simplified classification of surgical procedures. *Eur Arch Otorhinolaryngol* 2012;269:1635-46.
25. Robbins KT, Clayman G, Levine PA, et al. Neck dissection classification update: revisions proposed by the American Head and Neck Society and the American Academy of Otolaryngology-Head and Neck Surgery. *Arch Otolaryngol Head Neck Surg* 2002;128:751-8.
26. Pearson BW. Subtotal laryngectomy. *Laryngoscope* 1981;91:1904-12.
27. Bernier J, Domenge C, Ozsahin M, et al. Postoperative irradiation with or without concomitant chemotherapy for locally advanced head and neck cancer. *N Engl J Med* 2004;350:1945-52.
28. List MA, Ritter-Sterr C, Lansky SB. A performance status scale for head and neck cancer patients. *Cancer* 1990;66:564-9.
29. Hirano M, Kurita S, Matsuoka H, Tateishi M. Vocal fold fixation in laryngeal carcinomas. *Acta Otolaryngol* 1991;111:449-54.
30. Kirchner JA. Fifteenth Daniel C. Baker, Jr, memorial lecture. What have whole organ sections contributed to the treatment of laryngeal cancer? *Ann Otol Rhinol Laryngol* 1989;98:661-7.
31. Olofsson J, Lord IJ, van Nostrand AW. Vocal cord fixation in laryngeal carcinoma. *Acta Otolaryngol* 1973;75:496-510.
32. Vilaseca I, Ballesteros F, Martinez-Vidal BM, Lehrer E, Bernal-Sprekelsen M, Blanch JL. Quality of life after transoral laser microresection of laryngeal cancer: a longitudinal study. *J Surg Oncol* 2013;108:52-6.

Figure legends

Fig. 1. Graphical representation of T2 glottic carcinoma subtypes: (I) pT2 with superficial supraglottic extension to the base and roof of the ventricle and/or ventricular band; (II) pT2 with superficial lateral subglottic extension; (III) pT2 with anterior supracommissural and/or subcommissural extension; (IV) pT2 with deep thyroarytenoid (TA) muscle infiltration; (V) pT3 for superior and/or inferior PGS invasion lateral to the thyroarytenoid muscle.

Fig. 2. End point analysis (overall survival, disease-specific survival, locoregional control, and local control) of the patient cohort using Kaplan–Meier curves.

Fig. 3. Patient cohort stratification for pT subtypes (first column), history of previous treatment (second column), age (third column), and type of surgery (fourth column) using Kaplan–Meier curves. The end points considered were (from top to bottom) disease-specific survival, locoregional control, and local control. * $p < 0.05$; ** $p < 0.01$.

Fig. 4. End point analysis of laryngeal function preservation and laryngectomy-free survival in the patient cohort using Kaplan–Meier curves.

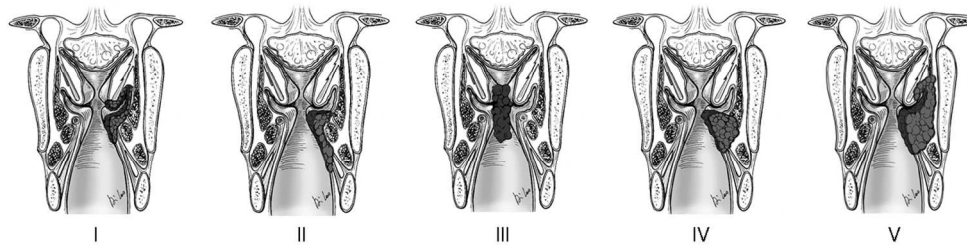


Figure 1. Graphical representation of T2 glottic carcinoma subtypes: (I) pT2 with superficial supraglottic extension to the base and roof of the ventricle and/or ventricular band; (II) pT2 with superficial lateral subglottic extension; (III) pT2 with anterior supracommissural and/or subcommissural extension; (IV) pT2 with deep thyroarytenoid (TA) muscle infiltration; (V) pT3 for superior and/or inferior PGS invasion lateral to the thyroarytenoid muscle.
189x51mm (300 x 300 DPI)

Accepted A

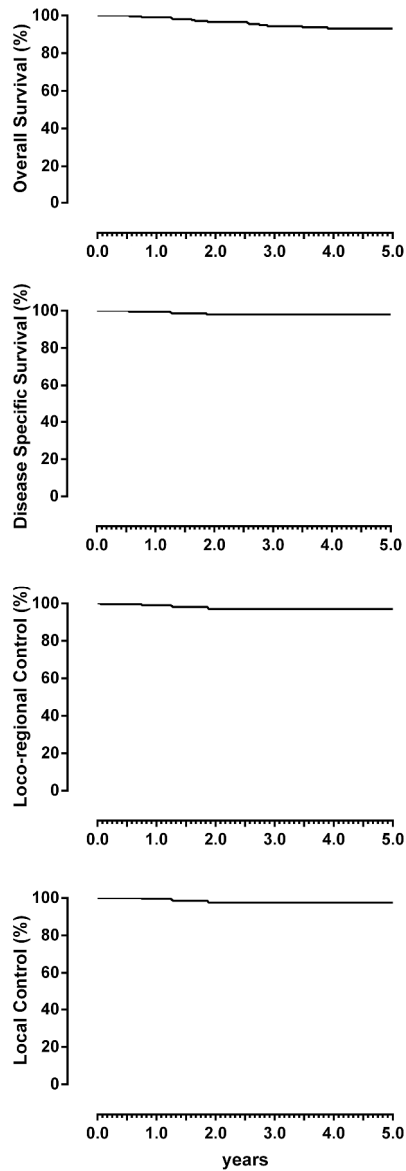


Figure 2. End point analysis (overall survival, disease specific survival, locoregional control, and local control) of the patient cohort using Kaplan–Meier curves
211x560mm (600 x 600 DPI)

AC

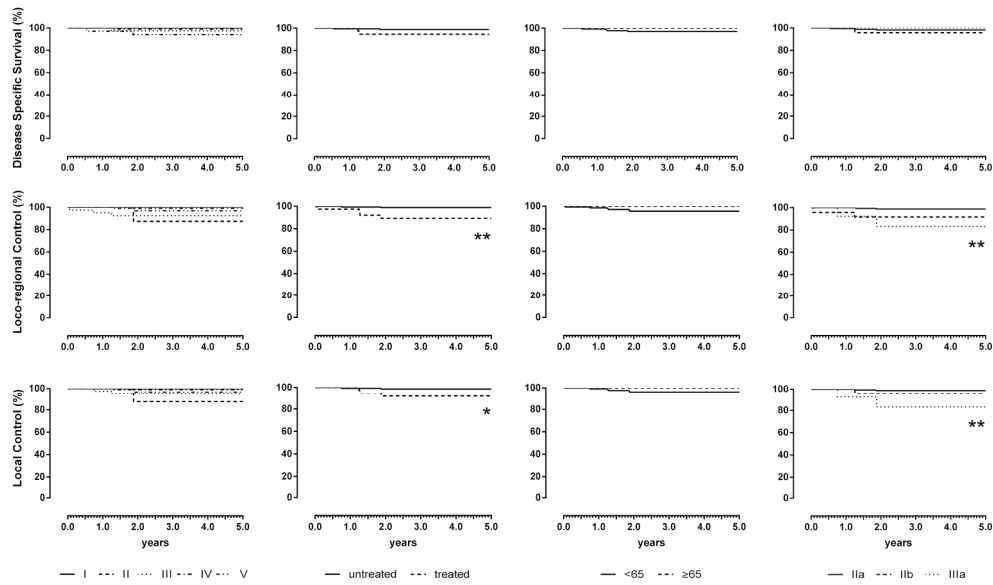


Figure 3. Patient cohort stratification for pT subtypes (first column), history of previous treatment (second column), age (third column), and type of surgery (fourth column) using Kaplan–Meier curves. The end points considered were (from top to bottom) disease-specific survival, locoregional control, and local control.

*p < 0.05; **p < 0.01.

112x66mm (600 x 600 DPI)

Accepte

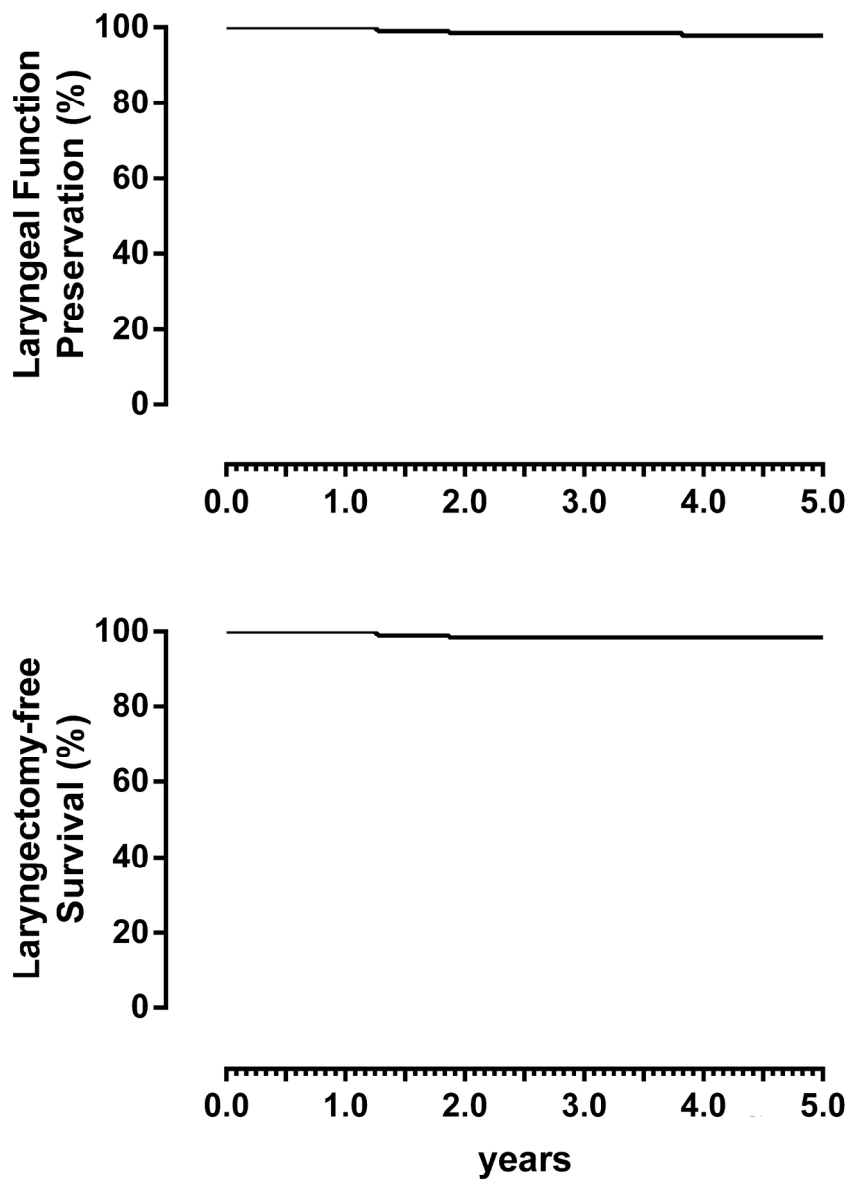


Figure 4. End point analysis of laryngeal function preservation and laryngectomy-free survival in the patient cohort using Kaplan–Meier curves
97x126mm (600 x 600 DPI)

AC

Table 1. Characteristics of the 216 patients undergoing open partial horizontal laryngectomies according to age, sex, Karnofsky performance status, pathological grade and pT sub-category

	No. of Patients (%)
Age, years	
Mean	59.8±9.9
Range	23–87
Sex	
Male	201/216 (93.1%)
Female	15/216 (6.9%)
Karnofsky Performance Status	
100	128/216 (59.3%)
90	65/216 (30.1%)
80	23/216 (10.6%)
Pathological Grade	
pT2	180/216 (83.3%)
pT3	36/216 (16.7%)
pN0	195/204 (95.6%)
pN1	5/204 (2.4%)
pN2	4/204 (2.0%)
Level VI pN+	1/9 (11.1%)
pT Sub-category	
I	11/216 (5.1%)
II	13/216 (6.0%)
III	40/216 (18.5%)
IV	116/216 (53.7%)
V	36/216 (16.7%)

Table 2: Cause of death

	No. of Patients (%)
Laryngeal cancer	4/216 (1.8%)
Post-operative death	0/216 (0.0%)
II Primary Cancer	4/216 (1.8%)
Unrelated to laryngeal cancer	5/216 (2.3%)
Total deaths	13/216 (6.0%)

Accepted Article

Table 3. Acute postoperative complications and late sequelae

	No. of patients (%)
Acute complications	
Cervical bleeding	5/216 (2.3%)
Aspiration pneumonia	4/216 (1.8%)
Wound infection	5/216 (2.3%)
Others	4/216 (1.8%)
Late sequelae	
Laryngeal soft tissue stenosis	23/216 (10.6%)
Aspiration pneumonia	2/216 (0.9%)
Dyspnea	1/216 (0.5%)

Accepted Article

Table 4. Five-years incidences and Kaplan-Meier estimates stratified LFP and LFS

	No. of Patients	LFP		LFS	
		Incidence (%)	Estimates	Incidence (%)	Estimates
<i>pT subtypes</i>					
I	11/216	11/11 (100%)	100%	11/11 (100%)	100%
II	13/216	13/13 (100%)	100%	13/13 (100%)	100%
III	40/216	38/40 (95.0%)	93.8%	39/40 (97.5%)	97.4%
IV	116/216	115/116 (99.1%)	99.1%	115/116 (99.1%)	99.1%
V	36/216	35/36 (97.2%)	96.9%	35/36 (97.2%)	96.9%
<i>Previous treatment</i>					
Untreated	177/216	175/177 (98.9%)	98.6%	176/177 (99.4%)	99.4%
Treated	39/216	37/39 (94.9%)	94.6%	37/39 (94.9%)	* 94.6%
<i>Age (years)</i>					
<65	144/216	140/144 (97.2%)	94.7%	141/144 (97.9%)	100%
≥65	72/216	72/72 (100%)	97.8%	72/72 (100%)	100%
<i>OPHL</i>					
Type IIa	178/216	175/178 (98.3%)	98.0%	176/178 (98.9%)	98.8%
Type IIb	24/216	23/24 (95.8%)	95.8%	23/24 (95.8%)	95.8%
Type IIIa	14/216	14/14 (100%)	100%	14/14 (100%)	100%

Log-Rank test. * = $p < .05$.