

AperTO - Archivio Istituzionale Open Access dell'Università di Torino

Comparison of results between chitosan hollow tube and autologous nerve graft in reconstruction of peripheral nerve defect: An experimental study

This is the author's manuscript

Original Citation:

Availability:

This version is available <http://hdl.handle.net/2318/1522195> since 2016-06-13T16:57:47Z

Published version:

DOI:10.1002/micr.22418

Terms of use:

Open Access

Anyone can freely access the full text of works made available as "Open Access". Works made available under a Creative Commons license can be used according to the terms and conditions of said license. Use of all other works requires consent of the right holder (author or publisher) if not exempted from copyright protection by the applicable law.

(Article begins on next page)



UNIVERSITÀ DEGLI STUDI DI TORINO

This is an authorversion of the contribution published on:

Questa è la versione dell'autore dell'opera:

Microsurgery. 2015 Apr 22. doi: 10.1002/micr.22418. [Epub ahead of print]

The definitive version is available at:

La versione definitiva è disponibile alla URL:

<http://onlinelibrary.wiley.com/doi/10.1002/micr.22418/abstract;jsessionid=603F8F3F8CBFB3959BC38272D3D349E9.f03t01>

COMPARISON OF RESULTS BETWEEN CHITOSAN HOLLOW TUBE AND AUTOLOGOUS NERVE GRAFT IN RECONSTRUCTION OF PERIPHERAL NERVE DEFECT: AN EXPERIMENTAL STUDY

YUVAL SHAPIRA, M.D.,¹ MICHAEL TOLMASOV, Ph.D.,¹ MOSHE NISSAN, Ph.D.,¹ EVGENIY REIDER, M.D.,²
AKIVA KOREN, M.MED.SC., D-ABNM,¹ TALY BIRON, M.SC.,¹ YIFAT BITAN, M.MED.SC.,¹ MIRA LIVNAT, Ph.D.,¹
GIULIA RONCHI, Ph.D.,³ STEFANO GEUNA, M.D., Ph.D.,³ and SHIMON ROCHKIND, M.D., Ph.D.^{1*}

Object: This study evaluated a chitosan tube for regeneration of the injured peripheral nerve in a rodent transected sciatic nerve model in comparison to autologous nerve graft repair. **Methods:** Chitosan hollow tube was used to bridge a 10-mm gap between the proximal and distal ends in 11 rats. In the control group, an end-to-end coaptation of 10-mm long autologous nerve graft was performed in 10 rats for nerve reconstruction. **Results:** SFI showed an insignificant advantage to the autologous group both at 30 days (P 5 0.177) and at 90 days post procedure (P 5 0.486). Somato-sensory evoked potentials (SSEP) and compound muscle action potentials (CMAP) tests showed similar results between chitosan tube (group 1) and autologous (group 2) groups with no statistically significant differences. Both groups presented the same pattern of recovery with 45% in group 1 and 44% in group 2 (P 5 0.96) showing SSEP activity at 30 days. At 90 days most rats showed SSEP activity (91% vs.80% respectively, P 5 0.46). The CMAP also demonstrated no statistically significant differences in latency (1.39 ms in group 1 vs. 1.63 ms in group 2; P 5 0.48) and amplitude (6.28 mv vs. 6.43 mv respectively; P 5 0.8). Ultra-sonography demonstrated tissue growth inside the chitosan tube. Gastrocnemius muscle weight showed no statistically significant difference. Histo-morphometry of the distal sciatic nerve, 90 days post reconstructive procedure, showed similar number of myelinated fibers and size parameters in both groups (P <0.05). **Conclusions:** Chitosan hollow tube used for peripheral nerve reconstruction of rat sciatic nerve showed similar results in comparison to autologous nerve grafting. ^{V^C} 00:000-000, 2015.

Peripheral nerve injuries represent a major cause of morbidity and disability worldwide, as well as lead to substantial costs to society at individual and national levels. It has been estimated that peripheral nerve injuries affect 2.8% of all trauma patients, many of whom acquire life-long disability.¹ The annual incidence of peripheral nerve injuries in developed countries has been reported as 13 to 23 out of 100,000 persons.²⁻⁴

Recovery following severe peripheral nerve injury is often dismal despite the inherent capability for axonal regeneration.³ Autologous nerve grafts are considered the gold standard treatment in cases of nerve defect, although often not providing satisfactory results. Moreover, autologous nerve donor may cause related neurological morbidity at the donor site, including possible neuroma formation.⁵

The gold standard autograft repair of the damaged peripheral nerve is far from optimal and is often disappointing.⁶ Interposition of nerve scaffold⁷ whether cellular allograft or an artificial acellular conduit⁸ is an alternative procedure to the use of grafts. Most repair scaffolds consist of a hollow tube made of polymeric materials such as silicone, biologic materials such as collagen, or biodegradable polymers.^{5,9-13} The use of nerve guidance channels (tubes), sutured in between the proximal and distal nerve stumps, has been actively pursued to obviate the need for the second procedure at the donor site and to obtain better regenerative results in comparison to the autologous nerve graft. Entubulation repair cause less surgical trauma at the repair site,¹⁴ and may decrease the possibility for neuroma formation. Moreover, guidance channels may assist in directing axons from the proximal to the distal stump without any interference from imperfectly aligned degenerating fascicles of the nerve graft or the closely apposed distal stump and reduce axonal staggering.¹⁴ Guidance channels minimize the infiltration of fibrous scar tissue, which may further hinder axonal regeneration,¹⁵⁻¹⁷ while at the same time maximize the accumulation of soluble factors produced by the nerve stumps, and may also act as scaffolds for different filling materials which can further support regeneration. Nevertheless, tubulization with simple guides usually fails when bridging relatively long gaps of 6 mm in mice,^{18,19} 15 mm in rats²⁰ and 30 mm in primates.^{21,22} There are several hollow nerve tubes currently available for clinical use, which are applied for repair of small-diameter nerves with nerve defects of up to 2–3 cm.²³⁻²⁶ These nerve tubes (including Neurotube [Synovis; polyglycolic acid], Neuro-lac [Ascension; poly lactide-co-ε-caprolactone], and Neura-Gen [Integra; type-I collagen]) are made of different biomaterials and therefore differ in their physical properties. Due to the small nerve diameter and limited length, these conduits are clinically used for the repair of digital nerve injuries and do not benefit the majority of patients suffering from severe peripheral nerve injury. Severe nerve injuries with massive loss defect are currently treated with autograft repair, however, despite the advanced microsurgical techniques, functional recovery is far from being optimal and often disappointing.²⁷ Therefore, innovative regenerative therapies for injured peripheral nerve that simultaneously potentiate axonal regeneration, promote selective target reinnervation and modulate central reorganization are needed.²⁸ This study investigates, from a pre-clinical perspective, an artificial nerve device designed to reconstruct injured peripheral nerves.

MATERIALS AND METHODS

This study was performed in accordance with approved protocols by the Institutional Animal Care and adhered strictly to the Animal Care guidelines. The animals were housed 2 per cage with a 12-hour light/dark cycle, with free access to food and water.

Preparation of Chitosan Tube

Chitosan is partially or fully deacetylated form of chitin, which is found widely in nature in the exoskeletons of arthropods, shells of crustaceans, the cuticles of insects and the cell walls of fungi.^{29,30} It is made up of linked D-glucosamine and N-acetyl-D-glucosamine sub units. It is used in biomedical applications because of its biocompatibility, low toxicity, biodegradability, and structural similarity to natural glycosaminoglycans.

Chitosan-based scaffolds, developed and manufactured by Medovent GmbH, Germany, were used in this study.

Experiment Design and Surgical Technique

The model for this in vivo study consisted of 21 female Wistar rats, weighing 200–250 g each. The rats were operated to establish a complete sciatic nerve defect of 10 mm, immediately followed by nerve reconstruction employing composite chitosan-based hollow tube (n = 11) or autologous nerve graft (n = 10). General anesthesia was induced with intra-peritoneal injection of xylazine (15 mg) and ketamine (50 mg). The procedure was performed using a high magnification surgical microscope.

In group I, the left sciatic nerve was exposed and separated from biceps femoris and semimembranosus muscles beginning from the area of branches to the glutei and hamstring muscles and distally to the trifurcation into peroneal, tibial, and sural nerves. The sciatic nerve was then transected and a 5 mm nerve segment was removed. A 12 mm chitosan hollow tube was placed between the proximal and the distal parts of the transected nerve for reconstruction, enabling the nerve to enter the tube 1 mm on each side, while providing a 10 mm gap between the proximal and distal ends. Two 9-0 non-absorbable sutures were used to anchor the tube to the epineurium at the proximal and distal nerve stumps (Fig. 1). The muscular, subcutaneous and skin layers were closed.

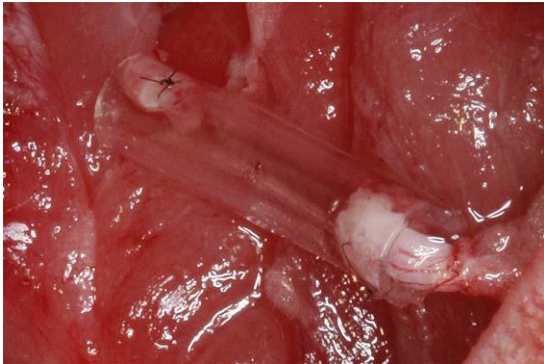


Figure 1. Nerve reconstruction using chitosan-based hollow tube.

In group II, the left sciatic nerve was exposed as described above and then sharply incised with micro scissors at the femur level below the superior gluteal nerve and above the division of the sciatic nerve to the tibial nerve and the peroneal nerve. A nerve segment of 10 mm was inverted. Immediately thereafter, end-to-end coaptation was performed using 2 to 3 non-absorbable 10-0 sutures. Coaptation of nerve fascicles was carried out to preserve all the fascicles within the epineurial sac. The muscular, subcutaneous and skin layers were closed.

Pre-operative evaluation and post-operative follow-up was performed and consisted of functional motor assessment of the sciatic nerve utilizing SFI, electrophysiological assessment of nerve conductivity, applying SSEP studies and CMAP. All assessment of SFI, SSEP, and CMAP were carried out in a blinded manner without disclosure of the different groups to the evaluating team.

During the observational period, imaging studies employing ultrasonography were carried out for evaluation of nerve regeneration inside the chitosan hollow tubes.

Sciatic functional index. SFI is a widely described test which helps to evaluate the functionality of operated sciatic nerve in rats in compared to the opposite intact limb.^{31–36} The rat was placed on a paper track after dipping the hind limbs in non-toxic ink. The imprints from the ambulating hind limbs enabled us to measure the maximal footprint length (PL), maximal distance between fingers 1-5 (IT) and fingers 2-4 (TS), from both normal (N) and operated (E) legs. The SFI value was calculated using Bain's formula.³⁷

All rats were evaluated for SFI at baseline (prior to surgery), as well as at 30 and 90 days after surgical reconstruction. The data were collected in a blinded manner and the groups were revealed to the examiner only after completion of the study.

Electrophysiology. Electrophysiology studies, SSEPs and CMAPs, were recorded using the Dantec “KEYPOINT” workstation. Conductivity of the sciatic nerve and spinal cord was studied by stimulation of the sci-atic nerve at the level of the tarsal joint with simultaneous recording from the skull over the somatosensory cortex. The SSEP recordings were performed on all rats in a blinded manner before surgery and at 30 and 90 days following the surgical procedure. During the electrophysiological study the rats were anesthetized using xylazine (15 mg) and ketamine (50 mg). Two subcutaneous needle electrodes were inserted under the skin of the scalp with the active electrode over the somatosensory cortex along the midline and reference electrode between the eyes. The ground electrode was placed subcutaneously on the dorsal back. The sciatic nerve was stimulated by two polarized electrodes placed on the lateral aspect of the tarsal joint. An average was generated of at least three hundred stimulation pulses of 0.1 msec in duration at a rate of 3 Hz. The stimulus intensity was set on 1.5–3.5 mA until a slight twitching of the limb was noted. The appearance of an evoked potential in two consecutive tests as a response to a stimulus was considered positive. Since SSEP pose substantial technical difficulties and more subjected to variations of anesthesia and level of central synaptic efficacy,³⁸ CMAP was added at 90 days to aid and validate electrophysiological studies. CMAP testing was performed on left hind limb and just prior to harvesting of the reconstructed nerves. CMAPs were done by applying supra-maximal stimulation (maximal response 120%) of the proximal sciatic nerve with electrodes placed at the sciatic notch and recording electrodes in the gastrocnemius muscle.

The data were collected in a blinded manner and the groups were revealed to the examiner only after completion of the study.

Ultrasound imaging . Ultrasound imaging enables in vivo periodic assessment of the tube. All rats were anesthetized during the sonographic examination. Ultra-sound examinations were performed on a unit equipped with color Doppler capabilities using 7–15 MHz linear transducer yielding an axial resolution of 0.2–0.4 mm. The sonographic scanning technique included longitudinal and transverse sections with a standard scanning gel. Identification of the chitosan tube on the ultrasound image was based on the recognition of a hyper-echoic structure of tubular shape in the longitudinal axis and circular shape on transverse section. This imaging modality has not been previously described for real-time in vivo evaluation of peripheral nerve-tube reconstruction. In this work we utilized ultrasonography for evaluation of the proximal and distal nerve stumps, integrity of the implanted chitosan tube, the nerve-tube relationship and demonstration of tissue proliferation inside the chitosan tube. Ultrasonography was used for imaging of the chitosan reconstruction group at 30 and 90 days after surgery.

Histology and morphometrical analysis. Regenerated sciatic nerve samples were harvested and fixed for 2 hour in a solution of 2.5% glutaraldehyde in Sorensen buffer 0.1M added with 0,5% sucrose. Samples were then washed in Sorensen buffer 0.1M added with 1,5% sucrose, post-fixed in 2% osmium tetroxide, dehydrated with ethanol and embedded in a mixture of Araldite res-ins following Glauerts' procedure.

The distal part of sciatic nerve samples were processed 5 mm distally to the area of neurorrhaphy (tube or distal nerve coaptation) for quantitative morphometry of myelinated nerve fibers. Series of 2-mm thick semi-thin transverse sections were cut using a Leica Ultracut UCT ultramicro-tome (Leica Microsystems, Wetzlar, Germany) and stained by Toluidine blue. Stereology was carried out on a DM4000B microscope equipped with a DFC320 digital camera and an IM50 image manager system (Leica Micro-systems, Wetzlar, Germany). Systematic random sampling and D-dissector were adopted using a protocol previously described.³⁹ Total fiber number, fibers' and axons' diameter and myelin thickness were estimated.

Muscle weight assessment. Immediately following harvest of the regenerated nerve tissue, the gastrocnemius muscle was removed on both sides (intact and operated hind limbs) and the wet muscle weight was recorded.

Statistical analysis. Data analysis was carried out on all 21 rats; 11 rats underwent reconstruction using chitosan tube, and 10 rats were treated according to auto-logous nerve graft reconstruction model. Statistical analysis and calculations were done using MatLab software (Ver. 2008b, The MathWorks, Inc.). Non-parametric statistics were used in this study. Hence, all figures are presented with Median 6 Mad. All significance levels were calculated using a Mann-Whitney U test and a Wilcoxon signed-rank test. SSEP responses were analyzed as categorical parameters using χ^2 test.

RESULTS

For evaluation of nerve reconstruction using chitosan hollow tube versus standard of care reconstruction with autologous nerve graft, we have used the following research measures: behavioral (SFI), electrophysiological (SSEP, CMAP), nerve imaging studies (US), histomorphometrical analysis, and muscle weights. To identify ongoing changes, we have conducted measurements at different time periods (0, 30, and 90 days).

Maintenance of bodyweight or rate of weight gain is one of the indicators of an animal's state of health.⁴⁰ We have found that 30 days after surgery the rats weight gain was minimal (6 g, 10.5 g; P 5 0.413), which might indicate stress related to the postsurgical healing process. After this initial phase, the rats continued gaining weight (19.5 g versus 22.5 gr; P 5 0.338) until the end of the experiment (45 gr vs. 55.4 gr; P 5 0.172). This weight gaining tendency was found to be identical in both chitosan tube and autologous nerve graft groups (Fig. 2).

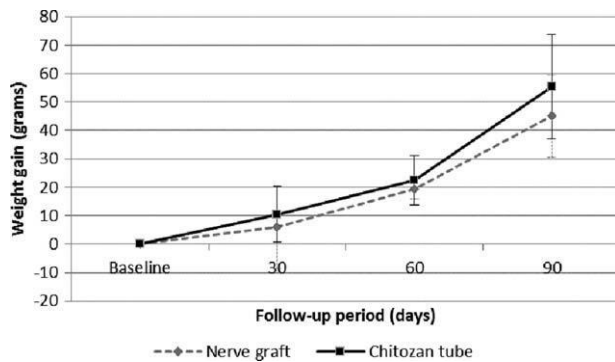


Figure 2. Weight gain related to the weight at the time of surgery, measured at day 30 and day 90 post-operatively. Average weight gain and standard deviation is presented for each group.

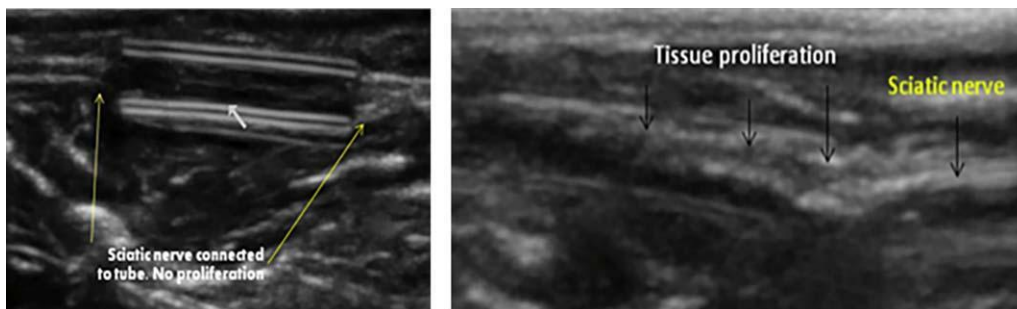


Figure 3. Ultrasound imaging of in vivo chitosan tube. Left image demonstrates the tube 30 days following surgery. Right image demonstrates the tube 90 days following surgery, with tissue proliferation inside the degraded tube. Changes in the ecogenicity of the tube can be appreciated, which may correlate with degradation process.

SFI showed no statistically significant difference between the chitosan tube reconstruction (group 1) and autologous nerve graft (group 2) groups both at the 30-days point (287.1 \pm 9.1 vs. 284.5 \pm 14.5, $P = 0.177$, respectively) and the 90-days point (274.2 \pm 16.9 vs. 266.8 \pm 10.7, $P = 0.486$, respectively).

Both groups presented the same pattern of recovery, with about half showing some SSEP activity at 30 days (45% group 1 vs. 44% group 2, $P = 0.96$). One rat from group 2 was not included in this evaluation. At 90 days, most rats (91% group 1 vs. 80% group 2, $P = 0.46$) showed SSEP activity. CMAP testing was carried out 90 days after surgery. No statistically significant difference was found between the groups both in latency (1.39 ms vs. 1.63 ms; $P = 0.48$) and amplitude (6.28 mv vs. 6.43 mv; $P = 0.8$).

Ultrasonography imaging performed during the observational period demonstrated progressive tissue growth inside the tube and no signs of conduit collapse or compression along the post-operative period (Fig. 3). The operated sciatic nerve was exposed 90 days after surgery (Fig. 4). The corresponding gastrocnemius muscle was harvested for evaluation of muscle weight. As expected, there was significant difference in gastrocnemius muscle weight between operated left limb and the intact right limb (0.6 vs. 1.3, $P < 0.001$). No statistically significant difference was noted between the study group (chitosan hollow tube) and the control group (autologous nerve graft) (0.7 vs. 0.6, $P = 0.3$) (Fig. 5).

Representative high resolution light micrographs of semi-thin sections of the regenerated sciatic

nerves are shown in Figure 6. Axonal regeneration occurred in both experimental groups (A: autograft, B: chitosan tube) with good regeneration pattern. Toluidine blue stained transverse nerve sections showed microfascicles typical of regenerated nerves. Figure 7 shows the results of the stereological assessment of myelinated fibers number (A) and diameter, myelin thickness and g-ratio (B) in the two experimental groups. The total number of myelinated nerve fibers was comparable between the two groups ($P_{0.005}$) (15867 63318 in the autograft group vs. 15,30262,872 in the chitosan group). Also the size parameters were not statistically different between the two experimental groups ($P_{0.05}$) (fiber diameter: 3.75 ± 0.36 vs. 3.41 ± 0.25 ; myelin thickness: 0.65 ± 0.05 vs. 0.65 ± 0.02 ; g-ratio: 0.58 ± 0.24 vs. 0.57 ± 0.11).

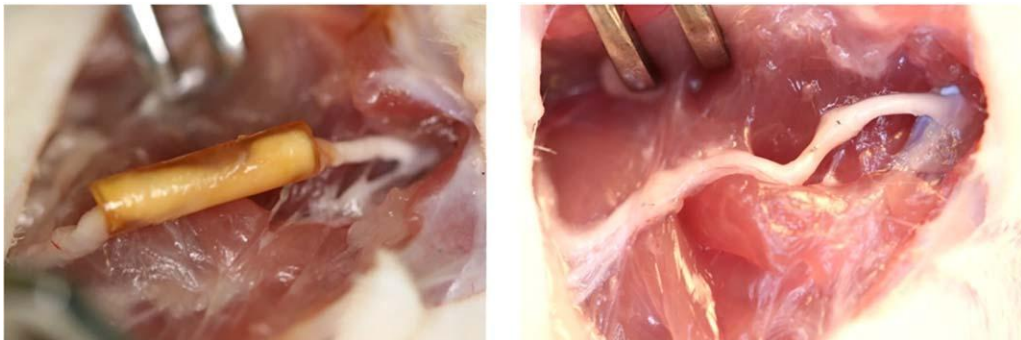


Figure 4. Reconstructed nerve after 90 days. Left image demonstrates left sciatic nerve growth inside the hollow chitosan tube is seen. No visual signs of inflammatory response around the tube are seen. Right image shows reconstructed left sciatic nerve using autologous nerve graft.

DISCUSSION

Peripheral nerve injuries are a significant cause of morbidity. Despite the inherent ability of the peripheral nervous system to regenerate, functional recovery after severe nerve injury is often unsatisfactory. Biohybrid project, consisting of research and development groups across Europe, was established with the aim of developing an implant that will promote better nerve regeneration, which will allow functional recovery without the need of harvesting nerve for transplant.^{41,42} The purpose of this study, conducted as part of the Biohybrid project, was to evaluate reconstruction of nerve loss with chitosan hollow tube compared to the accepted standard of care reconstruction consisting of autologous nerve grafting. The main focus was to provide pre-clinical evidence from the perspective of clinical employment of chitosan hollow tubes.

Previous research publications using various tubes for nerve reconstruction, and some of which are in clinical use, demonstrated functional recovery.^{7,9,26,43} The

required properties of an optimal nerve conduit should be biodegradable, permeable, flexible but non-collapsible, simple to handle and suture, transparent and capable of being sterilized without compromising its physical properties.²⁶ Some of the limitations of artificial nerve conduits relate to the absence of Schwann cells to support nerve regeneration which are present in the nerve autograft. Also hollow tubes lack internal supporting structures which may facilitate nerve growth.

Chitosan is an attractive material because of its mechanical strength, transparency, porosity, biodegradability, and biocompatibility without causing inflammatory response which may impair regeneration.^{30,44} Several studies have referred to the potential benefits of chitosan in the design of controlled drug release systems.^{45,46} The excellent biocompatibility of chitosan, together with its specific interaction with components of the extracellular matrix and growth factors, led to its use in tissue engineering.⁴⁷ It was also observed that due to its cationic nature, chitosan covalently coupled

to agarose gel enhanced neurite extension from dorsal root ganglia.⁴⁸ Previous in-vitro studies have demonstrated improved neural cell survival and neurotrophic factors upregulation in Schwann cells associated with chitosan.^{49,50} Several in vivo studies have demon-

strated the use of chitosan conduits for peripheral nerve regeneration in different animal models,⁴⁴ most of which involved different filling materials such as polyglycolic acid filaments or nanofibers.

Rosales-Cortes et al. analyzed the immunological response of a chitosan conduit in sciatic nerve regeneration of the axotomized sciatic nerve in dogs.⁵¹ Results showed that chitosan implants did not induce immunostimulation or immunodepression. Another study conducted by Matsumoto et al. investigated chitosan mesh tubes (C-tubes) in regenerating transected thoracic sympathetic nerve (n 5 3) and phrenic nerve (n 5 3) in beagle dogs and concluded that C-tubes can facilitate the regeneration of damaged sympathetic and phrenic nerves and restore lost functions.⁵² Patel et al. evaluated functional recovery of sciatic nerves in rats repaired with chitosan nerve guide using video assisted gait analysis.⁵³ Other outcome measurements included histology and muscle weight. The authors concluded that based on video-gait analysis, histology and muscle weight improved functional recovery was seen as a result of the use of chitosan nerve guides. Finally, a recent study by Gonzalez-Perez et al. showed that chitosan tubes may permit regeneration also for longer gap in the rat model.⁵⁴

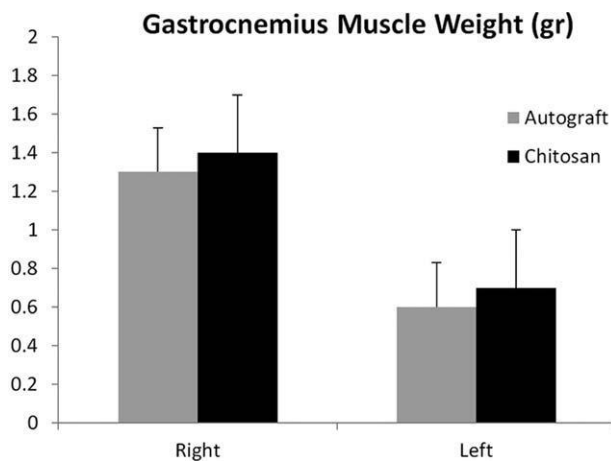


Figure 5. Gastrocnemius muscle weight in grams as measured 90 days after surgery: Right - intact limb; Left - operated limb.

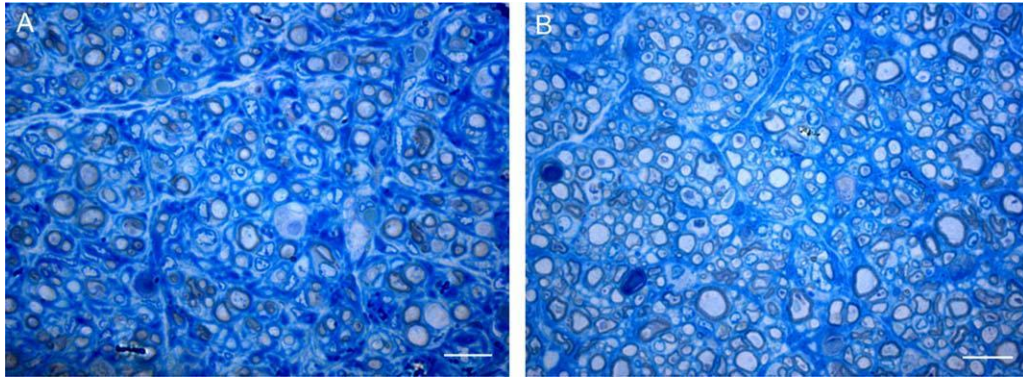


Figure 6. Light microscopy images of nerve sections stained with Toluidine Blue. A: Transverse section of the distal part of the repaired nerve with nerve autograft. B: Transverse section of the distal part of the repaired nerve with chitosan conduit.

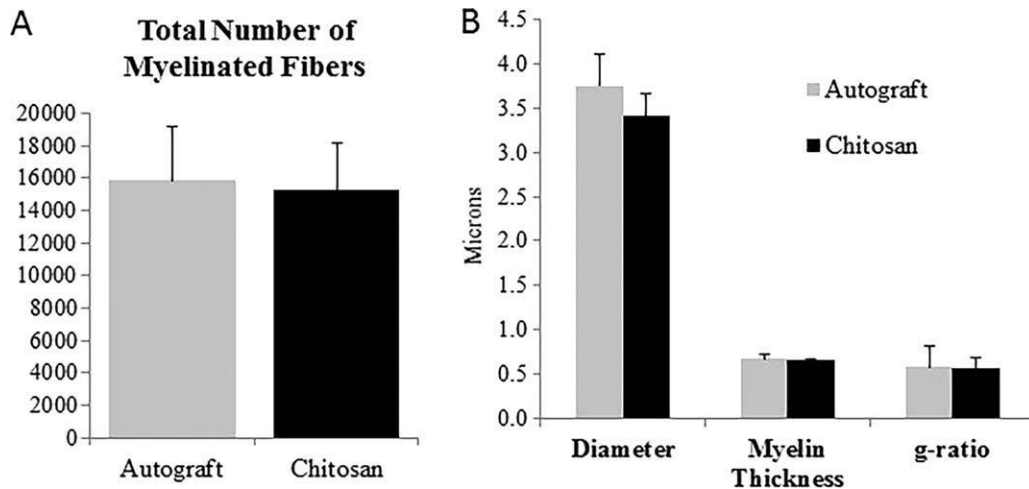


Figure 7. Histograms showing the results of morphometrical evaluation of nerve regeneration (A, number of myelinated fiber in the distal part of the sciatic nerve; B, fibers diameter, myelin thickness and g-ratio) in autograft and chitosan group. Data are represented as mean-6 standard deviation.

Two clinical case reports utilizing chitosan tube for reconstruction of the median nerve were published.^{55,56} Fan et al. described repair of a 3.5-cm long median nerve defect at the elbow using chitosan/polyglycolic acid nerve conduit.⁵⁵ The same group reported again on repair of a 3-cm long median nerve defect in the distal forearm using the same nerve conduit.⁵⁶ In both cases, three years later, improvement in motor and sensory function was noted. These two case reports do not add significant evidence to support routine clinical use of chitosan tubes due to the scientific limitation of these studies.

In the current study, we evaluate functional recovery and histomorphometrical outcome of chitosan tube reconstruction versus autograft repair and this is the first experimental study where imaging study was utilized in order to demonstrate the relationship between the implanted tube and regenerating tissue during the observational period. In vivo real-time imaging allows assessment of the physical properties of the implanted material, including tube detachment, collapse of the scaffold and external compression.

In this study, it has been demonstrated that after 90 days, functional and electrophysiological outcomes were comparable between the chitosan tube reconstruction group and autologous nerve graft group. Muscle weight assessment and histomorphometry also demonstrated comparable results in the two groups with similar axon numbers and myelin thickness. Ultrasonography of the chitosan

tube during the observational period did not identify detachment of the tube and neural stumps, nor external tissue compression or collapse. Nerve growth inside the tube was identified after 90 days.

Real-time imaging utilizing ultrasonography is under-used in the experimental environment considering its added value for evaluating the relationship of the reconstructed nerve and surrounding tissue, and its relative availability.

CONCLUSION

This study evaluated nerve regeneration through chitosan tube versus autologous nerve graft and found no statistically significant difference. Peripheral nerve reconstruction of the sciatic nerve in rats using chitosan hollow tubes is comparable with gold standard autologous nerve graft, with the inherent potential of treating large nerve gaps and also functioning as a scaffold for filling material which may support nerve regeneration.

Further study, currently being performed, will focus on nerve regeneration utilizing chitosan tube with different filling materials.

REFERENCES

Noble J, Munro CA, Prasad VS, Midha R. Analysis of upper and lower extremity peripheral nerve injuries in a population of patients with multiple injuries. *J Trauma* 1998;45:116–122.

Asplund M, Nilsson M, Jacobsson A, von Holst H. Incidence of traumatic peripheral nerve injuries and amputations in Sweden between 1998 and 2006. *Neuroepidemiology* 2009;32:217–228.

Evans GR. Peripheral nerve injury: A review and approach to tissue engineered constructs. *Anat Rec* 2001;263:396–404.

Taylor CA, Braza D, Rice JB, Dillingham T. The incidence of peripheral nerve injury in extremity trauma. *Am J Phys Med Rehabil* 2008;87:381–385.

Battiston B, Geuna S, Ferrero M, Tos P. Nerve repair by means of tubulization: Literature review and personal clinical experience comparing biological and synthetic conduits for sensory nerve repair. *2005;25:258–267.*

Chalfoun CT, Wirth GA, Evans GRD. Tissue engineered nerve constructs: Where do we stand? *J Cell Mol Med* 2006;10:309–317.

Belkas JS, Shoichet MS, Midha R. Peripheral nerve regeneration through guidance tubes. *Neurol Res* 2004;26:151–160.

Tang P, Kilic A, Konopka G, Regalbuto R, Akelina Y, Gardner T. Histologic and functional outcomes of nerve defects treated with acellular allograft versus cabled autograft in a rat model. *Microsurgery* 2013;33:460–467.

Rochkind S, Astachov L, el-Ani D, Hayon T, Graif M, Barsky L, Alon M, Odvak I, Nevo Z, Shahar A. Further development of reconstructive and cell tissue-engineering technology for treatment of complete peripheral nerve injury in rats. *Neurol Res* 2004;26:161–166.

Ijkema-Paassen J, Jansen K, Gramsbergen A, Meek MF. Transection of peripheral nerves, bridging strategies and effect evaluation. *Bio-materials* 2004;25:1583–1592.

Battiston B, Raimondo S, Tos P, Gaidano V, Audisio C, Scevola A, Perroteau I, Geuna S. Chapter 11: Tissue engineering of peripheral nerves. *Int Rev Neurobiol* 2009; 87:227–249.

Deumens R, Bozkurt A, Meek MF, Marcus MA, Joosten EA, Weis J, Brook GA. Repairing injured

peripheral nerves: Bridging the gap. *Prog Neurobiol* 2010;92:245–276.

Jiang X, Lim SH, Mao H-Q, Chew SY. Current applications and future perspectives of artificial nerve conduits. *Exp Neurol* 2010; 223:86–101.

Seckel BR. Enhancement of peripheral nerve regeneration. *Muscle Nerve* 1990;13:785–800.

Sadek AF, Fouly EH, Hamdy M. Functional and electrophysiological outcome after autogenous vein wrapping of primary repaired ulnar nerves. 2014;34:361–366.

Lee J-Y, Parisi TJ, Friedrich PF, Bishop AT, Shin AY. Does the addition of a nerve wrap to a motor nerve repair affect motor outcomes? 2014;34:562–567.

Siemionow M, Uygur S, Ozturk C, Siemionow K. Techniques and materials for enhancement of peripheral nerve regeneration: A literature review. 2013;33:318–328.

Butt M, Verdú E, Labrador RO, Vilches JJ, Forés J, Navarro X. Influence of physical parameters of nerve chambers on peripheral nerve regeneration and reinnervation. *Exp Neurol* 1996;137:26–33.

Gómez N, Cuadras J, Butt M, Navarro X. Histologic assessment of sciatic nerve regeneration following resection and graft or tube repair in the mouse. *Restor Neurol Neurosci* 1996;10:187–196.

Lundborg G, Dahlin LB, Danielsen N, Gelberman RH, Longo FM, Powell HC, Varon S. Nerve regeneration in silicone chambers: Influence of gap length and of distal stump components. *Exp Neurol* 1982;76:361–375.

Mackinnon SE, Dellon AL. A study of nerve regeneration across synthetic (maxon) and biologic (collagen) nerve conduits for nerve gaps up to 5 cm in the primate. *J Reconstr Microsurg* 1990;6:117–121.

Krarup C, Archibald SJ, Madison RD. Factors that influence peripheral nerve regeneration: An electrophysiological study of the monkey median nerve. *Ann Neurol* 2002; 51:69–81.

Bertleff MJOE, Meek MF, Nicolai J-. PA. A prospective clinical evaluation of biodegradable neurolac nerve guides for sensory nerve repair in the hand. *J Hand Surg Am* 2005;30:513–518.

Schlosshauer B, Dreesmann L, Schaller H-E, Sinis N. Synthetic nerve guide implants in humans: A comprehensive survey. *Neuro-surgery* 2006;59:740–747. discussion 747–748.

Weber RA, Breidenbach WC, Brown RE, Jabaley ME, Mass DP. A randomized prospective study of polyglycolic acid conduits for digital nerve reconstruction in humans. *Plast Reconstr Surg* 2000; 106:1036–1045. discussion 1046–1048.

De Ruyter GCW, Malessy MJA, Yaszemski MJ, Windebank AJ, Spinner RJ. Designing ideal conduits for peripheral nerve repair. *Neurosurg Focus* 2009;26:E5

Meek MF, Coert JH, Robinson PH. Poor results after nerve grafting in the upper extremity: Quo vadis? 2005;25:396–402.

Scholz T, Krichevsky A, Sumarto A, Jaffurs D, Wirth GA, Paydar K, Evans GR. Peripheral nerve injuries: An international survey of current treatments and future perspectives. *J Reconstr Microsurg* 2009;25:339–344.

Madhally SV, Matthew HW. Porous chitosan scaffolds for tissue engineering. *Biomaterials* 1999;20:1133–1142.

Haipeng G, Yinghui Z, Jianchun L, Yandao G, Nanming Z, Xiufang Z. Studies on nerve cell affinity of chitosan-derived materials. *J Biomed Mater Res* 2000;52:285–29

- De Medinaceli L, Freed WJ, Wyatt RJ. An index of the functional condition of rat sciatic nerve based on measurements made from walking tracks. *Exp Neurol* 1982;77:634–643.
- Hare GM, Evans PJ, Mackinnon SE, Best TJ, Bain JR, Szalai JP, Hunter DA. Walking track analysis: A long-term assessment of peripheral nerve recovery. *Plast Reconstr Surg* 1992;89:251–258.
- Hare GM, Evans PJ, Mackinnon SE, Best TJ, Midha R, Szalai JP, Hunter DA. Walking track analysis: Utilization of individual foot-print parameters. *Ann Plast Surg* 1993;30:147–153.
- Reynolds JL, Urbanchek MS, Asato H, Kuzon WM Jr. Deletion of individual muscles alters rat walking-track parameters. *J Reconstr Microsurg* 1996; 12:461–466.
- Varej~ao AS, Meek MF, Ferreira AJ, Patr_icio JA, Cabrita AM. Func-tional evaluation of peripheral nerve regeneration in the rat: Walking track analysis. *J Neurosci Methods* 2001;108:1–9.
- Walker JL, Evans JM, Meade P, Resig P, Sisken BF. Gait-stance duration as a measure of injury and recovery in the rat sciatic nerve model. *J Neurosci Methods* 1994;52:47–52.
- Bain JR, Mackinnon SE, Hunter DA. Functional evaluation of com-plete sciatic, peroneal, and posterior tibial nerve lesions in the rat. *Plast Reconstr Surg* 1989;83:129–138.
- Navarro X, Udina E. Chapter 6: Methods and protocols in peripheral nerve regeneration experimental research: Part III-electrophysiological evaluation. *Int Rev Neurobiol* 2009;87:105–126.
- Geuna S, Tos P, Battiston B, Guglielmone R. Verification of the two-dimensional disector, a method for the unbiased estimation of density and number of myelinated nerve fibers in peripheral nerves. *Ann Anat* 2000;182:23–34.
- Clark JD, Rager DR, Calpin JP. Animal well-being. III. An over-view of assessment. *Lab Anim Sci* 1997;47:580–585.
- Grothe C, Haastert-Talini K, Freier T, Navarro X, Dahlin LB, Salgado A, Rochkind S, Shahar A, Pinto LF, Hildebrandt M, Geuna S. BIOHYBRID - biohybrid templates for peripheral nerve regeneration. *J Peripheral Nerv Syst* 2012;17:220–222.
- Haastert-Talini K, Grothe C. Electrical stimulation for promoting peripheral nerve regeneration. *Int Rev Neurobiol* 2013;109:111–124.
- Tyner TR, Parks N, Faria S, Simons M, Stapp B, Curtis B, Sian K, Yamaguchi KT. Effects of collagen nerve guide on neuroma forma-tion and neuropathic pain in a rat model. *Am J Surg* 2007;193:e1–e6.
- Gnavi S, Barwig C, Freier T, Haastert-Talini K, Grothe C, Geuna S. The use of Chitosan-based scaffolds to enhance regeneration in the nervous system. *Int Rev Neurobiol* 2013;109:1–62.
- Felt O, Buri P, Gurny R. Chitosan: A unique polysaccharide for drug delivery. *Drug Dev Ind Pharm* 1998;24:979–993.
- Mattioli-Belmonte M, Gigante A, Muzzarelli RA, Politano R, De Benedittis A, Specchia N, Buffa A, Biagini G, Greco F. NN-dicar-boxymethyl chitosan as delivery agent for bone morphogenetic pro-tein in the repair of articular cartilage. *Med Biol Eng Comput* 1999; 37:130–134.
- Suh JK, Matthew HW. Application of chitosan-based polysaccharide biomaterials in cartilage tissue engineering: A review. *Biomaterials* 2000;21:2589–2598.
- Dillon GP, Yu X, Bellamkonda RV. The polarity and magnitude of ambient charge influences three-dimensional neurite extension from DRGs. *J Biomed Mater Res* 2000;51:510–519.

Hsu S, Lu PS, Ni H-C, Su C-H. Fabrication and evaluation of microgrooved polymers as peripheral nerve conduits. *Biomed Micro-devices* 2007;9:665–674.

50. Konofaos P, Ver Halen J. Nerve repair by means of tubulization: Past, present, future. *J Reconstruct Microsurg* 2013;29: 149–164.

Rosales-Cortés M, Peregrina-Sandoval J, Bañuelos-Pineda J, Sarabia-Estrada R, Gómez-Rodiles CC, Albarrán-Rodríguez E, Zaitseva GP, Pita-López ML. Immunological study of a chitosan prosthesis in the sciatic nerve regeneration of the axotomized dog. *J Biomater Appl* 2003;18:15–23.

Matsumoto I, Kaneko M, Oda M, Watanabe G. Repair of intra-thoracic autonomic nerves using chitosan tubes. *Interact Cardiovasc Thorac Surg* 2010;10:498–501.

Patel M, Vandevord PJ, Matthew H, Wu B, DeSilva S, Wooley PH. Video-gait analysis of functional recovery of nerve repaired with chitosan nerve guides. *Tissue Eng* 2006;12:3189–3199.

Gonzalez-Perez F, Cobianchi S, Geuna S, Barwig C, Freier T, Udina E, Navarro X. Tubulization with chitosan guides for the repair of long gap peripheral nerve injury in the rat. 2014.

Fan W, Gu J, Hu W, Deng A, Ma Y, Liu J, Ding F, Gu X. Repairing a 35-mm-long median nerve defect with a chitosan/PGA artificial nerve graft in the human: A case study. 2008;28: 238–242.

Gu J, Hu W, Deng A, Zhao Q, Lu S, Gu X. Surgical repair of a 30 mm long human median nerve defect in the distal forearm by implantation of a chitosan-PGA nerve guidance conduit. *J Tissue Eng Regen Med* 2012;6:163–168.