

AperTO - Archivio Istituzionale Open Access dell'Università di Torino

**Pathology of the Adrenal Cortex: a Reappraisal of the Past 25 Years Focusing on Adrenal Cortical Tumors.**

**This is the author's manuscript**

*Original Citation:*

*Availability:*

This version is available <http://hdl.handle.net/2318/152584> since

*Published version:*

DOI:10.1007/s12022-013-9291-6

*Terms of use:*

Open Access

Anyone can freely access the full text of works made available as "Open Access". Works made available under a Creative Commons license can be used according to the terms and conditions of said license. Use of all other works requires consent of the right holder (author or publisher) if not exempted from copyright protection by the applicable law.

(Article begins on next page)



# UNIVERSITÀ DEGLI STUDI DI TORINO

***This is an author version of the contribution published on:***

*Questa è la versione dell'autore dell'opera:*

*[Endocrine Pathology, 25 (1), 2014, DOI 10.1007/s12022-013-9291-6]*

*ovvero [Papotti M, Duregon E, Volante M, McNicol AM., 25 (1), Springer, 2014,  
pagg.35-48]*

***The definitive version is available at:***

*La versione definitiva è disponibile alla URL:*

*[<http://link.springer.com/article/10.1007%2Fs12022-013-9291-6>]*

**PATHOLOGY OF THE ADRENAL CORTEX: a reappraisal of the past 25 years focusing on adrenal  
cortical tumors**

Mauro Papotti, Eleonora Duregon, Marco Volante, Anne Marie McNicol\*

Department of Oncology, University of Turin at San Luigi Hospital, Orbassano (Torino), Italy and

\*Molecular and Cellular Pathology, UQ Centre for Clinical Research, The University of Queensland,  
Brisbane, Australia.

Corresponding author: Marco Volante, MD

Department of Oncology, University of Turin at San Luigi Hospital,

Regione Gonzole 10, 10043 Orbassano, Torino, Italy

Phone +390116705464; Fax: +390119026753; email: marco.volante@unito.it

1  
2  
3  
4  
5  
6  
7  
8  
9  
10  
11  
12  
13  
14  
15  
16  
17  
18  
19  
20  
21  
22  
23  
24  
25  
26  
27  
28  
29  
30  
31  
32  
33  
34  
35  
36  
37  
38  
39  
40  
41  
42  
43  
44  
45  
46  
47  
48  
49  
50  
51  
52  
53  
54  
55  
56  
57  
58  
59  
60  
61  
62  
63  
64  
65

## ABSTRACT

A reappraisal of the major advances in the diagnostic pathology of adrenal cortical lesions and tumors in the last 25 years is presented, with special reference to the definition of malignancy in primary adrenal cancer and its variants. Slightly more than 25 years ago Weiss proposed his diagnostic scoring system for adrenal cortical carcinoma. This represented a milestone for adrenal pathologists and the starting point for further modifications of the system, either through minor changes in the scoring procedure itself, or concentrating on some particular Weiss criterion such as mitotic index, integrated into alternative scoring schemes or algorithms that are currently under validation. Improvements in diagnostic immunohistochemistry have led to the identification of markers of cortical origin, such as Melan A, alpha-inhibin and SF-1 and of prognostic factors in carcinoma, such as the Ki-67 proliferation index and SF-1 itself. With regard to hyperplastic conditions, genetic investigations have allowed the association of the majority of cases of primary pigmented nodular adrenocortical disease (PPNAD) in Carney complex to mutations in the gene encoding the regulatory subunit 1A of protein kinase A (*PRKAR1A*). Other hereditary conditions are also associated with adrenal cortical tumors, including the Li-Fraumeni, Beckwith-Wiedemann, Gardner, Multiple Endocrine Neoplasia type 1 and Neurofibromatosis type 1 syndromes. Moreover, several advances have been made in the knowledge of the molecular background of sporadic tumors, and a number of molecules/genes are of particular interest as potential diagnostic and prognostic biomarkers.

**KEY WORDS:** Adrenal cortex, pathology, adenoma, carcinoma, diagnostic criteria, update

## INTRODUCTION: Where we were

1  
2  
3  
4  
5  
6  
7 Diagnostic pathology of adrenal cortical diseases classically included diffuse lesions and single or  
8  
9 multiple nodular conditions. In this respect, the diagnostic approach has not undergone major  
10  
11 changes in the past 25 years, but several new tools have become available for the purpose of  
12  
13 better identifying different diseases and tumor categories. Light microscopy and  
14  
15 immunophenotyping or molecular markers have led to the definition of more accurate and  
16  
17 reproducible categories of adrenal cortical disorders, especially in neoplastic diseases.  
18  
19  
20  
21  
22

23 Twenty-five years ago, pathology reports were based on few terms (mainly hyperplasia, adenoma,  
24  
25 carcinoma or metastasis) and a description of the relevant pathological features was attached,  
26  
27 according to local practice of different countries and institutions. Electron microscopy was  
28  
29 generally not necessary for subtyping adrenal cortical diseases and immunohistochemical  
30  
31 diagnostic markers related to adrenal cortex were very limited, and no prognostic or predictive  
32  
33 markers were known. However, as for other types of human diseases, pathology of the adrenal  
34  
35 cortex has progressed - especially in the most recent years - together with the improvement of the  
36  
37 clinical diagnosis and management of patients, and with the technical implementation of ancillary  
38  
39 tools.  
40  
41  
42  
43  
44  
45  
46

47 This overview will summarize the major advances in the diagnosis of adrenal cortical lesions,  
48  
49 separately approaching diagnostic, immunophenotypic and molecular data that have emerged in  
50  
51 the past 25 years, focusing on adrenal cortical tumors and on novel insights that have improved  
52  
53 the diagnostic work-up or are currently being validated. A summary of the most relevant  
54  
55 achievements is illustrated in **Figure 1**.  
56  
57  
58  
59  
60  
61  
62  
63  
64  
65

## DIAGNOSTIC CRITERIA OF MALIGNANCY

1  
2  
3  
4  
5  
6  
7 Twenty-five years ago several parameters of malignancy had been identified, all having a poor  
8  
9 sensitivity for adrenal cortical carcinoma diagnosis. As a result, Weiss proposed combining some of  
10  
11 them into a scoring system. This proposal (the Weiss Score) was a major advance in adrenal  
12  
13 cortical cancer pathology and still represents - in its original proposal [1,2] or after minor  
14  
15 modifications [3] - a milestone in this field. However, the effects of a 25 year-long application of  
16  
17 the Weiss Score, as also discussed by Weiss himself in a recent reappraisal of his score [4], led to  
18  
19 the recognition that the relevance and reproducibility of the individual parameters varies.  
20  
21  
22  
23

24  
25 As a direct consequence of this situation, alternative diagnostic protocols or algorithms have  
26  
27 emerged in the last decades, all having a limited application and a lower popularity compared to  
28  
29 Weiss Score, at least until recent years. As a matter of fact, all systems used for adrenal cortical  
30  
31 carcinoma diagnosis largely rely on mitotic figures count, which thus represents the most relevant  
32  
33 and accurate parameter to assess malignancy in adrenal cortical tumors, irrespective of the  
34  
35 diagnostic protocol applied. In this respect, Diaz-Cano and Blanes proposed a diagnostic algorithm  
36  
37 based on the mitotic count, and suggested that a cut-off value of >5 mitotic figures in 50 high  
38  
39 power fields was associated per se with malignant behavior [5]. Among other alternative  
40  
41 approaches, an algorithm was recently designed to combine architectural features (namely the  
42  
43 disruption of the reticulin framework) and the presence of malignancy-related parameters already  
44  
45 included in the Weiss Score, such as increased mitotic index and the presence of necrosis and  
46  
47 vascular invasion [6] (**Figure 2**). This algorithm was able to reclassify with a 100% sensitivity and  
48  
49 specificity all cases with a “malignant” Weiss Score (>3) and is generally simple and easier to apply.  
50  
51  
52  
53  
54  
55  
56  
57  
58  
59  
60  
61  
62  
63  
64  
65

1 In addition, in subsequent publications, it proved applicable also in specific adrenal cortical tumor  
2 variants, namely the myxoid and the oncocytic subtypes (see also below) [7,8].  
3  
4

5  
6 On the other hand, it soon became clear that some parameters proposed in the Weiss Score  
7  
8 (including sinusoidal invasion, diffuse growth, etc) were difficult to apply and lacked inter-observer  
9  
10 reproducibility . These difficulties were eventually addressed in a recent study reported by a French  
11  
12 group [9], which definitely demonstrated that not all Weiss criteria are easily applicable and that  
13  
14 pathologists' training is crucial in improving the diagnostic accuracy. Moreover, in a recent study  
15  
16 the reproducibility of reticulin staining - which is the key parameter of the algorithm described  
17  
18 above - was also tested among observers of different centers that blindly examined over 240  
19  
20 adrenal cortical tumors; the assessment of reticulin disruption was highly reproducible among  
21  
22 pathologists, especially after specific training and in cases classified as malignant according to the  
23  
24 Weiss Score [10].  
25  
26  
27  
28  
29  
30  
31  
32  
33  
34  
35

## 36 **SPECIAL TYPES OF ADRENAL CORTICAL TUMORS**

37  
38  
39  
40  
41  
42

### 43 **Oncocytic adrenal cortical tumors.**

44  
45

46 Oncocytic adrenal cortical neoplasms represent a subset of tumors with a predominant  
47  
48 component of usually large cells with the cytoplasm filled with mitochondria which confer a  
49  
50 granular and deeply eosinophilic appearance. Since the first report in 1986 [11], many case reports  
51  
52 or small series have been published. In the series collected at our Institution, the prevalence of  
53  
54 oncocytic adrenal cortical carcinomas among malignant tumors was approximately 18% [8].  
55  
56

57 Oncocytic adrenal cortical neoplasms may be classified into "pure" if made of >90% oncocytes,  
58  
59  
60  
61  
62  
63  
64  
65

1 mixed if oncocytes are present in 50% to 90% of the tumor, and focal if the oncocytic component  
2 accounts for less than 50%. As originally stated by Bisceglia et al. [12], the diagnosis of malignancy  
3  
4 in oncocytic tumors is difficult using the classical Weiss Score, since at least three parameters  
5  
6 (eosinophilic cytoplasm, high nuclear grade and diffuse architecture) are intrinsically present in  
7  
8 this tumor type, irrespective of the biological and clinical behavior. As a consequence, the cut-off  
9  
10 values validated for conventional adrenal cortical carcinoma may lead to an over-diagnosis of  
11  
12 malignancy in this special group. For this reason, exclusively for purely oncocytic tumors, an  
13  
14 alternative diagnostic system was proposed based on criteria specific for this tumor type: any of  
15  
16 the three “major criteria” (mitotic rate >5 per 50HPF, atypical mitoses, and venous invasion)  
17  
18 defines an oncocytic adrenal cortical carcinoma, whereas one to four “minor criteria” (necrosis,  
19  
20 capsular and sinusoidal invasion, size >10 cm or weight >200 g) defines an oncocytic adrenal  
21  
22 cortical neoplasm of borderline malignancy [12], A retrospective survival analysis provided by  
23  
24 Wong and coworkers [13] showed that this classification correctly predicted the malignant  
25  
26 potential of these tumors and demonstrated a generally better prognosis for oncocytic carcinomas  
27  
28 in comparison with those of the classical type. A further study claimed that the reticulin algorithm  
29  
30 correctly stratifies oncocytic adrenal cortical tumors into benign and malignant, and confirmed the  
31  
32 “low grade” malignancy for these tumors, as also supported by low mean mitotic and Ki-67  
33  
34 indexes [8]. Moreover, as for oncocytic neoplasms at other sites [14,15], the mitochondrial DNA  
35  
36 “common deletion” (4977 base pairs) was identified in approximately 40% of oncocytic adrenal  
37  
38 cortical tumors, more commonly in borderline or benign tumors, but not in control adrenal  
39  
40 cortical carcinomas of the classical type [8].  
41  
42  
43  
44  
45  
46  
47  
48  
49  
50  
51  
52  
53  
54  
55  
56  
57  
58  
59  
60  
61  
62  
63  
64  
65

### **Myxoid adrenal cortical tumors.**



1 Description of myxoid adrenal cortical tumors dates back to 1979 [16] and these neoplasms are  
2 characterized by extracellular deposits of myxoid material, highlighted by positive Alcian-Blue  
3 staining, which can be predominant in a subset of approximately 10% of ACC [7,17]. Among them,  
4 two groups can be identified based on architectural and cytological features, irrespective of the  
5 amount of myxoid material: group 1 tumors are characterized by monotonous cells of small to  
6 medium size, with mild to moderate nuclear atypia and scant, lightly eosinophilic cytoplasm,  
7 growing in a trabecular, pseudoglandular or cribriform pattern; conversely, group 2 tumors are  
8 more similar to classical adrenal cortical carcinomas, comprising large pleomorphic cells with a  
9 moderate to high nuclear atypia and abundant eosinophilic cytoplasm, growing in a diffuse  
10 pattern and usually having focal myxoid areas (< 20% of the total area) within an otherwise  
11 conventional adrenal cancer. Although some cases show a certain degree of overlapping features  
12 between these two groups, group 2 tumors are probably the result of degenerative myxoid  
13 changes in conventional adrenal cortical carcinomas and we suggest that should not be classified  
14 into this distinctive variant of adrenal cortical tumors.  
15  
16  
17  
18  
19  
20  
21  
22  
23  
24  
25  
26  
27  
28  
29  
30  
31  
32  
33  
34  
35  
36

37 Based on the aforementioned pathological features, the myxoid variant is challenging for several  
38 reasons. The first is the differential diagnosis, especially in biopsy material, with other myxoid  
39 neoplasms, such as extra-skeletal myxoid chondrosarcoma, chordoma, myxoid carcinomas from  
40 the kidney or other sites, myxoid lipomatous or nerve sheath tumours. Secondly, the distinction  
41 between benign and malignant adrenal cortical myxoid tumors may be difficult. Due to the above-  
42 mentioned cyto-architectural characteristics, myxoid tumors often lack two of the Weiss  
43 parameters (diffuse growth and nuclear atypia) and the identification of invasive areas might be  
44 hard or equivocal in the presence of abundant myxoid background. Therefore, in adrenal tumors  
45 with predominant myxoid stroma it is advisable to consider malignancy even in tumors with a low  
46  
47  
48  
49  
50  
51  
52  
53  
54  
55  
56  
57  
58  
59  
60  
61  
62  
63  
64  
65

1  
2  
3  
4  
5  
6  
7  
8  
9  
10  
11  
12  
13  
14  
15  
16  
17  
18  
19  
20  
21  
22  
23  
24  
25  
26  
27  
28  
29  
30  
31  
32  
33  
34  
35  
36  
37  
38  
39  
40  
41  
42  
43  
44  
45  
46  
47  
48  
49  
50  
51  
52  
53  
54  
55  
56  
57  
58  
59  
60  
61  
62  
63  
64  
65

grade appearance. Moreover, in terms of prognosis, it has also been suggested that myxoid adrenal cortical carcinomas may have a more aggressive clinical behavior [17].

### **Sarcomatoid variant of adrenal cortical carcinoma.**

This is the rarest adrenal cortical carcinoma variant and to our knowledge only 14 cases have been reported in the literature so far. They have been classified as either sarcomatoid carcinomas with spindle cell areas [18,22] or carcinosarcomas in the presence of a specialized mesenchymal component, revealing osteosarcomatous [23,24], chondrosarcomatous [23], rhabdomyosarcomatous [25,28] and primitive neuroectodermal tumor-like [28] differentiation. Sarcomatoid carcinoma is highly aggressive and the recognition of diagnostic features of malignancy is not problematic. For this reason it was suggested a cut-off of 10% of sarcomatous component to diagnose this unusual variant, irrespective of the Weiss Score [21].

### **Pediatric adrenal cortical tumors.**

Pediatric adrenal cortical tumors are rarer than their adult counterparts, with an incidence which varies across geographic regions, being remarkably high in Southern Brazil, compared to the United States and Europe. The diagnosis of malignancy in pediatric adrenal cortical tumors is even more challenging than those of adults, because the Weiss Score criteria often lack sensitivity and specificity in pediatric cases. For this reason in 2003, Wieneke and coworkers [29] proposed categorizing pediatric adrenal cortical tumors into three different prognostic groups, “benign”, “indeterminate for malignancy” and “malignant”, according to the evaluation of nine parameters that were found the most statistically significant to predict malignant behavior. In this study,

1 among the classical criteria considered in the Weiss system, only confluent necrosis, capsular or  
2 vascular invasion, presence of atypical mitotic figures and a mitotic count >15 per 20 high power  
3 fields were significantly related to poor prognosis. Conversely, some others (eosinophilic  
4 cytoplasm, diffuse architecture or sinusoidal invasion) were apparently less relevant. Four  
5 additional parameters had also a significant impact on prognosis, including tumor weight >400 g,  
6 tumor size >10.5 cm, vena cava invasion and peri-adrenal tissue infiltration. The prognostic  
7 relevance of these parameters has recently been validated in the Italian Pediatric Rare Tumor  
8 (TREP) Study [30]. Moreover, in this latter series, the authors found that focal myxoid stromal  
9 changes, which were not included in the Wieneke system, were also suggestive of malignancy in  
10 pediatric tumors.  
11  
12  
13  
14  
15  
16  
17  
18  
19  
20  
21  
22  
23  
24  
25  
26  
27  
28  
29

### 30 **Mixed cortico-medullary tumors.**

31  
32  
33 Mixed cortico-medullary adrenal tumors are rare, with fewer than 20 well-documented cases of  
34 mixed cortico-medullary adenomas. Most cases are benign and show a dual divergent  
35 differentiation, as confirmed by the concurrent expression of adrenal cortex and adrenal medulla  
36 markers. Moreover, a case showing mixed cortical and medullary histological characteristics, as  
37 well as gross and microscopic evidence of malignancy has recently been documented [31].  
38  
39  
40  
41  
42  
43  
44  
45  
46  
47  
48  
49  
50

### 51 **IMMUNOPHENOTYPIC MARKERS**

52  
53  
54  
55  
56  
57 In adrenal cortical tumor pathology, immunohistochemistry has chronologically become useful for  
58 the purpose of differential diagnosis, firstly between adrenal cortical carcinoma and extra-adrenal  
59  
60  
61  
62  
63  
64  
65

1 neoplasms (renal cell carcinoma, melanoma, poorly differentiated metastatic carcinomas,  
2 retroperitoneal sarcomas) (**Figure 3**), then between adrenal cortical and other primary adrenal  
3 tumors (pheochromocytoma, PEComa), and more recently between adrenal cortical adenoma and  
4 carcinoma. In addition, some immunohistochemical markers have been proposed as prognostic  
5 tools, although few of them have so far been validated in independent cohorts.  
6  
7  
8  
9  
10  
11  
12  
13  
14  
15  
16

### 17 **Diagnostic markers of adrenal cortical origin.**

18  
19  
20 Many malignant neoplasms metastasize to the adrenal gland including lung, gastrointestinal, renal  
21 and breast cancer, and melanoma [32], and reliable immunohistochemical markers are therefore  
22 required to establish the correct diagnosis. Adrenal cortical tumors are usually positive for a  
23 variety of markers that are common to several other malignancies, such as vimentin [33], and  
24 variably express cytokeratin and neuroendocrine markers, such as synaptophysin and  
25 neurofilament. Moreover, adrenal cortex as well as adrenocortical tumors nearly invariably  
26 express mesothelioma-related markers calretinin [34] and D2-40 [35], although the specificity for  
27 the adrenocortical origin of these markers is limited by their expression at a variable extent also in  
28 other neoplasms including abdominal ones (i.e. renal cell carcinoma, ovarian carcinoma).  
29  
30  
31  
32  
33  
34  
35  
36  
37  
38  
39  
40  
41  
42  
43  
44

45 In 1990, a monoclonal antibody (D11) highly specific for adrenal cortical tissue was described  
46 [36,37]. However, its immunoreactivity was later observed only in a small subset of adrenal  
47 cortical carcinomas, heavily restricting its use as a general marker for adrenal cortical derivation  
48 [38,39]. Moreover, D11 is no longer commercially available or otherwise accessible.  
49  
50  
51  
52  
53  
54  
55

56 Since 1998, Melan-A (MART-1) and alpha-inhibin have become the most commonly used markers  
57 to prove the adrenal cortical origin of a given lesion [40-44]. Alpha-inhibin was also demonstrated  
58 to reflect the hormonal secretion of the tumor, being more frequently and intensively expressed  
59  
60  
61  
62  
63  
64  
65

1  
2  
3  
4  
5  
6  
7  
8  
9  
10  
11  
12  
13  
14  
15  
16  
17  
18  
19  
20  
21  
22  
23  
24  
25  
26  
27  
28  
29  
30  
31  
32  
33  
34  
35  
36  
37  
38  
39  
40  
41  
42  
43  
44  
45  
46  
47  
48  
49  
50  
51  
52  
53  
54  
55  
56  
57  
58  
59  
60  
61  
62  
63  
64  
65

in androgen secreting neoplasms [45]. However, both markers have a limited sensitivity and fail to recognize a significant proportion (28% for Melan A and 31% for alpha-inhibin) of adrenal cortical carcinomas.

Although already described in 1995 by Sasano and coworkers [46], only recently has steroidogenic factor-1 (SF-1; also known as Ad4BP or NR5A1) progressively become the marker of choice to differentiate between tumors of adrenal cortical and non-adrenal cortical origin. Physiologically, it plays a key role in the development of steroidogenic tissues and in the regulation of steroid biosynthesis and was found to be over-expressed in most cases of childhood adrenal cortical tumors [47,48]. In 2010, Sbiera and coworkers [49] demonstrated in a very large series of cases that nuclear SF-1 staining is a highly sensitive and specific marker of adrenal cortical derivation, being restricted to steroidogenic tissues and related tumors. In their study, none of the pheochromocytomas nor of the tumors that usually metastasize to the adrenal gland were reactive to SF-1. The diagnostic accuracy of SF-1 was further validated by different groups [50] [51] [52] and this marker represents the best currently available tool in this diagnostic setting.

Variants of adrenal cortical tumors usually have an immunohistochemical profile similar to the conventional type. SF-1, Melan A and alpha-inhibin are expressed in oncocytic and myxoid cases in proportions comparable to classic adrenal cortical tumors [17,51]; neurofilament, either as diffuse cytoplasmic or small paranuclear dots, are more frequently and extensively expressed in the myxoid variant [7]. It is noteworthy that in the sarcomatoid variant of adrenal cortical carcinoma Melan-A, synaptophysin and calretinin are expressed to a lower extent or lost in the sarcomatous areas.

#### **Diagnostic markers of malignancy.**

1 In the last two decades, several studies have focused on the applicability of immunohistochemical  
2 markers as ancillary tools assisting morphology in the diagnosis between benign and malignant  
3 lesions. Some of these markers are related to specific genetic alterations occurring more  
4 frequently in adrenal cortical carcinomas than in adenomas, whereas others are related to  
5 different proliferative profiles within the spectrum of adrenal cortical tumors.  
6  
7  
8  
9  
10

11  
12  
13 To date, the proliferation marker Ki-67 is the sole immunohistochemical antibody which has  
14 steadily been reported useful in the differential diagnosis between adenoma and carcinoma [53-  
15 60]. Our group recently proposed phospho-histone H3 immunostaining as an alternative, faster  
16 and reliable method to highlight mitotic figures, being specifically useful in cases with low mitotic  
17 activity [61]. Moreover, in this study both phospho-histone H3 and Ki-67 immunostainings showed  
18 a high inter-observer agreement.  
19  
20  
21  
22  
23  
24  
25  
26  
27  
28

29  
30 Among the variety of other markers reported in the literature, p53 immunoreactivity was found  
31 well correlated with the presence of *TP53* gene mutations, which are found in 25-30% of sporadic  
32 adrenal cortical carcinomas, but not in adenomas. For this reason, it is of limited interest as a  
33 diagnostic tool because of a good specificity, but a very low sensitivity [60,62]. IGF-2 protein over-  
34 expression has also been observed in a high proportion of adrenal cortical carcinomas and almost  
35 no adenomas [60] but it is not usually included in the diagnostic armamentarium because of the  
36 difficult interpretation of the labeling.  
37  
38  
39  
40  
41  
42  
43  
44  
45  
46  
47  
48  
49  
50  
51  
52

### 53 **Prognostic markers.**

54  
55

56 As described for diagnostic markers, a variety of proteins have been explored as prognostic factors  
57 in adrenal cortical carcinoma, either associated with cell proliferation, adrenal cortical  
58 differentiation, genetic defects or specific characteristics of malignant tumors cells.  
59  
60  
61  
62  
63  
64  
65

1 Ki-67 proliferation index has been investigated as a prognostic marker for several years [63,64]. In  
2 a recent study, Ki-67 proved to be superior to mitotic count in terms of prognosis of adrenal  
3 cortical carcinoma patients, at least with regard to overall survival, helping to stratify three  
4 subgroups of patients based on cut-offs of <20%, 20-50% and >50% [61]. Another promising  
5 prognostic marker is SF-1, that, apart from the above mentioned diagnostic role, has also been  
6 validated in multiple cohorts as a marker of poor prognosis when expressed at high levels [49]  
7 [51]. Possibly providing a molecular explanation for SF-1 protein over-expression in a proportion of  
8 adrenal cortical carcinomas, the *NR5A1*, the SF-1 gene, was found amplified in childhood adrenal  
9 cortical cancer [47,48] and chromosomal gains in chromosome 9q (where the SF-1 gene is located)  
10 have also been described in adults [65]. Future studies are therefore needed to clarify the  
11 prognostic role of *NR5A1* gene amplification in adrenal cortical cancer.  
12  
13  
14  
15  
16  
17  
18  
19  
20  
21  
22  
23  
24  
25  
26  
27  
28

29  $\beta$ -catenin nuclear staining is associated with deregulation of the Wnt/ $\beta$ -catenin signaling pathway  
30 and correlates with CTNNB1 (the  $\beta$ -catenin gene) mutations. Its prognostic role has been validated  
31 in two independent cohorts of adrenal cortical carcinomas [66]. More recently, Ronchi and  
32 coworkers showed that low protein levels of serum glucocorticoid kinase 1, but not of nuclear  $\beta$ -  
33 catenin and phosphorylated AKT, were associated with poor overall survival in adrenal cortical  
34 carcinoma patients [67].  
35  
36  
37  
38  
39  
40  
41  
42  
43  
44

45 Several other molecules have also been reported to influence (at the protein expression level) the  
46 outcome of adrenal cortical cancer patients, including Matrix Metalloproteinase type 2 [68] and  
47 Glucose Transporter 1 [69], but have not yet been validated in additional studies.  
48  
49  
50  
51  
52  
53  
54  
55  
56  
57

## 58 **GENETICS OF ADRENAL CORTICAL DISEASES**

59  
60  
61  
62  
63  
64  
65

## Hyperplasia.

1  
2  
3 Some thirty years ago a peculiar condition was described by Carney at Mayo Clinic, characterized  
4  
5 by of multiple pigmented adrenal cortical nodules in association with other lesions (myxomas,  
6  
7 psammomatous melanotic schwannomas, spotty pigmentation and blue nevi of the skin or  
8  
9 mucosae, together with a variety of endocrine neoplasms) [70]. This seminal description was  
10  
11 subsequently confirmed by several additional cases that have led in the past two decades to a  
12  
13 better clinical and pathological characterization of this condition as part of the Carney complex.  
14  
15  
16 Moreover, different types of mutations of the *PRKAR1A* gene were identified as the genetic  
17  
18 causative defect for this syndrome [71].  
19  
20  
21  
22  
23  
24  
25  
26  
27

## Adrenal cortical tumors in familial cancer susceptibility syndromes.

28  
29  
30  
31 Even if the majority of adrenal cortical carcinomas arise in a sporadic setting, a minority of cases  
32  
33 are associated with familial cancer syndromes, including the autosomal dominant Li-Fraumeni and  
34  
35 Beckwith-Wiedemann syndromes and, more rarely, the Gardner syndrome, Multiple Endocrine  
36  
37 Neoplasia type 1, Neurofibromatosis type 1 and the Carney complex [72] (**Table 1**). The  
38  
39 association of adrenal cortical carcinoma with both the conditions that will subsequently be coded  
40  
41 as the Li-Fraumeni and hereditary colon cancer syndromes had already been established in the  
42  
43 eighties of last century [73,74], but little knowledge on the genetic background was available at  
44  
45 that time.  
46  
47  
48  
49  
50  
51

52  
53 Li-Fraumeni syndrome is a rare autosomal dominant cancer predisposition syndrome associated  
54  
55 with germline mutations in the tumor suppressor gene *TP53* and subsequent loss of  
56  
57 heterozygosity at 17p13.1 locus, which confers an increased susceptibility to sarcomas, breast  
58  
59 cancer, brain tumors, leukemia and lymphoma. Adrenal cortical carcinoma however develops in  
60  
61  
62  
63  
64  
65



1 only 3–4% of patients with Li-Fraumeni syndrome, usually in childhood [72]. Common *TP53*  
2 mutations include Arg to His substitution at codon 175 (which codes for amino acids of the DNA  
3 binding site), and Arg to His at codon 337 (R337H) (coding for the oligomerization domain). The  
4 latter is classically observed in children of Southern Brazil [75,76], where the incidence of adrenal  
5 cortical carcinoma is 10 to 15 times higher than in the rest of the world. Screening for germline  
6  
7  
8  
9  
10  
11  
12  
13  
14  
15  
16  
17  
18  
19  
20  
21  
22  
23  
24  
25  
26  
27  
28  
29  
30  
31  
32  
33  
34  
35  
36  
37  
38  
39  
40  
41  
42  
43  
44  
45  
46  
47  
48  
49  
50  
51  
52  
53  
54  
55  
56  
57  
58  
59  
60  
61  
62  
63  
64  
65

In Beckwith-Wiedemann Syndrome, various developmental abnormalities, such as macrosomia, exomphalos, macroglossia, abdominal wall defects, ear and renal anomalies, and cleft palate, can be associated with pediatric tumors in 5% of cases, including adrenal cortical carcinoma. Although the majority of cases with Beckwith-Wiedemann Syndrome arise de novo, 15% of them are inherited as the result of a defective genomic imprinting of 11p15.5 locus. This chromosomal region is usually subjected to a tissue-specific maternal imprinting, therefore, only the paternal allele is expressed [78]. In Beckwith-Wiedemann Syndrome, there is a loss of the maternal locus and a gain in the paternal locus. As a consequence, *IGF-2* which is expressed on the paternal allele is over-represented whereas *p57kip2* and *H19* which are expressed on the maternal allele are defective [79].

Other inherited cancer syndromes associated with adrenal cortical tumors (indeed, more often adenomas than carcinomas and generally restricted to adult patients) are Multiple Endocrine Neoplasia type 1, Gardner syndrome and Neurofibromatosis type 1. In Multiple Endocrine Neoplasia type 1, inactivating mutations in the *MEN1* gene, located in the chromosomal region 11q13, are responsible for the development of pituitary tumors, parathyroid tumors and other neuroendocrine tumors. In addition, patients are also at risk of developing multiple lipomas,

1  
2  
3  
4  
5  
6  
7  
8  
9  
10  
11  
12  
13  
14  
15  
16  
17  
18  
19  
20  
21  
22  
23  
24  
25  
26  
27  
28  
29  
30  
31  
32  
33  
34  
35  
36  
37  
38  
39  
40  
41  
42  
43  
44  
45  
46  
47  
48  
49  
50  
51  
52  
53  
54  
55  
56  
57  
58  
59  
60  
61  
62  
63  
64  
65

angiomas, and adrenal cortical tumors. The most common adrenal cortical phenotype observed in Multiple Endocrine Neoplasia type 1 is unilateral or bilateral hyperplasia, while adenomas are less common and carcinomas very rare occurrences [80]. Gardner syndrome is an autosomal dominant disorder caused by mutations in the adenomatous polyposis coli (*APC*) gene. Apart from adrenal cortical carcinoma, which is very rare in this syndrome, patients develop gastrointestinal polyps, osteomas, soft tissue tumors, epidermal cysts, desmoid tumors, and periampullary cancer, as well as other endocrine malignancies such as the cribriform variant of papillary thyroid cancer.

### **Sporadic adrenal cortical tumors.**

*Gene mutations.* Inactivating mutations in tumor suppressor genes and activating mutations in oncogenes responsible for familial cancer syndromes have also been found as somatic alterations in sporadic adrenal cortical tumors, with special reference to carcinomas [81]. Losses of the *MEN1* gene locus at 11q13, but very infrequent gene mutations, have been detected in sporadic adrenal tumors [82,83]. Somatic mutations of *TP53* gene, as seen in Li-Fraumeni syndrome, as well as p53 protein accumulation can be detected in sporadic tumors and have been considered as a marker of malignancy, being virtually absent in adenomas. Activation of the Wnt/ $\beta$ -catenin pathway as the result of *CTNNB1* mutations has been documented in up to 40% of carcinomas, but also in a relevant proportion of adenomas [84,85], especially non-secreting and/or large size tumors [86]. Moreover, the presence of activating mutations in the *CTNNB1* gene is associated with a worse outcome in adrenal cortical cancer patients [66]. Finally, somatic inactivating mutations or allelic losses of the *PRKAR1A* locus at 17q22–24, involved in the Carney complex, were also seen in sporadic cases of adrenal cortical adenoma and carcinoma [87].

1  
2  
3  
4  
5  
6  
7  
8  
9  
10  
11  
12  
13  
14  
15  
16  
17  
18  
19  
20  
21  
22  
23  
24  
25  
26  
27  
28  
29  
30  
31  
32  
33  
34  
35  
36  
37  
38  
39  
40  
41  
42  
43  
44  
45  
46  
47  
48  
49  
50  
51  
52  
53  
54  
55  
56  
57  
58  
59  
60  
61  
62  
63  
64  
65

However, a significant proportion of adrenal cortical tumors lacks known genetic defects, and therefore several studies have recently been conducted to clarify molecular mechanisms alternative to gene mutations in the pathogenesis of these tumors. Genomic, transcriptomic, and methylomic profiles have been reported in relatively large series of cases and helped to classify adrenal cortical tumor families with even prognostic implications and to distinguish benign from malignant forms. However, an integrative view able to incorporate all such information is still missing, thus making the huge amount of data available still poorly transferable into clinical practice.

*Chromosomal imbalances.* A number of studies have shown that chromosomal aberrations are more frequent in malignant than in benign and hyperplastic adrenal cortical lesions. Gains, losses and amplifications can be detected with either comparative genomic hybridisation (CGH) or allelotyping techniques. An aneuploid DNA pattern was often associated with such chromosomal imbalances, although the value of DNA ploidy analysis is limited for both diagnostic and prognostic purposes [88]. In particular, gains in chromosomes 6q, 7q, 12q, and 19p, and losses in chromosomes 3, 8, 10p, 16q, 17q, and 19q, have been associated with a significantly worse survival of adrenal cortical cancer patients, independent of tumor size, tumor weight, and functional status of the tumor [89]. A strong relationship between tumor size and number of chromosomal aberrations was reported, with no gains or losses detectable in adenomas smaller than five cm; conversely, gains on chromosomes 4 and 5 and losses on 2, 11, 17 were apparently restricted to carcinomas having a size of 7-20 cm [90]. Overall, extensive genomic imbalances were encountered in carcinomas by means of CGH, indicating that the molecular pathogenesis of sporadic tumors is complex and that multiple genetic changes drive malignant transformation and tumor progression. A recent study on childhood adrenal cortical tumors, using SNP array profiling, identified recurrent alterations in loci comprising well-known oncogenes (*MYC*, *MDM2*, *PDGFRA*,

1  
2  
3  
4  
5  
6  
7  
8  
9  
10  
11  
12  
13  
14  
15  
16  
17  
18  
19  
20  
21  
22  
23  
24  
25  
26  
27  
28  
29  
30  
31  
32  
33  
34  
35  
36  
37  
38  
39  
40  
41  
42  
43  
44  
45  
46  
47  
48  
49  
50  
51  
52  
53  
54  
55  
56  
57  
58  
59  
60  
61  
62  
63  
64  
65  
*KIT, MCL1, BCL2L1*) and tumor suppressors (*TP53, RB1, RPH3AL*), not yet associated to adrenal cortical carcinoma [91].

*Transcriptomic analysis.* The last decade has been characterized by the development of high-throughput methods for wide gene expression profiling. Since the first study in 2003 [92] progress has been made in both the understanding of the pathogenesis of adrenal cortical tumors and more recently in the stratification of adrenal cortical carcinomas into prognostic groups.

The early studies aimed at the definition and validation of a malignant signature [93-95]. An initial attempt was made by Slater et al. [95], who classified the tumors into two groups (benign and malignant), according to the Weiss Score and identified 74 genes differentially expressed in the two groups. However, by definition, using such an approach the gene signature of malignancy cannot be a better approach than the Weiss score, which is the reference. To overcome this limitation, other authors used the probability of recurrence as the reference [93]. Among genes of significant impact in this setting, general proliferation markers (cell cycle regulators and cell cycle effectors) common to all cancer types, and some adrenal cortical specific markers were identified. Among these latter, IGF2 gene resulted consistently up-regulated in adrenal cortical carcinomas in different transcriptome analyses, thus depicting a specific IGF2 cluster of cases associated also to up-regulation of other growth factors and growth factor receptor genes [59,93,96-98]. An alternative cluster was characterized by down-regulation of steroidogenic enzyme genes, such as *CYP11A, CYP11B* and *HSD3B1* [93], and this cluster was as efficient as pathological evaluation, using a Weiss score cut-off value of 4. Later, deReynies et al. identified two genes, *DGL7* and *PINK1*, as the best molecular predictors of malignancy [97]. All the above observations were then turned into prognostic stratification. Again, by means of unsupervised hierarchical clustering, different authors observed peculiar transcriptome characteristics capable of dividing adrenal cortical carcinomas into cases with bad or good prognosis [96,97,99]. In the paper by de Reynies

1 and coworkers [97] the *BUB1B* and *PINK1* genes showed the best prognostic performance.  
2 Integrating transcriptome and mutational profiles, three subgroups of adrenal cortical carcinomas  
3 with different biological and clinical behavior may be identified: 1) the p53 group, encompassing  
4 all tumors with a *TP53* mutation; 2) the  $\beta$ -catenin group, containing all tumors with deregulation  
5 of the Wnt/ $\beta$ -catenin pathway (apparently mutually exclusive with p53 group); 3) the remaining  
6 group, with neither p53 nor  $\beta$ -catenin altered pathways but enriched in cell cycle and metabolism  
7 genes [100,101].  
8  
9

10  
11  
12  
13  
14  
15  
16  
17  
18  
19 *MicroRNA profiling.* MicroRNAs (miRNAs) are short noncoding RNAs, 18 to 25 nucleotides in  
20 length, which influence gene expression either by post-transcriptional regulation of gene  
21 expression leading to target mRNA degradation or by the repression of its translation with  
22 consequent decrease in the particular protein levels or even by up-regulation of their targets  
23 [102]. Several studies analyzed the miRNA expression profile in adrenal cortical neoplasms. They  
24 mainly aimed at finding out those useful in differentiating adenomas from carcinomas and to date,  
25 a long list of de-regulated miRNAs is available [103]. Among them, miR-483 (in both 3p and 5p  
26 isoforms) and miR-195 are those more consistently found over-expressed and downregulated,  
27 respectively, both at the tissue and serum levels. Data concerning the prognostic role of these two  
28 miRNAs are controversial, as they were described as defining a subgroup of carcinomas with a  
29 poor prognosis by one group only [104,105]. miR-210 is another miRNA which was reported  
30 upregulated by different groups. It is the miRNA most consistently induced under hypoxia and high  
31 levels were found associated with clinico-pathological parameters of aggressiveness (necrosis and  
32 high Ki-67 proliferation index) and a poorer survival (Duregon et al., submitted manuscript).  
33  
34  
35  
36  
37  
38  
39  
40  
41  
42  
43  
44  
45  
46  
47  
48  
49  
50  
51  
52  
53

54  
55  
56 *DNA methylation profiling.* The role of DNA hypermethylation in adrenal cortical tumorigenesis  
57 has been evaluated in some recent studies. Altered DNA methylation of the H19 promoter had  
58 already been shown to be involved in the abnormal expression of both *H19* and *IGF2* genes in  
59  
60  
61  
62  
63  
64  
65

1 adrenal cortical carcinomas [106]. In contrast, promoter methylation of *TP53* has been  
2 demonstrated not to be a significant event in the development of adrenal cortical carcinomas  
3 [107]. Recently, a significant DNA hypermethylation of the *RASSF1A* promoter in adrenal cortical  
4 carcinoma, but not in adenoma, has been described, suggesting an epigenetic mechanism for  
5 *RASSF1A* silencing in malignant adrenal cortical tumors [108]. However, most DNA methylation  
6 studies thus far have focused on individual genes. More recently, comprehensive genome-wide  
7 analysis of DNA methylation in benign and malignant adrenal cortical tumors has been performed,  
8 sometimes obtaining controversial results, possibly related to the different methodological  
9 approaches [109-111]. Moreover, Barreau and coworkers distinguished two clusters of adrenal  
10 cortical carcinomas based on CpG island methylation status, the “CIMP” (CpG island methylator  
11 phenotype) and “non-CIMP”, the former associated to a poorer prognosis [112].  
12  
13  
14  
15  
16  
17  
18  
19  
20  
21  
22  
23  
24  
25  
26  
27  
28  
29  
30  
31

### 32 **Adenoma-Carcinoma sequence.**

33  
34  
35  
36 Although there has been much progress in the last 25 years, it is still unclear whether adrenal  
37 cortical carcinomas evolve from adenomas following a definite molecular progression pathway.  
38 Long-term follow-up of incidentally discovered adrenal cortical neoplasms suggests that adenomas  
39 generally maintain a benign phenotype [113]. However the sequence adenoma-carcinoma has  
40 been occasionally postulated in single cases showing the morphological co-existence of an  
41 aggressive component embedded within an otherwise adenomatous tissue [114-115]. In addition,  
42 a recent study described a mouse model in which an induced stabilized  $\beta$ -catenin associated with  
43 elevated IGF-2 expression resulted in a temporal progression from increasing adrenal cortical  
44 hyperplasia to subsequent adenoma, and occasionally carcinoma, formation [116]. Finally, Ronchi  
45 et al recently provided the first genome-wide high resolution overview of chromosomal changes in  
46  
47  
48  
49  
50  
51  
52  
53  
54  
55  
56  
57  
58  
59  
60  
61  
62  
63  
64  
65

1 large series of adrenal cortical tumors, including adenomas and carcinomas [117]. Among the  
2 benign tumors, small isolated copy number gains were the most frequent genetic alterations and  
3  
4 almost all of them were also present in several carcinomas, thus supporting the concept of a  
5  
6 common early molecular signature. Moreover, the Wnt/ $\beta$ -catenin and Notch signaling pathways  
7  
8 were commonly altered in both adenomas and carcinomas, strengthening their previous  
9  
10 hypothesis that these pathways are involved in early tumor pathogenesis.  
11  
12  
13  
14  
15  
16  
17  
18  
19  
20  
21  
22

### 23 **FUTURE PERSPECTIVES: Issues for the next 25 years**

24  
25  
26  
27  
28  
29

30 As summarized above, the pathological armamentarium for adrenal cortical disease – (and, more  
31 specifically for tumor characterization) has undergone a wide evolution in the past 25 years. All  
32 these achievements in the diagnostic approach and in the phenotypical characterization have  
33  
34 allowed a better definition of the disease on the one hand, but have also raised new questions and  
35  
36 opportunities for the next 25 years. An arbitrary list of issues to be covered in the near future  
37  
38 includes:  
39  
40  
41  
42  
43  
44  
45

- 46 a) the prospective validation and implementation of the accuracy and reproducibility of the  
47 available diagnostic schemes;  
48  
49
- 50 b) the definition of a grading system for adrenal cortical carcinomas, to further segregate cases  
51  
52 associated with “low” and “high” malignant potential;  
53  
54
- 55 c) the identification and validation of markers predictive of tumor response and progression;  
56  
57  
58  
59  
60  
61  
62  
63  
64  
65

1  
2  
3  
4  
5  
6  
7  
8  
9  
10  
11  
12  
13  
14  
15  
16  
17  
18  
19  
20  
21  
22  
23  
24  
25  
26  
27  
28  
29  
30  
31  
32  
33  
34  
35  
36  
37  
38  
39  
40  
41  
42  
43  
44  
45  
46  
47  
48  
49  
50  
51  
52  
53  
54  
55  
56  
57  
58  
59  
60  
61  
62  
63  
64  
65

d) the identification of novel genetic alterations/pathways involved in adrenal cortical tumorigenesis, with special reference to the subset of cases with no current specific molecular signature;

e) the integration of molecular, phenotypic, pathological and clinical data to design for adrenal cortical tumor patients - as has been done for other human malignancies - individualized clinical management protocols.

**Acknowledgments.** Work partially supported by grant from the Italian Association for Cancer Research (AIRC, Milan, grant no. IG/10795/2010 to MP) and University of Turin (ex-60% grants to MV and MP)



## REFERENCES

- 1  
2  
3  
4  
5  
6 1. Weiss LM (1984) Comparative histologic study of 43 metastasizing and nonmetastasizing  
7  
8 adrenocortical tumors. *Am J Surg Pathol* 8 (3):163-169  
9
- 10  
11 2. Weiss LM, Medeiros LJ, Vickery AL, Jr. (1989) Pathologic features of prognostic significance in  
12  
13 adrenocortical carcinoma. *Am J Surg Pathol* 13 (3):202-206  
14  
15  
16
- 17 3. Aubert S, Wacrenier A, Leroy X, Devos P, Carnaille B, Proye C, Wemeau JL, Lecomte-Houcke M,  
18  
19 Leteurtre E (2002) Weiss system revisited: a clinicopathologic and immunohistochemical study of  
20  
21 49 adrenocortical tumors. *Am J Surg Pathol* 26 (12):1612-1619  
22  
23  
24
- 25 4. Lau SK, Weiss LM (2009) The Weiss system for evaluating adrenocortical neoplasms: 25 years  
26  
27 later. *Hum Pathol* 40 (6):757-768. doi:S0046-8177(09)00083-5 [pii]  
28  
29  
30 10.1016/j.humpath.2009.03.010  
31  
32  
33  
34
- 35 5. Blanes A, Diaz-Cano SJ (2007) Histologic criteria for adrenocortical proliferative lesions: value of  
36  
37 mitotic figure variability. *Am J Clin Pathol* 127 (3):398-408. doi:F7G613581L18603Q [pii]  
38  
39  
40 10.1309/MCGUQ3R4A4WWN3LB  
41  
42  
43  
44
- 45 6. Volante M, Bollito E, Sperone P, Tavaglione V, Daffara F, Porpiglia F, Terzolo M, Berruti A,  
46  
47 Papotti M (2009) Clinicopathological study of a series of 92 adrenocortical carcinomas: from a  
48  
49 proposal of simplified diagnostic algorithm to prognostic stratification. *Histopathology* 55 (5):535-  
50  
51 543. doi:HIS3423 [pii]  
52  
53  
54 10.1111/j.1365-2559.2009.03423.x  
55  
56  
57  
58  
59  
60  
61  
62  
63  
64  
65

- 1  
2  
3  
4  
5  
6  
7  
8  
9  
10  
11  
12  
13  
14  
15  
16  
17  
18  
19  
20  
21  
22  
23  
24  
25  
26  
27  
28  
29  
30  
31  
32  
33  
34  
35  
36  
37  
38  
39  
40  
41  
42  
43  
44  
45  
46  
47  
48  
49  
50  
51  
52  
53  
54  
55  
56  
57  
58  
59  
60  
61  
62  
63  
64  
65
7. Papotti M, Volante M, Duregon E, Delsedime L, Terzolo M, Berruti A, Rosai J (2010) Adrenocortical tumors with myxoid features: a distinct morphologic and phenotypical variant exhibiting malignant behavior. *Am J Surg Pathol* 34 (7):973-983. doi:10.1097/PAS.0b013e3181e2b726
  8. Duregon E, Volante M, Cappia S, Cuccurullo A, Bisceglia M, Wong DD, Spagnolo DV, Szpak-Ulczok S, Bollito E, Daffara F, Berruti A, Terzolo M, Papotti M (2011) Oncocytic adrenocortical tumors: diagnostic algorithm and mitochondrial DNA profile in 27 cases. *Am J Surg Pathol* 35 (12):1882-1893. doi:10.1097/PAS.0b013e31822da401
  9. Tissier F, Aubert S, Leteurtre E, Al Ghuzlan A, Patey M, Decaussin M, Doucet L, Gobet F, Hoang C, Mazerolles C, Monges G, Renaudin K, Sturm N, Trouette H, Vacher-Lavenu MC, Viallon V, Baudin E, Bertagna X, Coste J, Libe R (2012) Adrenocortical tumors: improving the practice of the Weiss system through virtual microscopy: a National Program of the French Network INCa-COMETE. *Am J Surg Pathol* 36 (8):1194-1201. doi:10.1097/PAS.0b013e31825a6308  
00000478-201208000-00011 [pii]
  10. Duregon E, Fassina A, Volante M, Nesi G, Santi R, Gatti G, Cappellesso R, Dalino Ciaramella P, Ventura L, Gambacorta M, Dei Tos AP, Loli P, Mannelli M, Mantero F, Berruti A, Terzolo M, Papotti M (2013) The Reticulin Algorithm for Adrenocortical Tumor Diagnosis: A Multicentric Validation Study on 245 Unpublished Cases. *Am J Surg Pathol*. doi:10.1097/PAS.0b013e31828d387b
  11. Kakimoto S, Yushita Y, Sanefuji T, Kondo A, Fujishima N, Kishikawa M, Matsumoto K (1986) Non-hormonal adrenocortical adenoma with oncocytoma-like appearances. *Hinyokika Kyo* 32 (5):757-763

- 1  
2  
3  
4  
5  
6  
7  
8  
9  
10  
11  
12  
13  
14  
15  
16  
17  
18  
19  
20  
21  
22  
23  
24  
25  
26  
27  
28  
29  
30  
31  
32  
33  
34  
35  
36  
37  
38  
39  
40  
41  
42  
43  
44  
45  
46  
47  
48  
49  
50  
51  
52  
53  
54  
55  
56  
57  
58  
59  
60  
61  
62  
63  
64  
65
12. Bisceglia M, Ludovico O, Di Mattia A, Ben-Dor D, Sandbank J, Pasquinelli G, Lau SK, Weiss LM (2004) Adrenocortical oncocytic tumors: report of 10 cases and review of the literature. *Int J Surg Pathol* 12 (3):231-243
  13. Wong DD, Spagnolo DV, Bisceglia M, Havlat M, McCallum D, Platten MA (2011) Oncocytic adrenocortical neoplasms-a clinicopathologic study of 13 new cases emphasizing the importance of their recognition. *Hum Pathol*. doi:S0046-8177(10)00333-3 [pii]  
10.1016/j.humpath.2010.08.010
  14. Lewis PD, Baxter P, Paul Griffiths A, Parry JM, Skibinski DO (2000) Detection of damage to the mitochondrial genome in the oncocytic cells of Warthin's tumour. *J Pathol* 191 (3):274-281. doi:10.1002/1096-9896(2000)9999:9999<::AID-PATH634>3.0.CO;2-U [pii]  
10.1002/1096-9896(2000)9999:9999<::AID-PATH634>3.0.CO;2-U
  15. Lewis PD, Fradley SR, Griffiths AP, Baxter PW, Parry JM (2002) Mitochondrial DNA mutations in the parotid gland of cigarette smokers and non-smokers. *Mutat Res* 518 (1):47-54. doi:S1383571802000669 [pii]
  16. Tang CK, Harriman BB, Toker C (1979) Myxoid adrenal cortical carcinoma: a light and electron microscopic study. *Arch Pathol Lab Med* 103 (12):635-638
  17. Weissferdt A, Phan A, Suster S, Moran CA (2013) Myxoid adrenocortical carcinoma: a clinicopathologic and immunohistochemical study of 7 cases, including 1 case with lipomatous metaplasia. *Am J Clin Pathol* 139 (6):780-786. doi:10.1309/AJCPCDZLC13RSXRZ  
139/6/780 [pii]

- 1  
2  
3  
4  
5  
6  
7  
8  
9  
10  
11  
12  
13  
14  
15  
16  
17  
18  
19  
20  
21  
22  
23  
24  
25  
26  
27  
28  
29  
30  
31  
32  
33  
34  
35  
36  
37  
38  
39  
40  
41  
42  
43  
44  
45  
46  
47  
48  
49  
50  
51  
52  
53  
54  
55  
56  
57  
58  
59  
60  
61  
62  
63  
64  
65
18. Okazumi S, Asano T, Ryu M, Nagashima T, Odaka M, Isono K, Nishizawa T (1987) [Surgical resection of adrenal carcinoma extending into the vena cava, right atrium and ventricle: case report and review of the literature]. *Nippon Geka Gakkai Zasshi* 88 (2):231-238
  19. Collina G, Maldarizzi F, Betts CM, Eusebi V (1989) Primary sarcomatoid carcinoma of the adrenal gland. First case report. *Virchows Arch A Pathol Anat Histopathol* 415 (2):161-167
  20. Lee MS, Park IA, Chi JG, Ham EK, Lee KC, Lee CW (1997) Adrenal carcinosarcoma--a case report. *J Korean Med Sci* 12 (4):374-377
  21. Sturm N, Moulai N, Laverriere MH, Chabre O, Descotes JL, Brambilla E (2008) Primary adrenocortical sarcomatoid carcinoma: case report and review of literature. *Virchows Arch* 452 (2):215-219. doi:10.1007/s00428-007-0536-y
  22. Coli A, Di Giorgio A, Castri F, Destito C, Marin AW, Bigotti G (2010) Sarcomatoid carcinoma of the adrenal gland: A case report and review of literature. *Pathol Res Pract* 206 (1):59-65. doi:S0344-0338(09)00086-7 [pii] 10.1016/j.prp.2009.02.012
  23. Barksdale SK, Marincola FM, Jaffe G (1993) Carcinosarcoma of the adrenal cortex presenting with mineralocorticoid excess. *Am J Surg Pathol* 17 (9):941-945
  24. Bertolini F, Rossi G, Focchi F, Giacometti M, Fontana A, Gibertini MC, Roncucci L, Luppi G, Torricelli P, Rossi A, Conte PF (2011) Primary adrenal gland carcinosarcoma associated with metastatic rectal cancer: a hitherto unreported collision tumor. *Tumori* 97 (5):27e-30e. doi:10.1700/989.10734
  25. Decorato JW, Gruber H, Petti M, Levowitz BS (1990) Adrenal carcinosarcoma. *J Surg Oncol* 45 (2):134-136

- 1  
2  
3  
4  
5  
6  
7  
8  
9  
10  
11  
12  
13  
14  
15  
16  
17  
18  
19  
20  
21  
22  
23  
24  
25  
26  
27  
28  
29  
30  
31  
32  
33  
34  
35  
36  
37  
38  
39  
40  
41  
42  
43  
44  
45  
46  
47  
48  
49  
50  
51  
52  
53  
54  
55  
56  
57  
58  
59  
60  
61  
62  
63  
64  
65
26. Fischler DF, Nunez C, Levin HS, McMahon JT, Sheeler LR, Adelstein DJ (1992) Adrenal carcinosarcoma presenting in a woman with clinical signs of virilization. A case report with immunohistochemical and ultrastructural findings. *Am J Surg Pathol* 16 (6):626-631
27. Sasaki K, Desimone M, Rao HR, Huang GJ, Seethala RR (2010) Adrenocortical carcinosarcoma: a case report and review of the literature. *Diagn Pathol* 5:51. doi:1746-1596-5-51 [pii]  
10.1186/1746-1596-5-51
28. Thway K, Olmos D, Shah C, Flora R, Shipley J, Fisher C (2012) Oncocytic adrenal cortical carcinosarcoma with pleomorphic rhabdomyosarcomatous metastases. *Am J Surg Pathol* 36 (3):470-477. doi:10.1097/PAS.0b013e31824517d9  
00000478-201203000-00019 [pii]
29. Wieneke JA, Thompson LD, Heffess CS (2003) Adrenal cortical neoplasms in the pediatric population: a clinicopathologic and immunophenotypic analysis of 83 patients. *Am J Surg Pathol* 27 (7):867-881
30. Magro G, Esposito G, Cecchetto G, Dall'Igna P, Marcato R, Gambini C, Boldrini R, Collini P, D'Onofrio V, Salfi N, d'Amore E, Ferrari A, Bisogno G, Alaggio R (2012) Pediatric adrenocortical tumors: morphological diagnostic criteria and immunohistochemical expression of matrix metalloproteinase type 2 and human leucocyte-associated antigen (HLA) class II antigens. Results from the Italian Pediatric Rare Tumor (TREP) Study project. *Hum Pathol* 43 (1):31-39. doi:10.1016/j.humpath.2011.04.016  
S0046-8177(11)00185-7 [pii]
31. Turk AT, Asad H, Trapasso J, Perilli G, LiVolsi VA (2012) Mixed corticomedullary carcinoma of the adrenal gland: a case report. *Endocr Pract* 18 (3):e37-42. doi:10.4158/EP11222.CR

E50K93147X65W7G4 [pii]

1  
2  
3 32. Lam KY, Lo CY (2002) Metastatic tumours of the adrenal glands: a 30-year experience in a  
4  
5 teaching hospital. *Clin Endocrinol (Oxf)* 56 (1):95-101. doi:1435 [pii]  
6  
7

8  
9 33. Gaffey MJ, Traweek ST, Mills SE, Travis WD, Lack EE, Medeiros LJ, Weiss LM (1992) Cytokeratin  
10  
11 expression in adrenocortical neoplasia: an immunohistochemical and biochemical study with  
12  
13 implications for the differential diagnosis of adrenocortical, hepatocellular, and renal cell  
14  
15 carcinoma. *Hum Pathol* 23 (2):144-153  
16  
17

18  
19 34. Jorda M, De MB, Nadji M (2002) Calretinin and inhibin are useful in separating adrenocortical  
20  
21 neoplasms from pheochromocytomas. *Appl Immunohistochem Mol Morphol* 10 (1):67-70  
22  
23

24  
25 35. Browning L, Bailey D, Parker A (2008) D2-40 is a sensitive and specific marker in differentiating  
26  
27 primary adrenal cortical tumours from both metastatic clear cell renal cell carcinoma and  
28  
29 phaeochromocytoma. *J Clin Pathol* 61 (3):293-296. doi:jcp.2007.049544 [pii]  
30  
31  
32  
33  
34  
35 10.1136/jcp.2007.049544  
36  
37

38  
39 36. Schroder S, Niendorf A, Achilles E, Dietel M, Padberg BC, Beisiegel U, Dralle H, Bressel M,  
40  
41 Kloppel G (1990) Immunocytochemical differential diagnosis of adrenocortical neoplasms using  
42  
43 the monoclonal antibody D11. *Virchows Arch A Pathol Anat Histopathol* 417 (2):89-96  
44  
45

46  
47 37. Schroder S, Padberg BC, Achilles E, Holl K, Dralle H, Kloppel G (1992) Immunocytochemistry in  
48  
49 adrenocortical tumours: a clinicomorphological study of 72 neoplasms. *Virchows Arch A Pathol*  
50  
51  
52  
53 Anat Histopathol 420 (1):65-70  
54

55  
56 38. Tartour E, Caillou B, Tenenbaum F, Schroder S, Luciani S, Talbot M, Schlumberger M (1993)  
57  
58 Immunohistochemical study of adrenocortical carcinoma. Predictive value of the D11 monoclonal  
59  
60 antibody. *Cancer* 72 (11):3296-3303  
61  
62  
63  
64  
65

- 1  
2  
3  
4  
5  
6  
7  
8  
9  
10  
11  
12  
13  
14  
15  
16  
17  
18  
19  
20  
21  
22  
23  
24  
25  
26  
27  
28  
29  
30  
31  
32  
33  
34  
35  
36  
37  
38  
39  
40  
41  
42  
43  
44  
45  
46  
47  
48  
49  
50  
51  
52  
53  
54  
55  
56  
57  
58  
59  
60  
61  
62  
63  
64  
65
39. Komminoth P, Roth J, Schroder S, Saremaslani P, Heitz PU (1995) Overlapping expression of immunohistochemical markers and synaptophysin mRNA in pheochromocytomas and adrenocortical carcinomas. Implications for the differential diagnosis of adrenal gland tumors. *Lab Invest* 72 (4):424-431
40. Busam KJ, Iversen K, Coplan KA, Old LJ, Stockert E, Chen YT, McGregor D, Jungbluth A (1998) Immunoreactivity for A103, an antibody to melan-A (Mart-1), in adrenocortical and other steroid tumors. *Am J Surg Pathol* 22 (1):57-63
41. Ghorab Z, Jorda M, Ganjei P, Nadji M (2003) Melan A (A103) is expressed in adrenocortical neoplasms but not in renal cell and hepatocellular carcinomas. *Appl Immunohistochem Mol Morphol* 11 (4):330-333
42. Arola J, Liu J, Heikkila P, Voutilainen R, Kahri A (1998) Expression of inhibin alpha in the human adrenal gland and adrenocortical tumors. *Endocr Res* 24 (3-4):865-867
43. McCluggage WG, Burton J, Maxwell P, Sloan JM (1998) Immunohistochemical staining of normal, hyperplastic, and neoplastic adrenal cortex with a monoclonal antibody against alpha inhibin. *J Clin Pathol* 51 (2):114-116
44. Munro LM, Kennedy A, McNicol AM (1999) The expression of inhibin/activin subunits in the human adrenal cortex and its tumours. *J Endocrinol* 161 (2):341-347. doi:JOE03142 [pii]
45. Arola J, Liu J, Heikkila P, Ilvesmaki V, Salmenkivi K, Voutilainen R, Kahri AI (2000) Expression of inhibin alpha in adrenocortical tumours reflects the hormonal status of the neoplasm. *J Endocrinol* 165 (2):223-229. doi:JOE03576 [pii]

- 1  
2  
3  
4  
5  
6  
7  
8  
9  
10  
11  
12  
13  
14  
15  
16  
17  
18  
19  
20  
21  
22  
23  
24  
25  
26  
27  
28  
29  
30  
31  
32  
33  
34  
35  
36  
37  
38  
39  
40  
41  
42  
43  
44  
45  
46  
47  
48  
49  
50  
51  
52  
53  
54  
55  
56  
57  
58  
59  
60  
61  
62  
63  
64  
65
46. Sasano H, Shizawa S, Suzuki T, Takayama K, Fukaya T, Morohashi K, Nagura H (1995) Transcription factor adrenal 4 binding protein as a marker of adrenocortical malignancy. *Hum Pathol* 26 (10):1154-1156
47. Figueiredo BC, Cavalli LR, Pianovski MA, Lalli E, Sandrini R, Ribeiro RC, Zambetti G, DeLacerda L, Rodrigues GA, Haddad BR (2005) Amplification of the steroidogenic factor 1 gene in childhood adrenocortical tumors. *J Clin Endocrinol Metab* 90 (2):615-619. doi:jc.2004-0942 [pii] 10.1210/jc.2004-0942
48. Pianovski MA, Cavalli LR, Figueiredo BC, Santos SC, Doghman M, Ribeiro RC, Oliveira AG, Michalkiewicz E, Rodrigues GA, Zambetti G, Haddad BR, Lalli E (2006) SF-1 overexpression in childhood adrenocortical tumours. *Eur J Cancer* 42 (8):1040-1043. doi:S0959-8049(06)00127-4 [pii] 10.1016/j.ejca.2006.01.022
49. Sbiera S, Schull S, Assie G, Voelker HU, Kraus L, Beyer M, Ragazzon B, Beuschlein F, Willenberg HS, Hahner S, Saeger W, Bertherat J, Allolio B, Fassnacht M (2010) High diagnostic and prognostic value of steroidogenic factor-1 expression in adrenal tumors. *J Clin Endocrinol Metab* 95 (10):E161-171. doi:jc.2010-0653 [pii] 10.1210/jc.2010-0653
50. Sangoi AR, Fujiwara M, West RB, Montgomery KD, Bonventre JV, Higgins JP, Rouse RV, Gokden N, McKenney JK (2011) Immunohistochemical distinction of primary adrenal cortical lesions from metastatic clear cell renal cell carcinoma: a study of 248 cases. *Am J Surg Pathol* 35 (5):678-686. doi:10.1097/PAS.0b013e3182152629 00000478-201105000-00006 [pii]



- 1  
2  
3  
4  
5  
6  
7  
8  
9  
10  
11  
12  
13  
14  
15  
16  
17  
18  
19  
20  
21  
22  
23  
24  
25  
26  
27  
28  
29  
30  
31  
32  
33  
34  
35  
36  
37  
38  
39  
40  
41  
42  
43  
44  
45  
46  
47  
48  
49  
50  
51  
52  
53  
54  
55  
56  
57  
58  
59  
60  
61  
62  
63  
64  
65
51. Duregon E, Volante M, Giorcelli J, Terzolo M, Lalli E, Papotti M (2013) Diagnostic and prognostic role of steroidogenic factor 1 in adrenocortical carcinoma: a validation study focusing on clinical and pathologic correlates. *Hum Pathol* 44 (5):822-828. doi:10.1016/j.humpath.2012.07.025  
S0046-8177(12)00288-2 [pii]
52. Weissferdt A, Phan A, Suster S, Moran CA (2013) Adrenocortical Carcinoma: A Comprehensive Immunohistochemical Study of 40 Cases. *Appl Immunohistochem Mol Morphol*. doi:10.1097/PAI.0b013e31828a96cf
53. McNicol AM, Struthers AL, Nolan CE, Hermans J, Haak HR (1997) Proliferation in Adrenocortical Tumors: Correlation with Clinical Outcome and p53 Status. *Endocr Pathol* 8 (1):29-36. doi:EP080129 [pii]
54. Iino K, Sasano H, Yabuki N, Oki Y, Kikuchi A, Yoshimi T, Nagura H (1997) DNA topoisomerase II alpha and Ki-67 in human adrenocortical neoplasms: a possible marker of differentiation between adenomas and carcinomas. *Mod Pathol* 10 (9):901-907
55. Nakazumi H, Sasano H, Iino K, Ohashi Y, Orikasa S (1998) Expression of cell cycle inhibitor p27 and Ki-67 in human adrenocortical neoplasms. *Mod Pathol* 11 (12):1165-1170
56. Arola J, Salmenkivi K, Liu J, Kahri AI, Heikkila P (2000) p53 and Ki67 in adrenocortical tumors. *Endocr Res* 26 (4):861-865
57. Terzolo M, Boccuzzi A, Bovio S, Cappia S, De Giuli P, Ali A, Paccotti P, Porpiglia F, Fontana D, Angeli A (2001) Immunohistochemical assessment of Ki-67 in the differential diagnosis of adrenocortical tumors. *Urology* 57 (1):176-182. doi:S0090-4295(00)00852-9 [pii]

- 1  
2  
3  
4  
5  
6  
7  
8  
9  
10  
11  
12  
13  
14  
15  
16  
17  
18  
19  
20  
21  
22  
23  
24  
25  
26  
27  
28  
29  
30  
31  
32  
33  
34  
35  
36  
37  
38  
39  
40  
41  
42  
43  
44  
45  
46  
47  
48  
49  
50  
51  
52  
53  
54  
55  
56  
57  
58  
59  
60  
61  
62  
63  
64  
65
58. Stojadinovic A, Brennan MF, Hoos A, Omeroglu A, Leung DH, Dudas ME, Nissan A, Cordon-Cardo C, Ghossein RA (2003) Adrenocortical adenoma and carcinoma: histopathological and molecular comparative analysis. *Mod Pathol* 16 (8):742-751. doi:10.1097/01.MP.0000081730.72305.81
59. Soon PS, Gill AJ, Benn DE, Clarkson A, Robinson BG, McDonald KL, Sidhu SB (2009) Microarray gene expression and immunohistochemistry analyses of adrenocortical tumors identify IGF2 and Ki-67 as useful in differentiating carcinomas from adenomas. *Endocr Relat Cancer* 16 (2):573-583. doi:10.1677/ERC-08-0237  
ERC-08-0237 [pii]
60. Schmitt A, Saremaslani P, Schmid S, Rousson V, Montani M, Schmid DM, Heitz PU, Komminoth P, Perren A (2006) IGFII and MIB1 immunohistochemistry is helpful for the differentiation of benign from malignant adrenocortical tumours. *Histopathology* 49 (3):298-307. doi:HIS2505 [pii] 10.1111/j.1365-2559.2006.02505.x
61. Duregon E, Molinaro L, Volante M, Ventura L, Righi L, Bolla S, Terzolo M, Sapino A, Papotti M (2013) Comparative diagnostic and prognostic performances of morphological and phospho-histone H3-based mitotic count and Ki-67 proliferation index in adrenocortical carcinoma. *Mod Pathol*
62. Libe R, Groussin L, Tissier F, Elie C, Rene-Corail F, Fratticci A, Jullian E, Beck-Peccoz P, Bertagna X, Gicquel C, Bertherat J (2007) Somatic TP53 mutations are relatively rare among adrenocortical cancers with the frequent 17p13 loss of heterozygosity. *Clin Cancer Res* 13 (3):844-850. doi:13/3/844 [pii] 10.1158/1078-0432.CCR-06-2085

1  
2  
3  
4  
5  
6  
7  
8  
9  
10  
11  
12  
13  
14  
15  
16  
17  
18  
19  
20  
21  
22  
23  
24  
25  
26  
27  
28  
29  
30  
31  
32  
33  
34  
35  
36  
37  
38  
39  
40  
41  
42  
43  
44  
45  
46  
47  
48  
49  
50  
51  
52  
53  
54  
55  
56  
57  
58  
59  
60  
61  
62  
63  
64  
65

63. Vargas MP, Vargas HI, Kleiner DE, Merino MJ (1997) Adrenocortical neoplasms: role of prognostic markers MIB-1, P53, and RB. *Am J Surg Pathol* 21 (5):556-562

64. Morimoto R, Satoh F, Murakami O, Suzuki T, Abe T, Tanemoto M, Abe M, Uruno A, Ishidoya S, Arai Y, Takahashi K, Sasano H, Ito S (2008) Immunohistochemistry of a proliferation marker Ki67/MIB1 in adrenocortical carcinomas: Ki67/MIB1 labeling index is a predictor for recurrence of adrenocortical carcinomas. *Endocr J* 55 (1):49-55. doi:JST.JSTAGE/endocrj/K07-079 [pii]

65. Dohna M, Reincke M, Mincheva A, Allolio B, Solinas-Toldo S, Lichter P (2000) Adrenocortical carcinoma is characterized by a high frequency of chromosomal gains and high-level amplifications. *Genes Chromosomes Cancer* 28 (2):145-152. doi:10.1002/(SICI)1098-2264(200006)28:2<145::AID-GCC3>3.0.CO;2-7 [pii]

66. Gaujoux S, Grabar S, Fassnacht M, Ragazzon B, Launay P, Libe R, Chokri I, Audebourg A, Royer B, Sbiera S, Vacher-Lavenu MC, Dousset B, Bertagna X, Allolio B, Bertherat J, Tissier F (2011) beta-catenin activation is associated with specific clinical and pathologic characteristics and a poor outcome in adrenocortical carcinoma. *Clin Cancer Res* 17 (2):328-336. doi:1078-0432.CCR-10-2006 [pii]  
10.1158/1078-0432.CCR-10-2006

67. Ronchi CL, Sbiera S, Leich E, Tissier F, Steinhauer S, Deutschbein T, Fassnacht M, Allolio B (2012) Low SGK1 Expression in Human Adrenocortical Tumors Is Associated with ACTH-Independent Glucocorticoid Secretion and Poor Prognosis. *J Clin Endocrinol Metab*. doi:jc.2012-2669 [pii]  
10.1210/jc.2012-2669

- 1  
2  
3  
4  
5  
6  
7  
8  
9  
10  
11  
12  
13  
14  
15  
16  
17  
18  
19  
20  
21  
22  
23  
24  
25  
26  
27  
28  
29  
30  
31  
32  
33  
34  
35  
36  
37  
38  
39  
40  
41  
42  
43  
44  
45  
46  
47  
48  
49  
50  
51  
52  
53  
54  
55  
56  
57  
58  
59  
60  
61  
62  
63  
64  
65
68. Volante M, Sperone P, Bollito E, Frangipane E, Rosas R, Daffara F, Terzolo M, Berruti A, Papotti M (2006) Matrix metalloproteinase type 2 expression in malignant adrenocortical tumors: Diagnostic and prognostic significance in a series of 50 adrenocortical carcinomas. *Mod Pathol* 19 (12):1563-1569. doi:3800683 [pii]  
10.1038/modpathol.3800683
69. Fenske W, Volker HU, Adam P, Hahner S, Johanssen S, Wortmann S, Schmidt M, Morcos M, Muller-Hermelink HK, Allolio B, Fassnacht M (2009) Glucose transporter GLUT1 expression is an stage-independent predictor of clinical outcome in adrenocortical carcinoma. *Endocr Relat Cancer* 16 (3):919-928. doi:ERC-08-0211 [pii]  
10.1677/ERC-08-0211
70. Carney JA, Hruska LS, Beauchamp GD, Gordon H (1986) Dominant inheritance of the complex of myxomas, spotty pigmentation, and endocrine overactivity. *Mayo Clin Proc* 61 (3):165-172
71. Kirschner LS, Carney JA, Pack SD, Taymans SE, Giatzakis C, Cho YS, Cho-Chung YS, Stratakis CA (2000) Mutations of the gene encoding the protein kinase A type I-alpha regulatory subunit in patients with the Carney complex. *Nat Genet* 26 (1):89-92. doi:10.1038/79238
72. Else T (2012) Association of adrenocortical carcinoma with familial cancer susceptibility syndromes. *Mol Cell Endocrinol* 351 (1):66-70. doi:10.1016/j.mce.2011.12.008  
S0303-7207(11)00732-5 [pii]
73. Painter TA, Jagelman DG (1985) Adrenal adenomas and adrenal carcinomas in association with hereditary adenomatosis of the colon and rectum. *Cancer* 55 (9):2001-2004

- 1  
2  
3  
4  
5  
6  
7  
8  
9  
10  
11  
12  
13  
14  
15  
16  
17  
18  
19  
20  
21  
22  
23  
24  
25  
26  
27  
28  
29  
30  
31  
32  
33  
34  
35  
36  
37  
38  
39  
40  
41  
42  
43  
44  
45  
46  
47  
48  
49  
50  
51  
52  
53  
54  
55  
56  
57  
58  
59  
60  
61  
62  
63  
64  
65
74. Lynch HT, Kimberling W, Albano WA, Lynch JF, Biscone K, Schuelke GS, Sandberg AA, Lipkin M, Deschner EE, Mikol YB, et al. (1985) Hereditary nonpolyposis colorectal cancer (Lynch syndromes I and II). I. Clinical description of resource. *Cancer* 56 (4):934-938
75. Achatz MI, Hainaut P, Ashton-Prolla P (2009) Highly prevalent TP53 mutation predisposing to many cancers in the Brazilian population: a case for newborn screening? *Lancet Oncol* 10 (9):920-925. doi:10.1016/S1470-2045(09)70089-0  
S1470-2045(09)70089-0 [pii]
76. Custodio G, Parise GA, Kiesel Filho N, Komechen H, Sabbaga CC, Rosati R, Grisa L, Parise IZ, Pianovski MA, Fiori CM, Ledesma JA, Barbosa JR, Figueiredo FR, Sade ER, Ibanez H, Arram SB, Stinghen ST, Mengarelli LR, Figueiredo MM, Carvalho DC, Avilla SG, Woiski TD, Poncio LC, Lima GF, Pontarolo R, Lalli E, Zhou Y, Zambetti GP, Ribeiro RC, Figueiredo BC (2013) Impact of neonatal screening and surveillance for the TP53 R337H mutation on early detection of childhood adrenocortical tumors. *J Clin Oncol* 31 (20):2619-2626. doi:10.1200/JCO.2012.46.3711  
JCO.2012.46.3711 [pii]
77. Herrmann LJ, Heinze B, Fassnacht M, Willenberg HS, Quinkler M, Reisch N, Zink M, Allolio B, Hahner S (2012) TP53 germline mutations in adult patients with adrenocortical carcinoma. *J Clin Endocrinol Metab* 97 (3):E476-485. doi:10.1210/jc.2011-1982  
jc.2011-1982 [pii]
78. DeChiara TM, Robertson EJ, Efstratiadis A (1991) Parental imprinting of the mouse insulin-like growth factor II gene. *Cell* 64 (4):849-859. doi:0092-8674(91)90513-X [pii]
79. Weksberg R, Shuman C, Smith AC (2005) Beckwith-Wiedemann syndrome. *Am J Med Genet C Semin Med Genet* 137C (1):12-23. doi:10.1002/ajmg.c.30058

1  
2  
3  
4  
5  
6  
7  
8  
9  
10  
11  
12  
13  
14  
15  
16  
17  
18  
19  
20  
21  
22  
23  
24  
25  
26  
27  
28  
29  
30  
31  
32  
33  
34  
35  
36  
37  
38  
39  
40  
41  
42  
43  
44  
45  
46  
47  
48  
49  
50  
51  
52  
53  
54  
55  
56  
57  
58  
59  
60  
61  
62  
63  
64  
65

80. Langer P, Cupisti K, Bartsch DK, Nies C, Goretzki PE, Rothmund M, Roher HD (2002) Adrenal involvement in multiple endocrine neoplasia type 1. *World J Surg* 26 (8):891-896.

doi:10.1007/s00268-002-6492-4

81. Bertherat J, Bertagna X (2009) Pathogenesis of adrenocortical cancer. *Best Pract Res Clin Endocrinol Metab* 23 (2):261-271. doi:10.1016/j.beem.2008.10.006

S1521-690X(08)00139-5 [pii]

82. Heppner C, Reincke M, Agarwal SK, Mora P, Allolio B, Burns AL, Spiegel AM, Marx SJ (1999) MEN1 gene analysis in sporadic adrenocortical neoplasms. *J Clin Endocrinol Metab* 84 (1):216-219

83. Schulte KM, Mengel M, Heinze M, Simon D, Scheuring S, Kohrer K, Roher HD (2000) Complete sequencing and messenger ribonucleic acid expression analysis of the MEN I gene in adrenal cancer. *J Clin Endocrinol Metab* 85 (1):441-448

84. Tissier F, Cavard C, Groussin L, Perlemoine K, Fumey G, Hagnere AM, Rene-Corail F, Jullian E, Gicquel C, Bertagna X, Vacher-Lavenu MC, Perret C, Bertherat J (2005) Mutations of beta-catenin in adrenocortical tumors: activation of the Wnt signaling pathway is a frequent event in both benign and malignant adrenocortical tumors. *Cancer Res* 65 (17):7622-7627. doi:65/17/7622 [pii]

10.1158/0008-5472.CAN-05-0593

85. Berthon A, Martinez A, Bertherat J, Val P (2012) Wnt/beta-catenin signalling in adrenal physiology and tumour development. *Mol Cell Endocrinol* 351 (1):87-95.

doi:10.1016/j.mce.2011.09.009

S0303-7207(11)00543-0 [pii]

- 1  
2  
3  
4  
5  
6  
7  
8  
9  
10  
11  
12  
13  
14  
15  
16  
17  
18  
19  
20  
21  
22  
23  
24  
25  
26  
27  
28  
29  
30  
31  
32  
33  
34  
35  
36  
37  
38  
39  
40  
41  
42  
43  
44  
45  
46  
47  
48  
49  
50  
51  
52  
53  
54  
55  
56  
57  
58  
59  
60  
61  
62  
63  
64  
65
86. Bonnet S, Gaujoux S, Launay P, Baudry C, Chokri I, Ragazzon B, Libe R, Rene-Corail F, Audebourg A, Vacher-Lavenu MC, Groussin L, Bertagna X, Dousset B, Bertherat J, Tissier F (2011) Wnt/beta-catenin pathway activation in adrenocortical adenomas is frequently due to somatic CTNNB1-activating mutations, which are associated with larger and nonsecreting tumors: a study in cortisol-secreting and -nonsecreting tumors. *J Clin Endocrinol Metab* 96 (2):E419-426. doi:10.1210/jc.2010-1885 [pii] 10.1210/jc.2010-1885
87. Yu B, Ragazzon B, Rizk-Rabin M, Bertherat J (2012) Protein kinase A alterations in endocrine tumors. *Horm Metab Res* 44 (10):741-748. doi:10.1055/s-0032-1316292
88. Cibas ES, Medeiros LJ, Weinberg DS, Gelb AB, Weiss LM (1990) Cellular DNA profiles of benign and malignant adrenocortical tumors. *Am J Surg Pathol* 14 (10):948-955
89. Stephan EA, Chung TH, Grant CS, Kim S, Von Hoff DD, Trent JM, Demeure MJ (2008) Adrenocortical carcinoma survival rates correlated to genomic copy number variants. *Mol Cancer Ther* 7 (2):425-431. doi:10.1158/1535-7163.MCT-07-0267 7/2/425 [pii]
90. Kjellman M, Kallioniemi OP, Karhu R, Hoog A, Farnebo LO, Auer G, Larsson C, Backdahl M (1996) Genetic aberrations in adrenocortical tumors detected using comparative genomic hybridization correlate with tumor size and malignancy. *Cancer Res* 56 (18):4219-4223
91. Letouze E, Rosati R, Komechen H, Doghman M, Marisa L, Fluck C, de Krijger RR, van Noesel MM, Mas JC, Pianovski MA, Zambetti GP, Figueiredo BC, Lalli E (2012) SNP array profiling of childhood adrenocortical tumors reveals distinct pathways of tumorigenesis and highlights candidate driver genes. *J Clin Endocrinol Metab* 97 (7):E1284-1293. doi:10.1210/jc.2012-1184

1  
2  
3  
4  
5  
6  
7  
8  
9  
10  
11  
12  
13  
14  
15  
16  
17  
18  
19  
20  
21  
22  
23  
24  
25  
26  
27  
28  
29  
30  
31  
32  
33  
34  
35  
36  
37  
38  
39  
40  
41  
42  
43  
44  
45  
46  
47  
48  
49  
50  
51  
52  
53  
54  
55  
56  
57  
58  
59  
60  
61  
62  
63  
64  
65

jc.2012-1184 [pii]

92. Giordano TJ, Thomas DG, Kuick R, Lizyness M, Misek DE, Smith AL, Sanders D, Aljundi RT, Gauger PG, Thompson NW, Taylor JM, Hanash SM (2003) Distinct transcriptional profiles of adrenocortical tumors uncovered by DNA microarray analysis. *Am J Pathol* 162 (2):521-531. doi:S0002-9440(10)63846-1 [pii]

10.1016/S0002-9440(10)63846-1

93. de Fraipont F, El Atifi M, Cherradi N, Le Moigne G, Defaye G, Houlgatte R, Bertherat J, Bertagna X, Plouin PF, Baudin E, Berger F, Gicquel C, Chabre O, Feige JJ (2005) Gene expression profiling of human adrenocortical tumors using complementary deoxyribonucleic Acid microarrays identifies several candidate genes as markers of malignancy. *J Clin Endocrinol Metab* 90 (3):1819-1829. doi:jc.2004-1075 [pii]

10.1210/jc.2004-1075

94. Velazquez-Fernandez D, Laurell C, Geli J, Hoog A, Odeberg J, Kjellman M, Lundeberg J, Hamberger B, Nilsson P, Backdahl M (2005) Expression profiling of adrenocortical neoplasms suggests a molecular signature of malignancy. *Surgery* 138 (6):1087-1094. doi:S0039-6060(05)00652-5 [pii]

10.1016/j.surg.2005.09.031

95. Slater EP, Diehl SM, Langer P, Samans B, Ramaswamy A, Zielke A, Bartsch DK (2006) Analysis by cDNA microarrays of gene expression patterns of human adrenocortical tumors. *Eur J Endocrinol* 154 (4):587-598. doi:154/4/587 [pii]

10.1530/eje.1.02116



- 1  
2  
3  
4  
5  
6  
7  
8  
9  
10  
11  
12  
13  
14  
15  
16  
17  
18  
19  
20  
21  
22  
23  
24  
25  
26  
27  
28  
29  
30  
31  
32  
33  
34  
35  
36  
37  
38  
39  
40  
41  
42  
43  
44  
45  
46  
47  
48  
49  
50  
51  
52  
53  
54  
55  
56  
57  
58  
59  
60  
61  
62  
63  
64  
65
96. Giordano TJ, Kuick R, Else T, Gauger PG, Vinco M, Bauersfeld J, Sanders D, Thomas DG, Doherty G, Hammer G (2009) Molecular classification and prognostication of adrenocortical tumors by transcriptome profiling. *Clin Cancer Res* 15 (2):668-676. doi:15/2/668 [pii]  
10.1158/1078-0432.CCR-08-1067
97. de Reynies A, Assie G, Rickman DS, Tissier F, Groussin L, Rene-Corail F, Dousset B, Bertagna X, Clauser E, Bertherat J (2009) Gene expression profiling reveals a new classification of adrenocortical tumors and identifies molecular predictors of malignancy and survival. *J Clin Oncol* 27 (7):1108-1115. doi:JCO.2008.18.5678 [pii]  
10.1200/JCO.2008.18.5678
98. Tombol Z, Szabo PM, Molnar V, Wiener Z, Tolgyesi G, Horanyi J, Riesz P, Reismann P, Patocs A, Liko I, Gaillard RC, Falus A, Racz K, Igaz P (2009) Integrative molecular bioinformatics study of human adrenocortical tumors: microRNA, tissue-specific target prediction, and pathway analysis. *Endocr Relat Cancer* 16 (3):895-906. doi:10.1677/ERC-09-0096  
ERC-09-0096 [pii]
99. Laurell C, Velazquez-Fernandez D, Lindsten K, Juhlin C, Enberg U, Geli J, Hoog A, Kjellman M, Lundeberg J, Hamberger B, Larsson C, Nilsson P, Backdahl M (2009) Transcriptional profiling enables molecular classification of adrenocortical tumours. *Eur J Endocrinol* 161 (1):141-152. doi:10.1530/EJE-09-0068  
EJE-09-0068 [pii]
100. Assie G, Giordano TJ, Bertherat J (2012) Gene expression profiling in adrenocortical neoplasia. *Mol Cell Endocrinol* 351 (1):111-117. doi:10.1016/j.mce.2011.09.044

1  
2  
3  
4  
5  
6  
7  
8  
9  
10  
11  
12  
13  
14  
15  
16  
17  
18  
19  
20  
21  
22  
23  
24  
25  
26  
27  
28  
29  
30  
31  
32  
33  
34  
35  
36  
37  
38  
39  
40  
41  
42  
43  
44  
45  
46  
47  
48  
49  
50  
51  
52  
53  
54  
55  
56  
57  
58  
59  
60  
61  
62  
63  
64  
65

S0303-7207(11)00616-2 [pii]

101. de Krijger RR, Papathomas TG (2012) Adrenocortical neoplasia: evolving concepts in tumorigenesis with an emphasis on adrenal cortical carcinoma variants. *Virchows Arch* 460 (1):9-18. doi:10.1007/s00428-011-1166-y

102. Rana TM (2007) Illuminating the silence: understanding the structure and function of small RNAs. *Nat Rev Mol Cell Biol* 8 (1):23-36. doi:nrm2085 [pii]  
10.1038/nrm2085

103. Singh P, Soon PS, Feige JJ, Chabre O, Zhao JT, Cherradi N, Lalli E, Sidhu SB (2012) Dysregulation of microRNAs in adrenocortical tumors. *Mol Cell Endocrinol* 351 (1):118-128. doi:10.1016/j.mce.2011.09.041

S0303-7207(11)00585-5 [pii]

104. Soon PS, Tacon LJ, Gill AJ, Bambach CP, Sywak MS, Campbell PR, Yeh MW, Wong SG, Clifton-Bligh RJ, Robinson BG, Sidhu SB (2009) miR-195 and miR-483-5p Identified as Predictors of Poor Prognosis in Adrenocortical Cancer. *Clin Cancer Res* 15 (24):7684-7692. doi:1078-0432.CCR-09-1587 [pii]

10.1158/1078-0432.CCR-09-1587

105. Chabre O, Libe R, Assie G, Barreau O, Bertherat J, Bertagna X, Feige JJ, Cherradi N (2013) Serum miR-483-5p and miR-195 are predictive of recurrence risk in adrenocortical cancer patients. *Endocr Relat Cancer* 20 (4):579-594. doi:10.1530/ERC-13-0051

ERC-13-0051 [pii]

- 1  
2  
3  
4  
5  
6  
7  
8  
9  
10  
11  
12  
13  
14  
15  
16  
17  
18  
19  
20  
21  
22  
23  
24  
25  
26  
27  
28  
29  
30  
31  
32  
33  
34  
35  
36  
37  
38  
39  
40  
41  
42  
43  
44  
45  
46  
47  
48  
49  
50  
51  
52  
53  
54  
55  
56  
57  
58  
59  
60  
61  
62  
63  
64  
65
106. Gao ZH, Suppola S, Liu J, Heikkila P, Janne J, Voutilainen R (2002) Association of H19 promoter methylation with the expression of H19 and IGF-II genes in adrenocortical tumors. *J Clin Endocrinol Metab* 87 (3):1170-1176
107. Sidhu S, Martin E, Gicquel C, Melki J, Clark SJ, Campbell P, Magarey CJ, Schulte KM, Roher HD, Delbridge L, Robinson BG (2005) Mutation and methylation analysis of TP53 in adrenal carcinogenesis. *Eur J Surg Oncol* 31 (5):549-554. doi:S0748-7983(05)00026-0 [pii]  
10.1016/j.ejso.2005.01.013
108. Korah R, Healy JM, Kunstman JW, Fonseca AL, Ameri AH, Prasad ML, Carling T (2013) Epigenetic silencing of RASSF1A deregulates cytoskeleton and promotes malignant behavior of adrenocortical carcinoma. *Mol Cancer* 12:87. doi:10.1186/1476-4598-12-87  
1476-4598-12-87 [pii]
109. Fonseca AL, Kugelberg J, Starker LF, Scholl U, Choi M, Hellman P, Akerstrom G, Westin G, Lifton RP, Bjorklund P, Carling T (2012) Comprehensive DNA methylation analysis of benign and malignant adrenocortical tumors. *Genes Chromosomes Cancer* 51 (10):949-960. doi:10.1002/gcc.21978
110. Rechache NS, Wang Y, Stevenson HS, Killian JK, Edelman DC, Merino M, Zhang L, Nilubol N, Stratakis CA, Meltzer PS, Kebebew E (2012) DNA methylation profiling identifies global methylation differences and markers of adrenocortical tumors. *J Clin Endocrinol Metab* 97 (6):E1004-1013. doi:10.1210/jc.2011-3298  
jc.2011-3298 [pii]
111. Liu-Chittenden Y, Kebebew E (2013) CpG island methylator phenotype in adrenocortical carcinoma: fact or fiction? *J Clin Endocrinol Metab* 98 (1):48-50. doi:10.1210/jc.2012-4063

98/1/48 [pii]

1  
2  
3 112. Barreau O, Assie G, Wilmot-Roussel H, Ragazzon B, Baudry C, Perlemoine K, Rene-Corail F,  
4 Bertagna X, Dousset B, Hamzaoui N, Tissier F, de Reynies A, Bertherat J (2013) Identification of a  
5  
6 CpG island methylator phenotype in adrenocortical carcinomas. J Clin Endocrinol Metab 98  
7  
8  
9 (1):E174-184. doi:10.1210/jc.2012-2993  
10

11  
12  
13 jc.2012-2993 [pii]

14  
15  
16  
17  
18 113. Barzon L, Sonino N, Fallo F, Palu G, Boscaro M (2003) Prevalence and natural history of  
19  
20 adrenal incidentalomas. Eur J Endocrinol 149 (4):273-285  
21

22  
23  
24 114. Bernard MH, Sidhu S, Berger N, Peix JL, Marsh DJ, Robinson BG, Gaston V, Le Bouc Y, Gicquel  
25  
26 C (2003) A case report in favor of a multistep adrenocortical tumorigenesis. J Clin Endocrinol  
27  
28 Metab 88 (3):998-1001  
29

30  
31  
32 115. Trezzi R, Poli F, Fellegara G (2009) "Dedifferentiated" adrenal cortical neoplasm. Int J Surg  
33  
34 Pathol 17 (4):343-344. doi:10.1177/1066896909335155  
35

36  
37  
38 1066896909335155 [pii]

39  
40  
41  
42 116. Heaton JH, Wood MA, Kim AC, Lima LO, Barlaskar FM, Almeida MQ, Fragoso MC, Kuick R,  
43  
44 Lerario AM, Simon DP, Soares IC, Starnes E, Thomas DG, Latronico AC, Giordano TJ, Hammer GD  
45  
46 (2012) Progression to adrenocortical tumorigenesis in mice and humans through insulin-like  
47  
48 growth factor 2 and beta-catenin. Am J Pathol 181 (3):1017-1033.  
49  
50  
51 doi:10.1016/j.ajpath.2012.05.026  
52

53  
54  
55 S0002-9440(12)00430-0 [pii]

1  
2  
3  
4  
5  
6  
7  
8  
9  
10  
11  
12  
13  
14  
15  
16  
17  
18  
19  
20  
21  
22  
23  
24  
25  
26  
27  
28  
29  
30  
31  
32  
33  
34  
35  
36  
37  
38  
39  
40  
41  
42  
43  
44  
45  
46  
47  
48  
49  
50  
51  
52  
53  
54  
55  
56  
57  
58  
59  
60  
61  
62  
63  
64  
65

117. Ronchi CL, Sbiera S, Leich E, Henzel K, Rosenwald A, Allolio B, Fassnacht M (2013) Single nucleotide polymorphism array profiling of adrenocortical tumors - evidence for an adenoma carcinoma sequence? PLoS One 8 (9):e73959. doi:10.1371/journal.pone.0073959

PONE-D-13-23019 [pii]

**Table 1.** Summary of most relevant adrenal carcinoma-related inherited susceptibility

syndromes.

	<b>Li-Fraumeni</b>	<b>Beckwith- Wiedemann</b>	<b>Gardner</b>	<b>MEN1</b>	<b>Carney Complex</b>
<b>Tumor</b>	AC	AC	AA (rarely AC)	AA (rarely AC)	AA
<b>gene/locus</b>	<i>TP53</i> (17q13.1)	alterated imprinting of 11p15.5	<i>APC</i> (5q21–22)	<i>MEN1</i> (11q13)	<i>PRKAR1A</i> (17q23–24)
<b>protein</b>	p53	IGF-II, p57kip2	APC	menin	PRKAR1A

Legend. AC: adrenal carcinoma; AA: adrenal adenoma

## FIGURE LEGENDS

1  
2  
3  
4  
5 **Figure 1.** Milestones in the pathological and molecular characterization of adrenal diseases in  
6  
7 the past 25 years.  
8  
9

10  
11  
12 **Figure 2.** Pathological characteristics of a case of adrenal carcinoma (2.5 cm in the largest  
13 dimension) showing residual peripheral “adenomatous” features (left part in **a**, **e**, **f**, **g**; upper left  
14 corner in **b**). Carcinoma component showed reticulin disruption (**b**), atypical mitotic figures (**c**),  
15 increased mitotic index (as highlighted by phospho-histone H3, **d**) and increased Ki-67 index (**e**);  
16  
17 adrenocortical markers such as Melan A (**f**) and SF-1 (**g**) were positive in both components.  
18  
19 (*original magnifications: 100x in all figures except c and d, 400x; a, c: H&E; b: silver staining; d:*  
20  
21 *immunoperoxidase with AEC as chromogen; e, f, g: immunoperoxidase with diaminobenzidine as*  
22  
23 *chromogen*)  
24  
25  
26  
27  
28  
29  
30  
31  
32  
33  
34  
35

36 **Figure 3.** Morphological and immunophenotypical profile of a breast carcinoma metastatic into  
37 an adrenal adenoma. Breast cancer cells (**a** to **d**, upper left corner) were immunoreactive for pan-  
38 cytocheratins (**b**) and estrogen receptors (**d**) but negative for Melan A (**c**). (*original magnifications:*  
39  
40 *200x in all figures; a: H&E; b-c-d: immunoperoxidase with diaminobenzidine as chromogen*)  
41  
42  
43  
44  
45  
46  
47  
48  
49  
50  
51  
52  
53  
54  
55  
56  
57  
58  
59  
60  
61  
62  
63  
64  
65

Figure  
[Click here to download high resolution image](#)

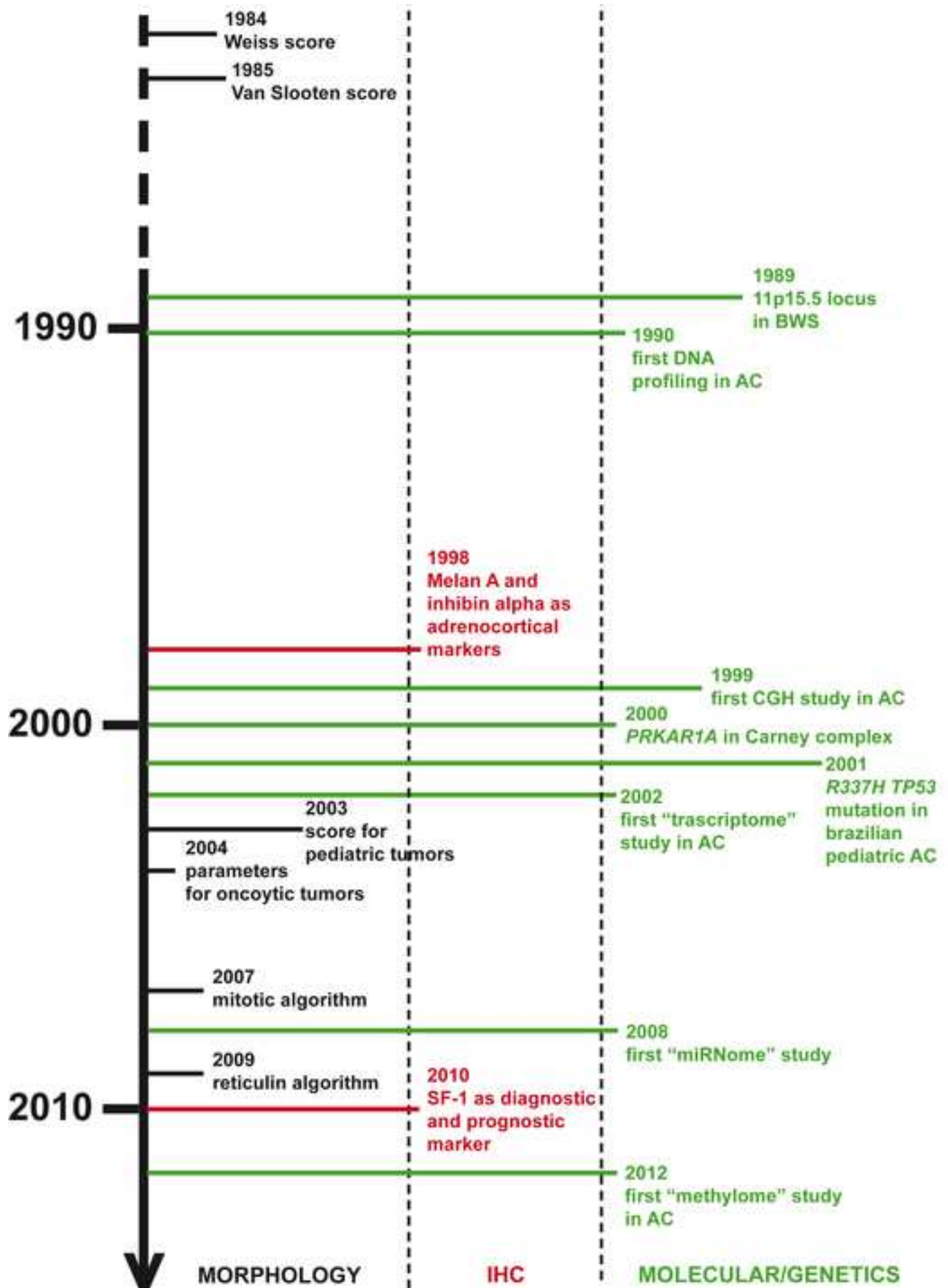




Figure  
[Click here to download high resolution image](#)

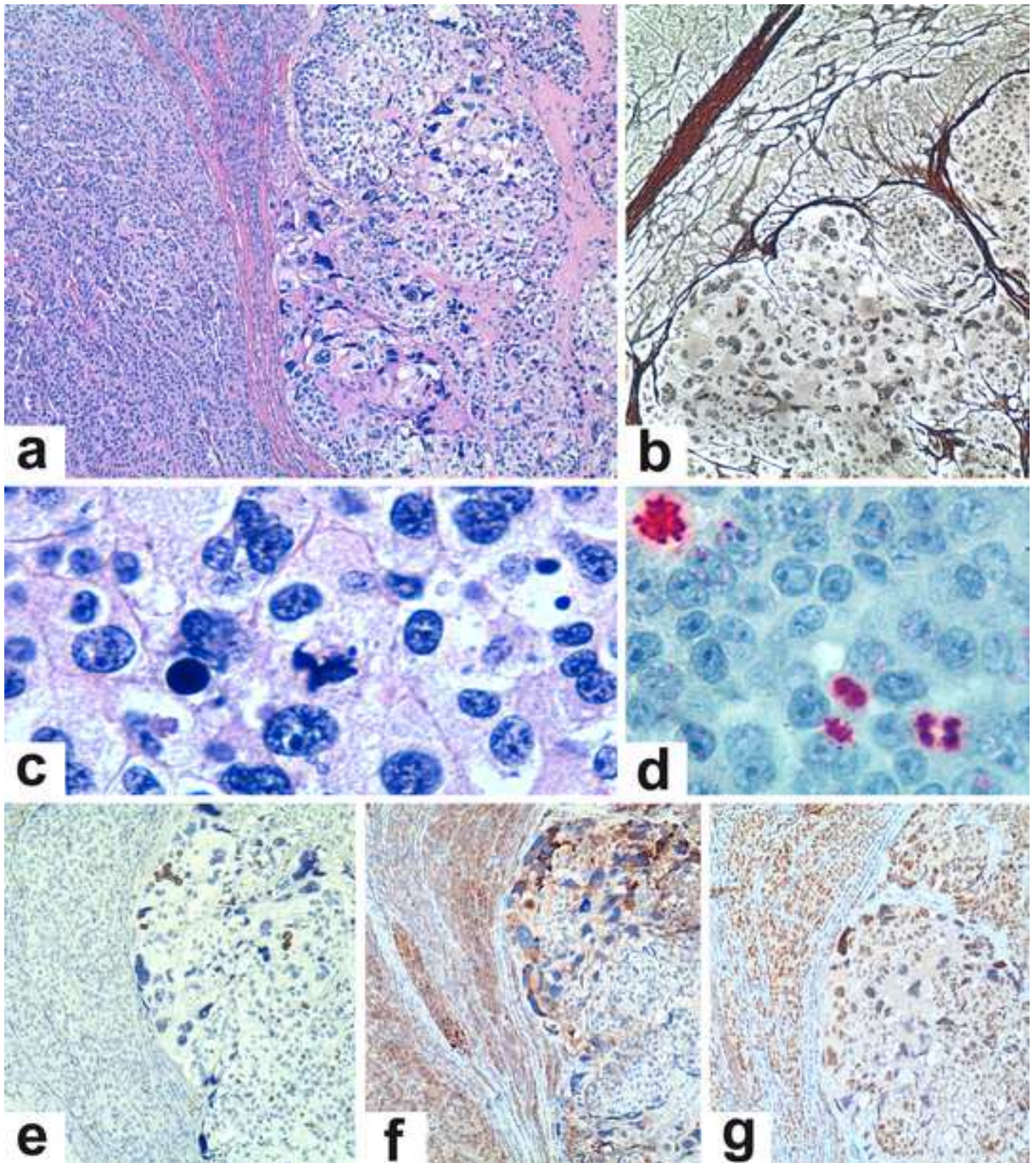




Figure  
[Click here to download high resolution image](#)

