

AperTO - Archivio Istituzionale Open Access dell'Università di Torino

microRNA expression patterns in adrenocortical carcinoma variants and clinical pathologic correlations

This is the author's manuscript

Original Citation:

Availability:

This version is available <http://hdl.handle.net/2318/152587> since

Published version:

DOI:10.1016/j.humpath.2014.04.005

Terms of use:

Open Access

Anyone can freely access the full text of works made available as "Open Access". Works made available under a Creative Commons license can be used according to the terms and conditions of said license. Use of all other works requires consent of the right holder (author or publisher) if not exempted from copyright protection by the applicable law.

(Article begins on next page)



UNIVERSITÀ DEGLI STUDI DI TORINO

This is an author version of the contribution published on:

Questa è la versione dell'autore dell'opera:

[Human pathology, 45 (8), 2014, DOI 10.1016/j.humpath.2014.04.005]

*ovvero [Duregon E, Rapa I, Votta A, Giorelli J, Daffara F, Terzolo M, Scagliotti GV,
Volante M, Papotti M., 45, Elsevier, 2014, pagg.1555-1562]*

The definitive version is available at:

La versione definitiva è disponibile alla URL:

[<http://www.sciencedirect.com/science/article/pii/S0046817714001580>]

micro-RNA EXPRESSION PATTERNS IN ADRENOCORTICAL CARCINOMA VARIANTS AND CLINICAL PATHOLOGICAL CORRELATIONS

Eleonora Duregon, MD, Ida Rapa, BSc, Arianna Votta, Jessica Giorcelli, Fulvia Daffara*, MD, Massimo Terzolo*, MD, Giorgio V. Scagliotti, MD, Marco Volante, MD, Mauro Papotti, MD

Departments of Oncology, and of *Clinical & Biological Sciences, University of Turin at San Luigi Hospital, Orbassano, 10043, Torino, Italy

KEY WORDS: adrenal cortex, carcinoma, micro-RNA, variant, prognosis

Running title: miRNA expression in adrenocortical carcinoma

Conflict of interest statement: All Authors declare the absence of any potential conflict of interest.

Source of support: Work supported by grant from the Italian Association for Cancer Research (AIRC, Milan, grant no. IG/10795/2010 to MP) and University of Turin (ex-60% grants to MV and MP). ED and IR are students of the Ph.D program in the Doctorate School of “Biomedical Sciences and Oncology” at the University of Turin.

Address for correspondence: Marco Volante, MD

Department of Oncology, University of Turin at San Luigi Hospital,

Regione Gonzole 10, 10043 Orbassano, Torino, Italy

Phone +390116705464; Fax: +390119026753; email: marco.volante@unito.it

ABSTRACT

Several miRNAs were shown to be de-regulated in adrenocortical carcinoma as compared to adenoma, but a detailed assessment of their expression in its histological variants and correlation with clinical-pathological characteristics has not been performed, so far. Our aim was to assess the expression of five selected miRNAs (*IGF2* gene-related miR-483-3p and 5p, hypoxia-induced miR-210, miR-195 and miR-1974) in a series of 51 adrenocortical carcinomas (35 classical, 6 myxoid, and 10 oncocytic) as compared to clinical and pathological features and immunohistochemical expression of prognostic markers, including steroidogenic factor 1 (SF-1), p53, β -catenin and glucose transporter 1 (GLUT-1). Oncocytic carcinomas had a reduced expression of miR-483-3p ($p= 0.0325$), miR-483-5p ($p= 0.0175$) and miR-210 ($p= 0.0366$), as compared to other histotypes. Over-expression of miR-210 was associated to the presence of necrosis ($p= 0.0035$), high Ki-67 index ($p=0.0013$) and high GLUT-1 expression ($p=0.0043$), whereas an inverse correlation with mitotic rate was observed in cases with high miR-483-3p ($p= 0.0191$) and miR-1974 ($p= 0.0017$) expression. High miR-1974 was also associated with low Ki-67 ($p= 0.0312$) and ENSAT stage ($p=0.0082$), and negative p53 ($p=0.0013$). At univariate analysis myxoid/classical histotype ($p=0.026$), high miR-210 ($p=0.0465$), high SF-1 protein ($p=0.0017$), high Ki-67 ($p=0.0066$) and high mitotic index ($p=0.0006$) were significantly associated to a shorter overall survival, the latter being the sole independent prognostic factor at multivariate analysis ($p= 0.017$). In conclusion, a) miR-483-3p, miR-483-5p and miR-210 are differentially expressed in adrenocortical carcinoma variants; b) high miR-210 is associated with clinico-pathological parameters of aggressiveness and a poor prognosis.

INTRODUCTION

Adrenocortical carcinoma is a rare malignancy with a highly aggressive biological behavior (20-40% five-year survival) [1,2]. The diagnosis of adrenocortical carcinoma is currently based on the Weiss System [3,4], a scoring procedure that can easily classify most cases, but is particularly challenged in tumors with incomplete morphological signs of malignancy, even if used by experts and specifically trained pathologists [5], and in adrenocortical carcinoma morphological variants, i.e. the myxoid and the oncocytic [2]. An inter-observer validation study recently showed that the Reticulin Algorithm, previously proposed as a diagnostic approach alternative to the Weiss System, is highly accurate and reproducible to define malignancy also in adrenocortical carcinoma special histotypes [6]. However, while the morphological distinctiveness of myxoid and oncocytic variant has already been thoroughly characterized and reviewed [7-10], their immunohistochemical and molecular phenotype has been addressed so far by very few studies only [8,10-13].

MicroRNAs (miRNAs) are short noncoding RNAs, 18 to 25 nucleotides in length, which regulate gene expression either by post-transcriptional regulation of gene expression leading to target mRNA degradation or by the repression of its translation with consequent decrease in the particular protein levels or even by up-regulation of their targets [14].

To date, several studies analyzed the miRNA expression profile in adrenocortical neoplasms, mainly aimed at finding out those useful to differentiate adenomas from carcinomas. However, the expression of none of these miRNAs has been tested within the group of adrenocortical carcinomas in terms of variability among variants or detailed association with clinical or pathological features. Therefore, we designed a study to explore the expression of five miRNA in a series of 51 adrenocortical carcinomas (including 35 classical, six myxoid, and 10 oncocytic) in comparison with clinical and pathologic features and immunohistochemical expression of markers related to biological

or clinical aggressiveness, including steroidogenic factor 1 (SF-1), p53, β -catenin and glucose transporter 1 (GLUT-1). Three miRNA were selected since those most consistently reported to be de-regulated in both tissue and serum of adrenocortical carcinoma patients: miR-483-3p and 5p, which are transcribed from an intronic sequence of *IGF2* gene and are commonly over-expressed in adrenocortical carcinoma, and miR-195 which is conversely down-modulated in adrenocortical carcinoma [15-20]; moreover, due to the peculiar metabolic and ultrastructural features of oncocytic cells which are the hall-mark of the oncocytic variant, two additional miRNAs - significantly de-regulated in adrenocortical cancer - were selected based on their involvement in the hypoxic pathway (miR-210) [21] or a peculiar mitochondrial localization (miR-1974) [22].

We here show that: a) miR-483-3p, miR-483-5p and miR-210 are differentially expressed among histological variants of adrenocortical carcinoma; b) high miR-210 levels are associated with clinical and pathological parameters of aggressiveness (necrosis and Ki-67 proliferation index) and a shorter overall survival.

MATERIAL AND METHODS

Tissue collection - 51 adrenocortical tumors having a Weiss score ≥ 3 [3,4] (including six myxoid and 10 oncocytic) were retrieved from the pathology files of the University of Turin. The 10 oncocytic tumors were also reclassified according to the Lin-Weiss-Bisceglia scheme [9], and all proved malignant even with this more accurate score. A control series of 47 unpublished conventional adrenocortical adenomas (all with a Weiss score ≤ 1) was also tested. All these cases had paraffin embedded tissue blocks suitable for miRNA extraction. The majority of adrenocortical carcinoma patients were treated at our Institution, which serves as a referral center for this disease in Italy. The histo-pathological features of all cases belonging to this data set have already been characterized as

detailed in previous publications by our group [6, 8, 10, 13, 23, 24]. For all of them, clinical data about treatment and outcome were updated (**Table 1**). The study received ethical approval from the local Review Board of our Institution.

miRNA expression analysis by means of real-time PCR - miRNA were extracted from paraffin embedded tissues using miRNeasy Kit (Qiagen srl Italy, Milan, Italy) according to manufacturer's instructions. Complementary DNA was synthesized with specific stemloop primers using 100ng total RNA in 15 µl total reaction. The reaction consisted of the following components: 100mM dNTP's, 10x RT Buffer, RNase Inhibitor, 5x TaqMan microRNA RT primer and Multiscribe RT enzyme and was carried out in a thermal cycler machine (Eppendorf, Hamburg, Germany) at the following conditions: 16°C for 30 minutes, 42°C for 30 minutes, 85°C for 5 minutes, 4°C for 10 minutes.

The following Taqman microRNA assays were employed by means of real-time PCR: hsa-miR-483-5p (code 002338), hsa-miR-483-3p (code 002339), hsa-miR-210 (code 000512), hsa-miR-195 (code 000494) and hsa-miR-1974 (code 121209_mat) (Life technologies, Carlsbad, CA, USA). Results were normalized using the $2^{-\Delta\Delta CT}$ -method (Pfaffl MW, 2001) using expression of U6-snRNA and the value for each miRNA in the case with the lowest expression as the reference. Reactions were carried out according to the following parameters in an ABI Prism 7900HT Sequence Detection System (Life technologies): 95°C for 10 minutes, 95°C for 15 seconds, 60°C for 60 seconds for 40 cycles.

Immunohistochemistry – 46 out of 51 adrenocortical carcinomas herein analyzed for miRNA expression were included in TMAs assembled as previously described [13] using three cores with a diameter of 2 mm from each case. Five µm thick paraffin sections serial to those used for conventional hematoxylin and eosin staining were obtained for immunohistochemical reactions. Raw data of SF-1 scores already obtained in 45 out of 46 cases were retrieved for comparison [13]; 46 out

of 51 cases had Ki-67 information already available from a recent study from our group [24]. Additional stainings included: p53 (DakoCytomation, Glostrup, Denmark; clone D07, diluted 1/300), β -catenin (Santacruz, polyclonal, clone H102, diluted 1/200), and GLUT-1 (Thermo scientific, clone SPM498, diluted 1/200). A biotin-free, dextran chain-based detection system (EnVision, Dako) was used according to a standard protocol, and diaminobenzidine served as the chromogen.

Staining interpretation and scoring system – All slides were analyzed by two pathologists (ED, MV), and all samples were considered adequate for all antibodies in the presence of two or more suitable cores after sectioning and staining procedures. Staining was assessed for each antibody as follows: SF-1, semiquantitative scoring system based on the evaluation of nuclear staining: score 0= no staining; score 1= focal (< 50% of the core) staining; score 2= diffuse (\geq 50% of the core) staining; p53, manual count of positive nuclei on 1000 cells and relative percentage; β -catenin, positive in presence cytoplasmic and/or nuclear staining; GLUT-1, positive only in presence of cell membrane staining.

Statistical analysis – Reciprocal correlations among the different miRNA expression levels and between miRNAs and mitotic/proliferation indexes were made using a two-tailed Spearman's test. Expression levels of miRNAs were compared to clinical and pathological characteristics and staining patterns for each antibody tested using Chi-square or Student's t tests, as appropriate. The prognostic impact of clinical and pathological parameters available (sex, age, hormonal secretion, weight, size, Weiss score, Ki-67 proliferation index, mitotic count, ENSAT stage and the reactivity to SF-1, p53, β -catenin and GLUT-1 antibodies) was tested in univariate overall survival analysis using the Kaplan–Meier product limit estimate of survival distribution and the Log Rank test. All parameters with a significant impact on survival at univariate analysis were included in multivariate analysis using

the Cox proportional hazard model. Statistical significance was set at $p < 0.05$. All tests were performed using GraphPad Prism version 6.0 and IBM SPSS Statistics Version 20.

RESULTS

Differential expression of miRNAs investigated in adenoma vs carcinoma samples.

All but one miRNA were significantly de-regulated in carcinoma vs adenoma samples. In particular, in agreement with what previously reported in the literature, miR-483-3p, miR-483-5p and miR-210 were significantly up-regulated whereas miR-195 was down regulated in carcinomas (p value: < 0.0001 for all four miRNAs) (**Figure 1**). By contrast, miR-1974 was not differentially expressed in benign vs malignant adrenocortical samples of our series ($p = 0.99$).

Reciprocal correlation among expression levels of miRNAs investigated in adrenocortical carcinoma

samples - miR-483-3p and miR-483-5p ($r = 0.7380$, $p < 0.0001$) and miR-210 and miR-1974 ($r = 0.4071$, $p = 0.003$) were highly reciprocally correlated. A slight inverse correlation among miR-1974 and miR-483-3p ($r = -0.2939$, $p = 0.0449$) was also observed (**Table 2**).

Correlation of miRNA expression levels and clinical pathological parameters including histological

variants - Significantly reduced expressions of miR-483-3p, miR-483-5p and miR-210 were observed in oncocytic as compared to classical and myxoid histotypes ($p = 0.0325$, $p = 0.0175$, $p = 0.0366$ for miR-483-3p, miR-483-5p and miR-210, respectively) (**Figure 2**). As far as concern clinical and pathological parameters, expression levels of any of the miRNAs analyzed were associated with patient age, tumor size, weight and total Weiss Score (**Table 3**). High miR-210 levels were associated to male sex (unpaired *t*-test, $p = 0.0003$), presence of necrosis (unpaired *t*-test, $p = 0.0035$) and high Ki-

67 proliferation index (unpaired *t*-test, $p=0.0013$). Although the association between high miR-210 and high mitotic rate was not statistically significant (unpaired *t*-test, $p=0.4963$), it was slightly positively correlated using the Spearman's linear correlation test ($r= 0.2898$, $p= 0.0457$). On the contrary, miR-493-3p and miR-1974 levels were higher in cases with low mitotic/proliferation indices (miR-493-3p and mitotic rate, unpaired *t*-test, $p= 0.0191$; miR-1974 and mitotic count, unpaired *t*-test, $p= 0.0017$; miR-1974 and Ki-67 proliferation index, unpaired *t*-test, $p= 0.0312$). High miR-1974 levels were also associated with low ENSAT stage ($p=0.0082$). Finally, miR-195 levels were slightly higher in functioning tumors (unpaired *t*-test, $p=0.0457$).

Correlation of miRNA expression levels with phenotypical markers of aggressiveness and disease

outcome - Membrane GLUT-1 staining was significantly associated with high miR-210 levels ($p=0.0043$), while negative p53 and β -catenin were associated with high levels of miR-1974 (unpaired *t*-test, $p=0.0013$) and miR-195 (unpaired *t*-test, $p= 0.011$), respectively. No statistically significant correlation was found among the miRNA investigated and SF-1 protein expression. At univariate survival analysis, myxoid or classical histotype [Log rank test, $p=0.026$, HR=0.1445 (CI 0.12-0.87)], mitotic count ≥ 11 [Log rank test, $p=0.0006$, HR=0.2398 (CI 0.07-0.46)], Ki-67 proliferation index ≥ 20 [median value; Log rank test, $p=0.0066$, HR=0.2827 (CI 0.09-0.59)], high SF-1 protein expression [Log rank test, $p=0.0017$, HR=0.2056 (CI 0.06-0.68)], and high miR-210 expression [Log rank test, $p=0.0465$, HR=0.4213 (CI 0.16-0.98)] were associated with a shorter overall survival (**Table 4 and Figure 3**). A trend to significance was observed for functioning carcinomas ($p=0.051$), nuclear p53 ($p= 0.063$), membrane GLUT-1 ($p= 0.065$), nuclear β -catenin ($p= 0.13$) and low miR-1974 levels ($p= 0.011$). At multivariate survival analysis, mitotic count confirmed to be the sole independent prognostic factor ($p= 0.017$).

DISCUSSION

In a series of adrenocortical carcinomas we investigated the expression of five miRNA, known to be de-regulated in this tumor type, demonstrating a differential expression of miR-483-3p, miR-483-5p and miR-210 in histological variants and a correlation with clinical and pathological features associated with aggressive behavior, with special reference to miR-210.

MiR-483-3p and miR-483-5p are derived from different arms of the same miRNA precursor, within the second intron of *IGF2* gene at 11p15.5. In NCI-H295R adrenocortical carcinoma cell line, miR-483-5p promotes cell proliferation, but has no effect on apoptosis [18], while miR-483-3p, targeting the pro-apoptotic protein PUMA [25], protects cells from apoptosis [18]. They were consistently found to be over-expressed in comparison with adenomas [15-20] and reciprocally correlated [15]. As expected, we found a strong reciprocal correlation among miR-483-3p and miR-483-5p ($r= 0.7380$, $p<0.0001$). Moreover, we found a significantly lower expression in the oncocytic variant of adrenocortical carcinoma, whose meaning remains to be defined, but supports a different and specific phenotype also at the molecular level for this special type [10,26]. Interestingly, high miR-483-3p levels were also a feature of low proliferating tumors. The above findings, apparently in contrast to the oncogenic functions of miR-483-3p mentioned above [18,25], are in agreement with recent data on the possible alternative function of this same miRNA as an onco-suppressor, acting as negative modulator of cell proliferation and pro-apoptotic molecule, at least in skin cells [27].

MiR-210 maps to the same 11p15.5 chromosome locus as miR-483-3p and miR-483-5p, and was also reported to be up-regulated in adrenocortical carcinoma [18,21]. As for miR-483-3p and miR-483-5p, miR-210 was significantly down-regulated in the oncocytic variant as compared to the classical and myxoid types. This observation is of particular interest considering that oncocytic cells (at least in the thyroid and kidney) display a genetic disassembly of the respiratory complex I, which in turn

contributes to the inability of stabilizing HIF1alpha [28]. Interestingly, miRNA-210 high expression was also positively associated with parameters of hypoxia, like necrosis and GLUT-1, and aggressive biological behavior such as mitotic rate and Ki-67 proliferation index, that are usually low in oncocytic tumors.

MiR-195 is located at 17p13.1, where also the TP53 gene maps. A loss of heterozygosity of this chromosome region has been reported in 84% of adrenocortical carcinomas and 30% of adenomas [29,30]. Accordingly, miR-195 is down-regulated in adrenocortical carcinomas both at the tissue [15,17,19] and serum levels [20]. In our series, low miR-195 was a feature of functioning and β -catenin negative tumors, but no correlation was found with p53 protein expression.

As to concern miR-1974, which was reported to be down-modulated in adrenocortical carcinoma by Ozata et al. [18], we initially hypothesized an aberrant expression in oncocytic tumors due to its peculiar localization in the mitochondria [22]. This miRNA has been currently re-challenged as a mitochondrial DNA-coded tRNA (mirbase miRNA accession: MI0009984; www.mirbase.org), but it appeared to be associated with adrenocortical tumors with low aggressiveness. In fact, no correlation with the histological variant was observed, but high miR-1974 levels were associated with low mitotic and Ki-67 proliferation indexes and low ENSAT stage. However, the significance of miR-1974 as a biomarker in adrenocortical tumors is of limited value since no difference in expression levels was detected between adenomas and carcinomas in our series.

In our case series, at univariate analysis histological variant and miR-210 were found to have a strong impact on survival together with well established prognostic factors such as mitotic count, Ki-67 proliferation index and high expression levels of SF-1 [13,24,31,32]. Concerning the importance of histological variant in ACC clinical outcome, we have confirmed the results of a retrospective survival analysis provided by Wong et al. [26], in which was shown a better prognosis for malignant adrenocortical neoplasm showing predominant oncocytic features in comparison with those of

classical type. The prognostic value of miR-210 has already been demonstrated in breast [33], pancreatic [34], head and neck carcinomas [35], pediatric osteosarcoma [36], and glioblastoma [37]. However, after testing all the above parameters in multivariate analysis, mitotic count remained the single independent significant parameter in our series, although a trend to significance was maintained for non-oncotic histotype and miR-210. No other miRNA significantly influenced overall survival in the case series analyzed.

CONCLUSIONS

Adrenocortical carcinoma variants have morphological, immunophenotypical and molecular peculiarities, including a differential miRNA expression profiles. In addition, high miR-210 expression should be included among molecular features of potential prognostic impact.

REFERENCES

1. Berruti A, Baudin E, Gelderblom H, et al. Adrenal cancer: ESMO Clinical Practice Guidelines for diagnosis, treatment and follow-up. *Ann Oncol* 2012; 23: 131-138.
2. Papotti M, Libe R, Duregon E, Volante M, Bertherat J, Tissier F. The weiss score and beyond- Histopathology for adrenocortical carcinoma. *Horm Cancer* 2011; 2: 333-340.
3. Weiss LM. Comparative histologic study of 43 metastasizing and nonmetastasizing adrenocortical tumors. *Am J Surg Pathol* 1984; 8: 163-169.
4. Weiss LM, Medeiros LJ, Vickery AL, Jr. Pathologic features of prognostic significance in adrenocortical carcinoma. *Am J Surg Pathol* 1989; 13: 202-206.
5. Tissier F, Aubert S, Leteurtre E, et al. Adrenocortical tumors: improving the practice of the Weiss system through virtual microscopy: a National Program of the French Network INCa-COMETE. *Am J Surg Pathol* 2012; 36: 1194-1201.
6. Duregon E, Fassina A, Volante M, et al. The Reticulin Algorithm for Adrenocortical Tumor Diagnosis: A Multicentric Validation Study on 245 Unpublished Cases. *Am J Surg Pathol* 2013; 37: 1433-40.
7. McNicol AM. A diagnostic approach to adrenal cortical lesions. *Endocr Pathol* 2008; 19: 241-251.
8. Papotti M, Volante M, Duregon E, Delsedime L, Terzolo M, Berruti A, Rosai J. Adrenocortical tumors with myxoid features: a distinct morphologic and phenotypical variant exhibiting malignant behavior. *Am J Surg Pathol* 2010; 34: 973-983.
9. Bisceglia M, Ludovico O, Di Mattia A, et al. Adrenocortical oncocytic tumors: report of 10 cases and review of the literature. *Int J Surg Pathol* 2004; 12: 231-243.
10. Duregon E, Volante M, Cappia S, et al. Oncocytic adrenocortical tumors: diagnostic algorithm and mitochondrial DNA profile in 27 cases. *Am J Surg Pathol* 2011; 35: 1882-1893.

11. Weissferdt A, Phan A, Suster S, Moran CA. Myxoid adrenocortical carcinoma: a clinicopathologic and immunohistochemical study of 7 cases, including 1 case with lipomatous metaplasia. *Am J Clin Pathol* 2013; 139: 780-786.
12. Zhang J, Sun J, Liang Z, Gao J, Zeng X, Liu T. Myxoid adrenocortical neoplasms: a study of the clinicopathologic features and EGFR gene status of ten Chinese cases. *Am J Clin Pathol* 2011; 136: 783-792.
13. Duregon E, Volante M, Giorcelli J, Terzolo M, Lalli E, Papotti M. Diagnostic and prognostic role of steroidogenic factor 1 in adrenocortical carcinoma: a validation study focusing on clinical and pathologic correlates. *Hum Pathol* 2013; 44: 822-828.
14. Rana TM. Illuminating the silence: understanding the structure and function of small RNAs. *Nat Rev Mol Cell Biol* 2007; 8: 23-36.
15. Soon PS, Tacon LJ, Gill AJ, et al. miR-195 and miR-483-5p Identified as Predictors of Poor Prognosis in Adrenocortical Cancer. *Clin Cancer Res* 2009; 15: 7684-7692.
16. Doghman M, El Wakil A, Cardinaud B, et al. Regulation of insulin-like growth factor-mammalian target of rapamycin signaling by microRNA in childhood adrenocortical tumors. *Cancer Res* 2010; 70: 4666-4675.
17. Patterson EE, Holloway AK, Weng J, Fojo T, Kebebew E. MicroRNA profiling of adrenocortical tumors reveals miR-483 as a marker of malignancy. *Cancer* 2011; 117: 1630-1639.
18. Ozata DM, Caramuta S, Velazquez-Fernandez D, et al. The role of microRNA deregulation in the pathogenesis of adrenocortical carcinoma. *Endocr Relat Cancer* 2011; 18: 643-655.
19. Chabre O, Libe R, Assie G, et al. Serum miR-483-5p and miR-195 are predictive of recurrence risk in adrenocortical cancer patients. *Endocr Relat Cancer* 2013; 20: 579-594.
20. Patel D, Boufraquech M, Jain M, et al. MiR-34a and miR-483-5p are candidate serum biomarkers for adrenocortical tumors. *Surgery* 2013;154:1224-1228.

21. Tombol Z, Szabo PM, Molnar V, et al. Integrative molecular bioinformatics study of human adrenocortical tumors: microRNA, tissue-specific target prediction, and pathway analysis. *Endocr Relat Cancer* 2009; 16: 895-906.
22. Bandiera S, Ruberg S, Girard M, et al. Nuclear outsourcing of RNA interference components to human mitochondria. *PLoS One* 2011; 6: e20746.
23. Volante M, Bollito E, Sperone P, et al. Clinicopathological study of a series of 92 adrenocortical carcinomas: from a proposal of simplified diagnostic algorithm to prognostic stratification. *Histopathology* 2009; 55: 535-543.
24. Duregon E, Molinaro L, Volante M, et al. Comparative diagnostic and prognostic performances of the hematoxylin-eosin and phospho-histone H3 mitotic count and Ki-67 index in adrenocortical carcinoma. *Modern Pathol* 2014 E-pub Jan 17 doi:10.1038/modpathol.2013.230
25. Veronese A, Lupini L, Consiglio J, et al. Oncogenic role of miR-483-3p at the IGF2/483 locus. *Cancer Res* 2010; 70: 3140-3149.
26. Wong DD, Spagnolo DV, Bisceglia M, Havlat M, McCallum D, Platten MA. Oncocytic adrenocortical neoplasms-a clinicopathologic study of 13 new cases emphasizing the importance of their recognition. *Hum Pathol* 2011; 42: 489-499.
27. Bertero T, Bourget-Ponzio I, Puissant A, et al. Tumor suppressor function of miR-483-3p on squamous cell carcinomas due to its pro-apoptotic properties. *Cell Cycle* 2013; 12: 2183-2193.
28. Porcelli AM, Ghelli A, Ceccarelli C, et al. The genetic and metabolic signature of oncocytic transformation implicates HIF1alpha destabilization. *Hum Mol Genet* 2010; 19: 1019-1032.
29. Gicquel C, Bertagna X, Gaston V, et al. Molecular markers and long-term recurrences in a large cohort of patients with sporadic adrenocortical tumors. *Cancer Res* 2001; 61: 6762-6767.
30. Soon PS, Libe R, Benn DE, et al. Loss of heterozygosity of 17p13, with possible involvement of ACADVL and ALOX15B, in the pathogenesis of adrenocortical tumors. *Ann Surg* 2008; 247: 157-164.

31. Vargas MP, Vargas HI, Kleiner DE, Merino MJ. Adrenocortical neoplasms: role of prognostic markers MIB-1, P53, and RB. *Am J Surg Pathol* 1997; 21: 556-562.
32. Sbiera S, Schull S, Assie G, et al. High diagnostic and prognostic value of steroidogenic factor-1 expression in adrenal tumors. *J Clin Endocrinol Metab* 2010; 95: 161-171.
33. Hong L, Yang J, Han Y, Lu Q, Cao J, Syed L. High expression of miR-210 predicts poor survival in patients with breast cancer: a meta-analysis. *Gene* 2012;507:135-138.
34. Greither T, Grochola LF, Udelnow A, Lautenschlager C, Wurl P, Taubert H. Elevated expression of microRNAs 155, 203, 210 and 222 in pancreatic tumors is associated with poorer survival. *Int J Cancer* 2010; 126: 73-80.
35. Gee HE, Camps C, Buffa FM, Patiar S, Winter SC, Betts G, Homer J, Corbridge R, Cox G, West CM, Ragoussis J, Harris AL. hsa-mir-210 is a marker of tumor hypoxia and a prognostic factor in head and neck cancer. *Cancer* 2010; 116: 2148-2158.
36. Cai H, Lin L, Cai H, Tang M, Wang Z. Prognostic evaluation of microRNA-210 expression in pediatric osteosarcoma. *Med Oncol* 2013; 30: 499.
37. Qiu S, Lin S, Hu D, Feng Y, Tan Y, Peng Y. Interactions of miR-323/miR-326/miR-329 and miR-130a/miR-155/miR-210 as prognostic indicators for clinical outcome of glioblastoma patients. *J Transl Med* 2013; 11: 10.

LEGENDS FOR FIGURES

Figure 1. Box plots demonstrating the differential expression of four out of five miRNAs investigated in adrenocortical adenomas as compared to carcinomas. All p values <0.0001.

Figure 2. Box plots demonstrating the differential expression of miRNAs investigated in adrenocortical carcinoma variants. Lower panels illustrate representative images of architectural patterns in classic, myxoid and oncocytic adrenocortical carcinoma cases (Hematoxylin and eosin staining, original magnification for all pictures 200x)

Figure 3. Overall survival curves according to miR-210 expression levels, segregated according to the median value

Table 1. Clinical pathological features of 51 adrenocortical carcinomas analyzed for microRNA expression.

Parameter	
F/M ratio	1.38
Age, mean (years) [range]	47 [20-79]
Functional status	Not functioning: 21
<i>(Not known: 7)</i>	Functioning: 23
	(cortisol: 15, cortisol+androgen:4, androgen: 2, aldosterone: 2)
Mean size (cm) [range]	11.5 [2-30]
Mean weight (g) [range]	561 [8-3200]
ACC variant	Classical: 34
	Myxoid: 7
	Oncocytic (pure/mixed): 10 (7/3)
Weiss Score distribution	3-4: 17
	5-6: 15
	7-8-9: 29
ENSAT stage <i>(Not known: 12)</i>	1-2: 27
	3-4: 12
Disease status <i>(lost to FU: 2)</i>	NED/DOC: 19
	AWD: 10
	DOD: 20
Median overall survival (months)	60 [4-420]

(classical + myxoid ACC: 59, oncocytic ACC: 79)

Adjuvant mitotane

17

Abbreviations: ACC, adrenocortical carcinoma; M, male; F, female; FU, follow up; NED, not evidence of disease; DOC, died of other cause; AWD, alive with disease; DOD, died of disease.

Table 2. Reciprocal correlations among miRNAs investigated.

marker	miRNA 483-3p	miRNA 483-5p	miRNA 210	miRNA 195
miRNA 483-5p	<i>r= 0.7380</i> <i>p= <0.0001</i>	--	--	
miRNA 210	r= 0.1855 p= 0.1924	r= 0.0467 p=0.7444	--	--
miRNA 195	r= -0.1937 p=0.1733	r= - 0.2489 p= 0.0782	r= 0.1072 p=0.4538	--
miRNA 1974	<i>r= -0.2939</i> <i>p= 0.0449</i>	r= 0.1671 p= 0.2413	<i>r= 0.4071</i> <i>p= 0.0030</i>	r= -0.0181 p= 0.8997

Table 3. Correlation between miRNA expression and clinical pathological parameters in adrenocortical carcinomas.

Parameter		miR-483-3p		miR-483-5p		miR-210		miR-195		miR-1974	
		mean	p	mean	p	mean	p	mean	p	mean	p
Age	≤45	410.9	0.0614	330.5	0.0819	20.03	0.4628	9.020	0.2207	11.25	0.4241
	>45	281.6		179.1		8.924		12.32		14.48	
Sex	F	299.7	0.1532	252.4	0.9701	5.322	0.0003	7.790	0.4594	12.76	0.5838
	M	366.2		293.9		65.33		12.22		12.06	
Size (cm)	≤11	302.3	0.6616	291.9	0.6558	10.32	0.3048	8.165	0.7122	15.49	0.6069
	>11	348.6		161.1		32.69		10.38		11.06	
Weight (g)	≤260	306.2	0.4432	274.2	0.4935	15.93	0.7819	8.055	0.3107	13.27	0.6283
	>260	512.2		446.2		27		11.40		9.27	
Functional status	func.	181.5	0.1868	185.1	0.1190	21.59	0.4011	7.95	0.0454	7.52	0.1297
	not func.	382.3		327.8		8.516		12.43		17.20	
ENSAT stage	1-2	353.3	0.0521	256.5	0.4244	15.39	0.7945	10.38	0.7044	16.35	0.0082
	3-4	153		295.8		22.85		12.32		5.13	
Weiss score	3-4-5	382.4	0.5720	217.4	0.4880	7.557	0.0545	10.38	0.4628	15.49	0.0677
	6-7-8-9	181.5		295.8		32.69		10.27		10.06	
Histologic type	classical	432.9	0.0325	389.5	0.0175	206.9	0.0366	19.71	0.1503	23.28	0.2853
	myxoid	326.7		319.3		99.27		70.86		7.026	
	oncocytic	54.5		52.12		27.19		7.081		88.53	
Necrosis	present	353.3	0.8470	221.4	0.9480	38.31	0.0035	7.84	0.5184	12.06	0.7874
	absent	292		288		4.92		10.83		12.76	
Mitotic x50HPF*	<11	410.6	0.0191	280.2	0.3305	12.07	0.4963	10.38	0.3412	22.36	0.0017
	≥11	176.7		252.4		34.23		9.93		6.230	
Ki-67 index*	<20	382.4	0.1942	302.3	0.3853	5.217	0.0013	8.325	0.8823	27.81	0.0312
	≥20	180.6		237.4		55.63		10.83		10.06	
SF-1	low	336.2	0.4733	173.7	0.7714	10.08	0.0979	10.48	0.6289	12.06	0.1423
	high	179.2		270.2		43.82		8.845		9.69	

p-53	negative	325.1	0.0548	256.5	0.3439	20.03	0.2266	10.10	0.7595	17.20	0.0013
	positive	15.09		11.20		5.217		12.32		5.13	
β-catenin	negative	336.2	0.2768	256.5	0.6305	15.46	0.5473	18.28	0.0110	12.06	0.4848
	positive	180.6		182.3		20.33		5.98		7.67	
GLUT-1	negative	337.8	0.8860	217.4	0.7034	10.08	0.0043	10.38	0.7579	9.270	0.4571
	positive	292.0		288.0		65.27		10.83		16.19	

1
2
3

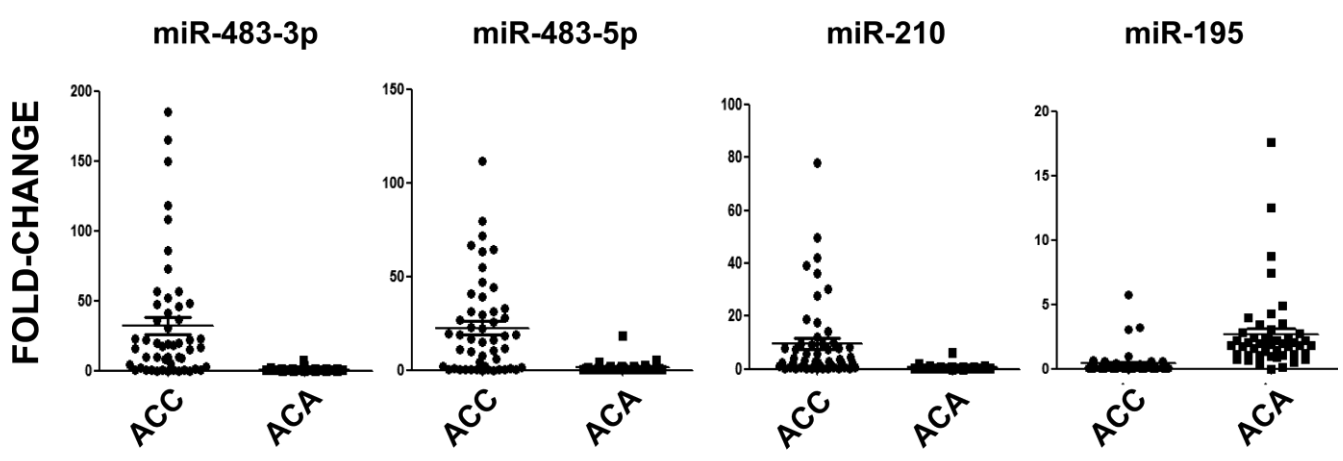
Table 4. Univariate overall survival analysis

Parameter	Hazard Ratio (logrank)	95% CI	<i>p</i>
Female sex	1.182	0.4807-2.902	0.7185
Age ≤45	0.9130	0.3749-2.212	0.8390
Presence of hormone secretion	0.3844	0.1690-0.9919	0.0511
ENSAT stage 3-4	0.5632	0.1954-1.398	0.1991
Size >11 cm	0.6701	0.2635-1.704	0.7070
Weight >260 g	1.187	0.4552-3.087	0.7253
Weiss Score ≥6	0.8818	0.3654-2.116	0.7762
Mitotic count x 50HPF ≥11*	0.2398	0.0682-0.4553	0.0006
Ki-67 ≥20*	0.2827	0.0978-0.5869	0.0066
Myxoid and classical histotype*	0.1445	0.1195-0.8670	0.0266
High expression SF-1*	0.2056	0.0623-0.6773	0.0017
Positive p53	0.2665	0.0675-1.075	0.0632
Positive β-catenin	0.4105	0.1618-1.042	0.1318
Positive GLUT-1	0.4152	0.1631-1.057	0.0652
High miR-483-3p	1.091	0.4518-2.634	0.8466
High miR-483-5p	1.4	0.5700-3.437	0.4631
High miR-210*	0.4213	0.1603-0.9690	0.0465
Low miR-195	1.33	0.5522-3.217	0.5228
Low miR-1974	2.062	0.8477-4.905	0.1131

4 *: parameters included in **multivariate analysis**: mitotic index: $p=0.017$; Ki-67: $p= 0.167$; histotype: $p=$
5 0.355 ; SF-1: $p= 0.236$; miR-210: $p= 0.219$.

6

7 Figure 1.

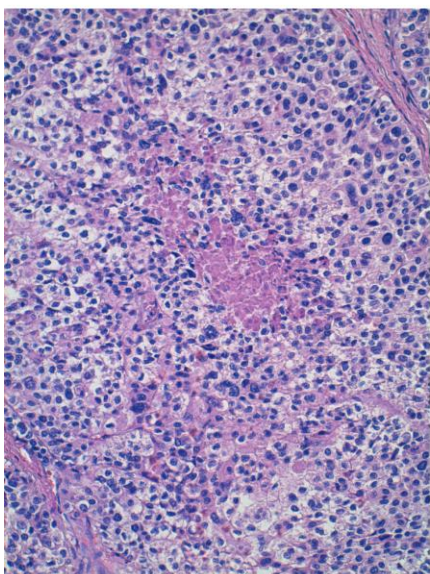
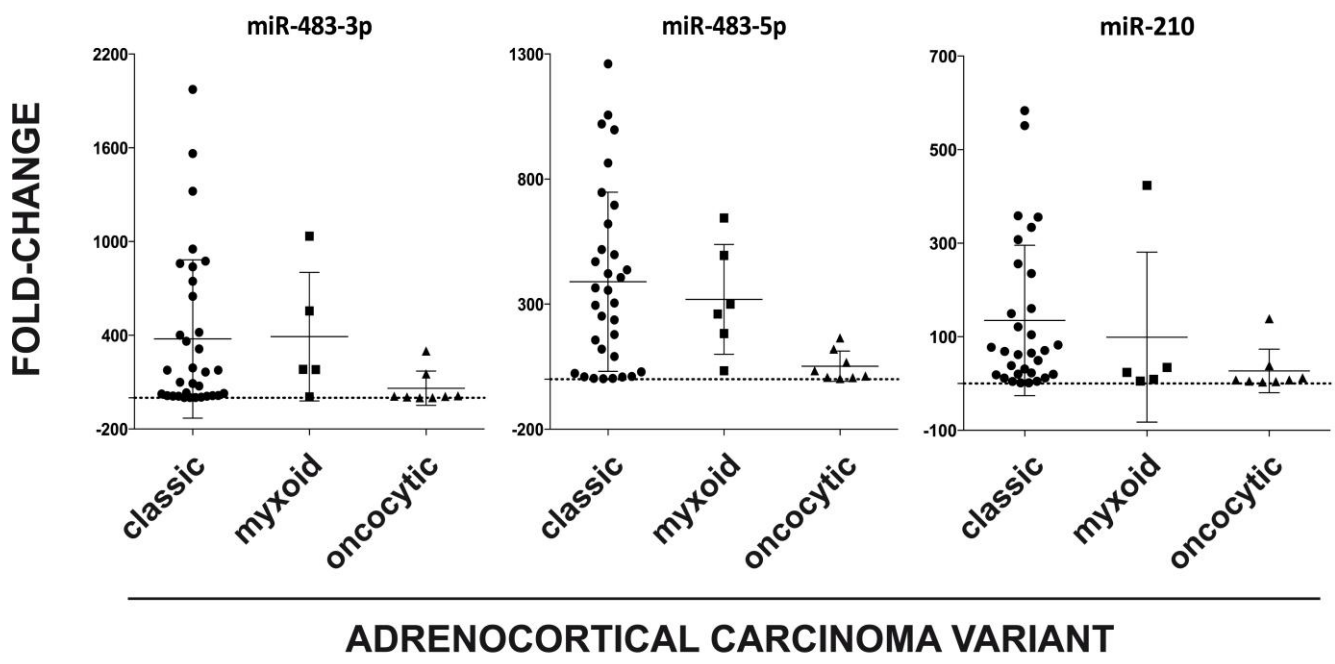


8

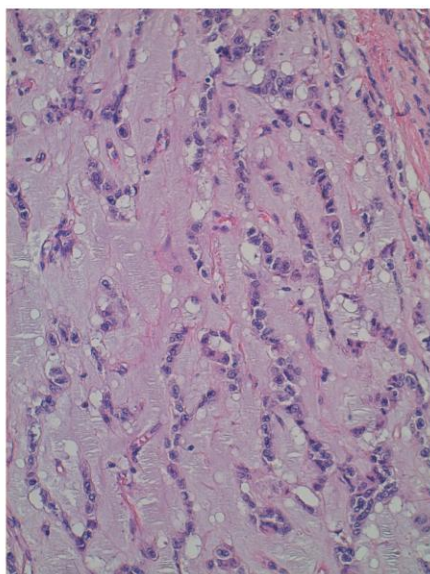
9

10

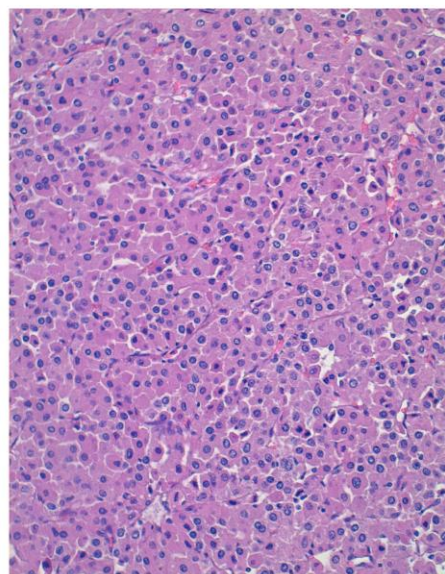
11 Figure 2.



classic



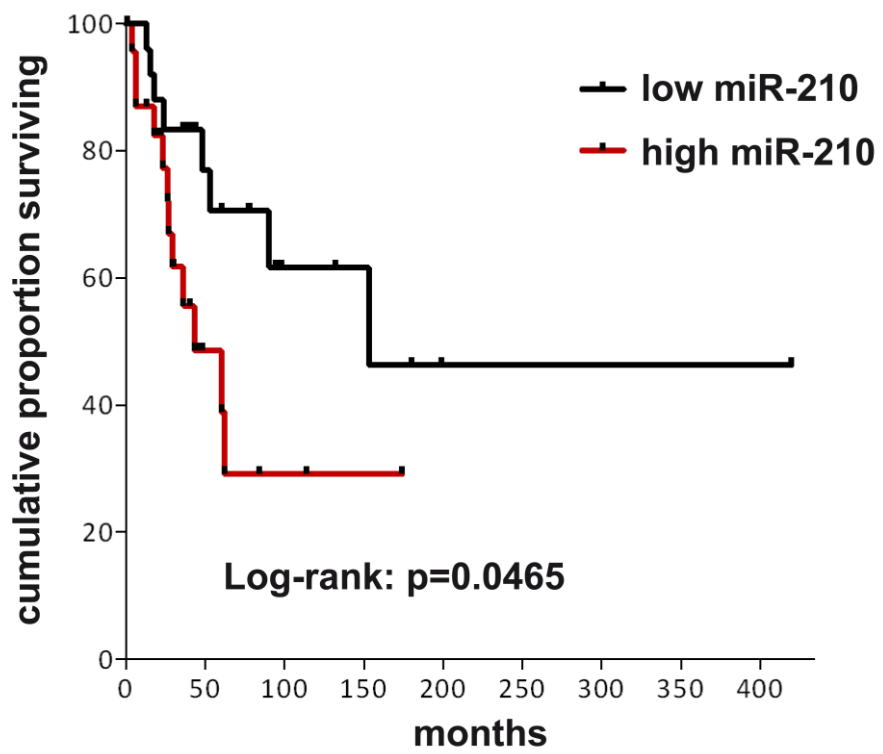
myxoid



oncocytic

12
13
14

15 Figure 3.



16