

AperTO - Archivio Istituzionale Open Access dell'Università di Torino

Superficial vein thrombosis in frail elderly adults

This is the author's manuscript

Original Citation:

Availability:

This version is available <http://hdl.handle.net/2318/1558404> since 2018-10-16T12:10:24Z

Published version:

DOI:10.1111/jgs.13779

Terms of use:

Open Access

Anyone can freely access the full text of works made available as "Open Access". Works made available under a Creative Commons license can be used according to the terms and conditions of said license. Use of all other works requires consent of the right holder (author or publisher) if not exempted from copyright protection by the applicable law.

(Article begins on next page)

This is the author's final version of the contribution published as:

Maggiani, Guido; Fornelli, Giorgia; Bo, Mario. Superficial vein thrombosis in frail elderly adults. *JOURNAL OF THE AMERICAN GERIATRICS SOCIETY*. 63 (11) pp: 2434-2435.
DOI: 10.1111/jgs.13779

The publisher's version is available at:

<http://doi.wiley.com/10.1111/jgs.13779>

When citing, please refer to the published version.

Link to this full text:

<http://hdl.handle.net/2318/1558404>

Letter to the Editor

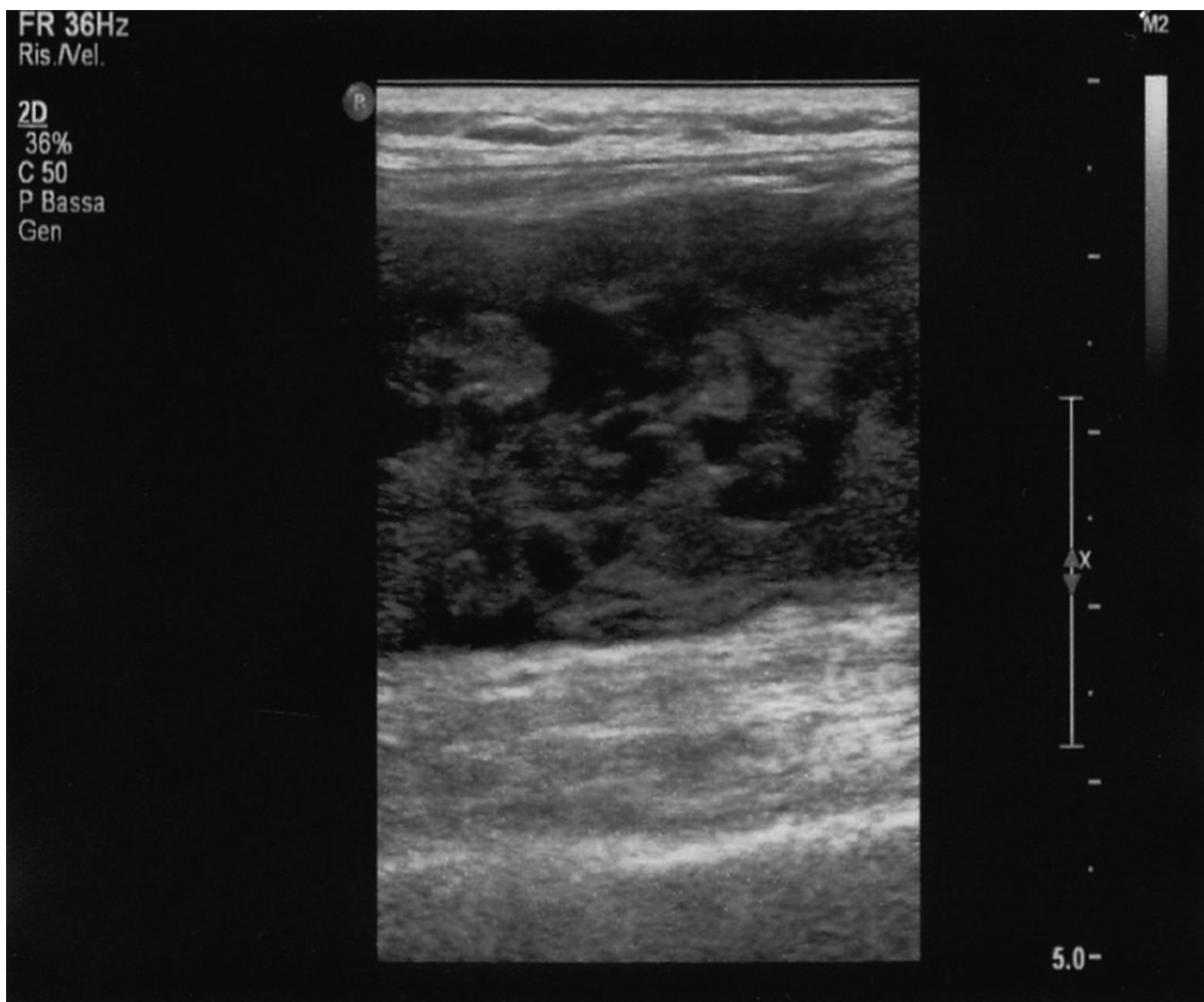
Superficial Vein Thrombosis in Frail Elderly Adults

To the Editor: A nursing home resident in his 80s presented to the emergency department with pain and swelling in his left leg. Past medical history included hypertension, epilepsy secondary to a previous subdural hematoma, severe vascular dementia with functional dependence, and behavioral disturbances.

Medical records reported administration of low-molecular-weight heparin (LMWH) at therapeutic doses for suspicion of upper limb superficial vein thrombosis (SVT) in the presence of mild swelling in left upper limb in the last 10 days. In the absence of vascular access, hypodermoclysis was started because of dehydration.

At admission, the man was bedridden and in poor general condition, highly dehydrated, alert, not oriented, and uncooperative. He had a painful swelling in his left groin with erythematous skin. His blood pressure was 110/70 mmHg, heart rate 90 (sinusal rhythm), temperature 37°C, oxygen saturation 97% (fraction of inspired oxygen 0.21). Laboratory tests showed severe leukocytosis (white blood cell count $34.30 \times 10^9/L$) with high inflammation indices (C-reactive protein 106.2 mg/L), thrombocytosis (platelets $877 \times 10^9/L$), and mild anemia (hemoglobin 10.2 g/dL, hematocrit 31.6%); hepatorenal function was normal.

Figure 1.



Ultrasound imaging showing left thigh hematoma.

Left lower limb ultrasound imaging showed no signs of vein thrombosis but a wide thigh abscessualized hematoma (Figure 1); a percutaneous drain was positioned. Despite intensive antibiotic treatment with ampicillin with sulbactam and vancomycin according to local infection control guidelines, he developed septic shock and general worsening of his condition and soon died.

Lower limb deep vein thrombosis (DVT) is a serious event, with high risk of pulmonary embolism.[1] Although a recent study[2] in critically ill individuals failed to demonstrate greater mortality despite high risk of pulmonary embolism in individuals with non-lower limb DVT, the recommended treatment is anticoagulation with fondaparinux or LMWH.

Data regarding unfavorable outcomes associated with SVT are much less conclusive, and management of SVT is not as standardized as for DVT. International scientific societies[1] recommend anticoagulation for ultrasound-defined lower limb SVT, favoring the use of prophylactic doses of fondaparinux (2.5 mg/d) over a prophylactic dose of LMWH in individuals with a lower limb SVT at least 5 cm in diameter. To our knowledge, no recommendations have been made about upper extremities SVT.

The publication of the Comparison of Arixtra in Lower Limb Superficial Vein Thrombosis with Placebo trial[3] validated anticoagulation with fondaparinux for individuals with acute, symptomatic lower limb SVT. The prescription of LMWH for SVT is also common,[4] but use of extended prophylactic doses and exact dosage are debated.

To the best of the knowledge of the authors of the current letter, no data ever demonstrated efficacy of anticoagulation for SVT in frail multimorbid elderly adults, and data on upper limbs thrombosis are even less complete. In the man described herein, it is likely that LMWH therapy resulted in subcutaneous bleeding, which formed an abscess.

Frail multimorbid elderly adults are susceptible to drug adverse effects and complications,[5] and expected benefit and potential harm should always be considered when determining treatment. In young, fit individuals with SVT, anticoagulation can accelerate pain relief and mobility, improving quality of life. In frail bedridden individuals, concerns about mobility are negligible, and pain can be successfully treated using better-tolerated drugs. In such an individual, treatment of suspected upper limb SVT with full-dose LMWH is unlikely to be beneficial and could substantially increase the risk of bleeding events. Knowledge of guidelines is an essential step in daily clinical practice, but physicians should always keep in mind that most of these guidelines are based on studies that enrolled younger, healthier participants than those found in real-world clinical practice. Moreover, a careful analysis of the balance between benefit and harm should always be made for frail, vulnerable individuals, who are highly susceptible to serious adverse events.

References

1 Guyatt GH, Akl EA, Crowther M et al. Executive summary: Antithrombotic Therapy and Prevention of Thrombosis, 9th ed: American College of Chest Physician evidence-based clinical practice guidelines. *Chest* 2012;141(2 Suppl):7S–47S.

2 Lamontagne F, McIntyre L, Dodek P et al. Nonleg venous thrombosis in critically ill adults: A nested prospective cohort study. *JAMA Intern Med* 2014;174:689–696.

3 Decousus H, Prandoni P, Mismetti P et al. Fondaparinux for the treatment of superficial-vein thrombosis in the legs. *N Engl J Med* 2010;363:1222–1232.

4 Scott G, Mahdi AJ, Alikhan R. Superficial vein thrombosis: A current approach to management. *Br J Haematol* 2015;168:639–645.

5 Hubbard RE, O'Mahony MS, Woodhouse KW. Medication prescribing in frail older people. *Eur J Clin Pharmacol* 2013;69:319–326.