

AperTO - Archivio Istituzionale Open Access dell'Università di Torino

**Endorectal ultrasound in the diagnosis of rectal cancer: accuracy and criticisms.**

**This is the author's manuscript**

*Original Citation:*

*Availability:*

This version is available <http://hdl.handle.net/2318/157351> since

*Published version:*

DOI:10.1016/j.ijsu.2014.08.370

*Terms of use:*

Open Access

Anyone can freely access the full text of works made available as "Open Access". Works made available under a Creative Commons license can be used according to the terms and conditions of said license. Use of all other works requires consent of the right holder (author or publisher) if not exempted from copyright protection by the applicable law.

(Article begins on next page)



## UNIVERSITÀ DEGLI STUDI DI TORINO

This Accepted Author Manuscript (AAM) is copyrighted and published by Elsevier. It is posted here by agreement between Elsevier and the University of Turin. Changes resulting from the publishing process - such as editing, corrections, structural formatting, and other quality control mechanisms - may not be reflected in this version of the text. The definitive version of the text was subsequently published in INTERNATIONAL JOURNAL OF SURGERY, 12 Suppl 2, 2014, 10.1016/j.ijisu.2014.08.370.

You may download, copy and otherwise use the AAM for non-commercial purposes provided that your license is limited by the following restrictions:

- (1) You may use this AAM for non-commercial purposes only under the terms of the CC-BY-NC-ND license.
- (2) The integrity of the work and identification of the author, copyright owner, and publisher must be preserved in any copy.
- (3) You must attribute this AAM in the following format: Creative Commons BY-NC-ND license (<http://creativecommons.org/licenses/by-nc-nd/4.0/deed.en>), 10.1016/j.ijisu.2014.08.370

The definitive version is available at:

<http://linkinghub.elsevier.com/retrieve/pii/S1743919114008541>

# **Endorectal ultrasound in the diagnosis of rectal cancer: Accuracy and criticisms**

Alessandra Surace, Alessia Ferrarese, Silvia Marola, Alessandro Borello, Jacopo Cumbo, Matteo Rivelli, Mario Solej, Valter Martino, Marco Ferronato, Herbert Dal Corso, Mario Nano

## **Abstract**

**Introduction:** Endorectal ultrasound (ERU) is used for locoregional staging of rectal cancer. Our work compares the data in the literature regarding diagnostic accuracy of the technique and results of routine use of the technique in two centers in Piedmont. **Material and methods:** 77 reports ultrasound with the final diagnosis of rectal cancer from the period 2008–2012 were examined. The echographies were performed by two experienced operators, using two ultrasound device with the same technical characteristics. **Results:** Sensitivity levels are high, with the exception of stage T3. Specificity is always high. The relationships of verisimilitude, both negative and positive, showing that the accuracy of the test is still high. The risk of overstaging is higher for pT1, while most important the risk of understaging concerns the stage T3 (23.5%); on the contrary the ERU is able to exclude infiltration of perirectal organs with a good accuracy (NPV of 99.3%). **Conclusion:** Although our study was a retrospective study, likewise some literature's reports, the interpretation of our analysis results shows a significant risk of downstaging T3 and N+ tumors. ERU represents in our experience a very important radiological staging methods to evaluate T1 and T2 rectal cancer.

## **Abbreviations**

ERU, Endorectal ultrasound; CRC, colorectal cancer; TEM, Transanal Endoscopic Microsurgery; TME, total mesorectal excision

## **1. Introduction**

Subperitoneal rectal cancer is about 35% of cases of colorectal cancer (CRC) in Europe. Incidence and mortality are of 15–25/100.000/year and 4–10/100.000/year; the highest rates are recorded in males [1].

Preoperative staging relies on clinical evaluation and on endoscopic and imaging techniques. Endorectal ultrasound (ERU) is a diagnostic technique used to study the wall of the rectum and subperitoneal adjacent structures; together with the MRI is the investigation of choice for preoperative local staging of rectal cancer.

ERU was introduced in 1956 by Wild and Reid for the study of prostate cancer [2]; ten years after the technique was also applied to the study of the rectum [3] and [4]. Since then, ERU became more and more widespread, now becoming the gold standard for rectal cancer locoregional staging because of its feasibility and minimal disturbance to the patient [5].

Review of literature shows conflicting results on ERU accuracy, since this is an operator-dependent technique; however, in most of the studies is stressed the high diagnostic accuracy of the technique [6]. The two major studies published on ERU are the meta-analysis of Puli (2009), which shows a high diagnostic accuracy, and a multicenter study (Marusch, 2011) [7]), which differs from the results of Puli.

The aim of our study is to compare our results with literature data, to highlight agreements and discrepancies, and highlight the causes of staging errors that have had greater significance in our clinical experience.

## **2. Materials and method**

We retrospectively reviewed the cases operated for rectal cancer in San Luigi Gonzaga Teaching Hospital in Orbassano and Santa Croce e Carle Hospital in Cuneo, from January 2008 to June 2012. Data were aggregated and the header of origin of individual patients has been cleared to avoid that this was a confounding factor for subsequent statistical analysis; reports were divided by stage.

## **3. Sample selection**

On 130 patients operated, 117 are staged with the ERU. Only exclusion criteria was the treatment with neoadjuvant therapy; applying this limit, the patients included in the study were 77.

The echographies were performed by two experienced operators as defined in the literature coming from the same school and with identity setting and reporting: they collaborated for five years and for one year compared to blind their reports. The ultrasound used in the two centers are identical and use a radial probe at a frequency of 10–13 MHz.

#### **4. Variables**

Characteristics of ERU accuracy were estimated by comparing ultrasound report with the pathological findings, considered the gold standard; for staging TNM classification was used [8].

N and T parameters were analyzed separately. For T staging, patients were stratified by stage. In each stage was conducted statistical analysis: true positives (in which ultrasound diagnosis agrees with the anatomo-pathologic examination), false negatives (classified by ultrasound at a stage lower than anatomopatology), false positives (classified by ultrasonography at a stage higher than anatomopatology) and true negatives (patients correctly staged by ultrasonography as belonging to a different stage than that taken considered) were identified.

#### **5. Statistical analysis**

Sensitivity, specificity, positive and negative predictive value, positive and negative likelihood ratio, with confidence intervals at 95% were estimated [9]. The significance of the results was estimated by chi-square test.

Probability to overestimate of ultrasound stage was estimated, using a logistic regression model where the dependent variable is the probability of overestimation and the explanatory variables are sensitivity, specificity, positive predictive value (PPV), negative predictive value (NPV), positive likelihood ratio (LR+) and negative likelihood ratio (LR-) [10].

Overestimation Odds ratio, relative confidence intervals of 95% and significance tests was calculated.

All analyzes were conducted with SAS 8.1 program.

#### **6. Results**

77 ERUs reports were divided as follows: 14 UT0, 6 UTIs, 16 UT1, UT2 17, 19 UT3, 5 UT4 (total uT=77); UN0 52, 16+uN (uN total=68). The number of patients studied for the parameter N is lower than in patients studied for parameter T because 9 patients staged as UT0 have not been evaluated by the parameter N.

Table 1 presents the characteristics of accuracy compared ERU pathological examination in the T staging of the tumor, stratified by stage.

Stage	SENS % [I.C.]	SPEC % [I.C.]	PPV% [I.C.]	NPV% [I.C.]	LR + [I.C.]	LR - [I.C.]	Overstaging risk	Understaging risk
pT0	0.958 [0.699– 0.996]	0.869 [0.766– 0.931]	0.575 [0.364– 0.762]	0.991 [0.921– 0.999]	7.328 [3.873– 13.867]	0.048 [0.03– 0.724]	0 [0.51– 52.18]	0 [0.51– 52.18]
PTis	0.9 [0.463– 0.989]	0.993 [0.937– 0.999]	0.9 [0.463– 0.989]	0.993 [0.937– 0.999]	129.6 [8.06– 2083.968]	0.101 [0.007– 1.397]	42.11 [23.06– 63.95]	0 [0.51– 52.18]
pT1	0.778 [0.453– 0.937]	0.882 [0.785– 0.939]	0.467 [0.248– 0.699]	0.968 [0.89– 0.991]	6.611 [3.158– 13.838]	0.252 [0.074– 0.858]	47.06 [26.02– 69.24]	11.76 [3.58– 34.71]
pT2	0.833 [0.552– 0.953]	0.908 [0.813– 0.957]	0.625 [0.386– 0.815]	0.967 [0.888– 0.991]	9.028 [4.403– 20.157]	0.184 [0.052– 0.652]	33.03 [16.29– 56.55]	11.11 [3.38– 33.14]
pT3	0.714 [0.454– 0.883]	0.952 [0.869– 0.984]	0.769 [0.497– 0.918]	0.938 [0.85– 0.975]	15 [4.736– 47.512]	0.3 [0.131– 0.688]	17.65 [16.29– 41.42]	23.53 [9.69– 47.64]
pT4	0.833 [0.31– 0.982]	0.993 [0.939– 0.999]	0.833 [0.31– 0.982]	0.993 [0.939– 0.999]	123.333 [7.437– 2045.279]	0.168 [0.013– 2.107]	0 [0.51– 52.18]	0 [0.51– 52.18]

**Table 1** Qualitative analysis dell'ERU for the parameter T, with the calculation of the risk of over-and underestimation. SENS = sensitivity; SPEC = specificity; I.C. = confidence interval; PPV = positive predictive value; NPV = negative predictive value; LR = likelihood ratio.

Results show levels of sensitivity in accord with literature, with the exception of pT3 in which the sensitivity does not reach 80%. The specificity is still high: the highest value is found for stage pT4 (99.3%), while the specificity for the stadium PT0 is only 88.2%. The highest risk of overstaging concerns the pT1. The positive predictive values are always moderately low, except for pTis, while negative values are high. The likelihood ratio both negative and positive show that the accuracy of the test is high. Due to the low sample size, confidence intervals at 95% are very large.

Specificity, PPV and LR+ for stage Tis are high (99.3%, 0.9 and 129.6 respectively).

LR-of pT0 stadium is 0.048: the risk that a tumor of the major stage is identified as UT0 is therefore very low. However, the risk of overstaging for pTo is 42%.

Specificity and LR+ for T1 stadium are respectively 88.2% and 6.611. The PPV is low (0.467), with high risk of overstaging (47%), but low risk of understaging for T2 (11%).

Sensitivity and specificity for pT2 stage are respectively 83% and 91%. In this case, the main risk is the overstadiation (33%). The risk of understadiation is 11%.

T3 stage has low sensitivity (71.4%), high specificity (95%) and high NPV (94%). The understaging risk is high (23.5%), conversely the risk of overstaging (17.65%).

For stage T4 there is a high ability of the test to define the true positives (specificity = 99%; PPV = 83.3%); Furthermore the ERU is able to exclude the infiltration of perirectal organs (NPV = 99.3%).

Evaluation of these variables has also been applied to the parameter N. Sensitivity and specificity for pN0 stage are 84%, and 99%. Sensitivity and specificity for pN+ stage are 95.5%, and 91.4%. The PPV for N0 and N1 is elevated (98% and 62% respectively). LR-for N+ is 0.05, furthermore LR+ is high for both N0 and N+ (82% and 11% respectively). The main risk is understaging the tumor (37.5%), furthermore overstaging risk is 14.2%.

## 7. Discussion

The main limitation of our study is the low sample size (77 patients). However, our work has an important strength: ultrasound scans were performed by only two operators, with overlapping manner of reporting. In this way only the minimum bias linked to the aggregation of reports drawn up by different operators, considering an operator-dependent technique such as ultrasound.

We compared the data of our statistical analysis with the main meta-analysis deal with ERU in the literature[6] and with the multi-center study that seems to contradict its results [7]; we have obtained intermediate values of sensitivity for all stages. Sensitivity for pT2 found in our analysis is greater. Regarding the values of specificity, our analysis shows higher values than the analysis of Puli and Marusch for stage pT3, lower values for pT1, middle for pT2 stage; for stage pT4 the three values are similar.

Our analysis shows that ERU is a technique sensitive enough, with high levels of specificity for the parameter T. Main clinical significance deal with relative risk pT1 and pT3 tumors, the limits for the indication of TEM (Transanal Endoscopic Microsurgery) [11] and [12] and neoadjuvant therapy, respectively.

Regarding stage T1, ERU shows a discrete sensitivity (78%) and good specificity (88%). Risk of overestimation for T1 is high (42.11%): its reflects the habit of overstaging a dubious tumor for avoiding the risk of under-treatment. Risk of understaging T2 lesion is 11%: risk of performing TEM for a patient in an advanced stage, is therefore low; anyway, ERU is currently the most accurate diagnostic technique for T1 stage, as confirmed by the literature [13].

Data analysis for pT3 tumors showed a significant risk of understaging (23.53%), in agreement with the literature [11] and [14]. For both T2 and T3 stage surgical treatment of choice is TME; the correct preoperative staging of T3 tumors refers the patient to neoadjuvant therapy, if comorbidities allow. For this reason, the risk of understaging of almost 24%, as indicated by our analysis, required a retrospective analysis of understaged cases to improve diagnostic accuracy of our technique: our attention is focused on cases of pT3 understaged (4 patients) and pN+ false negatives (6 patients). From this analysis, it appears that errors are correlated to:

- 33% = technique errors:

- Limited inflation of the probe cover has made the layers of the rectal wall hardly distinguishable from each other.

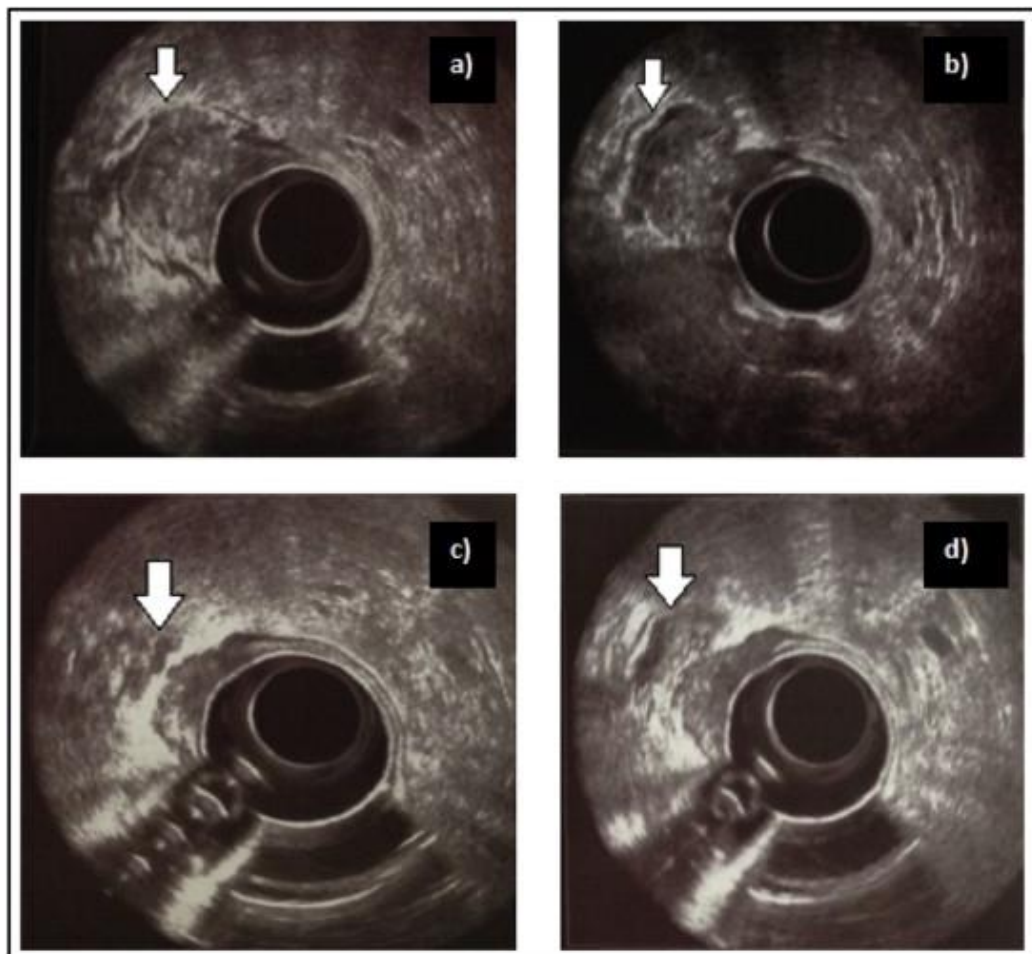
- the partial three-dimensional reconstruction of a more cranial peritumoral lymph node than the cancer did not permit a complete evaluation of the same.

- 17% = tumor site: the higher lesions can not be studied by ERU in their proximal portion, making incomplete evaluation of parietal infiltration.

- 17% = tumor stage: initial infiltration of subserosal has been interpreted as uT2.

- 33% = interpretation:

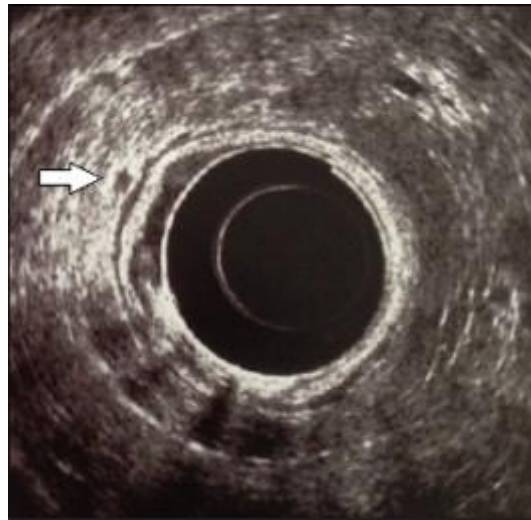
- The operator has not identified an ileal loop which, occupying the pouch of Douglas, made contact with hypoechoic image of tumor. It looks like an image of continuity between ileal wall and rectal wall infiltrated by the tumor, which creates false layers of the wall, causing understaging (Fig. 1).



**Figure 1** a) b) c) d): Cranio-caudal progression of the probe that highlights how the loop in Douglas comes into contact with the wall of the rectum, looking like in continuity.



○ Incorrect assessment of a lymph node as reactive. The characteristics of the lymph node were: oval shape, size 02-3 mm, hypochoic structure and irregular margins, so only 2 of the 5 criteria of malignancy were satisfied (Fig. 2).



**Figure 2** The lymph node visible at 7 o'clock (arrow) appears hypochoic, homogeneous with irregular margins (positive criteria for lymph node metastasis); however, is of 3 mm, oval and inhomogeneous (negative criteria for lymph node metastasis).

The accuracy of ERU identifying the infiltration of the organs adjacent to the rectum is, however, satisfactory, with sensitivity values of 83.3% and specificity of 99.3%: this allows efficient planning of surgery.

The criteria used to distinguish a metastatic lymph node from a reactive lymph node are not sensitive enough, especially for the initial stages of invasion: risk of understaging is high (37.5%).

In conclusion, the results of ERU in the staging of rectal cancer are highly variable depending on the operator that performs the investigation: it is important to periodically compare the interpretation of ultrasound with histological examination of the surgical specimen, to identify the most common errors and improve, so, their diagnostic accuracy.

### **Ethical approval**

None required.

### **Sources of funding**

All authors have no source of funding.

## **Author contribution**

**Alessandra Surace:** Participated substantially in conception, design, and execution of the study and in the analysis and interpretation of data; also participated substantially in the drafting and editing of the manuscript.

**Alessia Ferrarese:** Participated substantially in conception, design, and execution of the study and in the analysis and interpretation of data.

**Silvia Marola:** Participated substantially in conception, design, and execution of the study and in the analysis and interpretation of data.

**Alessandro Borello:** Participated substantially in conception, design, and execution of the study and in the analysis and interpretation of data.

**Jacopo Cumbo:** Participated substantially in conception, design, and execution of the study and in the analysis and interpretation of data.

**Matteo Rivelli:** Participated substantially in the analysis and interpretation of data.

**Mario Solej:** Participated substantially in conception, design, and execution of the study and in the analysis and interpretation of data.

**Marco Ferronato:** Participated substantially in conception, design, and execution of the study and in the analysis and interpretation of data.

**Valter Martino:** Participated substantially in conception, design, and execution of the study and in the analysis and interpretation of data.

**Herbert dal Corso:** Participated substantially in conception, design, and execution of the study and in the analysis and interpretation of data.

**Mario Nano:** Participated substantially in conception, design, and execution of the study and in the analysis and interpretation of data; also participated substantially in the drafting and editing of the manuscript.

## **Conflicts of interest**

All authors have no conflict of interests.

## References

- [1] B. Glimelius, L. Pählman, A. Cervantes, Rectal cancer: ESMO Clinical Practice Guidelines for diagnosis, treatment and follow-up, *Ann. Oncol. off. J. Eur. Soc. Med. Oncol*, 21 (Suppl. 5) (2010), pp. v82–v86
- [2] H. Watanabe, D. Ieari, Y. Ianahashi, Transrectal ultrasonotomography of the prostate, *J. Urol.*, 114 (1975), pp. 734–739
- [3] H.H. Alzin, E. Kohlberger, R. Schwaiger, S. Alloussi, Valeur de l'echographic endorectal dans la chirurgie du rectum, *Ann. Radiol.*, 26 (1983), pp. 334–336
- [4] J. Dragsted, J. Gammelgaard, Endoluminale ultrasonic scanning in the evaluation of rectal cancer, *Gastrointest. Radiol.*, 8 (1983), pp. 367–369
- [5] B. Amato, L. Sivero, G. Vigliotti, et al., Surgery for cancer in the elderly: state of the art, *Chirurgia (Turin)*, 26 (4) (2013), pp. 313–315
- [6] S.R. Puli, M.L. Bechtold, J.B.K. Reddy, A. Choudhary, M.R. Antillon, W.R. Brugge, How good is endoscopic ultrasound in differentiating various T stages of rectal cancer? Meta-analysis and systematic review, *Ann. Surg. Oncol.*, 16 (2) (2009), pp. 254–265
- [7] F. Marusch, H. Ptok, M. Sahm, U. Schmidt, K. Ridwelski, I. Gastinger, H. Lippert, Endorectal ultrasound in rectal carcinoma—do the literature results really correspond to the realities of routine clinical care?, *Endoscopy*, 43 (5) (2011), pp. 425–431
- [8] B. Stephen, M.D. Edge, C. Carolyn, M.D. Compton, The American Joint Committee on Cancer: the 7th edition of the AJCC cancer staging manual and the future of TNM, *Ann. Surg. Oncol.*, 17 (6) (2010), pp. 1471–1474
- [9] D. Sackett, R. Haynes, G. Guyatt, P. Tugwell, *Clinical Epidemiology: a Basic Science for Clinical Medicine*, (second ed.) (1985)
- [10] K.J. Rothman, S. Greenland, T.L. Lash, *Modern Epidemiology*, Lippincott & Wilkins (2008)
- [11] D. Loffredo, A. Marvaso, S. Ceraso, et al., Minimal invasive surgery in treatment of liver metastases from colorectal carcinomas: case studies and survival rates, *BMC Surg.*, 13 (Suppl. 2) (2013), p. S45
- [12] S. Perrotta, G. Quarto, V. Desiato, et al., TEM in the treatment of recurrent rectal cancer in elderly, *BMC Surg.*, 13 (Suppl. 2) (2013), p. S56
- [13] J. Zhu, P.T. Huang, K.F. Ding, X. Zhang, C.M. Liu, X.M. Liu, B.Z. Li, S.R. Cai, S. Zheng, Clinical value of radial endorectal ultrasound in the assessment of preoperative staging of rectal carcinoma, *Zhonghua Zhong Liu Za Zhi*, 35 (2) (2013), pp. 148–153
- [14] C. Rispoli, N. Rocco, L. Iannone, B. Amato, Developing guidelines in geriatric surgery: role of the grade system, *BMC Geriatr.*, 9 (Suppl. 1) (2009), p. A99

