Diagnostic Pathway with Multiparametric Magnetic Resonance Imaging Versus Standard Pathway: Results from a Randomized Prospective Study in Biopsy-naïve Patients with Suspected Prostate Cancer

*Manuscript

Diagnostic pathway with multiparametric magnetic resonance imaging vs. standard pathway: Results from a randomized prospective study in biopsy-naïve patients with suspected prostate cancer

Francesco Porpiglia[a], Matteo Manfredi[a], Fabrizio Mele[a], Marco Cossu[a], Enrico Bollito[b], Andrea Veltri[c], Stefano Cirillo[d], Daniele Regge[e], Riccardo Faletti[f], Roberto Passera[g], Cristian Fiori[a], Stefano De Luca[a]

a. Division of Urology, University of Turin, San Luigi Gonzaga Hospital, Orbassano (Turin)
b. Division of Pathology, University of Turin, San Luigi Gonzaga Hospital, Orbassano (Turin)
c. Division of Radiology, University of Turin, San Luigi Gonzaga Hospital, Orbassano (Turin)
d. Division of Radiology, Mauriziano Hospital, Turin
e. Department of Radiology, Candiolo Cancer Institute - FPO, IRCCS, Candiolo (Turin)
f. Department of Surgical Sciences - Radiology Unit, University of Turin, Città della Salute e della Scienza, Turin
g. Division of Nuclear Medicine, University of Turin, San Giovanni Battista Hospital, Turin

Corresponding author:

Prof. F. Porpiglia, MD
Division of Urology,
Department of Oncology, University of Turin
San Luigi Gonzaga Hospital,
Regione Gonzole 10, 10043 Orbassano (Turin) - Italy
Phone number +390119026558
Fax number +390119038654
porpiglia@libero.it

Keywords: Diagnosis, Magnetic resonance imaging, Prostate cancer, Systematic random biopsy, Targeted biopsy

Abstract word count: 300

Paper word count: 2518

ABSTRACT

Background: An approach based on multiparametric magnetic resonance imaging (mp-MRI) might increase the detection rate (DR) of clinically significant (cs) prostate cancer (PCa).

Objective: To compare an mp-MRI-based pathway with the standard approach for the detection of PCa and csPCa.

Design, setting, participants: Between 11/2014 and 04/2016, 212 biopsy-naïve patients with suspected PCa (PSA≤15 ng/ml, negative DRE) were included in the present RCT. Patients were randomized into a prebiopsy mp-MRI group (arm A, 107pts) or a standard biopsy (SB) group (arm B, 105pts).

Intervention: In arm A, patients with mp-MRI evidence of lesions suspected for PCa were submitted to mp-MRI/TRUS fusion software-guided targeted biopsy (TB) (81pts). The remaining patients in arm A (26pts) with negative mp-MRI and patients in arm B underwent 12-core SB.

Outcomes measurements and statistical analysis: Primary endpoint: to compare the DR of PCa and csPCa between the two arms of the study; Secondary endpoint: to compare the DR between TB and SB.

Results and limitations: The overall DRs for PCa (50.5% vs. 29.5%, A vs. B, p=0.002) and csPCa (43.9% vs. 18.1%, A vs. B, p<0.001) were higher in arm A. Concerning the biopsy approach, the overall DRs of PCa (60.5% vs. 19.2% vs. 29.5%, p<0.001) and csPCa (56.8% vs. 3.8% vs. 18.1%, p<0.001) were significantly different (TB in arm A, SB in arm A, and SB in arm B, respectively). The reproducibility of the study could have been affected by the single-centre nature.

Conclusion: A diagnostic pathway based on mp-MRI had a higher DR than the standard pathway in both PCa and csPCa.

Patient summary: In this randomized trial, we compared a pathway for the diagnosis of prostate cancer, based on multiparametric magnetic resonance imaging, with the standard pathway, based on random biopsy. We found that the mp-MRI-based pathway had better performance than the standard.

INTRODUCTION

Prostate biopsy with multiple samples using a standardized template (standard biopsy - SB) under transrectal ultrasound (TRUS) guidance is the standard diagnostic approach today in suspicion of prostate cancer (PCa)[1], as recommended by the European Urological Association guidelines[2].

However, many biopsies are unnecessary, or they cannot detect clinically significant (cs) PCa[3]. With the introduction of the multiparametric prostate MRI (mp-MRI), many authors have reported improved PCa detection and localization[4,5]. Moreover, mp-MRI can be useful to select patients more effectively who are eligible for prostate biopsy because of its high negative predictive value, mainly in men with previous negative mapping[6,7]. Finally, mp-MRI allows the clinician to guide prostate biopsy sampling. Some studies have reported comparable findings of PCa detection rates between mp-MRI targeted biopsies and SB[8,9]; however, the latter approach has been described as increasing csPCa detection in biopsy-naïve patients, thus decreasing the detection of non-significant PCa[10].

The aim of this randomized, prospective, two-arm study was to evaluate the diagnostic accuracy of the mp-MRI pathway itself and in comparison to the standard pathway in biopsy-naïve men.

MATERIALS AND METHODS

Study population and design

The study enrolment lasted from 11/2014 to 03/2016. It was conducted in accordance with Good Clinical Practice Guidelines and the ethical principles of the Declaration of Helsinki, as amended in Hong Kong. In addition, the study was approved by the local ethics committee (San Luigi Gonzaga Hospital, Orbassano, Italy). The CONSORT flow diagram is shown in Figure 1.

The eligibility criteria were: (1) age ≤75 years old; (2) prostate-specific antigen (PSA) **level up to** 15 ng/ml; (3) negative digital rectal examination (DRE); and (4) signed informed consent.

The exclusion criteria were: (1) previous prostate biopsy/surgery; (2) previous prostate mp-MRI; and (3) contraindication to mp-MRI.

We emphasize that none of the enrolled patients had previously been included in published cohorts.

Two-hundred-twenty-three eligible patients scheduled for prostate biopsy in our department were randomly assigned to one of the following arms: arm A, mp-MRI prior to prostate biopsy; or arm B, standard prostate biopsy. In arm A, all patients with mp-MRI evidence of lesions suspicious for PCa were submitted to mp-MRI/TRUS fusion software-based targeted biopsy (TB) (sub-arm A MRI+). In cases of negative mp-MRI, arm A patients underwent SB (sub-arm A MRI-).

The present RCT compared the outcomes between the two arms.

The primary endpoint was the comparison of the overall detection rates of PCa and csPCa between arm A and B. The secondary endpoints were: (1) comparison of the overall detection rates of PCa and csPCa between sub-arm A MRI+ and MRI-; (2) comparison in terms of pathological results; (3) comparison of complication rates; and (4) follow-up of patients in sub-arm A MRI- and sub-arm A MRI+ with negative biopsy.

In this first report, the primary endpoint and the first two secondary endpoints were reached and considered. The study is ongoing to determine to the remaining secondary endpoints.

Randomization

Immediately after signing a specific informed consent form, the patients were randomized into either arm A or B.

<u>Sequence generation:</u> Patients were randomly assigned to arm A or B following a 1:1 simple randomization procedure, according to a computer-generated randomization list. The randomization list was prepared by an external randomization manager. We emphasize that he was the only person to have possession of the list, and he had no clinical involvement in the trial.

<u>Allocation concealment and implementation:</u> Different staff members (blinded to the randomization sequence) evaluated the inclusion criteria and obtained the patients' informed consents. Immediately after this phase, staff members contacted the external randomization manager, who assigned the patients to one of the two groups.

Finally, independent staff members (F.M. and M.M.) planned the two different diagnostic pathways, i.e., mp-MRI and different prostate biopsies in arm A vs. the standard prostate biopsies in arm B.

Multiparametric MRI

All of the patients in arm A underwent mp-MRI according to the ESUR guidelines. The PIRADS classification was used to describe the found lesions[11]. mp-MRI was performed out at three centres with a 1.5-T scanner using a 32-channel phase array coil or 4-channel phase array coil combined with an endorectal coil. A description of mp-MRI acquisition is provided in the supplementary material[5,11,12]. Three experienced radiologists analysed the mp-MRI findings. PIRADS$\geq$3 lesions were considered suspicious for PCa.

Prostate biopsy

All of the patients underwent prostate biopsy in an ambulatory setting according to the guidelines[2]. TRUS was performed by using a Hawk Ultrasound scanner 2102 EXL with a biplanar transducer (B-K Medical, Herlev, Denmark). Biopsies were performed using a disposable 18-G biopsy gun with a specimen size of 18-22 mm (Bard Medical, Covington, USA) by two dedicated senior urologists. Both of the urologists had a level of experience in SB of >20 years and in TB of >1 year (>100 procedures per urologist).

TB was performed by using the BioJet™ fusion system (D&K Technologies, Barum, Germany), as previously described[13]. The gland and the regions of interest (ROIs) were contoured, and the prostate contour was fused in real time with the TRUS image. Biopsies were performed via either a transrectal (55 patients, 67.9%) or transperineal (26 patients, 32.1%) approach, based on the location of the ROI: transrectal for ROIs in the peripheral zone; and transperineal for ROIs in the transition, central or anterior zone. The patient was placed in the lithotomy position. TB was performed on a maximum of two ROIs, and three to six cores were obtained for biopsy from each lesion. Lesions from the transition or central zone scored as PIRADS 3 were not biopsied.

Twelve-core SB was performed according to the Rodrìguez-Covarrubias protocol via a transrectal approach[14].

Pathological analysis

Histopathological examination was conducted by a dedicated uropathologist who was blinded to the inclusion of each patient in the RCT and to the mp-MRI results, according to a standardized protocol[15].

The biopsy Gleason score (GS), number of total and positive cores, total and maximum cancer core length (CCL), and maximum cancer core involvement (CCI) rate were recorded according to the standards of reporting for MRI-targeted biopsy studies (START) criteria[16].

csPCa was defined according to previously published studies: the START criteria for TB (biopsy GS$\geq$7 or maximum CCL$\geq$5mm[16,17]); and the updated Epstein criteria for SB[18].

Sample size determination and statistical analyses

A sample size of 186 patients (93 per arm) was required to detect a 20% absolute increase (from 30% to 50% with arm B vs. arm A, respectively) in the detection rate of PCa, with an alpha error of 0.05 and a beta error of 0.20 (two-sample test for proportions, superiority design). Considering 10% of patients lost to

follow-up, the total sample size was calculated to number 205 patients. No interim analyses were planned, while all procedures were performed on an intention-to-treat basis.

The associations between categorical variables (PIRADS and GS) and the arm were analysed by Fisher's exact test; the Mann-Whitney and Kruskal-Wallis tests were used for continuous variables. All of the results for continuous variables are expressed as the median (inter-quartile rate [IQR]). All of the reported p-values were obtained by the two-sided exact method at the conventional 5% significance level. Data were analysed as of April 2016 by R software, version 3.2.3 (R Foundation for Statistical Computing, Vienna-A, http/www.R-project.org), **according to previously published guidelines for the reporting of statistics[19].**

RESULTS

Totals of 111 and 112 patients were enrolled in arms A and B, respectively. Protocol violations were registered in 4 of 111 patients (3.6%) and 7 of 112 patients (6.3%) in arms A and B, respectively. After exclusion of these patients, 107 and 105 patients per arm were evaluable in arms A and B, respectively. The patients' demographics are reported in Table 1.

Comparison between arm A and arm B

As reported in Table 2, there was a significant difference between arms A and B in the overall detection rates of PCa (50.5% vs. 29.5%, p=0.002) and csPCa (43.9% vs. 18.1%, p<0.001), respectively.

Comparison between targeted and standard biopsy

In arm A, mp-MRI was positive in 81 (75.7%) patients who underwent TB, whilst it was negative in 26 (24.3%) patients who underwent SB. A significant difference was recorded when stratifying the patients on the basis of the biopsy approach in terms of the overall detection rates of PCa (60.5% vs. 19.2% vs. 29.5%, p<0.001) and csPCa (56.8% vs. 3.8% vs. 18.1%, p<0.001) for TB, SB in arm A, and SB in arm B, respectively (Table 2).

Targeted biopsy detection rate according to PIRADS score

In arm A, mp-MRI found one suspected lesion in 54 patients (66.7%) and two suspected lesions in 27 patients (33.3%). The rates of detection of PCa and csPCa by TB according to PIRADS scores are reported in Table 3.

Number of samples and pathologic characteristics

In arm A, 800 cores were obtained: 488 by the TB approach and 312 by the SB approach. In arm B, 1260 cores were sampled.

The median total numbers of biopsies per patient were 6 (5-12) and 12 (12-12) in arms A and B, respectively (p<0.001). The median numbers of positive cores per patient were 4 (2-6) and 3 (2-4) in arms A and B, respectively (p=0.105).

In the subgroup analysis, the median numbers of positive cores per patient were 4 (3-6), 1 (1-1) and 3 (2-4) by TB in both arms, SB in arm A and SB in arm B, respectively (p=0.001).

Pathological characteristics are reported in Table 4.

DISCUSSION

The advent of mp-MRI has changed the approach to prostate biopsy, allowing clinicians to direct biopsies to suspected lesions rather than operating randomly. In 2009, it was estimated that the cost of unnecessary prostate biopsies was greater than that of mp-MRI[20].

Biopsy-naïve men seem to be the ideal population for mp-MRI: this imaging method has, in fact, great potential to reduce over-diagnosis in men with high risk of indolent disease detection with random biopsy.

The simplest MRI-targeted biopsy strategy is the cognitive approach, which directs visually targeted samples to the suspicious ROI highlighted on mp-MRI. Three RCTs have compared a first biopsy pathway based on mp-MRI to 12-core SB alone, producing conflicting results[8,21,22]. The first two studies concluded that the PCa detection rate was higher in the mp-MRI group[21,22]. However, in the most recent RCT, the authors reported that the mp-MRI group had comparable detection rates of PCa and csPCa, compared to the control group[8].

MRI/TRUS fusion software-based targeted biopsy represents the most accurate and practical targeted biopsy strategy[23]. One RCT that used fusion biopsy in a diagnostic pathway based on mp-MRI was published[9]. In the mp-MRI group, two-core fusion biopsy of mp-MRI-suspected lesions and 12-core SB were performed. No significant differences were detected in either the PCa (59.0% vs. 54.0%) or csPCa detection rate (44.0% vs. 49.0%) between the mp-MRI and control groups (12-core SB), respectively. In contrast, some non-randomized studies comparing MRI-targeted biopsy and SB in biopsy-naïve men have concluded that the approach using mp-MRI and subsequent fusion biopsy limited over-detection of clinically insignificant PCa while providing greater detection of csPCa than SB alone[24**-28**].

To the best of our knowledge, this study was the first RCT comparing PCa detection rates between a diagnostic pathway, based on mp-MRI and subsequent MRI/TRUS fusion software-guided targeted biopsy alone, with the standard pathway, based on SB, in a cohort of biopsy-naïve men.

The first report of our RCT seemed to confirm the potential role of mp-MRI as a first-line technique in the diagnostic pathway of biopsy-naïve patients with suspected PCa, according to our inclusion criteria.

PCa was diagnosed in 50.5% of patients in the mp-MRI group, with 87.0% of cases being clinically significant. These data significantly outperformed the results of the standard pathway. In this group, the overall detection of PCa was 29.5%, similar to the results of previously published series of SB in biopsy-naïve patients[29]. We emphasize that the present study was restricted to patients with PSA **levels up to** 15 ng/ml and negative DRE only.

The differences in PCa detection rates between the arms of the study were greater than those found in earlier RCTs[8,9], perhaps due to the different protocols used (cognitive biopsy[8], two-core fusion biopsy[9]) and the patient selection criteria.

When stratifying the population in terms of the approach to biopsy, we found that TB in sub-arm A MRI+ had the best results in terms of the overall detection rate of PCa (60.5%) and the rate of csPCa detected (93.9%). We emphasize that the analysis in the different subgroups might have been affected by the underpowered sample size.

The usefulness of the PIRADS classification was emphasized by our findings: a significantly higher detection rate in terms of overall detection of PCa and csPCa in PIRADS 4 and 5 lesions, compared to PIRADS 3

lesions, was found. The results in Table 4 suggested that PIRADS 3 lesions might not receive biopsy, although all of them were diagnosed as csPCa after biopsy.

The pathological results confirmed the superiority of the mp-MRI pathway in terms of the quality of biopsy samples. Fewer biopsy samples per patient were necessary in arm A, compared to arm B. The median total and maximum CCL and maximum CCI were significantly higher in arm A, compared to arm B.

Our results seemed to contribute to confirming the role of mp-MRI in avoiding unnecessary biopsies. In sub-arm A MRI-, only one csPCa (3.8%) was diagnosed. This finding could suggest that prostate biopsy in a biopsy-naïve man with suspicion of PCa but negative mp-MRI could be avoided in the near future. Nevertheless, strict follow-up of these patients is recommended until more robust data are available.

The main strength of the current study was its prospective RCT design, in accordance with Good Clinical Practice Guidelines. The results were reported according to the START recommendations. Moreover, the accuracy in terms of histopathological evaluation was guaranteed by the involvement of a single expert uropathologist. mp-MRI was performed according to standardized protocols and was reported using the PIRADS system. This RCT was based on the creation of a new diagnostic pathway, which was possible owing to collaboration among the experts of three radiology centres and a urology division qualified in innovative PCa diagnosis and treatment.

A limitation of this approach could be the lack of reproducibility in other centres (i.e., lack of skilled staff or technologies). Moreover, we well know that the reproducibility of a single-centre RCT is not comparable to multicentre-study results. It is possible that the adoption of PIRADS, version 2.0[30], or the use of a 3-T MRI would have resulted in even better diagnostic performance of mp-MRI, although a recent systematic review did not support this hypothesis[6]. Further limitations included the lack of correlation with specimen pathology and the heterogeneity of the mp-MRI equipment. Finally, as previously stated, some comparisons between the subgroups might have been less reliable due to the small sample size.

CONCLUSIONS

In the setting of biopsy-naïve men with suspected PCa, PSA **levels up to** 15 ng/ml and negative DRE, pre-biopsy mp-MRI allowed us to detect greater numbers of PCa and csPCa, compared to 12-core SB. Moreover, biopsy samples resulted in more information in terms of CCL and CCI. Our results supported that mp-MRI could be considered prior to a first prostate biopsy. Larger sample sizes would definitely confirm our data.

ACKNOWLEDGMENTS

None.

REFERENCES

1. Prostate cancer: diagnosis and treatment. National Institute for Health and Care Excellence Web site. https://www.nice.org.uk/guidance/cg175. Published January 2014. Accessed July 2015.
2. Heidenreich A, Bastian PJ, Bellmunt J, et al. EAU guidelines on prostate cancer. Part 1: screening, diagnosis, and local treatment with curative intent-update 2013. Eur Urol. 2014;65(1):124-37
3. Ukimura O, Coleman JA, de la Taille A, et al. Contemporary role of systematic prostate biopsies: indications, techniques, and implications for patient care. Eur Urol. 2013;63(2):214-30.
4. Le JD, Tan N, Shkolyar E, et al. Multifocality and prostate cancer detection by multiparametric magnetic resonance imaging: correlation with whole-mount histopathology. Eur Urol. 2015;67(3):569-76
5. Sciarra A, Barentsz J, Bjartell A, et al: Advances in magnetic resonance imaging: how they are changing the management of prostate cancer. Eur Urol. 2011;59:962.
6. Fütterer JJ, Briganti A, De Visschere P, et al. Can Clinically Significant Prostate Cancer Be Detected with Multiparametric Magnetic Resonance Imaging? A Systematic Review of the Literature. Eur Urol. 2015;68(6):1045-53
7. Kiechle JE, Pahwa S, Gulani V, Kanaan G, Sedelaar JP, Ponsky LE. Magnetic resonance imaging for prostate cancer: what the urologist needs to know. Minerva Urol Nefrol. 2015;67:201-10
8. Tonttila PP, Lantto J, Pääkkö E, et al. Prebiopsy Multiparametric Magnetic Resonance Imaging for Prostate Cancer Diagnosis in Biopsy-naïve Men with Suspected Prostate Cancer Based on Elevated Prostate-specific Antigen Values: Results from a Randomized Prospective Blinded Controlled Trial. Eur Urol. 2016;69(3):419-25
9. Baco E, Rud E, Eri LM, et al. A Randomized Controlled Trial to assess and compare the outcomes of two-core prostate biopsy guided by fused magnetic resonance and transrectal ultrasound images and traditional 12-core systematic biopsy. Eur Urol. 2016;69(1):149-56
10. Schoots IG, Roobol MJ, Nieboer D, Bangma CH, Steyerberg EW, Hunink MG. Magnetic resonance imaging-targeted biopsy may enhance the diagnostic accuracy of significant prostate cancer detection compared to standard transrectal ultrasound-guided biopsy: a systematic review and meta-analysis. Eur Urol. 2015;68(3):438-50.
11. Barentsz JO, Richenberg J, Clements R, et al. European Society of Urogenital R (2012) ESUR prostate MR guidelines 2012. Eur Radiol 22(4):746–757
12. Futterer J: MR imaging in local staging of prostate cancer. Eur J Radiol 2007; 63: 328.
13. Tewes S, Hueper K, Hartung D, et al. Targeted MRI/TRUS fusion-guided biopsy in men with previous prostate biopsies using a novel registration software and multiparametric MRI PI-RADS scores: first results. World J Urol. 2015;33(11):1707-14
14. Rodrìguez-Covarrubias F, Gonzalez-Ramirez A, Aguilar-Davidov B et al. Extended sampling at first biopsy improves cancer detection rate: results of a prospective, randomized trial comparing 12 versus 18-core prostate biopsy. J Urol 2011;185:2132
15. De Matteis A, Bollito E, Galosi AB, et al. Prostate biopsy: characteristics of the histological sample. Arch Ital Urol Androl 2005;77:28
16. Moore CM, Kasivisvanathan V, Eggener S, et al (START Consortium). Standards of reporting for MRI-targeted biopsy studies (START) of the prostate: recommendations from an International Working Group. Eur Urol. 2013; 64(4):544-52
17. Ahmed HU, Hu Y, Carter T, et al. Characterizing clinically significant prostate cancer using template prostate mapping biopsy. J Urol. 2011;186(2):458-64

18. Kryvenko ON, Carter HB, Trock BJ, Epstein JI. Biopsy criteria for determining appropriateness for active surveillance in the modern era. Urology 2014;83(4):869-74
19. **Vickers AJ, Sjoberg DD. Guidelines for Reporting of Statistics in European Urology. Eur Urol 2015;67:181-7**
20. Ahmed HU, Kirkham A, Arya M, et al. Is it time to consider a role for MRI before prostate biopsy? Nat Rev Clin Oncol 2009; 6:197–206
21. Park BK, Park JW, Park SY, et al. Prospective evaluation of 3-T MRI performed before initial transrectal ultrasound-guided prostate biopsy in patients with high prostate-specific antigen and no previous biopsy. AJR Am J Roentgenol 2011;197(5):W876–W881
22. Panebianco V, Barchetti F, Sciarra A, et al. Multiparametric magnetic resonance imaging vs. standard care in men being evaluated for prostate cancer: a randomized study. Urol Oncol. 2015;33(1):17.e1-7
23. Manfredi M, Costa Moretti T, Emberton M, Villers A, Valerio M. MRI/US fusion software-based targeted biopsy: the new standard of care? Minerva Urol Nefrol 2015;67:233-246
24. Mozer P, Roupret M, Le Cossec C, et al. First round of targeted biopsies with magnetic resonance imaging/ultrasound fusion images compared to conventional ultrasound-guided transrectal biopsies for the diagnosis of localised prostate cancer. BJU Int. 2015;115(1):50-7
25. Delongchamps NB, Peyromaure M, Schull A, et al. Prebiopsy magnetic resonance imaging and prostate cancer detection: comparison of random and targeted biopsies. J Urol 2013;189(2):493–499
26. Mendhiratta N, Rosenkrantz AB, Meng X, et al. Magnetic Resonance Imaging-Ultrasound Fusion Targeted Prostate Biopsy in a Consecutive Cohort of Men with No Previous Biopsy: Reduction of Over Detection through Improved Risk Stratification. J Urol. 2015;194(6):1601-6
27. Pokorny MR, de Rooij M, Duncan E, et al. Prospective study of diagnostic accuracy comparing prostate cancer detection by transrectal ultrasound-guided biopsy versus magnetic resonance (MR) imaging with subsequent MR-guided biopsy in men without previous prostate biopsies. Eur Urol 2014;66:22-9
28. **Siddiqui MM, Rais-Bahrami S, Turkbey B, et al. Comparison of MR/ultrasound fusion-guided biopsy with ultrasound-guided biopsy for the diagnosis of prostate cancer. JAMA. 2015;313(4):390-7**
29. Valerio M, Donaldson I, Emberton M, et al. Detection of Clinically Significant Prostate Cancer Using Magnetic Resonance Imaging–Ultrasound Fusion Targeted Biopsy: A Systematic Review. Eur Urol. 2015;68(1):8-19
30. Weinreb JC, Barentsz JO, Choyke PL, et al. PI-RADS Prostate Imaging - Reporting and Data System: 2015, Version 2. Eur Urol. 2016;69(1):16-40

328 **FIGURE LEGEND**

329 Fig.1 – Consolidated Standards of Reporting Trials (CONSORT) flow diagram of the study. mp-MRI =
330 multiparametric magnetic resonance imaging; PSA = prostate-specific antigen.

Table

Table 1 – Demographic characteristics of the study population. mp-MRI = multiparametric magnetic resonance imaging; PSA = prostate-specific antigen. Data for continuous variables are reported as the median (IQR).

	Arm A (mp-MRI group)		Arm B (control group)
Group size, n	107		105
Age, yr	64 (58-70)		66 (60-70)
PSA, ng/ml	5.9 (4.8-7.5)		6.7 (5.5-8.5)
Prostate volume, ml	46.2 (34.5-71.6)		45.7 (34.6-65.0)
	TB	SB (Arm A)	SB (Arm B)
Group size, n	81	26	105
Age, yr	64 (59-70)	63 (58-69)	66 (60-70)
PSA, ng/ml	5.9 (4.8-7.3)	6.1 (5.3-7.5)	6.7 (5.5-8.5)
Prostate volume, ml	44.4 (34.2-67.3)	55.6 (39.5-72.6)	45.7 (34.6-65.0)

Table 2 – Comparison of cancer detection rates in terms of randomization arm and biopsy approach. mp-MRI = multiparametric magnetic resonance imaging; PCa = prostate cancer; csPCa = clinically significant prostate cancer; TB = targeted biopsy; SB = standard biopsy.

	Arm A (mp-MRI group)		Arm B (control group)	p-value
Group size, n	107		105	
Overall detection of PCa, n (%)	54 (50.5)		31 (29.5)	0.002
Overall detection of csPCa, n (%)	47 (43.9)		19 (18.1)	<0.001
Ratio of overall detection of csPCa/PCa, %	87.0		61.3	0.013
	TB	SB (Arm A)	SB (Arm B)	p-value
Group size, n	81	26	105	
Overall detection of PCa, n (%)	49 (60.5)	5 (19.2)	31 (29.5)	<0.001
Overall detection of csPCa, n (%)	46 (56.8)	1 (3.8)	19 (18.1)	<0.001
Ratio of overall detection of csPCa/PCa, %	93.9	20.0	61.3	<0.001

Table 3 – Comparison of cancer detection rates in sub-arm A MRI+ in terms of PIRADS score. PIRADS = Prostate Imaging Reporting and Data System; PCa = prostate cancer; csPCa = clinically significant prostate cancer.

	PIRADS score 3	PIRADS score 4	PIRADS score 5	p-value
Group size, n (%)	24	40	16	
Overall detection of PCa, n (%)	3 (12.5)	32 (80.0)	14 (87.5)	<0.001
Overall detection of csPCa, n (%)	3 (12.5)	30 (75)	13 (81.3)	<0.001
Ratio of overall detection of csPCa/PCa, %	100.0	93.8	92.9	1.000

Table 4 – Histopathological characteristics of the study population. mp-MRI = multiparametric magnetic resonance imaging; GS = Gleason score; SB = standard biopsy; TB = targeted biopsy; CCL = cancer core length; CCI = cancer core invasion. Data for continuous variables are presented as the median (IQR).

	Arm A (mp-MRI group)		Arm B (control group)	p-value
Group size, n	107		105	
PCa, n (%)	54 (50.5)		31 (29.5)	0.002
Biopsy GS, n (%) • 6 • 7 • 8 • >8	 10 (18.5) 38 (70.4) 5 (9.3) 1 (1.9)		 17 (54.8) 11 (35.5) 2 (6.5) 1 (3.2)	0.002
Total CCL, mm	16 (8-31)		5 (2-20)	0.005
Maximum CCL, mm	7 (5-9)		4 (2-8)	0.013
Maximum CCI, %	60 (33-77)		25 (14-67)	0.010
	TB	SB (Arm A)	SB (Arm B)	p-value
Group size, n	81	26	105	
PCa, n (%)	49 (60.5)	5 (19.2)	31 (29.5)	<0.001
Biopsy GS, n (%) • 6 • 7 • 8 • >8	 5 (10.2) 38 (77.6) 5 (10.2) 1 (2.0)	 5 (100) 0 (0) 0 (0) 0 (0)	 17 (54.8) 11 (35.5) 2 (6.5) 1 (3.2)	<0.001
Total CCL, mm	18 (10-32)	3 (2-3)	5 (2-20)	0.048
Maximum CCL, mm	8 (6-10)	2 (1-3)	4 (2-8)	0.064
Maximum CCI, %	67 (33-80)	10 (9-25)	25 (14-67)	0.062

Illustration

Click here to download high resolution image

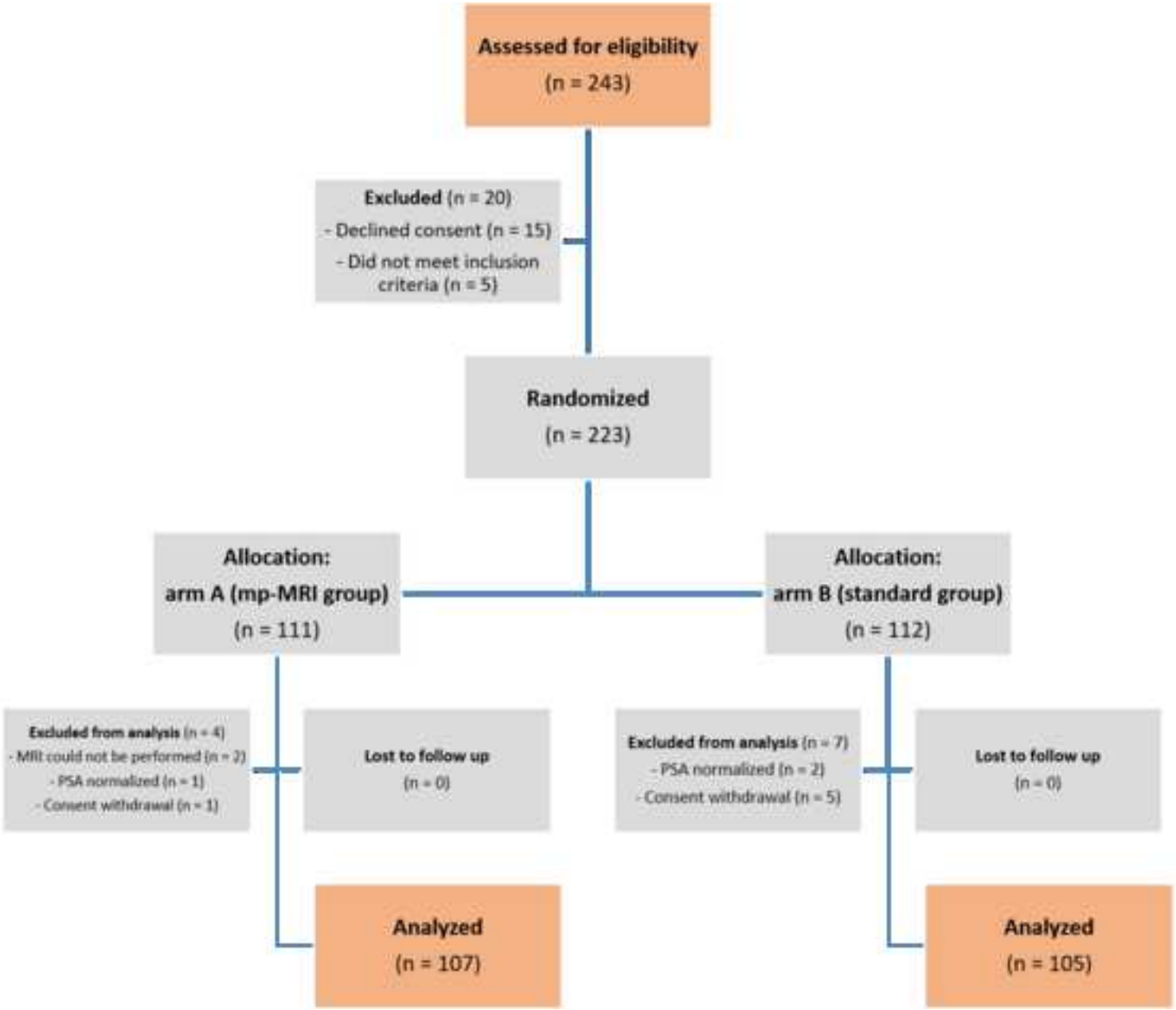

***Take Home Message**

This randomized trial included 212 biopsy-naïve patients with suspected prostate cancer (PCa), randomized to pre-biopsy multiparametric-MRI (mp-MRI), or standard biopsy. The detection rate of PCa and clinically significant PCa in mp-MRI group was higher if compared to standard group.