

AperTO - Archivio Istituzionale Open Access dell'Università di Torino

Consensus Paper: Cerebellum and Emotion

This is the author's manuscript

Original Citation:

Availability:

This version is available <http://hdl.handle.net/2318/1609925> since 2017-05-16T11:16:38Z

Published version:

DOI:10.1007/s12311-016-0815-8

Terms of use:

Open Access

Anyone can freely access the full text of works made available as "Open Access". Works made available under a Creative Commons license can be used according to the terms and conditions of said license. Use of all other works requires consent of the right holder (author or publisher) if not exempted from copyright protection by the applicable law.

(Article begins on next page)

This is the author's final version of the contribution published as:

Adamaszek, M; D'Agata, F.; Ferrucci, R.; Habas, C.; Keulen, S.; Kirkby, K.C.; Leggio, M.; Mariën, P.; Molinari, M.; Moulton, E.; Orsi, L.; van Overwalle, F.; Papadelis, C.; Priori, A.; Sacchetti, B.; Schutter, D.J.; Styliadis, C.; Verhoeven, J.. Consensus Paper: Cerebellum and Emotion. *CEREBELLUM*. None pp: 1-25.
DOI: 10.1007/s12311-016-0815-8

The publisher's version is available at:

<http://link.springer.com/content/pdf/10.1007/s12311-016-0815-8>

When citing, please refer to the published version.

Link to this full text:

<http://hdl.handle.net/2318/1609925>

Consensus Paper: Cerebellum and Emotion

Adamaszek M, D'Agata F, Ferrucci R, Habas C, Keulen S, Kirkby KC, Leggio M, Mariën P, Molinari M, Moulton E, Orsi L, Van Overwalle F, Papadelis C, Priori A, Sacchetti B, Schutter DJ, Styliadis C, Verhoeven J

Type of Draft: Consensus Article

Word count (full manuscript): 11387

Number of figures: 6

Number of tables: 2

Affiliations

Michael Adamaszek, Klinik Bavaria Kreischa, Department of Neurological and Neurocognitive Rehabilitation, An der Wolfsschlucht 1-2, 01731 Kreischa, Germany

Federico D'Agata, Department of Neuroscience, University of Turin, Italy

Roberta Ferrucci, Fondazione IRCCS Ca' Granda, Italy; Università degli Studi di Milano, Italy

Christophe Habas MD, PhD, Service de NeuroImagerie (NeuroImaging department) Centre Hospitalier national D'Ophtalmologie des 15/20, Paris, France.

Stefanie Keulen, Department of Clinical and Experimental Neurolinguistics, CLIEN, Vrije Universiteit Brussel, Brussels, Belgium; Center for Language and Cognition Groningen, Rijksuniversiteit Groningen, Groningen, The Netherlands

Kenneth C Kirkby, Psychiatry, School of Medicine, University of Tasmania, Australia

Maria Leggio, I.R.C.C.S. Santa Lucia Foundation, Rome, Italy; Department of Psychology, Sapienza University of Rome, Italy

Peter Mariën, Department of Clinical and Experimental Neurolinguistics, CLIEN, Vrije Universiteit Brussel, Brussels, Belgium; Department of Neurology and Memory Clinic, ZNA Middelheim Hospital, Antwerp, Belgium

Marco Molinari, I.R.C.C.S. Santa Lucia Foundation, Rome, Italy

Eric Moulton, P.A.I.N. Group, Center for Pain and the Brain, Boston Children's Hospital, Harvard Medical School, Boston, Massachusetts, USA

Laura Orsi, Neurology, Città della Salute e della Scienza, Turin, Italy

Frank Van Overwalle, Faculty of Psychology and Educational Sciences, Vrije Universiteit Brussel, Brussels, Belgium

Christos Papadelis, Fetal-Neonatal Neuroimaging and Developmental Center, Boston Children's Hospital, Boston, Massachusetts, USA; Division of Newborn Medicine, Department of Medicine, Boston Children's Hospital, Harvard Medical School, Boston, Massachusetts, USA

Alberto Priori, Fondazione IRCCS Ca' Granda, Italy; Università degli Studi di Milano, Italy; III Clinica Neurologica, Polo Ospedaliero San Paolo, Italy

Benedetto Sacchetti, Department of Neuroscience, Section of Physiology, University of Turin, Italy

Dennis J.L.G. Schutter, Radboud University Nijmegen, Donders Institute for Brain, Cognition and Behaviour, The Netherlands

Charis Styliadis, Medical School, Faculty of Health Sciences, Aristotle University of Thessaloniki, Thessaloniki, Greece

Jo Verhoeven, Department of Language and Communication Science, City University, London, UK; Computational Linguistics and Psycholinguistics Research Center (CLIPS), Universiteit Antwerpen, Antwerp, Belgium

Correspondence to:

Michael Adamaszek

Dept. Neurological and Neurocognitive Rehabilitation

Klinik Bavaria Kreischa

An der Wolfsschlucht 1-2

D-01731 Kreischa

Phone +49-35206-63814

Fax +49-35206-61262

Mail michael.adamaszek@freenet.de

CONFLICT OF INTEREST

The authors declare that they have no conflict of interest.

Abstract

Over the past three decades insight into the role of the cerebellum in emotional processing has substantially increased. Methodological refinements in cerebellar lesion studies and major technological advancements in the field of neuroscience have led to exponential growth of knowledge on the topic. It is timely to review the available data and to critically evaluate the current status of the role of the cerebellum in emotion and related domains. The main aim of this article is to present an overview of current facts and ongoing debates relating to clinical, neuroimaging and neurophysiological findings on the role of the cerebellum in key aspects of emotion. Experts in the field of cerebellar research discuss the range of cerebellar contributions to emotion in nine topics. Topics include the role of the cerebellum in perception and recognition, and forwarding and encoding of emotional information, in the experience and coordination of emotional states in relation to motor, cognitive and social behaviors. In addition, perspectives including cerebellar involvement in emotional learning, pain, emotional aspects of speech, and neuropsychiatric aspects of the cerebellum in mood disorders, are briefly discussed. Results of this consensus paper illustrate how theory and empirical research have converged to produce a composite picture of brain topography, physiology and function that establishes the role of the cerebellum in many aspects of emotional processing.

Keywords: Cerebellum – Emotion – Perception – Recognition – Processing – Learning – Neurotopography - Neurophysiology – Pain – Speech - Mood

Introduction

Research on the relationship between the cerebellum and emotion processing has a relatively short history of 60 years. Whereas early reports were often anecdotal or restricted for methodological reasons (e.g., technical, animal experimentation), there has been a substantial development in research since the early 1990s. Only a few years after the introduction of the dysmetria of thought theory, Schmahmann and Sherman [1] described in a seminal study of patients with focal cerebellar lesions a consistent

pattern of cognitive and affective deficits and coined the term “cerebellar cognitive affective syndrome” (CCAS) to describe this condition. CCAS has held as an anchor point, promoting successive waves of neuroscientific research investigating the role of the cerebellum in nonmotor functions, including cognition and affect. This research continues to be enabled and stimulated by technical advances, applying neuroimaging procedures such as Computed Tomography (CT) and Magnetic Resonance Imaging (MRI) to the investigation of abnormalities in human brain. New discoveries have led to innovative lines of research opening up novel and fascinating topics such as the emotional cerebellum. Broad agreement has been reached around the contribution of the cerebellum to diverse domains of emotional processing, starting with emotional perception and recognition, proceeding through evaluation of emotional contexts, and culminating in emotional bodily and facial expressions and social behavior. Consensus has emerged from clinical, experimental, neuroimaging and neurophysiological investigations of emotion that the cerebellum is crucially implicated in the cortico- limbic networks subserving emotion processing.

This paper gathers the opinions of a group of selected scientists with established expertise in distinct research areas addressing the nonmotor role of the cerebellum in cognitive, affective, social and emotional processing. The opinions are presented as condensed abstracts following a systematic order. The series starts with the perception, recognition and forwarding of information about emotion, and ranges through to discussion of emotionally relevant domains such as language and pain. The consensus paper starts with a discussion of the role of the cerebellum in emotional perception by Maria Leggio and Marco Molinari who provide a critical overview of these early stages of emotional pathways. Next, Federico D’Agata, Michael Adamaszek and Laura Orsi discuss how the cerebellum is involved in emotional recognition, in both early and later stages of emotional processing, and its relevance to social cognition. Roberta Ferrucci and Alberto Priori provide an account of how our knowledge of cerebellar contributions to emotional processing has developed. Benedetto Sacchetti discusses the role of the vermis and its connections in the stages of emotional learning and memory. Christophe Habas takes a broader neuroanatomical perspective by summing up current insights about the topographical organisation of the emotional cerebellum. In addition, Michael Adamaszek and Kenneth Kirkby provide a critical overview of what is known about the neurophysiological basis of the cerebellar contribution to emotion. Eric

Moulton discusses pain processing, a topic of both theoretical and clinical importance, summarizing the involvement of the cerebellum in a broad range of aversive emotions. Stefanie Keulen, Jo Verhoeven, Frank Van Overwalle and Peter Mariën provide an in depth overview of how the cerebellum responds to and shapes the emotional components of language, in particular to emotional speech processing. Finally, Dennis Schutter outlines the role of the cerebellum in mood disorders, addressing clinical issues and their pathophysiological background.

Cerebellum and Emotional Perception (Maria Leggio, Marco Molinari)

The concept of perception is a complex one. According to the Oxford Advanced Learner's Dictionary perception is: - the way we notice things, especially with the senses, - the ability to understand the true nature of something, - as well as an idea, a belief or an image we have as a result of how we see or understand something. A vast amount of the literature on neuroscience addresses the complexity of mechanisms involved in perceiving the outside world as well as our own physical or emotional state.

Within this framework, several empirical data show that the cerebellum is involved in a wide range of perceptual processing (see the consensus paper by Baumann et al. (2) for an extensive view of this issue). Indeed, perceptual optimization and prediction of incoming information have been shown to rely on cerebellar processing in virtually all sensory domains (3,4).

According to Shobe's theoretical model (5), emotional processing arises from subcortical networks that influence cortical activity, enabling a cross-callosal transfer of emotional information from the right hemisphere to the left hemisphere. Interestingly, this cross-callosal transfer is considered relevant for perceiving negative emotions (5).

Furthermore, there is evidence that two discrete neural systems support emotional perception: one operating at a conscious (explicit) level, the other at a non-conscious (implicit) level (6). The two systems share most of the neural substrates, but explicit processing recruits additional networks in comparison to the implicit one.

Neuroimaging and clinical data identify the cerebellum as a key region among the emotion relevant structures (7,8) and distinct subregions of the cerebellum are

selectively involved in different primary emotions (9). However, what the exact role of the cerebellum is in the emotion related networks is still an open question. Positive and negative emotions have been both considered to be processed by the cerebellar circuits (9,10), although a prevalence of negative emotions processing has been suggested (11,12). In different functional domains the cerebellum has been considered to be associated with implicit processing. Regarding emotion, contrasting data have been reported. Indeed, a cerebellar involvement in both implicit and explicit processing has been described (6,13).

We recently analysed emotional perception in subjects with cerebellar lesions. During emotional stimulation mean blood flow velocity (MFV) of the middle cerebral arteries (MCAs) was recorded by means of transcranial Doppler ultrasound (TCD) (14). It has been demonstrated that in healthy subjects negative emotional stimuli processing clearly evokes an increased MFV in the right MCA (15). Since this increase during negative emotional stimulation is lost in patients affected by cerebellar pathologies, cerebellar lesions cause selective impairments in the ability to activate the right hemispheric areas during negative emotional stimulation (14). This finding suggests that the cerebellum has a role in negative emotional stimuli processing. Indeed, cerebellar involvement in elaborating negative emotions is also supported by neuroimaging and neurophysiological studies (11,12).

Emotional processing is an important component of gambling behavior. Different studies focussed on the frontal cortex and basal ganglia as key nodes in the gambling functional brain networks (16,17). A cerebellar role in perceiving emotions would suggest a possible alteration in the gambling behavior in case of cerebellar damage. Surprisingly, a normal gambling pattern has been reported in subjects affected by cerebellar pathologies (18). Indeed, patients with cerebellar disorders do not fail to anticipate the possible consequences of their choices and thus learn to avoid choices that predict future regret correctly. As a result, cerebellar patients are able to anticipate regret and to maximize expected values. Furthermore, they present normal physiological modulation of skin conductance according to the different conditions of the gambling task (18). Overall, in presence of a cerebellar lesion subjects are able to process emotional events and to perceive their negative emotional content.

However, when cerebellar patients are asked to evaluate their affective state through an emotional rating scale that indicates the valence and the intensity of the

affective response, they are unable to make explicit their negative feeling (18). This datum, in line with functional neuroimaging data by Scheuerecker et al. (6), demonstrates implicit/explicit differences in the cerebellar processing of emotional perception, i.e. a cerebellar specific involvement in explicit self-monitoring of regret but not in implicitly controlling regret dependent behavior (18).

A similar deficit in explicit perceiving emotion has been observed when the mood of patients affected by cerebellar pathologies is tested by MoMo. MoMo is a new mood-monitoring device developed to detect depressive mood as well as daily and weekly mood fluctuations (19). Unlike the patients with a diagnosis of major depression, cerebellar patients affected by clinically relevant depressive disorders are unable to explicitly recognize their bad mood (personal observation, manuscript in preparation).

The importance of the cerebellar circuits for explicit self-recognition of negative emotion may be of relevance for understanding the neuropsychiatric profiles that can be detected in subjects affected by cerebellar disorders (20).

It is important to underline that sometime emotional symptoms are the major complaint of cerebellar patients. This condition has been well depicted by Annoni et al (21) in a patient affected by left cerebellar stroke. Self-evaluation of life situation was marked by affective indifference, he did not feel his own emotions and did not care about other persons' emotional states. The patient declared: "Before my stroke, when a person of the family was suffering, it was as if a part of myself was ill. Now, it is a simple fact, like something written in a newspaper". He suffered from several cognitive deficits but his most persistent affliction concerned the loss of emotions (21).

In spite of this body of evidence regarding behaviour/emotional symptoms caused by cerebellar lesions (20-22), the counseling and medical management of patients affected by cerebellar diseases still suffer from the lack of a well defined cerebellar psychiatric nosology and from the clinicians' unawareness of the neuropsychiatric symptoms.

Schmahmann, Weilburg and Sherman (20) grouped the wide range of cerebellar behavioral and emotional disorders in 5 major categories – attentional control, emotional control, autism spectrum, psychosis spectrum, and social skill set. They conceptualized these behaviours, many of which are specific diagnosable entities, "as either excessive or reduced responses to the external or internal environment".

It has been advanced that psychotic symptoms may arise from the loss of internal coherence between internally perceived and externally generated signals (23). This “mind-world synchronization” can be achieved only if the perceptual systems constantly tune themselves to an ever-changing environment (24) and the perceptual tuning can be obtained only if patterns are detected and predictions are made (3).

Following early proposal from Braitenberg and colleagues (25) we applied the “sequence detection model” to describe the operational mode of the cerebellar processing in several domains including emotion processing (3). According to this model, the cerebellum detects and simulates repetitive patterns of temporally or spatially structured events, allowing internal models to be created (26) and predictions about the incoming events to be made (27).

It is worth noting that cerebellar dysfunctions have been described in several psychiatric pathologies, such as schizophrenia and autism, in which impairments in patterns processing and error signals prediction have been advanced.

Ultimately cerebellar processing might take part in generating coherent representations of the world (28,29) and the hypothesis that patients affected by cerebellar lesions are impaired in self-perception of emotions because of an affected top-down emotional-cognitive integration supports this idea.

Cerebellum and Emotional Recognition (Federico D’Agata, Michael Adamaszek, Laura Orsi)

We define social cognition as the capacity used by humans to understand and interact with other people in a social environment. We will include in the basic skills of social cognition the perception of others as subjects endowed with intentions, beliefs, thoughts and emotions and the use of these skills to build interactions between two or more individuals (e.g. attachment, teamwork, obedience, imitation, respect of social norms). Social cognition is important for the life of the Homo Sapiens and it is a main aspect of its development. At a very early phase in their development, children are able to respond to social stimuli (e.g. facial expressions, joint attention) and the learning of these skills is essential. However there are many open questions. Is social cognition a special kind of cognition from a neural perspective, or does it use general mechanisms

readapted from emotion and cognitive processing? What are the neural networks involved? This section will focus on a more specific question: is the cerebellum part of these networks? It should be emphasized that the cerebellum is involved in many cognitive and affective skills that are necessary for the proper functioning of social cognition, but its specificity is more controversial.

In social cognition there are two main topics: the mirroring field that focuses on circuits that are involved in one's own actions and emotions and in perceiving those of others and the Theory of Mind (ToM) field that study the role of midline structures in mentalizing about the states of others (30). However, it remains to be demonstrated if social cognition is hard wired into the brain or not (31,32). There is convincing evidence, derived from data obtained in healthy subjects and patients with cerebellar damage, of the involvement of the cerebellum in many basic social cognition skills. Healthy subjects showed posterior cerebellar activations during joint attention (33), during anticipation of social group success (34), during observation and imitation of facial emotions (especially negative emotions), during goal directed actions (35,36) and during mother-infant interaction (37). In a recent meta-analysis (38), partial involvement of the cerebellum was found in event or person mentalizing or mirroring tasks. In addition a critical contribution to higher abstraction mentalizing was found as well. Important findings correlate brain areas connected to the cerebellum and the size of the social group or social status, both in humans (39,40) and in monkeys (41,42), in particular the amygdala and the frontal cortex.

Cerebellar stroke patients showed impairment in the ability to recognize emotions regardless of the stimulus (visual or auditory), particularly for negative emotions (43). Patients with cerebellum degeneration (spinocerebellar ataxia) had deficits in ToM and recognition of face emotional expressions, especially of social emotions like guilt, with a gradient related to the complexity of the stimulus (44,45).

These studies suggest that the cerebellum also contributes to processes involving morality. Harenski and colleagues (46), for example, showed activation of the right cerebellum when subjects were presented with emotional images associated with moral values as compared to value-neutral images. These results concur with a prior functional magnetic resonance (fMRI) study that showed right cerebellum activity when participants were experiencing moral compassion (47). The positive association that was found between cerebellum activity and perceived degree of severity of

presented moral violations further adds to a link between the cerebellum and morality (48). In addition to perceiving and experiencing, the cerebellum also appears to be involved in moral decision making (49). A recent fMRI study using the psychophysiological interaction analysis method reported significant interactions between the cerebellum and cortical midline structures (CMS) including the medial prefrontal cortex (MPFC) and posterior cingulate cortex (PCC) in morality-related task conditions (50). The observation that the functional association between the cerebellum and CMS increased when participants were experiencing intuitive negative emotional responses, suggests that the cerebellum participates in modulating emotions during the process of decision making.

In clinical populations, patients with schizophrenia presented with alterations in fronto-temporal-thalamo-cerebellar networks, with decreased cerebellum volume and with cerebellar neurotransmitter dysfunctions (51). A core feature of schizophrenia is affective blunt, emotion recognition deficits and social difficulties that could be related to cerebellar alterations for emotion and to mixed results for ToM (52). Perhaps the most convincing evidences come from research on Autism Spectrum Disorder (ASD). In genetically engineered mice the loss of Tsc1 (tuberous sclerosis 1) causes alterations in Purkinje cells morphology and abnormal behavior, including altered social interactions, therefore indicating a close link between cell function and ASD deficits (53). During early postnatal years patterns of ASD gene coexpression are specifically expressed in the cerebellum, moreover, early disruption of the cerebellar circuitry is positively correlated with ASD with a risk ratio as high as 40 (54).

A fundamental concept that emerged is *developmental diaschisis* (54): cerebellar dysfunction in critical sensitive periods may disrupt the maturation of distant neocortical circuits, in fact, with the exception of the cerebellum, ASD deficits arising from early-life lesions are to a large degree recoverable over time (Figure 1).

<<insert figure 1 here>>

Many ASD symptoms (motor, emotional, social) can be unified in a framework that depicts the disorder as a predictive impairment (55) arising from a loss of connection of the frontal cortex and cerebellum during development. This fronto-cerebellar network may be equally important in ontogeny as it is in phylogeny.

Comparing the brains of primates and humans, it has been recognized that the posterior cerebellar lobes, the frontal cortices and pontine connections co-evolved in parallel (56,57). These cerebello-thalamo-cortical networks play a crucial role in human evolution (58), but it is still under debate if the main determinant of the evolutionary pressure was the use of tools or the size and complexity of the social group (59). Using phylogenetic comparative analysis some authors demonstrated that the cerebellum and frontal structures not only co-evolved, but also correlated with the development of tools and with the size of the social group (58). This means that if we consider the cerebellum as part of a single system, both in terms of phylogeny and ontogeny, we can appreciate its importance in the development of many important skills crucially involved in social cognition.

Cerebellum and Emotional Processing (Roberta Ferrucci, Alberto Priori)

Emotional information processing comprises evaluative, experiential, and expressive components (60,61). The evaluation of affect depends on an individual's ability to identify the emotional valence conveyed by an event or an object and is influenced by mental illness. People with psychiatric disorders may lose their capacity to distinguish between pleasant and unpleasant experiences and the ability to assign the appropriate emotional valence to these experiences. For example, patients with depression tend to consider positive life events negative or harmful whereas patients with schizophrenia seem unable to extract from a situation or experience the emotional content needed to decide whether the experience is pleasurable or unpleasant.

The cerebellum is particularly well-suited to regulate emotion, as connections with limbic regions, including the amygdala, the hippocampus, and the septal nuclei have been posited (9).

The concept that the cerebellum intervenes in regulating emotions and mood has gained popularity since the 1970s (9,62). The first study linking the cerebellum to emotions reported the case of a patient who underwent electrical stimulation of the dentate nucleus and superior peduncle and reported experiencing negative feelings (63). Later in 1970, it was shown that chronic stimulation of cerebellum improves

emotional symptoms, such as aggression, anxiety, and depression, in the affected patients.

A recent possible way of gathering insights into the functional role of the human cerebellum in the regulation of emotion may be provided by transcranial direct current stimulation (tDCS) (64). The need for a non-invasive tool to influence cerebellar function in normal and pathological conditions led researchers to develop cerebellar tDCS. Cerebellar tDCS, depends on the principle that weak direct currents delivered at around 2 mA for minutes over the cerebellum through surface electrodes induce prolonged changes in cerebellar function (65). Cerebellar tDCS modulates several cerebellar skills in humans including motor control, learning and emotional processing (66,67). In a recent study designed to understand the cerebellar role in emotional expression recognition, Ferrucci et al. (64) showed that Cerebellar tDCS significantly enhanced the response to negative facial emotions leaving the perception for positive and neutral facial expression unchanged. These results fit in well with fMRI studies showing that whereas the emotional stimulus happiness activates the middle temporal gyrus, parahippocampal gyrus, hippocampus, claustrum, inferior parietal lobule, cuneus, middle frontal gyrus, inferior frontal gyrus, and anterior cingulate gyrus, the negative emotional stimulus activates the posterior cingulate, fusiform gyrus, and cerebellum (11). The study also suggests that processing of negative facial expressions involves at least two dissociable, but interlocking systems. One responds to facial stimuli (sad) involved in social conditions, the other implicates regions involved in behavioral extinction by responding to angry facial expressions. In addition, reciprocal connections link the cerebellum with brainstem areas containing neurotransmitters involved in mood regulation, including serotonin, norepinephrine, and dopamine (68,69). These results therefore add to previous proposals suggesting that the cerebellum is embedded in a widespread network that determines the meaning of external stimuli and might also mediate facilitatory cortical processes. Healthy subjects' ability to recognize an angry facial expression also fit in with current evolutionary knowledge suggesting that natural selection resulted in a propensity to react more strongly to negative than to positive stimuli (70). This heightened sensitivity to negative information, termed 'negativity bias,' is a reliable psychological phenomenon in adults (71). By allowing individuals to adapt to the environment it favors survival of the human species.

Recognizing an expression of anger should prepare the organism for defense and struggle, as part of a defense system designed to protect the organism against threats to acquire valuable resources. Hence, we hypothesize that the fight-flight reactions of the organism involve cerebello-hypothalamic interactions. Over the past three decades, numerous investigators have electrically stimulated discrete brain areas to evoke aggressive behavior in several animal species, showing that aggression can be elicited by electrical stimulation of the hypothalamus and periaqueductal gray (PAG) of the midbrain (62). The hypothalamus seems to be critical for the ability to express aggressive responses and the attack mechanism seems to be powerfully modulated by distinct nuclei in the amygdala (72). Animal aggression has also been studied extensively using experimental models other than those entailing brain stimulation. The attacks simulated in naturalistic models (such as maternal aggression, offensive or defensive territorial aggression, mouse-killing, and the "cornered rat") and in artificial models (such as shock-induced fighting) all share similarities with the 'hypothalamic attack' (72).

Cerebellum and Emotional Learning (Benedetto Sacchetti)

In the past two decades, an increasing number of studies have pointed out that the cerebellum, with particular emphasis on the cerebellar vermis, plays a role in memory formation of emotionally laden stimuli. In 1990, Supple et al. demonstrated that irreversible lesions of the cerebellar vermis, but not of the cerebellar hemispheres, impaired the acquisition of classically conditioned bradycardia in rabbits (73) and rats (74). Subsequently, we demonstrated that reversible inactivation of the cerebellar vermis, performed after pairing sensory stimuli to unconditioned aversive stimulation, caused amnesia in rats (75). Additional studies confirmed these findings (75-81; see 81 for an extensive review).

One of the more important discoveries in these studies was that the role of the cerebellum in emotional learning is more complex than the simple regulation of motor and/or emotional responses. In fact, manipulation of the vermis caused amnesic effects without interfering with basal motor or emotional responses, or with sensory stimuli perception in rodents (74-77,80). These data are in accordance with data obtained in

humans, which showed that some regions of the cerebellum are activated by associative aversive processes independent of the direct regulation of motor/autonomic processes (81-83). Overall, both animal and human studies indicate that the vermis plays a role in the associative processes that form emotional memory traces. Remarkably, this part of the brain is involved in all of the putative phases of the emotional memory process, namely the acquisition (73,74,81), consolidation (75,80), storage/retrieval and reconsolidation (77), and extinction (83) of memories.

The involvement of the vermis in emotional learning raises the question of whether this structure is also a site for plasticity related to memory trace formation. Supple et al. (73) showed that an acoustic stimulus, previously paired with an electric shock, elicited increased firing of the vermal Purkinje cells. Subsequent studies demonstrated that associative fear learning is correlated with potentiation of both excitatory (76,84) and inhibitory (85) synapses impinging onto the same Purkinje cells. These changes are long lasting (at least up to 24 h after learning) and are strictly related to associative processes, thus representing neural substrates of cerebellar learning processes. The concomitant plasticity of excitatory and inhibitory synapses plays a critical role in the spike generation of Purkinje cells, and therefore for the precision of memory and learned behavior (85). Remarkably, learning-related changes in the inhibitory–excitatory balance were also detected in the mossy fibre terminals at the vermal cortex entrance (78). Indeed, the manipulations of either the excitatory synapses on the Purkinje cells (77) or of the mossy fibre terminals (78) caused amnesia, revealing that these changes are not a metaplasticity phenomenon, but a necessity for learning to occur.

In forming new emotional memory traces, the vermis likely interacts with several other structures involved in emotional learning, such as the amygdala, hypothalamus, periaqueductal grey, and sensory cortex. A recent study showed that blockade of the basolateral amygdala, a key site for fear learning, prevents the formation of learning-related plasticity in the vermis (86). On the other hand, it has been reported that vermian and fastigial stimulation induce electrophysiological responses in the basolateral amygdala (87). These results suggest that the vermis interacts with the amygdala during emotional associative processes and that such interplay may be bidirectional.

By way of the fastigial nucleus, the vermis also projects to the periaqueductal grey area, and this connectivity is fundamental for generating appropriate patterns of emotional behavioral responses (79,88). Another important interplay for associative fear memories may stem from the connectivity of the vermis to the auditory cortex. Sensory cortices, such as the auditory cortex, are required for the formation (89) and the long-term storage/retrieval (81) of emotional memories (91). By passing through a cortico-pontine-cerebellar pathway, auditory cortical outputs arrive at the cerebellar vermis (92). Therefore, the vermis may receive memory-related information encoded at the level of the sensory cortex through the mossy fibres, a pathway that, as previously described, displays learning-related changes (78).

Given all of these connections, the vermis may represent an interface between sensory stimuli, the emotional state of the subject, and motor responses. Thus, learning-related plasticity at this site may be necessary to relay appropriate emotional/motor behaviors to sensory stimuli, and to maintain this information for a long period of time.

Topographical aspects of Cerebellum and Emotion (Christophe Habas)

A growing number of clinical, anatomical and imaging data have firmly established the role of the cerebellum not only in sensorimotor function but also in cognition and, very likely, in emotion. In particular, functional imaging, including brain resting-state functional connectivity has allowed a precise *in vivo* anatomic-functional parcellation of the whole human cerebellar cortex, and a clear characterization of the main cortico-cerebellar networks organized into parallel closed loops subserving specific cerebellar functions. The cerebellum has thus been subdivided into two main regions (93): 1. a sensorimotor zone (lobules I-VI and VIII) in relation with sensorimotor cortex, and 2. a cognitive supramodal region (lobules VI, VII especially crus I and II, VIII and IX) in relation with the associative cortices, and included in intrinsically connected circuits such as right and left executive and default-mode networks (94). However, several data support the view that a third well-delineated

cerebellar limbic zone specifically devoted to emotional processing must be added (1,95).

Stimulation functional imaging. Baumann and Mattingley (9) found strong posterior vermal and paravermal cerebellar activation (lobules VI-IX) correlated with several primary emotions (happiness, anger, disgust, fear and sadness). Activated clusters were not strictly segregated as vermal lobule VIIIA was recruited by disgust, sadness and happiness, while lobule IX activation was involved in anger and disgust. Alexithymia was accompanied by hypoactivity in vermal lobules V-VI, lobule IX and the dentate nuclei (96). Activation of the lateral hemispheres was also observed for anger and fear (9), disgust (97), autonomic functions (98) and pain (99,100). It is noteworthy that noxious thermal stimulation induces activation of the anterior vermis, deep cerebellar nuclei and hemispheric lobule VI, and that pain intensity rating was associated with activation within vermal lobule III, the deep cerebellar nuclei and ipsilateral hemispheric lobules III-VI (101). Meta-analyses found emotion-related activity in vermal lobule VIIAt (7), left crus I and right lobule VI (7,102), right lobules VIIIA, IV/V and IX, left lobules VI and VIIIB, right crus I and left crus II (102). Another meta-analysis reported cerebellar activation during explicit emotional face processing in the vermis of lobules IV and VI (103). Moulton et al. (100) demonstrated that heat noxious stimuli and passive viewing of unpleasant images activated the same zones in hemispheric parts of lobule VI, crus I and VIIb.

Resting-state functional connectivity. An independent component analysis found at rest that the salience network involved in interoception, autonomic and emotional regulation (104) encompasses vermal and hemispheric parts of the lobule VI as well as the adjacent crus I and dentate nuclei (94). Furthermore, region-of-interest analyses showed functional coherence between the cerebellum and the brain areas participating in emotion processing:

1. amygdala and vermis of lobules I-V, VIIb, VIIIA and IX, and hemispheric part of lobules I-VI and VIIb (105), especially the centromedial subnucleus (106);
2. hippocampus (declarative memory) and lobules I-X (105);
3. right dentate nucleus (main output channel of the cerebellum) and hypothalamus, insula and anterior cingulate cortex (BA 24) (107).

Synthesis. The “emotional” cerebellum might include several specific and non-specific areas. First, the posterior vermal and paravermal areas (and associated deep

cerebellar nuclei especially the fastigial nuclei) with a prominent role of lobules VI-VII may partake in primary emotion processing. Each emotion would recruit specific cerebellar loci, with some spatial overlapping. This specific “medial limbic” part of the cerebellum may partly belong to the salience network including the insula, frontal operculum, anterior cingulate and medial prefrontal cortices, and may also be connected with the amygdala and hippocampus. Second, lateral hemispheres of the posterior cerebellum (lobules VI-VIII, especially crus I and II) which are part of the executive cerebellum, may be recruited by cognitive aspects of emotion processing (working memory, attention allocation, emotion evaluation, response selection) or associative learning. Third, since the dentate nucleus is functionally connected with the neocerebellar cortex (especially lobules VI/VII) and with the hypothalamus and cingulate cortex, some areas within lobules VII (crus I and II) may participate in a more lateral (and likely phylogenetically more recent) “limbic” area within the cerebellum. Fourth, anterior lobe and lobule VIIIB activation could also reflect automatic motor aspect of emotional processing like facial expression or startle/withdrawal/avoidance reflex. Fifth, pain processing mainly concerns the vermal anterior lobe and hemispheric lobe VI.

In conclusion, the cerebellum not only seems to be involved in experience of emotion (medial and lateral “limbic” cerebellum) but also in the control and coordination of autonomic, cognitive and appropriate behavioral responses (salience and executive networks).

Neurophysiology of Emotion in the Cerebellum (Michael Adamaszek, Kenneth Kirkby)

Clinical and brain imaging research has identified discrete regions of the cerebellum that are involved in cerebral circuits responsible for emotional processing. Of note are the medial cerebellum, in particular the vermis, and lobules VI and Crus I in the lateral cerebellum, and their reciprocal connections to the prefrontal cortex and temporal lobes (7). Whilst our understanding of cerebellar topography in relation to emotional processing continues to grow, research into the neurophysiology of these processes has been less prominent in the literature. Neurophysiology offers a number

of important insights into autonomic responses and higher order neural circuitry involved in emotional processing. Reports of impaired responsiveness of arterial blood flow to aversive stimuli (108) and reduction of the decrease in heart rate normally associated with fear conditioning in subjects with vermal lesions (109) emphasise cerebellar participation in autonomic pathways that subserve the cardiovascular system and emotional regulation (110). Additionally, observations such as an impaired skin conduction response to negative stimuli attributed to a left cerebellar lesion (111), an impaired startle response after vermal lesions (112), and an impaired blink reflex to fear stimuli in medial cerebellar lesions (113), emphasise the neurophysiological evidence of cerebellar involvement in unconscious responses mediated by autonomic neural pathways during emotional processing and associated behavioral routines.

With regard to high order processing of emotional cues, neurophysiological investigations have indicated functional connectivity between the cerebellum and different cerebral domains involved in preattentive processing. Event-related potential (ERP) studies in humans with circumscribed cerebellar lesions of the lateral hemispheres have identified impaired visual emotional attention (114) and emotional face recognition (115). The associated ERP differences have been found in both early and late processing stages, suggesting impairments of bottom up as well as top down control of emotional cue processing (see figure 2).

<<insert figure 2 here>>

The cerebellum plays a key role in the rapid synchronization of motor and sensory information processing, including the complexities of recognising and responding to emotional cues. This seems to involve serial as well as parallel computations in networks that handle stimulus perception (116,117) feeding into nerve pathway loops that enable forwarding functions which anticipate the results of motor or sensory activity (118,119). Whilst cerebellar input to autonomic pathways seems to track along a closed neuronal loop in several milliseconds, in higher order emotional processing ERP data characterise the cerebellum as an active interface with important functions in the large-scaled cerebral networks responsible.

The findings of research into the neurophysiology of emotional processing by the cerebellum form a suitable vantage point to comment on emerging trends in

neuroscience research. Firstly, ERP research protocols offer the most sensitive definition of time characteristics of neurophysiological pathways. ERP aids in identifying the nature of contributions of the cerebellum to the cerebral networks of different emotional domains such as emotional attention, emotional recognition, emotional empathy and emotional behavior (20). Additionally, information may be ascertained about compensatory cerebral activity of homologous areas (120), for example in prefrontal cortex in the case of disrupted cerebello-cerebral circuits of the medial or lateral prefrontal cortex (94). Electrophysiological procedures are also promising in filling the gaps in topographic descriptions of cerebello-cerebral pathways, since they distinguish the neurophysiological characteristics of these pathways in the sub-second range (117).

However, a combination of neuroimaging and electrophysiological techniques may increase the resolution of both timing and topographic parameters, as has been used to demonstrate that lesions of the Crus I are the source of ERP deviations (115). Using such combined methodologies, future research should aim to distinguish internal cerebellar contributions to emotional processing that are restricted to, for example error detection, versus those that mediate finely tuned processing of distinct emotional cues, stimulating or inhibiting the cerebral networks to which they belong to produce optimal emotional behavior. Further to this approach, research should also clarify which domains of the cerebellum serve general and which domains serve specific roles in the processing of emotion (as it has been shown for specific contributions to different emotional valences in face expressions – see 115). There is some evidence of altered P300, a prominent ERP component of cognitive information processing, in cerebellar disease (121,122). This suggests that studying the neurophysiological concomitants of cognition, in particular attention and working memory, and evaluation of their relevance to emotional processing would be of particular interest (123).

The advances in brain stimulation devices and the neurophysiological manipulations that these make available are another fascinating area of research. Thus the effects of stimulation of the vermis on emotional performance has been demonstrated in intracranial (124) and transcranial (12) stimulation. Such approaches may be used to probe excitatory and inhibitory pathways of the cerebellum, combined with electrophysiological mapping of the responses propagated in the cerebello-cerebral circuitry involved in emotional processing.

Pain and the cerebellum (Christos Papadelis, Charis Styliadis, Eric Moulton)

The cerebellum is one of the most consistently responsive brain structures to pain (99), a subjective experience that incorporates sensory, affective, and cognitive components. Our classical understanding of the cerebellum suggests a motoric role in pain, though recent findings indicate a more direct role in pain processing. Despite recent neuroimaging studies indicating that the cerebellum responds to noxious stimuli, its functional relevance is only starting to gain attention.

Ascending nociceptive input to the cerebellum Studies of pain often use acute experimental stimuli to activate nociceptive pathways, the physiological processes underlying pain perception. Nociceptors are primary afferents that respond to high threshold mechanical and heat stimuli, and chemical stimulation such as during inflammation. Two major categories of nociceptive afferents exist: A-delta and C-fiber nociceptors. A-delta nociceptors are thinly myelinated and fast conducting, while C-fiber nociceptors are unmyelinated and slower conducting. Electrophysiological studies in animals indicate that stimulation of cutaneous and visceral nociceptors can activate Purkinje cell activity in the cerebellum (99,125). At least three nociceptive spinocerebellar pathways have been proposed: (i) spino-olivocerebellar: conveys A-delta and C-fiber nociceptive afferent input to Purkinje cells in the cerebellar anterior lobe ipsilateral to stimulation (126); (ii) spino-pontocerebellar: conveys C-fiber nociceptive input to Purkinje cells in the cerebellar vermis (127); and (iii) spino-bulbar-cerebellar: projects spinal nociceptive input to the lateral reticular nucleus, and further into mossy fiber inputs to the cerebellar cortex (128).

Descending cortical and subcortical input to the cerebellum The cerebellum receives also input from areas associated with nociceptive processing (i.e. cognition, affect, and motor function [1]), such as somatosensory cortices, periaqueductal gray, anterior cingulate cortex, dorsolateral prefrontal cortices, basal ganglia, hippocampus, hypothalamus, and amygdala (128-130). With the cerebellum receiving descending information from other brain areas and ascending nociceptive information from the

spinal cord, the structure is ideally positioned to influence, or be influenced by, the processing of pain.

Neuroimaging responses to pain in the cerebellum A meta-analysis of neuroimaging studies featuring experimental pain revealed specifically localized responses within the cerebellar vermis and bilaterally in the posterior hemispheres (99). The spatial extent of vermal activation spanned across vermal lobules III, IV, and V, while bilateral hemispheric activation spanned from hemispheric lobule VI to crus I.

Though pain neuroimaging studies are not typically designed to evaluate the physiological significance of cerebellar responses, a few notable studies have focused in on this structure in the context of pain. An fMRI study found that activation in hemispheric lobule VI and the anterior vermis varied with subject reports of pain intensity, though only when stimuli were self-administered (131). The authors suggested that these cerebellar regions could reflect pain perception, and are involved in signaling the expected sensory consequences of pain. In another fMRI study, trigeminal neuropathic pain elicited by brushing and heat showed responses in crus I, crus II, and lobule VIIB that were not evoked by non-painful control stimuli (132).

Recent neuroimaging evidence suggests that certain cerebellar responses during pain may reflect multi-modal aversive processing. An fMRI study found that noxious heat and the passive viewing of unpleasant pictures activated overlapping regions of the cerebellum (100). Further analysis revealed that these functionally overlapping areas were inversely correlated with activation in the anterior hypothalamus, subgenual anterior cingulate cortex, and the parahippocampal gyrus (Figure 3). These findings suggest that responses in these cerebellar regions are not specific to pain processing, but appear to apply to other aversive sensory and affective experiences as well (133,134). Aversive processing may relate to the cerebellum's proposed role in emotional processing.

<<insert figure 3 here>>

Neuroimaging of emotional processing in the cerebellum Neuroimaging studies indicate that negative emotions correlate with activity in left VI, right IV/V and bilateral crus I, and positive emotions with right VI activity (7,135). The functional segregation of emotion within the cerebellum has been suggested, as the vermis is

related to high arousal (136) and to each of the five primary emotions (9) (Figure 4), while hemispheric VI activity relates with aversion (100) and unpleasantness (136).

<<insert figure 4 here>>

The timing of the progression of cerebellar responses to affective stimuli indicates that the cerebellum has a sophisticated role in emotion. A magnetoencephalography (MEG) study found differential spatiotemporal processing of arousal and valence across distinct cerebellar lobules (137; see also 138,139) (Figure 5). While these separate processes appeared to occur in parallel, the earliest activity related to high arousal in left crus II and vermal lobule VI, followed by unpleasant valence in left crus I, and then an interaction effect between pleasant valence and high arousal in left VI and crus I. This sequence of events suggests an integrative process between these attentional and emotional dimensions. Further study is required to determine the functional topography of the cerebellum as it relates to pain and its different sensory, affective, and cognitive components.

<<insert figure 5 here>>

The cerebellum, language and emotion: the role of emotional prosody (Stefanie Keulen, Jo Verhoeven, Frank Van Overwalle, Peter Mariën)

During the past decades, the traditional view of the cerebellum as a mediator of motor function has been thoroughly revised and it has been recognized that the cerebellum subserves a wide range of neurocognitive, linguistic, affective and social functions (38,140-143).

A crucial aspect of speech is the role of prosody, i.e. the melody and rhythm of speech, which supports the meaning of linguistic units (e.g. words, phrases or sentences). Prosody results from the complex interplay of several acoustic variables such as pitch, loudness and rhythm (144), which are typically affected after cerebellar pathology. In his hallmark 1917-paper Gordon Holms (145) described impaired speech following cerebellar damage as typically slow, monotonous, staccato, scanned, indistinct, remarkably irregular, jerky, explosive, slurred, and laboured resulting in

what was later called ataxic dysarthria and dysprosodia.

In the past, two main types of prosody have generally been distinguished: linguistic (or propositional) and emotional (or affective) prosody (146,147). Linguistic prosody supports the distinction between different sentence types by means of intonation (e.g. interrogative and declarative sentences), but also between word categories by means of word stress (e.g. /'ædrəs/ (noun) versus /ə'drəs/ (verb)). Emotional prosody modulates content in such a way that it conveys information about the emotional state of the speaker. In early models, the expression and comprehension of emotional prosody were typically situated in the homologous, non-dominant areas for expression and comprehension of language, i.e. the inferior frontal gyrus and the posterior temporal gyrus of the non-dominant hemisphere (see also: 144,148,149). However, recent studies have shown that both types of prosody require bilateral cerebral and even subcortical involvement to some degree (e.g. 150-154). The different prosodic modalities have been associated with different neural correlates. Wildgruber et al. (148), Dapretto et al. (155) (perception tasks) and Mayer et al. (156) (production tasks) found that linguistic prosody is selectively associated with activity in the language dominant inferior frontal and superior temporal gyrus (STG). Dogil et al. (157) (same experiment as in 156), found increased BOLD-response in the language dominant STG (when rendering pitch accents), and in the posterior part of the non-dominant STG extending into the middle temporal gyrus (when rendering boundary tones). The perception of emotional prosody was variably associated with non-dominant inferior frontal gyrus activity (155), bilateral orbito-frontal activity (148) and activation in the anterior part of the non-dominant STG ('affect'-mode in 157). Dogil et al. (157) concluded that '... exclusively neocortical areas [are] critically involved in prosody generation' (p. 78). Nonetheless, studies have shown that subcortical lesions encompassing the putamen and globus pallidus induce mood disorders with deficits in emotional prosodic production (158). It has been argued that dysprosody is caused by a timing deficit (144), with timing being a fundamental role of the cerebellum in motor execution processing.

Recent functional neuroimaging studies have confirmed a possible role of the cerebellum in the processing of emotional prosody. In an fMRI study of emotional prosody recognition, in which participants listened to numbers pronounced with prosodic manipulation suggesting neutral versus simple (happy, sad, angry) and

complex (guilt, proud, bored) emotions, Alba-Ferrara et al. (159) found significantly increased metabolic activation in the *right* cerebellum ($Z=3.29$) (in the presence of several left and right-hemisphere – mostly frontal, including (para)limbic – activations). This activation was also present when comparing complex and simple emotions, even when controlled for pitch. Strelnikov et al. (160) studied the perception of speech prosody in read sentences with PET and apart from activity in the right dorsolateral prefrontal cortex (PFC), they also observed activity in the right posterior lobe of the cerebellum. The area mediating functional overlap between the differentially affected domains (prosody, syntax and emotion) was the right posterior PFC. Right cerebellar activity was primarily related to speech timing perception. According to Pichon and Kell (161) the cerebellar vermis modulates fundamental frequency in emotional speech production, as increased BOLD response was triggered in the cerebellum, thalamus, globus pallidus, substantia nigra and superior temporal sulcus in especially the right hemisphere. Krienen et al. (162) argued the existence of segregated fronto-cerebellar circuits: one originating in the medial PFC, which is connected to Crus I of the limbic cerebellum (7,43,163).

<<insert figure 6 here>>

Lesion studies and studies in degenerative cerebellar disorders have provided additional evidence for the involvement of the cerebellum in (disrupted) emotional prosody. Sokolovsky et al. (45) described impaired verbal emotion attribution in patients with spinocerebellar ataxia whereas Adamaszek et al. (43) reported difficulties in prosody naming and prosody matching in a group of 15 patients with discrete ischemic cerebellar lesions. They also found a correlation between volume of the lesion and the number of errors in emotional and complex tasks.

Although the role of the cerebellum in emotional speech processing has not been thoroughly investigated, the currently available evidence of cerebellar involvement in the processing of emotional prosody as a marker of prosody timing is growing. Future research will further reveal the multifaceted role of the cerebellocerebral circuitry in the linguistic production and perception of 'emotions and affect'.

Acknowledgments:

This research was funded by a *Strategic Research Program* (SPR15) awarded by the Vrije Universiteit Brussel, Belgium.

Cerebellum in Mood Disorders (Dennis Schutter)

Mood disorders are characterized by disturbances in the person's emotional and cognitive states associated with abnormalities in the regulation of these states. Mood disorders can be subdivided in unipolar disorder which is a mental state characterized by a longitudinal state of severe depressed mood, and bipolar disorder which is a mental condition characterized by moods that cycle between depression and mania. Molecular, structural and functional studies provide evidence that mood disorders can go accompanied by cerebellar abnormalities.

Proton magnetic resonance spectroscopy (MRS) research has provided evidence for global reductions of gamma-aminobutyric acid (GABA) synthesizing proteins in cerebellar tissue of patients diagnosed with unipolar and bipolar disorder (164). More recently, results from another post-mortem study demonstrated significant reductions of Purkinje cells in the anterior lobe of the cerebellum in a patient with bipolar disorder. Furthermore, abnormal GABA proteins are proposed to play a significant role in the expression and migration of GABAergic Purkinje cells during cerebellar development (165). In addition, there is some evidence suggesting that the cerebellar vermis in children with depression and familial bipolar disorder show neurochemical abnormalities in the metabolite N-acetylaspartate and choline ratio (166). Further support for metabolic disturbances comes from a study that showed decreased myo-inositol and choline concentrations in the cerebellar vermis of healthy children and adolescents between nine and 17 years of age with a familial risk for bipolar disorder (167). In sum, results suggest anomalies in cerebellar metabolism and cellular architecture in mood disorders.

In addition to metabolic abnormalities, cerebellar vermal abnormalities have been repeatedly demonstrated in patients with bipolar disorder (168-171). In spite of the fact that the observed volumetric reductions may in some cases be confounded by medication use, the findings do support the idea that the vermis is part of a neural circuit that regulates mood. Patients with bipolar disorder show a progressive decline

in hippocampal, fusiform and cerebellar gray matter density over four years as compared to control subjects (172). The decline is correlated to worsening of cognitive functioning and illness course, and fits prior findings of cerebellar vermal volume reductions. In contrast, other studies have not been able to detect vermal volumetric reductions or even found evidence for enlarged vermal volumes in bipolar patients in comparison to controls (172,173). Additional support for smaller cerebellar volumes in unipolar and bipolar patients was recently provided by a voxel-based morphometry study (174-176). In addition, some evidence was found that their healthy siblings also had smaller cerebellar volumes, suggesting that reduced cerebellar volumes may constitute a clinico-anatomical biomarker for the susceptibility to developing mood disorders (177). White matter deficiencies in the cerebellum have also been reported in unipolar and bipolar disorder and provide further empirical ground for structural abnormalities in the cerebellar circuitry of patients suffering from mood disorders (178,179).

On the functional level, disease specific increases of resting state cerebellar activity have been observed in unipolar disorder (180-182), and in women with premenstrual syndrome depressive disorder in the follicular to the late luteal phase (183). In contrast, a meta-analysis provided evidence for decreases in cerebellar activity during reward processing in patients diagnosed with unipolar disorder (184). The latter finding concurs with previous meta-analytic findings of abnormal cerebellar responses to emotional relevant information in unipolar disorder (181). Preliminary findings from a longitudinal study in older patients suggest that in- or decreased resting state cerebellar activity in unipolar disorder depends on whether patients are male or female respectively (185).

A number of studies have found reductions of local signal synchronization in the cerebellum of patients with unipolar and bipolar disorder (186,187). Interestingly, abnormal synchronization of local cerebellar signals has been found to differentiate between treatment resistant and treatment sensitive in patients with unipolar disorder (188). The decrease in local cerebellar signal synchronization in unipolar disorder concurs with diffusion tensor imaging results showing abnormal white matter integrity and neural connectivity in the cerebellum of young treatment resistant patients with unipolar disorder (189). In fact, increases of local signal synchronization in the

cerebellum have been linked to clinical improvement following antidepressant treatment (182).

Abnormalities in cerebellar functional connectivity to limbic and cortical regions is a reliable finding in patients with unipolar disorder (190-193). In particular, abnormal cerebellar-cerebral resting-state functional connectivity is able to discriminate depressive patients from healthy controls (194). Both in- and decreased functional coupling of the cerebellum with the brain's cortical default mode network has been observed in unipolar disorder (191,192). Moreover, a recent study showing functional decoupling of the cerebellum and the caudate nucleus lends further support for the proposed disturbances in cerebello-cortico-limbic circuits (193). Finally, several studies indicate that cerebellar functional connectivity to amygdala and hypothalamus normalizes following successful antidepressant treatment (194,195). In Table 1 an overview is provided of the results showing cerebellar abnormalities in mood disorder as compared to healthy controls.

<< Insert Table 1 about here >>

Summary and Conclusions

The aim of the present compilation is to provide an overview of the available evidence for the involvement of the cerebellum in emotion and related domains from a multidisciplinary perspective. Results of this review provide support for the idea that the cerebellum is an intricate and integral part of the neural machinery dedicated to emotion. In particular the vermis and lateral lobules, such as crus I and II of the cerebellum, have been found to be involved not only in early steps of perception and recognition of emotional cues, but also in later integrative stages of emotional evaluation. In addition, these regions are suggested to be implicated in forwarding output to cerebral pathways for optimal emotional, but therefore also cognitive and motoric, and finally social behavioral expression. The novel insights in cerebellar function raise many new questions that need to be addressed in future research.

Involvement of the cerebellum in implicit and explicit processing of emotion

perception is dealt with by Leggio and Molinari. The authors note differences in the amount of dependence on top down control mechanisms, i.e. a specific cerebellar recruitment in explicit but not implicit processing of negative emotional behavior, which might account for loss of self-perception of emotions in cerebellar lesions. Similarly, D'Agata, Adamaszek and Orsi emphasized the involvement of the cerebellum in emotion recognition, necessary for the proper function of social cognition and moral decision making, with recognition deficits correlated with the complexity of the socially relevant emotional stimulus.

Involvement of the cerebellum in the perceptual and attentional processes of emotionally relevant information is proposed to have resulted from the development of neural circuits dedicated to emotion processing . Sachetti points to the central role of the vermis in the associative processes involved in forming emotional memory traces, across all substantial stages from acquisition up to consolidation, retrieval as well as extinction of these traces. Sacchetti attributes associative emotional learning of the cerebellum to excitatory and inhibitory synaptic plasticity. The result is a cerebellum responsive to the demands of emotional situations on the basis of stored emotional memories and learned social behaviors. This assumption is close to the view of Ferrucci and Priori, who conceive the cerebellum as an intrinsic part of a widespread network that determines the meaning of external stimuli. Further, as having a presumptive role in mediating facilitatory cortical processes as a key function of emotional processing. Based on clinical and experimental studies, including non-invasive transcerebellar DCS, Ferrucci and Priori emphasize the role of the cerebellum in processing negative emotional stimuli. They also focus on cerebellar connections to the hypothalamus, a crucial center mediating the expression of anger. Through this cerebello-hypothalamic axis, the cerebellum contributes to fight-flight behavior.

The study of higher and more sophisticated functions has recently expanded with evidence of cerebellar involvement in tasks in which emotion is intertwined with cognition and reasoning. An example of particular relevance is that of moral judgment, which also incorporates concepts like morality, sense of justice and self-agency. Several neuroimaging studies reported significant activation of the cerebellum in moral task compared to control conditions (46-50). Indeed, Demirtas-Tatlid and Schmahmann in a recent review outlined the reciprocal connections of the cerebellum to areas implicated in the neural basis of reason, emotion, moral behavior and aggression,

including the dorsolateral and medial prefrontal, anterior and posterior cingulate, superior and middle temporal, posterior parietal and posterior parahippocampal cortices as well as the hypothalamus (197). A possible interpretation comes from a recent experiment that reported a significant interaction between the cortical midline structures, in particular the medial prefrontal cortex (MPFC) and the posterior cingulate cortex (PCC), as important for self-referential processing, and brain areas activated by morality-related tasks including the cerebellum (50). Human morality, distributed in a complex and wide array of neural circuits operating in a decentralized and highly parallel fashion, responds to environmental demands by producing adaptive behavior (198). In this regard, one of the core functions of the cerebellum seems to be the integration and forwarding of emotional and cognitive aspects to the cerebral cortex in behaviour adaptation. The observed patterns of cerebellar activation during specific moral tasks, are associated with domain-dependent networks of cortical structures in the lateral and medial prefrontal cortex, as well as subcortical structures of the midbrain and the cerebellum. Hence such cerebellar activity might reflect an integrative contribution to higher order processing areas, involved in evaluating and solving cognitive-emotional tasks, such as forming moral judgements. According to the recent findings of Han (2016) involving the left lateral cerebellar hemisphere,, the integrative functions of Crura I and II of lobule VII of the cerebellum are presumably one of the most relevant cerebellar hubs of converging and forwarding emotional and cognitive informations to the cortical areas, in particular the prefrontal cortex. Thus, further neuroimaging and neurophysiological studies are needed to clarify further details of cerebellar functions in different issues of moral.

A full understanding of the role of the cerebellum in emotion requires attention to the areas of the expression of emotion in language, and the processing and emotional valence of pain. With respect to speech processing, Keulen, Verhoeven, Van Overwalle and Mariën discuss the close functional interplay between cerebellar and cerebral regions during the processing of emotional prosody in speech. The crucial role of the cerebellum in speech prosody seems to relate to the timing domain. As a result, dysprosody in cerebellar speech disorders might be caused by a timing and planning deficit. Considering the experience of pain, Papadelis, Styliadis and Moulton point to the involvement of the cerebellum in a variety of pathways of pain processing. Cerebellar

interactions with ascending and descending pain information channels emphasize its influence in different aspects of pain processing. The vermis, and the posterior hemispheres of the cerebellum are important locations for the perception and modulation of pain experience. Interestingly, the cerebellum seems to influence the categorisation of aversive stimuli via multi-modal processing pathways. This is in line with the summary by Adamaszek and Kirkby of the neurophysiological features relating to the cerebellum in processing of emotion. The analysis of time-dependent stimuli requires fast information processing in integrative steps, utilizing parallel and serial processing to evaluate discrete aspects of emotional information, synthesising these to adjust emotional behavior.

Neuropsychiatric disorders are of particular interest in research on cerebellar involvement in emotional behavior. D'Agata, Adamaszek and Orsi note that mental disorders such as schizophrenia or autism spectrum disorder with prominent deficits of social cognition are presumably associated with cerebellar impairments that disrupt the fronto-thalamo-cerebellar networks. Schutter defines cerebellar involvement in mood disorders at its molecular, structural, and also functional levels. Schutter describes specific reductions of local signal synchronization in patients suffering from unipolar and bipolar mood disorders, and also closely linked to clinical improvement following antidepressant treatment.

According to the foundational concept that the cerebellum constructs or generates internal models for the control and adaptation of behavior across contexts (199), a related issue is the interaction between emotion and motor coordination, and, in particular the impact on emotional processing of ataxic disturbances in patients suffering from cerebellar disorder. Although little is known about the direct influence of emotion on the symptoms of cerebellar ataxia, indirect evidence of impaired emotional processing is suggested by depressive comorbidity in cerebellar patients. Depression is a commonly reported comorbidity in Spinocerebellar Ataxia (SCA), where depression is argued to reflect the emotional response to suffering as well as a part of the neurodegenerative process itself. There is a close and perhaps causal relationship between cerebellar ataxia and depression in ataxia (200). However, as found in a recent study by Lo, after accounting for ataxia severity, depressive symptoms still have a significant negative impact on health outcomes (201). This opens the possibility that quality of life of patients suffering from ataxia and emotional

disturbances will improve with treatment of cognitive and psychiatric disorders such as medication, cognitive rehabilitation, psychological counseling and environmental interventions. As it has been found for motor functions, motor performance improves with continuous and intensive motor training (202). By analogy, intensive training of emotional performance might ameliorate deficits of perceiving and handling emotional cues.

In relation to the topographic mapping of cerebellar functions in emotions, Habas describes cerebellar involvement in the experience of emotion and in the executive, autonomic, cognitive and behavioral dimensions of emotion. He assigns a principal role to the vermis in specific domains of emotional processing, representing a “medial limbic” part of the cerebellum. This is linked to salient emotional networks in the cerebral regions (insula, anterior cingulate, medial prefrontal cortex, amygdala). A more lateral “limbic” area encompassed by the posterior cerebellar hemispheres represents the cerebellar executive networks, responsible for cognitive aspects such as attentional allocation or response selection. In addition, intra-cerebellar connections especially of the dentate nucleus with its connections to key cerebral regions, and crus I and II might be of further relevance to cerebellar contributions to emotion.

Considered from an evolutionary or phylogenetic point of view, the cerebellar regions contributing to emotion have been divided successively into archi- and neocerebellum. In this schema, the phylogenetically early differentiation of the cerebellum forming the archicerebellum (vestibulocerebellum) contains the fastigial nucleus, the vermis and intermediate parts of the cerebellar hemispheres, with respective fiber connections to cerebral areas such as the amygdala, hippocampus, temporal lobe, hypothalamus, septal nuclei, nucleus accumbens, and substantia nigra (203-205). The archicerebellar structures are assumed to code the perception, recognition and forwarding of emotional cues to the mentioned cerebral and adjacent subcortical areas. The neocerebellum, comprising the lateral parts of the cerebellar hemispheres (consisting of lobule VI, lobule VII including Crus I and II, lobule VIII B), is ascribed functions relating to co-evolution with later developments of the brain, namely cognitive and associative functions of the cerebral cortex, in particular, regions of the prefrontal cortex. Indeed, neuroimaging analysis indicate a map distribution for associative learning in the cerebellum with a medial-to-lateral cerebellar contribution

along emotional, motor, and cognitive functions. According to this pattern of distribution of cerebellar functions, the cerebellum has been assumed to be coupled to nonmotor functions paralleling the evolutionary development of the large nonmotor portions of the cerebellum, prefrontal, and association cortices, which is consistent with a phylogenetic expansion in size of the cerebellum parallel to the growth of the frontal cortex (206,207), and therefore to represent a behavioral variable of brain evolution (208).

At the microscopic level, each part of the cerebellar cortex is comprised of the same small set of neuronal elements constituted predominately by Purkinje cells, mossy and climbing fibers, and granular cells, laid out according to a highly uniform and stereotyped geometry. Furthermore, at an intermediate level, the cerebellum can be broken down into several hundred or thousand microzones or microcompartments presumably representing cerebellar functional units, with a further grouping into zones and multizonal microcomplexes suggesting functional modules with a very similar if not identical structure (206). According to Schmahmann, the architecture of the cortinuclear microcomplexes subserves a computational function unique to the cerebellum, termed the universal cerebellar transform (UCT). Schmahmann proposes that this universal cerebellar transform represents the fashion in which the cerebellum integrates internal representations with external stimuli and self generated responses in an implicit and non-conscious manner. This mechanism serves as an oscillations dampener which optimizes performance according to context (205). In this model, the cerebellum also processes emotions in this universal transformation mode. Future research might disentangle the particularities of distinct domains of emotion processing by the cerebellum. That is, clarifying to what extent the anatomic signatures of each of the cerebellar regions, in particular vermal versus more lateral regions, are unique, or share specific neural substrates (205). Furthermore, the finer details of the organization of cerebellar architecture would be of interest in interpreting the intriguing evidence that certain circuits, and therefore certain zones, may be more affected in some diseases than in others (209).

Based on this compilation of expert opinions and the relevant literature, consensus exists regarding the fundamental role of the vermal structures in emotion processing (overview of consensus see table 2). The vermis has been repeatedly reported in diverse studies as the key hub serving the perceiving and forwarding of

emotional cues within the cortical-subcortical networks of emotion. On the basis of a range of observations, the adjacent parts of the cerebellar hemispheres have been argued to be involved in certain stages of emotion processing. This might suggest that further intracerebellar pathways contribute to cerebral emotional functioning, forming part of large-scaled networks subserving emotional recognition and behavior. Research into the more differentiated dorsolateral and medial prefrontal regions with their connections to primary and associative temporal and parietal cortices including the amygdala, the auditory cortex and the extrastriate visual areas is still in progress. The extent to which these areas provide cognitive support to other areas involved in emotion processing or are directly involved is not resolved yet. Therefore, as outlined by the authors of this consensus paper, these cerebral regions are of strong interest with respect to their functional connections to the cerebellum. Summarising the statements of the contributing authors, each contribution suggests a specific impact of the cerebellum on emotional processing. These findings have pointed to distinct and well delineated cortical-subcortical networks. As noted by most authors, the cerebellum has been found to be predominately involved in processing negative contents, in particular cues of fear and anger. This may reflect one of the cerebellum's key roles handling strong incoming stimuli that are predictive of a change in emotional demands or context, necessitating the rapid synchronization of emotional information strands to optimize responses.

-----please insert table 2 here-----

With respect to the consensus on cerebellar contributions to emotions, some critical issues remain unanswered and might be subject to further research (overview of warranted research options see also table 2). Leggio and Molinari reported differences in cerebellar processing of implicit and explicit emotional perception. It would be of considerable interest to localise the different pathways and neurophysiology that subserve this specialization of explicit emotional perception. Following D'Agata, Adamaszek and Orsi's summary, further investigation of the role of the fronto-thalamo-cerebellar axis in forwarding and integrating emotional information in various forms of social cognition might be of particular interest. This might help to

clarify the specificity of each cerebellar contribution to the broad spectrum of high order emotional networks, as is relevant in developmental disorders such as ASD and probably schizophrenia. Sacchetti's emphasis on the vermis in processing emotional memory traces warrants ongoing research into more details of the assumed interface function of the cerebellum, relaying incoming emotional signals to the responsible cortical-subcortical networks. More research is needed to identify the cerebellar connections to cerebral areas such as the amygdala, hypothalamus, and also the dorsolateral and medial prefrontal cortex, recognised as guiding emotional learning and regulation. In accordance with the outlined association with formation of fear-related memories and congruent with the appraisal of emotional perception by Leggio and Molinari, one interesting issue might be to investigate the differences between implicit and explicit emotional memory. Another key question is whether general mechanisms of the cerebellum are sufficient to explain its role in emotion processing. To date, candidate mechanisms include a binary form of error detection or a simple differentiation between positive or negative emotions. In a similar vein, Styliadis recently demonstrated for specific time periods and topographical locations within the cerebellum at least two different processing channels encoding valence and arousal characteristics of emotion (137). Further research will likely further our understanding of the details of cerebellar mechanisms for emotional processing, in particular cerebellar activity in general versus specific modes in discrete emotional domains.

Another point requiring further research is the viewpoint of Keulen, Verhoeven, Van Overwalle and Mariën that the cerebellum regulates the fine grained timing that underpins emotional speech prosody. Research on the emotional components of aurally versus visually coded linguistic information would be of particular interest. This may assist in demarcating the cerebellar contribution to cerebral networks that integrate emotional information in linguistic networks. Additionally, the assumed impact of cerebellar damage on verbal working memory (and the associated control of linguistic and behavioral execution depending on emotional valence), might disclose further evidence of specific dependencies of the internal cerebellar modes on verbal working memory. Indeed, the activity increase of the right inferior and superior cerebellum that accompanies phonological encoding and storage components of verbal working memory (196) emphasizes the importance of further unravelling the precise timing mechanisms and topographical characteristics of the cerebellum when processing

emotionally distinct linguistic information.

The distinction between medial and more lateral limbic areas within the cerebellum proposed by Habas needs further clarification, especially, regarding the lateral parts of the cerebellum and their embedding in executive networks. This may clarify a role for the cerebellum in cognitive aspects to emotion. In accordance with the summary by Adamaszek and Kirkby, further neurophysiological research guided by specific ERP protocols may add to our understanding of cerebellar involvement in early and late processing stages of emotional perception and recognition, as well as in influencing cognitive domains. Moreover, specially designed ERP protocols may provide further information about the topography of specific cerebellar locations and their involvement in domain specific networks of emotional processing. Further, topographical research may inform our understanding of neuropsychiatric implications of cerebellar disease. Schutter raises questions about cerebellar-cerebral connectivity and the interpretation of functional decoupling mechanisms in cerebral areas such as to the caudate nucleus, amygdala and hypothalamus. These findings suggest that disturbed cerebello-cortico-limbic circuits are a significant factor in mood disorders, a subject for further research.

The advent of new devices, especially non-invasive technologies such as tDCS that target discrete areas of the cerebellum, has important implications for the field. Stimulation can be tuned to facilitate or inhibit activity of a given brain area. This permits the probing of cerebellar pathways. An obvious line of research is to further refine our knowledge of the topography and connectivity of cerebellar regions associated with emotion processing, as discussed by Ferrucci and Priori. This will likely clarify the contribution of the cerebellum to the larger scale cerebral networks that handle emotional recognition, evaluation and expression. However, the prospect of therapeutic manipulation of target areas of the cerebellum also arises. This is particularly germane given the key role of the cerebellum in processing negative emotional content. Given the increasing knowledge about optimal parameters of transcranial stimulation of brain areas implicated in mood disorders, future research with cerebellar tDCS may open the way to therapeutic interventions for emotional deficits or attentional impairments in patients with cerebellar disorders. Specific neuropharmacological agents such as serotonin-selective reuptake inhibitors, 5-hydroxytryptamine-agonists or amantadine, which enhanced cerebellar signals, may

also prove of interest in clinical studies on therapeutic approaches to cerebellar induced disturbances of emotion.

As a preliminary conclusion, the traditional view of the cerebellum being primarily involved in motor-related processes has fundamentally shifted based on the results of several decades of neuroscience research. evidence. In addition to its recently acknowledged role in cognition, there is compelling evidence that the cerebellum plays a crucial role in a wide variety of processes associated with emotion and emotion-related disorders. This evidence has converged from a number of perspectives. A key agenda for future research is to further delineate and disambiguate the neural mechanisms by which the cerebellum contributes to the processing of emotion. Further progress in the field of cerebellum research will contribute to achieve a better understanding of the neurobiological substrates of emotion.

References

1. Schmahmann JD, Sherman JC. The cerebellar cognitive affective syndrome. *Brain* 1998; 121:561-579
2. Baumann O, Borra RJ, Bower JM, Cullen KE, Habas C, Ivry RB et al. Consensus paper: the role of the cerebellum in perceptual processes. *Cerebellum* 2015; 14(2):197-220.
3. Molinari M, Chiricozzi F, Clausi S, Tedesco A, De Lisa M, Leggio M. Cerebellum and detection of sequences, from perception to cognition. *Cerebellum* 2008; 7:611- 5.
4. Roth MJ, Synofzik M, Lindner A. The cerebellum optimizes perceptual predictions about external sensory events. *Curr Biol* 2013;23:930-5.
5. Shobe ER. Independent and Collaborative Contributions of the Cerebral Hemispheres to Emotional Processing. *Front Hum Neurosci* 2014; 22(8):230.

6. Scheuerecker J, Frodl T, Koutsouleris N, Zetsche T, Wiesmann M, Kleemann AM et al. Cerebral differences in explicit and implicit emotional processing--an fMRI study. *Neuropsychobiology* 2007; 56(1):32-9.
7. Stoodley CJ, Schmahmann JD. Functional topography in the human cerebellum: a meta-analysis of neuroimaging studies. *Neuroimage* 2009;44(2):489-501.
8. Stoodley CJ, Schmahmann JD. Evidence for topographic organization in the cerebellum of motor control versus cognitive and affective processing. *Cortex* 2010;46(7):831-44.
9. Baumann O, Mattingley JB. Functional topography of primary emotion processing in the human cerebellum. *Neuroimage* 2012; 61:805-11.
10. Turner BM, Paradiso S, Marvel CL, Pierson R, Boles Ponto RR, Hichwa RD et al. The cerebellum and emotional experience. *Neuropsychologia* 2007; 45:1331-41.
11. Park JY, Gu BM, Kang DH, Shin YW, Choi CH, Lee JM, et al. Integration of cross-modal emotional information in the human brain: An fMRI study. *Cortex* 2008; 46(2):161-9.
12. Ferrucci R, Giannicola G, Rosa M, Fumagalli M, Boggio PS, Hallett M, Zago S, Priori A. Cerebellum and processing of negative facial emotions: cerebellar transcranial DC stimulation specifically enhances the emotional recognition of facial anger and sadness. *Cogn Emot* 2012; 26(5):786-99.
13. Schutter DJ, Enter D, Hoppenbrouwers SS. High-frequency repetitive transcranial magnetic stimulation to the cerebellum and implicit processing of happy facial expressions. *J Psychiatry Neurosci* 2009; 34(1):60-5.
14. Lupo M, Troisi E, Chiricozzi FR, Clausi S, Molinari M, Leggio M. Inability to Process Negative Emotions in Cerebellar Damage: a Functional Transcranial Doppler Sonographic Study. *Cerebellum* 2015 [Epub ahead of print].

15. Troisi E, Silvestrini M, Matteis M, Monaldo BC, Vernieri F, Caltagirone C. Emotion-related cerebral asymmetry: hemodynamics measured by functional ultrasound. *J Neurol* 1999; 246(12):1172-6.
16. Coricelli G, Crichley H D, Joffily, M, O'Doherty J P, Sirigu A, Dolan R J. Regret and its avoidance: a neuroimaging study of choice behavior. *Nat. Neurosci* 2005; 8:1255-62.
17. Coricelli G, Dolan J R, Sirigu A. Brain, emotion and decision making: the paradigmatic example of regret. *Trends Cogn Sci* 2007; 11:258-65
18. Clausi S, Coricelli G, Pisotta I, Pavone EF, Lauriola M, Molinari M, Leggio M. Cerebellar damage impairs the self-rating of regret feeling in a gambling task. *Front Behav Neurosci* 2015; 9:113.
19. Clausi S, Aloise F, Contento MP, Pizzamiglio L, Molinari M, Leggio M. Monitoring mood states in everyday life: a new device for patients with cerebellar ataxia. *Psychiatry Res* 2014; 220(1-2):719-21.
20. Schmahmann JD, Weilburg JB, Sherman JC. The neuropsychiatry of the cerebellum – insights from the clinic. *Cerebellum* 2007; 6(3):254–67.
21. Annoni JM, Ptak R, Caldara-Schnetzler AS, Khateb A, Zei Pollermann B. (2003). Decoupling of Autonomic and Cognitive emotional Reactions after Cerebellar Stroke. *Ann. Neurol* 2003;53:654-8.
22. Villanueva R. The cerebellum and neuropsychiatric disorders. *Psychiatry Res.* 2012;198(3):527-32.
23. D'Angelo E, Casali S. Seeking a unified framework for cerebellar function and dysfunction: from circuit operations to cognition. *Front Neural* 2013; 6:1-23.
24. Paquette S, Mignault Goulet G, Rothermich K. Prediction, Attention and Unconscious Processing in Hierarchical Auditory Perception. *Frontiers in Psychology.* 2013;4:955-6.

25. Braitenberg V, Heck D, Sultan F The detection and generation of sequences as a key to cerebellar function: experiments and theory. *Behav Brain Sci.* 1997;20:229–77.
26. Ito M. 2008. Control of mental activities by internal models in the cerebellum. *Nat Rev Neurosci.* 9:304-13
27. Leggio M. and Molinari M. Cerebellar Sequencing: a Trick for Predicting the Future. *Cerebellum.*, 14(1), 35-38, 2015
28. Blakemore SJ, Smith JS, Steel R, Johnstone EC, Frith CD. The perception of self-produced sensory stimuli in patients with auditory hallucinations and passivity experiences: evidence for breakdown in self-monitoring. *Psychol. Med* 2000; 30:1131-9.
29. Molinari M, Restuccia D, Leggio MG. State estimation, response prediction, and cerebellar sensory processing for behavioral control. *Cerebellum* 2009; 8:399-402.
30. Keysers C, Gazzola V. Integrating simulation and theory of mind: from self to social cognition. *Trends Cogn Sci* 2007; 11:194–6. doi:10.1016/j.tics.2007.02.002.
31. Balsters JH, Whelan CD, Robertson IH, Ramnani N. Cerebellum and cognition: Evidence for the encoding of higher order rules. *Cereb Cortex* 2013; 23:1433–43. doi:10.1093/cercor/bhs127.
32. Baetens K, Ma N, Steen J, Van Overwalle F. Involvement of the mentalizing network in social and non social high construal. *Soc Cogn Affect Neurosci* 2014; 9:817–24. doi:10.1093/scan/nst048.
33. Gordon I, Eilbott J a, Feldman R, Pelphrey K a, Vander Wyk BC. Social, reward, and attention brain networks are involved when online bids for joint attention are met with congruent versus incongruent responses. *Soc Neurosci* 2013; 8:544–54. doi:10.1080/17470919.2013.832374.

34. Aue T. I feel good whether my friends win or my foes lose: brain mechanisms underlying feeling similarity. *Neuropsychologia* 2014; 60:159–67.
35. Gazzola V, Keysers C. The observation and execution of actions share motor and somatosensory voxels in all tested subjects: Single-subject analyses of unsmoothed fMRI data. *Cereb Cortex* 2009; 19:1239–55. doi:10.1093/cercor/bhn181.
36. Schraa-Tam CKL, Rietdijk WJR, Verbeke WJMI, Dietvorst RC, Van Den Berg WE, Bagozzi RP, et al. fMRI activities in the emotional cerebellum: A preference for negative stimuli and goal-directed behavior. *Cerebellum* 2012; 11:233–45. doi:10.1007/s12311-011-0301-2.
37. Rocchetti M, Radua J, Paloyelis Y, Xenaki LA, Frascarelli M, Caverzasi E, et al. Neurofunctional maps of the “maternal brain” and the effects of oxytocin: A multimodal voxel-based meta-analysis. *Psychiatry Clin Neurosci* 2014. doi:10.1111/pcn.12185.
38. Van Overwalle F, Baetens K, Mariën P, Vandekerckhove M. Social cognition and the cerebellum: A meta-analysis of over 350 fMRI studies. *Neuroimage* 2014; 86:554–72. doi:10.1016/j.neuroimage.2013.09.033.
39. Kanai R, Bahrami B, Roylance R, Rees G. Online social network size is reflected in human brain structure. *Proc R Soc B Biol Sci* 2012;279: 1327–34. doi:10.1098/rspb.2011.1959.
40. Zink CF, Tong Y, Chen Q, Bassett DS, Stein JL, Meyer-Lindenberg A. Know Your Place: Neural Processing of Social Hierarchy in Humans. *Neuron* 2008; 58:273–83. doi:10.1016/j.neuron.2008.01.025.
41. Sallet J, Mars RB, Noonan MP, Andersson JL, O’Reilly JX, Jbabdi S, et al. Social Network Size Affects Neural Circuits in Macaques. *Science* 2011; 334:697–700. doi:10.1126/science.1210027.

42. Noonan MP, Sallet J, Mars RB, Neubert FX, O'Reilly JX, Andersson JL, et al. A neural circuit covarying with social hierarchy in macaques. *PLoS Biol* 2014;12:e1001940. doi:10.1371/journal.pbio.1001940.
43. Adamaszek M, D'Agata F, Kirkby KC, Trenner MU, Sehm B, Steele CJ, et al. Impairment of emotional facial expression and prosody discrimination due to ischemic cerebellar lesions. *Cerebellum* 2014;13:338–45. doi:10.1007/s12311-013-0537-0.
44. D'Agata F, Caroppo P, Baudino B, Caglio M, Croce M, Bergui M, et al. The recognition of facial emotions in spinocerebellar ataxia patients. *Cerebellum* 2011;10:600–10. doi:10.1007/s12311-011-0276-z.
45. Sokolovsky N, Cook A, Hunt H, Giunti P, Cipolotti L. A preliminary characterisation of cognition and social cognition in spinocerebellar ataxia types 2, 1, and 7. *Behav Neurol* 2010;23:17–29. doi:10.3233/BEN-2010-0270.
46. Harenski CL, Harenski KA, Shane MS, Kiehl KA. Aberrant neural processing of moral violations in criminal psychopaths. *J Abnorm Psychol*, 2010;119:863-874. doi: 10.1037/a0020979.
47. Moll J, de Oliveira-Souza R, Garrido GJ, Bramati IE, Caparelli-Daquer EMA, Paiva ML, Zahn R, Grafman J. The self as a moral agent: Linking the neural bases of social agency and moral sensitivity. *Soc Neurosci* 2007;2:336-352. doi: 10.1080/17470910701392024.
48. Harenski CL, Antonenko O, Shane MS, Kiehl KA. Gender differences in neural mechanisms underlying moral sensibility. *Soc Cogn Affect Neurosci* 2008;3:313-321. doi: 10.1093/scan/nsn026.
49. Reniers RL, Corcoran R, Vollm BA, Mashru A, Howard R, Liddle PF. Moral decision-making, ToM, empathy and the default mode network. *Biol Psychol* 2012;90:202-210. doi:10.1016/j.biopsycho.2012.03.009.

50. Han H, Chen J, Jeong C, Glover GH. Influence of the cortical midline structures on moral emotion and motivation in moral decision-making. *Behav Brain Res* 2016;302:237-251. doi: 10.1016/j.bbr.2016.01.001.
51. Yeganeh-Doost P, Gruber O, Falkai P, Schmitt A. The role of the cerebellum in schizophrenia: from cognition to molecular pathways. *Clinics* 2011;66:71-7. doi:10.1590/S1807-59322011001300009.
52. Mothersill O, Knee-Zaska C, Donohoe G. Emotion and Theory of Mind in Schizophrenia-Investigating the Role of the Cerebellum. *Cerebellum* 2015. doi:10.1007/s12311-015-0696-2.
53. Tsai PT, Hull C, Chu Y, Greene-Colozzi E, Sadowski AR, Leech JM, et al. Autistic-like behaviour and cerebellar dysfunction in Purkinje cell Tsc1 mutant mice. *Nature* 2012;488:647-51. doi:10.1038/nature11310.
54. Wang SSH, Kloth AD, Badura A. The Cerebellum, Sensitive Periods, and Autism. *Neuron* 2014;83:518-32. doi:10.1016/j.neuron.2014.07.016.
55. Sinha P, Kjelgaard MM, Gandhi TK, Tsourides K, Cardinaux AL, Pantazis D, et al. Autism as a disorder of prediction. *Proc Natl Acad Sci U S A* 2014;111:15220-5. doi:10.1073/pnas.1416797111.
56. Balsters JH, Cussans E, Diedrichsen J, Phillips KA, Preuss TM, Rilling JK, et al. Evolution of the cerebellar cortex: The selective expansion of prefrontal-projecting cerebellar lobules. *Neuroimage* 2010;49:2045-52. doi:10.1016/j.neuroimage.2009.10.045.
57. Ramnani N, Behrens TEJ, Johansen-Berg H, Richter MC, Pinsk MA, Andersson JLR, et al. The evolution of prefrontal inputs to the cortico-pontine system: Diffusion imaging evidence from macaque monkeys and humans. *Cereb Cortex* 2006;16:811-8. doi:10.1093/cercor/bhj024.

58. Barton RA. Embodied cognitive evolution and the cerebellum. *Philos Trans R Soc B Biol Sci* 2012;367:2097–107. doi:10.1098/rstb.2012.0112.
59. Dunbar RIM, Shultz S. Evolution in the social brain. *Science* 2007;317:1344–7. doi:10.1126/science.1145463.
60. Ekman, P. Facial expressions of emotion: an old controversy and new findings. *Philos Trans R Soc Lond B Biol Sci* 1992;335(1273): 63-69.
61. Izard, C. E. Innate and universal facial expressions: evidence from developmental and cross-cultural research. *Psychol Bull* 1994;115(2): 288-299.
62. Heath, R. G., Dempsey, C. W., Fontana, C. J., & Myers, W. A. Cerebellar stimulation: effects on septal region, hippocampus, and amygdala of cats and rats. *Biol Psychiatry* 1978;13(5): 501-529.
63. Nashold, B. S., Jr., & Slaughter, D. G. Effects of stimulating or destroying the deep cerebellar regions in man. *J Neurosurg* 1969;31(2): 172-186.
64. Ferrucci, R., Giannicola, G., Rosa, M., Fumagalli, M., Boggio, P. S., Hallett, M. Cerebellum and processing of negative facial emotions: cerebellar transcranial DC stimulation specifically enhances the emotional recognition of facial anger and sadness. *Cogn Emot* 2011;26(5): 786-799.
65. Ferrucci, R., Cortese, F., & Priori, A. Cerebellar tDCS: how to do it. *Cerebellum* 2014; 14(1): 27-30.
66. Ferrucci, R., & Priori, A. Transcranial cerebellar direct current stimulation (tcDCS): motor control, cognition, learning and emotions. *Neuroimage* 2014; 85 Pt 3: 918-923.
67. Grimaldi, G., Argyropoulos, G. P., Boehringer, A., Celnik, P., Edwards, M. J., Ferrucci, R. Non-invasive cerebellar stimulation--a consensus paper. *Cerebellum* 2014;13(1): 121-138.

68. Dempsey, C. W., Tootle, D. M., Fontana, C. J., Fitzjarrell, A. T., Garey, R. E., & Heath, R. G. Stimulation of the paleocerebellar cortex of the cat: increased rate of synthesis and release of catecholamines at limbic sites. *Biol Psychiatry* 1983; 18(1): 127-132.
69. Marcinkiewicz, M., Morcos, R., & Chretien, M. CNS connections with the median raphe nucleus: retrograde tracing with WGA-apoHRP-Gold complex in the rat. *J Comp Neurol* 1989 ; 289(1): 11-35.
70. Fox, E., Lester, V., Russo, R., Bowles, R. J., Pichler, A., & Dutton, K. Facial Expressions of Emotion: Are Angry Faces Detected More Efficiently? *Cogn Emot* 2000;14(1): 61-92.
71. Morewedge, C. K. Negativity bias in attribution of external agency. *J Exp Psychol Gen* 2009; 138(4): 535-545.
72. Siegel, A., Roeling, T. A., Gregg, T. R., & Kruk, M. R. Neuropharmacology of brain-stimulation-evoked aggression. *Neurosci Biobehav Rev* 1999; 23(3): 359-389.
73. Supple WF, Kapp BS. The anterior cerebellar vermis: essential involvement in classically conditioned bradycardia in the rabbit. *J Neurosci* 1993;13:3705-3711.
74. Supple WF, Leaton RN. Lesions of the cerebellar vermis and cerebellar hemispheres: effects on heart rate conditioning in rats. *Behav Neurosci* 1990; 104:934-947.
75. Sacchetti B, Baldi E, Lorenzini CA, Bucherelli C. Cerebellar role in fear-conditioning consolidation. *Proc Natl Acad Sci USA* 2002; 99:8406-8411.
76. Sacchetti B, Scelfo B, Strata P. Cerebellum and emotional behavior. *Neuroscience* 2009; 162:756-762.
77. Sacchetti B, Sacco T, Strata P. Reversible inactivation of amygdala, cerebellum, but not perirhinal cortex, impairs reactivated fear memories. *Eur J Neurosci* 2007; 25: 2875-2884.

78. Ruediger S, Vittori C, Bednarek E, Genoud C, Strata P, Sacchetti B, Caroni P. Learning-related feedforward inhibitory connectivity growth required for memory precision. *Nature* 2011; 473:514-518.
79. Koutsikou S, Crook JJ, Earl EV, Leith JL, Watson TC, Lumb BM, Apps R. Neural substrates underlying fear-evoked freezing: the periaqueductal grey-cerebellar link. *J Physiol* 2014; 15: 592:2197-213.
80. Gianlorenço AC, Riboldi AM, Silva-Marques B, Mattioli R. Cerebellar vermis H₂ receptors mediate fear memory consolidation in mice. *Neurosci Lett* 2015; 5:57-61.
81. Ploghaus A, Tracey I, Gati JS, Clare S, Menon RS, Matthews PM, Rawlins JN. Dissociating pain from its anticipation in the human brain. *Science* 1999; 284:1979-1981.
82. Labrenz F, Icenhour A, Thürling M, Schlamann M, Forsting M, Timmann D, Elsenbruch S. Sex differences in cerebellar mechanisms involved in pain-related safety learning. *Neurobiol Learn Mem* 2015;123: 92-9.
83. Utz A, Thürling M, Ernst TM, Hermann A, Stark R, Wolf OT, Timmann D, Merz CJ. Cerebellar vermis contributes to the extinction of conditioned fear. *Neurosci Lett* 2015; 604: 173-177.
84. Zhu L, Scelfo B, Hartell NA, Strata P, Sacchetti B. The effects of fear conditioning on cerebellar LTP and LTD. *Eur J Neurosci* 2007; 26:219-227.
85. Scelfo B, Sacchetti B, Strata P. Learning-related long-term potentiation of inhibitory synapses in the cerebellar cortex. *Proc Natl Acad Sci USA* 2008; 105:769-774.
86. Zhu L, Sacco T, Strata P, Sacchetti B. Basolateral amygdala inactivation impairs learning-induced long-term potentiation in the cerebellar cortex. *PLoS One* 2011; 6:e16673.
87. Snider RS and Maiti A. Cerebellar contributions to the Papez Circuit. *J Neurosci Res* 1976; 2 (2): 133-46.

88. Watson TC, Koutsikou S, Cerminara NL, Flavell CR, Crook JJ, Lumb BM, Apps R. The olivo-cerebellar system and its relationship to survival circuits. *Front Neural Circuits* 2013; 7:72.
89. Grosso A, Cambiaghi M, Renna A, Milano L, Merlo GR, Sacco T, Sacchetti B. The higher-order auditory cortex is involved in the assignment of affective value to sensory stimuli. *Nat Commun* 2015a; 6:8886. doi: 10.1038/ncomms9886.
90. Sacco T, Sacchetti B. Role of secondary sensory cortices in emotional memory storage and retrieval in rats. *Science* 2010; 329:649-656.
91. Grosso A, Cambiaghi M, Concina G, Sacco T, Sacchetti B. Auditory cortex involvement in emotional learning and memory. *Neuroscience* 2015b; 299: 45-55.
92. Azizi SA, Burne RA, Woodward DJ. The auditory corticopontocerebellar projection in the rat, inputs to the paraflocculus and midvermis: An anatomical and physiological study. *Exp Brain Res* 1985; 59:36-49.
93. O'Reilly JX, Beckmann CF, Tomassini V, Ramnani N, Johansen-Berg H. Distinct and overlapping functional zones in the cerebellum defined by resting state functional connectivity. *Cerebra Cortex* 2009; 20: 953-965
94. Habas C, Kamdar N, Nguyen D, Prater K, Beckmann CF, Menon V, Greicius MD. Distinct cerebellar contributions to intrinsic connectivity networks. *J Neurosci* 2009; 29: 8586-8594
95. Schutter DJLG, Honk JV. The cerebellum on the rise in human emotion. *Cerebellum* 2005; 4: 290-294
96. Moriguchi Y, Decety J, Ohnishi T, Maeda M, Mori T, Nemoto K, Matsuda H, Komaki G. Empathy and judging other's pain: an fMRI study of alexithymia. *Cereb Cortex* 2007; 17: 2223-2234
97. Lane DJ, Reiman EM, Ahern GL, Schwartz GE, Davidson RJ. Neuroanatomical correlates of happiness, sadness, and disgust. *Am J Psychiatry* 1997; 154: 926-933

98. Parsons LM, Fox PT, Downs JH, Glass T, Hirsch TB, Martin CC, Jerabek PA, Lancaster JL. Neuroimaging evidence implicating the cerebellum in support of sensory/cognitive associated with thirst. PNAS 2000; 97: 2332-2336

99. Moulton EA , Schmahmann J, Beccerra L, Borsook D. The cerebellum and pain: passive integrator or active participator? Brain Res Rev 2010; 65: 14-27

100. Moulton EA , Elman I, Pendse G, Schmahmann J, Beccerra L, Borsook D. Aversion-related circuitry in the cerebellum: responses to noxious heat and unpleasant images. J Neurosci 2011; 31: 3795-3804

101. Helmchen C, Mohr C, Erdmann C, Petersen D, Nitschke MF. Differential cerebellar activation related to perceived pain intensity during noxious thermal stimulation in humans: a functional magnetic resonance imaging study. Neurosci Lett 2003; 335: 202-206

102. Keren-Happuch E, Chen S-H A, Ho M-HR , Desmond JE. A meta-analysis of cerebellar contributions to higher cognition from PET and fMRI studies. Hum Brain Mapp 2014; 32: 593-615

103 Fusar-Poli P, Placentino A, Carletti F, Landi P, Allen P, Surguladze S, Benedetti F, Abbamonte M, Gasparotti R, Barale F, Perez J, McGuire P, Politi P. Functional atlas of emotional faces processing: a voxel-based meta-analysis of 105 functional magnetic resonance imaging studies. J Psychiatry Neurosci 2009; 34: 418-432

104. Seeley WW, Menon V, Schatzberg AF, Keller J, Glover GH, Kenna H, Reiss AL, Greicius MD. Dissociable intrinsic connectivity networks for salience processing and executive control. J Neurosci 2007; 27: 2349-2356

105. Sang L, qin W, Liu Y, Zhang Y, Jiang T, Yu C. resting-state functional connectivity of the vermal and hemispheric subregions of the cerebellum with both the cerebral cortical networks and subcortical structures. NeuroImage 2012; 61: 1213-1225

106. Roy AK, Shehzad Z, Margulies DS, Kelly AMC, Uddin LQ, Gotimer K, Biswal BB, Castellanos FX, Milham MP. Functional connectivity of the human amygdala using resting-state fMRI. *NeuroImage* 2009; 45: 614-626

107. Allen G, McColl R, Barnard H, Ringe WK, Fleckenstein J, Cullum CM. Magnetic resonance imaging of cerebellar-prefrontal and cerebellar-parietal functional connectivity. *NeuroImage* 2005; 28: 39-48

108. Nisimaru N. Cardiovascular models of the cerebellum. *J Physiol Sci (Jpn J Physiol)* 2004; 54: 431-48

109. Maschke M, Schugens M, Kindsvater K, Kolb FP, Diener HC, Timmann D. Fear conditioned changes of heart rate in patients with medial cerebellar lesions. *J Neurol Neurosurg Psychiatry* 2002; 72(1): 116-18

110. Blood JD, Wu J, Chaplin TM, Hommer R, Vasquez L, et al. The variability heart: high frequency and very low frequency correlates of depressive symptoms in children and adolescents. *J Affect Disord* 2015; 186: 119-26

111. Annoni JM, Ptak R, Caldara-Schnetzer AS, Khateb A, Pollermann BZ. Decoupling of Autonomic and Cognitive Emotional Reactions after Cerebellar Stroke. *Ann Neurol* 2003; 53: 654-58

112. Lopiano L, de`Sperati C, Montarolo PG. Long-term habituation of the acoustic startle response: role of the cerebellar vermis. *Neuroscience* 1990; 35(1): 79-84

113. Maschke M, Drepper J, Kindsvater K, Kolb FP, Diener HC, Timmann D. Fear conditioned potentiation of the acoustic blink reflex in patients with cerebellar lesions. *J Neurol Neurosurg Psychiatry* 2000; 68(3): 358-64

114. Adamaszek M, Olbrich S, Kirkby KC, Woldag H, Heinrich A. Event-related potentials indicating impaired emotional attention in cerebellar stroke - a case study. *Neurosci Lett* 2013; 548: 206-11

115. Adamaszek M, Olbrich S, Kirkby KC, D'Agata F, Langner S, Steele CJ, Sehm B, Busse S, Kessler C, Hamm AO. Neural correlates of disturbed emotional face recognition in cerebellar lesions. *Brain Research* 2015; 1613: 1-12

116. Snow WM, Stoesz BM, Anderson JE. The Cerebellum in emotional processing: evidence from human and non-human animals. *AIMS Neuroscience* 2014; 1(1): 96-119

117. Ivry RB. Sensory Processing and the Cerebellum: Timing. In: Consensus Paper: The Role of the Cerebellum in perceptual processes. Baumann O, Borra RJ, Bower JM, et al. *Cerebellum* 2015; 14: 197-220

118. Keele SW, Ivry R. Does the cerebellum provide a common computation for diverse tasks? A timing hypothesis. *Ann N Y Acad Sci* 1990; 608: 179-207

119. Leggio MG, Chiricozzi FR, Clausi S, Tedesco AM, Molinari M. The neuropsychological profile of cerebellar damage: the sequencing hypothesis. *Cortex* 2011; 47: 137-44

120. Olofsson JK, Nordin S, Sequeira H, Polich J. Affective picture processing: an integrative review of ERP findings. *Biol Psychol* 2008; 77: 247-65

121. Tachibana H, Kawabata K, Tomino Y, Sugita M. Prolonged P3 latency and decreased brain perfusion in cerebellar degeneration. *Acta Neurol Scand* 1999; 100(5): 310-6

122. Rusiniak M, Lewandowska M, Wolak T, Pluta A, Milner R, Ganc M, Włodarczyk A, Senderski A, Sliwa L, Skarzynski H. A modified oddball paradigm for investigation of neural correlates of attention: a simultaneous ERP-fMRI study. *Magn Reson Mater Phy* 2013; 26: 511-526

123. Okon-Singer H, Hendler T, Pessoa L, Shackman AJ. The neurobiology of emotion-cognition interactions: fundamental questions and strategies for future research. *Front Human Neuroscience* 2015; 9:58. Doi: 10.3389/fnhum.2015.00058

124. Heath RG. Modulation of emotion with a brain pacemaker. Treatment for intractable psychiatric illness. *J Nerv Ment Dis* 1977; 165(5): 300-17
125. Saab CY and Willis WD. The cerebellum: organization, functions and its role in nociception. *Brain Res Rev* 2003; 42(1): 85-95
126. Ekerot CF, Garwicz M, Schouenborg J. The postsynaptic dorsal column pathway mediates cutaneous nociceptive information to cerebellar climbing fibres in the cat. *J Physiol* 1991; 441: 275-84.
127. Wu J and Chen PX. Discharge response of cerebellar Purkinje cells to stimulation of C-fiber in cat saphenous nerve. *Brain Res* 1992; 581(2): 269-72.
128. Apkarian AV, Bushnell MS, Treede RD, Zubieta JK. Human brain mechanisms of pain perception and regulation in health and disease. *Eur J Pain* 2005; 9(4): 463-84.
129. Schmahmann JD (1996) From movement to thought: anatomic substrates of the cerebellar contribution to cognitive processing. *Hum Brain Mapp* 1996; 4(3): 174-98
130. Cerminara NL, Koutsikou S, Lumb BM, Apps R. The periaqueductal grey modulates sensory input to the cerebellum: a role in coping behaviour? *Eur J Neurosci* 2009; 29(11): 2197-206.
131. Helmchen C, Mohr C, Erdmann C, Binkofski F. Cerebellar neural responses related to actively and passively applied noxious thermal stimulation in human subjects: a parametric fMRI study. *Neurosci Lett* 2004; 361(1-3): 237-40.
132. Borsook D, Moulton EA, Tully S, Schmahmann JD, Becerra L. Human cerebellar responses to brush and heat stimuli in healthy and neuropathic pain subjects. *Cerebellum* 2008; 7(3): 252-72.
133. Moulton EA, Elman I, Becerra LR, Goldstein RZ, Borsook D. The cerebellum and addiction: insights gained from neuroimaging research. *Addiction Biology* 2014; 19(3): 317-31.
134. Diano M, D'Agata F, Cauda F, Costa T, Geda E, Saco K, Duca S, Torta DM, Germiniani

GC. Cerebellar Clustering and Functional Connectivity During Pain Processing. *Cerebellum* 2015; 1: 1-14.

135. E KH, Chen SH, Ho MH, Desmond JE. A meta-analysis of cerebellar contributions to higher cognition from PET and fMRI studies. *Hum Brain Mapp* 2014; 35(2): 593-615.

136. Colibazzi T, Posner J, Wang Z, Gorman D, Gerber A, et al. Neural systems subserving valence and arousal during the experience of induced emotions. *Emotion* 2010; 10(3): 377-89.

137. Styliadis C, Ioannides AA, Bamidis PD, Papadelis C. Distinct cerebellar lobules process arousal, valence and their interaction in parallel following a temporal hierarchy. *Neuroimage* 2015; 110: 149-61.

138. Lang PJ, Bradley MM, Cuthbert BN. International affective picture system (IAPS): Technical manual and affective ratings. University of Florida, Center for Research in Psychophysiology 1999, Gainesville.

139. Diedrichsen J, Balsters JH, Flavell J, Cussans E, Ramnani N. A probabilistic atlas of the human cerebellum. *NeuroImage* 2009; 46: 39-46.

140. De Smet HJ, Paquier P, Verhoeven J, Mariën P. The cerebellum: its role in language and related cognitive and affective functions. *Brain Lang* 2013; 127: 334-42.

141. Schmahmann J. Disorders of the Cerebellum: Ataxia, Dysmetria of Thought, and the Cerebellar Cognitive Affective Syndrome. *J Neuropsych Clin N* 2004; 16: 367-78.

142. Beaton A, Mariën P. Language, cognition and the cerebellum: grappling with an enigma. *Cortex* 2010; 46: 811-20.

143. Van Overwalle F, Baetens K, Mariën P, Vandekerckhove M. Cerebellar areas dedicated to social cognition ? A comparison of meta-analytic and connectivity results. *Soc Neurosci* 2015; 10: 37-41.

144. Sidtis JJ, Van Lancker Sidtis DA. Neurobehavioral Approach to Dysprosody. *Seminars in Speech and Language* 2003; 24: 93-105.
145. Holmes G. The symptoms of acute cerebellar injuries due to gunshot injuries. *Brain* 1917; 40: 461–535.
146. Jackson JH. On affections of speech from diseases of the brain. *Brain* 1915; 38: 106-174.
147. Raithel V, Hielscher-Fastabend M. Emotional and Linguistic Perception of Prosody. *Reception of Prosody. Folia Phoniatr Logo* 2004; 56:7–13.
148. Wildgruber D, Ackermann H, Kreifelts B, Ethofer T. Cerebral processing of linguistic and emotional prosody: fMRI studies. *Prog Brain Res* 2006; 156: 249–268
149. Ross EE. The aprosodias: functional-anatomic organization of the affective components of language in the right hemisphere. *Arch Neurol* 1981; 38: 561-70.
150. Le Jeune F, Péron J, Biseul I, Fournier S, Sauleau P, Drapier S, Vérin M. Subthalamic nucleus stimulation affects orbitofrontal cortex in facial emotion recognition: A pet study. *Brain* 2008; 131: 1599–1608.
151. Chancelliere A, Kertesz A. Lesion localization in acquired deficits of emotional expression and comprehension. *Brain Cogn* 1990; 13: 133-47.
152. Van Lancker D, Sidtis JJ. The identification of affective-prosodic stimuli by left- and right-hemisphere-damaged subjects: all errors are not equal. *J Speech Hear Res* 1992; 35: 963-70.
153. Kotz SA, Meyer M, Alter K, Besson M, von Cramon Y, Friederici AD. On the lateralization of emotional prosody: An event-related functional MR investigation. *Brain Lang* 2003; 86: 366-76.

154. Mitchell RLC, Elliott R, Barry M, Cruttenden A, Woodruff PWR. The neural response to emotional prosody, as revealed by functional magnetic resonance imaging. *Neuropsychologia* 2003; 41: 1410-21.

155. Dapretto M, Hairiri A, Bialik M, Bookheimer S. Cortical correlates of affective vs. linguistic prosody: an fMRI study. *Neuroimage* 1999; 9: 1054.

156. Mayer J, Wildgruber D, Riecker A, Dogil G, Ackermann H, Godd W. Prosody Production and Perception: Converging Evidence from fMRI Studies, Proceedings from ISCA 2002: International Speech Communication Association: Speech Prosody 2002: 487-90.

157. Dogil G, Ackermann H, Grodd W, Haider H, Kamp H, Mayer J, Riecker A, Wildgruber D. The speaking brain: a tutorial introduction to fMRI experiments in the production of speech, prosody and syntax, *J Neurolinguist* 2002; 15: 59–90

158. Van Lancker D, Sidtis D, Pachana N, Cummings JL, Sidtis JJ. Dysprosodic speech following basal ganglia insult: toward a conceptual framework for the study of the cerebral representation of prosody. *Brain Lang* 2006; 97: 135-53.

159. Alba-Ferrara L, Hausmann M, Mitchell RL, Weis S. The Neural Correlates of Emotional Prosody Comprehension: Disentangling Simple from Complex Emotion. *PLoS One* 2011; Doi: 10.1371/journal.pone.0028701

160. Strelnikov K, Vorobyev VA, Chernigovskaya TV, and Medvedev SV. Prosodic clues to syntactic processing—a PET and ERP study. *Neuroimage* 2006; 29: 1127–34.

161. Pichon S, Kell CA. Affective and sensorimotor component of emotional prosody generation. *J. of Neuroscience* 2013; 33: 1640-50.

162. Krienen FM, Buckner RL. Segregated Fronto-Cerebellar Circuits Revealed by Intrinsic Functional Connectivity. *Cereb. Cortex* 2009; 19: 2485-97.

163. Alalade E, Denny K, Potter G, Steffens D, Wang L. Altered Cerebellar-Cerebral Functional Connectivity in Geriatric Depression. *PLoS One* 2011; Doi: 10.1371/journal.pone.0020035

164. Fatemi SH, Stary JM, Earle JA, Araghi-Niknam M, Eagan E. GABAergic dysfunction in schizophrenia and mood disorders as reflected by decreased levels of glutamic acid decarboxylase 65 and 67 kDa and Reelin proteins in cerebellum. *Schizophr Res* 2005; 72: 109-22.

165. Maloku E, Covelo IR, Hanbauer I, Guidotti A, Kadriu B, Hu Q, Davis JM, Costa E. Lower number of cerebellar Purkinje neurons in psychosis is associated with reduced reelin expression. *Proc Natl Acad Sci* 2010; 107: 4407-11.

166. Cecil KM, DelBello MP, Sellars MC, Strakowski SM. Proton magnetic resonance spectroscopy of the frontal lobe and cerebellar vermis in children with a mood disorder and a familial risk for bipolar disorders. *J Child Adolesc Psychopharmacol* 2003 ; 13: 545-55.

167. Singh MK, Spielman D, Libby A, Adams E, Acquaye T, Howe M, Kelley R, Reiss A, Chang KD. Neurochemical deficits in the cerebellar vermis in child offspring of parents with bipolar disorder. *Bipolar Disord* 2011; 13: 189-97.

168. Mills NP, Delbello MP, Adler CM, Strakowski SM. MRI analysis of cerebellar vermal abnormalities in bipolar disorder. *Am J Psychiatry* 2005; 162: 1530-2.

169. Monkul ES, Hatch JP, Sassi RB, Axelson D, Brambilla P, Nicoletti MA, Keshavan MS, Ryan ND, Birmaher B, Soares JC. MRI study of the cerebellum in young bipolar patients. *Prog Neuropsychopharmacol Biol Psychiatry* 2008 ; 32: 613-9.

170. Kim D, Cho HB, Dager SR, Yurgelun-Todd DA, Yoon S, Lee JH, Lee SH, Lee S, Renshaw PF, Lyoo IK. Posterior cerebellar vermal deficits in bipolar disorder. *J Affect Disord* 2013; 150: 499-506.

171. Baldaçara L, Nery-Fernandes F, Rocha M, Quarantini LC, Rocha GG, Guimarães JL, Araújo C, Oliveira I, Miranda-Scippa A, Jackowski A. Is cerebellar volume related to bipolar disorder? *J Affect Disord* 2011; 135: 305-9.

172. Moorhead TW, McKirdy J, Sussmann JE, Hall J, Lawrie SM, Johnstone EC, McIntosh AM. Progressive gray matter loss in patients with bipolar disorder. *Biol Psychiatry* 2007; 62: 894-900.

173. Adler CM, DelBello MP, Jarvis K, Levine A, Adams J, Strakowski SM. Voxel-based study of structural changes in first-episode patients with bipolar disorder. *Biol Psychiatry* 2007; 61: 776-81.

174. Eker C, Simsek F, Yilmazer EE, Kitis O, Cinar C, Eker OD, Coburn K, Gonul AS. Brain regions associated with risk and resistance for bipolar I disorder: a voxel-based MRI study of patients with bipolar disorder and their healthy siblings. *Bipolar Disord* 2014; 16: 249-61.

175. Frodl TS, Koutsouleris N, Bottlender R, Born C, Jäger M, Scupin I, Reiser M, Möller HJ, Meisenzahl EM. Depression-related variation in brain morphology over 3 year: effects of stress? *Arch Gen Psychiatry*. 2008;65:1156-65.

176. Peng J, Liu J, Nie B, Li Y, Shan B, Wang G, Li K. Cerebral and cerebellar gray matter reduction in first-episode patients with major depressive disorder: a voxel-based morphometry study. *Eur J Radiol*. 2011;80:395-9.

177. Schutter DJ, Koolschijn PC, Peper JS, Crone EA. The cerebellum link to neuroticism: a volumetric MRI association study in healthy volunteers. *PLoS One* 2012;7:e37252.

178. Mahon K, Wu J, Malhotra AK, Burdick KE, DeRosse P, Ardekani BA, Szeszko PR. A voxel-based diffusion tensor imaging study of white matter in bipolar disorder. *Neuropsychopharmacology* 2009;34:1590-600.

179. Abe O, Yamasue H, Kasai K, Yamada H, Aoki S, Inoue H, Takei K, Suga M, Matsuo K, Kato T, Masutani Y, Ohtomo K. Voxel-based analyses of gray/white matter volume and diffusion tensor data in major depression. *Psychiatry Res* 2010;181:64-70.

180. Guo W, Liu F, Liu J, Yu L, Zhang Z, Zhang J, Chen H, Xiao C. Is there a cerebellar compensatory effort in first-episode, treatment-naive major depressive disorder at rest? *Prog Neuropsychopharmacol Biol Psychiatry* 2013;46:13-8.

181. Fitzgerald PB, Laird AR, Maller J, Daskalakis ZJ. A meta-analytic study of changes in brain activation in depression. *Hum Brain Mapp* 2008;29:683-95.

182. Wang L, Li K, Zhang Q, Zeng Y, Dai W, Su Y, Wang G, Tan Y, Jin Z, Yu X, Si T. Short-term effects of escitalopram on regional brain function in first-episode drug-naive patients with major depressive disorder assessed by resting-state functional magnetic resonance imaging. *Psychol Med* 2014;44:1417-26.

183. Rapkin AJ, Berman SM, Mandelkern MA, Silverman DH, Morgan M, London ED. Neuroimaging evidence of cerebellar involvement in premenstrual dysphoric disorder. *Biol Psychiatry* 2011;69:374-80.

184. Zhang WN, Chang SH, Guo LY, Zhang KL, Wang J. The neural correlates of reward-related processing in major depressive disorder: a meta-analysis of functional magnetic resonance imaging studies. *J Affect Disord.* 2013;151:531-9.

185. Dotson VM, Beason-Held L, Kraut MA, Resnick SM. Longitudinal study of chronic depressive symptoms and regional cerebral blood flow in older men and women. *Int J Geriatr Psychiatry* 2009;24:809-19.

186. Liang MJ, Zhou Q, Yang KR, Yang XL, Fang J, Chen WL, Huang Z. Identify changes of brain regional homogeneity in bipolar disorder and unipolar depression using resting-state fMRI. *PLoS One* 2013;8:e79999.

187. Liu CH, Ma X, Wu X, Zhang Y, Zhou FC, Li F, Tie CL, Dong J, Wang YJ, Yang Z, Wang CY. Regional homogeneity of resting-state brain abnormalities in bipolar and unipolar depression. *Prog Neuropsychopharmacol Biol Psychiatry* 2013;41:52-9.
188. Guo W, Liu F, Xue Z, Gao K, Liu Z, Xiao C, Chen H, Zhao J. Abnormal resting-state cerebellar-cerebral functional connectivity in treatment-resistant depression and treatment sensitive depression. *Prog Neuropsychopharmacol Biol Psychiatry* 2013;44:51-7.
189. Peng HJ, Zheng HR, Ning YP, Zhang Y, Shan BC, Zhang L, Yang HC, Liu J, Li ZX, Zhou JS, Zhang ZJ, Li LJ. Abnormalities of cortical-limbic-cerebellar white matter networks may contribute to treatment-resistant depression: a diffusion tensor imaging study. *BMC Psychiatry* 2013 Mar 2;13:72.
190. Guo W, Liu F, Liu J, Yu M, Zhang Z, Liu G, Xiao C, Zhao J. Increased cerebellar-default-mode-network connectivity in drug-naive major depressive disorder at rest. *Medicine (Baltimore)* 2015;94:e560.
191. Ma Q, Zeng LL, Shen H, Liu L, Hu D. Altered cerebellar-cerebral resting-state functional connectivity reliably identifies major depressive disorder. *Brain Res* 2013;1495:86-94.
192. Liu L, Zeng LL, Li Y, Ma Q, Li B, Shen H, Hu D. Altered cerebellar functional connectivity with intrinsic connectivity networks in adults with major depressive disorder. *PLoS One* 2012;7:e39516.
193. Gardner A, Åstrand D, Öberg J, Jacobsson H, Jonsson C, Larsson S, Pagani M. Towards mapping the brain connectome in depression: functional connectivity by perfusion SPECT. *Psychiatry Res* 2014;223:171-7.
194. Arnold JF, Zwiers MP, Fitzgerald DA, van Eijndhoven P, Becker ES, Rinck M, Fernández G, Speckens AE, Tendolkar I. Fronto-limbic microstructure and structural connectivity in remission from major depression. *Psychiatry Res* 2012;204:40-8.

195. Yang R, Zhang H, Wu X, Yang J, Ma M, Gao Y, Liu H, Li S. Hypothalamus-anchored resting brain network changes before and after sertraline treatment in major depression. *Biomed Res Int* 2014;2014:915026.
196. Marvel C, Desmond J. Cerebellum and verbal working memory. In: Marien P et al., Consensus paper: Language and the Cerebellum: An ongoing Enigma. *Cerebellum* 2014; 13: 386-410
197. Demirtas-Tatlide and Schmahmann JD. Morality: Incomplete without the cerebellum? *Brain* 2013; 136:1-3
198. Funk CM and Gazzaniga MS. The functional brain architecture of human morality. *Curr Opin Neurobiol* 2009; 19(6): 6778-681
199. Koziol LF, Budding D, Andreasen N, D'Arrigo S, Bulgheroni S, et al. Consensus paper: the cerebellum's role in movement and cognition. *Cerebellum* 2014; 13(1):151-77
200. Sonni A, Kurdziel LB, Baran B, Spencer RM. The effects of sleep dysfunction on cognition, affect, and quality of life in individuals with cerebellar ataxia. *J Clin Sleep Med* 2014; 10: 535-43
201. Lo RY, Figueroa KP, Pulst SM, Perlman S, Wilmot G, et al. Depression and clinical progression in spinocerebellar ataxias. *Parkins Rel Disord* 2016; 22: 87-92
202. Ilg W, Bastian AJ; Boesch S, Burciu RG, Celnik P, et al. Consensus paper: management of degenerative cerebellar disorders. *Cerebellum* 2014; 13(2): 248-68
203. Snider RS and Maiti A. Cerebellar contributions to the Papez circuit. *J Neurol Res* 1976; 2(29): 133-46
204. Haines DE, Dietrichs E, Mihailoff GA, McDonald EF. The cerebellar-hypothalamic axis: basic circuits and clinical observations. *Int Rev Neurobiol* 1997; 41:83-107

205. Schmahmann JD. Dysmetria of thought: an unifying hypothesis for the cerebellar role in sensorimotor function, cognition, and emotion. In: Koziol LF, Budding D, Andreasen N, D'Arrigo S, Bulgheroni S, et al. Consensus paper: the cerebellum's role in movement and cognition. *Cerebellum* 2014; 13(1):151-77????

206. D'Angelo E and Casali S. Seeking a unified framework for cerebellar function and dysfunction: from circuit operations to cognition. *Front Neural Circuits* 2013; 6(116): 1-23

207. Klein AP, Ulmer JL, Quinet SA, Mathews V, Mark LP. Nonmotor functions of the cerebellum: an introduction. *AJNR* 2016; doi.org/10.3174/ajnr.A4720

208. Barton RA. Embodied cognitive evolution and the cerebellum. *Phil Trans Soc B* 2012; 367: 2097-2107

209. Reeber SL, Otis TS, Sillitoe RV (2013) New roles for the cerebellum in health and disease. *Front Syst Neurosci*

Legends

Figure 1

Lesion mapping for early and late injuries resulting in autism social deficits. Brain areas result in lasting Autism Spectrum Disorders social deficits when injured neonatally (blue), in adulthood (red), or that can be fully or partially compensated after an injury regardless of age (light or dark grey). Medial temporal area is depicted in violet to indicate that both neonatal and adult injuries can cause social deficits, but only if the whole medial structures are damaged, for neonatal lesions, deficits are not compensatable. Data about ACC neonatal lesion are nowadays lacking.

Abbreviations: PFC = Prefrontal cortex, ACC = Anterior cingulate cortex, OFC = Orbitofrontal cortex.

Brain renders were realized with Mango (<http://ric.uthscsa.edu/mango>) from the MRICron canonical ch2better.nii template (<http://www.mccauslandcenter.sc.edu/mricro/mricron>).

Adapted by Wang et al., 2014, *Neuron* [20]. Copyright 2014 by *Cell Press*. Adapted with permission.

Figure 2

Representative overview of event-related potentials (ERP) to different paradigms of emotional preception and recognition in patients of cerebellar lesions. At the left row, the diminished late positive potentials to salient emotional cues with positive, negative and in comparison neutral emotional contents (solid line = neutral emotional content; dotted line = positive emotional content; dashed dotted line = negative emotional content) around a time area of 450 to 750 ms are displayed in the upper panel. In correspondance, mapped head surface distribution of the ERP displayed at the middle panel, and dipole source results showed at the lower panel, indicated a frontal shift of the commonly centroparietal location of this ERP component in healthy subjects. At the right row, the upper panel displays the diminished late positive potentials to different emotional face expressions (solid line = neutral facial expression; dotted line = emotional facial expression) around 452 ms to 752 ms with the corresponding power peaks of surface derivations of lateral prefrontal cortex. At the middle panel, mapped head surface distribution of the ERP are shown, whereas the lower panel depict the in-depth analysis of the dipole sources, indicating contralateral prefrontal activations to each emotion as a compensatory mechanism.

Figure 3

Aversive stimuli in the form of pain (red) and unpleasant pictures (yellow) produced overlapping fMRI activation (blue) in posterior cerebellar hemispheres Lobule VI, VIIb, and Crus I. Activation in these overlapping cerebellar areas was inversely related to activation in limbic areas in the brain, including the hypothalamus (Hypo), parahippocampal gyrus (PHG), and subgenual anterior cingulate cortex (sACC). Figure adapted from Moulton et al., 2011.

Figure 4

Cerebellar responses to passive viewing of affective pictures from the International Affective Picture System (IAPS) [18]. Healthy adult participants were exposed to positive, negative and neutral affective pictures. (a & b): Human cerebellar anatomy shown in sagittal and coronal

planes, derived using the probabilistic atlas of the cerebellum [19]. c–f: BOLD activity superimposed to MR anatomical scans from the analysis comparing emotion-specific effects. Figure adapted from Baumann and Mattingly, 2012.

Figure 5

Spatiotemporal cerebellar activations to passive viewing of affective pictures from IAPS. Activations are superimposed on the probabilistic cytoarchitectonic maps for cerebellar lobules for (a) high arousal, (b) unpleasant valence, and (c) pleasant and high arousal stimuli. Figure adapted from Styliadis et al., 2015.

Figure 6

Effects of emotional prosody production (execution phase)

Production of emotional prosody compared with neutral speech production increased BOLD responses bilaterally in inferior gyrus (BA44, BA45, and BA47, extending into anterior insula), superior cerebellum, thalamus and globus pallidus, substantia nigra, and STS with a much larger extent from anterior to posterior in the right hemisphere. Lateralization analyses revealed stronger activation of the posterior right (vs left) STS ($p < 0.01$ FEW). We observed no other lateralization, even at lower threshold ($p < 0.05$ FEW). Note that these results are consistent with the nonlateralized bilateral inferior prefrontal network observed in perception studies (Wildgruber et al., 2006; Ethofer et al., 2009). Interestingly, the left sylvian parietotemporal area (STP/TPJ), as an important component of the dorsal stream, was more strongly activated during production of emotional than of neutral prosody, but not other regions to this fast sensorimotor translating systems (i.e., dorsal premotor cortex, dorsal Broca's region; Hickok and Poeppel, 2007) showed this activity pattern. Graphic from: Swann Pichon, and Christian A. Kell J. Neurosci. 2013;33:1640-1650

Figures and Tables:

Figure 1

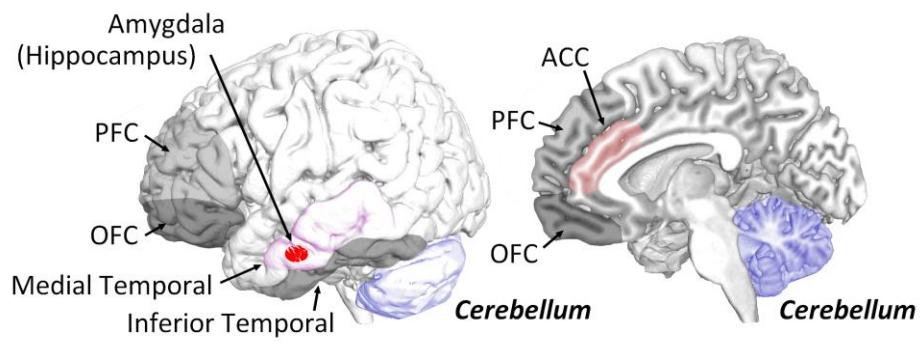


figure 2

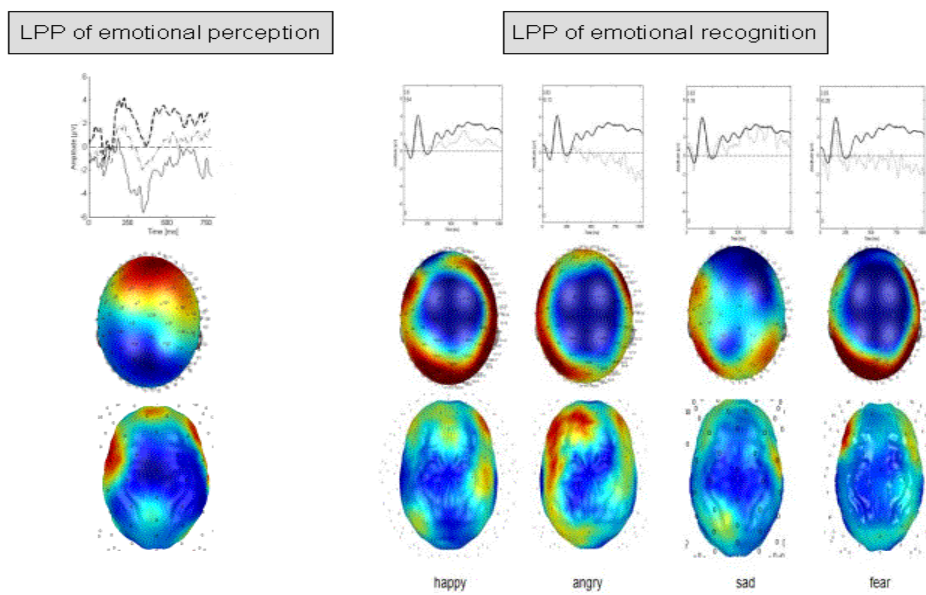


figure 3

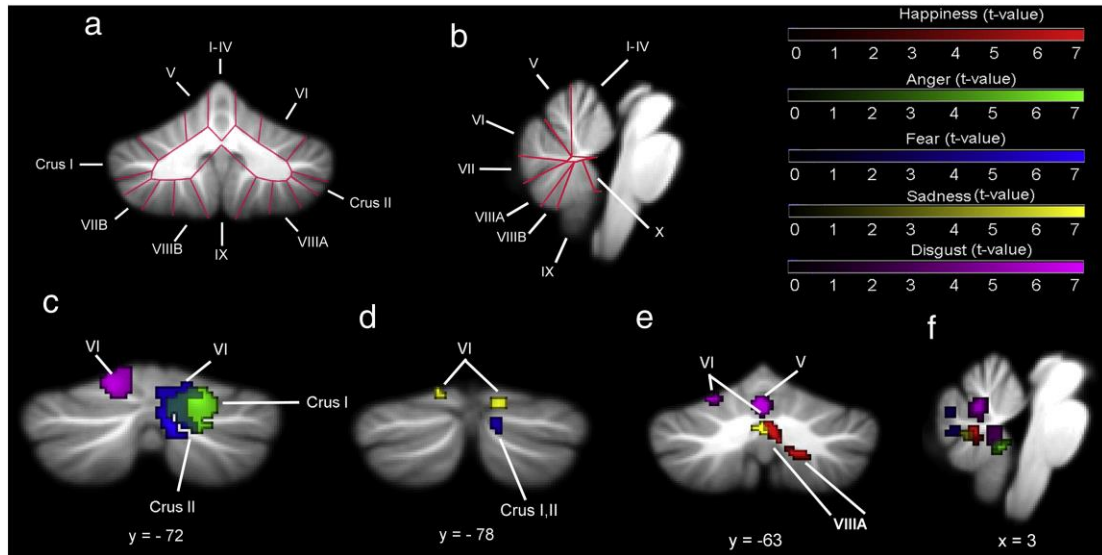


figure 4

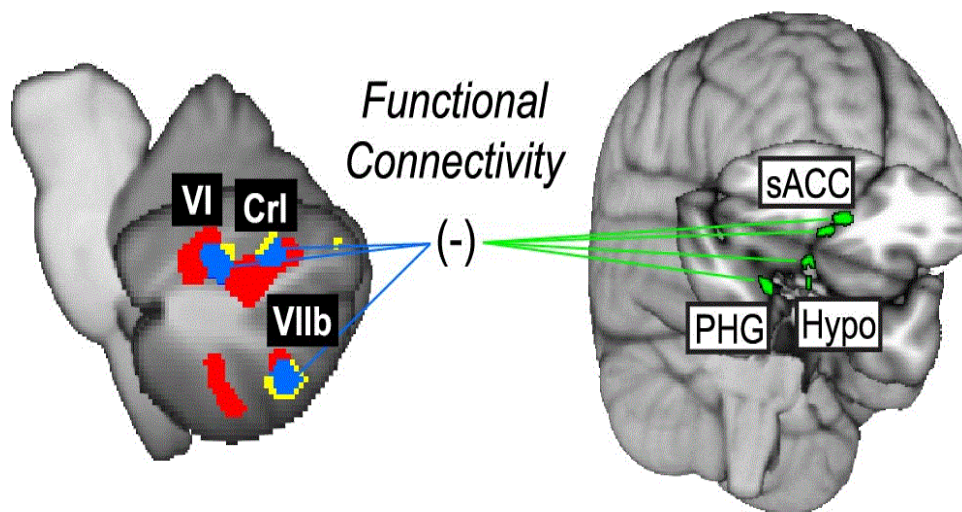


figure 5

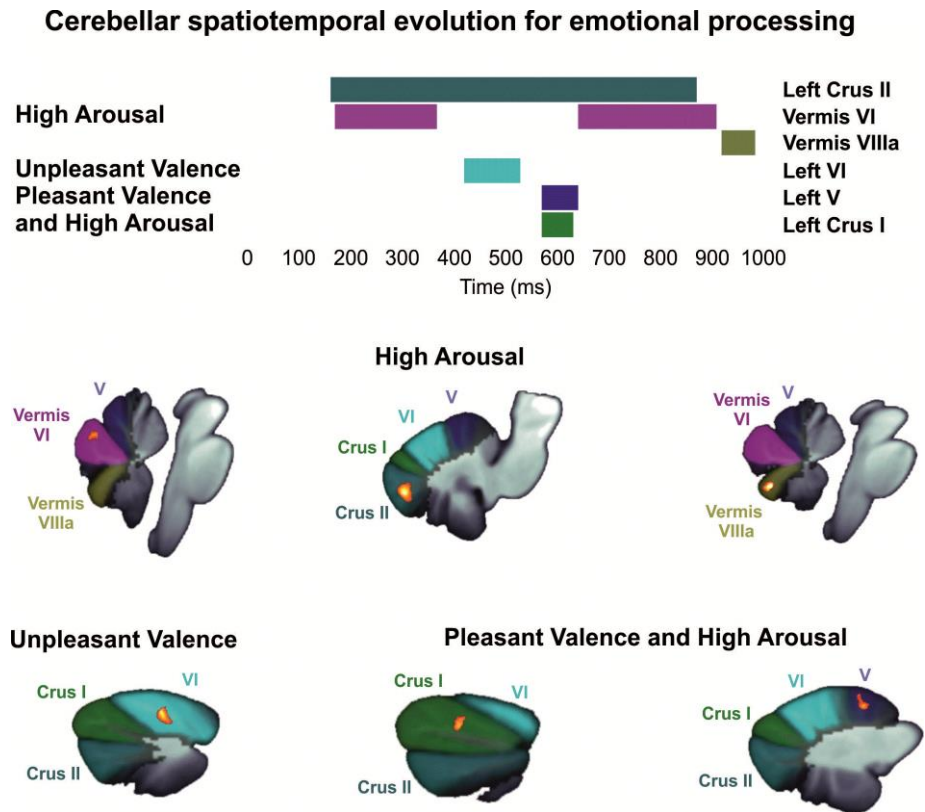


figure 6

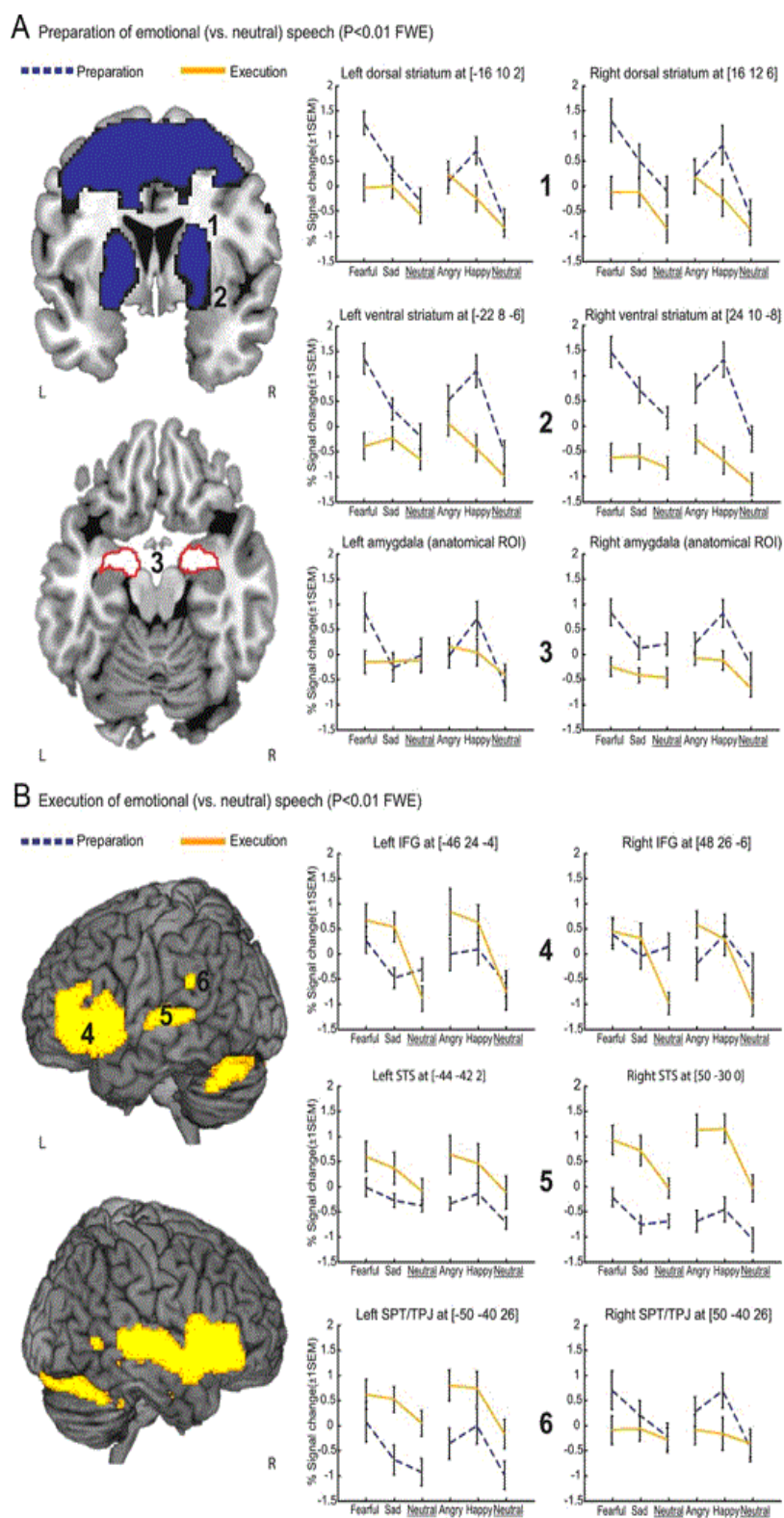


table 1

Table 1: Overview of main cerebellar abnormalities in unipolar and bipolar disorder.

Analytic level	Main finding	Reference [number]
Molecular	Abnormal GABA synthesizing proteins in UP and BP Disturbances in the metabolite N-acetylaspartate and choline ratio in BP	Fatemi et al., 2005 [1]; Maloku et al., 2010 [2] Cecil et al., 2003 [3]
Structural	Reduced gray matter volumes of vermis in BP Volumetric reduction of posterior cerebellar vermis in BP Smaller cerebellar volumes in BP Progressive gray matter loss in BP Increased gray matter volume in BP Smaller cerebellar volumes in UP White matter abnormalities in UP and BP	Eker et al., 2014 [10]; Milles et al., 2005 [4]; Monkul et al., 2008 [5] Kim et al., 2013 [6] Baldaçara et al., 2011 [7] Moorhead et al., 2007 [8] Adler et al., 2007 [9] Frodl et al., 2008 [11]; Peng et al., 2011 [12] Abe et al., 2010 [15]; Mahon et al., 2009 [14]
Functional	Increased resting state activity in UP Decreased activity in reward processing Increased resting state activity in male patients and decreased resting state activity in female patients with UP Reduced local signal synchronization in UP and BP Abnormal white matter integrity and neural connectivity in UP Decreased functional connectivity with cerebral cortex in UP Increased functional connectivity with cerebral cortex in UP Decreased functional connectivity with caudate nucleus in UP	Guo et al., 2013 [16]; Rapkin et al., 2011 [19]; Wang et al., 2014 [18] Zhang et al., 2013 [20] Dotson et al., 2009 [21] Liang et al., 2013 [22]; Liu et al., 2013 [23] Peng et al., 2013 [25] Ma et al., 2013 [27] Liu et al., 2012 [28] Gardner et al., 2014 [29]

GABA; gamma-aminobutyric acid; UP: Unipolar disorder; BP: Bipolar disorder

table 2

Consensus to Cerebellum and Emotion: agreements and warranted research	
agreement	<ul style="list-style-type: none"> - The cerebellum forms part of neural circuits that are involved in subsequent stages of processing emotions, i.e. perception, recognition, evaluation and integration into behavior. - Associative learning represents a core mode of cerebellar processing of emotion. - The cerebellum modulates excitatory and inhibitory processing of emotion for adaptive motor and non-motor behaviour. - Vermis and lateral hemispheres, in particular crura I/II and deep nuclei are key regions of the cerebellum in emotional processing. - Emotions of negative valence have a stronger impact on the cerebellum and its predictive role in emotional behavior.
warranted research	<ul style="list-style-type: none"> - Identification of cerebellar pathways to cortical-subcortical networks (most notably amygdala, hypothalamus, prefrontal areas) involved in explicit and implicit perception and learning. - Clarification of distributions of the fronto-thalamo-cerebellar axis in social cognition and its peculiarities in developmental and neuropsychiatric disorders - Identification of cerebellar networks involved in processing emotional contents of language. - Therapeutic options (pharmacological, neurophysiological, behavioral psychotherapeutical, physical).