

# Blood parasites in hooded crows (*Corvus corone cornix*) in Northwest Italy

Frine Eleonora Scaglione<sup>1\*</sup>, Francesca Tiziana Cannizzo<sup>1</sup>, Paola Pregel<sup>1</sup>,  
Antòn David Pérez-Rodríguez<sup>2</sup> & Enrico Bollo<sup>1</sup>

<sup>1</sup> Dipartimento di Scienze Veterinarie, Università degli Studi di Torino, Via L. da Vinci 44, 10095 Grugliasco, Italy.

<sup>2</sup> Department of Zoology and Physical Anthropology, Complutense University of Madrid, Faculty of Biology,  
C/ José Antonio Nováis, 2 Ciudad Universitaria, 28040 Madrid, Spain.

\* Corresponding author at: Dipartimento di Scienze Veterinarie, Università degli Studi di Torino, Largo P. Braccini 2, 10095 Grugliasco, Italy.  
Tel.: +39 011 6709039, Fax: +39 011 6709031, e-mail: frineeleonora.scaglione@unito.it

Veterinaria Italiana 2016, **52** (2), 111-116. doi: 10.12834/VetIt.110.307.2

Accepted: 29.11.2015 | Available on line: 09.05.2016

## Keywords

*Corvus corone cornix*,  
Haemoparasites,  
*Haemoproteus* spp.,  
Hooded crow,  
*Leucocytozoon* spp.,  
*Plasmodium* spp.

## Summary

Haemoparasites and their effects on hooded crows (*Corvus corone cornix*) are poorly studied. The aims are to evaluate the prevalence of *Haemoproteus* spp./*Plasmodium* spp. or *Leucocytozoon* spp., to correlate this with gross and histopathological findings, and to investigate the association among infection and geographical origin, age, gender, parasite distribution and prevalence among organs. Hooded crows (n = 47) were collected within a regional culling programme from 3 districts in the province of Turin (Italy) and subjected to necropsy. Histological and molecular analyses were carried out on some tissues. *Leucocytozoon* spp. was detected in 46 crows (97.9%) by polymerase chain reaction (PCR), whereas 28 birds (59.6%) were found to be positive for *Haemoproteus* spp./*Plasmodium* spp. The distribution of parasites in several organs varied significantly, showing that *Leucocytozoon* spp. is ubiquitous in organs in contrast with *Haemoproteus* spp./*Plasmodium* spp., which have a specific predilection for spleen and lungs. The prevalence of *Haemoproteus* spp./*Plasmodium* spp. also differed significantly among the crows captured in the areas of the study. The high prevalence of haemoparasites emphasizes the success of ornithophilic vectors and the susceptibility of this species to infection. Differences in prevalence among the sites are probably due to orographic features of the areas, variations in vector species and density, or to crow population size or structure. In spite of the high infection rate, no gross and histological lesions were found. This finding further suggests an evolutionary adaptation between crows and avian blood parasites.

## Emoparassiti in cornacchie grigie (*Corvus corone cornix*) in Piemonte

### Parole chiave

Cornacchia grigia,  
*Corvus corone cornix*,  
Emoparassiti,  
*Haemoproteus* spp.,  
*Leucocytozoon* spp.,  
*Plasmodium* spp.

### Riassunto

Gli emoparassiti e i loro effetti sulle cornacchie grigie (*Corvus corone cornix*) sono ad oggi scarsamente studiati. Obiettivo del presente lavoro è di valutare la prevalenza di *Haemoproteus* spp./*Plasmodium* spp. o *Leucocytozoon* spp. e valutarne l'eventuale correlazione con le lesioni anatomoistopatologiche. Inoltre viene studiata l'associazione tra infestazione e provenienza, età, sesso, distribuzione e prevalenza del parassita negli organi. Quarantasette cornacchie grigie raccolte nell'ambito di un programma di abbattimento regionale, provenienti da 3 distretti della provincia di Torino (Italia) sono state sottoposte a necropsia. Sui tessuti prelevati sono state eseguite analisi istologiche e biomolecolari. Quarantasei cornacchie (97,9%) sono risultate positive a *Leucocytozoon* spp. e 28 (59,6%) sono risultate positive a *Haemoproteus* spp./*Plasmodium* spp. Nei diversi organi la distribuzione dei parassiti varia in modo significativo, dimostrando che *Leucocytozoon* spp. è ubiquitario, contrariamente a *Haemoproteus* spp./*Plasmodium* spp., che hanno una particolare predilezione per milza e polmoni. Differenze statisticamente significative nella prevalenza di *Haemoproteus* spp./*Plasmodium* spp. sono evidenziate nelle tre aree di studio. L'alta prevalenza di emoparassiti sottolinea l'attività dei vettori ornitofili e la suscettibilità di questa specie all'infestazione. Le differenti prevalenze nelle tre zone geografiche sono probabilmente ascrivibili alle caratteristiche orografiche, alla presenza e densità di differenti specie di vettori, o alle dimensioni delle popolazioni di cornacchie grigie. Nonostante l'alta incidenza di infestazione non sono state osservate lesioni anatomoistopatologiche. Tali dati suggeriscono inoltre un adattamento evolutivo tra cornacchie ed emoparassiti.

## Introduction

Blood parasites have been object of extensive research since the beginning of the 20<sup>th</sup> century (Valkiūnas 2005). The presence of haemoparasites in birds is quite common. It is estimated that 68% of all bird species are susceptible to haemosporidians (Atkinson *et al.* 2002).

Hooded crows (*Corvus corone cornix*) are widespread in Central Europe and Western Asia. Their number has increased, especially in urban areas around the world, where they have become synanthropic. Few studies have been conducted on haemoparasites in this species. In particular, only 1 species of *Leucocytozoon* spp. in *Corvus corone* has been described (Sato *et al.* 2007). Considering that Italy is geographically situated on the main bird migration routes and that hooded crows are 1 of the commonest bird species, we deemed it interesting to evaluate gross and histopathological findings in hooded crows and to determine the prevalence of *Haemoproteus* spp./*Plasmodium* spp. or *Leucocytozoon* spp. from 47 crows culled by game wardens in 3 areas of Northwest of Italy. We also investigated the associations among infection and geographical origin, age, gender, parasite distribution among organs, and pattern of affected organs.

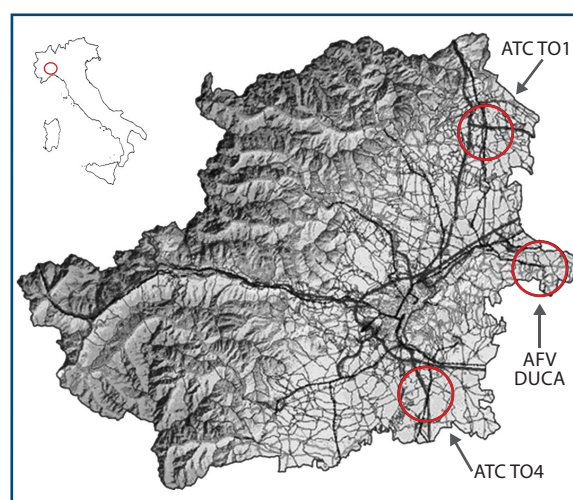
## Materials and methods

Following the adoption of a regional animal containment programme<sup>1</sup> during the years 2010-2011, 47 hooded crows (27 males and 20 females), from 3 districts of the province of Turin (Northwest Italy: ATC TO1: 45°11' - 45°32'N and 7°39' - 7°59'E; ATC TO4: 44°56' - 44°51'N and 7°43' - 7°51'E; AFV DUCA: 45°10' - 45°16'N and 7°57' - 8°4'E) (Figure 1) were captured with Larsen cage traps. The crows were euthanised with CO<sub>2</sub> and subjected to a standard necropsy procedure. Portions of heart, lungs, liver, kidneys, spleen, skeletal muscle, and central nervous system (CNS) were collected and frozen at -20°C for biomolecular investigation and fixed in 10% neutral buffered formalin (pH 7) for histological investigations. Age was determined by the colour of the mandible, according to the guidelines proposed by Svensson (Svensson 1992).

The genomic DNA was extracted from sampled organs using a commercial DNA isolation kit (MACHEREY-NAGEL, Düren, Germany), according to the manufacturer's protocol. The extracted

templates were used for the DNA amplification by means of a thermal cycler (Gene Amp PCR System 2400, Perkin Elmer, Waltham, MA, USA), using a specific primer set, as described by Hellgren and colleagues (Hellgren *et al.* 2004). Briefly, a nested polymerase chain reaction (nested-PCR) targeting the mitochondrial cytochrome b gene of *Haemoproteus* spp., *Plasmodium* spp. and *Leucocytozoon* spp. was performed. The first step of the PCR protocol was performed using HaemNFI (5'-CATATATTAAGAGAAITATGGAG-3') and Haem NR3 (5'-ATAGAAAGATAAGAAATACCATTTC-3') primers, to amplify parasite mtDNAs from species of *Haemoproteus* spp., *Plasmodium* spp. and *Leucocytozoon* spp. The reaction was performed in a final volume of 25 µl, which included 2 µl of the extracted DNA template, 1.5 µM of each primer, and 12.5 µl of HotStarTaq<sup>®</sup> Master Mix (Qiagen, Hilden, Germany).

In the second step of PCR protocol HaemF (5'-TGGTGCTTTTCGATATATGCATG-3') and HaemR2 (5'-GCATTATCTGGATGTGATAATGGT-3') primers (Bench *et al.* 2000) for *Plasmodium* spp. and *Haemoproteus* spp., and HaemFL (5'-ATGGTGTTTTAGATACTTACATT-3') and HaemR2L (5'-CATTATCTGGATGAGATAATGGIGC-3') for *Leucocytozoon* spp. were used. In the first step the DNA amplification was conducted, following a hot-start incubation (95°C for 15 minutes), under the following conditions: 30 seconds at 94°C, 30 seconds at 55°C, and 45 seconds at 72°C for 20 cycles. A final elongation step was performed at 72°C for



**Figure 1.** Map of Turin province (Piedmont, Italy), indicating the districts enrolled in the study.

<sup>1</sup> Decreto Giunta Regione Piemonte of the August 3 2007 n. 74-6702. Approvazione dell'atto di intesa tra la Regione Piemonte e la Facoltà di Medicina Veterinaria dell'Università degli Studi di Torino per la razionalizzazione ed integrazione delle attività di raccolta e smaltimento degli animali selvatici morti o oggetto di interventi di contenimento. *Off J*, **35**, 30.08.2007 and amendments.

<sup>2</sup> According to Italian National Bioethic Committee Guidelines and to the Italian law: Legge of 11 February 1992, n. 157. Norme per la protezione della fauna selvatica omeoterma e per il prelievo venatorio. *Off J*, **46**, 25.02.1992 (Suppl. n. 41) and amendments.

10 minutes. In order to perform the second step, 4  $\mu$ l of the first PCR product were used as template (2  $\mu$ l for *Plasmodium* spp. and *Haemoproteus* spp. detection, and 2  $\mu$ l for *Leucocytozoon* spp. detection, separately). The PCR conditions were the same as in the first step, except for the number of cycles (35 cycles). A positive control DNA for each tested parasite was obtained from individuals with known infection (Ortego and Cordero 2009). Each amplicon obtained from the second PCR step was visualized by means of agarose gel electrophoresis.

Tissue samples collected for histological investigations were paraffin-embedded and sections of 4  $\mu$ m were cut using a microtome (Leica Microsystems, Wetzlar, Germany), stained with haematoxylin and eosin and examined under a light microscope (Leica DM LS2, Leica Microsystems, Wetzlar, Germany).

Statistical analysis was performed using GraphPad InStat (vers. 3.05) statistical software (GraphPad Inc., San Diego, CA). The association among sex, age or geographical area and presence of *Haemoproteus* spp./*Plasmodium* spp. was evaluated using the chi-squared test for independence or Fisher's exact test. The difference between *Haemoproteus* spp./*Plasmodium* spp. and *Leucocytozoon* spp. distribution in organs was ascertained with the Fisher's exact test. A p value less than 0.05 was considered statistically significant.

## Results

Neither macroscopical nor histological lesions were observed in the examined samples. Out of 47 crows tested by nested-PCR (Figures 2 and 3), 31 (59.6%) were found positive for *Haemoproteus* spp./*Plasmodium* spp. and 46 (97.9%) positive for *Leucocytozoon* spp. The haemoparasite prevalences were significantly different (Fisher's  $p < 0.001$ ), with a higher relative risk (1,484) for *Leucocytozoon* spp. Conversely crows infected with *Leucocytozoon* spp.

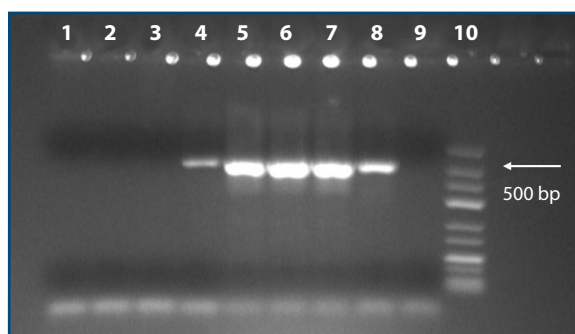
and *Haemoproteus* spp./*Plasmodium* spp. were uniformly distributed in the 3 observed age classes and between genders (Table I and II). *Leucocytozoon* spp. prevalence did not differ significantly in the 3 examined areas, while the prevalence of *Haemoproteus* spp./*Plasmodium* spp. was significantly lower in the ATCTO1 area (Table III).

The results concerning the distribution of the parasites in the various organs are reported in Table IV. An extremely statistically significant difference ( $p < 0.001$ ) between the distribution of *Haemoproteus* spp./*Plasmodium* spp. and *Leucocytozoon* spp. in organs was assessed by dividing the sampled birds into 2 classes, i.e. those with  $\leq 2$  organs involved and those with  $> 2$  organs parasitised. With reference to *Haemoproteus* spp./*Plasmodium* spp., 44.8% (13 out of 29 animals) of positive animals showed a PCR positivity in only 1 or 2 organs, while in 16 cases (55.2%) the parasites were present in more than 2 organs. On the other hand *Leucocytozoon* spp. was found present in more than 2 organs in almost all infected birds (97.8%). The most frequently parasitised organs were lungs and liver for *Leucocytozoon* spp. and spleen and lungs for *Haemoproteus* spp./*Plasmodium* spp.

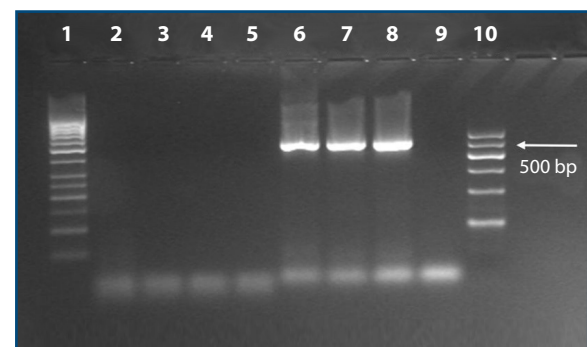
## Discussion

Haemoparasites in birds have been the subject of many studies (Valkiūnas 2005, Lachish et al. 2011), yet very few data are available on hooded crows (*Corvus corone cornix*) hemoparasites (Valkiūnas et al. 2000), in which only 1 species of *Leucocytozoon* spp. has been described (Sato et al. 2007).

Many bird hosts could be simultaneously infected by several species or strains of parasites (Bruce et al. 2000, Poulin and Morand 2000, Silva-Iturriza et al. 2012). Co-infections are a major cause of evolution of virulence and the selection pressure imposed by parasites on host is expected to be stronger when several parasites exploit the same host (Arriero and



**Figure 2.** *Haemoproteus* spp./*Plasmodium* spp. PCR. PCR products for *Haemoproteus* spp./*Plasmodium* spp. = columns 1-7; positive control = column 8; blank = column 9; marker = column 10.



**Figure 3.** *Leucocytozoon* spp. PCR. PCR products for *Leucocytozoon* spp. = columns 2-7; positive control = column 8; blank = column 9; marker = columns 1 and 10.

**Table I.** Age distribution of hooded crows testing positive by nested-PCR for *Leucocytozoon* spp. and *Haemoproteus* spp./*Plasmodium* spp. in Northwest Italy (2010-2011).

| Age class                     | <i>Leucocytozoon</i> spp. prevalence | <i>Haemoproteus</i> spp./ <i>Plasmodium</i> spp. prevalence |
|-------------------------------|--------------------------------------|---|
| ≤ 1 year (n = 7)              | 7 (100%)                             | 5 (71.4%)   |
| 1 year > x > 2 years (n = 28) | 27 (96.4%)                           | 21 (75.0%)  |
| ≥ 2 year (n = 12)             | 12 (100%)                            | 5 (41.7%)   |

Møller 2008). In this study, infection and co-infection by haemoparasites in hooded crows do not appear to be responsible for macroscopic and histological lesions, suggesting an evolutionary adaptation between hosts and avian blood parasites, as already reported (Beadell et al. 2009).

In literature, *Haemoproteus* spp. is the most frequently observed blood parasite in birds, followed by *Leucocytozoon* spp. and *Plasmodium* spp. (Murata 2002, Savage et al. 2009, Carlson et al. 2013). However, in this study, *Leucocytozoon* spp. proved to be the most prevalent haematozoan parasite in hooded crows, followed by *Haemoproteus* spp./*Plasmodium* spp. This finding may be due to the vectors' differences in species and abundance suggested in several large-scale studies (Savage et al. 2009).

The reported high prevalence (97.9%) for *Leucocytozoon* spp. in hooded crows shows that this parasite was present in almost all the examined birds and in most of the analysed organs (range: 83.0-95.7%).

Moreover, there were no significant differences in the prevalence of bird infections among the various age groups. This finding agrees with the results reported by Castro and colleagues (Castro et al. 2011), but is in contrast with several other studies on birds (Atkinson and Samuel 2010, Van Oers et al. 2010, Knowles et al. 2011).

No significant association between sex and infection was detected, even if usually females are more parasitised because the decrease in movement during the nesting period increases the likelihood of their infection with haemosporidians.

However, as the birds in this study were captured

**Table II.** Gender distribution of hooded crows testing positive by nested-PCR for *Leucocytozoon* spp. and *Haemoproteus* spp./*Plasmodium* spp. in Northwest Italy (2010-2011).

| Gender          | <i>Leucocytozoon</i> spp. prevalence | <i>Haemoproteus</i> spp./ <i>Plasmodium</i> spp. prevalence |
|-----------------|--------------------------------------|---|
| Male (n = 27)   | 27 (100%)                            | 19 (70.4%)  |
| Female (n = 20) | 19 (90.0%)                           | 12 (60.0%)  |

**Table III.** Number of hooded crows testing positive by nested-PCR for *Leucocytozoon* spp. and *Haemoproteus* spp./*Plasmodium* spp. in the 3 examined districts in Northwest Italy (2010-2011).

| Districts       | <i>Leucocytozoon</i> spp. prevalence | <i>Haemoproteus</i> spp./ <i>Plasmodium</i> spp. prevalence* |
|-----------------|--------------------------------------|--|
| ATCT01 (n=18)   | 18 (100%)                            | 6 (33.3%)*   |
| ATCT04 (n=15)   | 14 (92.8%)                           | 12 (85.7%)   |
| AFV DUCA (n=14) | 14 (100%)                            | 13 (86.7%)   |

\*p = 0.001

from October to March, this nesting-related difference could not be observed. The data showed a statistically significant difference in the prevalence of *Haemoproteus* spp./*Plasmodium* spp. in the birds captured in 1 of the 3 observed districts. Previous studies conducted in other countries demonstrated that the differences in prevalence between sites are probably due to variation in vector diversity, population size, and avian community composition (Valkiūnas 2005, Savage et al. 2009, Jenkins and Owens 2011, Santiago-Alarcon 2012). Although it is based on few data, our study shows that the vectors could cause the observed difference.

Blood samples and blood smears were not collected in this study because the birds were captured in accordance with current National regulations by means of Larsen cage traps and immediately euthanized.

Even if it was not possible to determine whether the detected *Leucocytozoon* spp. signals were from erythrocytic parasites sequestered in various tissues or whether they originated from exoerythrocytic meronts, in 8 cases (17%) the erythrocytic or the merozoite stage was excluded. In fact, during these stages the spleen should be PCR positive,

**Table IV.** Organs of hooded crows testing positive by nested-PCR for *Haemoproteus* spp./*Plasmodium* spp. and *Leucocytozoon* spp. (in brackets the percentage referred to the total of positive animals) in Northwest Italy (2010-2011).

|   | Heart      | Lungs      | Liver      | Kidneys    | Spleen     | Skeletal muscle | Central nervous system |
|---|------------|------------|------------|------------|------------|-----------------|------------------------|
| <i>Haemoproteus</i> spp./ <i>Plasmodium</i> spp. positivity | 8 (25.8%)  | 13 (41.9%) | 11 (35.5%) | 7 (22.6%)  | 17 (54.8%) | 10 (32.3%)      | 12 (38.7%)             |
| <i>Leucocytozoon</i> spp. positivity                        | 43 (93.5%) | 45 (97.8%) | 44 (95.6%) | 43 (93.5%) | 39 (84.8%) | 43 (93.5%)      | 43 (93.5%)             |



being it a well-perfused organ, which plays an important role in the destruction of parasitised blood cells (John 1994). Furthermore, megalomeronts can be detected anywhere in the bird organism, but most of all in the spleen (Valkiūnas 2005). The fact that only some organs were *Haemoproteus* spp./*Plasmodium* spp. PCR positive led us to exclude an erythrocytic stage.

The high prevalence of avian haematozoa in hooded crows emphasizes the success of ornithophilic vectors and the susceptibility of this species to infection. Differences in prevalence among sites could be due to variation in vector species and density or to crow population size or structure. In spite of the high infection rate, no haemoprotozoan-associated gross and histological lesions were found. This

finding further suggests an evolutionary adaptation between crows and avian blood parasites. Even if bird migration occurs mainly outside vector season, the mutual transmission of these parasites among crows and migratory birds should not be ruled out.

## Acknowledgements

The authors gratefully acknowledge the Centro di Referenza di Patologia Comparata 'Bruno Maria Zaini', Italy; Prof. Javier Perez-Tris of the Department of Zoology and Physical Anthropology, Complutense University of Madrid, Spain and Spanish Ministry of Education for financial support (FPU studentship to APR); and Dr Elvira Stefania Cannizzo.

## References

- Arriero E. & Møller A.P. 2008. Host ecology and life-history traits associated with blood parasite species richness in birds. *J Evol Biol*, **21**, 1504-1513.
- Atkinson C.T., Dusek R.J., Woods K.L. & Iko W.M. 2000. Pathogenicity of avian malaria in experimentally-infected Hawaii Amakihi. *J Wildl Dis*, **36**, 197-204.
- Atkinson C.T. & Samuel M.D. 2010. Avian malaria *Plasmodium relictum* in native Hawaiian forest birds: epizootiology and demographic impacts on apapane *Himatione sanguinea*. *J Avian Biol*, **41**, 357-366.
- Beadell J.S., Covas R., Gebhard C., Ishtiaq F., Melo M., Schmidt B.K., Perkins S.L., Graves G.R. & Fleischer R.C. 2009. Host associations and evolutionary relationships of avian blood parasites from West Africa. *Int J Parasitol*, **39**, 257-266.
- Bensch S., Stjernman M., Hasselquist D., Ostman O., Hansson B., Westerdaal H. & Pinheiro R.T. 2000. Host specificity in avian blood parasites: a study of *Plasmodium* and *Haemoproteus* mitochondrial DNA amplified from birds. *Proc Biol Sci*, **267**, 1583-1589.
- Bruce M.C., Donnelly C.A., Alpers M.P., Galinski M.R., Barnwell J.W., Walliker D. & Day K.P. 2000. Cross-species interactions between malaria parasites in humans. *Science*, **287**, 845-848.
- Carlson J., Martínez-Gómez J.E., Valkiūnas G., Loiseau C., Bell D.A. & Sehgal R.N. 2013. Diversity and phylogenetic relationships of hemosporidian parasites in birds of Socorro Island, México and their role in the re-introduction of the Socorro dove (*Zenaidura macroura*). *J Parasitol*, **99**, 270-276.
- Castro I., Howe L., Tompkins D.M., Barraclough R.K. & Slaney D. 2011. Presence and seasonal prevalence of *Plasmodium* spp. in a rare endemic New Zealand passerine (tieke or saddleback, *Philesturnus carunculatus*). *J Wildl Dis*, **47**, 860-867.
- Hellgren O., Waldenström J. & Bensch S. 2004. A new PCR assay for simultaneous studies of *Leucocytozoon*, *Plasmodium*, and *Haemoproteus* from avian blood. *J Parasitol*, **90**, 797-802.
- Jenkins T. & Owens I.P. 2011. Biogeography of avian blood parasites (*Leucocytozoon* spp.) in two resident hosts across Europe: phylogeographic structuring or the abundance-occupancy relationship? *Mol Ecol*, **20**, 3910-3920.
- John J.L. 1994. The avian spleen: a neglected organ. *Quarter Rev Biol*, **69**, 327-351.
- Knowles S.C., Wood M.J., Alves R., Wilkin T.A., Bensch S. & Sheldon B.C. 2011. Molecular epidemiology of malaria prevalence and parasitaemia in a wild bird population. *Mol Ecol*, **20**, 1062-1076.
- Lachish S., Knowles S.C., Alves R., Wood M.J. & Sheldon B.C. 2011. Infection dynamics of endemic malaria in a wild bird population: parasite species-dependent drivers of spatial and temporal variation in transmission rates. *J Anim Ecol*, **80**, 1207-1216.
- Murata K. 2002. Prevalence of blood parasites in Japanese wild birds. *J Vet Med Sci*, **64**, 785-790.
- Ortego J. & Cordero P.J. 2009. PCR-based detection and genotyping of haematozoa (Protozoa) parasitizing eagle owls, *Bubo bubo*. *Parasitol Res*, **104**, 467-470.
- Poulin R. & Morand S. 2000. The diversity of parasites. *Quarter Rev Biol*, **75**, 277-293.
- Santiago-Alarcon D., Havelka P., Schaefer H.M. & Segelbacher G. 2012. Bloodmeal analysis reveals avian *Plasmodium* infections and broad host preferences of *Culicoides* (Diptera: Ceratopogonidae) vectors. *PLoS One*, **7**, e31098.
- Sato Y., Hagihara M., Yamaguchi T., Yukawa M. & Murata K. 2007. Phylogenetic comparison of *Leucocytozoon* spp. from wild birds of Japan. *J Vet Med Sci*, **69**, 55-59.
- Savage A.F., Robert V., Goodman S.M., Raharimanga V., Raherilalao M.J., Andrianarimisa A., Ariey F. & Greiner

- E.C. 2009. Blood parasites in birds from Madagascar. *J Wildl Dis*, **45**, 907-920.
- Silva-Iturriza A., Ketmaier V. & Tiedemann R. 2012. Prevalence of avian haemosporidian parasites and their host fidelity in the central Philippine islands. *Parasitol Int*, **61**, 650-657.
- Svensson L. 1992. Identification guide to European Passerines. British Trust for Ornithology, Stockholm.
- Valkiūnas G. 2005. Avian malaria parasites and other haemosporidia. CRC Press, Boca Raton.
- Valkiūnas G., Olsen H. & Iezhova T. 2000. Haemoparasites in the hooded crow, *Corvus corone cornix* L., in the vicinity of Copenhagen. *Bull Scand Soc Parasitol*, **10**, 1-4.
- Van Oers K., Richardson D.S., Saether S.A. & Komdeur J. 2010. Reduced blood parasite prevalence with age in the Seychelles warbler: selective mortality or suppression of infection? *J Ornithol*, **151**, 69-77.