

Concise report

Magnetic resonance and ultrasonography real-time fusion imaging of the hand and wrist in osteoarthritis and rheumatoid arthritis

Annamaria Iagnocco¹, Chiara Perella¹, Maria Antonietta D'Agostino², Emanuela Sabatini¹, Guido Valesini¹ and Philip G. Conaghan³

Abstract

Objective. To investigate the role of a new hybrid imaging modality, integrated in the US equipment and derived by a real-time MRI and US fusion process, in the hand and wrist joints of a small group of rheumatic patients.

Methods. Consecutive patients with OA and RA with hand and wrist involvement were studied. Clinical assessment, physical examination, hand and wrist radiography and laboratory tests were carried out. After performing 0.2T MRI (T₁, T₂ and short time inversion recovery sequences) of the dominant hand and wrist, images were recorded in a US machine equipped with a virtual navigator system. Ultrasonography was performed in the same joints using an 18 MHz linear probe. Image MRI/US superposition was carried out, with real-time contemporary visualization of the US and related MRI images. Randomly selected stored images of different joints were subsequently re-analysed by a different operator. Concordance between the static and dynamic evaluations was assessed.

Results. Nine patients (six with OA and three with RA) were studied. The real-time MRI/US overlap provided fusion images of both tools. A striking concordance in the visualization of the bony profile was found with evidence of pronounced osteophytes in OA and bone erosions in RA. The analysis of stored selected images demonstrated a high concordance between real-time and static assessment.

Conclusion. MRI/US fusion imaging gives a composite set of information with accurate anatomical correlations.

Key words: Magnetic resonance, Ultrasonography, Fusion imaging, Osteoarthritis, Rheumatoid arthritis.

Introduction

OA is the most common arthritis involving the hand, with a clinical presentation that includes chronic pain, progressive deformity and gradual loss of joint function. RA is a chronic polyarthritis frequently involving the hand and

wrist and characterized by erosive joint destruction and associated loss of function. Both diseases are classified according to internationally accepted criteria [1, 2]. While conventional radiography (CR) is considered the most feasible imaging technique for assessing structural abnormalities [3], MRI can be used to evaluate a number of soft tissue and bony pathologies including synovitis, loss of articular cartilage, ligament and tendon abnormalities, osteophytes, enthesophytes, cortical erosions and bone marrow changes. The recent introduction of low-field extremity scanners has resulted in patient-friendly assessment of peripheral joints while limiting the scanner space required and installation costs [4]. High- and low-field MRI have comparable ability in detecting erosions and synovitis (when contrast is used), although low field may have lower sensitivity in detecting bone marrow lesions [5].

¹Dipartimento di Medicina Interna e Specialità Mediche, Rheumatology Unit, Sapienza Università di Roma, Rome, Italy,

²Department of Rheumatology, Université Paris Ouest-Versailles-Saint Quentin en Yvelines, Hôpital Ambroise Paré APHP, Paris, France and

³NIHR Leeds Musculoskeletal Biomedical Research Unit, Department of Rheumatology, University of Leeds, Leeds, UK.

Submitted 14 September 2010; revised version accepted 10 February 2011.

Correspondence to: Annamaria Iagnocco, Dipartimento di Medicina Interna e Specialità Mediche, UOC Reumatologia, Sapienza Università di Roma, Policlinico Umberto 1, Viale del Policlinico 155, 00161 Rome, Italy. E-mail: annamaria.iagnocco@uniroma1.it

Musculoskeletal ultrasonography (US) is also a useful imaging tool in the diagnosis and management of OA and RA [6, 7]. Like MRI, it can demonstrate synovial proliferation and effusion within joints, tendon sheath and bursae and cortical bone changes [8, 9]. However, US may not be as sensitive as MRI in detecting bony erosions in areas where a good acoustic window cannot be obtained.

Recently, impressive technical advances in imaging have been made using fusion imaging. Using this new tool, image superposition of US and MRI and/or CT is performed, with consequent contemporary visualization of the US and related MRI or CT images [10]. The overlapping real-time images provide a combination of the information produced by the individual tools, enhancing data provided by either single technique and presenting anatomical correlations [10]. Using a new fusion image system integrated into an US machine, the aim of the present study was to investigate the role of this novel hybrid imaging modality, using hand and wrist joints from a small group of OA and RA patients.

Methods

This study was carried out in the outpatient clinic of the Rheumatology Unit of Sapienza, University of Rome, Italy and was conducted in compliance with Good Clinical Practice. Ethical committee approval from the Comitato Etico Policlinico Umberto I, Roma was obtained and patients gave their written informed consent.

Patients

Consecutive patients with hand OA and RA with hand and wrist involvement, classified according to ACR criteria, were included in the study [1, 2]. The presence of any other rheumatic disease was the major exclusion criterion in this study. All patients were evaluated by a single rheumatologist who took the clinical history and performed the physical examination. Demographic, clinical and laboratory collected data are presented in Table 1. All patients then underwent MRI and US imaging evaluation.

Imaging evaluation

CR

CR of both hands and wrists was performed in all patients. The foot was also examined in RA patients in order to calculate the Sharp-van der Heijde score [11]. All changes in OA patients were recorded according to the Kallman scale for hand OA [12].

MRI

MRI (0.2T) of the dominant hand and wrist was acquired using an ESAOTE Artoscan machine (Genoa, Italy); T₁, T₂ and short time inversion recovery (STIR) sequences were acquired. Axial and isotropic images were acquired with turbo 3D T₁ reconstruction. No contrast agent was used.

US

Ultrasound examination was performed by an experienced sonographer (A.I.), who studied the same

TABLE 1 Demographic, clinical and laboratory findings in patients with OA and RA

Demographic, clinical and laboratory findings	OA	RA
Number of patients	6	3
Gender: men/women (ratio)	2/4 (0.5)	1/2 (0.5)
Age, mean (range), years	71 (59–75)	66.3 (59–77)
Disease duration, mean (range), month	36 (12–60)	201.6 (5–360)
ESR, mean (s.d.), mm/h	13.6 (2.69)	50.3 (22.1)
CRP, negative/positive	Negative	Positive
VAS pain, mean (s.d.), mm	13.3 (8.87)	70.6 (19.74)
Dreiser scale, mean (s.d.)	2.16 (2.41)	–
Duration of morning stiffness, mean (s.d.), min	8.7 (2.69)	–
Painful joints, mean (s.d.)	–	9.3 (6.18)
Swollen joints, mean (s.d.)	–	7.3 (4.03)
HAQ, mean (s.d.)	–	15.3 (8.6)
DAS-28, mean (s.d.)	–	6.3 (1.05)

VAS: visual analogue scale; DAS-28: 28-joint DAS.

anatomical areas analysed by MRI in all patients, using an 18 MHz linear probe. Radio-carpal, MCP, PIP and DIP joints were evaluated, by performing both dorsal longitudinal and transverse scans using a multiplanar approach. Using the B-mode function, the following pathologies were recorded using validated definitions [9, 13] and scored as either present or absent: hypertrophy of the synovial membrane, joint effusion and changes in bony contour such as erosions or osteophytes.

Fusion imaging

The fusion imaging modality (virtual navigator) integrated in the ESAOTE MyLab70-XVision US equipment (Genoa, Italy) was then employed. The fusion imaging and correlated tracking system permit contemporary visualization of MRI and US images. The procedure consists of different phases: once the MRI examination has been performed, the data are uploaded through local area network (LAN), CD or USB devices in digital imaging and communications in medicine (DICOM) file format onto the US machine. Then, a transmitter is located close to the patient, while a mobile receiver is placed on the probe. The correlation procedure can then commence. The system is based on a communication protocol between the US machine and the browser in order to correctly visualize, in terms of size and format, the images from the reference technique, which is (in this study) MRI. Axial sequences are initially used, as these allow easier application to start the navigation system. When changing the planes, depth and the magnification of the US images, the reference image is automatically refreshed in real time; the one-to-one ratio with the US image is automatically maintained. The spatial retrieval of the ultrasound scan is guaranteed by a magnetic tracking system consisting of a dedicated card that drives an electromagnetic positioning device and the fixed emitter. During the real-time ultrasound scanning, the operator can simultaneously display the same arbitrary MRI planes visualized by the US

machine, maintaining perfect and precise spatial correlations.

Subsequently, randomly selected and stored images of five different joints acquired in both OA and RA patients (one radio-carpal, two MCP, one PIP and one DIP) were re-analysed by a different operator (C.P.), expert in musculoskeletal US, who was blinded to clinical and imaging data that were collected previously. Concordance with the previous real-time evaluation was assessed.

Results

Nine patients (six with OA and three with RA) were studied. Demographic, clinical and laboratory findings are reported in Table 1.

OA patients

All of the OA patients complained of hand pain and brief duration of morning stiffness. Physical examination demonstrated small Heberden and Bouchard nodes. Heberden nodes were present in 40 DIP joints and Bouchard nodes in 24 PIP joints.

Hand CR demonstrated: small osteophytes in 2 MCP, 18 PIP and 41 DIP joints; moderate osteophytes in 4 DIP joints; large osteophytes in 1 MCP, 8 PIP and 4 DIP joint. Joint space narrowing was recorded in three MCP, eight PIP and eight DIP joints; joint fusion was observed in four DIP joints of one patient. In two patients, bone erosions, subchondral bone sclerosis and cysts were detected in the PIP and DIP joints.

Both US and MRI examination demonstrated markedly increased numbers of osteophytes in the MCP, PIP and DIP joints. US detected osteophytes in 65 MCP, 65 PIP and 66 DIP joints in all the seven patients, even with minimal radiographic involvement. US evaluation revealed the presence of joint effusion in the second MCP joint that could not be detected by MRI.

RA patients

Hand and wrist CR demonstrated, in two of the three patients, the presence of changes in the bone profile of the wrist, MCP, PIP and DIP joints; erosions were detected in the distal ulna and radius, in the mid-carpal and CMC joints, in 14 MCP, 18 PIP and 11 DIP joints. In the other patient CR was normal. The mean Sharp-van der Heijde score was 192.6.

Both US and MRI revealed the presence of effusion/synovial hypertrophy in the radio-carpal, MCP and PIP joints of all patients. Erosions were found in the wrist, and MCP joints of all patients; erosive involvement was demonstrated in PIP and even DIP joints in two of the three patients.

In all the examined joints of both OA and RA patients, MRI/US fusion imaging revealed excellent agreement in bony pathology detection, particularly evident for osteophytes (Fig. 1A) and cortical bone erosions (Fig. 1B and C). Analysis of the randomly selected stored images acquired in both groups of patients demonstrated a

concordance between assessments of real time and static images (Fig. 1).

Discussion

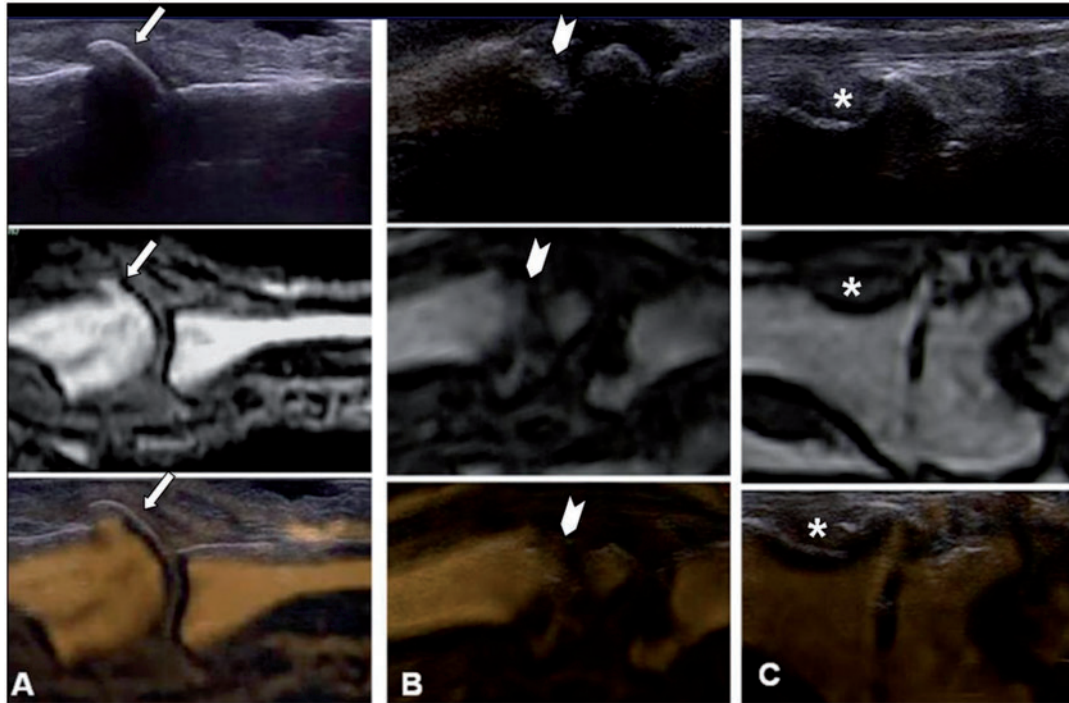
As far as we know, this is the first report of real-time fusion imaging between US and MRI in the hand and wrist of patients with OA and RA. The capability to perform fusion imaging provides the advantage of correlating findings from two imaging tools in a comprehensive examination. It has been applied in the evaluation of various disorders [14]. Recently, different imaging techniques have been employed in the building of a fusion image. By mixing PET with CT, Kostakoglu *et al.* [15] used this tool to stage various cancers and detect residual disease. By identifying internal liver lesions, Krucker *et al.* [16] demonstrated the feasibility of US-CT fusion imaging during US- and CT-guided biopsy, registering increased precision and accuracy of image-guided diagnosis and procedures. The electromagnetic tracking used in imaging guidance has demonstrated its accuracy, particularly during interventional procedures [17].

In different rheumatic diseases, US provides very accurate data about soft tissues and bony cortex abnormalities; however, it may lack sensitivity and therefore responsiveness in assessing bony tissue changes [13]. By its tomographic nature, MRI enables the evaluation of joint pathologies including bone marrow lesions; however, there may be some limitations in spatial resolution and functional assessment is still often difficult [16-20].

In the current study, real-time MRI/US fusion imaging of hand and wrist joints was performed in OA and RA patients. By using this new technique, we could confirm the co-registration of images obtained from the two modalities, particularly clear at the level of the cortical bone. In fact, we recorded excellent agreement in the fused images' assessment of osteophytes in OA patients and bone erosions in RA subjects (Fig. 1). This finding was supported by the concordance of real-time and static images evaluated by two independent sonographers. The novelty of our study is based on the real-time fusion process, carried out by using the virtual navigator system that was integrated in this particular US machine. This application provides the opportunity to merge real-time US with a retrospective data set of static MRI images, thus improving US operator confidence, particularly in difficult-to-scan patients. This new modality, therefore enhances the information provided by the individual modalities, with the potential to improve anatomical and functional correlations.

When used for disease follow-up and therapy monitoring, sonography is limited by the difficulty in identifying anatomical landmarks at subsequent US exams. Thus, employing fusion imaging should circumvent this problem by providing MRI reference points at subsequent US examinations. The most promising application of this new tool in rheumatic diseases is therefore its application in disease and therapy monitoring, enabling more reproducible and hopefully more responsive US assessment.

Fig. 1 MRI and US fusion imaging of the hand and wrist joints in OA and RA patients. **(A)** Second MCP joint of a patient with hand OA. US shows a pronounced osteophyte (\downarrow) as a hyperechoic step-up prominence on the dorsal aspect of the metacarpal head and IA soft tissues; MRI demonstrates the same osteophyte (\downarrow) as a hyperintense prominence on T₁-weighted image and shows bony components; MRI/US fusion imaging reveals a striking concordance in the bony profile visualization at the level of the osteophyte (\downarrow). **(B)** Fifth MCP joint of a patient with RA. US shows the presence of a deep cortical bone erosion (∇) at the level of the metacarpal head; MRI confirms the irregularity (∇) in the metacarpal profile; MRI/US fusion imaging shows good concordance (∇) after superposition of the two images. **(C)** Radio-carpal joint of a patient with RA. US demonstrates the presence of cortical bone erosions (*) at the level of the radial epiphysis and carpal surface; MRI shows cortical bone erosions (*) on T₁-weighted image in the wrist joint; fused US/MRI image demonstrates a perfect overlap in the areas of erosions (*).



However, the disadvantage of performing both imaging modalities, especially in terms of increase in costs and time spent for the imaging assessments, represents an obvious limitation to widespread use of this tool.

To our knowledge this study represents the first study of OA and RA patients using MRI/US real-time fusion imaging. However, further studies are needed in wider cohorts of patients to confirm our findings and determine the optimum application of this technology.

Rheumatology key message

- MRI/US fusion imaging provides consistent bony landmarks for potential longitudinal evaluation.

Acknowledgements

We thank Dr Riccardo Mancini for figure elaboration.

Disclosure statement: The authors have declared no conflicts of interest.

References

- 1 Arnett FC, Edworthy SM, Bloch DA *et al.* The American Rheumatism Association 1987. Revised criteria for the classification of rheumatoid arthritis. *Arthritis Rheum* 1988; 31:315–24.
- 2 Altman R, Alarcón G, Appelrouth D *et al.* The American College of Rheumatology criteria for the classification and reporting of osteoarthritis of the hand. *Arthritis Rheum* 1990;33:11:1601–10.
- 3 Voskuyl AE, Dijkmans BA. Remission and radiographic progression in rheumatoid arthritis. *Clin Exp Rheumatol* 2006;24:37–40.
- 4 Schmidt GP, Reiser MF, Baur-Melnyk A. Whole-body imaging of the musculoskeletal system: the value of MR imaging. *Skeletal Radiol* 2007;36:1109–19.
- 5 Duer-Jensen A, Ejbjerg B, Albrecht-Beste E *et al.* Does low-field dedicated extremity MRI (E-MRI) reliably detect bone erosions in rheumatoid arthritis? A comparison of two different E-MRI units and conventional radiography with high-resolution CT scanning. *Ann Rheum Dis* 2009; 68:1296–302.

- 6 Meenagh G, Filippucci E, Iagnocco A *et al.* Ultrasound imaging for the rheumatologist. VIII. Ultrasound imaging in osteoarthritis. *Clin Exp Rheumatol* 2007;25:172-5.
- 7 Filippucci E, Meenagh G, Delle Sedie A *et al.* Ultrasound imaging for the rheumatologist. XX. Sonographic assessment of hand and wrist joint involvement in rheumatoid arthritis: comparison between two- and three-dimensional ultrasonography. *Clin Exp Rheumatol* 2009;272:197-200.
- 8 Keen HI, Wakefield RJ, Grainger AJ, Hensor EM, Emery P, Conaghan PG. An ultrasonographic study of osteoarthritis of the hand: synovitis and its relationship to structural pathology and symptoms. *Arthritis Rheum* 2008;59:1756-63.
- 9 Keen HI, Wakefield RJ, Grainger AJ, Hensor AJ, Emery P, Conaghan PG. Can ultrasonography improve on radiographic assessment in osteoarthritis of the hands? A comparison between radiographic and ultrasonographic detected pathology. *Ann Rheum Dis* 2008;67:1116-20.
- 10 Schlaier JR, Warnat J, Dorenbeck U, Proescholdt M, Schebesch KM, Brawanski A. Image fusion of MR images and real-time ultrasonography: evaluation of fusion accuracy combining two commercial instruments, a neuronavigation system and a ultrasound system. *Acta Neurochir* 2004;146:271-6.
- 11 Boini S, Guillemin F. Radiographic scoring methods as outcome measures in rheumatoid arthritis: properties and advantages. *Ann Rheum Dis* 2001;60:817-27.
- 12 Kallman DA, Wigley FM, Scott W, Hochberg MC, Tobin JD. New radiographic grading scales for osteoarthritis of the hand. Reliability for determining prevalence and progression. *Arthritis Rheum* 1989;32:1584-91.
- 13 Wakefield RJ, Balint PV, Szkudlarek M *et al.* OMERACT 7 Special Interest Group. Musculoskeletal ultrasound including definitions for ultrasonographic pathology. *J Rheumatol* 2005;32:2485-7.
- 14 Singh AK, Kruecker J, Xu S *et al.* Initial clinical experience with real-time transrectal ultrasonography-magnetic resonance imaging fusion-guided prostate biopsy. *BJU Int* 2008;101:841-5.
- 15 Kostakoglu L, Hardoff R, Mirtcheva R, Goldsmith SJ. PET-CT fusion imaging in differentiating physiologic from pathologic FDG uptake. *Radiographics* 2004;24:1411-31.
- 16 Krücker J, Xu S, Glossop N *et al.* Electromagnetic tracking for thermal ablation and biopsy guidance: clinical evaluation of spatial accuracy. *J Vasc Interv Radiol* 2007;18:1141-50.
- 17 Kuhn SA, Romeike B, Walter J, Kalf R, Reichart R. Multiplanar MRI-CT fusion neuronavigation-guided serial stereotactic biopsy of human brain tumors: proof of a strong correlation between tumor imaging and histopathology by a new technical approach. *J Cancer Res Clin Oncol* 2009;135:1293-302.
- 18 Korompilias AV, Karantanas AH, Lykissas MG, Beris AE. Bone marrow edema syndrome. *Skeletal Radiol* 2009;38:425-36.
- 19 Boesen M, Ostergaard M, Cimmino MA, Kubassova O, Jensen KE, Bliddal H. MRI quantification of rheumatoid arthritis: Current knowledge and future perspectives. *Eur J Radiol* 2009;71:189-96.
- 20 Tan AL, Grainger AJ, Tanner SF *et al.* High-resolution magnetic resonance imaging for the assessment of hand osteoarthritis. *Arthritis Rheum* 2005;52:2355-65.