

# Ultrasound imaging for the rheumatologist

## XXIII. Sonographic evaluation of hand joint involvement in primary Sjögren's syndrome

L. Riente<sup>1</sup>, C.A. Scirè<sup>2</sup>, A. Delle Sedie<sup>1</sup>, C. Baldini<sup>1</sup>, E. Filippucci<sup>3</sup>, G. Meenagh<sup>4</sup>,  
A. Iagnocco<sup>5</sup>, C. Montecucco<sup>2</sup>, W. Grassi<sup>3</sup>, G. Valesini<sup>5</sup>, S. Bombardieri<sup>1</sup>

<sup>1</sup>*Cattedra di Reumatologia, Università di Pisa, Pisa, Italy;*

<sup>2</sup>*Cattedra di Reumatologia, IRCCS Policlinico S. Matteo, Università di Pavia, Pavia, Italy;*

<sup>3</sup>*Cattedra di Reumatologia, Università Politecnica delle Marche, Jesi, Italy;*

<sup>4</sup>*Department of Rheumatology, Antrim Hospital, Antrim, United Kingdom;*

<sup>5</sup>*Cattedra di Reumatologia, Università di Roma "La Sapienza", Rome, Italy.*

*Lucrezia Riente, MD*

*Carlo Alberto Scirè, MD*

*Chiara Baldini, MD*

*Andrea Delle Sedie, MD*

*Emilio Filippucci, MD*

*Gary Meenagh, MD*

*Annamaria Iagnocco, MD*

*Carlomaurizio Montecucco, MD,*

*Professor of Rheumatology*

*Walter Grassi, MD, Professor of*

*Rheumatology*

*Guido Valesini, MD, Professor of*

*Rheumatology*

*Stefano Bombardieri, MD, Professor*

*of Rheumatology*

*Please address correspondence and reprint requests to:*

*Dr Lucrezia Riente,*

*U.O. Reumatologia,*

*Dipartimento di Medicina Interna,*

*Università di Pisa,*

*Via Roma 67, Pisa 56126, Italy.*

*E-mail: l.riente@int.med.unipi.it*

*Received and accepted on August 20, 2009.*

*Clin Exp Rheumatol 2009; 27: 747-750.*

*© Copyright CLINICAL AND EXPERIMENTAL RHEUMATOLOGY 2009.*

**Key words:** Ultrasound, Sjögren, arthritis, tenosynovitis.

*Competing interests: none declared.*

### ABSTRACT

**Objective.** *To study the frequency and features of joint and tendon involvement in the hand of patients with primary Sjögren's syndrome (pSS) by musculoskeletal ultrasound (US) examination.*

**Methods.** *Forty-eight patients with pSS diagnosed according to the preliminary classification criteria proposed by the American-European Classification Criteria Group were enrolled in the study. Bilateral US examination of the 1<sup>st</sup>–5<sup>th</sup> metacarpophalangeal (MCP), 2<sup>nd</sup>–5<sup>th</sup> proximal interphalangeal (PIP) joints and of flexor tendons were performed. A semi-quantitative grading method (0 to 3) for scoring joint effusion, synovial proliferation and intra-articular power Doppler (PD) signal was used.*

**Results.** *We observed clear evidence of inflammatory arthritis in 9 (18.7%) patients. Bone erosions at MCP and/or PIP joint were visualized in 6 out of 48 (12.5%) patients. In 10 (20.8%) patients we imaged flexor tenosynovitis which appeared more frequent than in healthy subjects even if no statistically significant difference was detected.*

**Conclusion.** *US examination appears to be a useful imaging technique to study joint and soft tissue involvement in connective tissue diseases. The presence of bone erosions in pSS patients is unexpected. Future studies will hopefully concentrate more on defining the erosive capability of connective tissue disorders together with inflammatory involvement of tendons.*

### Introduction

Primary Sjögren's syndrome (pSS) is an autoimmune inflammatory disorder characterized by exocrine glandular

involvement and extra-glandular manifestations such as arthralgia, arthritis, myalgia, neuropathy, vasculitis, pulmonary, renal and gastrointestinal disease. Several studies report a high prevalence of arthralgia in pSS whilst the prevalence of true arthritis is still under debate (1-3). Reports vary between studies and it has been shown that arthritis occurred in 24% and in 17.6% respectively of 110 and 102 subjects with pSS (1, 4, 5). Furthermore, according to Tzioufas *et al.*, 50% of pSS patients experience episodes of arthritis at some stage during the course of the disease (6).

Musculoskeletal ultrasound (US) plays a key role in the assessment of joints and tendons in rheumatic diseases (7-15). To date only one study has evaluated articular involvement in pSS using sonographic examination of the knee joint (16).

The aim of our study is to investigate the US features in the hand in patients with pSS.

### Patients and methods

We performed a multicentre study in 4 different Rheumatology Units in Italy: University of Pisa, University of Pavia, Università Politecnica delle Marche and the Sapienza University of Rome. In each unit, US examinations were performed by a rheumatologist experienced in musculoskeletal US using a Logiq 9 (General Electrics Medical Systems, Milwaukee, WI) with a linear probe operating at 14 MHz. The inter-observer agreement of sonographers in detecting and scoring US features of joint inflammation and bone erosions has been previously calculated and reported in a recent study (17). Good-to-excellent agreement rates were found in the detection and semiquantitative

assessment of US signs of both joint inflammation and bone erosions, and good agreement rates between sonographers were also found in the detection of tenosynovitis.

#### Patients

Forty-eight patients (3 males and 45 females, mean age: 57 years, ranging from 81 to 24 years; mean disease duration: 4.7 years, ranging from 1 to 31 years) with pSS were enrolled in the study. The diagnosis of pSS was established according to the preliminary classification criteria proposed by the American-European Classification Criteria (AECC) Group (18). At the time of the US examination, 31 out of 48 (64.5%) patients complained of pain in the hands and 12 out of 48 (25%) also showed swelling of metacarpophalangeal (MCP) or proximal interphalangeal (PIP) joints. However, a history of painful hands was mentioned by 47 out of 48 patients. After informed consent was obtained, serum samples were taken from the patients and immediately stored at -20°C until tested for IgG antibodies to viral citrullinated peptides (VCP) (19), rheumatoid factor (RF), antinuclear antibodies and antibodies to Ro(SSA) and La(SSB) antigens. Only patients negative for anti VCP antibodies were eligible for the study. Moreover, all the patients were submitted to minor salivary gland biopsy. Focus score  $\geq 1$  was detected in 40 patients (grade 3 and 4 according to the Chisholm and Mason scoring) (20). Patients with a focus score  $< 1$  were positive for antibodies to Ro(SSA) and La(SSB) antigens and fulfilled the AECC criteria. The clinical characteristics of the patients are summarized in Table I.

#### Control group

As controls we enrolled 40 healthy volunteers (3 males and 37 females)

with mean age 52 years, max. 75 and min. 28 years.

#### US assessment

Bilateral US examination of the 1<sup>st</sup> – 5<sup>th</sup> MCP, 2<sup>nd</sup> – 5<sup>th</sup> PIP joints and of flexor tendons were performed using a multi-planar scanning technique. Joint effusion, synovial hypertrophy, bone erosion and tenosynovitis were diagnosed by US according to the preliminary definitions provided by the Outcome Measures in Rheumatoid Arthritis Clinical Trials (OMERACT) Special Interest Group for Musculoskeletal Ultrasound in Rheumatology (21). A semi-quantitative grading method (0 to 3) for scoring joint effusion, synovial proliferation and intra-articular power Doppler (PD) signal was used (17, 22-24).

#### Statistical analysis

Qualitative variables were compared using contingency table analysis and Fisher's exact test. *P*-values  $< 0.05$  were considered statistically significant.

#### Results

##### pSS patients

In 20 out of 48 (41.6%) patients US examination disclosed joint effusion with or without synovial proliferation. More precisely, we observed synovial proliferation (grade 2) with joint effusion in at least one MCP or PIP joint in 4 out of 48 (8.3%) patients and in 3 of them also a positive PD signal. Osteophytes were not imaged in any of the 4 patients, but in 1 of them bone erosions (at the 2<sup>nd</sup> and 5<sup>th</sup> metacarpal heads) were visualized. Only one of the 4 patients was positive for RF; both auto-antibodies to Ro(SSA) and La(SSB) were present in another patient, while only anti Ro(SSA) antibodies were detected in the last two subjects.

In 5 other patients, synovial proliferation (grade 1) with joint effusion, but

no PD signal, was visualized at MCP and PIP joints with no evidence of osteoarthritic change.

In the remaining patients we imaged only mild effusion without signs of synovial hypertrophy in 11 out of 20. Bony irregularities due to osteoarthritis were present in 2 subjects within this last group.

In 10 out of 48 (20.8%) patients we observed flexor tendon effusion with synovial hypertrophy but no PD signal.

Bone erosions at MCP and/or PIP were visualized in 6 out of 48 (12.5%) patients and in 5 of them features of inflammatory arthritis were not detected by US. In addition, there was no US evidence of osteoarthritis change in any of these 6 individuals who had hand pain or gave a history. Laboratory tests revealed positivity for RF in 5 of the 6 subjects, both antibodies to Ro(SSA) and La(SSB) in 1 out of 6 and only antibodies to Ro(SSA) in 4 patients.

Pathological findings detected by US examination of hand in pSS patients are reported in Table II.

##### Healthy control group

In the group of healthy controls minimal effusion without synovial proliferation at MCP or PIP was discovered in 12 out of 40 (30%) subjects. There was no significant difference in the frequency of effusion without synovial proliferation in pSS and the control group ( $p=0.27$ ). In 2 other individuals, who also showed osteoarthritic change, mild effusion at MCP or PIP was associated to slight synovial proliferation but no PD signal.

No bone erosions were detected in any controls

Flexor tenosynovitis was visualized in 2 out of 40 (5%) normal subjects.

The frequency of tenosynovitis in pSS patients is higher than in healthy controls (20.8% vs. 5%,  $p=0.057$ ) with a statistically significant trend.

**Table I.** Main characteristics of patients with pSS.

Patient number	M/F	Mean age years (range)	Rheumatoid factor (prevalence %)	Antibodies to VCP (prevalence %)	Positive lip biopsy Focus score $\geq 1$ (prevalence %)	Antibodies to Ro(SSA) $\pm$ La(SSB) (prevalence %)
48	3/45	57 (81-24)	28/48 (58%)	0/48 (0%)	40/48 (83%)	29/48 (60%)

M/F: male/female ratio; VCP: viral citrullinated peptides.

**Table II.** Pathological findings detected by US examination of hand in pSS patients.

	no. of patients
Joint effusion with synovial proliferation in at least one MCP or PIP joint (grade 2)	4/48
Joint effusion with synovial proliferation in at least one MCP or PIP joint (grade 1)	5/48
Joint effusion without synovial proliferation	11/48
flexor tenosynovitis	10/48
Bone erosions at MCP and/or PIP joints	6/48

### Discussion

Articular signs and symptoms are frequent in pSS. The true prevalence of joint and tendon involvement in this connective tissue disorder remain unclear. In 1993, Pease *et al.* reviewed the clinical course of 48 pSS patients and reported that the incidence of arthritis and/or arthralgia was 54% and in a third of these patients it was the presenting feature prior to the sicca syndrome (25). A study in elderly patients revealed that articular involvement was present in 29% of the subjects (26). Furthermore, arthritis was reported in 12.5% and 9.8% of patients with early and late onset pSS respectively (27).

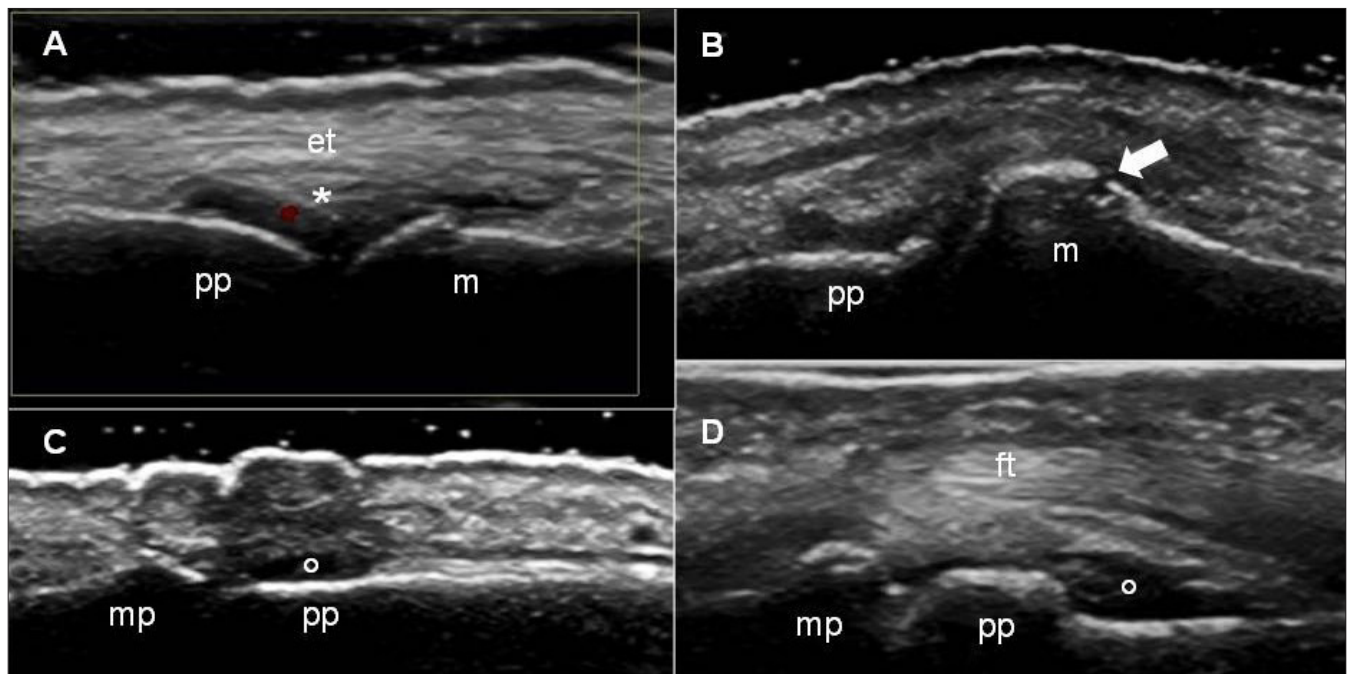
Kruize *et al.* failed to observe arthritis (4) in a small number of subjects followed longitudinally (1, 5).

Important advances have been made in the field of musculoskeletal US confirming its eminent position in the detailed depiction of the anatomical changes in joints and tendons in rheumatic disorders. The study by Iagnocco *et al.* remains the pivotal study using US to investigate focal joint involvement in pSS describing the presence of synovial thickening and slight synovitis within the knee (16).

Our study showed a high proportion of patients with pSS reporting hand pain. Subsequent US examination showed

clear evidence of inflammatory arthritis in 9 (18.7%) patients. This is consistent with most of the smaller studies performed to date (1, 5). Interestingly, 6 patients had MCP and PIP erosions, detected in 5 out of these 6 patients in the absence of cardinal signs suggestive of active inflammatory disease. The origin of these findings is unclear but may represent hallmark features of previous inflammatory activity within these particular joints.

The study by Wright *et al.* reported erosive changes within the MCP joints of patients with systemic lupus erythematosus (SLE) (8 out of 17) (28). Some lupus patients may develop arthritis with erosive features (the "rhumus" hand) but usually radiographs of hands in these patients do not reveal erosive changes and the disorder is widely viewed as being non-erosive. The presence of bone erosions in both pSS and SLE patients is unexpected. US is able to visualize even minimal interruptions of the bony cortex so the US technique is now recognized as an imaging modality with higher sensitivity than x-ray in the detection of small erosions



**Fig. 1.** A. Dorsal longitudinal scan of the 3rd metacarpo-phalangeal joint. Power Doppler technique showing the presence of signal in the fat pad. pp: proximal phalanx; m: metacarpal head; et: extensor tendon; \*: fat pad  
 B. Dorsal longitudinal scan of the 1st metacarpo-phalangeal joint. Gray scale US. pp: proximal phalanx; m: metacarpal head; the arrow indicates an erosion  
 C. Dorsal longitudinal scan of the 2nd interphalangeal joint. Gray scale US. pp: proximal phalanx; mp: middle phalanx; °: shows the effusion in the capsula  
 D. Volar longitudinal scan of the 2nd interphalangeal joint. Gray scale US. pp: proximal phalanx; mp: middle phalanx; ft: flexor tendons; °: shows the effusion in the capsula.



which evade traditional radiography (7, 8, 29).

Our 6 patients with bone erosion on US examination had had regular clinical follow up at our Rheumatology Units and the typical manifestations of pSS, according to the preliminary classification criteria proposed by the American-European Classification Criteria, had been observed. None of the 6 patients described symmetrical arthritis or had rheumatoid nodules. The sonographic demonstration of bone erosion might however suggest the possibility of co-existent rheumatoid arthritis or suggest the presence of a subset of pSS patients with aggressive arthritis. We think that a strict US follow-up should be performed in pSS patients, particularly when positive for RF, to establish the more correct diagnosis and effective therapy in order to avoid structural damage.

A minimal effusion at MCP or PIP, without synovial proliferation, was visualized in 11 out of 48 pSS patients and also in 12 out of 40 healthy subjects with no statistically significant difference (30).

Flexor tenosynovitis in pSS patients appeared more frequent than in healthy subjects but no statistically significant difference was detected. Further studies on larger populations may help to clarify the prevalence further.

US examination appears to be a useful imaging technique to study joint and soft tissue involvement in connective tissue diseases. Future studies will hopefully concentrate more on defining the erosive capability of these disorders together with inflammatory involvement of tendons. Future comparisons between US and MRI could be very interesting in the follow-up of pSS patients and could help further our understanding of this disease.

#### Link

For ultrasound images, go to [www.clinexprheumatol.org/ultrasound](http://www.clinexprheumatol.org/ultrasound)

#### References

- HAGA HJ, PEEN E: A study of the arthritis pattern in primary Sjögren's syndrome. *Clin Exp Rheumatol* 2007; 25: 88-91.
- KELLY CA, FOSTER H, PAL B *et al.*: Primary Sjögren's syndrome in north east England – a longitudinal study. *Br J Rheumatol* 1991; 30: 437-42.
- GARCÍA-CARRASCO M, RAMOS-CASALS M, ROSAS J *et al.*: Primary Sjögren syndrome: clinical and immunologic disease patterns in a cohort of 400 patients. *Medicine* (Baltimore). 2002; 81: 270-80.
- KRUIZE AA, HENÉ RJ, VAN DER HEIDE A *et al.*: Long-term follow-up of patients with Sjögren's syndrome. *Arthritis Rheum* 1996; 39: 297-303.
- PERTOVAARA M, PUKKALA E, LAIPPALA P, MIETTINEN A, PASTERNAK A: A longitudinal cohort study of Finnish patients with primary Sjögren's syndrome: clinical, immunological, and epidemiological aspects. *Ann Rheum Dis* 2001; 60: 467-72.
- TZIOUFAS AG, MITSIAS DI, MOUTSOPOULOS H: Sjögren's syndrome. In HOCHBERG MC, SILMAN AJ, SMOLEN JS, WEINBLATT ME, WEISMAN MH (Eds): *Rheumatology*. Philadelphia, Mosby Elsevier 2008: 1341-52
- FILIPPUCCI E, IAGNOCCO A, MEENAGH G *et al.*: Ultrasound imaging for the rheumatologist. *Clin Exp Rheumatol* 2006; 24: 1-5.
- FILIPPUCCI E, IAGNOCCO A, MEENAGH G *et al.*: Ultrasound imaging for the rheumatologist VII. Ultrasound imaging in rheumatoid arthritis. *Clin Exp Rheumatol* 2007; 25: 5-10.
- MEENAGH G, FILIPPUCCI E, IAGNOCCO A *et al.*: Ultrasound imaging for the rheumatologist VIII. Ultrasound imaging in osteoarthritis. *Clin Exp Rheumatol* 2007; 25: 172-5.
- RIENTE L, DELLE SEDIE A, FILIPPUCCI E *et al.*: Ultrasound imaging for the rheumatologist IX. Ultrasound imaging in spondyloarthritis. *Clin Exp Rheumatol* 2007; 25: 349-53.
- DELLE SEDIE A, RIENTE L, IAGNOCCO A *et al.*: Ultrasound imaging for the rheumatologist X. Ultrasound imaging in crystal-related arthropathies. *Clin Exp Rheumatol* 2007; 25: 513-7.
- RIENTE L, DELLE SEDIE A, FILIPPUCCI E *et al.*: Ultrasound imaging for the rheumatologist XIV. Ultrasound imaging in connective tissue diseases. *Clin Exp Rheumatol* 2008; 26: 230-3.
- DELLE SEDIE A, RIENTE L, FILIPPUCCI E *et al.*: Ultrasound imaging for the rheumatologist XV. Ultrasound imaging in vasculitis. *Clin Exp Rheumatol* 2008; 26: 391-4.
- KANE D, GRASSI W, STURROCK R, BALINT PV: Musculoskeletal ultrasound—a state of the art review in rheumatology. Part 2: Clinical indications for musculoskeletal ultrasound in rheumatology. *Rheumatology* (Oxford) 2004; 43: 829-38.
- KANE D, BALINT PV, STURROCK R, GRASSI W: Musculoskeletal ultrasound – a state of the art review in rheumatology. Part 1: Current controversies and issues in the development of musculoskeletal ultrasound in rheumatology. *Rheumatology* (Oxford) 2004; 43: 823-8.
- IAGNOCCO A, COARI G, PALOMBI G, VALESINI G: Knee joint synovitis in Sjögren's syndrome. Sonographic study. *Scand J Rheumatol* 2002; 31: 291-5.
- FILIPPUCCI E, MEENAGH G, DELLE SEDIE A *et al.*: Ultrasound imaging for the rheumatologist. XX. Sonographic assessment of hand and wrist joint involvement in rheumatoid arthritis: comparison between two- and three-dimensional ultrasonography. *Clin Exp Rheumatol* 2009; 27: 197-200.
- VITALI C, BOMBARDIERI S, MOUTSOPOULOS HM *et al.*: Preliminary criteria for the classification of Sjögren's syndrome. Results of a prospective concerted action supported by the European Community. *Arthritis Rheum* 1993; 36: 340-7.
- ANZILOTTI C, RIENTE L, PRATESI F *et al.*: IgG, IgA, IgM antibodies to a viral citrullinated peptide in patients affected by rheumatoid arthritis, chronic arthritides and connective tissue disorders. *Rheumatology* (Oxford) 2007; 46: 1579-82.
- CHISHOLM DM, MASON DK: Labial salivary gland biopsy in Sjögren's disease. *J Clin Pathol* 1968; 21: 656-60.
- WAKEFIELD RJ, BALINT PV, SZKUDLAREK M *et al.*: Musculoskeletal ultrasound including definitions for ultrasonographic pathology. *J Rheumatol* 2005; 32: 2485-7.
- WAKEFIELD RJ, D'AGOSTINO MA, IAGNOCCO A *et al.*: The OMERACT ultrasound group: status of current activities and research directions. *J Rheumatol* 2007; 34: 848-51
- MEENAGH G, FILIPPUCCI E, DELLE SEDIE A *et al.*: Ultrasound imaging for the rheumatologist. XVIII. Ultrasound measurements. *Clin Exp Rheumatol* 2008; 26: 982-5
- IAGNOCCO A, EPIS O, DELLE SEDIE A *et al.*: Ultrasound imaging for the rheumatologist. XVII. Role of colour Doppler and power Doppler. *Clin Exp Rheumatol* 2008; 26: 759-62.
- PEASE CT, SHATTLES W, BARRETT NK, MAINI RN: The arthropathy of Sjögren's syndrome. *Br J Rheumatol* 1993; 32: 609-13.
- GARCÍA-CARRASCO M, CERVERA R, ROSAS J *et al.*: Primary Sjögren's syndrome in the elderly: clinical and immunological characteristics. *Lupus* 1999; 8: 20-3.
- HAGA HJ, JONSSON R: The influence of age on disease manifestations and serological characteristics in primary Sjögren's syndrome. *Scand J Rheumatol* 1999; 28: 227-32.
- WRIGHT S, FILIPPUCCI E, GRASSI W, GREY A, BELL A: Hand arthritis in systemic lupus erythematosus: an ultrasound pictorial essay. *Lupus* 2006; 15: 501-6.
- WAKEFIELD RJ, GIBBON WW, CONAGHAN PG *et al.*: The value of sonography in the detection of bone erosions in patients with rheumatoid arthritis: a comparison with conventional radiography. *Arthritis Rheum* 2000; 43: 2762-70.
- GRASSI W, FILIPPUCCI E: Ultrasonography and the rheumatologist. *Curr Opin Rheumatol* 2007; 19: 55-60.