

AperTO - Archivio Istituzionale Open Access dell'Università di Torino

## Functional Connectivity Networks in Asymptomatic and Symptomatic DYT1 Carriers

### This is the author's manuscript

*Original Citation:*

*Availability:*

This version is available <http://hdl.handle.net/2318/1615135> since 2016-11-22T00:25:34Z

*Published version:*

DOI:10.1002/mds.26725

*Terms of use:*

Open Access

Anyone can freely access the full text of works made available as "Open Access". Works made available under a Creative Commons license can be used according to the terms and conditions of said license. Use of all other works requires consent of the right holder (author or publisher) if not exempted from copyright protection by the applicable law.

(Article begins on next page)

# Functional Connectivity Networks

## in Asymptomatic and Symptomatic DYT1 Carriers

Enrico Premi, MD,<sup>1</sup> Matteo Diano, PsyD, PhD,<sup>2,3</sup> Stefano Gazzina, MD,<sup>1</sup> Franco Cauda, PsyD, PhD,<sup>2,3</sup> Vera Gualeni, MD,<sup>1</sup> Michele Tinazzi, MD, PhD,<sup>4</sup> Mirta Fiorio, MD, PhD,<sup>4</sup> Paolo Liberini, MD,<sup>1</sup> Clara Lazzarini, MD,<sup>5</sup> Silvana Archetti, PhD,<sup>6,7</sup> Giorgio Biasiotto, PhD,<sup>6,7</sup> Marinella Turla, MD,<sup>8</sup> Valeria Bertasi, MD,<sup>8</sup> Maria Cotelli, MD,<sup>8</sup> Roberto Gasparotti, MD,<sup>9</sup> Alessandro Padovani, MD, PhD,<sup>1</sup> and Barbara Borroni, MD<sup>1\*</sup>

<sup>1</sup>Centre for Ageing Brain and Neurodegenerative Disorders, Neurology Unit, Department of Clinical and Experimental Sciences, University of Brescia, Brescia, Italy <sup>2</sup>GCS fMRI Koelliker Hospital, Turin, Italy <sup>3</sup>Department of Psychology, University of Turin, Turin, Italy <sup>4</sup>Department of Neurological and Movement Sciences, University of Verona, Verona, Italy <sup>5</sup>Neurophysiology Department, University Hospital "Spedali Civili", Brescia, Italy <sup>6</sup>Department of Molecular and Translational Medicine, University of Brescia, Brescia, Italy <sup>7</sup>Biotechnology Laboratory, Department of Diagnostic, "Spedali Civili" Hospital, Brescia, Italy <sup>8</sup>Neurology Unit, Valle Camonica Hospital, Brescia, Italy <sup>9</sup>Neuroradiology Unit, University of Brescia, Brescia, Italy

### ABSTRACT

**Background:** DYT1 mutation is characterized by focal to generalized dystonia and incomplete penetrance. To explore the complex perturbations in the different neural networks and the mutual interactions among them, we studied symptomatic and asymptomatic DYT1 mutation carriers by resting-state functional MRI.

**Methods:** A total of 7 symptomatic DYT1, 10 asymptomatic DYT1, and 26 healthy controls were considered. Resting-state functional MRI (Oxford Centre for Functional MRI of the Brain) [FMRIB] Software Library (FSL) MELODIC, dual regression, (as a toolbox of FSL, with Nets is referred to "networks") (FSLNets) (<http://fsl.fmrib.ox.ac.uk/fsl/fslwiki/FSLNets>) was performed on 9 resting-state neural networks.

**Results:** DYT1 mutation signature (symptomatic DYT1 and asymptomatic DYT1) was characterized by increased connectivity in the dorsal attention network and in the left fronto-parietal network. Functional correlates of symptomatic DYT1 patients (symptomatic DYT1 vs healthy controls) showed increased connectivity in the sensorimotor network.

**Discussion:** This study argues that DYT1 dystonia is a network disorder, with crucial nodes in sensory-motor integration of posterior parietal structures. A better characterization of cortical networks involved in dystonia is crucial for possible neurophysiological therapeutic interventions. V<sup>C</sup> 2016 International Parkinson and Movement Disorder Society

Dystonia is a neurological syndrome clinically defined by focal or generalized sustained muscle contractions, postures, and/or involuntary movements.<sup>1</sup> The most frequent genetic form of primary torsion dystonia is the autosomal dominant DYT1 mutation,<sup>2</sup> with incomplete penetrance, clinical presentation ranging from focal to generalized dystonia, and an onset in childhood or in early adulthood.

The involvement of the basal ganglia, cerebellum,<sup>3,4</sup> supplementary motor cortex, and parietal regions,<sup>5,6</sup> along with increased sensorimotor connectivity activation<sup>7</sup> (as also evident in sporadic forms of dystonia)<sup>4,8</sup> have been described so far.

Even if the neurological basis of the disease is not well understood, neuroimaging data support the hypothesis that dystonia is a disorder of functional connectivity.<sup>9</sup> An increased cortical excitability, decreased cortical inhibition, or impaired sensorimotor integration have been postulated as possible pathogenic mechanisms.<sup>7,10,11</sup> Furthermore, different patterns of functional neural perturbations have been described, considering genetic status (asymptomatic vs clinically evident).<sup>4,12</sup>

The aim of the present study was to further delineate functional abnormalities in DYT1 symptomatic and asymptomatic mutation carriers using resting-state MRI with dual regression<sup>13,14</sup> approach as well as between-network relationship with the (as a toolbox of FSL, with Nets is referred to “networks”) (FSLNets) (<http://fsl.fmrib.ox.ac.uk/fsl/fslwiki/FSLNets>) package.

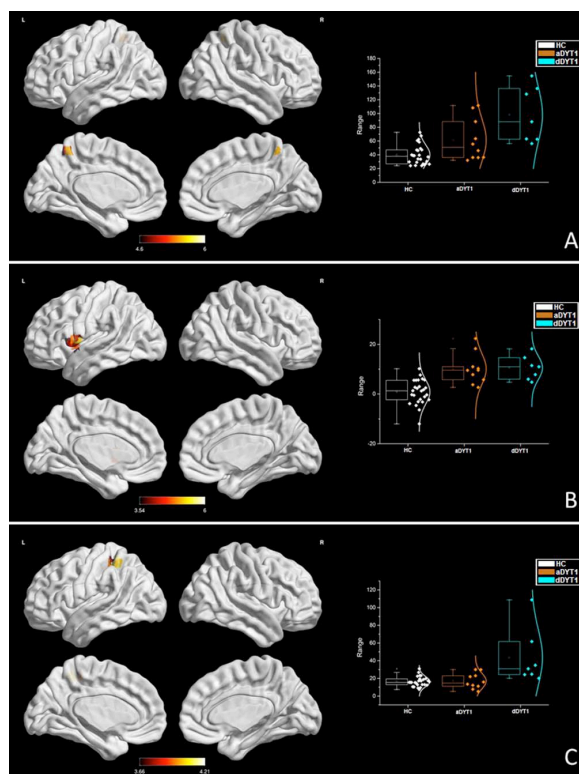


FIG. 1. Functional connectivity alterations in DYT1. A: Dorsal attention network (DAN): dDYT1>aDYT1>HC contrast is shown. B: Left frontoparietal network (FPN): dDYT1>aDYT1>HC contrast is shown. C: Sensorimotor network (SMN): dDYT1>HC contrast is shown. In panels A, B, and C, the box and whisker plots represent the b parameters for each of the patients in each group, extracted from the second stage of dual regression. In all aforementioned comparisons, significant findings (t value) are superimposed on a 3D ICBM152 surface brain map using BrainNet viewer<sup>34</sup> with maximum voxel projection into the 3D surface.  $P < .05$  corrected for multiple comparisons. dDYT1, patients carrying DYT1 mutation; aDYT1, asymptomatic patients carrying DYT1 mutation; HC, healthy controls; L, left; R, right. [Color figure can be viewed at

wileyonlinelibrary.com.]this novel approach to genetic dystonia, we evaluated the intrinsic network signature and symptom-related changes in DYT1 mutation to explore (1) at-rest functional brain networks alterations that characterized the different phases of DYT1 disease (considering asymptomatic DYT1 carriers [aDYT1] and dystonic patients bearing DYT1 mutation [dDYT1]) and (2) complex mutual association among brain functional networks involved in DYT1 disease.

## Methods

### Participants

Participants carrying a DYT1 mutation, belonging to 2 apparently unrelated families from the same geo-graphical area, were recruited from the Neurological Unit, University of Brescia, Italy (see Supplementary Figure 1).<sup>16,17</sup> A control group (HC) was enrolled from healthy volunteers for imaging analyses.

Each participant underwent neurological examination, and clinical scales to assess dystonia, that is, the Fahn-Marsden Rating Scale,<sup>18</sup> the Unified Dystonia Rating Scale,<sup>19</sup> and the Global Dystonia Rating Scale.<sup>19</sup>

### Neuroimaging Data Processing

Voxel-based morphometry on T1 images was applied (segmentation, normalization in Montreal Neurological Institute (MNI) template, 12-mm spatial smoothing).<sup>20</sup> The following 3 separate groups were considered: (1) DYT1 dystonic patients (n = 7); (2) asymptomatic DYT1 mutation carriers (n = 10); and (3) healthy participants (n = 26). The grey matter (GM) maps analysis was adjusted for the total intracranial volume (intracranial volume [ICV] - GM volume - white matter volume - cerebrospinal fluid volume) and age. A family-wise error correction for multiple comparisons at whole-brain level with a  $p < .05$  was considered.

Echo-planar imaging (EPI) data for resting state acquisition (8 minutes, 195 volumes, eyes closed, whole-brain acquisition) was preprocessed using (Oxford Centre for Functional MRI of the Brain [FMRIB] Software Library) (FSL) software (<http://fsl.fmrib.ox.ac.uk/fsl/fslwiki/FSL>) (motion correction, slice timing correction, spatial smoothing at 7 mm, temporal filtering, MNI152 spatial normalization).<sup>21</sup> To obtain common spatial cerebral networks, we used MELODIC (FSL) with a temporal concatenation approach producing 9 relevant common cerebral networks (dorsal attention network [DAN], sensorimotor network [SMN], default mode network, left and right frontoparietal networks [FPNs], executive network, visual network, ventral salience network, and the cerebellar network].

The set of spatial maps from the group analysis was used to generate participant-specific versions of the spatial maps and associated time-series using dual regression approach.<sup>13</sup> First, for each participant, the group-average set of spatial maps was regressed into the participant's 4-dimensional (4D) space-time dataset. This results in a set of participant-specific time-series, 1 per group-level spatial map. Then, the same time-series were regressed into the same 4D dataset, resulting in a set of participant-specific spatial maps, one per group-level spatial map. Group differences were explored by FSL's randomize permutation-testing tool (5000 permutations, threshold-free cluster enhancement to estimate cluster activation) with  $p < .05$  corrected for multiple comparisons, considering age as nuisance variable. To study the independent component analysis (ICA) network interactions and how these networks are functionally connected, we used FSLNets package (<http://fsl.fmrib.ox.ac.uk/fsl/fslwiki/FSLNets>), that is, a set of MATLAB scripts (Mathworks Inc., Sherborn, MA, USA). First, the Ridge regression partial correlation ( $\rho \geq 0.1$ ) was calculated from the normalized time courses (derived for the ICA components). Second, the obtained partial correlation matrices

were z transformed and corrected for temporal autocorrelation. Third, we performed 1-group t

tests on of the entire sample (controls 1 patients) to look at the degree of correlation between networks in the entire population of our study. Fourth, the z-stat from 1-group t tests was clustered using hierarchical clustering. The hierarchical clustering was calculated using linkage (part of MATLAB scripts) with Ward's method (in FSLNets the script is called "nets\_hierarchy"). See Supplementary Materials for further details.

## Results

The clinical characteristics of the affected partici-pants ranged from focal dystonia (neck, hand, or foot) to generalized dystonia (see Supplementary Table 1); all patients were under treatment with botulinum tox-in only at different regimes considering the clinical presentation. Moreover, 26 age-matched healthy con-trols were included for imaging analysis (mean age 49.3 years; 18 (69%) were female).

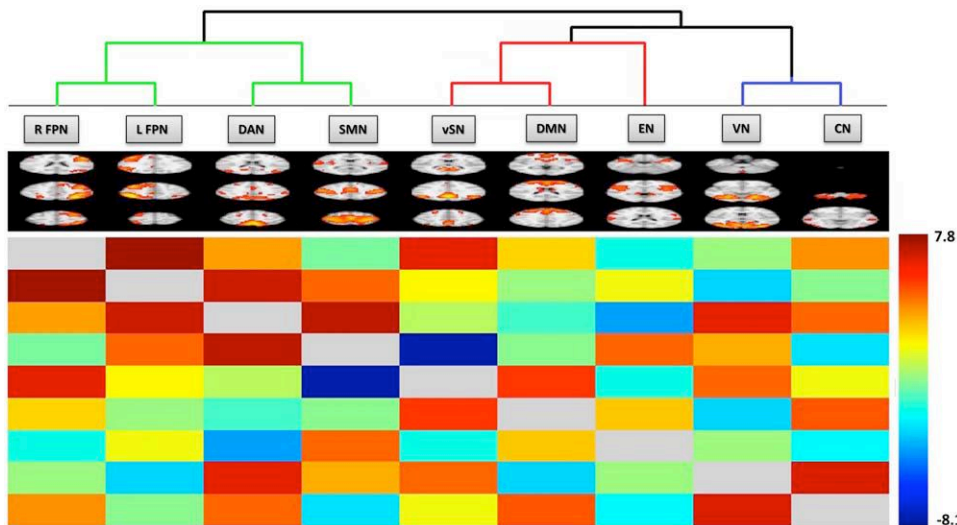


FIG. 2. Matrix Z value from 1-sample t test of 9 neural networks time courses, for the whole group of participants. The resulting nodes are clustered hierarchically by using the information about temporal analysis extracted with partial Ridge regression with rho set to 0.1 matrix, providing a tendency of how the cerebrals networks are associated each other. The color bar represents the Z score range of values. DAN, dorsal attention network; SMN, sensorimotor network; DMN, default mode network; FPN, frontoparietal networks (left and right); EN, executive network; VN, visual network; vSN, ventral salience network; CN, cerebellar network. [Color figure can be viewed at [wileyonlinelibrary.com](http://wileyonlinelibrary.com).]

By voxel based-morphometry, no significant differences in regional brain atrophy between dDYT1 vs HC, aDYT1 vs HC and dDYT1 vs aDYT1 were reported.

DYT1 mutation signature (dDYT1 and aDYT1 vs HC) was characterized by increased connectivity in DAN (precuneus region). Plot analysis of the mean of b parameters extracted from the significant clusters (for further details, see Supplementary Materials) showed progressive increases of functional connectivity from aDYT1 to dDYT1 when compared with the HC (see Fig. 1A and Supplementary Table 2). Furthermore, left FPN (inferior frontal operculum) showed enhanced connectivity in DYT1 carriers when compared with the HC, with comparable connectivity in both dDYT1 and aDYT1 (Fig. 1B and Supplementary Table 2).

Functional correlates of symptomatic DYT1 patients (dDYT1 vs HC) showed increases of functional connectivity in SMN (postcentral regions; Fig. 1C and Supplementary Table 2).

Finally, looking at the clustering levels by between-network correlations, left and right FPNs were associated as well as DAN and SMN. At different clustering levels, all 4 networks affected in DYT1 pathology (FPNs, DAN, and SMN) were all functionally inter-connected (Fig. 2)

## Discussion

In the present work, we investigated the functional brain signature of DYT1 mutation (exploring intra- and inter-network connectivity) in both symptomatic and asymptomatic carriers.

DYT1 carriers exhibited an increased activation of parietal association and fronto-parietal regions, and symptomatic carriers revealed an additional increase of brain connectivity in the SMN. Furthermore, all of these networks (FPNs, SMN, DAN) were functionally intercorrelated at different levels, supporting the idea that a complex functional perturbation (rather than the involvement of single networks one at a time) might lead to DYT1 dystonia.

In this sense, DYT1-dystonia increased cortical excitability is not restricted to sensorimotor cortex, and mechanisms of high-order integration are affected.<sup>1,11</sup> Precuneus is involved in spatial attention, multisensory integration, and different action-related functions together with frontal areas.<sup>22,23</sup> Optimal movement execution requires accurate integration of sensory inputs for the best movement planning.<sup>23</sup> In this view, asymptomatic DYT1 carriers showed impaired temporal discrimination thresholds,<sup>16</sup> motor sequence learning, and altered brain activation responses.<sup>17</sup>

The increased connectivity of parietal and frontal networks could be considered a compensatory mechanism of a disorganized representation of sensory information. Even if the role of hyperactivation in resting-state functional magnetic resonance imaging (RS-fMRI) is not completely defined, it might be hypothesized that functionally connected brain regions try to counteract the ongoing pathological process.<sup>24-27</sup> Comparable findings have been reported in functional imaging studies of sporadic dystonia,<sup>28-31</sup> suggesting similarity with hereditary forms of the disorder.

Penetrance in DYT1 dystonia is driven by the over-activation of the sensorimotor network, as already widely described in dystonic patients.<sup>10</sup> As a result of a reduction of intracortical inhibition,<sup>12</sup> an increase of cortical network activity could be the result of broad changes in high-order multimodal sensory integrative processes.<sup>1</sup> How dorsal attention network activity

influences on sensory motor network overactivation, leading to dystonia, is not clear yet.

Specific pathological features in DYT1 dystonia have been ruled out by an autopsy study, with no consistent disease, arguing that biochemical changes were more relevant than morphological alterations.<sup>32</sup>

Indeed, we did not find the involvement of 2 previously described actors in DYT1 (basal ganglia and cerebellar networks).<sup>4,28,33</sup> With regard to the basal ganglia, the present methodology prevented us from performing a careful analysis of these structures for an intrinsic limit of this approach; probably the variability in the basal ganglia across participants did not allow us the construction of a common subcortical network. The cerebellum has received increasing attention as an important neuroanatomical structure in the pathophysiology of the disease.<sup>4,23</sup> However, the small sample size of our 3 groups represented the main constrain to explore resting-state functional connectivity of the cerebellum.

This work entails some significant limits that need to be acknowledged. Beyond the small sample size that limited the evaluation of regions of interest in this disease, the dDYT1 group was clinically heterogeneous, including participants with focal and generalized dystonia. Finally, the comparison with sporadic or other genetic dystonia, as well as the association between functional brain connectivity and clinical symptoms, should be carried out in larger samples.

In conclusion, the present study argues that DYT1 dystonia is a network disorder, with crucial nodes in the sensory motor integration of posterior parietal structures. A better characterization of cortical networks involved in dystonia is crucial for possible neurophysiological therapeutic interventions.



## References

1. 1. Carbon M, Argyelan M, Habeck C, et al. Increased sensorimotor network activity in DYT1 dystonia: a functional imaging study. *Brain* 2010;133(Pt 3):690-700.
1. 2. de Carvalho Aguiar PM, Ozelius LJ. Classification and genetics of dystonia. *Lancet Neurol* 2002;1(5):316-325.
1. 3. Draganski B, Schneider SA, Fiorio M, et al. Genotype-phenotype interactions in primary dystonias revealed by differential changes in brain structure. *NeuroImage* 2009;47(4):1141-1147.
1. 4. Eidelberg D, Moeller JR, Antonini A, et al. Functional brain networks in DYT1 dystonia. *Ann Neurol* 1998;44(3):303-312.
1. 5. Carbon M, Kingsley PB, Su S, et al. Microstructural white matter changes in carriers of the DYT1 gene mutation. *Ann Neurol* 2004; 56(2):283-286.
1. 6. Carbon M, Su S, Dhawan V, Raymond D, Bressman S, Eidelberg D. Regional metabolism in primary torsion dystonia: effects of penetrance and genotype. *Neurology* 2004;62(8):1384-1390.
1. 7. Niethammer M, Carbon M, Argyelan M, Eidelberg D. Hereditary dystonia as a neurodevelopmental circuit disorder: Evidence from neuroimaging. *Neurobiol Dis* 2011;42(2):202-209.
1. 8. Dresel C, Li Y, Wilzeck V, Castrop F, Zimmer C, Haslinger B. Multiple changes of functional connectivity between sensorimotor areas in focal hand dystonia. *J Neurol Neurosurg Psychiatry* 2014; 85(11):1245-1252.
1. 9. Mohammadi B, Kollewe K, Samii A, Beckmann CF, Dengler R, Munte TF. Changes in resting-state brain networks in writer's cramp. *Hum Brain Mapp* 2012;33(4):840-848.
1. 10. Quartarone A, Hallett M. Emerging concepts in the physiological basis of dystonia. *Mov Disord* 2013;28(7):958-967.
1. 11. Quartarone A, Siebner HR, Rothwell JC. Task-specific hand dystonia: can too much plasticity be bad for you? *Trends Neuro* 2006; 29(4):192-199.
1. 12. Edwards MJ, Huang YZ, Wood NW, Rothwell JC, Bhatia KP. Different patterns of electrophysiological deficits in manifesting and non-manifesting carriers of the DYT1 gene mutation. *Brain* 2003;126(Pt 9):2074-2080.
1. 13. Filippini N, MacIntosh BJ, Hough MG, et al. Distinct patterns of brain activity in young carriers of the APOE-epsilon4 allele. *Proc Natl Acad Sci U S A* 2009;106(17):7209-7214.
1. 14. Werner CJ, Dogan I, Sass C, et al. Altered resting-state connectivity in Huntington's disease. *Hum Brain Mapp* 2014;35(6):2582-2593.
1. 15. Onu M, Badea L, Roceanu A, Tivarus M, Bajenaru O. Increased connectivity between sensorimotor and attentional areas in Parkinson's disease. *Neuroradiology* 2015;57(9):957-968.
1. 16. Fiorio M, Gambarin M, Valente EM, et al. Defective temporal processing of sensory stimuli in DYT1 mutation carriers: a new endophenotype of dystonia? *Brain* 2007;130(Pt 1):134-142.
1. 17. Ghilardi MF, Carbon M, Silvestri G, et al. Impaired sequence learning in carriers of the DYT1 dystonia mutation. *Ann Neurol* 2003;54(1):102-109.
1. 18. Burke RE, Fahn S, Marsden CD, Bressman SB, Moskowitz C, Friedman J. Validity and reliability of a rating scale for the primary torsion dystonias. *Neurology* 1985;35(1):73-77.
1. 19. Comella CL, Leurgans S, Wu J, Stebbins GT, Chmura T. Rating scales for dystonia: a multicenter assessment. *Mov Disord* 2003; 18(3):303-312.
1. 20. Ashburner J, Friston KJ. Why voxel-based morphometry should be used. *NeuroImage* 2001;14(6):1238-1243.

1. 21. Jenkinson M, Beckmann CF, Behrens TE, Woolrich MW, Smith SM. FSL. *NeuroImage* 2012;62(2):782-790.
1. 22. Andersen RA, Buneo CA. Intentional maps in posterior parietal cortex. *Annu Rev Neurosci* 2002;25:189-220.
1. 23. Avanzino L, Tinazzi M, Ionta S, Fiorio M. Sensory-motor integration in focal dystonia. *Neuropsychologia* 2015;79(Pt B):288-300.
1. 24. Farb NA, Grady CL, Strother S, et al. Abnormal network connectivity in frontotemporal dementia: evidence for prefrontal isolation. *Cortex* 2013;49(7):1856-1873.
1. 25. Rytty R, Nikkinen J, Paavola L, et al. GroupICA dual regression analysis of resting state networks in a behavioral variant of fronto-temporal dementia. *Front Hum Neurosci* 2013;7:461.
26. 26. Zhou J, Greicius MD, Gennatas ED, et al. Divergent network connectivity changes in behavioural variant frontotemporal dementia and Alzheimer's disease. *Brain* 2010;133(Pt 5):1352-1367.
26. 27. Jones DT, Knopman DS, Gunter JL, Graff-Radford J, Vemuri P, Boeve BF, Petersen RC, Weiner MW, Jack CR Jr; Alzheimer's Disease Neuroimaging Initiative. Cascading network failure across the Alzheimer's disease spectrum. *Brain* 2016;139(Pt 2):547-562.
26. 28. Odergren T, Stone-Elander S, Ingvar M. Cerebral and cerebellar activation in correlation to the action-induced dystonia in writer's cramp. *Mov Disord* 1998;13(3):497-508.
26. 29. Preibisch C, Berg D, Hofmann E, Solymosi L, Naumann M. Cerebral activation patterns in patients with writer's cramp: a functional magnetic resonance imaging study. *J Neurol* 2001;248(1):10-17.
26. 30. Dresel C, Haslinger B, Castrop F, Wohlschlaeger AM, Ceballos-Baumann AO. Silent event-related fMRI reveals deficient motor and enhanced somatosensory activation in orofacial dystonia. *Brain* 2006;129(Pt 1):36-46.
26. 31. Tecchio F, Melgari JM, Zappasodi F, et al. Sensorimotor integration in focal task-specific hand dystonia: a magnetoencephalographic assessment. *Neuroscience* 2008;154(2):563-571.
26. 32. Paudel R, Kiely A, Li A, et al. Neuropathological features of genetically confirmed DYT1 dystonia: investigating disease-specific inclusions. *Acta Neuropathol Commun* 2014;2:159.
26. 33. Hinkley LB, Sekihara K, Owen JP, Westlake KP, Byl NN, Nagarajan SS. Complex-value coherence mapping reveals novel abnormal resting-state functional connectivity networks in task-specific focal hand dystonia. *Front Neurol* 2013;4:149.
26. 34. Xia M, Wang J, He Y. BrainNet Viewer: a network visualization tool for human brain connectomics. *PloS ONE* 2013;8(7):e68910.