

AperTO - Archivio Istituzionale Open Access dell'Università di Torino

Robot-assisted Surgery for Benign Ureteral Strictures: Experience and Outcomes from Four Tertiary Care Institutions

This is the author's manuscript

Original Citation:

Availability:

This version is available <http://hdl.handle.net/2318/1623649> since 2017-11-30T18:53:06Z

Published version:

DOI:10.1016/j.eururo.2016.07.022

Terms of use:

Open Access

Anyone can freely access the full text of works made available as "Open Access". Works made available under a Creative Commons license can be used according to the terms and conditions of said license. Use of all other works requires consent of the right holder (author or publisher) if not exempted from copyright protection by the applicable law.

(Article begins on next page)

This Accepted Author Manuscript (AAM) is copyrighted and published by Elsevier. It is posted here by agreement between Elsevier and the University of Turin. Changes resulting from the publishing process - such as editing, corrections, structural formatting, and other quality control mechanisms - may not be reflected in this version of the text. The definitive version of the text was subsequently published in EUROPEAN UROLOGY, None, 2016, 10.1016/j.eururo.2016.07.022.

You may download, copy and otherwise use the AAM for non-commercial purposes provided that your license is limited by the following restrictions:

- (1) You may use this AAM for non-commercial purposes only under the terms of the CC-BY-NC-ND license.
- (2) The integrity of the work and identification of the author, copyright owner, and publisher must be preserved in any copy.
- (3) You must attribute this AAM in the following format: Creative Commons BY-NC-ND license (<http://creativecommons.org/licenses/by-nc-nd/4.0/deed.en>), 10.1016/j.eururo.2016.07.022

The publisher's version is available at:

<http://linkinghub.elsevier.com/retrieve/pii/S0302283816304274>

When citing, please refer to the published version.

Link to this full text:

<http://hdl.handle.net/>

Robot-assisted Surgery for Benign Ureteral Strictures: Experience and Outcomes from Four Tertiary Care Institutions

Nicolò Maria Buffi^a, Giovanni Lughezzani^a, Rodolfo Hurle^a, Massimo Lazzeri^a, Gianluigi Taverna^b, Giorgio Bozzini^b, Riccardo Bertolo^c, Enrico Checcucci^c, Francesco Porpiglia^c, Nicola Fossati^{d, e, f}, Giorgio Gandaglia^{d, e, f}, Alessandro Larcher^d, Nazareno Suardi^d, Francesco Montorsi^d, Giuliana Lista^d, Giorgio Guazzoni^a, Alexandre Mottrie^{e, f}

Abstract

Background

Minimally invasive treatment of benign ureteral strictures is still challenging because of its technical complexity. In this context, robot-assisted surgery may overcome the limits of the laparoscopic approach.

Objective

To evaluate outcomes for robotic ureteral repair in a multi-institutional cohort of patients treated for ureteropelvic junction obstruction and ureteral stricture (US) at four tertiary referral centres.

Design, setting, and participants

This retrospective study reports data for 183 patients treated with standard robot-assisted pyeloplasty (PYP) and robotic uretero-ureterostomy (UUY) at four high-volume centres from January 2006 to September 2014.

Surgical procedure

Robotic PYP and robot-assisted UUY were performed according to previously reported surgical techniques.

Outcome measurements and statistical analysis

Preoperative, intraoperative, and postoperative variables and outcomes were assessed. A descriptive statistical analysis was performed.

Results and limitations

No robot-assisted UUY cases required surgical conversion, while 2.8% of PYP cases were not completed robotically. The median operative time was 120 and 150 min for robot-assisted PYP and robot-assisted UUY, respectively. No intraoperative complications were reported. The overall complication rate for all procedures was 11% ($n = 20$) and complications were mostly of low grade. The high-grade complication rate was 2.2% ($n = 4$). At median follow-up of 24 mo, the overall

success rate was >90% for both procedures. The study limitations include its retrospective nature and the heterogeneity of the study population.

Conclusions

Robotic surgery for benign US is safe and effective, with limited risk of high-grade complications and good intermediate-term results.

Patient summary

In this study we review the use of robotic surgery at four different tertiary care centres in the treatment of patients affected by benign ureteral strictures. Our results demonstrate that robotic surgery is a safe alternative to the standard open approach in the treatment of ureteral strictures.

Keywords

- Ureter;
- Ureteral strictures;
- Robot-assisted surgery;
- Surgical technique;
- Outcomes;
- Ureteral surgery;
- Reimplantation

1. Introduction

The worldwide spread of robotic surgical technology such as the da Vinci system (Intuitive Surgical, Sunnyvale, CA, USA) has changed the way urologists approach minimally invasive complex reconstructive procedures in the last 10 yr. As an example, robot-assisted radical prostatectomy has improved surgeon vision and facilitated difficult steps such as nerve-sparing dissection and urethral anastomosis [1].

Besides radical prostatectomy, robotic technology has been adopted for the treatment of several other urologic conditions such as ureteral stricture (US). Although the laparoscopic approach in this field has been described, its widespread adoption has been limited by technical issues. Open surgery is still the most frequent approach for these complex reconstructions [2]. However, robot-assisted surgery represents a feasible and less challenging minimally invasive alternative to open surgery. The main advantages of the Da Vinci system are greater dexterity for intracorporeal suturing and better three-dimensional visualization of the surgical field. Therefore, this technology may help surgeons to overcome the traditional limits of laparoscopic surgery and may be safely adopted for benign ureteral conditions such as ureteropelvic junction obstruction (UPJO) and US.

Here we describe a multi-institutional cohort of patients who underwent robot-assisted ureteral repair for benign US at four tertiary care centres, and evaluate the feasibility and outcomes for this approach.

2. Materials and methods

2.1. Study population

After institutional review board approval in each centre, data for 183 patients treated for UPJO and US from January 2006 to September 2014 at four high volume institutions (Humanitas Hospital, Milan, Italy; Ospedale San Raffaele, Milan, Italy; OLV Clinic, Aalst, Belgium; S. Luigi Gonzaga Hospital, Orbassano, Italy) were collected.

Inclusion criteria for the study are all the patients with a UPJO or US, including cases of either primary or recurrent obstruction, treated with a “simple” ureteral anastomosis. Patients who had recent pyelonephritis or urinary tract infection were excluded. Preoperative clinical assessment of patients with UPJO included clinical evaluation of symptoms, mercaptoacetyltriglycine (MAG)-3 diuretic renal scans, and computed tomography (CT) urography. The preoperative work-up for patients affected by US included CT urography. Patients were selected for surgery according to the presence of symptoms and/or evidence of obstruction on diagnostic imaging.

Follow-up included an abdominal ultrasound, urinalysis, and a urine culture after 1 mo, as well as CT urography and a MAG-3 diuretic renal scan after 6 mo for patients affected by UPJO obstruction and US. Abdominal ultrasound was repeated at 12 mo and annually thereafter. Follow-up visits were at 1, 3, 6, and 12 mo, and annually thereafter, with clinical evaluation of symptom relief at each visit.

The study hypothesis was that robotic surgery is a feasible, safe, and effective minimally-invasive strategy for treatment of UPJO and US. The criteria for success for patients treated for UPJO and US were resolution of symptoms, no radiologic evidence of obstruction on CT urography, and no functional evidence of obstruction on MAG-3 renal scans.

2.2. Surgical techniques

In this multi-institutional study, patients were treated using one of three different robotic surgical techniques according to the site of the ureteral disease. Patients affected by UPJO underwent robot-assisted pyeloplasty. Patients affected by proximal US (starting from the ureteral pelvic junction to the external iliac vessels) underwent robot-assisted uretero-ureterostomy. Patients affected by distal US (starting from the external iliac vessels to the intramural segment of the ureter) underwent robot-assisted ureteral reimplantation.

Surgical techniques for robot-assisted pyeloplasty and robot-assisted uretero-ureterostomy have previously been described [3] and [4]. For robot-assisted ureteral reimplantation, the patient is positioned in the dorsal lithotomy and Trendelenburg position (20°) and the robot is brought into position between the patient's legs. An orogastric tube is placed before gaining access to the intraperitoneal space to decompress the stomach. Traditional open access is used to gain access to the intraperitoneal space. Port placement is illustrated in Fig. 1, with two 8-mm robotic trocars in a triangular arrangement in relation to the 12-mm robotic camera port at the umbilicus. Additional 5-mm and 12-mm assistant ports are positioned ipsilateral to the defect.

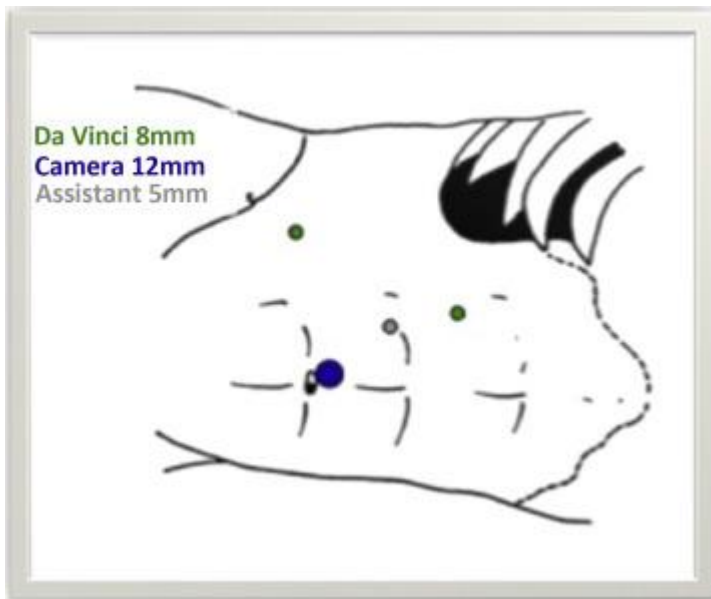


Fig. 1.

Port placement.

Figure options

After port positioning, the colon is swept aside and its peritoneal reflections are transected at the line of Toldt to access the retroperitoneal cavity ipsilateral to the US site. At this point, the stenotic portion of the ureter is usually identified as a bulge in the ureteral wall. However, in some cases a ureteroscope may also be used in this surgical step to identify the stenotic area, as first described by Glinianski et al [5]. Dissection of the ureter should be performed carefully to avoid disruption of the arterial blood supply. Transection of the affected portion of the ureter is completed using robotic scissors. Spatulation of the ureter is then performed. At this point, careful dissection of the bladder is completed to allow adequate mobilisation of the bladder on its pedicle. Further mobilisation can be achieved by freeing the bladder superiorly from the peritoneum. Periodic filling and voiding of the bladder through a Foley catheter are performed to determine whether sufficient mobilisation had been achieved to reach the transected ureter. This is important to obtain a tension-free anastomosis. For transperitoneal extravesical ureteral reimplantation, the bladder is directly incised at the site of the new ureteral orifice, which should be medial to the tendon to allow for a ureteral path that is as straight as possible. The bladder mucosa is then reached and two marker stitches are placed before incision to simplify the subsequent anastomosis. A small incision is made in the upper part of the isolated mucosa to access the bladder. Two running sutures with a 3-0 Vicryl SH needle are then used to complete the vesicoureteral anastomosis according to the modified Lich-Gregoire technique. The vesical muscular part is then closed over the anastomosis with a tension-free suture. The peritoneum is closed over the anastomosis. For patients suffering from bladder outlet obstruction, the Politano-Leadbetter technique is generally adopted to minimize the risk of ureterovesical reflux.

If a tension-free ureterovesical anastomosis cannot be completed with simple bladder mobilisation, a psoas bladder hitch or a Boari flap may be indicated. A transbladder psoas hitch antireflux reimplantation has been described by De Naeyer et al [6]. If a psoas hitch still leaves the planned anastomosis under tension, a Boari flap may be created, as described by Schimpf et al [7].

After all these reconstructive procedures, a bladder catheter and suction drain were always left in place. In addition, a JJ stent was placed and removed approximately 1 mo after surgery.

3. Results

Overall, 145 patients were treated with robot-assisted pyeloplasty for UPJO, 17 patients underwent robotic uretero-ureterostomy for proximal US, and 21 patients underwent robotic ureteral reimplantation for distal US.

3.1. Descriptive analysis

Preoperative characteristics for the overall population are summarised in Table 1. The majority of patients were symptomatic (76%), and the most common symptom was flank pain (67.2%). Detailed patient history details are also listed in Table 1. Overall, 31 subjects (17%) had undergone previous ureteral surgery. Specifically, 14 patients underwent ureteroscopy (7.7%), five patients (2.7%) were treated with JJ stenting for hydronephrosis, one patient (0.5%) underwent open ureter reimplantation for a distal US, and eight (4.4%) and three (1.6%) patients were treated with open pyeloplasty and endopyelotomy, respectively, for UPJO. In addition, two (1.4%) patients had an iatrogenic US, one following removal of a retroperitoneal mass and one following a hysterectomy. The median follow-up was 24 mo (range 6–80).

Table 1.

Descriptive characteristics for the overall population and detailed patient history.

Parameter	Value
Total patient population (<i>n</i>)	183
Mean age, yr (median) [range]	43 (42) [6–80]
Mean body mass index, kg/m² (median) [range]	23 (23) [16–42]
Gender, <i>n</i> (%)	
Male	88 (48)
Female	95 (52)
American Society of Anesthesiologists score, <i>n</i> (%)	
1	150 (82)
2	27 (14.8)
3	6 (3.2)
Procedure, <i>n</i> (%)	
Robotic pyeloplasty	145 (79.2)
Robotic uretero-ureterostomy	17 (9.3)
Robotic ureteral reimplantation (%)	21 (11.5)
Previous ureteral surgery, <i>n</i> (%)	31 (17)
Symptoms, <i>n</i> (%)	
Flank pain	123 (67.2)
Haematuria/other	11 (6)
Hyperpyrexia	5 (2.7)
Asymptomatic	44 (24)
Previous urinary tract infection, <i>n</i> (%)	37 (20)
Mean follow-up, mo (median) [range]	30 (24) [2–80]

Parameter	Value
Patient history by procedure	
Robotic pyeloplasty, <i>n</i> (%)	
Ureteropelvic junction obstruction	145 (100)
Robotic uretero-ureterostomy, <i>n</i> (%)	
Previous ureteral surgery for ureteral calculi	12 (70.6)
Iatrogenic US following retroperitoneal mass removal	
Primary congenital stricture	4 (23.4)
Robotic ureteral reimplantation, <i>n</i> (%)	
Previous ureteral surgery for ureteral calculi	9 (43)
Iatrogenic distal US following hysterectomy	
Primary obstructed megaureter	11 (52.2)

US = ureteral stricture.

Table options

For robotic pyeloplasty, the median operative time was 120 min. The median hospital stay was 5 d (range 2–12 d). The median time to catheter and drainage removal was 3 d (range 2–9) and 4 d (range 2–10), respectively (Table 2).

Table 2.

Preoperative, intraoperative, and postoperative characteristics for the study population.

	Robotic pyeloplasty	Robotic uretero-ureterostomy	Robotic reimplantation
Preoperative data			
Side, <i>n</i> (%)			
Right	73 (50.3)	11 (64.7)	11 (52.4)
Left	72 (49.7)	6 (35.3)	10 (47.6)
Surgical approach, <i>n</i> (%)			
Transperitoneal	107 (73.8)	17 (100)	21 (100)
Retroperitoneal	34 (23.4)		
Transmesocolic	4 (2.8)		
Previous ureteral surgery, <i>n</i> (%)			
	17 (11.7)	12 (70.6)	2 (9.5)
Symptoms, <i>n</i> (%)			
	107 (73.8)	16 (94.1)	16 (76.2)
Previous urinary tract infection			
Asymptomatic	38 (26.2)	1 (5.9)	5 (23.8)
Renal colic/pain	96 (66.2)	16 (94.1)	11 (52.4)
Haematuria	3 (2.1)		2 (9.5)
Other	8 (5.5)		3 (14.3)
Intraoperative data			

	Robotic pyeloplasty	Robotic uretero-ureterostomy	Robotic reimplantation
Intraoperative complications (n)	0	0	0
Surgical conversion, n (%)	4 (2.8)	0	0
Additional trocars (n)	0	0	0
Postoperative complications, n (%)	12 (8.3)	3 (17.6)	5 (23.8)
Clavien-Dindo I	5 (3.4)	2 (11.7)	2 (9.5)
Clavien-Dindo II	5 (3.4)	1 (5.8)	1 (4.8)
Clavien-Dindo IIIa/IIIb	2 (1.5)	0	2 (9.5)
Clavien-Dindo IV	0	0	0
Mean operative time, min (median) [range]	128 (120) [60–285]	178 (150) [100–420]	166 (165) [90–255]
Postoperative data			
Mean hospital stay, d (median) [range]	4.7 (5) [2–12]	5 (5) [4–9]	8 (5) [4–30]
Mean drain removal, d (median) [range]	4 (4) [2–10]	3 (3) [3,4]	5 (3) [1–29]
Mean catheter removal, d (median) [range]	3 (3) [2–9]	2.6 (2) [2–5]	5 (4) [1–15]
Mean pain score on discharge (median) [range]	1 (1) [0–7]	1 (1) [0–3]	1 (0) [0–2]

Table options

The median operative time was 150 min (range 100–420) for robot-assisted uretero-ureterostomy and 165 min (range 90–255) for robot-assisted ureteral reimplantation, and the median hospital stay was 5 d (range 4–9 and 4–30, respectively). The median time to catheter and drainage removal was 2 d (range 2–5) and 3 d (range 3–4) after robot-assisted uretero-ureterostomy, and 4 d (range 1–15) and 3 d (range 1–29) after robot-assisted ureteral reimplantation, respectively.

3.2. Feasibility

Four cases (2.8%) of robot-assisted pyeloplasty required conversion to open surgery, three cases for adverse anatomic conditions and one case because of a lost needle. All robot-assisted uretero-ureterostomy and robot-assisted ureteral reimplantation cases were successfully completed robotically. None of the procedures needed additional trocars.

3.3. Safety

No intraoperative complications were reported. The overall postoperative complication rate was 10.9% ($n = 20$; Table 3). Specifically, 8.3% ($n = 12$) of robot-assisted pyeloplasty cases experienced postoperative complications. High-grade complications (Clavien-Dindo grade III) occurred in two patients (1.4%) after robot-assisted pyeloplasty: one patient developed urine leakage requiring reintervention and the other experienced JJ stent migration.

Table 3.

Detailed list of postoperative complications.

Complication	Frequency, <i>n</i> (%)
Robotic pyeloplasty	
Anastomotic leakage (Clavien-Dindo III)	1 (0.7)
DJ positioning (Clavien-Dindo III)	1 (0.7)
Electrolyte imbalance (Clavien-Dindo I)	2 (1.4)
Bleeding from a robotic port (Clavien-Dindo I)	1 (0.7)
Prolonged haematuria (Clavien-Dindo I)	1 (0.7)
Hyperpyrexia	
Clavien-Dindo II (treated with antibiotics)	5 (3.4)
Clavien-Dindo I	1 (0.7)
Robotic uretero-ureterostomy	
Hyperpyrexia	
Clavien-Dindo II (treated with antibiotics)	1 (6)
Clavien-Dindo I	2 (12)
Robotic ureteral reimplantation	
Laparoscopic drainage of haematoma	1 (4.8)
Urinary fistula	1 (4.8)
Hyperpyrexia	
Clavien-Dindo II (treated with antibiotics)	1 (4.8)
Clavien-Dindo I	2 (9.5)

Table options

The postoperative complication rate for robot-assisted uretero-ureterostomy was 17.6% ($n = 3$), which were Clavien-Dindo grade I ($n = 2$) or grade II ($n = 1$). The postoperative complication rate after robot-assisted ureteral reimplantation was 23.8% ($n = 5$). High grade complications requiring surgical reintervention occurred in two cases (9.5%): one patient developed haematoma and the other a urinary fistula.

3.4. Efficacy

For robot-assisted pyeloplasty, the 2-yr recurrence-free rate was 92.5% (86.0–96.0%). The median pain score (visual analogue scale [VAS]) on discharge was 1 for both robot-assisted pyeloplasty (range 0–7) and robot-assisted laparoendoscopic single-site pyeloplasty (range 0–3).

The 2-yr recurrence-free rate was 94.1% (65.0–99.1%) for robot-assisted uretero-ureterostomy and 93.3% (61.3–99.0%) for robot-assisted ureteral reimplantation (Table 4). The median VAS pain score on discharge was 1 (range 0–3) for robot-assisted uretero-ureterostomy and 0 (range 0–2) for robot-assisted ureteral reimplantation.

Table 4.

Frequency of recurrence and 2-yr recurrence-free rate for each robotic procedure.

	Pyeloplasty	Uretero- ureterostomy	Reimplantation
Recurrence, <i>n</i> (%)			
Yes	9 (6)	1 (6)	1 (5)
No	136 (94)	16 (94)	20 (95)
2-yr recurrence-free rate, % (95% CI)	92.5 (86.0– 96.0)	94.1 (65.0–99.1)	93.3 (61.3–99.0)

Table options

4. Discussion

It has been reported that suturing and tissue handling in a limited space can be performed more easily with a robot compared to conventional laparoscopy, even using other robotic system [8] and [9]. These factors are even more relevant in complex surgical procedures such as ureteral reconstructive surgery. Previous successful experiences with robot-assisted management of benign US have been reported, although the majority of these studies were limited by the small number of patients included and short follow-up time.

Our study results provide further demonstration that robotic surgery is an effective minimally invasive approach for the treatment of different benign US conditions, including the upper, middle and distal ureter. Specifically, the proportion of patients requiring conversion to a different surgical procedure was 2.8% in the robot-assisted pyeloplasty group, while none of the middle and lower ureteral cases required conversion, confirming the feasibility of the approach. Safety was demonstrated by the absence of intraoperative complications. In addition, the incidence of high-grade postoperative complications (Clavien-Dindo grade III) was low, as they occurred in just two patients in both the robot-assisted pyeloplasty and vesicoureteral reimplantation groups. The efficacy of robot-assisted surgery for benign ureteral strictures was confirmed by the high 2-yr recurrence-free rate, which was $\geq 92.5\%$ for all the surgical procedures. To the best of our knowledge, the current study represents the first attempt to jointly evaluate the feasibility and outcomes for robot-assisted surgery for a variety of benign US conditions. The strengths of the current study are the relatively large sample size (given the rarity of the condition) and the fairly long follow-up time.

Minnillo et al [10] demonstrated that robot-assisted pyeloplasty can be safely performed at an academic training institution by adoption of a robotic training program. The improvement in surgical results observed over a 7-yr period emphasizes that a dedicated and committed team with proper training can achieve long-term results similar to those for open pyeloplasty.

In 2005 Patel et al reported the first large ($n = 50$) series of robot-assisted pyeloplasty cases, concluding that the technique, although in its infancy, offers outstanding short-term efficacy and minimal morbidity, as well being easier and quicker to learn [11]. Similarly, Schwentner et al [12] presented their 5-yr experience with 92 cases of dismembered Anderson-Hynes robotic procedures, reporting durable results and no late complications. Mufarrij et al [13] reported the first multi-institutional experience, describing outcomes in 140 patients, including primary and secondary UPJO with or without concomitant stone extraction. Gupta et al [14] confirmed the excellent outcomes for this procedure in a single-institutional series of 85 patients. Etafy et al [15] attributed their lower success rate (81%) to the more strict criteria used for the assessment.

To date, the largest series has been reported by Sivaraman et al. [16], who collected and analysed 169 cases from three US institutions, and confirmed that robot-assisted pyeloplasty is a viable option for either primary or secondary UPJO repair with reproducible outcomes, a high success rate, and low incidence of complications.

Autorino et al [17] published a systematic review and meta-analysis of robot-assisted and laparoscopic UPJO repair, summarizing the outcomes for surgical series that included more than 50 patients. According to this study, the conversion rate was less than 2.3%, with a complication rate ranging from 1.8% to 17.9%. However, a limitation of their results is that reporting of complications was not standardized across different studies. The success rate was >81% at median follow-up ranging from 12 to 39 mo.

While several groups have reported robot-assisted surgery outcomes for UPJO, only a few studies have investigated the role of this surgery in the management of mid and low ureteral pathology. The largest series to date is a retrospective review of 44 procedures by Hemal et al [18]. The study included 18 distal ureteral procedures (5 distal ureterectomies with ureteroneocystostomy; 1 ureteroneocystostomy with psoas hitch; 2 ureteroneocystostomies with vesicovaginal fistula repair; 8 monolateral megaureter repairs; and 1 bilateral megaureter repair), 12 proximal ureteral procedures (6 monolateral ureteroureterostomies, 2 bilateral ureteroureterostomies, and 4 retrocaval ureter repairs), ten nephroureterectomies (5 with bladder cuff resection), and four miscellaneous procedures. Complications included one case of sepsis and one antibiotic-induced infection. The average follow-up period was 13.5 mo. Operative success as defined as symptom resolution and 100% postoperative imaging results.

Musch et al [19] described the feasibility and short-term outcomes for different robot-assisted reconstructive procedures for the distal ureter. The surgical indications and operative techniques were as follows: seven distal ureteral resections with psoas hitch reimplantation; two extravesical vesicoureteral reimplantations and one end-to-end anastomosis because of a benign distal US; four distal ureteral resections with a psoas hitch procedure and pelvic lymphadenectomy for urothelial carcinoma of the ureter; one distal ureteral resection with a psoas hitch procedure and Boari flap because of unexpected locally recurrent prostate cancer; one extravesical reimplantation because of vesicoureteral reflux; one bilateral intravesical reimplantation of ectopic ureters (as part of a radical prostatectomy); one resection of a nonfunctioning upper kidney pole with associated megaureter and ureterocele and intravesical reimplantation of the lower pole ureter; and one resection of pelvic endometriosis and ureterolysis. There were no intraoperative complications, but there was one conversion to open surgery. At 3 mo after surgery, complications occurred in 12 patients (75%): ten (62%) were minor according to the Clavien-Dindo classification (grade I–II), while two (12%) were major (grades IIIb and IVa, respectively). At median follow-up of 10.2 mo, 15 patients (94%) remained without signs of urinary tract obstruction and 13 (81%) were asymptomatic.

Baldie et al [20] reported on their experience and outcomes for robot-assisted mid and distal ureteral reconstruction (13 ureteral reimplantations and 3 ureteroureterostomies). In their study, there were two open conversions because of excessive scar tissue. A symptomatic bowel injury (Clavien grade IIIb) occurred in one case. All cases were clinically and radiographically successful at the last follow-up examination.

Patil et al [21] reported the collective experience of three multinational institutions in the use of robotics to evaluate and treat complex distal ureteral obstruction. Twelve patients from three different centres underwent robotic-assisted laparoscopic ureteral reimplantation. The indications for ureteral reimplantation were US in ten cases and ureterovaginal fistula in two cases. All procedures were successfully completed robotically without open conversion. There were no

intraoperative or postoperative complications. Postoperative intravenous urography and MAG-3 revealed normal findings in 10 patients and mild residual hydronephrosis in two patients. After mean follow-up of 15.5 mo, all patients were asymptomatic.

Phillips and Wang [22] summarized the current status for robot-assisted laparoscopic ureteral reimplantation and reconstruction. They performed a PubMed search using the keywords “robot” and “ureter”, “distal ureter”, “ureteral reimplant”, “psoas”, and “Boari”. Papers addressing proximal ureteral reconstruction and nephroureterectomy were excluded. A total of nine papers were considered as relevant, even though the largest series included fewer than 18 patients. Complication rates in the case reports and series reviewed were low (10%). The most common complication was stricture recurrence at the surgical site (5%). These strictures were managed with balloon dilation and chronic stent changes. There were also reports of haematuria due to bleeding at the anastomosis, which was controlled via transurethral fulguration. One patient developed and later succumbed to aspiration pneumonia.

While the current study represents the largest series published to date on outcomes for robotic surgery in the treatment of benign ureteral strictures, there are several limitations that should be mentioned. First, the retrospective nature of the study may limit the significance of our findings. In addition, while the surgical techniques and follow-up protocols were standardized across the different institutions, the multicentre nature of our series should be taken into account when interpreting our results. Similarly, the heterogeneity of the study population may also be considered as a limitation, even though the main objective of the current study was to evaluate outcomes for robotic surgery for a wide range of different benign ureteral diseases. Moreover, no direct comparison between the outcomes for robotic surgery and those obtained with other minimally invasive techniques was performed. While these outcomes may not be substantially different in the hands of highly experienced laparoscopic surgeons, we strongly believe that the recognized advantages of robotic technology will help to improve accessibility for these demanding minimally invasive reconstructive procedures and to reduce the long learning curve associated with laparoscopic surgery [23]. These advantages may be even more pronounced for complex cases, such as secondary UPJO. Finally, the current results were obtained at high-volume centres and thus may not be generalisable to less experienced institutions.

5. Conclusions

This multi-institutional study confirms the feasibility, safety, and efficacy of robotic surgery as a minimally invasive alternative to open surgery for the treatment of benign ureteral strictures.

Author contributions: Nicolò Maria Buffi had full access to all the data in the study and takes responsibility for the integrity of the data and the accuracy of the data analysis.

Study concept and design: Buffi, Lughezzani, Porpiglia, Lista, Mottrie.

Acquisition of data: Buffi, Lista, Bozzini, Fossati, Larcher, Gandaglia, Bertolo, Checcucci.

Analysis and interpretation of data: Buffi, Lughezzani, Fossati, Larcher, Lista.

Drafting of the manuscript: Buffi, Lughezzani, Gandaglia, Lista.

Critical revision of the manuscript for important intellectual content: Hurle, Lazzeri, Taverna, Bozzini, Porpiglia, Suardi, Montorsi, Guazzoni, Mottrie.

Statistical analysis: Lista, Fossati, Larcher.

Obtaining funding: None.

Administrative, technical, or material support: None.

Supervision: Porpiglia, Montorsi, Guazzoni, Mottrie.

Other: None.

Financial disclosures: Nicolò Maria Buffi certifies that all conflicts of interest, including specific financial interests and relationships and affiliations relevant to the subject matter or materials discussed in the manuscript (eg, employment/affiliation, grants or funding, consultancies, honoraria, stock ownership or options, expert testimony, royalties, or patents filed, received, or pending), are the following: None.

Funding/Support and role of the sponsor: None.

Appendix A. Supplementary data

The following are Supplementary data to this article:

Help with MP4 files
Options

References

1.
 - [1]
 - V. Ficarra, G. Novara, T.E. Ahlering, *et al.*
 - Systematic review and meta-analysis of studies reporting potency rates after robot-assisted radical prostatectomy
 - *Eur Urol*, 62 (2012), pp. 418–430
 - [SD-008]
2.
 - [2]
 - B.K. Varda, E.K. Johnson, C. Clark, *et al.*
 - National trends of perioperative outcomes and costs for open, laparoscopic and robotic pediatric pyeloplasty
 - *J Urol*, 191 (2014), pp. 1090–1095
 - [SD-008]
3.
 - [3]
 - A. Cestari, N.M. Buffi, G. Lista, *et al.*
 - Retroperitoneal and transperitoneal robot-assisted pyeloplasty in adults: techniques and results
 - *Eur Urol*, 58 (2010), pp. 711–718
 - [SD-008]

4.
 - [4]
 - N. Buffi, A. Cestari, G. Lughezzani, *et al.*
 - Robot-assisted uretero-ureterostomy for iatrogenic lumbar and iliac ureteral stricture: technical details and preliminary clinical results
 - *Eur Urol*, 60 (2011), pp. 1221–1225
 - [SD-008]
5.
 - [5]
 - M. Glinianski, K.A. Guru, G. Zimmerman, *et al.*
 - Robot-assisted ureterectomy and ureteral reconstruction for urothelial carcinoma J
 - *Endourol*, 23 (2009), pp. 97–100
 - [SD-008]
6.
 - [6]
 - G. De Naeyer, P. Van Migem, P. Schatteman, *et al.*
 - Case report: pure robot-assisted psoas hitch ureteral reimplantation for distal-ureteral stenosis
 - *J Endourol*, 21 (2007), pp. 618–620
 - [SD-008]
7.
 - [7]
 - M.O. Schimpf, J.R. Wagner
 - Robot-assisted laparoscopic Boari flap ureteral reimplantation
 - *J Endourol*, 22 (2008), pp. 2691–2694
 - [SD-008]
8.
 - [8]
 - J. Rassweiler, G. Pini, A.S. Gozen, *et al.*
 - Role of laparoscopy in reconstructive surgery
 - *Curr Opin Urol*, 20 (2010), pp. 471–482
 - [SD-008]
9.
 - [9]
 - G. Bozzini, S. Gidaro, G. Taverna
 - Robot-assisted laparoscopic partial nephrectomy with the ALF-X robot on pig models
 - *Eur Urol*, 69 (2016), pp. 376–377
 - [SD-008]
10.
 - [10]
 - B.J. Minnillo, J.A. Cruz, R.H. Sayao, *et al.*
 - Long-term experience and outcomes of robotic assisted laparoscopic pyeloplasty in children and young adults
 - *J Urol*, 185 (2011), pp. 1455–1460
 - [SD-008]
11.
 - [11]
 - V. Patel
 - Robotic-assisted laparoscopic dismembered pyeloplasty
 - *Urology*, 66 (2005), pp. 45–49

- [SD-008]
- 12.
 - [12]
 - C. Schwentner, A. Pelzer, R. Neururer, *et al.*
 - Robotic Anderson-Hynes pyeloplasty: 5-year experience of one centre
 - BJU Int, 100 (2007), pp. 880–885
 - [SD-008]
- 13.
 - [13]
 - P.W. Mufarrij, M. Woods, O.D. Shah, *et al.*
 - Robotic dismembered pyeloplasty: a 6-year, multi-institutional experience
 - J Urol, 180 (2008), pp. 1391–1396
 - [SD-008]
- 14.
 - [14]
 - N.P. Gupta, R. Nayyar, A.K. Hemal, *et al.*
 - Outcome analysis of robotic pyeloplasty: a large single-centre experience
 - BJU Int, 105 (2010), pp. 980–983
 - [SD-008]
- 15.
 - [15]
 - M. Etafy, D. Pick, S. Said, *et al.*
 - Robotic pyeloplasty: the University of California-Irvine experience
 - J Urol, 185 (2011), pp. 2196–2200
 - [SD-008]
- 16.
 - [16]
 - A. Sivaraman, R.J. Leveillee, M.B. Patel, *et al.*
 - Robot-assisted laparoscopic dismembered pyeloplasty for ureteropelvic junction obstruction: a multi-institutional experience
 - Urology, 79 (2012), pp. 351–355
 - [SD-008]
- 17.
 - [17]
 - R. Autorino, C. Eden, A. El-Ghoneimi, *et al.*
 - Robot-assisted and laparoscopic repair of ureteropelvic junction obstruction: a systematic review and meta-analysis
 - Eur Urol, 65 (2014), pp. 430–452
 - [SD-008]
- 18.
 - [18]
 - A.K. Hemal, R. Nayyar, N.P. Gupta, *et al.*
 - Experience with robot assisted laparoscopic surgery for upper and lower benign and malignant ureteral pathologies
 - Urology, 76 (2010), pp. 1387–1393
 - [SD-008]
- 19.
 - [19]
 - M. Musch, L. Hohenhorst, A. Paillart, *et al.*
 - Robot-assisted reconstructive surgery of the distal ureter: single institution experience in 16 patients

- BJU Int, 111 (2013), pp. 773–783
 - [SD-008]
- 20.
- [20]
 - K. Baldie, J. Angell, K. Ogan, *et al.*
 - Robotic management of benign mid and distal ureteral strictures and comparison with laparoscopic approaches at a single institution
 - Urology, 80 (2012), pp. 596–601
 - [SD-008]
- 21.
- [21]
 - N.N. Patil, A. Mottrie, B. Sundaram, *et al.*
 - Robotic-assisted laparoscopic ureteral reimplantation with psoas hitch: a multiinstitutional, multinational evaluation
 - Urology, 72 (2008), pp. 47–50
 - [SD-008]
- 22.
- [22]
 - E.A. Phillips, D.S. Wang
 - Current status of robot-assisted laparoscopic ureteral reimplantation and reconstruction
 - Curr Urol Rep, 13 (2012), pp. 190–194
 - [SD-008]
- 23.
- [23]
 - C.C. Passerotti, A.M. Passerotti, M.F. Dall’Oglio, *et al.*
 - Comparing the quality of the suture anastomosis and the learning curves associated with performing open, freehand, and robotic-assisted laparoscopic pyeloplasty in a swine animal model
 - J Am Coll Surg, 208 (2009), pp. 576–586
 - [SD-008]