

AperTO - Archivio Istituzionale Open Access dell'Università di Torino

## Single-port laparoscopic incisional hernia repair in a horse

### This is the author's manuscript

*Original Citation:*

*Availability:*

This version is available <http://hdl.handle.net/2318/1665068> since 2023-06-26T12:51:43Z

*Published version:*

DOI:10.1111/eve.12547

*Terms of use:*

Open Access

Anyone can freely access the full text of works made available as "Open Access". Works made available under a Creative Commons license can be used according to the terms and conditions of said license. Use of all other works requires consent of the right holder (author or publisher) if not exempted from copyright protection by the applicable law.

(Article begins on next page)

## Single-port laparoscopic incisional hernia repair in a horse

M. Gandini\*, G. Giusto, V. Caramello, F. Comino and A. Rosso

Department of Veterinary Sciences, University of Turin, Grugliasco, Italy.

\*Corresponding author email: marco.gandini@unito.it Keywords: horse; laparoscopy; single port; hernia repair; mesh

### Summary

A 16-year-old Italian Saddle Horse gelding was referred for treatment of an incisional hernia that developed 7 months after a ventral midline laparotomy for treatment of acute abdominal pain. Physical examination revealed a hernia approximately 20 cm long and 15 cm wide on the ventral aspect of the abdomen. Ultrasonography revealed the dimensions of the hernia ring to be approximately 15 cm in length and 10 cm in width. A single-port laparoscopic incisional hernia repair using an operating 0° laparoscope was performed with an appropriately sized (24 × 3 × 18 cm) piece of mesh fixed in place with simple interrupted transabdominal sutures. At 4 weeks post operatively, followup physical examination and ultrasonography confirmed healing of the surgical site with no evidence of hernia recurrence. The same evaluation was done 6 months post operatively, and the horse returned to its previous level of activity 8 months post operatively. In horses, laparoscopic application of mesh should be considered among the treatment options for incisional hernia. In the present case, this technique was performed with a single port using an operative laparoscope, in contrast to the multiportal techniques reported previously. The case presented here demonstrates that single-port laparoscopic herniorrhaphy is feasible, and allows proper placement of an expanded polytetrafluoroethylene intraperitoneal mesh in horses

### Introduction

Ventral and incisional hernias are common surgical problems in large animals (Elce et al. 2005; Caron and Mehler 2009; Vilar et al. 2009; Whitfield-Cargile et al. 2011). In horses, incisional hernias occur in 8–16% of cases after median laparotomy (Caron and Mehler 2009; Vilar et al. 2009; Whitfield-Cargile et al. 2011; Ramakrishna and Lakshman 2013). Small hernias may need surgical repair to prevent intestinal strangulation in the hernial ring (Elce et al. 2005), while large hernias may require closure because they interfere with athletic activities or normal parturition, may worsen from repeated trauma, or are cosmetically unsightly. Several techniques for surgical repair of ventral hernias in horses have been reported. The edges of the hernia wall can be opposed by suture only (Whitfield-Cargile et al. 2011), but implantation of a mesh may be required in some cases to aid closure (Elce et al. 2005; Rijkenhuizen 2005; Kelmer and Schumacher 2008; Caron and Mehler 2009; Vilar et al. 2009). The latter may be performed with open surgery or minimally invasive techniques, and selection of the appropriate technique must be adapted to each individual case. Open-surgery mesh hernioplasty is not free from complications, both in man and large animals (Rijkenhuizen 2005; Kelmer and Schumacher 2008; Caron and Mehler 2009; Vilar et al. 2009; Whitfield-Cargile et al. 2011; Ramakrishna and Lakshman 2013). In human patients, laparoscopic mesh hernioplasty is currently the preferred technique (Alexander and Scott 2013; Ramakrishna and Lakshman 2013) and, compared with the open technique, seems to be advantageous in terms of shorter rehabilitation periods, less post operative pain and minor risk of wound infection (Alexander and Scott 2013; Basile et al. 2013). Many materials (LeBlanc et al. 2002) have been proposed for incisional hernia repair, including polypropylene and expanded polytetrafluoroethylene (ePTFE) meshes, but the former carries a high risk of adhesions if placed intraperitoneally (Surour 2014). The main complication associated with laparoscopic implantation of synthetic meshes is intestinal adhesions to the mesh (Caron and Mehler

2009), but other complications such as seroma, wound or mesh infection, fistula, and hernia recurrence may occur (Whitfield-Cargile et al. 2011; Caron 2014). An adaptation of a laparoscopic technique for incisional hernia repair in horses, peritoneal onlay mesh hernioplasty, was recently reported by Caron and Mehler (2009). The technique employs multiple ports and onlay placement of a dual-layer mesh, fixed in place with sutures and tacks or surgical staples. In man and small animals, reducing the number of ports in laparoscopic surgery reduces post operative pain and complications (Dupre et al. 2009; Misra 2011; Roy and De 2011). To date there have been no reports of use of this technique in horses. Our hypothesis was that a single-port laparoscopic hernioplasty using a dual layer intraperitoneal mesh and an operative laparoscope is feasible in horses and results in effective hernia repair.

### Case history

A 16-year-old Italian Saddle Horse gelding used for novice level showjumping and eventing, weighing 500 kg, was referred to our hospital for incisional repair of a hernia of 6 months' duration, consequent to an incisional infection following abdominal surgery. A hernia approximately 20 cm long and 15 cm wide was evident on the ventral aspect of the abdomen, located in the cranial half of the original surgical incision. The remaining portion of the incision had healed without complications. At ultrasonography (Esaote Mylab 30 equipped with a 2–8 MHz probe Esaote CA 541)<sup>1</sup> the hernia ring measured 15 cm in length and 10 cm in width. Intestine was contained in the hernia. No adhesions of the intestines to the hernia wall were detected. Surgical laparoscopic correction was recommended to the owner on the basis of possible traumatism during activity. The horse was fasted for 24 h prior to surgery. Anaesthesia was induced with diazepam (Valium 0.05 mg/kg bwt, i.v.)<sup>2</sup> and ketamine (Ketavet 2.2 mg/kg bwt, i.v.)<sup>3</sup> and maintained with isoflurane in oxygen. The horse was then placed under general anaesthesia in dorsal recumbency, and the surgical site was aseptically prepared. The videocamera (Stryker 810 Medical Videocamera)<sup>4</sup>, monitor, insufflator (Stryker 16L High Flow Insufflator)<sup>4</sup> and light source (Stryker Quantum 4000 light source)<sup>4</sup> were all placed in a tower on the right side of the surgeon between the hindlimbs of the horse.

### Surgical procedure

The portal site was created using a 15 mm trocar cannula system (Versaport V2 15 mm)<sup>5</sup> placed on the midline approximately 15 cm cranial to the hernia ring using a Hasson technique (Caron and Mehler 2009). A 0° 33 cm operative laparoscope (Karl Storz 26034A)<sup>6</sup> was inserted. After intraperitoneal placement of the trocar was assured, the abdomen was insufflated with CO<sub>2</sub> to a pressure of 15 mmHg. The abdominal cavity was visually inspected to ensure that no viscera were injured during trocar insertion. To improve field visibility, 2 transabdominal stay sutures (USP 2 polyester, Surgidac)<sup>5</sup> were placed at the cranial and caudal edge of the hernial ring and as needed held in tension by an assistant. The retroperitoneal fat was dissected circumferentially around the hernia, as previously described (Caron and Mehler 2009), with 45 cm long disposable laparoscopic scissors (Endo Shears)<sup>5</sup> inserted through the operative channel of the laparoscope. Haemostasis was provided with monopolar cautery (Alsatom MB1/A-MC)<sup>7</sup>. A piece of mesh (Gore Dualmesh)<sup>8</sup> 24 × 9 × 18 cm had simple interrupted sutures USP 1 polyester with long tails (Surgidac)<sup>5</sup> placed on its perimeter, approximately 3–4 cm apart. The mesh was marked with a sterile surgical pen (Surgical Skin Marker)<sup>9</sup> to ensure correct orientation once it was placed intraperitoneally (Fig 1). On the side of the mesh to be placed against the peritoneum, each suture was identified by a number on the left side and a letter on the right side. The long tails of the sutures were clinched into the adjacent knot before tying the latter (Fig 2). The mesh was then rolled up on itself, introduced into the abdominal cavity through the 15 mm trocar with a 45 cm laparoscopic atraumatic grasper (Snowden Pencer 90-7220)<sup>10</sup> passed through the operating channel of the laparoscope (Fig 3), and oriented within the abdomen. Under visual control, an 18 gauge, 9 cm long spinal needle was inserted through the abdominal wall approximately 4 cm caudally to

the most caudal margin of the hernia ring to identify the correct spot for placing the first suture. Correspondingly, a 1 cm skin incision was made with a No. 21 scalpel blade. Again, under visual control, a suture passer (Gore Suture Passer)<sup>8</sup> was inserted at one end of the skin incision through the fascia and used to retrieve one of the suture tails (Fig 4) at the point marked with the letter 'A'. The suture passer was then placed at the opposite end of the skin incision and used to retrieve the other suture end, with care taken that the 2 strands exited the abdominal wall at least 1 cm apart. The suture ends were not tied but clamped with a mosquito forceps. After the mesh was checked to ensure complete coverage of the defect, all other sutures were passed through the abdominal wall with the same technique in the order A-1-B-2- C-3-D-4-E-5, and so on (Fig 1) to prevent kinking or torsion of the mesh. Moderate tension on the mesh was assured by placing the transabdominal sutures at an appropriate distance one from each other. The mesh was then visually checked for correct positioning before the sutures were tied outside the abdomen. After final inspection of the complete hernioplasty, the abdomen was deflated, the laparoscopic portal was closed by using the trocar to guard the passage of a large needle transabdominally (Gandini and Giusto 2014), and the skin was opposed with single vertical mattress sutures (Monosoft)<sup>5</sup>. The horse was treated with ampicillin sodium (Vetamplus 20,000 iu/kg bwt i.v.)<sup>11</sup>, gentamicin sulfate (Aagent, 6.6 mg/ kg bwt i.v.)<sup>11</sup>, and flunixin meglumine (Finadyne 0.4 mg/kg bwt, i.v.)<sup>3</sup> before surgery and for 2 days post operatively. After recovery a sterile cotton pad was applied on the ventral aspect of the abdomen and a custom-made, elastic, adjustable belly-band was applied. The horse was reintroduced to feed 6 h post operatively and discharged from the hospital 3 days after surgery. Skin sutures were removed by the referring veterinarian 10 days after surgery. Laparoscopic mesh hernioplasty was achieved without intra- or post operative complications. Surgical time (skin incision to closure) was 150 min. The horse showed mild abdominal discomfort in the first 24 h that was responsive to administration of nonsteroidal anti-inflammatory drugs. The abdominal bandage was maintained for 4 weeks post operatively. The horse was examined at the farm at 4 weeks and 6 months following surgery for the extent of incisional healing, resolution of the hernia, post operative inflammation and the presence or absence of incisional pain. Ultrasonography (with an Esaote Mylab 30 equipped with a 2–8 MHz probe Esaote CA 541)<sup>1</sup> was performed to assess the position of the mesh and for any sign of infection or adhesions. Outcome The horse was discharged with the custom-made abdominal bandage, and the referring veterinarian was asked to change the cotton pad every day and adjust the bandage if it slipped. As reported by the referring veterinarian, the surgical wound looked always clean, and no discharge or swelling were detected during the bandage changes. At follow-up 4 weeks following surgery, no wound healing complications were observed, excessive skin from the previous hernia sac had shrunk, the defect was no longer notable, and no abdominal pain was detected. During the recovery period, only hand walking 2 or 3 times per day was allowed. At 6 months follow-up, any kind of complications were noted, and the horse was introduced to a ridden light level of work. The horse was then returned to full exercise 8 months after hernioplasty.

## Discussion

Single-port laparoscopic surgery was recently reported as a possible alternative to conventional laparoscopic surgery in human patients (Podolsky et al. 2010; Misra 2011; Roy and De 2011; Stylianos et al. 2011) and small animals (Dupre et al. 2009). This approach offers several advantages including decreased abdominal pain, shortened hospital stays, reduction of post operative ileus, and lower costs (Dupre et al. 2009; Podolsky et al. 2010; Khosla and Ponsky 2011; Misra 2011; Roy and De 2011; Stylianos et al. 2011). Furthermore, single-port access may prevent additional portsite hernia formation by decreasing the number of fascial defects (Podolsky et al. 2010). Although no complications directly connected to the number of ports were reported by Caron and Mehler (2009), reducing the number of ports may be beneficial in horses while allowing correct performance of the procedure, although in some cases could lengthen the surgical time or not provide adequate access to the area (e.g. in case of very large hernias) A number of dedicated devices have been developed to perform single-port surgery, including multi-instrument ports, articulating instruments and telescopes (Khosla and Ponsky 2011). While introducing

these new instruments into their sets, most surgeons have forgotten a basic tool: the operative laparoscope (Khosla and Ponsky 2011), proven useful, effective, and safe in many procedures (Khosla and Ponsky 2011; Stylianos et al. 2011; Lee et al. 2012) including ventral hernia repair in man (Bucher et al. 2011). The major drawbacks of operative laparoscopes are the need for long (42–45 cm) instruments, the simultaneous movement of the instrument with the laparoscope, and the coaxial telescope viewing axis and instrument working axis, which prevent triangulation. In equine laparoscopy, because of the dimensions of the cases, long instruments are usually recommended (Caron 2012) and thus are part of a typical equine laparoscopic set. Only a short period of adaptation is needed to master the simultaneous movement of laparoscope and instrument (Lee et al. 2012), while the coaxial view and working direction may be ideal (Rhee et al. 2014). We found it very easy to adapt to the absence of triangulation with two long instruments, and the simultaneous movement of instrument and laparoscope resulted in the perception of reduced effort. The surgical time (skin incision to closure) in our case was 150 min, less than reported by Caron and Mehler (2009); the difference can probably be accounted for by the reduced number of ports. A 15-mm bladeless trocar<sup>1</sup> to enter the abdomen and to serve as the single port was used in our case. The choice was dictated by the fact that this trocar, being bladeless, reduces the risk of injury to abdominal viscera during insertion in the abdomen. It has 2 reduction caps that allow insertion of 5–12 mm instruments or laparoscopes, and it is sufficiently large (without reduction caps) to allow the insertion of the rolled-up mesh into the abdomen. The placement of only one trocar on the linea alba instead of multiple ports lateral to the hernia (as reported by Caron) (Caron and Mehler 2009; Caron 2012) can reduce pain and seroma formation at the trocar site by avoiding passage through muscles and damage to abdominal-wall vessels. This insertion site was considered appropriate for closure of a hernia of maximum 20 cm in length; with larger hernias, placement of a second port on the opposite side of the hernia ring could be required. Also, in the case reported here, the original incision (approximate length 20 cm) started from the umbilicus and thus left enough space between the cranial edge of the hernia and the sternum to place the trocar. In smaller horses with large hernias, this space could be reduced, thus necessitating the insertion of other ports. Ideally, meshes should be placed retroperitoneally or retromuscularly to protect the abdominal organs from adhesions (Tullerens and Fretz 1983; Rijkenhuizen 2005). Polypropylene meshes placed intra-abdominally, directly adjacent to the intestine, have been reported as not causing adhesions in horses (Vander Velden and Klein 1994) and man (Heniford and Ramshaw 2000), although severe complications can occur (Tullerens and Fretz 1983). Application of ePTFE meshes has been shown to be effective for intraperitoneal placement in horses. In the present case, no adhesions were found on 6-month follow-up ultrasonography. In horses, anchoring of the mesh using full-thickness sutures through the abdominal wall at 4–5 cm intervals has been considered a quick and adequate method (Rijkenhuizen 2005; Caron 2012). Staples or tacks are other options for mesh fixation (Gandini and Giusto 2014), but serious complications, such as adhesions and intestinal lesions (Karahasanoglu et al. 2004; Heltmeier and Groebli 2013), have been reported without significant reduction in abdominal pain (Reynvoet et al. 2014). In our experience, mesh fixation using the simple interrupted suture with long tails was effective, although there is no evidence that this technique reduced complications or post operative pain, compared to the method proposed by Caron (Caron and Mehler 2009; Caron 2014). Certainly, placing sutures instead of staples or tacks reduces the need for specific devices, thus reducing costs (Bansal et al. 2011). One disadvantage of the described technique could be confusion among suture strands caused by the number of sutures placed around the mesh perimeter. This problem was solved by including the strands of a stay suture in the knot of the following one so that they were parallel to and in contact with the mesh. They could be easily retrieved just by pulling on them once the previous stay suture was passed transabdominally. The choice of a braided suture was made because it is easier to handle compared to monofilament sutures that have more memory effect. Another limitation of this technique is the relative difficulty of placing the sutures very near to the laparoscopic portal. This can be reduced by placing the portal as far as the laparoscope length allows while maintaining proper vision of the farthest edges of the mesh. (In larger hernias, as previously noted, insertion of two ports opposite each other may be necessary.) The circumferential

dissection of the peritoneum performed to improve inclusion of the mesh in tissues could be regarded as a difficult step of the procedure. But it does not involve complete dissection of the peritoneal lining of the hernial sac, but only of the circumference. Thus, starting from the most caudal part and continuing on both sides cranially, allowed completion of the procedure without having tissue hanging in the view of the laparoscope. Another difficulty encountered was loss of pneumoperitoneum during insertion of the mesh through the trocar. The effects of this loss was minimised in our case by application of 2 transfascial stay sutures at the cranial and caudal edges of the hernia that were tensed by an assistant while the surgeon passed the mesh through the trocar. Although this procedure was performed in one case only, it does demonstrate that single-port laparoscopy using an operating laparoscope is feasible and allows proper placement of an ePTFE intraperitoneal mesh. Nevertheless, a larger number of cases treated with this technique is needed to prove that this technique is advantageous compared to conventional multiportal laparoscopic herniorrhaphy or traditional, open methods of incisional herniorrhaphy.

Author's declaration of interests No conflicts of interest have been declared. Ethical animal research Informed consent was obtained from the owner before surgery. Source of funding None. Antimicrobial stewardship policy The manuscript complies with the Antimicrobial stewardship policy, and Critically Important Antimicrobials have been used in the described case. Authorship All authors contributed equally to the study preparation of the manuscript and approved the manuscript. Manufacturers' addresses 1 Esaote Spa, 50127 Firenze, Italy. 2 Roche, Milano, Italy. 3 Intervet Italia srl, Milano, Italy. 4 Stryker Italia, Roma, Italy. 5 Covidien, Segrate Milano, Italy. 6 Karl Storz GmbH & Co. KG, Tuttlingen, Germany.

7 Alsa Apparecchi Medicali, Bologna, Italy. 8 Gore spa, Verona, Italy. 9 Viscot Medical, East Hanover, New Jersey, USA. 10 Care Fusion Italia, Firenze, Italy. 11 Fatro spa, Ozzano Emilia, Bologna, Italy.

## References

- Alexander, A.M. and Scott, D.J. (2013) Laparoscopic ventral hernia repair. *Surg. Clin. N. Am.* 93, 1091-1110.
- Bansal, V.K., Misra, M.C., Kumar, S., Rao, Y.K., Singhal, P., Goswami, A., Guleria, S., Arora, M.K. and Chabra, A. (2011) A prospective randomized study comparing suture mesh fixation versus tacker mesh fixation for laparoscopic repair of incisional and ventral hernias. *Surg. Endosc.* 25, 1431-1438.
- Basile, F., Biondi, A. and Donati, M. (2013) Surgical approach to abdominal wall defects: history and new trends. *Int. J. Surg.* 11, 20-23.
- Bucher, P., Pugin, F. and Morel, P. (2011) Single-port access prosthetic repair for primary and incisional ventral hernia: toward less parietal trauma. *Surg. Endosc.* 25, 1921-1925.
- Caron, J.P. (2012) Mesh incisional hernioplasty. In: *Advances in equine laparoscopy*, 1st edn., Ed: Ragle, A., Wiley-Blackwell, Ames. p 260. Caron, J.P. (2014) Incisional hernia repair in horses: a cadaveric study of endoscopic component separation. *Vet. Surg.* 43, 1-5.
- Caron, J.P. and Mehler, S.J. (2009) Laparoscopic mesh incisional hernioplasty in five horses. *Vet. Surg.* 38, 318-325. Dupre, G., Fiorbianco, V., Skalicky, M., Gultiken, N., Ay, S.S. and Findik, M. (2009) Laparoscopic ovariectomy in dogs: comparison between single portal and two-portal access. *Vet. Surg.* 38, 818-824.
- Elce, Y.A., Kraus, B.M. and Orsini, J.A. (2005) Mesh hernioplasty for repair of incisional hernias of the ventral body wall in large horses. *Equine Vet. Educ.* 17, 252-256. Gandini, M. and Giusto, G. (2014) A new technique for laparoscopic trocar site closure: feasibility study and comparison with a previously described method in pigs. In: *Proceedings of the 49th Congress of the European Society of Surgical Research* 52, 204.

- Heltmeier, T. and Groebli, Y. (2013) Small bowel lesion due to spiral tacks after laparoscopic intraperitoneal onlay mesh repair for incisional hernia. *Intern. J. Surg. Case Rep.* 4, 283-285.
- Heniford, B.T. and Ramshaw, B.J. (2000) Laparoscopic ventral hernia repair. *Surg. Endosc.* 14, 419-423.
- Karahasanoglu, T., Onur, E., Baca, B., Hamzaoglu, I., Pekmezci, S., Boler, D.E., Kilic, N. and Altug, T. (2004) Spiral tacks may contribute to intra-abdominal adhesion formation. *Surg. Today* 34, 860-864.
- Kelmer, G. and Schumacher, J. (2008) Repair of abdominal wall hernias in horses using primary closure and subcutaneous implantation of mesh. *Vet. Rec.* 163, 677-679.
- Khosla, A. and Ponsky, T.A. (2011) Use of operative laparoscopes in singleport surgery: the forgotten tool. *J. Minim. Access Surg.* 7, 116-120.
- LeBlanc, K.A., Bellanger, D., Rhynes, K.V., Baker, D.G. and Stout, R.W. (2002) Tissue attachment strength of prosthetic meshes used in ventral and incisional hernia repair. *Surg. Endosc.* 16, 1542-1546.
- Lee, S.Y., Lee, H.M., Kao, C.Y. and Chuang, J.H. (2012) Transumbilical 1-port laparoscopic resection of benign ovarian tumor. *J. Pediatr. Surg.* 47, 1340-1344.
- Misra, S. (2011) SMILS: Single-site, multi-incision, laparoscopic surgery, the way forward? *J. Minim. Access. Surg.* 7, 253-254.
- Podolsky, E.R., Mouhlas, A., Wu, A.S., Poor, A.E. and Curcillo, P.G. (2010) Single port access (SPATM) laparoscopic ventral hernia repair: initial report of 30 cases. *Surg. Endosc.* 24, 1557-1561.
- Ramakrishna, H.K. and Lakshman, K. (2013) Intra peritoneal polypropylene mesh and newer meshes in ventral hernia repair. *Ind. J. Surg.* 75, 346-351
- . Reynvoet, E., Deschepper, E., Rogiers, X., Troisi, R. and Berrevoet, F. (2014) Laparoscopic ventral hernia repair: is there an optimal mesh fixation technique? A systematic review *Langenbecks Arch. Surg.* 399, 55-63.
- Rhee, R., Fernandez, G., Bush, R. and Seymour, N.E. (2014) The effects of viewing axis on laparoscopic performance: a comparison of non-expert and expert laparoscopic surgeons. *Surg. Endosc.* 28, 2634-2640.
- Rijkenhuizen, A.B.M. (2005) Laparoscopic repair of a traumatic ventral abdominal hernia using a mesh. *Equine Vet. Educ.* 17, 243-251.
- Roy, P. and De, A. (2011) Single-incision laparoscopic intraperitoneal onlay mesh hernioplasty for anterior abdominal wall hernia: a safe and feasible approach. *J. Minim. Access Surg.* 7, 37-39.
- Stylianou, S., Nichols, L., Ventura, N., Malvezzi, L., Knight, C. and Burnweit, C. (2011) The "all-in-one" appendectomy: quick, scarless, and less costly. *J. Pediatr. Surg.* 46, 2336-2341.
- Surour, M.A. (2014) Interposition of the omentum and/or the peritoneum in the emergency repair of large ventral hernias with polypropylene mesh. *Int. J. Surg.* 12, 578-586.
- Tullerens, E.P. and Fretz, P.B. (1983) Prosthetic repair of large abdominal wall defects in horses and food animals. *J. Am. Vet. Med. Ass.* 182, 258-262.
- Vander Velden, M.A. and Klein, W.R. (1994) A modified technique for implantation of polypropylene mesh for the repair of external abdominal hernias in horses: a review of 21 cases. *Vet. Q* 16, 108-110.
- Vilar, J.M., Doreste, F., Spinella, G. and Valentini, S. (2009) Double-layer mesh hernioplasty for repair of incisional hernias in 15 horses. *J. Equine. Vet. Sci.* 29, 172-176.
- Whitfield-Cargile, C.M., Rakestraw, P.C., Hardy, J., Cohen, N.D. and Davis, B.E. (2011) Comparison of primary closure of incisional hernias in horses with and without the use of prosthetic mesh support. *Equine Vet. J.* 43, 69-75.

Figures:



Fig 1: The long tails of the sutures mark the correct surgical orientation.

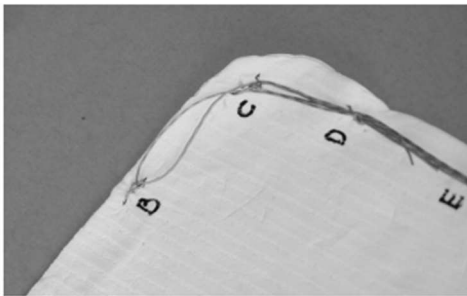


Fig 2: The long tails of the sutures are clinched into the adjacent knot.




Fig 3: The atraumatic forceps and operating laparoscope (A). To perform the procedure, the atraumatic forceps are passed through the service channel of the operating laparoscope (B).

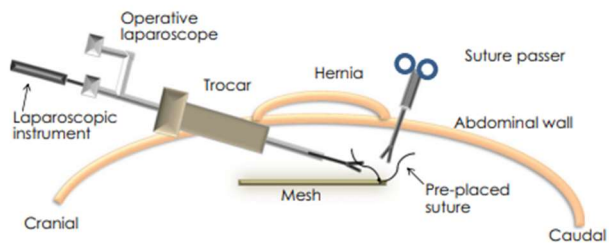


Fig 4: Diagram showing instruments positions and procedures.