

AperTO - Archivio Istituzionale Open Access dell'Università di Torino

**Adjunctive efficacy of diode laser in the treatment of peri-implant mucositis with mechanical therapy: A randomized clinical trial**

**This is the author's manuscript**

*Original Citation:*

*Availability:*

This version is available <http://hdl.handle.net/2318/1710809> since 2019-08-30T10:11:43Z

*Published version:*

DOI:10.1111/clr.13428

*Terms of use:*

Open Access

Anyone can freely access the full text of works made available as "Open Access". Works made available under a Creative Commons license can be used according to the terms and conditions of said license. Use of all other works requires consent of the right holder (author or publisher) if not exempted from copyright protection by the applicable law.

(Article begins on next page)



# UNIVERSITÀ DEGLI STUDI DI TORINO

*This is an author version of the contribution published on:  
Questa è la versione dell'autore dell'opera:*

Aimetti M, Mariani GM, Ferrarotti F, Ercoli E, Liu CC, Romano F

Adjunctive efficacy of diode laser in the treatment of peri-implant mucositis  
with mechanical therapy: a randomized clinical trial.

Clinical Oral Implants Research 2019;30(5):429-438.

doi. 10.1111/clr.13428

*The definitive version is available at:  
La versione definitiva è disponibile alla URL:  
<https://onlinelibrary.wiley.com/doi/10.1111/clr.13428>*

**Adjunctive efficacy of diode laser in the treatment of peri-implant mucositis with mechanical therapy: a randomized clinical trial.**

Mario Aimetti \*, Giulia Maria Mariani \*, Francesco Ferrarotti\*, Elena Ercoli\*, Chun Ching Liu\*,  
Federica Romano\*

\*Department of Surgical Sciences, C.I.R. Dental School, University of Turin, Turin, Italy.

**Correspondence to:**

Prof. Mario Aimetti

Section of Periodontology, C.I.R. Dental School, Via Nizza 230 10126 Turin (Italy)

Tel: +390116331543 Fax: +390116331506 E-mail: [mario.aimetti@unito.it](mailto:mario.aimetti@unito.it)

**Running title:** Laser therapy in peri-implant mucositis

**Keywords:** decontamination; dental implant; diode laser; inflammation; mucositis.

**Word count:** 3999

**Number of figures:** 2

**Number of tables:** 6

**Number of references:** 56

## ABSTRACT

**Objectives:** Due to the inconclusive findings on the effect of laser therapy in the management of peri-implant diseases, the aim of this study was to analyze the adjunctive clinical efficacy of 980-nm diode laser (DL) irradiation in the treatment of peri-implant mucositis with mechanical debridement.

**Material and methods:** Two hundred and twenty patients with one implant diagnosed with peri-implant mucositis (probing depth (PD)  $\geq$  4 mm and bleeding on probing (BoP) (primary outcome)) were randomly allocated to test and control treatments. Patients in the control group (n = 110) received debridement using curettes and ultrasonic devices, while patients allocated in the test group (n = 110) received mechanical therapy in combination with DL irradiation (setting 980 nm, 2.5 W, 10 KHz, pw, 30 s). BoP, presence of plaque and PD were recorded at baseline, 1 month and 3 months after treatment.

**Results:** Both therapeutic modalities yielded similar clinical improvements with comparable reductions in the number of BoP-positive sites, plaque scores and PD values at 3 months (all *P*-values  $>$  0.05). Complete disease resolution was obtained in 38/110 (34.5%) implants in the test group compared with 34/110 (30.9 %) implants in the control group at the end of the observation period.

**Conclusion:** Based on these results, the adjunct use of DL did not yield any statistically significant clinical benefit as compared to non-surgical mechanical treatment alone in controlling peri-implant inflammation at 3 months.

## INTRODUCTION

The plaque-induced inflammatory disease confined to the peri-implant soft tissue compartment without any bone loss, named as peri-implant mucositis, frequently occurs in patients restored with dental implants (Renvert, Persson, Pirih, Camargo, 2018). It is estimated that it affects approximately 21% to 88% of patients and 9% to 51% of the implant sites with a mean weighted prevalence of 47% and 29%, respectively, as reported in a recent systematic review (Lee, Huang, Zhu, Weltman, 2017). It is a reversible condition if inflammation is properly controlled, but if left untreated it may progress to peri-implantitis with loss of supporting bone around implants (Renvert, et al., 2018). Since successful treatment of peri-implantitis continues to be challenging because of its complexity and the absence of established guidelines (Clark, Levin, 2016; Salvi, Zitzmann, 2014), the prevention and treatment of peri-implant mucositis have acquired increasing importance (Tonetti, Chapple, Jepsen, Sanz, 2015).

For the management of peri-implant mucositis, different methods of decontamination of the implant surface have been proposed including mechanical curettage alone or associated with local or systemic antimicrobials (Suárez-López del Amo, Yu, Wang, 2016), glycine powder air polishing (Ji, et al., 2014; Riben-Grundstrom, Norderyd, André, Renvert, 2015) or probiotic supplements (Hallström, Lindgren, Widén, Renvert, Twetman, 2016). However, some of these methods can damage the surface properties of implants, promote bacterial resistance or cannot access to complex three-dimensional geometries of implant sites (Louropoulou, Slot, Van der Weijden, 2012; Ungvari, et al., 2010). In recent years the use of laser has received increasing attention for treating periodontal and peri-implant infections due its anti-infective properties against periodontal pathogens, easy handling, and hemostatic effects (Mizutani, et al., 2016). *In vitro* studies have demonstrated that the CO<sub>2</sub> laser, the diode laser (DL), and the erbium-doped yttrium aluminum garnet – Er:YAG – laser may be suitable for the irradiation of titanium surfaces, since they do not cause thermal increase (Kreisler, Al Haj, Gotz, Duschner, d’Hoedt, 2002; Oyster, Parker, Gher, 1995). The 980-nm DL may be attractive due its safety when used directly on the implant surface, its capacity of soft tissue penetration and removal of pocket epithelium along with its antibacterial and biostimulating effects (Aoki, et al., 2008; Romanos, et al., 2004; Romanos, Everts, Nentwig, 2000). It detoxifies implant surfaces by killing pathogenic bacteria through photo-

thermal effects and by inactivating bacterial endotoxins (Gokhale, et al., 2012; Gonçalves, et al., 2010). Biostimulation has proven to enhance the mRNA expression of insulin growth factor, transforming growth factor-beta and vascular endothelial growth factor in human gingival fibroblasts stimulating the connective tissue metabolism (Hakki, Bozkurt, 2012). This promotes the periodontal healing process and enhances the functional connective attachment to titanium implants (Khadra, Lyngstadaas, Haanæs, Mustafa, 2005). Some studies using the same wavelength led to satisfactory clinical and microbiological results in the treatment of periodontitis (Qadri, Javed, Johanssen, Gustafsson, 2015). However, this laser has the risk of heat generation on surrounding tissue when used with improper irradiation parameters and techniques. This is more likely to occur in presence of tissue inflammation because it is highly absorbed in hemoglobin and other chromophores (Aoki, et al., 2015).

Data about the effect of laser therapy in the management of peri-implant mucositis are inconclusive (Albaker, ArRjaie, Alrabiah, Adduljabbar, 2018), and only little information is available on the application of DL in the treatment of peri-implant diseases (Lerario, et al., 2016; Mettraux, Sculean, Burgi, Salvi, 2016). In view of these considerations, the aim of the present randomized controlled trial was to analyze the adjunctive clinical efficacy of 980-nm DL irradiation in the management of peri-implant mucositis with mechanical debridement.

## **MATERIAL AND METHODS**

### **Study design and study population**

This study was a double-blinded, randomized, parallel, 3-month clinical trial conducted in accordance with the revised Helsinki Declaration and approved by the Institutional Ethics Committee (n° 1001/2016). This report was written following the CONSORT guidelines for reporting clinical trials.

Study participants were consecutively recruited from adult patients requiring treatment of peri-implant mucositis between May 2016 and July 2017 at the Section of Periodontology, C.I.R. Dental School of the University of Turin (Italy). The clinical procedures and evaluations were carried out between September 2016 and November 2017. All eligible individuals signed an informed consent document before enrollment.

For participating in the study, the following inclusion criteria and case definition (AAP, 2013) were used: 1) presence of one or more peri-implant mucositis sites with probing depth (PD)  $\geq$  4 mm

combined with bleeding on probing (BoP) under light forces (0.25 N) with or without suppuration and no evidence of radiographic bone loss beyond bone remodeling. Marginal bone loss  $\leq 1$  mm as compared to radiographs exposed at the prosthetic delivery or in the absence of previous radiographs a vertical distance  $< 2$  mm from the expected crestal bone level following remodeling were considered for enrollment (Sanz, Chapple, the Working Group 4 of the VIII European Workshop on Periodontology, 2012); 2) no evidence of occlusal overload (i.e. occlusal contacts revealed appropriate adjustment); 3) no cement remnants identified on radiographs and clinically by running a probe in peri-implant sulcus or, when possible, by visual inspection using compressed air; 4) implant-supported fixed restorations inserted at least 6 months before patient enrollment and not interfering with assessment of clinical parameters; 5) periodontally healthy patients or treated chronic periodontitis patients without residual sites with PD  $\geq 5$  mm after active treatment; 6) full-mouth plaque score (FMPS) and full-mouth bleeding score (FMBS)  $\leq 20$  % at the screening visit; 7) non-smokers or light smokers ( $< 10$  cigarettes/day). Exclusion criteria were as follows: 1) systemic diseases which could influence the outcomes of the therapy (such as bone metabolic and hematologic disorders, uncontrolled diabetes, radiotherapy in the head and neck area); 2) current use of steroids and bisphosphonates; 3) peri-implantitis; 4) pregnancy or lactation.

### **Sample size and randomization**

The primary outcome was resolution of inflammation, as evidenced by the absence of BoP. Considering as clinically relevant a difference of 20% in terms of frequency in BoP-positive sites between the 2 treatment groups at 3-month follow-up, a power calculation gave a sample size of 100 patients per treatment group to have an 80% power to detect a significant difference ( $\alpha = 0.05$ ) based on data from Lerario et al. (2016). To compensate for possible dropouts the sample size was adjusted to 220 patients (110 per group).

After enrollment, each patient was given an ascending number and was randomly assigned to receive at the experimental sites either the test (mechanical debridement and DL) or the control procedure (mechanical debridement alone) by a computer-generated table. A balanced randomly permuted block was used to prepare the randomization table. Each patient provided a single implant to be treated. If

more than one implant with mucositis was present, a random number generator was used to choose the implant to be included in the study. To conceal assignment, forms with the treatment modality were put into identical and opaque envelopes with the patient corresponding number on the outside. The sealed envelopes were placed into the custody of a clinician not involved in the study (MA). He opened the envelope just prior to treatment delivery and informed the clinician which treatment was to be performed. Examiners and patients were unaware of the allocation to test or control protocol for the duration of the study. The statistical analyses were performed with coded group identification.

### **Treatment**

After baseline examination all test and control participants received individualized home oral hygiene instructions to perform carefully the rolling brushing technique procedure in the peri-implant area and the Bass modified technique around teeth, and the inter-proximal cleaning with dental floss (Oral-B, Procter & Gamble, Weybridge, UK) or interdental brush (TePe Munhygienprodukter, Malmo, Sweden).

The test group was treated with 980-nm DL application at 2.5 W in pulsed mode (mean 0.7 W, 10 KHz, time  $t_{on} = 30 \mu s$ , time  $t_{off} = 70 \mu s$ , 30% dc, fluence  $120 J/cm^2$ ). The 300- $\mu m$  optical fiber was inserted parallel to the longitudinal axis of the implant, up to 1 mm from the most apical portion of the sulcus, and moved, during laser light emission, in apico-coronal and mesio-distal direction for 30 s. The laser tip was checked and cleansed with sterile saline after 7-8 s to prevent hotspots in the soft tissues (Kreisler et al., 2002). The DL application was preceded and followed by pocket irrigation with 3% hydrogen peroxide solution for 10 s. Subsequently, mechanical debridement was carried out with both ultrasonic and manual instruments (titanium-coated Gracey curettes or carbon fiber curettes) to remove all soft and calcified deposits. The DL application and mechanical debridement was repeated three times for each inflamed site as previously reported (Mettraux et al., 2016; Roncati, Lucchese, & Carinci, 2013; Roncati & Gariffo, 2016). Finally, biostimulation was performed by using a specific handpiece with an output lens of about 1 cm in diameter, characterized by a defocalized beam, for 60 s at 0.7 W, in continuous wave (frequency 20 Hz, fluence  $1 J/cm^2$ ). The handpiece was kept perpendicular to the peri-implant mucosa, and was guided in a circular motion from coronal to apical in



paths parallel to the implant surface and in the contact mode. The procedure was repeated the following day (Roncati, Lucchese, & Carinci, 2013).

The control group received the same treatment procedures, but without any DL irradiation. The laser tip was inserted into the peri-implant sulcus but not activated. In both groups instrumentation was carried out until the operator felt the surface adequately debrided. The time for debridement was comparable in test and control implants and varied between 7 and 10 min. Treatments were provided by three operators (GMM, FF, CCL) previously trained in using DL by an experienced clinician.

All test and control patients were recalled at 1 month and 3 months after the completion of the non-surgical treatment for reinforcement in oral hygiene instructions and professional implant cleaning with rubber cups (Pro-Cup, Kerr Italia, Srl, Scafati, SA, Italy) and polishing paste (CleanPolish, Kerr Italia, Srl, Scafati, SA, Italy).

### **Outcomes**

Two examiners, who were blinded to the group assignment, performed all measurements of clinical assessment. Each patient was re-evaluated by the same clinician who performed the baseline examination. Before study initiation, each examiner was calibrated for intra- and inter-examiner reproducibility using duplicate measurements of a minimum of 30 non-study implants. The correlation coefficient for the intra-examiner reproducibility was from 0.93 to 0.97; for the inter-examiner reproducibility, it was from 0.91 to 0.95.

The following parameters were recorded at six sites of each selected implant by means of a graduated plastic probe (Hu-Friedy, Chicago, IL, USA) at baseline, at 1 month and 3 months of follow-up: 1) presence/absence of plaque along the mucosal margin expressed in percentage ([PI] %); 2) presence/absence of BOP (%) during probing around implants expressed in percentage; 3) peri-implant PD (mm) calculated as the distance between the peri-implant margin and the bottom of the peri-implant sulcus/pocket; 4) recession (mm) of the mucosal margin relative to the restoration margin (REC) at two sites (buccal and lingual/palatal). The FMPS and FMBS were also calculated at baseline and at 3 months postoperatively.

### **Statistical analysis**

Data were first examined for normality using the Kolmogorov-Smirnov test; the data that achieved

normality were analyzed using parametric methods. The homogeneity of groups at baseline was tested using the unpaired *t*-test (FMBS, FMPS, PD) and the Mann-Whitney *U*-test (PI, BoP). Differences between groups in qualitative variables scores were assessed by means of the Chi-square test. Repeated-measures ANOVA and the Friedman's test were used to detect intragroup differences in clinical parameters over time. Multiple comparisons were conducted with the post-hoc tests (Newman-Keuls test and Dunn test). Subsequently, intergroup differences in FMPS, FMBS, and PD were statistically explored using the unpaired student *t*-test and differences in BoP and PI parameters with the Mann-Whitney *U*-test. The Bonferroni correction was applied for multiple comparisons. Comparisons between patients treated by different operators were performed for assessing differences in distribution of demographic and clinical variables by using chi-square, ANOVA or Kruskal-Wallis tests. All statistical tests were conducted at a 5% level of significance using a statistical tools package (SPSS version 19, IBM, Chicago, IL, USA).

## RESULTS

Figure S1 summarizes the flow chart of the study. Two hundred and sixty-six subjects were assessed for their eligibility. Of these 46 were excluded: 39 did not meet the inclusion criteria, while the other 7 refused to participate. As a result, a total of 220 patients with peri-implant mucositis (149 females and 71 males, mean age  $57.5 \pm 10.1$  years, range 32-78 years) were enrolled in the study and randomly assigned to the test or control procedures. All participants (110 [test] and 110 [control]) received the allocated procedure and were included in the statistical analyses.

Patient characteristics at baseline were not significantly different ( $P > 0.05$ ) between groups (Table 1). The distributions of dental implants with mucositis were: 7.2% incisive, 5.5% canine, 47.3% premolar and 40% molar for the test group and 10.9% incisive, 8.2% canine, 38.2% premolar and 42.7% molar, for the control group. Peri-implant tissue healing in both groups was uneventful in all treated patients. As reported in Table 2, FMPS and FMBS remained below 20% during the experimental phase in both treatment groups. Between-group analyses did not indicate relevant differences.

Mean and median PI, BoP, and PD values and the respective changes from baseline to 1 month and 3 months after treatment in both experimental groups are summarized in Table 3. No statistically significant differences were detected for any of the baseline clinical parameters between treatment

modalities. Both treatments were associated with comparable and significant reduction in mean PI and PD values after 3 months of healing (all  $P < 0.001$ ). Mucosal recessions of 1-3 mm were observed in 15 subjects (6 test and 9 controls). No differences were found within and between groups at the end of the study.

Regarding BoP scores, changes were more pronounced at 1-month follow-up in patients treated with adjunctive DL application ( $P < 0.01$ ), but at 3-month follow-up both groups experienced comparable low residual BoP scores ( $P > 0.05$ ). Smoking habits did not influence clinical outcomes in terms of BoP and PD (Table 4), while patients with a previous history of periodontitis experienced less improvement in PD at 3 months (Table 5). In spite of the higher reduction in the percentage of BoP-positive sites in the periodontitis group as compared to periodontally healthy individuals, the differences did not reach statistical significance (Table 5).

The frequency distribution of peri-implant mucositis at baseline and the frequency of disease resolution at 3 months after non-surgical treatment at site and implant level are reported in Table 6. Disease resolution was obtained at 198 out of 319 (62.1%) sites diagnosed for peri-implant mucositis and at 38 of 110 (34.5%) implants in the test group. In the control group disease resolution was obtained at 166 out of 305 (54.4%) sites diagnosed for peri-implant mucositis and at 34 of 110 (30.9%) implants. The differences between the treatment groups were not statistically significant ( $P = 0.651$  and  $P = 0.548$ ).

When analysing the results for inter-operator comparison, no differences were recorded in patient demographic characteristics (Table S1) as well as in clinical outcomes (Table S2) among different operators. Two clinical cases are presented in Figs 1 and 2.

## **DISCUSSION**

Due to the lack of evidence in the literature (Albaker, ArRjaie, Alrabiah, Adduljabbar, 2018), the present RCT was aimed to compare the effect of mechanical debridement with and without 980-nm DL irradiation on clinical outcomes in peri-implant mucositis. The duration of the present study was set at 3 months based on the clinical and biochemical results by Salvi et al. (2012) that suggested a healing period longer than 3 weeks to obtain the clinical healing of peri-implant tissues.

Results showed that both treatment modalities reduced BoP and PD after 3 months, but no statistically significant added value was observed in the use of DL. These findings demonstrate that the

professional mechanical removal of bacterial biofilm in conjunction with proper self-performed plaque control is effective alone in the treatment of peri-implant mucositis. It should be emphasized that patients in both treatment groups maintained low plaque indices (< 20%) during the whole study period, demonstrating good oral hygiene performance and successful re-motivation during the post-treatment controls. Effective biofilm control by patients has been widely demonstrated as a requisite for successful implant therapy (Salvi, Lang, 2004).

In spite of the heterogeneous definitions among studies, bleeding on gentle probing is currently recognized the key parameter for the diagnosis of peri-implant mucositis (Renvert, et al., 2018) due to its correlation with mucosal inflammation at the histological level (Lang, Wetzel, Stich, Caffesse, 1994). Therefore, the clinical endpoint following non-surgical treatment of mucositis lesions should be complete disease resolution, as evidenced by the absence of BoP (Sanz, et al., 2012). At the 3-month follow-up, complete resolution of BoP was achieved in 35% and 31% of implants in the test and control group, respectively; corresponding percentages were 62% and 54% at the site level. These findings are in line with those of other clinical studies evaluating treatment of peri-implant mucositis lesions with mechanical instrumentation alone (Máximo, et al., 2009) or in combination with the topical application of chlorhexidine (Heitz-Mayfield, et al., 2011; Schwarz, John, Hegewald, Becker, 2015) or with glycine powder (Ji, et al., 2014; Riben-Grundstrom, et al., 2015). A recent systematic review reported residual BoP scores between 14.7% and 47.5%, indicating that complete resolution of inflammation could not be expected at all implant sites regardless of the non-surgical protocol tested (Schwarz, Becker, Sager, 2015).

Notably, DL application was more effective in reducing peri-implant inflammation in the first month postoperatively. At this time point the difference in BoP between test and control peri-implant sites was statistically significant ( $P \leq 0.001$ ).

Reversibility of peri-implant mucositis is not necessarily related to PD. Menezes et al. (2016) observed a weak correlation between PD and BoP at mucositis sites. The PD changes in the current study are in accordance with data from previous trials on mechanical treatment combined with anti-infective decontamination reporting a PD reduction of 0.40 mm to 0.63 mm (Heitz-Mayfield, et al., 2011; Ji, et al., 2014; Thöne-Mühling, et al., 2010).

Most of the data on the use of DL in the management of peri-implant diseases referred to the treatment of peri-implantitis (Arisan et al. 2015; Mettraux et al. 2016; Papadopoulos et al. 2015; Roncati, Lucchese, & Carinci, 2013), and revealed a high variability in the treatment outcomes, which could be partly attributed to differences in wavelengths (810 nm and 980 nm), laser setting and application time. The use of 810-nm DL as adjunct of mechanical debridement in the treatment of mucositis and peri-implantitis was assessed in only one retrospective study (Lerario et al., 2016). The authors reported that 5% of implant sites treated by the combined treatment displayed persisting inflammation compared to 60% of control sites at 1 year. These favourable results were attributed to the DL action against periodontal pathogens as well as to its biostimulating property promoting wound healing (Aoki et al., 2015). However, data were not stratified on the peri-implant diseases, the experimental groups were unbalanced with more patients allocated in the test group, and four of the six patients in the control group were smokers. In our study at 3-month follow-up 38% and 46% of the test and control peri-implant sites were still BoP-positive. These results agree with the findings of other clinical studies where DL was used in non-surgical periodontal treatment (Slot, Jorritsma, Cobb, & Van der Weijden, 2014) or other types of laser were applied for the resolution of peri-implant mucositis (John, Becker, Schmucker, & Schwarz, 2017; Zeza, Farina, Pilloni, & Mongardini, 2017).

The present study is, to the authors' knowledge, the first controlled clinical trial on the use of a 980-nm DL at peri-implant mucositis sites with a stringent experimental design. The selection of the irradiation parameters was based on previous clinical investigations (Roncati & Gariffo, 2016; Roncati, et al., 2013). According to Choi et al. (2010) the stimulatory effect of DL on periodontal fibroblasts begins to manifest within 24 to 36 h after laser treatment, accelerating the healing process and encouraging the recovery of periodontal attachment. Laser irradiation two times in 24 h may promote this biological process.

Data from *in vitro* studies showed that 980-nm DL was effective in decontaminating rough, smooth and sand blasted implant surfaces at 2.5 W (Gonçalves, et al., 2010) and did not damage titanium surface texture irrespective of the energetic parameters used during irradiation (Romanos, Everts, & Nentwig, 2000). Moreover, the present energy fluence was within the limits of safety to use on titanium surfaces without causing any damage, according to the study by Stübinger et al. (2010). It is important to point

out that the irradiation was directed toward the soft-tissue side. Typically DL is absorbed by melanin, hemoglobin and other chromophores that are present into peri-implant soft tissues, with 810-nm DL being absorbed more readily by hemoglobin than 980-nm laser (Aoki, et al., 2008). To prevent any coagulation and temperature increase, regular check and cleaning of the application tip were carried out every 7-8 s (Kreiser, et al., 2002). We used a pulsed emission that has the clinical advantage to enable the thermal relaxation during the time-off avoiding the overheating of radiated tissues. Anyway, when using according to appropriate parameters the DL laser does not cause visible surface changes and does not generate temperature increase more than 47°C (Romanos, et al., 2000; Stübinger, et al., 2010).

DL application was also preceded and followed by irrigation with 3% hydrogen peroxide solution. Laser energy activates the hydrogen peroxide solution, releasing free radicals and singlet oxygen and thus enhancing antibacterial activity on periodontal pathogens (Caccianiga, Baldoni, Ghisalberti, Pausco, 2016).

It is noteworthy that in the current study smoking did not have any significant effect in BoP or PD reduction. These findings could be explained by the small number of smokers and by the exclusion of heavy smokers from the study population.

An important factor was the negative effect of a previous history of periodontitis on the treatment outcomes (Sgolastra, Petrucci, Severino, Gatto, Monaco, 2015). Patients with chronic periodontitis had statistically significant less reduction in PD than those with no history of periodontitis. No statistically significant differences were detected for BoP. All patients, irrespective of the diagnosis of periodontitis, belonged to a cohort of subjects displaying a good compliance in home oral hygiene procedures before the non-surgical treatment. This aspect could have been important also in causing the absence of dropouts in attending the follow-up visits due to the high motivation of the enrolled patients. Therefore, conclusions can be drawn only for this group of patients. This limits data generalizability.

Limitations of the present study rely on the enrollment of implants with different configurations and surfaces. However, similar soft and hard tissue healing response was observed on different implant surfaces (Abrahamsson, Berglundh, Wennström, Lindhe, 1996; Zitzmann, Abrahamsson, Berglundh, Lindhe, 2002). Another aspect to be taken in account is that a minimum width of keratinized mucosa

was not considered in the inclusion criteria. Recent studies have discussed the role of less than 2 mm of keratinized mucosa in controlling peri-implant inflammation. While some studies demonstrated increased levels of plaque and inflammation around implants in the absence of keratinized mucosa (Schrott, Jimenez, Hwang, Fiorellini, Weber, 2009; Zigdon, Machtei, 2008), others failed to confirm it (Frisch, Ziebolz, Vach, Ratka-Kruger, 2015; Mehta, Lim, 2010). It has to be considered that plaque levels were low and similar between test and control groups.

Finally, the current study presented clinical outcomes within 3 months of follow-up. Clinical relevance of follow-up determines not only effect of treatment, but also duration of this effect (Zeza, Piloni, 2012).

In conclusion, the present study indicated that the adjunctive use of 980-nm DL did not yield any statistically significant clinical benefit as compared to mechanical debridement alone in non-surgical treatment of peri-implant mucositis after three months, but it was more effective in reducing clinical signs of inflammation during the first month after treatment. At three months complete disease resolution was obtained in 34.5% of implants in the test group and in 30.9% of implants in the control group.

#### **Conflict of Interest Statement**

No financial support was received for this study. The authors have no relationship to any of the commercial products or companies mentioned herein or conflict of interest to declare.

## REFERENCES

- Abrahamsson, I., Berglundh, T., Wennström, J., & Lindhe J. (1996). The peri-implant hard and soft tissues at different implant systems. A comparative study in the dog. *Clinical Oral Implants Research* **7**: 212–219. <https://doi.org/10.1034/j.1600-0501.1996.070303.x>
- Albaker, A. M., ArRjaie, A. S., Alrabiah, M., & Adduljabbar, T. (2018). Effect of photodynamic and laser therapy on peri-implant mucositis: a systematic review. *Photodiagnosis and Photodynamic Therapy* **21**: 147–152. <https://doi.org/10.1016/j.pdpdt.2017.11.01>
- American Academy of Periodontology. (2013). Peri-implant mucositis and peri-implantitis: a current understanding of their diagnoses and clinical implications. *Journal of Periodontology* **84**: 436-443. <https://doi.org/10.1902/jop.2013.134001>
- Aoki, A., Mizutani, K., Schwarz, F., Sculean, A., Yukna, R.A., Takasaki, A. A., Romanos, G. E., Taniguchi, Y., Sasaki, K. M., Zeredo, J. L., Koshy, G., Coluzzi, D. J., White, J. M., Abiko, Y., Ishikawa, I., & Izumi, Y. (2015). Periodontal and peri-implant wound healing following laser therapy. *Periodontology 2000* **68**: 217–269. <https://doi.org/10.1111/prd.12080>
- Aoki, A., Mizutani, K., Takasaki, A. A., Sasaki, K. M., Nagai, S., Schwarz, F., Yoshida, I., Eguro, T., Zeredo, J. L., & Izumi, Y. (2008). Current status of clinical laser applications in periodontal therapy. *General Dentistry* **56**: 674–687.
- Arısan, V., Karabuda, Z. C., Arıcı, S. V., Topcuoğlu, N., & Külekci G. (2015). A randomized clinical trial of an adjunct diode laser application for the nonsurgical treatment of peri-implantitis. *Photomedicine and Laser Surgery* **33**: 547–554. <https://doi.org/10.1089/pho.2015.3956>
- Caccianiga, G., Baldoni, M., Ghisalberti, C. A., & Paiusco, A. (2016). A preliminary in vitro study on the efficacy of high-power photodynamic therapy (HLLT): Comparison between pulsed diode lasers and superpulsed diode lasers and impact of hydrogen peroxide with controlled stabilization. *BioMed Research International* **2016**:1386158. <https://doi.org/10.1155/2016/1386158>
- Choi, E. J., Yim, J. Y., Koo, K. T., Seol, Y. J., Lee, Y. M., Ku, Y., Rhyu, I. C., Chung, C. P., & Kim, T. I. Biological effects of a semiconductor diode laser on human periodontal ligament fibroblasts. (2010). *Journal of Periodontal and Implant Science* **40**:105–110. <https://doi.org/10.5051/jpis.2010.40.3.105>



- Clark, D., & Levin, L. (2016). Dental implant management and maintenance: how to improve long-term implant success? *Quintessence International* **47**: 417–423. <https://doi.org/10.3290/j.qi.a35870>
- Cobb, C.M. (2006). Lasers in periodontics. A review of the literature. *Journal of Periodontology* **77**: 545-564. <https://doi.org/10.1902/jop.2006.050417>
- Frish, E., Ziebolz, D., Vach, K., & Ratka-Kruger P. (2015). The effect of keratinized mucosa width on peri-implant outcome under supportive postimplant therapy. *Clinical Implant Dentistry and Related Research* **17**(Suppl 1): e236–e244. <https://doi.org/10.1111/cid.12187>
- Gokhale, S. R., Padhye, A. M., Byakod, G., Jain, S. A., Padbidri, V., & Shivaswamy, S. (2012). A comparative evaluation of the efficacy of diode laser as an adjunct to mechanical debridement versus conventional mechanical debridement in periodontal flap surgery: a clinical and microbiological study. *Photomedicine and Laser Surgery* **30**: 598–603. <https://doi.org/10.1089/pho.2012.3252>
- Gonçalves, F., Zanetti, A. L., Zanetti, R. V., Martelli, F. S., Avila-Campos, M. J., Tomazinho, L. F., & Granjeiro, J. M. (2010). Effectiveness of 980-nm diode and 1064-nm extra-long-pulse neodymium-doped yttrium aluminum garnet lasers in implant disinfection. *Photomedicine and Laser Surgery* **28**: 273–280. <https://doi.org/10.1089/pho.2009.2496>
- Hakki, S. S., & Bozkurt, S. B. (2012). Effects of different setting of diode laser on the mRNA expression of growth factors and type I collagen of human gingival fibroblasts. *Laser Medical Sciences* **27**: 325–331. <https://doi.org/10.1007/s10103-010-0879-5>
- Hallström, H., Lindgren, S., Widén, C., Renvert, S., & Twetman, S. (2016). Probiotic supplements and debridement of peri-implant mucositis: a randomized controlled trial. *Journal of Periodontology* **87**: 493–501. <https://doi.org/10.3109/00016357.2015.1040065>
- Heitz-Mayfield, L. J., Salvi, G. E., Botticelli, D., Mombelli, A., Faddy, M., & Lang, N. P. (2011). Anti-infective treatment of peri-implant mucositis: a randomized controlled clinical trial. *Clinical Oral Implants Research* **22**: 237–241. <https://doi.org/10.1111/j.1600-0501.2010.02078.x>
- Ji, Y. J., Tang, Z. H., Wang, R., Cao, J., Cao, C. F., & Jin, L. J. (2014). Effect of glycine powder air-polishing as an adjunct in the treatment of peri-implant mucositis: A pilot clinical trial. *Clinical Oral Implants Research* **25**: 683–689. <https://doi.org/10.1111/clr.12123>

- John, G., Becker, J., Schmucker, A., & Schwarz, F. (2017). Nonsurgical treatment of peri-implant mucositis and peri-implantitis at two-piece zirconium implants. A clinical follow-up observation after up to 3 years. *Journal of Clinical Periodontology* **44**: 756–761. <http://doi.org/10.1111/jcpe.12738>.
- Khadra, M., Lyngstadaas, S. P., Haanaes, H. R., & Mustafa, K. (2005). Effect of laser therapy on attachment, proliferation and differentiation of human osteoblast-like cells cultured on titanium implant material. *Biomaterials* **26**: 3503–3509. <https://doi.org/10.1016/j.biomaterials.2004.09.033>
- Kim, B. S., Kim, Y. K., Yun, P. Y., Yi, Y. J., Lee, H. J., Kim, S. G., & Son, J. S. (2009). Evaluation of peri-implant tissue response according to the presence of keratinized mucosa. *Oral Surgery Oral Medicine Oral Pathology Oral Radiology and Endodontics* **107**: e24–e28. <https://doi.org/10.1016/j.tripleo.2008.12.010>
- Kreisler, M., Al Haj, H., Gotz, H., Duschner, H., & d’Hoedt, B. (2002). Effect of simulated CO<sub>2</sub> and GaAlAs laser surface decontamination on temperature changes in Ti-plasma sprayed dental implants. *Lasers Surgery and Medicine* **30**: 233–239. <https://doi.org/10.1002/lsm.10025>
- Lang, N. P., Wetzel, A. C., Stich, H., & Caffesse, R. G. (1994). Histologic probe penetration in healthy and inflamed peri-implant tissues. *Clinical Oral Implants Research* **5**: 191–201.
- Lee, C. T., Huang, Y. W., Zhu, L., & Weltman, R. (2017). Prevalences of peri-implantitis and peri-implant mucositis: systematic review and meta-analysis. *Journal of Dentistry* **62**: 1–12. <https://doi.org/10.1016/j.jdent.2017.04.011>
- Lerario, F., Roncati, M., Gariffo, A., Attorresi, E., Lucchese, A., Galanakis, A., Palaia, G., & Romeo, U. (2016). Non-surgical periodontal treatment of peri-implant diseases with the adjunctive use of diode laser: preliminary clinical study. *Lasers Medical Sciences* **31**: 1–6. <https://doi.org/10.1007/s10103-015-1785-7>
- Louropoulou A., Slot, D. E. & Van der Weijden, F. A. (2012). Titanium surface alterations following the use of different mechanical instruments: a systematic review. *Clinical Oral Implants Research* **23**: 643-658. <https://doi.org/10.1111/j.1600-0501.2011.02208.x>
- Máximo, M. B., De Mendonça, A. C., Renata Santos, V., Figueiredo, L. C., Feres, M., & Duarte, P. M. (2009). Short-term clinical and microbiological evaluations of peri-implant diseases before and after mechanical anti-infective therapies. *Clinical Oral Implants Research* **20**: 99–108.

<https://doi.org/10.1111/j.1600-0501.2008.01618.x>

Mehta, P., & Lim, L. P. (2010). The width of the attached gingiva--much ado about nothing? *Journal of Dentistry* **38**: 517-525. <https://doi.org/10.1016/j.jdent.2010.04.007>

Menezes, K. M., Fernandes-Costa, A. N., Silva-Neto, R. D., Calderon, P. S., & Gurgel, B. C. (2016). Efficacy of 0.12% chlorhexidine gluconate for non-surgical treatment of peri-implant mucositis. *Journal of Periodontology* **87**: 1305–1313. <https://doi.org/10.1902/jop.2016.160144>

Mettraux, G. R., Sculean, A., Bürgin, W. B., & Salvi, G. E. (2016). Two-year clinical outcomes following non-surgical mechanical therapy of peri-implantitis with adjunctive diode laser application. *Clinical Oral Implants Research* **27**: 845–849. <https://doi.org/10.1111/clr.12689>

Mizutani, K., Aoki, A., Coluzzi, D., Yukna, R., Wang, C., Pavlic, V., & Izumi, Y. (2016). Lasers in minimally invasive periodontal and peri-implant therapy. *Periodontology 2000* **71**: 185–212. <https://doi.org/10.1111/prd.12123>

Oyster, D. K., Parker, W. B., & Gher, M. E. (1995). CO2 lasers and temperature changes of titanium implants. *Journal of Periodontology* **66**: 1017–1024. <https://doi.org/10.1902/jop.1995.66.12.1017>

Papadopoulos, C. A., Vouros, I., Menexes, G., & Konstantinidis, A. (2015). The utilization of a diode laser in the surgical treatment of peri-implantitis. A randomized clinical trial. *Clinical Oral Investigations* **19**: 1851–1860. <https://doi.org/10.1007/s00784-014-1397-9>

Qadri, T., Javed, F., Johannsen, G., & Gustafsson, A. (2015). Role of diode lasers (800–980 nm) as adjuncts to scaling and root planing in the treatment of chronic periodontitis: A systematic review. *Photomedicine and Laser Surgery* **33**: 568–575. <https://doi.org/10.1089/pho.2015.3914>.

Renvert, S., Persson, G. R., Pirihi, F. Q., & Camargo, P. M. (2018). Peri-implant health, peri-implant mucositis, and peri-implantitis. Case definitions and diagnostic considerations. *Journal of Clinical Periodontology* **45**(Suppl 20): S278–S285. <https://doi.org/10.1111/jcpe.12956>

Riben-Grundstrom, C., Norderyd, O., André, U., & Renvert, S. (2015). Treatment of peri-implant mucositis using a glycine power air-polishing or ultrasonic device: a randomized clinical trial. *Journal of Clinical Periodontology* **42**: 462–469. <https://doi.org/10.1111/jcpe.12395>

Romanos, G. E., Everts, H., & Nentwig, G. H. (2000). Effects of diode and Nd:YAG laser irradiation on titanium discs: a scanning electron microscope examination. *Journal of Periodontology* **71**: 810–

815. <https://doi.org/10.1902/jop.2000.71.5.810>

Romanos, G. E., Henze, M., Banihashemi, S., Parsanejad, H. R., Winckler, J., & Nentwig, G. H. (2004). Removal of epithelium in periodontal pockets following diode (980 nm) laser application in the animal model: an in vitro study. *Photomedicine and Laser Surgery* **22**: 177–183. <https://doi.org/10.1089/1549541041438597>

Roncati, M., & Gariffo, A. (2016). Three years non surgical periodontal treatment protocol to observe clinical outcomes in  $\geq 6$  mm pockets: a retrospective case series. *The International Journal of Periodontics and Restorative Dentistry* **36**: 189-197. <https://doi.org/10.11607/prd.2600>.

Roncati, M., Lucchese, A., & Carinci, F. (2013). Nonsurgical treatment of peri-implantitis with the adjunctive use of an 810-nm diode laser. *Journal of the Indian Society of Periodontology* **17**: 812–815. <https://doi.org/10.4103/0972-124X.124531>

Salvi, G. E., Aglietta, M., Eick, S., Sculean, A., Lang, N. P., & Ramseier, C. A. (2012). Reversibility of experimental periimplant mucositis compared with experimental gingivitis in humans. *Clinical Oral Implants Research* **23**: 182–190. <https://doi.org/10.1111/j.1600-0501.2011.02220.x>

Salvi, G. E., & Lang, N. P. (2004). Diagnostic parameters for monitoring peri-implant conditions. *The International Journal of Oral & Maxillofacial Implants* **19**(Suppl): 116–127.

Salvi, G. E., & Zitzmann, N. U. (2014). The effects of anti-infective preventive measures on the occurrence of biologic implant complications and implant loss: a systematic review. *The International Journal of Oral & Maxillofacial Implants* **29**: 292–307. <https://doi.org/10.11607/jomi.2014suppl.g5.1>

Sanz, M., Chapple, I. L., & Working Group 4 of the VIII European Workshop on Periodontology. (2102). Clinical research on peri-implant diseases: consensus report of Working Group 4. *Journal of Clinical Periodontology* **39**(Suppl 12): 202-206. <https://doi.org/10.1111/j.1600-051X.2011.01837.x>

Schrott, A. R., Jimenez, M., Hwang, J. W., Fiorellini, J., & Weber, H. P. (2009). Five-year evaluation of the influence of keratinized mucosa on peri-implant soft-tissue health and stability around implants supporting full-arch mandibular fixed prostheses. *Clinical Oral Implants Research* **20**: 1170–1177. <https://doi.org/10.1111/j.1600-0501.2009.01795.x>

Schwarz, F., Becker, K., & Sager, M. (2015). Efficacy of professionally-administered plaque removal with or without adjunctive measures for the treatment of peri-implant mucositis. A systematic review

and meta-analysis. *Journal of Clinical Periodontology* **42**(Suppl 16): 202–213. <https://doi.org/10.1111/jcpe.12349>.

Schwarz, F., John, G., Hegewald, A., & Becker, J. (2015). Non-surgical treatment of peri-implant mucositis and peri-implantitis at zirconia implants: a prospective case series. *Journal of Clinical Periodontology* **42**: 783–788. <https://doi.org/10.1111/jcpe.12439>

Sgolastra, F., Petrucci, A., Severino, M., Gatto, R., & Monaco, A. (2015). Periodontitis, implant loss and peri-implantitis. A meta-analysis. *Clinical Oral Implants Research* **26**: e8–e16. <https://doi.org/10.1111/clr.12319>

Slot, D. E., Jorritsma, K. H., Cobb, C. M., & Van der Weijden, F. A. (2014). The effect of the thermal diode laser (wavelength 808–980 nm) in non-surgical periodontal therapy: a systematic review and meta-analysis. *Journal of Clinical Periodontology* **41**: 681–692. <https://doi.org/10.1111/jcpe.12233>

Stubinger, S., Etter, C., Miskiewicz, M., Homann, F., Saldamli, B., Wieland, M., & Sader, R. (2010). Surface alterations of polished and sandblasted and acid-etched titanium implants after Er:YAG, carbon dioxide, and diode laser irradiation. *International Journal of Oral and Maxillofacial Implants* **25**; 104–111.

Suárez-López del Amo, F., Yu, S. H., & Wang, H. L. (2016). Non-surgical therapy for peri-implant diseases: a systematic review. *Journal of Oral and Maxillofacial Research* **7**: 1–14. <https://doi.org/10.5037/jomr.2016.7313>

Thöne-Mühling, M., Swierkot, K., Nonnenmacher, C., Mutters, R., Flores-de-Jacoby, L., & Mengel, R. (2010). Comparison of two full-mouth approaches in the treatment of peri-implant mucositis: A pilot study. *Clinical Oral Implants Research* **21**: 504–512. <https://doi.org/10.1111/j.1600-0501.2009.01861.x>

Tonetti, M. S., Chapple, I. L., Jepsen, S., & Sanz, M. (2015). Primary and secondary prevention of periodontal and peri-implant diseases introduction to, and objectives of the consensus from the 11(th) European Workshop on Periodontology. *Journal of Clinical Periodontology* **42**(Suppl 16): 1–4. <https://doi.org/10.1111/jcpe.12382>

Ungvari, K., Pelsoczi, I. K., Kormos, B., Oszko, A., Rakonczay, Z., Kemeny, L., Radnai, M., Nagy, K., Fazekas, A., & Turzo, K. (2010). Effects on titanium implant surfaces of chemical agents used for the

treatment of peri-implantitis. *Journal of Biomedical Mater Res B Applied Biomaterials* **94**: 222–229.  
<https://doi.org/10.1002/jbm.b.31644>

Zeza, B., Farina, R., Pilloni, A., & Mongardini, C. (2017). Clinical outcomes of experimental gingivitis and peri-implant mucositis treatment with professionally administered plaque removal and photodynamic therapy. *International Journal of Dental Hygiene* <https://doi.org/10.1111/idh.12302>

Zeza, B., & Pilloni, A. (2012). Peri-implant mucositis treatments in humans: A systematic review. *Annals Stomatologica (Roma)* **3**: 83–89.

Zigdon, H., & Machtei, E. E. (2008). The dimensions of keratinized mucosa around implants affect clinical and immunological parameters. *Clinical Oral Implants Research* **19**: 387–392.  
<https://doi.org/10.1111/j.1600-0501.2007.01492.x>

Zitzmann, N. U., Abrahamsson, L., Berglundh, T., & Lindhe, J. (2002). Soft tissue reaction to plaque formation at implant abutments with different surface topography. An experimental study in dogs. *Journal of Clinical Periodontology* **29**: 456–461. <https://doi.org/10.1034/j.1600-051X.2002.290511.x>

**Table 1. Baseline characteristics of patients**

Variables	Test Group (n=110)	Control Group (n=110)	P-value
Age (mean ± SD, years)	58.1 ± 10.1	56.8 ± 10.2	0.332 <sup>a</sup>
Males/females (n)	32/78	39/71	0.313 <sup>b</sup>
Light smokers (n)	14/96	20/90	0.263 <sup>b</sup>
Incisors/Canines/Premolars/Molars (n)	8/6/52/44	12/9/42/47	0.739 <sup>b</sup>
History of treated periodontitis [n (%)]	54 (49)	45 (41)	0.223 <sup>b</sup>
Time of implant function (mean ± SD, years)	6.8 ± 3.6	7.4 ± 4.4	0.258 <sup>a</sup>

SD standard deviation

<sup>a</sup>Unpaired *t*-test

<sup>b</sup>Chi-square test

**Table 2. Changes of FMPS and FMBS (mean ± SD) at baseline and 3 months in both groups**

Parameters	Group	Baseline	3 months	Δ <sub>0-3months</sub>
FMPS (%)	Test	17.8 ± 3.7	16.9 ± 4.1	0.9 ± 4.4 <sup>b</sup>
	Control	18.9 ± 4.3	16.4 ± 3.8	2.5 ± 4.8 <sup>b</sup>
<i>Difference between groups</i>		NS <sup>a</sup>	NS <sup>a</sup>	
FMBS (%)	Test	15.9 ± 4.8	15.2 ± 4.6	0.7 ± 5.3
	Control	16.8 ± 4.1	16.0 ± 5.3	0.8 ± 6.1
<i>Difference between groups</i>		NS <sup>a</sup>	NS <sup>a</sup>	

FMPS Full-Mouth Plaque Score, FMBS Full-Mouth Bleeding Score, SD standard deviation.

NS = difference between groups is not statistically significant (P >0.05)

<sup>a</sup>Unpaired *t*-test

<sup>b</sup>P <0.01, *p* values represent changes between two time points (paired *t*-test)

**Table 3. Changes in clinical parameters (mean  $\pm$  SD, and median) over the 3-month experimental period in both groups**

Parameters	Group	Baseline	1 month	$\Delta_{0-1\text{ month}}$	3 months	$\Delta_{0-3\text{ months}}$			
<b>PI Implant (%)</b>	<b>Test</b>	34.4 $\pm$ 28.8 <sup>a</sup>	33.3	14.9 $\pm$ 17.8 <sup>b</sup>	16.7	19.5 $\pm$ 27.4	11.2 $\pm$ 18.8 <sup>b</sup>	0.0	23.2 $\pm$ 17.8
	<b>Control</b>	30.6 $\pm$ 28.1 <sup>a</sup>	25.0	16.6 $\pm$ 17.2 <sup>b</sup>	16.7	14.0 $\pm$ 27.2	12.6 $\pm$ 16.3 <sup>b</sup>	0.0	17.9 $\pm$ 27.5
<i>Difference between groups</i>		NS <sup>c</sup>		NS <sup>d</sup>		NS <sup>d</sup>	NS <sup>d</sup>		NS <sup>d</sup>
<b>BoP Implant (%)</b>	<b>Test</b>	48.3 $\pm$ 26.9 <sup>a</sup>	41.7	19.1 $\pm$ 20.5 <sup>b</sup>	16.7	29.2 $\pm$ 28.8	23.2 $\pm$ 23.5 <sup>b</sup>	16.7	25.1 $\pm$ 29.2
	<b>Control</b>	46.2 $\pm$ 25.6 <sup>a</sup>	50.0	26.1 $\pm$ 26.4 <sup>b</sup>	16.7	20.1 $\pm$ 26.8	26.8 $\pm$ 23.0 <sup>b</sup>	33.3	19.4 $\pm$ 26.7
<i>Difference between groups</i>		NS <sup>c</sup>		0.01 <sup>d</sup>		0.02 <sup>d</sup>	NS <sup>d</sup>		NS <sup>d</sup>
<b>PD Implant (mm)</b>	<b>Test</b>	3.5 $\pm$ 0.7 <sup>a</sup>	3.3	3.0 $\pm$ 0.5 <sup>b</sup>	3.3	0.5 $\pm$ 0.6	2.9 $\pm$ 0.6 <sup>b</sup>	2.8	0.6 $\pm$ 0.8 <sup>c</sup>
	<b>Control</b>	3.4 $\pm$ 0.9 <sup>b</sup>	3.3	2.9 $\pm$ 0.8 <sup>b</sup>	2.9	0.5 $\pm$ 0.7	3.0 $\pm$ 0.7 <sup>b</sup>	3.0	0.4 $\pm$ 0.7 <sup>c</sup>
<i>Difference between groups</i>		NS <sup>c</sup>		NS <sup>d</sup>		NS <sup>d</sup>	NS <sup>d</sup>		NS <sup>d</sup>

*SD* Standard deviation, *PI* Presence of plaque, *BoP* Presence of bleeding on probing, *PD* Probing depth.

*NS* = difference between groups is not statistically significant ( $P > 0.05$ )

<sup>a</sup> $P < 0.001$ ,  $p$  values represent changes among the three time points (ANOVA or Friedman's test)

<sup>b</sup> $P \leq 0.001$ ,  $p$  values represent longitudinal changes from baseline (Newman-Keuls test or Dunn test)

<sup>c</sup>Mann-Whitney  $U$ -test or unpaired  $t$ -test

<sup>d</sup>Bonferroni-corrected Mann-Whitney  $U$ -test or Bonferroni-corrected  $t$ -test



**Table 4. Changes in clinical parameters (mean  $\pm$  SD) over the 3-month experimental period by smoking habits**

	<b>BoP Implant (%)</b>					<b>PD Implant (mm)</b>				
	<b>Baseline</b>	<b>1 month</b>	$\Delta_{0-1}$ <b>month</b>	<b>3 months</b>	$\Delta_{0-3}$ <b>months</b>	<b>Baseline</b>	<b>1 month</b>	$\Delta_{0-1}$ <b>month</b>	<b>3 months</b>	$\Delta_{0-3}$ <b>months</b>
<b>TEST GROUP</b>										
<i>Non-smokers</i>										
<i>(n=96)</i>	48.1 $\pm$ 27.0 <sup>a</sup>	20.7 $\pm$ 19.2	27.4 $\pm$ 27.7	22.5 $\pm$ 21.6	25.6 $\pm$ 29.7	3.5 $\pm$ 0.7 <sup>a</sup>	3.0 $\pm$ 0.5	0.5 $\pm$ 0.6	2.9 $\pm$ 0.6	0.6 $\pm$ 0.8
<i>Smokers</i>										
<i>(n=14)</i>	50.0 $\pm$ 27.7 <sup>a</sup>	25.1 $\pm$ 28.3	24.9 $\pm$ 41.2	27.4 $\pm$ 33.7	22.6 $\pm$ 25.0	3.6 $\pm$ 0.7 <sup>a</sup>	3.0 $\pm$ 0.6	0.6 $\pm$ 0.5	2.8 $\pm$ 0.5	0.8 $\pm$ 0.9
<b>CONTROL GROUP</b>										
<i>Non-smokers</i>										
<i>(n=90)</i>	46.7 $\pm$ 24.4 <sup>a</sup>	25.2 $\pm$ 25.5	21.5 $\pm$ 27.8	27.4 $\pm$ 24.1	19.2 $\pm$ 30.0	3.4 $\pm$ 0.8 <sup>a</sup>	3.0 $\pm$ 0.7	0.4 $\pm$ 0.7	3.0 $\pm$ 0.7	0.4 $\pm$ 0.6
<i>Smokers</i>										
<i>(n=20)</i>	44.2 $\pm$ 31.2 <sup>a</sup>	26.0 $\pm$ 30.4	14.2 $\pm$ 36.1	24.2 $\pm$ 17.5 <sup>a</sup>	20.0 $\pm$ 28.9	3.5 $\pm$ 1.2 <sup>a</sup>	2.8 $\pm$ 1.1	0.7 $\pm$ 0.7	3.0 $\pm$ 0.7	0.5 $\pm$ 1.1
<i>Difference between groups</i>										
	NS <sup>b</sup>	NS <sup>b</sup>	NS <sup>b</sup>	NS <sup>b</sup>	NS <sup>b</sup>	NS <sup>b</sup>	NS <sup>b</sup>	NS <sup>b</sup>	NS <sup>b</sup>	NS <sup>b</sup>

*SD* Standard deviation, *BoP* Presence of bleeding on probing, *PD* Probing depth.

*NS* = difference between groups is not statistically significant ( $P > 0.05$ )

<sup>a</sup>  $P < 0.001$ , *p* values represent changes among the three time points (ANOVA or Friedman's test)

<sup>b</sup> Anova or Kruskal-Wallis test

**Table 5. Changes in clinical parameters (mean  $\pm$  SD) over the 3-month experimental period by previous history of periodontitis**

	BoP Implant (%)					PD Implant (mm)				
	Baseline	1 month	$\Delta_{0-1}$ months	3 months	$\Delta_{0-3}$ months	Baseline	1 month	$\Delta_{0-1}$ months	3 months	$\Delta_{0-3}$ months
<b>TEST GROUP</b>										
<i>No periodontitis (n=56)</i>	43.4 $\pm$ 24.6 <sup>a</sup>	17.0 $\pm$ 17.8	26.4 $\pm$ 26.9	23.3 $\pm$ 24.6	20.1 $\pm$ 27.9	3.4 $\pm$ 0.7 <sup>a</sup>	2.9 $\pm$ 0.5	0.5 $\pm$ 0.6	2.9 $\pm$ 0.6	0.5 $\pm$ 0.8
<i>Periodontitis (n=54)</i>	53.9 $\pm$ 28.7 <sup>a</sup>	21.5 $\pm$ 23.2	32.4 $\pm$ 32.2	23.1 $\pm$ 22.2	30.8 $\pm$ 29.6	3.6 $\pm$ 0.8 <sup>a</sup>	3.0 $\pm$ 0.5	0.6 $\pm$ 0.6	3.0 $\pm$ 0.7	0.6 $\pm$ 0.9
<b>CONTROL GROUP</b>										
<i>No periodontitis (n=65)</i>	42.3 $\pm$ 21.7 <sup>a</sup>	22.1 $\pm$ 20.2	20.3 $\pm$ 25.9	25.1 $\pm$ 23.0	17.2 $\pm$ 30.6	3.3 $\pm$ 0.9 <sup>a</sup>	2.9 $\pm$ 0.7	0.4 $\pm$ 0.7	2.7 $\pm$ 0.5	0.5 $\pm$ 0.8
<i>Periodontitis (n=45)</i>	51.9 $\pm$ 29.8 <sup>a</sup>	31.9 $\pm$ 32.7	20.0 $\pm$ 28.3	29.3 $\pm$ 29.1 <sup>a</sup>	22.6 $\pm$ 28.2	3.5 $\pm$ 0.7 <sup>a</sup>	3.1 $\pm$ 0.8	0.4 $\pm$ 0.6	3.2 $\pm$ 0.8	0.3 $\pm$ 0.8
<i>Difference between groups</i>	NS <sup>b</sup>	NS <sup>b</sup>	NS <sup>b</sup>	NS <sup>b</sup>	NS <sup>b</sup>	NS <sup>b</sup>	NS <sup>b</sup>	NS <sup>b</sup>	0.008 <sup>b</sup>	NS <sup>b</sup>

SD Standard deviation, BoP Presence of bleeding on probing, PD Probing depth.

NS = difference between groups is not statistically significant (P > 0.05)

<sup>a</sup> P < 0.001, p values represent changes among the three time points (ANOVA or Friedman's test)

<sup>b</sup>Anova or Kruskal-Wallis test

**Table 6. Frequency distribution of peri-implant mucositis at baseline and disease resolution (absence of BoP) at 3 months.**

		Test group (n = 110)		Control group (n = 110)	
		Site [n (%)]	Implant [n (%)]	Site [n (%)]	Implant [n (%)]
baseline	Peri-implant mucositis	319 (53.2 %)	110 (100 %)	305 (50.8 %)	110 (100 %)
3 months	Disease resolution	198 (62.1 %)	38 (34.5 %)	166 (54.4 %)	34 (30.9 %)

## Figure legends

**Figure 1.** Non-surgical treatment procedures at peri-implant mucositis sites treated with DL application and mechanical debridement (test group). (A-D) Clinical appearance of peri-implant mucositis with BoP. (E) Radiographic exam showing the absence of bone loss. (F) Irrigation with 3% hydrogen peroxide solution. (G) DL irradiation using a 300- $\mu$ m optical fiber for 30 s. (H-I) Mechanical debridement using both ultrasonic and manual instruments. (L) Biostimulation for 60 s at 0.7 W in continuous wave. The biostimulation was repeated the following day. (M) Resolution of inflammation and enhanced soft tissue firmness after 3-month observation time.

**Figure 2.** Non-surgical treatment procedures at peri-implant mucositis sites treated with mechanical debridement alone (control group). (A-B) Clinical and radiographic appearance of peri-implant mucositis. (C-F) Reduction of inflammation at 3-month follow-up.

## Supporting information

**Figure S1.** Flow diagram according to CONSORT 2010.

**Appendix 1.** CONSORT 2010 checklist for a randomized trial.

**Table S1.** Baseline characteristics of patients stratified by operator.

**Table S2.** Changes in clinical parameters (mean  $\pm$  SD, median) over the 3-month experimental period stratified by operator.

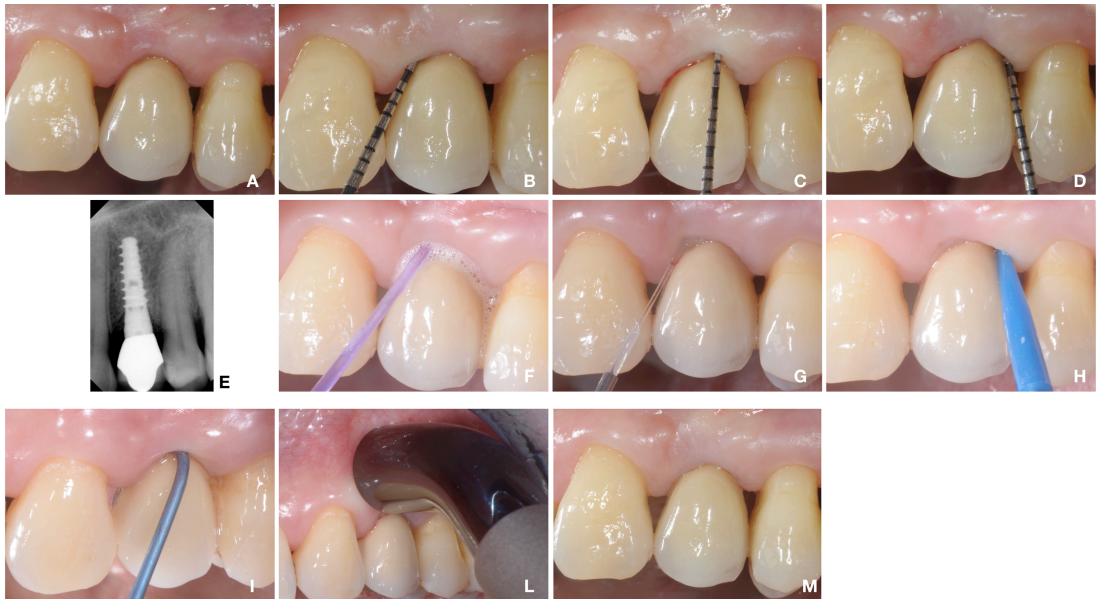


Figure 1

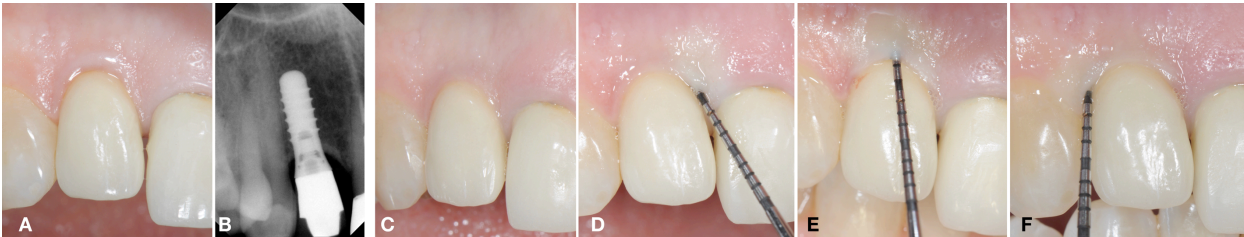


Figure 2