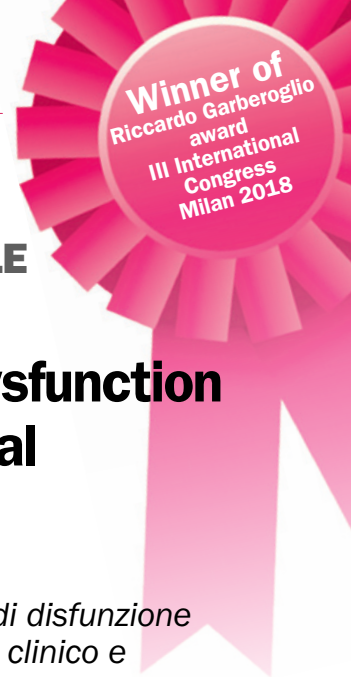



ORIGINAL ARTICLE / ARTICOLO ORIGINALE

Variation of vascular and blood indicators of early endothelial dysfunction after root canal therapy: A clinical and biomolecular study

KEYWORDS

Chronic inflammation, endothelial dysfunction, endothelial activation, apical periodontitis, root canal treatment.

PAROLE CHIAVE

Infiammazione cronica, disfunzione endoteliale, attivazione endoteliale, parodontite apicale, trattamento endodontico.

**Beatrice Giuggia*¹,
Loredana Bergandi²,
Allegra Comba¹,
Mario Alovisi¹,
Giorgia Carpegna¹,
Nicola Scotti¹,
Damiano Pasqualini¹,
Elio Berutti¹.**

¹University of Turin, Department of Surgical Sciences, Dental School, Turin, Italy.

²University of Turin, Department of Oncology, Turin, Italy.

Received 2019, February 27

Accepted 2019, March 10

Variazione degli indicatori vascolari ed ematochimici di disfunzione endoteliale precoce dopo terapia endodontica: studio clinico e biomolecolare.

Abstract

Aim: Apical periodontitis (AP) is correlated with a higher risk of developing cardiovascular disease (CVD). No data currently exist to suggest that endothelial dysfunction (ED) improves after endodontic treatment in patients who have AP, despite a link between chronic AP and ED. This study was designed to investigate the expression of early ED markers in young adults with chronic AP, before and after root canal treatment.

Methodology: 41 subjects (20 controls and 21 patients with AP) were examined at enrolment. Patients with AP were also assessed 2 and 12 months after treatment. ENDO-PAT was used to measure endothelial flow reserve (EFR) and ELISAs were used to assess plasma levels of interleukin (IL)-1, IL-6 and TNF-alpha, vasoconstrictor ED endothelin (ET)-1, the circulating endothelial adhesion markers intercellular adhesion molecule-1 (ICAM)-1/CD54 and soluble vascular cellular adhesion molecule-1 (sVCAM)-1/CD106, soluble CD14, and the endothelial leukocyte adhesion molecule E-selectin.

Results: Baseline serum levels of ET-1, ICAM-1, E-selectin, IL-1, and sCD14 were elevated in patients with AP compared to the control group. There was no macroscopic evidence of reduced EFR in either group. Treatment for AP was associated with reduced inflammation and improved early ED, indicated by a lowering of IL-1, sCD14, ET-1, ICAM-1/CD54 and E-selectin levels to resemble those of control subjects.

Conclusions: Early vascular ED may be driven by AP but is reversible with effective endodontic treatment.

Obiettivi: La parodontite apicale (AP) è stata associata con un rischio aumentato di patologia cardiovascolare (CVDs). Non vi è evidenza che la disfunzione endoteliale (ED) migliori a seguito del trattamento endodontico in pazienti con AP, nonostante sia stata dimostrata un'associazione tra AP e ED. Questo studio è stato disegnato al fine di valutare l'espressione dei marker precoci di ED in giovani adulti con AP cronica, prima e dopo il trattamento endodontico.

Materiali e metodi: 41 soggetti (20 controlli e 21 pazienti con AP) sono stati analizzati all'arruolamento. I pazienti con AP sono stati anche valutati a 2 e 12 mesi post-trattamento. ENDO-PAT è stato utilizzato per misurare l'endothelial flow reserve (EFR) ed ELISA assays sono stati utilizzati per valutare i livelli plasmatici di interleuchina IL-1, IL-6 e TNF-alpha, il vasoconstrictore ED endothelina (ET)-1, i marker circolanti di adesione endoteliale, la molecola di adesione intercellulare (ICAM)-1/CD54 e la molecola solubile di adesione cellulare vascolare (sVCAM)-1/CD106, il CD14 solubile, e la molecola di adesione endoteliale leucocitaria (E-selectin).

Risultati: I livelli serici al baseline di ET-1, ICAM-1, E-selectin, IL-1, and sCD14 sono risultati aumentati al baseline nei pazienti con AP rispetto al gruppo di controllo. Non è stata individuata un'evidenza macroscopica di una riduzione di EFR in entrambi i gruppi. Il trattamento endodontico della AP è risultato associato a una riduzione dell'infiammazione e un miglioramento di ED precoce, abbassando i livelli plasmatici di IL-1, sCD14, ET-1, ICAM-1/CD54 e E-selectin a quelli dei soggetti del gruppo di controllo.

Conclusioni: La disfunzione vascolare endoteliale precoce può essere promossa da AP ed è reversibile con un trattamento endodontico efficace.

Corresponding author

Beatrice Giuggia
University of Turin Dental School | via Nizza 230 -10126 Turin - Italy | Tel. +39 340 3859810 | E-mail: beaggiuggia@gmail.com

Peer review under responsibility of Società Italiana di Endodonzia

10.32067/GIE.2019.33.01.07

Società Italiana di Endodonzia. Production and hosting by Ariesdue. This is an open access article under the CC BY-NC-ND license (<http://creativecommons.org/licenses/by-nc-nd/4.0/>).

Introduction

Cardiovascular disease (CVD) is becoming an increasing burden in the developing world due to an evolving profile of risk factors (1). Furthermore, it is the leading cause of morbidity and mortality worldwide (2, 3).

The endothelium acts as a modulator of vascular tone via the production of relaxing factors, such as vasodilator prostaglandins, nitric oxide (NO) and endothelium-dependent hyperpolarization factors, as well as contracting factors, including endothelin (ET)-1, the most potent endogenous vasoconstrictor (4-7). The expression of cell-surface adhesion molecules on the endothelium, in particular intercellular adhesion molecule-1 (ICAM-1), soluble vascular cellular adhesion molecule-1 (sVCAM-1), and endothelial leukocyte adhesion molecule (ELAM, also known as E-selectin), promotes the binding of circulating leukocytes to the endothelium (8) and drives endothelial cell activation. The development of CVD may be predicted by ED and endothelial cell activation.

Apical periodontitis (AP) occurs in 34-61% of adults aged 35-45 years old living in the developed world and this statistic rises with age (9). Inflammation associated with AP may enhance an individual's risk of developing CVD (10). For example, a correlation has been reported between the presence of lesions of endodontic origin (LEO) or pulpal inflammation and the risk of ischemic heart disease (11-14). There are similarities in the immune responses to AP and periodontal disease (15), including increased levels of serum soluble CD14 (sCD14) and C-reactive protein (CRP) that occurs as a response to lipopolysaccharide-induced activation of endothelial or epithelial cells that do not normally express membrane-bound CD14 (16). Both sCD14 and CRP facilitate systemic inflammation.

Elevated interleukin (IL)-2 and asymmetric dimethylarginine (ADMA), an endogenous inhibitor of nitric oxide synthase (NOS), have been reported

alongside poor NO availability in young adult males with AP and early signs of ED (17). Although early pre-clinical ED is likely to be reversible (18) via modifications in life style, recommended drug treatment and the reversal of cardiovascular risk factors (19), there are no data available to indicate that endothelial function is restored following endodontic treatment in patients with AP. The aim of this study was to investigate vascular and molecular markers of early ED before and after root canal treatment in patients with chronic AP.

Materials and Methods

Study population. This study was authorized by the Città della Salute e della Scienza Ethical Committee (ref. nr. 0009323; CS2/510). Every patient included in the study provided signed, written consent. This observational, case-controlled clinical trial was designed with a study power of 80%, for a sample of 19 paired subjects, assuming a 5% significance level.

Patients who had at least one chronic periradicular inflammatory LEO were enrolled into the LEO group. Subjects were below 35 years of age, of normal weight with no medical history of diabetes or systemic, oncologic, or immune system diseases, not taking current immunosuppressive or cortisone drug treatment and not undergoing dental treatment. Age-matched control subjects were recruited randomly from a medical database of the same area. Subjects underwent assessment for CVD prior to study initiation and any subjects with CVD were excluded.

Pulpal and periradicular status were determined using vitality thermal and electric pulp tests (Diagnostic Unit; Sybron, Orange, CA), palpation, and percussion. Complete periodontal charting was recorded. Intra-oral radiographs were used to assess the periradicular status of any cases of suspected AP using phosphor sensor imaging plates (20, 21). At all visits, standardized periapical radiographs were derived using



Rinn XCP (Rinn Corp, Elgin, IL) alignment system with customized silicone bite. Three clinical assistant professors analyzed the clinical and radiological data and made any diagnoses accordingly. Performance calibration was carried out to minimize any interexaminer variability. Examiner concordance was analyzed with the Fleiss k score ($k > 0.70$).

Endothelial function. Peripheral arterial tonometry (PAT) was utilized to measure endothelial flow reserve (EFR) at the distal extremity of the upper limbs. This method is not operator-dependent and provides a reproducible index of endothelial-dependent vasodilation. Finger biosensors measured any changes in vasal tone influenced by the endothelium using ENDO-PAT2000 (Itamar Medical, Caesarea, Israel). Modifications of vasal tone were produced by occlusion of the brachial artery for 5 minutes with a consequent hyperemic response. The opposite arm was used as a control.

Blood sample collection. Blood samples were collected at enrolment from all subjects, and also from the LEO patients at 2 and 12 months after apical treatment. Plasma was isolated by centrifugation at $2400 \times g$ for 15 minutes and frozen immediately at -80°C .

Biochemical analysis: enzyme-linked immunosorbent assay (ELISA). Plasma concentrations of IL-1, IL-6, tumor necrosis factor (TNF)- α , ET-1, ICAM-1/CD54, sVCAM-1/CD106, sCD14 and E-selectin were determined using ELISAs (R&D systems, Minneapolis, USA and Sigma Aldrich, Milan, Italy).

Endodontic treatment. Access cavity and endodontic pre-treatment were carried out to form a reservoir for irrigant solutions following the administration of local anesthesia and isolation of rubber dam. A size 10 stainless-steel K-File (Dentsply Maillefer, Baillagues, Switzerland) was used to carry out root canal scouting and a mechanical glide path was created using Proglider (Dentsply Maillefer, Baillagues, Switzerland). The endodontic motor (X-Smart, Dent-

sply Maillefer, Baillagues, Switzerland) was set at a 16:1 contra angle using the suggested settings (300 rpm on display, 5 Ncm), at working length (WL). Electronic WL was recorded with an apex locator (Diagnostic Unit, Sybron, Orange CA, USA) and checked three times during treatment. Initial WL was recorded with a size 10 stainless-steel K-File during canal scouting and initial glide path using an electronic apex locator. A second WL was recorded after glide path with a size 17 K-File using an electronic apex locator and periapical radiographs. Root canal shaping was carried out using ProTaper Next™ X1-X2 (Dentsply Maillefer, Baillagues, Switzerland) at WL. Definitive WL was checked with a size 17 K-File after X1 and shaping was accomplished with X2 at WL, with X-Smart motor set at the suggested settings. A size 10 K-File 0.5 mm beyond the apex was used to establish and confirm apical patency. Irrigation was performed with a syringe and 30 G endodontic needle using 5% NaOCl (Nicolor 5, OGNA, Muggiò, Italy) and 10% EDTA (Tubuliclean, OGNA, Muggiò, Italy), for a total of 20 ml each and root canals were subsequently dried with sterile paper points. Root canals were filled immediately following treatment using sealer (Pulp Canal Sealer EWT, Kerr Endodontics, Orange, CA, USA) and Thermafil technique (Dentsply Maillefer, Baillagues, Switzerland), according to the manufacturer's instructions. A temporary filling was used to seal the access cavity (IRM, Dentsply International Inc., Milford, DE USA) which was subsequently reconstructed. Biochemical analysis was carried out in the LEO group at 2 and 12-month timepoints post-root canal treatment and clinical-radiological re-evaluation was conducted 12 months post-treatment to assess the outcome of endodontic treatment (22). Patient outcomes were categorized as "healed", "healing" and "diseased" according to Friedman & Mor (23).

Statistical analysis. Continuous variables were reported as mean \pm standard

error of the mean (SEM). The Shapiro-Wilk test was used to assess normality and the Student's t-test was utilized to compare mean values. Statistical significance was set at $p=0.05$ (Stata Statistical Software, Release 15, Stata-Corp. 2017 College Station, TX: Stata-Corp LLC).

Results

Twenty healthy subjects (mean age 32.07 years \pm 5.28) were assessed at baseline and 23 LEO patients (mean age 33.05 years \pm 6.27) were assessed at baseline and at 2 and 12 months after treatment. Two LEO patients were lost to follow-up at 12 months and were excluded from the analysis. A favourable outcome was reported for 19 LEO patients 12 months after treatment (90.5%), with 13 classified as "healed" and 6 as "healing". Two remained classified as "diseased". There were no statistically significant differences in clinical parameters or markers of systemic inflammation between the groups at baseline, except for higher serum concentrations of IL-1 (Fig. 1A) and sCD14 (Fig. 1B) in the LEO group compared to the control group. Concentrations of IL-1 (Fig. 1A) and sCD14 (Fig. 1B) were significantly reduced at 2 and 12 months after treatment in the LEO patients. Post-treatment concentrations were comparable to those of the control group. Mean EFR, as a measure of endothelial reserve, was similar in the control and LEO groups at baseline and in the LEO group 2 and 12 months after treatment ($p>0.05$).

ET-1, ICAM-1/CD54 and E-selectin concentrations were all significantly higher in the LEO group at baseline compared to the control group (Fig. 1C, D, E respectively). In each case, concentrations had decreased significantly at 2 and 12 months after treatment. sVCAM-1 levels were comparable between the groups at baseline and did not change following treatment (Fig. 1F).

With the exception of two non-reponders, there was a positive trend for markers of ED to return to concentra-

tions comparable to those of healthy controls after root canal treatment in the LEO group.

Discussion

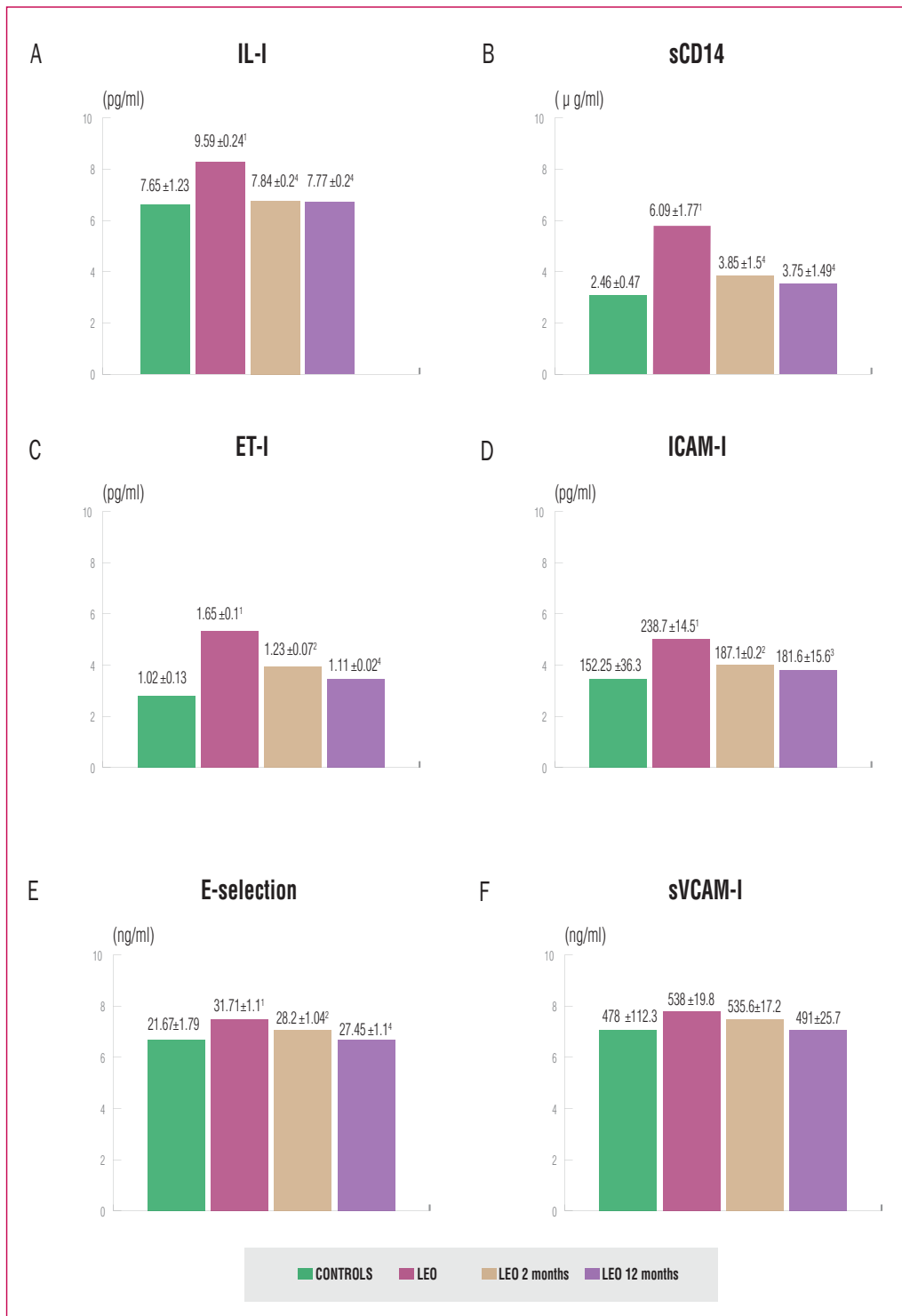
Endothelial function has attracted much attention in the clinical setting as a reliable marker of cardiovascular events in humans (24). Low NO levels are considered a predictor of ED (25), an early manifestation of cardiovascular atherosclerotic disease. An increase in NOS, an endogenous inhibitor (ADMA), and IL-2 concentrations have been reported in young adult males with AP and early signs of ED (measured by EFR at the level of the distal extremity in the upper limbs using PAT) (17). Our study did not fully support these results as no differences were observed in EFR between the LEO and healthy groups. Therefore, we can only conclude that any changes in biomarker expression observed in this study occurred before a detectable alteration in vasal tone.

In our study, the increased expression of the potent endogenous vasoconstrictor and proinflammatory peptide ET-1 (6), was higher in the LEO group than the healthy group at baseline, suggesting that apical lesions may lead to an increase of serum ET-1 that, in turn, could lead to ED. The subsequent post-treatment reduction in serum ET-1 was associated with the successful treatment of apical lesions.

The well-defined relationship between ED and endothelial cell activation has led to the use of E-selectin (26), sVCAM-1 and ICAM-1 (25) as markers of mortality and subclinical atherosclerosis (27). Indeed, the increased vasoconstriction, smooth muscle cell proliferation, platelet aggregation, leukocyte adhesion, low-density lipoprotein oxidation, and matrix metalloproteinase activation associated with ED and endothelial cell activation, can drive atherosclerosis and vascular disease (27). In this study, baseline levels of ICAM-1 and E-selectin were elevated in LEO patients compared to healthy controls, and these returned



Figure 1
 Descriptive statistics (mean and standard error of the mean) and inferential analysis of the tested variables; $p \leq 0.0001$ LEO group vs. healthy subjects at baseline¹; $p \leq 0.01$ ², $p < 0.001$ ³ and $p \leq 0.0001$ ⁴ LEO group 2 or 12 months after root canal treatment vs. LEO group at baseline
(A) Interleukin-1;
(B) soluble sCD14;
(C) Endothelin-1;
(D) intercellular adhesion molecule ICAM-1;
(E) E-selectin;
(F) soluble vascular cellular adhesion molecule sVCAM-1.
 LEO=lesion of endodontic origin.



to levels equivalent to those observed in healthy controls after root canal treatment. Traditional cardiovascular risk factors, such as hypercholesterolemia, smoking, and oxidative stress, and non-traditional risk factors, such as the

proinflammatory cytokines TNF-α and IL-6, are important mediators of endothelial cell activation. The LEO patients in this study had higher serum concentrations of IL-1 and sCD14 than the control patients, whereas the serum



concentrations of IL-6 and TNF- α did not differ between the groups.

Conclusions

These data suggest that AP is correlated with early vascular ED. This is evidenced by elevated serum concentrations of ET-1, ICAM-1 and E-selectin adhesion molecules and inflammatory IL-1 and sCD14, in the absence of any macroscopic evidence of decreased EFR. In each case, concentrations returned to those observed in healthy controls following treatment, suggest-

ing that treatment of AP ameliorates early ED.

Clinical Relevance

Apical periodontitis is correlated to an increase of early vascular endothelial dysfunction markers in the serum. Endodontic therapy returns these to the level observed in healthy subjects.

Conflict of Interest

The authors deny any conflicts of interest related to the study.

References

- 1 Bambrick P, Tan WS, Mulcahy R et al. Vascular risk assessment in older adults without a history of cardiovascular disease. *Exp Gerontol* 2016;79:37–45.
- 2 WHO | Global atlas on cardiovascular disease prevention and control. WHO. Available at: http://www.who.int/cardiovascular_diseases/publications/atlas_cvd/en/. Accessed August 11, 2018, n.d.
- 3 1990-2010 global cardiovascular disease atlas. - PubMed - NCBI. Available at: <https://www.ncbi.nlm.nih.gov/pubmed/25432106>. Accessed August 11, 2018, n.d.
- 4 Vanhoutte PM, Shimokawa H, Feletou M et al. Endothelial dysfunction and vascular disease - a 30th anniversary update. *Acta Physiol Oxf Engl* 2017;219:22–96.
- 5 Godo S, Shimokawa H. Endothelial Functions. *Arterioscler Thromb Vasc Biol* 2017;37:108–14.
- 6 Kolettis TM, Barton M, Langleben D et al. Endothelin in coronary artery disease and myocardial infarction. *Cardiol Rev* 2013;21:249–56.
- 7 Ghosh A, Gao L, Thakur A et al. Role of free fatty acids in endothelial dysfunction. *J Biomed Sci* 2017;24:50.
- 8 Best PJ, Lerman A. Endothelin in cardiovascular disease: from atherosclerosis to heart failure. *J Cardiovasc Pharmacol* 2000;35(4 Suppl 2):S61-63.
- 9 Cotti E, Dessì C, Piras A et al. Can a chronic dental infection be considered a cause of cardiovascular disease? A review of the literature. *Int J Cardiol* 2011;148:4–10.
- 10 Segura-Egea JJ, Martín-González J, Castellanos-Cosano L. Endodontic medicine: connections between apical periodontitis and systemic diseases. *Int Endod J* 2015;48:933–51.
- 11 Caplan DJ, Chasen JB, Krall EA et al. Lesions of endodontic origin and risk of coronary heart disease. *J Dent Res* 2006;85:996–1000.
- 12 Pasqualini D, Bergandi L, Palumbo L et al. Association among oral health, apical periodontitis, CD14 polymorphisms, and coronary heart disease in middle-aged adults. *J Endod* 2012;38:1570–7.
- 13 Joshipura KJ, Pitiphat W, Hung HC et al. Pulpal inflammation and incidence of coronary heart disease. *J Endod* 2006;32:99–103.
- 14 Caplan DJ, Pankow JS, Cai J et al. The relationship between self-reported history of endodontic therapy and coronary heart disease in the Atherosclerosis Risk in Communities Study. *J Am Dent Assoc* 1939 2009;140:1004–12.
- 15 Berlin-Broner Y, Febbraio M, Levin L. Association between apical periodontitis and cardiovascular diseases: a systematic review of the literature. *Int Endod J* 2017;50:847–59.
- 16 Hayashi J, Masaka T, Ishikawa I. Increased levels of soluble CD14 in sera of periodontitis patients. *Infect Immun* 1999;67:417–20.
- 17 Cotti E, Dessì C, Piras A et al. Association of endodontic infection with detection of an initial lesion to the cardiovascular system. *J Endod* 2011;37:1624–9.
- 18 Woo KS, Chook P, Yu CW et al. Effects of diet and exercise on obesity-related vascular dysfunction in children. *Circulation* 2004;109:1981–6.
- 19 Celemajer DS. Endothelial dysfunction: does it matter? Is it reversible? *J Am Coll Cardiol* 1997;30:325–33.
- 20 European Society of Endodontology. Quality guidelines for endodontic treatment: consensus report of the European Society of Endodontology. *Int Endod J* 2006;39:921–30.
- 21 AAE and AAOMR Joint Position Statement: Use of Cone Beam Computed Tomography in Endodontics 2015 Update. *J Endod* 2015;41:1393–6.
- 22 Orstavik D. Time-course and risk analyses of the development and healing of chronic apical periodontitis in man. *Int Endod J*. 1996;29:150-5. 24
- 23 Friedman S, Mor C. The success of endodontic therapy—healing and functionality. *J Calif Dent Assoc*. 2004 Jun;32(6):493-503.
- 24 Bruno RM, Gori T, Ghiadoni L. Endothelial function testing and cardiovascular disease: focus on peripheral arterial tonometry. *Vasc Health Risk Manag* 2014;10:577–84.
- 25 Dessein PH, Joffe BI, Singh S. Biomarkers of endothelial dysfunction, cardiovascular risk factors and atherosclerosis in rheumatoid arthritis. *Arthritis Res Ther* 2005;7:R634-643.
- 26 Hunt KJ, Baker NL, Cleary PA et al. Longitudinal Association Between Endothelial Dysfunction, Inflammation, and Clotting Biomarkers With Subclinical Atherosclerosis in Type 1 Diabetes: An Evaluation of the DCCT/EDIC Cohort. *Diabetes Care* 2015;38:1281–9.
- 27 Liao JK. Linking endothelial dysfunction with endothelial cell activation. *J Clin Invest* 2013;123:540–1.