

AperTO - Archivio Istituzionale Open Access dell'Università di Torino

Holmes tremor: a delayed complication after resection of brainstem cavernomas

This is the author's manuscript

Original Citation:

Availability:

This version is available <http://hdl.handle.net/2318/1886180> since 2025-02-04T11:05:31Z

Published version:

DOI:10.3171/2020.7.JNS201352

Terms of use:

Open Access

Anyone can freely access the full text of works made available as "Open Access". Works made available under a Creative Commons license can be used according to the terms and conditions of said license. Use of all other works requires consent of the right holder (author or publisher) if not exempted from copyright protection by the applicable law.

(Article begins on next page)

Holmes tremor: a delayed complication after resection of brainstem cavernomas

*Marco Cenzato, MD,1 Davide Colistra, MD,1 Giorgia Iacopino, MD, 2 Christian Raftopoulos, MD, PhD, 3 Ulrich Sure, MD, PhD, 4 Marcos Tatagiba, MD, PhD, 5 Robert F. Spetzler, MD, PhD,6 Alexander N. Konovalov, MD, PhD,7 Andriy Smolanka, MD, PhD, 8Volodymir Smolanka, MD, PhD, 8 Roberto Stefini, MD,9 Carlo Bortolotti, MD,10 Paolo Ferroli, MD,11Giampietro Pinna, MD,12 Angelo Franzini, MD,11 Philipp Dammann, MD, 4 Georgios Naros, MD, 5 Davide Boeris, MD, PhD,1 Paolo Mantovani, MD,10 Domenico Lizio, PhD,13 Mariangela Piano, MD,14 and Enrica Fava, MD, PhD1,15

1 Neurosurgery, Great Metropolitan Hospital Niguarda, Milan; 2 Neurosurgery, Department of Human Neurosciences, Sapienza University, Rome, Italy; 3 Department of Neurosurgery, Saint-Luc University Clinic, Catholic University of Louvain, Brussels, Belgium; 4 Department of Neurosurgery, University Hospital Essen, University of Duisburg-Essen; 5 Department of Neurosurgery, University Hospital Tübingen, Germany; 6 Neurosurgery, Barrow Neurological Institute, Phoenix, Arizona; 7 Neurosurgery, Burdenko Neurosurgical Institute, Moscow, Russia; 8 Neurosurgery, University Hospital Uzhhorod, Ukraine; 9 Department of Neurosurgery, Legnano Hospital, Milan; 10 Department of Neurologic Surgery, Bellaria Hospital, Institute of Neurological Sciences of Bologna; 11 Department of Neurosurgery, Carlo Besta Neurological Institute, Milan; 12 Neurosurgery Department, University Hospital Verona; Departments of 13 Medical Physics and 14 Neuroradiology, Great Metropolitan Hospital Niguarda, Milan; and 15 Department of Medical Biotechnologies and Translational Medicine, University of Milan, Italy

OBJECTIVE

In this paper, the authors aimed to illustrate how Holmes tremor (HT) can occur as a delayed complication after brainstem cavernoma resection despite strict adherence to the safe entry zones (SEZs).

METHODS

After operating on 2 patients with brainstem cavernoma at the Great Metropolitan Hospital Niguarda in Milan and noticing a similar pathological pattern postoperatively, the authors asked 10 different neurosurgery centers around the world to identify similar cases, and a total of 20 were gathered from among 1274 cases of brainstem cavernomas. They evaluated the

tremor, cavernoma location, surgical approach, and SEZ for every case. For the 2 cases at their center, they also performed electromyographic and accelerometric recordings of the tremor and evaluated the post-operative tractographic representation of the neuronal pathways involved in the tremorigenesis. After gathering data on all 1274 brainstem cavernomas, they performed a statistical analysis to determine if the location of the cavernoma is a potential predicting factor for the onset of HT.

RESULTS

From the analysis of all 20 cases with HT, it emerged that this highly debilitating tremor can occur as a delayed complication in patients whose postoperative clinical course has been excellent and in whom surgical access has strictly adhered to the SEZs. Three of the patients were subsequently effectively treated with deep brain stimulation (DBS), which resulted in complete or almost complete tremor regression. From the statistical analysis of all 1274 brainstem cavernomas, it was determined that a cavernoma location in the midbrain was significantly associated with the onset of HT ($p < 0.0005$).

CONCLUSIONS

Despite strict adherence to SEZs, the use of intraoperative neurophysiological monitoring, and the immediate success of a resective surgery, HT, a severe neurological disorder, can occur as a delayed complication after resection of brainstem cavernomas. A cavernoma location in the midbrain is a significant predictive factor for the onset of HT. Further anatomical and neurophysiological studies will be necessary to find clues to prevent this complication.

Keywords: Holmes tremor; cavernoma; brainstem; safe entry zone; vascular disorders

Cavernomas account for 5%–10% of all vascular malformations, 1–3 and brainstem cavernomas account for about 20% of all intracranial cavernous angiomas. 4 Surgery should be considered in selected patients with brainstem cavernomas, particularly in cases of a second symptomatic bleeding or in cases of a single debilitating bleed.⁵

Accurate knowledge of the main safe entry zones (SEZs) to the brainstem is fundamental to minimize surgical morbidity. A rare complication of surgery for brainstem cavernoma is the Holmes tremor (HT). In the medical literature, this syndrome is described in four case reports 6–9 and cited in two series. 10,11 HT is characterized by a resting, postural, and intentional tremor that occurs sometime after a damaging event. It is characterized by low-frequency muscle contractions (<5 Hz) 12 and is explained in the majority of cases by the interruption of the nigrostriatal, dentatothalamic, and/or rubroolivary contralateral bundles. 13 The most

effective treatment for HT is surgery, which entails either lesioning or deep brain stimulation (DBS) of the ventral intermediate nucleus (VIM) of the thalamus.¹⁴

Our current study focuses on a series of 20 patients out of 1274 cases that were operated on for brainstem cavernoma in 11 different neurosurgery centers all over the world in order to illustrate how HT can occur as a delayed complication after resective surgery despite strict adherence to the SEZs, the use of intraoperative neurophysiological monitoring, and the immediate clinical success of the surgery.

Methods

After identifying the delayed onset of HT in 2 patients operated on at the Great Metropolitan Hospital Niguarda in Milan, we discussed our findings during international clinical meetings, noting that this complication was also reported by colleagues with extensive experience in brainstem surgery. We then contacted 10 different neurosurgery centers, gathering a total of 20 similar cases.

The patient was assessed in the sitting position with the limbs fully supported against gravity (rest tremor) and in the upright position with the hands along the body (postural tremor). The intention tremor was assessed using the index-nose test.

For each patient, the following variables were recorded: sex, age, location of the cavernoma, preoperative symptoms, surgical approach, SEZ, immediate and postoperative symptoms, symptoms at follow-up, time of HT presentation, type of treatment for HT, outcome, and time of follow-up.

After gathering data on all 1274 brainstem cavernomas from all centers, we employed Fisher's exact test to determine if the location of the cavernoma (medulla, pons-medulla, pons, midbrain) is a potential predicting factor for the onset of HT. Statistical analysis was performed using the software Stata/SE 16.1 (StataCorp.).

In our illustrative cases 3 and 4, the clinical appearance of tremor was evaluated by measuring the electromyographic (EMG) and accelerometric characteristics of the tremor itself (in illustrative case 3, both before and after treatment with DBS). We also evaluated the postoperative tractographic representation of the neuronal pathways involved in the tremorigenesis.

Electromyography

EMG analysis of the most involved limb was performed in the resting, postural, and intention positions (in illustrative case 3, even after treatment with DBS). Surface adhesive electrodes were placed in pairs on the following muscles: biceps brachii, triceps brachii, flexor communis digitorum, and extensor radialis carpi. The frequency and average amplitude of the muscle jerks during the tremor were evaluated. The examination was performed at the same time (11:00 am) for all patients. 15 Patients were asked not to use drugs known to affect tremor, such as alcohol or caffeinated drinks, before the examination. 16

Accelerometry

We recorded the tremor by using an iPhone accelerometer (in illustrative case 3, before and after treatment with DBS), accessible through a free application (app) called VibSensor 2.0.0 (Now Instruments and Software Inc.). VibSensor was built to measure the frequency of seismographic activity on all three axes, one for each direction of space. 17 When testing the 2 patients operated on in Milan, we recorded the most involved (upper) limb in all positions. The phone was placed on the dorsal surface of the hand at the wrist level and was secured with a rubber band. The spectrum of signal strength in the different frequencies is displayed in the graph produced by the app.

MRI and Fiber Tracking

Patients underwent a 1.5-T magnetic field tomography (Achieva 1.5T, Philips) diagnostic MRI examination. Images with contrast in T1, T2, and diffusion tensor imaging were obtained. The processing for reconstruction of the white matter tracts of interest was performed using the Oxford Centre for Functional MRI of the Brain Software Library (FSL). 18 The nigrostriatal tract (NST) was reconstructed by selecting fibers that pass through two regions of interest (ROIs): the substantia nigra and the homolateral striatum (Fig. 1A and B). The dentatothalamic tract (DTT) was reconstructed by the selection of fibers passing through four ROIs: the dentate nucleus of the cerebellum beneath the floor of the fourth ventricle, 19 the superior cerebellar peduncle between the upper part of the pons and the cerebellum, 20 and the contralateral red nucleus 21 (Fig. 1C–E), in addition to the contralateral thalamus, the latter obtained by automatic segmentation of the FSL. The rubroolivary tract (ROT) was obtained by selecting fibers that pass through two ROIs: the red nucleus and the ipsilateral inferior olivary nucleus (Fig. 1F and G).

The maximum intensity (Max) value was measured from the reconstructions of all the fiber bundles. This value represents the maximum number of streamlines in the voxel that has the highest probability density to contain the reconstructed tract. This value, compared between the same bundles of different hemispheres, may be indicative of differences within the white matter due to, for example, an injured area.

Results

The mean age of the 20 patients with HT was 43.5 years (range 24–68 years). Ten patients were males and 10 were females. There were 15 cavernomas within the midbrain, 3 at the pontomedullary junction, and 2 within the superior cerebellar peduncle (Table 1).

The surgical approach was selected on a case-by-case basis depending on the anatomical location of the lesion. The following approaches were used for midbrain lesions: supracerebellar infratentorial (10 cases), pterional (1 ipsilateral and 1 contralateral to the lesion), subtemporal (2 cases), frontotemporoorbitozygomatic (FTOZ; 1 ipsilateral and 1 contralateral to the lesion), and transfrontal transchoroidal (1 case). A midline suboccipital telovelar approach was chosen for the 3 cavernomas at the pontomedullary junction (Table 1).

The SEZs used to access the midbrain were lateral mesencephalic (9 cases) or anterior mesencephalic (5 cases) or infracollicular (3 cases), while the subfacial triangle was chosen in all 3 pontomedullary lesions (Table 1).

The signs and symptoms of presentation were different, including diplopia in 13 patients, hemiparesis in 6, ataxia in 5, hemihypesthesia in 2, and dysmetria and dysarthria in 2. Three patients (cases 1, 2, and 11) underwent surgery because of a second symptomatic bleed, but on admission they had been asymptomatic. After surgery, 15 patients were clinically stable, 4 clinically worsened, and 1 neurologically improved.

HT developed between 3 days and 24 months after surgery, contralaterally to the site of the cavernoma in 18 cases and ipsilaterally in 2 cases. The tremor was associated with palatal tremor and inferior olive hypertrophic degeneration in 2 cases. HT spontaneously disappeared in 1 case and improved in 6 cases (1 spontaneously, 2 after medical treatment, and 3 after DBS), while it did not improve in 12 cases and worsened in 1 case. The follow-up was between 5 months and 7 years.

The total number of brainstem cavernomas operated on in all centers was 1274 (Table 2). One hundred thirty-three (10.4%) cavernomas were located in the medulla, 206 (16.2%) in the pons-medulla, 594 (46.6%) in the pons, and 341 (26.8%) in the midbrain. So, based on these data, 1.57% (20/1274) of patients developed HT after resection of brainstem cavernomas, 1.46% (3/206) of patients after resection of cavernomas of the pons-medulla, and 4.99% (17/341) of patients after resection of cavernomas of the midbrain. In the statistical analysis of all 1274 cases, a cavernoma location in the midbrain was significantly associated with the onset of HT ($p < 0.0005$; Supplemental Table).

Illustrative Cases

Case 3

A 50-year-old woman was admitted to our hospital for the onset of diplopia and left hemiparesis. Brain MRI showed a suspected hemorrhagic cavernoma within the right cerebral peduncle (Fig. 2A and B). The patient underwent resection of the cavernous malformation via an ipsilateral subtemporal approach through the lateral mesencephalic SEZ (Fig. 2C and D). Postoperative MRI showed total resection of the cavernoma (Fig. 2E and F). The patient was discharged 1 week after surgery with no adjunctive deficits in a good clinical condition.

One month later she developed a tremor, suspected to be an HT, on the left side and involving mainly the upper limb. The tremor included a resting and postural component and worsened on the index-nose test. The EMG and accelerometric recordings showed a tremor frequency of 3 Hz in the three positions (Fig. 3A, C, E, and G). Electro-myography showed a synchronous bursting of hand flexor and extensor muscles, with a higher burst amplitude of the flexors. Postoperative fiber tracking showed a reduced representation of the NST and ROT through the right red nucleus, homolateral to the lesion, and no representation of the right DTT. The data were confirmed by Max values. The tremor did not improve spontaneously or after levodopa treatment; thus, after 9 months, the patient underwent surgery for DBS of the VIM thalamic nucleus. After surgical treatment, the patient clinically improved, and the EMG and accelerometric (Fig. 3B, D, F, and H) recordings showed outstanding improvement in the tremor.

Case 4

A 64-year-old woman was admitted to our hospital for the onset of progressively worsening diplopia and un-steady gait. Brain MRI showed a suspected hemorrhagic cavernoma at the right pontomedullary junction, under the floor of the fourth ventricle (Fig. 4A–C). The patient underwent resection of the cavernous malformation via a midline suboccipital telovelar approach through the subfacial SEZ (Fig. 4D and E). The patient's neurological status was unchanged postoperatively.

Three months later, the patient developed a tremor, suspected to be an HT, in the left upper limb. The tremor had resting and postural components and appeared to be worse during the index-nose test. On EMG and accelerometric recordings, the tremor showed a frequency of around 1.5–2 Hz in the three assessment positions. Electromyography showed a synchronous bursting of hand flexor and extensor muscles, with a higher burst amplitude of the extensors. The postoperative fiber tracking showed a reduced representation of the ROT through the right

red nucleus, ipsilateral to the lesion, and surprisingly a reduced representation of the contralateral NST and DTT. The data were confirmed by Max values.

The patient did not respond to levodopa and is currently making a decision about DBS.

Discussion

Brainstem cavernomas represent a relatively rare vascular malformation that can lead to severe neurological symptoms by direct compression or following hemorrhage. Today, it is crucial that brainstem cavernomas are exclusively treated in highly specialized centers, with all the available new technologies. Strict adherence to the SEZs to the brainstem is also required to minimize surgical morbidity.

HT is one of many possible postsurgery complications. It is very unusual and is generally found quite some time after surgery. HT can be highly debilitating for the affected individuals. The syndrome is characterized by a resting, postural, and intentional tremor that ensues sometime after the damaging event with a low-frequency muscle contraction (< 5 Hz).¹² To date, it is generally accepted that HT occurs as a result of lesions in the brainstem/cerebellum and in the thalamus.¹³ According to anatomopathological²² and PET data,²³ both the nigrostriatal dopaminergic and dentatothalamic pathways must be damaged to generate a contralateral HT.¹³ A recent tractographic study has also shown a reduction in the NST and DTT from the injured mesencephalic side.⁷ Damage to the DTT due to disruption of afferent pathways (deafferentation) from the cerebellar dentate nucleus to the thalamus presumably leads to thalamic functional changes. In other words, this suggests that the approximately 4-Hz rhythmic discharges observed in the thalamus during functional neurosurgery, which correspond to the HT rhythm, contribute to the development of the tremor. So, the coagulation of thalamic neurons through VIM lesioning or, similarly, the functional changes obtained through VIM DBS represent two different techniques to control the tremor.

HT can also be caused by damage to the Guillain-Mollaret triangle. A recent paper has described a reduction of the fibers of the central tegmental tract on the side of the damaged brainstem, according to tractographic examination.²⁴

Review of the Literature and Analysis of Our Series

In the literature, authors have reported a case of HT due to the presence of a mesencephalon cavernoma, with a worsening of symptoms after surgery.²⁵ There are also 4 well-described cases of HT following the resection of brainstem cavernomas. Pahwa et al. described the case of a 45-year-old woman with a right mesencephalon cavernoma who, 3 months after partial excision, presented with a progressively increasing contralateral HT of the hand, which almost completely resolved after thalamic DBS.⁶ Seidel et al. reported the case of a 16-year-old girl

with a left midbrain cavernoma who, 9 months after surgery, had a highly debilitating contralateral HT, which almost completely resolved after 3 months of combined pramipexole and levodopa treatment. 7 Aydin et al. described the case of a 30-year-old woman with a right pontomesencephalic cavernoma who, 6 months after an excision performed via a telovelar suboccipital approach, presented with an HT in the contralateral upper limb, which almost completely recovered after DBS of the VIM nucleus of the thalamus and the inner globus pallidus. 8 Delaunois et al. reported the case of a 29-year-old woman with a right mesencephalon cavernoma who, 10 days after a homolateral transsylvian transuncal surgery performed via the anterior mesencephalic SEZ, developed an HT in the contralateral upper limb, which disappeared after 1 year of treatment with levodopa. 9 This case is included as case 6 in our series (Table 1).

We compared the literature to our analysis of the 20 cases of HT, finding that HT after the resection of brainstem cavernomas is a rare morbidity: 1.57% (20/1274) of all patients in our series developed HT. In the statistical analysis of 1274 cases, a cavernoma location in the mid-brain was significantly associated with the onset of HT ($p < 0.0005$). This strong association can be easily explained by the fact that the majority of anatomical structures involved in the genesis of HT are densely packed in the mid-brain (Fig. 5).

In our series HT occurred equally in both sexes, whereas in the largest study of HT ever published (29 cases), the authors found a slight female predominance. 14 The rest of the literature reports a male prevalence. In the 4 cases of HT occurring after brainstem cavernoma surgery that have been reported so far, the patients were all women. 6–9 The average age in our study was 43.5 years (range 24–68 years), while in those other 4 cases the average age was 30 years (range 16–45 years). In the literature on HT, the age at clinical presentation has varied. As described above, the onset delay has ranged between 1 and 24 months after surgery; in our series the delay was between 3 days and 24 months, while in those previously mentioned 4 cases the time span ranged from 10 days to 9 months. Also in line with what has been reported in the literature, there was a clear prevalence of cavernomas at the mesencephalic level (15 cases) versus the pontomedullary level (3 cases) in our series. In the previously mentioned 4 cases of HT following brainstem cavernoma resection, the localization was exclusively mesencephalic. In only 2 of our cases was the cavernoma located in the superior cerebellar peduncle, causing a homolateral HT, probably as a result of damage to the dentate-rubral fibers and the ascending arm of the dentate-olivary fibers before the decussation. In the literature, there are very few cases in which the tremor homolateral to the lesion of the superior cerebellar peduncle is described as “intentional” 26 or “reminiscent of moderate essential tremor.” 27,28

The location and characteristics of the cavernoma, in particular the outcrop area or the area closest to the ependymal surface, determine the choice of the SEZ. Among the 20 cases we examined, the infracollicular SEZ—with an infratentorial supracerebellar approach—was chosen in all 3 cases in which the cavernoma had the point closest to the surface located

near the quadrigeminal plate. When this point was located laterally with respect to the midbrain, the lateral mesencephalic SEZ was chosen in all 9 cases, via the supracerebellar infratentorial approach in 7 cases and the subtemporal approach in 2 cases. When the point closest to the surface was anterior to the mesencephalon, all 5 cases were operated on via the anterior mesencephalic SEZ, using the transsylvian pterional approach (2 cases, 1 ipsilateral and 1 contralateral), FTOZ approach (2 cases, 1 ipsilateral and 1 contralateral), or transfrontal transchoroidal approach (1 case). When the cavernoma emerged near the floor of the fourth ventricle (3 cases), the subfacial SEZ was chosen with a telovelar midline suboccipital approach. The approach was specified in only 2 of the 4 cases of HT following brainstem cavernoma resection in the literature: the pterional transsylvian approach with the anterior mesencephalic SEZ in the case published by Delaunois et al., in which the cavernoma reached the anterior surface of the midbrain, and the telovelar suboccipital approach in the case published by Aydin et al., in which the cavernoma reached the pontine surface of the floor of the fourth ventricle. 8,9

Overall, the delayed onset of the HT occurred with all the SEZs, regardless of the surgeon.

In line with the literature, the onset symptoms of cavernomas varied. 14 It is important to note that 15 of the 20 patients remained stable after surgery and 1 even improved, while in 4 cases there were additional neurological deficits. In 2 cases, after some time from the acute event, an inferior olive hypertrophic degeneration with palatal tremor was associated with the HT, a rare but well-reported event in the literature. 22,29

DBS proved to be the most effective treatment in our study, in line with findings in the literature.

Analysis of the Illustrative Cases

In case 3 the tremor was predominant in the flexor muscles; in case 4 it was predominant in the extensors. The frequency of the tremor was different, settling at around 3 Hz in case 3 and at 1.5–2 Hz in case 4. Tractographic data were different in the 2 cases as well: in case 3 the NST, DTT, and ROT were less represented on the lesion side (mesencephalic), but in case 4 only the ROT was less represented on the lesion side (pontomedullary) and the NST and DTT were reduced on the opposite side. It is possible that these data, especially the tractographic data, reflect the different lesion sites and therefore the different pathways of the fibers involved in the damage. In fact, in the HT with the mesencephalic lesion the studied bundles would all seem to be involved homolaterally, while in the HT with the pontomedullary lesion only the ROT would seem to be involved homolaterally. Moreover, the fact that the fiber tracts theoretically responsible for tremorigenesis are reduced on the lesion side, specifically those passing through the SEZ, is further proof that the current SEZs to the brainstem are insufficient to prevent the delayed onset of HT. Thus, in case 3, in which the lateral

mesencephalic SEZ was used, the affected pathways of the NST, DTT, and ROT at the level of the cerebral peduncle run close to this SEZ (Fig. 5).

In case 4, in which the subfacial SEZ was used, the affected tract was the ROT within the central tegmental tract, which at the level of the floor of the fourth ventricle runs just below this SEZ (Fig. 6).

In case 3, the treatment with DBS reduced the amplitude but not the frequency of the tremor.

The synchronous pattern of the tremor observed in the 2 illustrative cases contrasts with the definition of the classic HT as an alternating-pattern tremor. 16 According to Milanov, 16 HT is present even at rest and has the lowest frequency (less than 4 Hz) but an alternating pattern of EMG bursting. The tremors observed in our illustrative cases have mixed features, being present at rest and showing a low frequency (as in HT) but a synchronous pattern. Myorhythmia, as described by Baizabal-Carvallo et al., 30 shares some of the features of the tremors observed in our illustrative cases. The pattern is reported to be alternating or synchronous, with one agonist muscle contracting more intensely than the antagonist, resulting in oscillatory movement.

Surgical Tips and Other Important Considerations

From the results of this study, we can establish that a cavernoma location in the midbrain is a significant predictive factor for the onset of HT, and we can hypothesize which areas, during the resection, are most at risk for the onset of HT.

In cases of mesencephalic lesions in the area of the tegmentum, consider the following. In the anterior mesencephalic surgical SEZ, which is directed through the cerebral peduncle between the corticospinal and corticobulbar tracts laterally and the exit point of the oculomotor nerve medially, care should be taken in the deepest part of the working space to avoid the red nucleus with the NST, DTT, and ROT. In the lateral mesencephalic SEZ, which is located between the medial lemniscus posteriorly and the substantia nigra anterolaterally, care should be taken to avoid the substantia nigra and, at an average of 3.4 mm deep to the surface of the midbrain, 31 the red nucleus with the NST, DTT, and ROT. In the infracollicular SEZ, which is located between the trochlear nerve inferiorly and the inferior margin of the inferior colliculus superiorly, care should be taken as the incision deepens from dorsal to ventral to avoid the ROT within the central tegmental tract and the DTT within the decussation of the superior cerebellar peduncles.

In the case of lesions at the pontomedullary junction, near the floor of the fourth ventricle, if the surgeon chooses the subfacial SEZ, care should be taken to avoid the ROT within the central tegmental tract, which runs deep inside the subfacial triangle.

This study represents the first series of postsurgical HT cases reported in the literature, as well as the first series on HT after the resection of brainstem cavernomas. Its major limitation is its inclusion of retrospective cases. Our data demonstrate that the HT complication is more than just episodic. The sample was collected from among patients operated on by neurosurgeons from 11 different centers, all of whom had similar experiences in surgery for brainstem cavernomas. Unfortunately, at the moment there is no evidence that intraoperative neurophysiological monitoring can help in preventing this complication, but in the present study we could link the surgical SEZ to the anatomical structure involved in HT.

Conclusions

Brainstem cavernomas are a relatively rare vascular pathology. Surgery, although complex and accompanied by a high risk of serious complications, should be advised as the treatment of choice in selected cases. Surgery should be performed using SEZs to the brainstem. HT is one of the possible, albeit rare, complications of this type of surgery and is in most cases secondary to damage to the nigrostriatal, dentatothalamic, and rubroolivary pathways.

From our study it has emerged that, despite strict adherence to SEZs, the use of intraoperative neurophysiological monitoring, and the immediate success of the surgery, HT can occur as a delayed complication following resection of brainstem cavernoma. A cavernoma location in the mid-brain is a significant predictive factor for the onset of HT. We listed the anatomical pathways involved in the genesis of this highly debilitating complication, but further anatomical and neurophysiological studies will be necessary to find a means of prevention.

Acknowledgments

We thank the illustrator, Lorenzo Di Santo, for his special contribution to this article.

Disclosures

The authors report no conflict of interest concerning the materials or methods used in this study or the findings specified in this paper.

Author Contributions

Conception and design: Colistra, Cenzato. Acquisition of data: Colistra, Raftopoulos, Sure, Tatagiba, Spetzler, Konovalov, A Smolanka, V Smolanka, Stefini, Bortolotti, Ferrolì, Pinna, Franzini, Dammann, Naros, Boeris, Mantovani, Lizio, Piano, Fava. Analysis and interpretation of data: Colistra, Iacopino, Lizio, Fava. Drafting the article: Colistra, Iacopino, Fava. Critically revising the article: Cenzato, Raftopoulos, Sure, Tatagiba, Spetzler, Konovalov, A Smolanka, V

Smolanka, Fava. Reviewed submitted version of manuscript: Raftopoulos, Sure, Tatagiba, Spetzler, Konovalov. Approved the final version of the manuscript on behalf of all authors: Colistra. Administrative/ technical/material support: Lizio. Study supervision: Cenzato.

Supplemental Information

Online-Only Content

References

1. McCormick WF, Hardman JM, Boulter TR. Vascular malformations (“angiomas”) of the brain, with special reference to those occurring in the posterior fossa. *J Neurosurg.* 1968; 28(3):241–251.
2. Metellus P, Kharkar S, Kapoor S, et al. Cerebral cavernous malformations. *Neurosurg Q.* 2008;18:223–229.
3. Giombini S, Morello G. Cavernous angiomas of the brain. Account of fourteen personal cases and review of the literature. *Acta Neurochir (Wien).* 1978;40(1-2):61–82.
4. Moriarity JL, Clatterbuck RE, Rigamonti D. The natural history of cavernous malformations. *Neurosurg Clin N Am.* 1999;10(3):411–417.
5. Akers A, Al-Shahi Salman R, Awad IA, et al. Synopsis of guidelines for the clinical management of cerebral cavernous malformations: consensus recommendations based on systematic literature review by the Angioma Alliance scientific advisory board clinical experts panel. *Neurosurgery.* 2017;80(5):665–680.
6. Pahwa R, Lyons KE, Kempf L, et al. Thalamic stimulation for midbrain tremor after partial hemangioma resection. *Mov Disord.* 2002;17(2):404–407.
7. Seidel S, Kasprian G, Leutmezer F, et al. Disruption of nigrostriatal and cerebellothalamic pathways in dopamine responsive Holmes’ tremor. *J Neurol Neurosurg Psychiatry.*

2009;80(8):921–923.

8. Aydin S, Abuzayed B, Kiziltan G, et al. Unilateral thalamic Vim and GPi stimulation for the treatment of Holmes' tremor caused by midbrain cavernoma: case report and review of the literature. *J Neurol Surg A Cent Eur Neurosurg*. 2013;74(4):271–276.

9. Delaunois J, Vaz G, Raftopoulos C. Transsylvian transuncal approach for an anterior midbrain cavernous malformation resection: a case report. *Oper Neurosurg (Hagerstown)*. 2018;14(3):E38–E43.

10. Abla AA, Lekovic GP, Turner JD, et al. Advances in the treatment and outcome of brainstem cavernous malformation surgery: a single-center case series of 300 surgically treated patients. *Neurosurgery*. 2011;68(2):403–415.

11. Wang CC, Liu A, Zhang JT, et al. Surgical management of brain-stem cavernous malformations: report of 137 cases. *Surg Neurol*. 2003;59(6):444–454.

12. Bhatia KP, Bain P, Bajaj N, et al. Consensus statement on the classification of tremors. From the task force on tremor of the International Parkinson and Movement Disorder Society. *Mov Disord*. 2018;33(1):75–87.

13. Deuschl G, Bergman H. Pathophysiology of nonparkinsonian tremors. *Mov Disord*. 2002;17(suppl 3):S41–S48.

14. Raina GB, Cersosimo MG, Folgar SS, et al. Holmes tremor: clinical description, lesion localization, and treatment in a series of 29 cases. *Neurology*. 2016;86(10):931–938.

15. van Hilten JJ, van Dijk JG, Dunnewold RJW, et al. Diurnal variation of essential and physiological tremor. *J Neurol Neurosurg Psychiatry*. 1991;54(6):516–519.

16. Milanov I. Electromyographic differentiation of tremors. *Clin Neurophysiol*. 2001;112(9):1626–1632.

17. Bhatti D, Thompson R, Hellman A, et al. Smartphone apps provide a simple, accurate bedside screening tool for orthostatic tremor. *Mov Disord Clin Pract (Hoboken)*. 2017;4(6):852–857.
18. Kwon HG, Hong JH, Hong CP, et al. Dentatorubrothalamic tract in human brain: diffusion tensor tractography study. *Neuroradiology*. 2011;53(10):787–791.
19. Salamon N, Sicotte N, Drain A, et al. White matter fiber tractography and color mapping of the normal human cerebellum with diffusion tensor imaging. *J Neuroradiol*. 2007;34(2):115–128.
20. Hong JH, Kim OL, Kim SH, et al. Cerebellar peduncle injury in patients with ataxia following diffuse axonal injury. *Brain Res Bull*. 2009;80(1-2):30–35.
21. Habas C, Cabanis EA. Cortical projection to the human red nucleus: complementary results with probabilistic tractography at 3 T. *Neuroradiology*. 2007;49(9):777–784.
22. Masucci EF, Kurtzke JF, Saini N. Myorhythmia: a widespread movement disorder. Clinicopathological correlations. *Brain*. 1984;107(Pt 1):53–79.
23. Remy P, de Recondo A, Defer G, et al. Peduncular ‘rubral’ tremor and dopaminergic denervation: a PET study. *Neurology*. 1995;45(3 Pt 1):472–477.
24. He JM, He J, Lin HX, et al. Holmes tremor with impairment of the Guillain-Mollaret triangle following medullar hemorrhage. *Neurol Sci*. 2018;39(7):1305–1306.
25. Samadani U, Umemura A, Jaggi JL, et al. Thalamic deep brain stimulation for disabling tremor after excision of a midbrain cavernous angioma. Case report. *J Neurosurg*. 2003;98(4):888–890.
26. Fukui T, Ichikawa H, Sugita K, Tsukagoshi H. Intention tremor and olivary enlargement: clinico-radiological study. *Intern Med*. 1995;34(11):1120–1125.

27. Albin RL. Cerebellar input tremor. *Neurology*. 1998;50(1): 307–308.
28. Savoiaro M. Cerebellar input tremor: inferior or superior cerebellar peduncle lesion? *Neurology*. 1998;51(6):1777–1778.
29. Rieder CRM, Rebouças RG, Ferreira MP. Holmes tremor in association with bilateral hypertrophic olivary degeneration and palatal tremor: chronological considerations. Case report. *Arq Neuropsiquiatr*. 2003;61(2B):473–477.
30. Baizabal-Carvallo JF, Cardoso F, Jankovic J. Myorhythmia: phenomenology, etiology, and treatment. *Mov Disord*. 2015; 30(2):171–179.
31. Yagmurlu K, Rhoton AL Jr, Tanriover N, Bennett JA. Three-dimensional microsurgical anatomy and the safe entry zones of the brainstem. *Neurosurgery*. 2014;10(suppl 4):602–620.

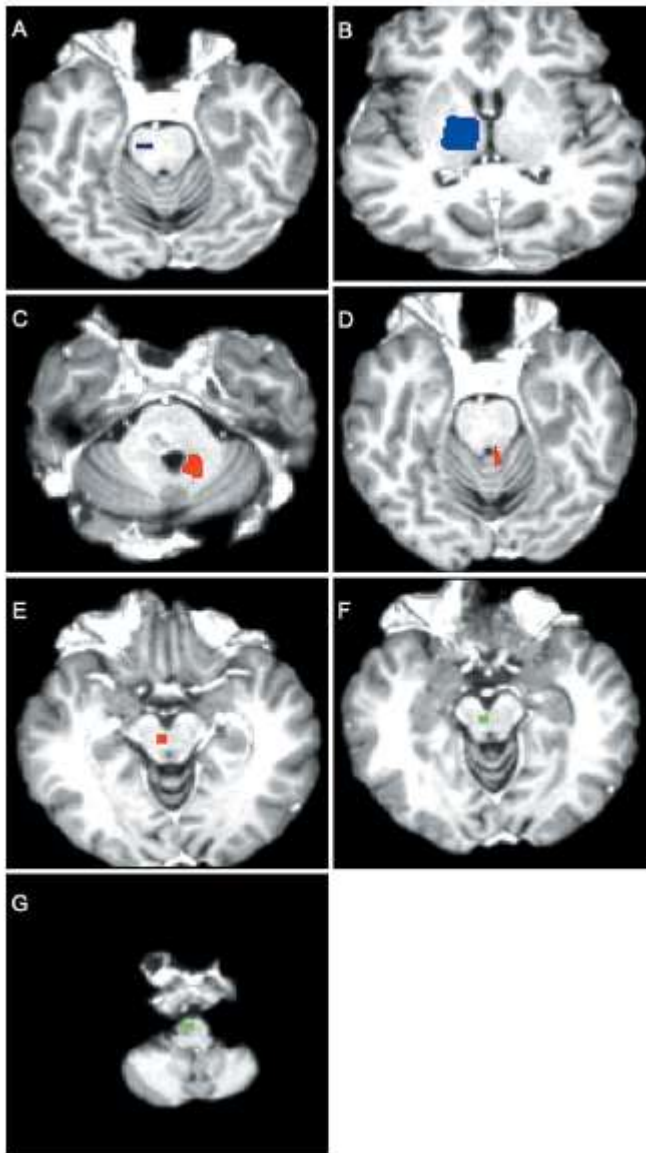


FIG. 1. Axial T1-weighted MR images showing ROIs for reconstruction of the NST (blue areas), located at the level of the substantia nigra (A) and the ipsilateral striatum (B); of the DTT (red areas), located at the level of the dentate nucleus (C), the superior cerebellar peduncle (D), and the contralateral red nucleus (E); and the ROT (green areas), located at the level of the red nucleus (F) and the ipsilateral inferior olivary nucleus (G).

Case No.	Surgeon	Hospital	Sex	Age (yrs)	Cavernoma Location	Surgical Approach	SEZ
1	R. F. Spetzler	Barrow Neurological Institute, Phoenix	M	47	Superior cerebellar peduncle	Supracerebellar infratentorial	Infracollicular
2	R. F. Spetzler	Barrow Neurological Institute, Phoenix	F	31	Superior cerebellar peduncle	Supracerebellar infratentorial	Infracollicular
3	M. Cenzato	Great Metropolitan Hospital Niguarda, Milan	F	50	Rt mesencephalon	Subtemporal	Lat mesencephalic
4	M. Cenzato	Great Metropolitan Hospital Niguarda, Milan	F	64	Rt pontomedullary	Midline suboccipital telovelar	Subfacial
5	R. Stefini	Legnano Hospital, Milan	M	28	Rt mesencephalon	Contralateral FTOZ	Ant mesencephalic
6*	C. Raftopoulos	Saint-Luc University Clinic, Brussels	F	29	Rt mesencephalon	Ipsilat pterional transsylvian	Ant mesencephalic
7	C. Raftopoulos	Saint-Luc University Clinic, Brussels	M	56	Lt mesencephalon	Transfrontal transchoroidal	Ant mesencephalic
8	C. Raftopoulos	Saint-Luc University Clinic, Brussels	F	59	Lt mesencephalon	Ipsilat FTOZ	Ant mesencephalic
9	C. Raftopoulos	Saint-Luc University Clinic, Brussels	F	31	Lt mesencephalon	Supracerebellar infratentorial	Lat mesencephalic
10	C. Bortolotti	Bellaria Hospital, Bologna	M	55	Lt mesencephalon	Supracerebellar infratentorial	Lat mesencephalic
11	P. Feroli	C. Besta Neurological Institute, Milan	F	48	Rt pontomedullary	Midline suboccipital telovelar	Subfacial
12	A. N. Konovalov	Burdenko Neurosurgical Institute, Moscow	F	67	Rt mesencephalon	Supracerebellar infratentorial	Infracollicular
13	A. N. Konovalov	Burdenko Neurosurgical Institute, Moscow	M	24	Lt mesencephalon	Subtemporal	Lat mesencephalic
14	A. Smolanka	University Hospital Uzhhorod, Uzhhorod	M	25	Rt mesencephalon	Contralat pterional transsylvian	Ant mesencephalic
15	A. Smolanka	University Hospital Uzhhorod, Uzhhorod	M	25	Rt mesencephalon	Supracerebellar infratentorial	Lat mesencephalic
16	M. Tatagiba	University Hospital Tübingen, Tübingen	F	68	Lt mesencephalon	Supracerebellar infratentorial	Lat mesencephalic
17	U. Sure	University Hospital Essen, Essen	M	52	Lt mesencephalon	Supracerebellar infratentorial	Lat mesencephalic
18	U. Sure	University Hospital Essen, Essen	M	37	Lt pontomedullary	Midline suboccipital telovelar	Subfacial
19	U. Sure	University Hospital Essen, Essen	F	38	Lt mesencephalon	Supracerebellar infratentorial	Lat mesencephalic
20	G. Pinna	University Hospital Verona, Verona	M	35	Lt mesencephalon	Supracerebellar infratentorial	Lat mesencephalic

Ant = anterior.

* This case has been inserted courtesy of Delaunois et al., 2018.⁹

TABLE 1. Summary of data from collected cases with HT

Hospital	Midbrain	Pons	Pons-Medulla	Medulla	Total Cases
Barrow Neurological Institute, Phoenix	151 (30.2%)	216 (43.2%)	77 (15.4%)	56 (11.2%)	500
Great Metropolitan Hospital Niguarda, Milan	15 (23.1%)	36 (55.4%)	9 (13.8%)	5 (7.7%)	65
Legnano Hospital, Milan	1 (20.0%)	2 (40.0%)	1 (20.0%)	1 (20.0%)	5
Saint-Luc University Clinic, Brussels	10 (33.3%)	12 (40.0%)	5 (16.7%)	3 (10.0%)	30
Bellaria Hospital, Bologna	8 (26.7%)	15 (50.0%)	3 (10.0%)	4 (13.3%)	30
C. Besta Neurological Institute, Milan	16 (35.6%)	18 (40.0%)	6 (13.3%)	5 (11.1%)	45
Burdenko Neurosurgical Institute, Moscow	67 (19.1%)	182 (51.9%)	70 (19.9%)	32 (9.1%)	351
University Hospital Uzhhorod, Uzhhorod	7 (29.2%)	13 (54.2%)	3 (12.5%)	1 (4.2%)	24
University Hospital Tübingen, Tübingen	20 (29.9%)	30 (44.8%)	7 (10.4%)	10 (14.9%)	67
University Hospital Essen, Essen	28 (29.8%)	38 (40.4%)	19 (20.2%)	9 (9.6%)	94
University Hospital Verona, Verona	18 (28.5%)	32 (50.8%)	6 (9.5%)	7 (11.1%)	63
Total cases	341 (26.8%)	594 (46.6%)	206 (16.2%)	133 (10.4%)	1274

TABLE 2. Location of 1274 brainstem cavernomas

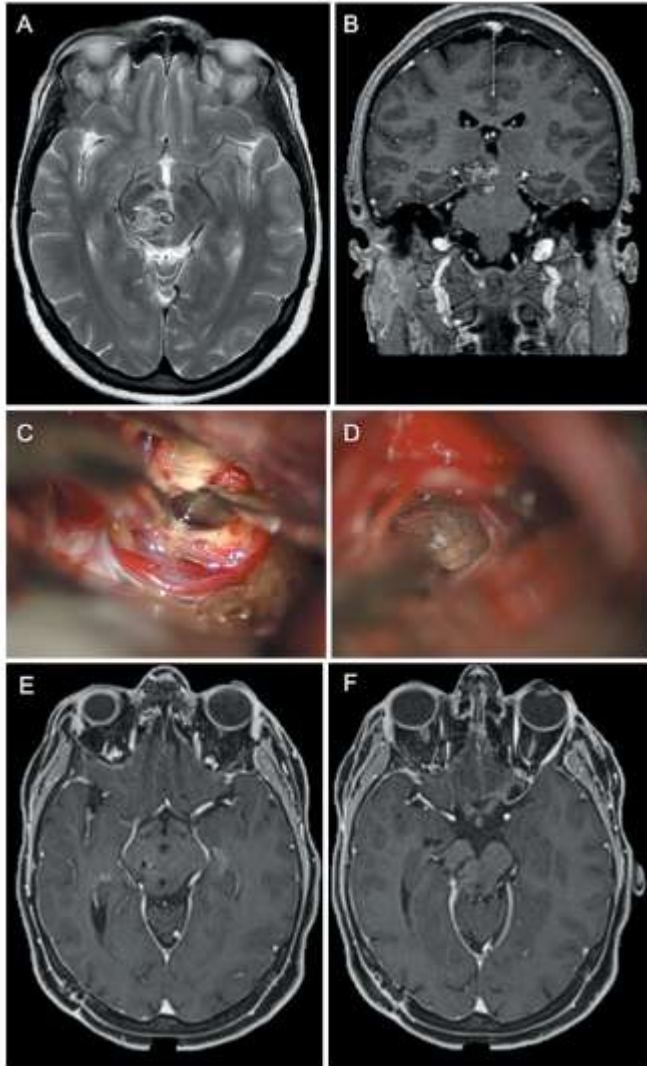


FIG. 2. Case 3. Preoperative axial (A) and coronal (B) T2-weighted MR images showing a brainstem cavernoma at the level of the right cerebral peduncle. Intraoperative images showing the surgical access through the lateral mesencephalic sulcus (C) and the dyschromic area corresponding to the cavernoma (D) inside the brainstem. Postoperative axial T1-weighted MR images with gadolinium enhancement show in more caudal (E) and more cranial (F) sections the surgical entry point at the level of the right lateral mesencephalic sulcus and complete removal of the cavernoma.

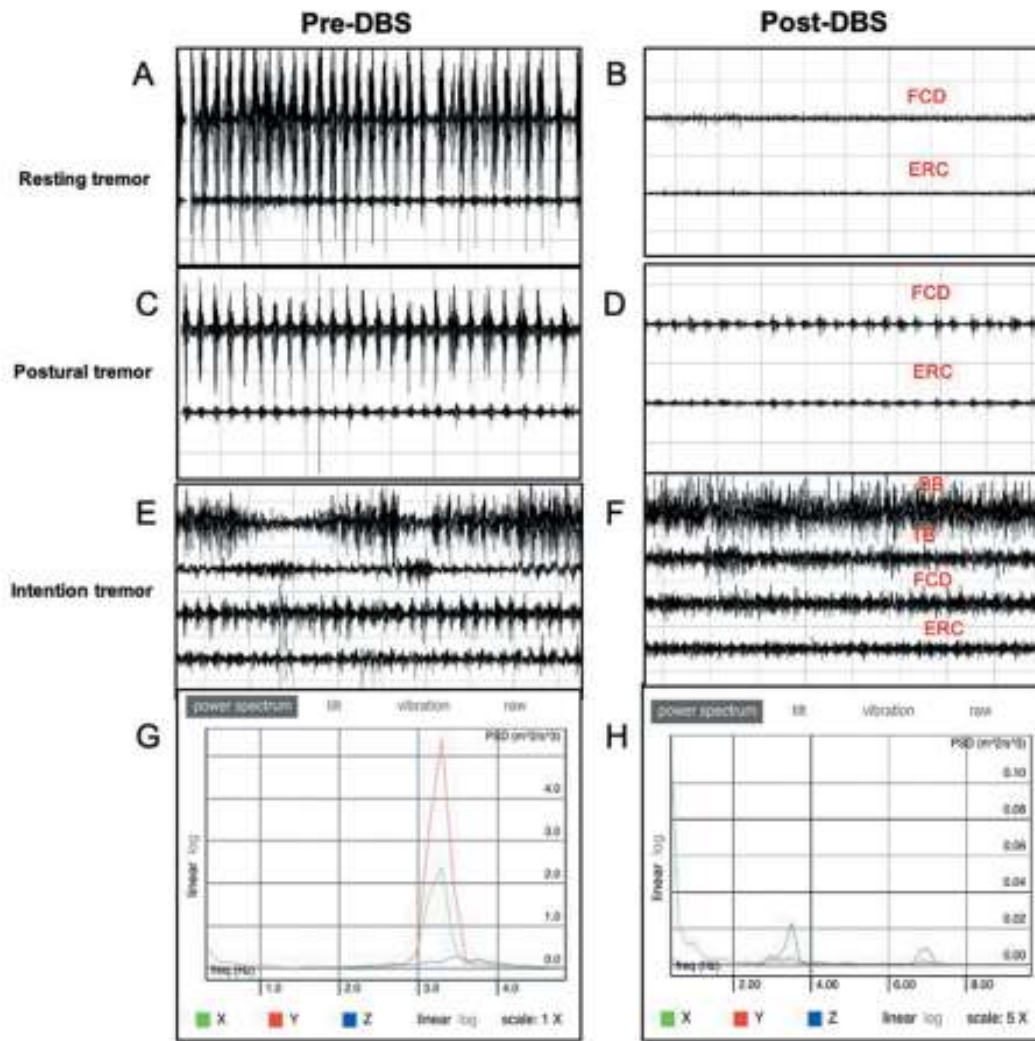


FIG. 3. Case 3. EMG results showing in all positions a tremor frequency around 3 Hz but a notable difference in the amplitude of

the tremor between the pre-DBS (A, C, E) and post-DBS (B, D, F) recordings. Power spectrum graphs obtained with VibSensor,

showing a stable tremor frequency around 3.3 Hz but a considerable reduction in the power spectral density (PSD) of the tremor

between the pre-DBS (G) and post-DBS (H) recordings. BB = biceps brachii muscle; ERC = extensor radialis carpi muscle; FCD =

flexor communis digitorum muscle; TB = triceps brachii muscle. Figure is available in color online only.

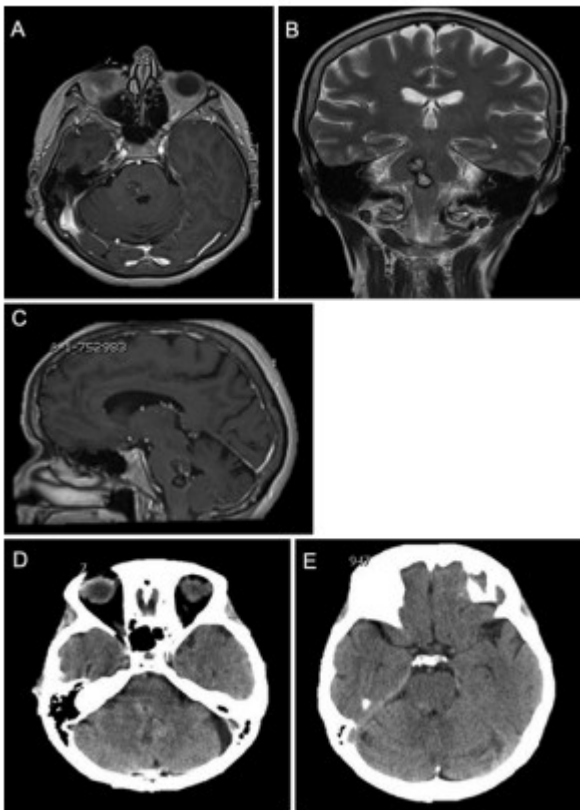


FIG. 4. Case 4. Preoperative MRI showing a cavernoma at the pontomedullary junction in axial Gd-enhanced T1-weighted (A), coronal T2-weighted (B), and sagittal Gd-enhanced T1-weighted (C) sections. Postoperative CT scan showing in more caudal (D) and more cranial (E) sections the surgical entry point at the level of the floor of the fourth ventricle, reached through the midline suboccipital telovelar approach.

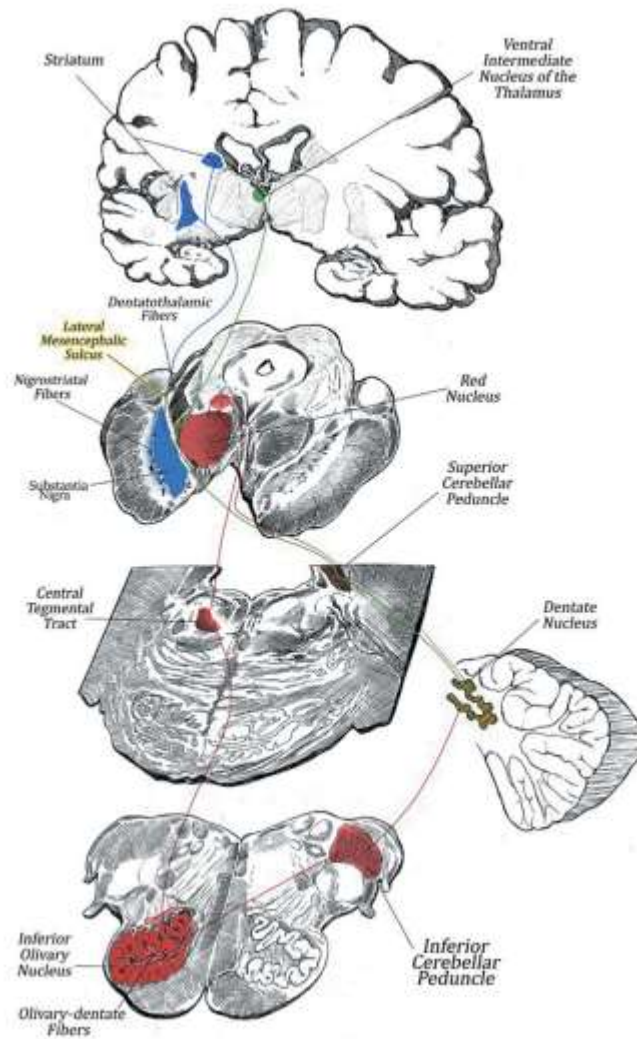


FIG. 5. Anatomical relationships between HT pathways and the lateral mesencephalic SEZ. Drawing of the nigrostriatal (blue), dentatothalamic (green), and rubro-olivo-dentato-rubric (red) pathways. The NST, DTT, and ROT at the level of the cerebral peduncle run close to the lateral mesencephalic sulcus (yellow), which is the SEZ used in case 3. Copyright Davide Colistra.

Published with permission

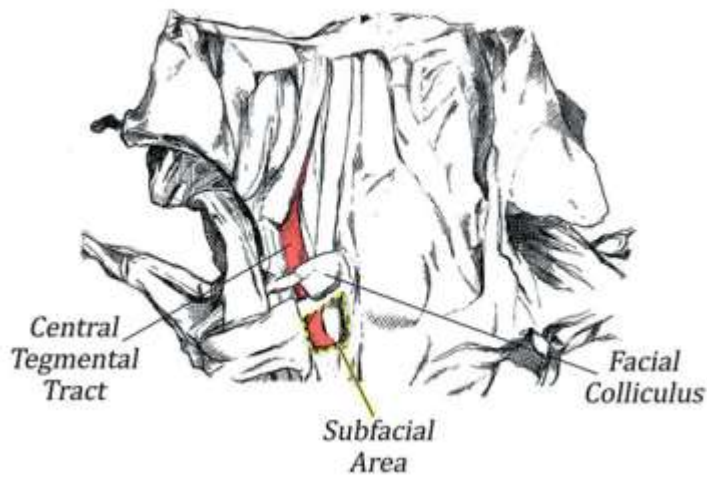


FIG. 6. Anatomical relationships between HT pathways and the subfacial SEZ. Freehand drawing showing how the central tegmental tract (red), within which the ROT runs, is at the level of the floor of the fourth ventricle just below the subfacial area (yellow), which is the SEZ used in case 4. Copyright for drawing: Davide Colistra; published with permission. The drawing is based on a photograph of a cadaveric dissection prepared by Kaan Yağmurlu, which appears in The Rhoton Collection; with permission (CC BY-NC-SA 4.0 [<http://creativecommons.org/licenses/by-nc-sa/4.0>]).