

AperTO - Archivio Istituzionale Open Access dell'Università di Torino

Safety and Effects of a Commercial Ozone Foam Preparation on Endometrial Environment and Fertility of Mares

This is a pre print version of the following article:

Original Citation:

Availability:

This version is available <http://hdl.handle.net/2318/1886812> since 2023-05-31T12:54:08Z

Published version:

DOI:10.1016/j.jevs.2023.104222

Terms of use:

Open Access

Anyone can freely access the full text of works made available as "Open Access". Works made available under a Creative Commons license can be used according to the terms and conditions of said license. Use of all other works requires consent of the right holder (author or publisher) if not exempted from copyright protection by the applicable law.

(Article begins on next page)

Safety and effects of a commercial ozone foam preparation on endometrial environment and fertility of subfertile mares

Gian Guido Donato^{a,*}, Simonetta Appino^c, Alessia Bertero^a, Mariagrazia Lucia Poletto^a, Patrizia Nebbia^a, Patrizia Robino^a, Katia Varello^b, Elena Bozzetta^b, Leila Vincenti^a, Tiziana Nervo^a

^a Dipartimento di Scienze Veterinarie, Università di Torino, Grugliasco, Italy; gianguido.donato@unito.it; alessia.bertero@unito.it; mariagrazialucia.poletto@unito.it; patrizia.nebbia@unito.it; patrizia.robino@unito.it; leila.vincenti@unito.it; tiziana.nervo@unito.it.

^b Istituto Zooprofilattico Sperimentale del Piemonte, Liguria e Valle d'Aosta, Torino, Italy; katia.varello@izsto.it; elena.bozzetta@izsto.it.

^c Dipartimento di Medicina Veterinaria, Università di Sassari, Sassari, Italy; simo@uniss.it.

* Corresponding author: Gian Guido Donato, Dipartimento di Scienze Veterinarie, Università di Torino, Grugliasco, Italy; E-mail address: gianguido.donato@unito.it

Highlights:

Ozone foam therapy caused a transient endometrial inflammation

Ozone foam therapy is not harmful for endometrial environment and fertility

Riger Spray[®] is a practical ozone preparation for field use

Abstract:

Mares' subfertility represents a complex diagnostic and therapeutic challenge and both clinical and subclinical endometritis are considered major causes of impaired fertility. Thanks to its properties, ozone has a big potential as a treatment for equine endometritis. Therefore, the aim of this study is to describe the safety and the effects on endometrium and reproductive parameters of subfertile mares of a commercial ozone foam preparation (Riger Spray[®]). Twenty-four mares were treated during estrus: ozone group with an intrauterine instillation of ozone foam preparation (OG, n=16) and control group with 20 ml of lactated Ringer's solution (CG, n=8). Samples for endometrial cytology were collected before the ozone treatment (T0), after 24 h (T1), after one week (T2), two weeks (T3), and when the subsequent estrous phase was detected (T4). Furthermore, samples for histological examination and uterine swab for bacteriological examination were collected at T0 and T4. At T1, a statistically significant increase of endometrial inflammation in the OG mares compared to T0 ($P<0.05$) and to CG at same time point ($P<0.05$) was observed, but it was already resolved at T2. No differences in endometrial inflammation in CG, biopsy grade before and after the treatment in the two groups, number of mares pregnant at the end of the season and number of mares pregnant at the first cycle were observed. However, the number of inseminations required for pregnancy tended to be lower ($P=0.0711$) in the OG (1.69 ± 0.06) than in CG mares (2.60 ± 0.89).

Keywords: mare, subfertility, ozone, horse, endometritis

Gian Guido Donato: Conceptualization, Methodology, Investigation, Writing- Original draft. **Simonetta Appino:** Investigation, Writing - Review & Editing. **Alessia Bertero:** Formal analysis, Writing- Original draft. **Maria Grazia Poletto:** Investigation, Conceptualization **Patrizia Nebbia:** Investigation, Writing - Review & Editing. **Patrizia Robino:** Investigation, Writing - Review & Editing. **Katia Varello:** Investigation. **Elena Bozzetta:** Investigation. **Leila Vincenti:** Supervision. **Tiziana Nervo:** Conceptualization, Methodology, Investigation, Supervision, Writing - Review & Editing.

1 Introduction:

Mares' subfertility, although extensively studied and discussed, still represents a complex diagnostic and therapeutic challenge for the practitioners and researchers working in equine breeding industries and leads to a substantial economic loss [1]. Even if fertile semen is used and multiple inseminations are performed according to good veterinary practices, unfortunately, many mares fail to become pregnant every year (the so called "barren mares") [2]. It is often difficult to pinpoint a single cause for the impaired fertility of these mares, but certainly the status of the endometrium is one of the main factors involved [3]. In addition, clinical, but also subclinical endometritis, are both major causes of infertility in the mare [4].

Many treatments for the improvement of the uterine environment have been used over the years. Nevertheless, considering the worldwide rise of antibiotic resistance, non-traditional therapies, like ozone, are representing an important field of research in the treatment of mare's subfertility.

Ozone was discovered in 1839 by Schönbein [5] and medical ozone applications date back to the end of the nineteenth century: in 1881, in a book on diphtheria, it was already mentioned as a disinfectant [6] and in 1892 an article was published describing the administration of ozone for treatment of tuberculosis [7]. Furthermore, during World War I ozone was used for treating German soldiers affected by gaseous gangrene and to prevent and suppress wound infections [8].

Ozone is a highly unstable gaseous molecule made of three atoms of oxygen with a cyclic structure that naturally forms from oxygen (O₂) by the action of ultraviolet light and electrical discharges in the atmosphere [9,10]. It is 1.6-fold denser and 10-fold more soluble in water than oxygen. It is the third most potent oxidant after fluorine and persulfate. Ozone is an unstable gas that cannot be stored and should be used at once because it has a half-life of 40 min at 20°C and 140 min at 0°C [11]. It is produced by ozone generators through a high-voltage gradient, starting from pure oxygen up to obtain a gaseous mixture containing a minimum of 95% oxygen and up to 5% ozone and usually, for clinical purposes, ozone concentrations range is 10–45 µg/ml [6,12]

Ozone has a wide antimicrobial, antiviral and antifungal activity [13–20]. The mechanisms are based on its great oxidizing properties, which induce the destruction of bacterial cell walls, cytoplasmic membrane and of lipid molecules in capsids. This causes an increase in permeability and the entry of ozone into the cells [21]. Moreover, ozone therapy is also able to damage bacterial and viral nucleic acid and stimulates the innate immune system to contrast the microorganisms [22,23].

The function of O₃ shares similarities with that of a prodrug, as it is modified upon reacting with molecules to develop more active substrates, thus prompting an endogenous cascade of reactions [24]. In fact, O₃ therapy induces moderate oxidative stress when interacting with lipids and this interaction increases endogenous production of antioxidants, local perfusion, and oxygen delivery, as well as enhances immune responses [24,25]. Thus, due to its multiple properties, ozone therapy is also shown

to boost immune system [22], optimize tissue regeneration mechanisms, stimulate granulation and epithelialization processes, and reduce inflammation in several pathological conditions [26-29].

In the last years, ozone is gaining more and more popularity in veterinary and human medicine, because of its efficacy in the treatment of reproductive pathologies that could affect female fertility [30]. Furthermore, ozone therapy is used to treat also mastitis, osteoarthritis, laminitis, lumbar pain, wounds, disc herniations and ocular pathologies [23]

Riger Spray® (Novagen, Podenzano, PC, Italy) is a product composed of ozonated sunflower oil. Its efficacy in improving reproductive performances and treating common reproductive pathologies in cows, goats and ewes had been widely described.

Zobel et al. [31] showed that in case of urovagina in the cow, the ozone treatment was more effective than streptomycin, resulting in a shorter period of days open and a lower number of inseminations until pregnancy.

Cows treated preventively after calving with Riger spray® became pregnant earlier, had a better conception rate and showed a significantly lower incidence of endometritis [32-34]. Furthermore, when used on cows with metritis and endometritis, ozone acted beneficially on overall fertility by shortening the days open until first service and the days open until pregnancy [33,35].

Intrauterine ozone treatment in cows, sheep and goats with retained placenta attained similar or better results compared to antibiotic therapy and the healthy control group, showing a physiological involution of the uterus and an optimal recovery of fertility [36-39].

Thanks to its proved antimicrobial, anti-inflammatory, immunostimulant, and angiogenetic properties, associated with the fact that it's a non-antibiotic therapy, ozone has a big potential as a treatment for endometritis and subfertility in the mare [40,41].

Currently, to the best of our knowledge no articles have been published about the effects of a treatment with commercial ozone foam spray in mares, therefore, the aim of the present study was to describe the safety and the effects of the use of an ozone foam spray treatment (Riger Spray®, Novagen, Podenzano, PC, Italy) on the endometrium of subfertile mares.

2 Materials and Methods

The experiment was approved by the Ethics and Animal Welfare Committee of the Department of Veterinary Sciences of the University of Turin (Italy) (0002180, 2021). Written informed consent of the horse owners was obtained. All procedures were performed in compliance with the guidelines of the Italian Ministry of Health for the care and use of animals (D.L. 4 March 2014 n. 26 and D.L. 27 January 1992 n. 116) and with EU Directive 86/609/CEE.

2.1 Animals and Clinical Records

Thirty-three Standardbred mares with an history of subfertility were referred to the Veterinary Teaching Hospital (OVU) of the University of Turin (Italy) and were submitted to a complete examination of the reproductive tract, including transrectal palpation, ultrasound examination (MyLabOne, Esaote, Italy), vaginal speculum examination, bacteriological, cytological and histological evaluation. Only subfertile mares negative to bacterial culture were included in this study because they were privately owned and therefore, due to the will of the owners, positive mares with

a diagnosis of infectious endometritis were treated with gold standard therapy, the antibiotic therapy, according to the results of antimicrobial sensitivity tests.

These mares had an average age of 14.08 ± 3.80 years (median: 14 years; range: 8-19 years), an average weight of 478.12 ± 41.32 kg (median: 479 kg, range: 410-548 kg) and a body condition score between 2.5 and 4 [42].

The mares were pluriparous and were determined to be subfertile because failed to get pregnant during the previous reproductive season after three or more inseminations performed according to good veterinary practices with semen from fertile stallions or underwent early embryonic loss [43]. The mares were housed in two different racehorse farms near Turin (Italy) under the management of the same veterinary team. They were kept in outdoor paddock and were fed with hay and pellet feed, and water was supplied *ad libitum*.

2.2 Treatment

The treatments were performed between February and April 2022 during the follicular phase.

An ultrasound examination was performed every two days to detect the presence of estrous, established through the detection of a dilated cervix, a >35 mm follicle, the absence of a corpus luteum, endometrial oedema, and a relatively flaccid uterus on palpation [44].

Mares were randomly divided into two groups:

Control group (CG): 8 mares were treated with an intra-uterine infusion of lactated Ringer's solution.

Ozone group (OG): 16 mares were treated with an intra-uterine infusion of an ozone-based foam spray product (Riger Spray[®], Novagen, Italy).

Before all the treatments, the rectal ampoule was gently emptied, the tail was wrapped and the perineum washed with water and povidone iodine (Betadine; MEDA PHARMA SpA, Milan, Italy) for three times, then dried with paper towel.

Subsequently, for the mares in CG, 20 ml of lactated Ringer's solution were instilled in the uterus through a syringe and an insemination catheter.

For the mares in OG, Riger Spray[®], was instilled transcervically in the uterus with a sterile insemination catheter and a special 10-cm long fitting, keeping the applicator of the can pressed for five seconds, as described for the treatment of bovine endometritis [32,35].

The mares in the two groups were homogeneous for age (CG: 13.25 ± 4.40 years; OG: 14.50 ± 3.60 years), parity, and body condition score.

2.3 Experimental design

In order to assess the safety of ozone foam spray treatment on uterine environment, uterine swabs for bacteriological examination were collected before the ozone treatment (T0), and after a period of 18 to 27 days (T4), when the subsequent estrous phase was detected. Subsequently, samples for endometrial cytology were collected at T0, 24 h after the treatment (T1), after one week (T2), after two weeks (T3) and at T4. Finally, endometrial samples for histological examination were collected at T0 and T4. Ultrasound examination was performed at T0, T1, T2, T3 and T4.

To determine the effect of ozone treatment on reproductive parameters of subfertile mares, the mares were inseminated at the cycle after the treatment. After the detection of a follicle bigger than 35 mm and the presence of endometrial oedema, 1500 IU of Human Chorionic Gonadotropin (Corulon[®], MSD Animal Health S.r.l., Segrate Milan, Italy) were administered intravenously to induce ovulation.

Artificial insemination with chilled semen of stallion of known fertility was performed 24 h after ovulation induction. The number of mares that successfully became pregnant after the first insemination, at the end of the 2022 reproductive season, the number of inseminations required for pregnancy and the episodes of early embryonic loss were recorded.

2.4 Sample collection and laboratory analysis

2.4.1 Cultural examination. The samples for cultural examination were collected with a double guarded uterine swab (Minitube, GmbH, Germany). Briefly, the instrument was introduced into the vagina and through the cervix. Once the tip reached the uterine body, the outer tube was retracted enough to expose the swab, that was gently rotated against the uterine wall. Finally, the swab was retracted into the outer tube prior to removal from the uterus. Subsequently, the swab was inserted in AMIES transport medium (Minitube, GmbH, Germany) and transported, within 2-8 hours at refrigeration temperature, to the Microbiology Laboratory of OVU for the examination. Each uterine swab was resuspended in 3 ml of a non-selective enrichment medium (Brain Heart Infusion Broth Oxoid) and incubated overnight at 37°C. Then, each cultural sample was streaked on agar with 5% sheep blood plates for a further 24 hours at 37°C. The isolates were identified by matrix assisted laser desorption ionization-time of flight/ mass spectrometry (MALDI-TOF/MS) (Bruker, Germany).

2.4.2 Cytological examination. The samples for cytological examination were collected with a double guarded uterine cytobrush (Minitube, GmbH, Germany) as previously described [45]. Briefly, the instrument was introduced into the vagina and through the cervix. Once the tip reached the uterine body, the outer tube was retracted enough to expose the cytobrush, that was gently rotated against the uterine wall. Finally, the cytobrush was retracted into the outer tube prior to removal from the uterus. The cytobrush was gently unrolled on a glass slide and dried at air. The slides were brought to the Animal Reproduction Laboratory of the Veterinary Teaching Hospital (OVU) of the University of Turin (Italy).

The cell smears were fixed and stained using Diff-Quick stain (Medion Diagnostics AG, Dürdingen, Switzerland), and evaluated, blindly, by a pathologist at 400X magnification (referred to as “high power field”, or “hpf”) over multiple fields. Ten microscopic fields were randomly selected in multiple areas of the slide and the average number of PMN/hpf was determined [46].

2.4.3 Histological examination. The samples for histological examination were collected transcervically from the utero-cornual junction, using a sterilized forceps for uterine biopsy (Equivet, Kruuse, Marselv, Denmark), as previously described [47]. Uterine biopsy samples were immediately placed in 10% buffered formalin. Formalin fixed biopsies were paraffin embedded; 5µm sections were then stained with Haematoxylin and Eosin, according to the standard procedure. Histological observation was performed, blindly, by a pathologist, and biopsy samples were graded according to Kenney and Doig classification [47].

2.5 Statistical Analysis

For statistical evaluation the data were analyzed with the software GraphPad Prism for Mac, ver.9.4.1. The analysis was considered significant with a P value <0.05. Data were tested for normality using Kolmogorov and Smirnov test.

Differences in number of PMN/hpf and inseminations required for pregnancy within and between groups were compared by means of Friedman and Mann-Whitney tests, respectively.

Differences between the two groups in the number of mares pregnant at the first insemination and at the end of the season were tested by means of Chi-squared test.

Regarding the histological classification, differences within the two groups were tested by means of McNemar's Chi-squared test.

3 Results

3.1 Uterine culture

Out of 33 mares sampled, 9 (27.30%) were positive to bacterial culture. Therefore, they were excluded from the study. In the remaining 24 mares, the uterine culture was negative at T0 and the animals were enrolled in this study. All 24 mares resulted also in culture negative at time T4.

3.2 Cytology

The number of PMN/hpf at the different time points is shown in Figure 1.

At T0, 14 mares (OG n=9; CG n= 5) showed a mild grade of inflammation (PMN/hpf between 1 and 2) and 10 mares (OG n= 7; CG n= 3) showed a moderate grade of inflammation (PMN/hpf between 3 and 5) [48]. No differences were observed between the two groups at T0 ($P>0.1$).

At T1, 24 hours after treatment, there was a statistically significant increase of endometrial inflammation in the OG mares compared to T0 ($P<0.05$) and compared to CG at the same time point ($P<0.05$).

Also in the CG mares, the number of PMN/hpf slightly increased, but the difference between T0 and T1 was not statistically significant ($P>0.1$).

Already at T2, at one week after treatment, the resolution of inflammation was noted in OG compared to T1 ($P<0.05$) and at T2, T3 and T4 the number of PMNs was not different from T0 in both OG and CG (OG: $P>0.1$; CG: $P>0.1$).

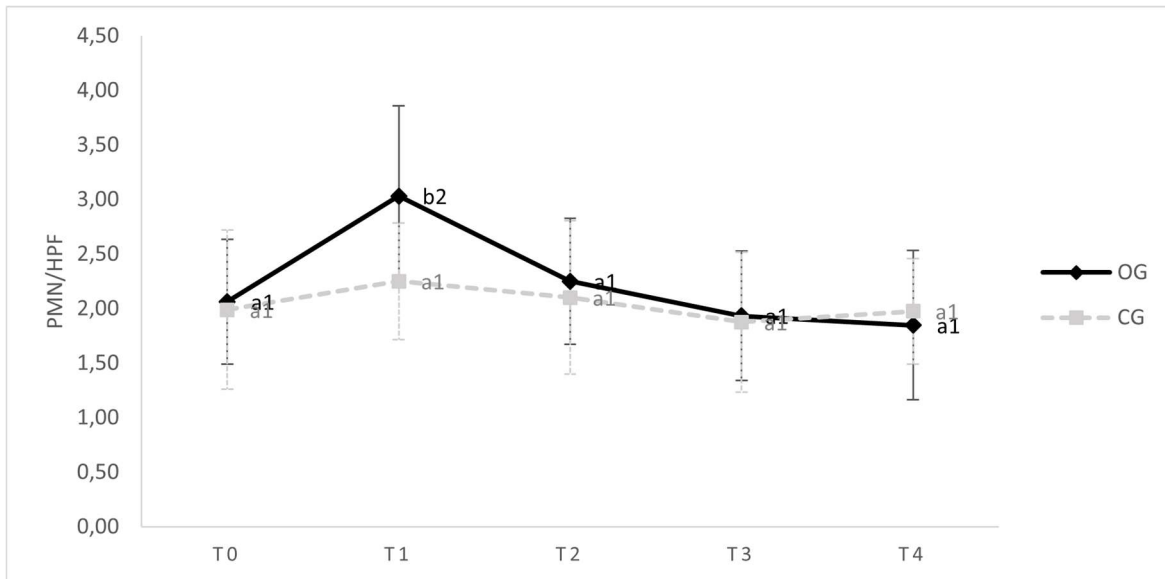


Figure 1: Number of PMN/hpf observed with uterine cytology in mares treated with ozone (OG) and in the control group (CG) at different time points. a, b Different letters indicate a statistical difference in the same group ($P < 0.05$). 1, 2 Different numbers indicate a statistical difference between the two groups ($P < 0.05$).

3.3 Histology

All the mares' endometria were graded as Kenney-Doig score IIA (OG $n=9$; CG $n=4$) or IIB (OG $n=7$; CG $n=4$). No mare demonstrated an increase in the severity in the endometrial Kenney-Doig score at the estrus successive to the treatment ($P > 0.1$).

In addition, no differences were observed in the endometrial histological classification between the two groups ($P > 0.1$) neither before nor after treatment ($P > 0.1$). Besides, no signs of fibrosis, necrosis or endometrial degeneration were observed after the treatment.

3.4 Effect of ozone therapy on clinical and reproductive parameters

After the treatment with ozone or with Lactated Ringer solution, no mare showed signs of discomfort or pain. In 6/16 mares (37.50%) of the OG in the day after treatment the presence of 1-2.5 cm of grade II (semi-echogenic) or III (hypoechoic) [49] fluid in the lumen of the uterus was observed, but it was not noticeable at the second examination, after one week (T1).

At the end of the season, 13/16 mares (81.30%) in the OG and 5/8 mares (62.50%) in the CG successfully became pregnant, but no statistically significant difference has been observed ($P > 0.1$).

At the first insemination after treatment, 6 mares in the OG (33.30%) and 1 in the CG became pregnant (12.50%) ($P > 0.1$). Regarding the number of inseminations required for pregnancy, it tended to be lower in the OG mares (1.69 ± 0.06) than in CG mares (2.60 ± 0.89) ($P = 0.0711$). No early embryonic losses were observed.

4 Discussion

To the best of the authors' knowledge, the safety and the effects on equine endometrium of Riger Spray[®] have never been described, although in cows, ewes and goats this ozone formulation has been shown to improve fertility rate, due to a healthier endometrial environment [33].

One of the major causes of fertility reduction in the mare is generally identified in endometritis, the local inflammation of the lumen of the uterus [4], that generally develops because of the establishment of microbial contamination of the organ, but also because of the inability of the mare to clear the

physiological inflammatory response after breeding [50]. Furthermore, chronic inflammation or infection of the endometrium could also lead to the development of other endometrial diseases, such as endometriosis (fibrosis of endometrial glands) [51] and angiosis (degenerative diseases of vessels), that are important causes of subfertility as well [52].

In our study, to assess the effects of ozone on the uterine environment, endometrial culture, cytology and histological examination were performed, all procedures that are routinely used for the diagnosis of uterine illnesses in mares [53-55]. Positive bacterial cultures have been reported in 12-60% of barren mares [46,54,56,57,] and the results of our study are in accordance with these authors, since 27.30 % of the mares presented a bacterial endometritis.

However, the failure to isolate bacteria does not eliminate the presence of endometritis, since this disease may be difficult to diagnose as not all the mares show positive bacteriological and/or cytological examination and evident clinical signs. According to De Amorim et al. [58], cytology is twice as sensitive than culture in the diagnosis of endometritis, and endometritis has to be suspected in mares with a history of subfertility. The mares in the present study, although negative to bacterial culture, had a previous history of subfertility and showed a mild to moderate grade of endometrial inflammation.

The aim of Riger Spray[®] and other products composed of ozonated oil is to obtain formulations containing ozone that are practical and easy to store and use in field conditions, since ozonated oil improves the short half-life of ozonated water or saline and O₂-O₃ gas mixture [59,60], avoiding the need of an ozone generator equipment. In the present study we decided to use ozonated oil in a single treatment, as previously described for bovine endometritis and recommended from the producer [32-35]. However, this decision is supported by the findings of Camargo Ferreira et al. [61] that observed the in vitro germicidal action of a single treatment with ozonated oil against *Pythium insidiosum* isolated from horse. Interestingly, to obtain the same effect with O₂-O₃ gas mixture, it was necessary to perform the treatment for three consecutive days, since a single exposure to gas was ineffective. Furthermore, since the amount of peroxide in the oil after the ozonation process is generally considered to be correlated with the antimicrobial action, it was observed that only ozonated oil with a peroxide index higher than 500 mEq kg⁻¹ was able to inactivate *P. insidiosum* [61]. Also Ávila et al. [62] recently proved the in vivo antimicrobial effect of a single intrauterine treatment with ozonated oil with peroxide index of 600 mEq kg⁻¹. Riger Spray[®] has a peroxide index higher than 1000 mEq kg⁻¹, therefore, it has the potential to exert an in vivo antimicrobial effect in the uterine environment. Thanks to its antimicrobial effect, ozone could play an important role in the prevention of antimicrobial resistance, a growing global issue [63] and it could be useful in equine reproduction, since antibiotics are routinely used in the majority of broodmares, even in the absence of intrauterine fluid, bacterial culture and antimicrobial sensitivity test [64]

Only a few studies have been performed about the use of ozone in the mare in the previous years, but recently, due to the ever-increasing attention that this molecule is eliciting in the equine reproduction field, different studies have been published: Camargo Ferreira et al. [40] proved the ability of uterine insufflation with an oxygen–ozone gas mixture to induce endometrial angiogenesis and the same effect has been observed in healthy women treated with ozonated saline flushing [65]. Therefore, it can be useful in cases of subfertility since blood supply is necessary for hormonal signaling, uterine contractility, placentation and feto–endometrial interactions [4] and blood flow is diminished in mares with endometrial degeneration [66].

Almeida et al. [67] observed that intrauterine ozone therapy can cause controlled and transient systemic oxidative stress in healthy mares. This result is promising since ozone therapy is described

to act inducing a controlled oxidative stress that stimulates an adaptive antioxidant response [8,68] and oxidative stress has been shown to be associated with endometritis in the mare [69].

Furthermore, Ávila et al. [62] have shown the effectiveness of ozone therapy in the treatment of endometritis. In particular, although the ozonated sunflower oil was not as effective as the O₂-O₃ gas mixture in the reduction of inflammation (the number of PMN did not change in the cycle after treatment), its antimicrobial property against the bacteria present in the equine uterus has been proved. Mazzuchini et al. [70] observed that the number of PMN tended to be higher 24 hours after the treatment with ozonated saline solution compared to control group.

The results of our study are in accordance with Mazzuchini et al. [70] and Ávila et al. [62], since in the mares treated with ozone an increase in the endometrial inflammation has been observed the day after treatment, but it completely resolved after one week, and the number of PMN was not different in the cycle after the treatment compared to the previous one. This inflammation, that is a natural response of the equine uterus to the introduction of exogenous materials such as semen, extender, bacteria, debris and also air [71,72], is probably due to the fact that Riger Spray[®] is an oil-based product, that is more aggressive on endometrium [73]. Therefore, this was not able to reduce the number of PMN, as described for the gaseous form [62] and the ozonated distilled sterile solution [41].

However, Riger Spray[®], despite its foam nature, is well tolerated by the equine uterus and no adverse reactions had been observed in the mare, such as a persistent exaggerated inflammatory response or abdominal discomfort. Furthermore, it did not predispose to a uterine unhealthy environment since no bacterial infections were detected after treatment.

The safety of Riger spray[®] was also investigated from the histological point of view and we assessed that this ozone presentation is not dangerous and detrimental for intrauterine use in the mare and do not cause chronic inflammatory changes in the endometrium, as previously described for other treatments like povidone-iodine [74] or enrofloxacin [75].

Riger Spray[®] has proved to be safe also according to clinical and reproductive parameters, since after treatment 81% of the mares successfully got pregnant, without any episode of early embryonic loss. No statistically significant differences between the two groups in the number of mares pregnant at the first cycle and at the end of the season were noticed, but the number of inseminations required to obtain the pregnancy tended to be lower in OG mares. Therefore, further investigations are needed increasing the sample size to observe if Riger spray[®] is not only safe but also effective in enhancing reproductive parameters, since many variables are involved in mare's infertility.

Furthermore, due to the many proven beneficial properties of ozone and the practicality of this ozone preparation, it's worth to perform additional investigations to establish the best protocol for ozone therapy and to demonstrate the efficacy of this product in mares with clinical endometritis and positive to bacterial culture, given the wide use of intrauterine antibiotics in the equine industry [76], the increase of antimicrobial resistance [77] and the worldwide effort to develop effective alternative antibiotic-free therapies to treat endometritis.

5 Conclusion

Intrauterine ozone therapy with Riger spray[®] is a safe treatment in the mare since no adverse effects were noted in terms of bacterial culture, endometrial cytology, histology and pregnancy outcomes. Furthermore, this ozone formulation is practical to use under field condition, although future studies are needed to assess antimicrobial activity and positive effects on fertility in mares with bacterial endometritis.

Financial disclosure

This research did not receive any specific grant from funding agencies in the public, commercial, or not-for-profit sectors.

Conflict of interest statement

The authors declare no conflicts of interest.

Figure captions

Figure 2: Number of PMN/hpf observed with uterine cytology in mares treated with ozone (OG) and in the control group (CG) at different time points. a, b Different letters indicate a statistical difference in the same group ($P < 0.05$). 1, 2 Different numbers indicate a statistical difference between the two groups ($P < 0.05$).

References

- [1] Pasolini MP, del Prete C, Fabbri S, Auletta L. Endometritis and Infertility in the Mare – The Challenge in Equine Breeding Industry—A Review. *Genital Infections and Infertility, InTech*; 2016. doi:10.5772/62461.
- [2] Coutinho da Silva MA. When should a mare go for assisted reproduction? *Theriogenology* 2008;70:441–4. doi:10.1016/j.theriogenology.2008.05.039.
- [3] Carluccio A, Veronesi MC, Plenteda D, Mazzatenta A. Platelet-rich plasma uterine infusion and pregnancy rate in barren mares with chronic degenerative endometritis. *Pol J Vet Sci* 2020;23:431–8. doi:10.24425/pjvs.2020.134688.
- [4] Leblanc M, Causey R. Clinical and subclinical endometritis in the mare: Both threats to fertility. *Reprod Domest Anim* 2009;44:10–22. doi:10.1111/j.1439-0531.2009.01485.x.
- [5] Schönbein CF. Recherches sur la nature de l'odeur, qui se manifeste dans certaines actions chimiques. *Hebd Seances Acad Sci* 1840; 10: 706-10.
- [6] Hidalgo-Tallón FJ, Torres-Morera LM, Baeza-Noci J, Carrillo-Izquierdo MD, Pinto-Bonilla R. Updated Review on Ozone Therapy in Pain Medicine. *Front Physiol* 2022;13. doi:10.3389/fphys.2022.840623.
- [7] Norris HE. The Internal Administration of Ozone in the Treatment of Phthisis. *Lancet* 1892; 140 (3612): 1180–1181. 1892. doi:10.1016/S0140-6736(01)92422-5
- [8] Bocci V, Borrelli E, Travagli V, Zanardi I. The ozone paradox: Ozone is a strong oxidant as well as a medical drug. *Med Res Rev* 2009;29:646–82. doi:10.1002/med.20150.
- [9] Erario M de los Á, Croce E, Moviglia Brandolino MT, Moviglia G, Grangeat AM. Ozone as modulator of resorption and inflammatory response in extruded nucleus pulposus herniation. Revising concepts. *Int J Mol Sci* 2021;22. doi:10.3390/ijms22189946.
- [10] Bocci VA. Scientific and medical aspects of ozone therapy. State of the art. *Arch Med Res* 2006; 37:425–35. doi:10.1016/j.arcmed.2005.08.006.
- [11] Cakir R. General Aspects of Ozone Therapy. *Pharmacology and Nutritional Intervention in the Treatment of Disease, InTech*; 2014. doi:10.5772/57470.

- [12] Cenci A, Macchia I, la Sorsa V, Sbarigia C, di Donna V, Pietraforte D. Mechanisms of Action of Ozone Therapy in Emerging Viral Diseases: Immunomodulatory Effects and Therapeutic Advantages With Reference to SARS-cov-2. *Front Microbiol* 2022;13. doi:10.3389/fmicb.2022.871645.
- [13] Colombo M, Gallo S, Garofoli A, Poggio C, Arciola CR, Scribante A. Ozone gel in chronic periodontal disease: A randomized clinical trial on the anti-inflammatory effects of ozone application. *Biology (Basel)* 2021;10. doi:10.3390/biology10070625.
- [14] Sharma M, Hudson JB. Ozone gas is an effective and practical antibacterial agent. *Am J Infect Control* 2008;36:559–63. doi:10.1016/j.ajic.2007.10.021.
- [15] Sechi LA, Lezcano I, Nunez N, Espim M, Dupre Á I, Pinna A, et al. Antibacterial activity of ozonized sunflower oil (Oleozone). *J Appl Microbiol* (2000); 90: 279-284. doi:10.1046/j.1365-2672.2001.01235.x
- [16] Predmore A, Sanglay G, Li J, Lee K. Control of human norovirus surrogates in fresh foods by gaseous ozone and a proposed mechanism of inactivation. *Food Microbiol* 2015;50:118-25. doi:10.1016/j.fm.2015.04.004.
- [17] Dubuis ME, Dumont-Leblond N, Laliberté C, Veillette M, Turgeon N, Jean J, et al. Ozone efficacy for the control of airborne viruses: Bacteriophage and norovirus models. *PLoS One* 2020;15.doi:10.1371/journal.pone.0231164.
- [18] Ouf SA, Moussa TA, Abd-Elmegeed AM, Eltahlawy SR. Anti-fungal potential of ozone against some dermatophytes. *Brazil J Microbiol* 2016;47:697–702. doi:10.1016/j.bjm.2016.04.014.
- [19] Morgoglione ME, Bosco A, Ciuca L, Pepe P, Coles GC, Cringoli G, et al. In vitro evaluation of ozonated water treatment on the viability of eimeria oocysts and giardia cysts from water buffaloes: A proof-of-concept study. *Vet Sci* 2021;8. doi:10.3390/vetsci8060115.
- [20] Moore G, Griffith C, Peters A. Bactericidal Properties of Ozone and Its Potential Application as a Terminal Disinfectant. *J Food Prot* 2000 ;63(8):1100-6. doi: 10.4315/0362-028x-63.8.1100.
- [21] Nagayoshi M, Fukuizumi T, Kitamura C, Yano J, Terashita M, Nishihara T. Efficacy of ozone on survival and permeability of oral microorganisms. *Oral Microbiology Immunology* 2004; 19: 240-6.
- [22] Ugazio E, Tullio V, Binello A, Tagliapietra S, Dosio F. Ozonated oils as antimicrobial systems in topical applications. Their characterization, current applications, and advances in improved delivery techniques. *Molecules* 2020;25. doi:10.3390/molecules25020334.
- [23] Sciorsci RL, Lillo E, Occhiogrosso L, Rizzo A. Ozone therapy in veterinary medicine: A review. *Res Vet Sci* 2020;130:240–6. doi:10.1016/j.rvsc.2020.03.026.
- [24] de Sire A, Marotta N, Ferrillo M, Agostini F, Sconza C, Lippi L, et al. Oxygen-Ozone Therapy for Reducing Pro-Inflammatory Cytokines Serum Levels in Musculoskeletal and Temporomandibular Disorders: A Comprehensive Review. *Int J Mol Sci* 2022;23. doi:10.3390/ijms23052528.
- [25] Smith N, Wilson A, Gandhi J, Vatsia S, Khan S. Ozone therapy: An overview of pharmacodynamics, current research, and clinical utility. *Med Gas Res* 2017;7:212–9.

- doi:10.4103/2045-9912.215752.[26] Uysal B, Demirbag S, Poyrazoglu Y, Cayci T, Yesildaglar N, Guven A, et al. Medical ozone therapy decreases postoperative uterine adhesion formation in rats. *Arch Gynecol Obstet* 2012;286:1201–7. doi:10.1007/s00404-012-2435-y.
- [27] Fitzpatrick E, Holland OJ, Vanderlelie JJ. Ozone therapy for the treatment of chronic wounds: A systematic review. *Int Wound J* 2018;15:633–44. doi:10.1111/iwj.12907.
- [28] Xiao W, Tang H, Wu M, Liao Y, Li K, Li L, et al. Ozone oil promotes wound healing by increasing the migration of fibroblasts via PI3K/Akt/mTOR signaling pathway. *Biosci Rep* 2017;37. doi:10.1042/BSR20170658.
- [29] Tartari APS, Moreira FF, Pereira MCDS, Carraro E, Cidral-Filho FJ, Salgado AI, et al. Anti-inflammatory Effect of Ozone Therapy in an Experimental Model of Rheumatoid Arthritis. *Inflammation* 2020;43:985–93. doi:10.1007/s10753-020-01184-2.
- [30] Merhi Z, Garg B, Moseley-Larue R, Moseley A, Smith A, Zhang J. Ozone therapy: A potential therapeutic adjunct for improving female reproductive health. *Med Gas Res* 2019;9:101–5. doi:10.4103/2045-9912.260652.
- [31] Zobel R, Tkalčić S, Štoković I, Pipal I, Buić V. Efficacy of Ozone as a Novel Treatment Option for Urovagina in Dairy Cows. *Reprod Domest Anim* 2012;47:293–8. doi:10.1111/j.1439-0531.2011.01857.x.
- [32] Djuricic D, Vince S, Ablondi M, Dobranic T, Samardzija M. Effect of preventive intrauterine ozone application on reproductive efficiency in Holstein cows. *Reprod Domest Anim* 2012;47:87–91. doi:10.1111/j.1439-0531.2011.01805.x.
- [33] Đuričić D, Valpotić H, Samardžija M. Prophylaxis and therapeutic potential of ozone in buiatrics: Current knowledge. *Anim Reprod Sci* 2015;159:1–7. doi:10.1016/j.anireprosci.2015.05.017.
- [34] Zobel R, Martinec R, Ivanović D, Rošić N, Stančić Z, Žerjavić I, et al. Intrauterine ozone administration for improving fertility rate in cattle. *Vet Arh* 2014;84:1–8.
- [35] Đuričić D, Lipar M, Samardžija M. Ozone treatment of metritis and endometritis in Holstein cows. *Vet Arh* 2014;84:103–10.
- [36] Djuricic D, Valpotic H, Samardzija M. The Intrauterine Treatment of the Retained Foetal Membrane in Dairy Goats by Ozone: Novel Alternative to Antibiotic Therapy. *Reprod Domest Anim* 2015;50:236–9. doi:10.1111/rda.12475.
- [37] Đuričić D, Valpotić H, Žura Žaja I, Samardžija M. Comparison of Intrauterine Antibiotics versus Ozone Medical Use in Sheep with Retained Placenta and Following Obstetric Assistance. *Reprod Domest Anim* 2016;51:538–40. doi:10.1111/rda.12715.
- [38] Djuricic D, Vince S, Ablondi M, Dobranic T, Samardzija M. Intrauterine ozone treatment of retained fetal membrane in Simmental cows. *Anim Reprod Sci* 2012;134:119–24. doi:10.1016/j.anireprosci.2012.08.023.
- [39] Zobel R, Tkalčić S. Efficacy of Ozone and Other Treatment Modalities for Retained Placenta in Dairy Cows. *Reprod Domest Anim* 2013;48:121–5. doi:10.1111/j.1439-0531.2012.02041.x.

- [40] Camargo Ferreira J, Silva Amaral R, Mara Cardoso L, Panelli Marchió S, Aldrovani Rodrigues M, Fonseca Alves CE, et al. Endometrial angiogenesis induced by uterine insufflation with an oxygen–ozone gas mixture in mares. *Reprod Domest Anim* 2021;56:1176–83. doi:10.1111/rda.13958.
- [41] Escandón BM, Espinoza JS, Perea FP, Quito F, Ochoa R, López GE, et al. Intrauterine therapy with ozone reduces subclinical endometritis and improves reproductive performance in postpartum dairy cows managed in pasture-based systems. *Trop Anim Health Prod* 2020;52:2523–8. doi:10.1007/s11250-020-02298-3.
- [42] Carroll CL, Huntington PJ. Body condition scoring and weight estimation of horses. *Equine Vet J* 1988;20:41–5. doi:10.1111/j.2042-3306.1988.tb01451.x.
- [43] Marinone AI, Mucci N, Kaiser G, Losinno L, Armendano J, Rodriguez E, et al. Reproductive Characteristics in Old and Young Subfertile Mares: Are They Really Different? *J Equine Vet Sci* 2017;55:90–6. doi:10.1016/j.jevs.2017.02.012.
- [44] Hayes KEN, Ginther OJ. Role of progesterone and estrogen in development of uterine tone in mares. *Theriogenology* 1986;25(4):581-90. doi: 10.1016/0093-691x(86)90142-1.[45] Cocchia N, Paciello O, Auletta L, Uccello V, Silvestro L, Mallardo K, et al. Comparison of the cytobrush, cottonswab, and low-volume uterine flush techniques to evaluate endometrial cytology for diagnosing endometritis in chronically infertile mares. *Theriogenology* 2012;77:89–98. doi:10.1016/j.theriogenology.2011.07.020.
- [46] Riddle WT, LeBlanc MM, Stromberg AJ. Relationships between uterine culture, cytology and pregnancy rates in a Thoroughbred practice. *Theriogenology* 2007;68:395–402. doi:10.1016/j.theriogenology.2007.05.050.
- [47] Kenney RM, Doig PA. Equine endometrial biopsy. In: Morrow DA, editor. *Current Therapy in Theriogenology*, Philadelphia: Saunders WB; 1986, p. 723–9.
- [48] Ferris RA, Bohn A, Mccue PM. Equine endometrial cytology: Collection techniques and interpretation. *Equine Vet Educ* 2015;27:316–22. doi:10.1111/eve.12280.
- [49] McKinnon AO, Squires EL, Harrison LA, Blach EL, Shideler RK. Ultrasonographic studies on the reproductive tract of mares after parturition: effect of involution and uterine fluid on pregnancy rates in mares with normal and delayed first postpartum ovulatory cycles. *J Am Vet Med Assoc.* 1988 Feb 1;192(3):350-3.
- [50] Canisso IF, Segabinazzi LGTM, Fedorka CE. Persistent breeding-induced endometritis in mares - a multifaceted challenge: From clinical aspects to immunopathogenesis and pathobiology. *Int J Mol Sci* 2020;21. doi:10.3390/ijms21041432.
- [51] Rebordão MR, Galvão A, Szóstek A, Amaral A, Mateus L, Skarzynski DJ, et al. Physiopathologic mechanisms involved in mare endometrosis. *Reprod Domest Anim* 2014;49:82–7. doi:10.1111/rda.12397.
- [52] Schöniger S, Schoon HA. The healthy and diseased equine endometrium: A review of morphological features and molecular analyses. *Animals* 2020;10. doi:10.3390/ani10040625.
- [53] Rua MAS, Quirino CR, Ribeiro RB, Carvalho ECQ, Bernadino M de LA, Bartholazzi Junior A, et al. Diagnostic methods to detect uterus illnesses in mares. *Theriogenology* 2018;114:285–92. doi:10.1016/j.theriogenology.2018.03.042.

- [54] Davies Morel MCG, Lawlor O, Nash DM. Equine endometrial cytology and bacteriology: Effectiveness for predicting live foaling rates. *Vet J* 2013;198:206–11. doi:10.1016/j.tvjl.2013.08.002.
- [55] Snider TA, Sepoy C, Holyoak GR. Equine endometrial biopsy reviewed: Observation, interpretation, and application of histopathologic data. *Theriogenology* 2011;75:1567–81. doi:10.1016/j.theriogenology.2010.12.013.
- [56] Causey RC. Making sense of equine uterine infections: The many faces of physical clearance. *Veterinary Journal* 2006;172:405–21. doi:10.1016/j.tvjl.2005.08.005.
- [57] Díaz - bertrana ML, Deleuze S, Rios LP, Yeste M, Fariña IM, del Alamo MMR. Microbial prevalence and antimicrobial sensitivity in equine endometritis in field conditions. *Animals* 2021;11. doi:10.3390/ani11051476.
- [58] Diel de Amorim M, Gartley CJ, Hill A, Scholtz EL, Chenier TS, Foster RA, et al. Comparison of Clinical Signs, Endometrial Culture, Endometrial Cytology, Uterine Low-Volume Lavage, and Uterine Biopsy and Combinations in the Diagnosis of Equine Endometritis. *J Equine Vet Sci* 2016;44:54–61. doi:10.1016/j.jevs.2015.10.012.
- [59] Epelle EI, Macfarlane A, Cusack M, Burns A, Amaeze N, Richardson K, et al. Stabilisation of Ozone in Water for Microbial Disinfection. *Environments - MDPI* 2022;9. doi:10.3390/environments9040045.
- [60] Hirahara Y, Iwata K, Nakamuro K. Effect of Citric Acid on Prolonging the Half-life of Dissolved Ozone in Water. *Food Safety* 2019;7:90–4. doi:10.14252/foodsafetyfscj.d-19-00005.
- [61] Ferreira JC, Pires RH, Costa GB da, Carrijo BN, Guiotto FG, Rodrigues VS. The In Vitro Effect of Ozone Therapy Against Equine *Pythium insidiosum*. *J Equine Vet Sci* 2021;98. doi:10.1016/j.jevs.2020.103305.
- [62] Ávila ACA, Diniz NC, Serpa RT, Chaves MMB de C, Viu MA de O, de Oliveira RA. Effectiveness of Ozone Therapy in The Treatment of Endometritis in Mares. *J Equine Vet Sci* 2022;112. doi:10.1016/j.jevs.2022.103900.
- [63] Roth A, Maruthamuthu MK, Nejati S, Krishnakumar A, Selvamani V, Sedaghat S, et al. Wearable adjunct ozone and antibiotic therapy system for treatment of Gram-negative dermal bacterial infection. *Sci Rep* 2022;12. doi:10.1038/s41598-022-17495-3.
- [64] Mouncey R, Arango-Sabogal JC, de Mestre A, Verheyen K. Descriptive Study of Medication Usage and Occurrence of Disease and Injury During Gestation in Thoroughbred Broodmares. *J Equine Vet Sci* 2022;118:104104. doi:10.1016/j.jevs.2022.104104.
- [65] Calderon I, Cohen M, Sagi-Dain L, Artzi O, Bejar J, Sagi S. The effect of ozonated sterile saline irrigation on the endometrium – A preliminary study. *J Obstet Gynaecol (Lahore)* 2016;36:635–40. doi:10.3109/01443615.2015.1133579.
- [66] Ferreira JC, Canesin HS, Ignácio FS, Rocha NS, Pinto CR, Meira C. Effect of age and endometrial degenerative changes on uterine blood flow during early gestation in mares. *Theriogenology* 2015;84:1123–30. doi:10.1016/j.theriogenology.2015.06.013.

- [67] Almeida BFM de, Amatti LZ, de Souza GG, Garcia LV, Montechiesi DF, Ignácio FS, et al. Effect of uterine ozone therapy and anticoagulant sampling on oxidative stress parameters in mares. *Res Vet Sci* 2021;136:503–11. doi:10.1016/j.rvsc.2021.04.002.
- [68] Clavo B, Rodríguez-Esparragón F, Rodríguez-Abreu D, Martínez-Sánchez G, Llontop P, Aguiar-Bujanda D, et al. Modulation of oxidative stress by ozone therapy in the prevention and treatment of chemotherapy-induced toxicity: Review and prospects. *Antioxidants* 2019;8. doi:10.3390/antiox8120588.
- [69] Abdelnaby EA, Emam IA, Salem NY, Ramadan ES, Khattab MS, Farghali HA, et al. Uterine hemodynamic patterns, oxidative stress, and chromoendoscopy in mares with endometritis. *Theriogenology* 2020;158:112–20. doi:10.1016/j.theriogenology.2020.09.012.
- [70] Mazzuchini MP, Garrido L, Segabinazzi TM, Tongu EA, Tiemi C, Okada C, et al. Safety of uterine lavage with ozonated saline in mares (Segurança da lavagem uterina com solução salina ozonizada em éguas). *Arch Vet Sci* 2022; 27:88-104.
- [71] Troedsson MHT, Loset K, Alghamdi AM, Dahms B, Crabo BG. Interaction between equine semen and the endometrium: The inflammatory response to semen. *Anim Reprod Sci* 2001;68:273–8. doi:10.1016/S0378-4320(01)00164-6.
- [72] Ferrer MS, Lyle SK, Paccamonti DL, Eilts BE, Hosgood G, Godke RA. Persistent breeding-induced endometritis after hysteroscopic insemination in the mare. *ReprodDomest Anim* 2012;47:732–9. doi:10.1111/j.1439-0531.2011.01951.x.
- [73] Campbell MLH, Hampshire D, Hamstead LE, Rose B v., Smith KC, de Mestre AM. The effects of intrauterine infusion of peanut oil on endometrial health, salivary cortisol and interovulatory period in mares. *Theriogenology* 2017;102:116–25. doi:10.1016/j.theriogenology.2017.07.009.
- [74] Olsen L, Al-Bagdadi F, Richardson G, Archbald L, Braun W, McCoy D, et al. A histological study of the effect of saline and povidone-iodine infusion on the equine endometrium. *Theriogenology* 1992;37:1311-25. doi:10.1016/0093-691X(92)90186-U.
- [75] Rodriguez JS, Han S, Nielsen S, Pearson LK, Gay JM, Tibary A. Consequences of Intrauterine Enrofloxacin Infusion on Mare Endometrium. *J Equine Vet Sci* 2012;32:106–11. doi:10.1016/j.jevs.2011.08.003.
- [76] Allen WR, Brown L, Wright M, Wilsher S. Reproductive efficiency of Flatrace and National Hunt Thoroughbred mares and stallions in England. *Equine Vet J* 2007;39:438–45. doi:10.2746/042516407X1737581.
- [77] Malaluang P, Wilén E, Lindahl J, Hansson I, Morrell JM. Antimicrobial resistance in equine reproduction. *Animals* 2021;11. doi:10.3390/ani11113035.