

ORIGINAL COMMUNICATION

Leg Perforators and Leg Length: An Anatomic Study Focusing on Topography and Angiogenesis[†]

FILIPPO BORIANI,^{1*} STEFANO BRUSCHI,¹ MARCO FRACCALVIERI,¹
AND RICCARDO CIPRIANI²

¹Department of Plastic Reconstructive and Aesthetic Surgery, University of Turin, Italy

²Department of Plastic Reconstructive and Aesthetic Surgery, University of Bologna-S
Orsola-Malpighi Hospital, Bologna, Italy

The highly variable anatomic distribution of lower leg perforators is explored, with a standardization based on leg length. The possibility of a correlation between leg length and number of perforators is investigated. Twenty-two lower limbs of cadavers were utilized for an anatomic study on the leg perforators branching from the three major vascular axes, anterior tibial, posterior tibial, and fibular. The parameters considered were the number of vascular pedicles per each major axis, the caliber, the distance of the fascial hole from the bony landmark (knee joint line), and the route of the vessels (muscular, septal). Arteries taken into account had a caliber of 0.5 mm or greater, with a maximum of 1.7 and a mean of 0.78. The perforators of the anterior tibial artery distribute along the entire length of the leg, but the peak of concentration is between second and third tenth and around the middle tenth. The fibular system provides perforators between the fourth and seventh tenth. The posterior tibial perforators concentrate to the middle third and to the supra-malleolar region. A correlation exists between leg length and number of perforating vessels for the tibial vascular systems, possibly due to neoangiogenesis during growth, at the level of the metaphyseal plates. On the contrary no relationship was noticed for the fibular artery, whose perforators concentrate far from the growth cartilages. Some tenths where perforators concentrate are identifiable. Tibial systems have a perforator incidence depending on leg length, which, on the contrary, does not influence the number of fibular perforators. Clin. Anat. 23:593–605, 2010. © 2010 Wiley-Liss, Inc.

Key words: leg vascular system; perforator flap; propeller flap; leg growth

INTRODUCTION

Several anatomic studies have described the perforator vessels of the leg district, illustrating a widely variable topography of the reliable perforators. Although the Doppler flowmetry or more complex methods can be utilized to define the position of perforators, a map of the biggest (at least 0.5 mm) and most consistent arteries can be useful to plan the reconstructive options. Among the various studies, a recent anatomic research by Schaverien and Saint-Cyr (2008) mapped the perforators of the leg without standardizing the distances of the arteries toward the various lengths of the legs. In the current study, the anatomic distribution of perforators is

described, with a standardization based on limb length. The possibility of a correlation between leg length and number of perforators was previously assumed by Boriani and Bogetti (2009). Aim of this

[†]Presented at the 23rd Conference of the Italian Society for Microsurgery, Modena, Italy, 1 October 2009.

*Correspondence to: Filippo Boriani, Viale A. Aldini, 23, 40136 Bologna, Italy. E-mail: filohorse@yahoo.it

Received 28 July 2009; Revised 4 February 2010; Accepted 1 March 2010

Published online 7 April 2010 in Wiley InterScience (www.interscience.wiley.com). DOI 10.1002/ca.20981

study was to investigate the verisimilitude of this assumption through anatomic research, in addition to localizing perforator arteries of the leg, relatively to its length.

MATERIALS AND METHODS

Twenty-two legs of 11 fresh cadavers were utilized for an anatomic study on the perforator vessels of the three major vascular axes, anterior tibial, posterior tibial, and fibular. The anatomical part considered was the lower leg between the knee joint line and malleoli. Time elapsed after death was 4 or 5 days as a maximum. All legs did not present any scar tissue. Dissections were all carried out by a single investigator (first author) at the Institute of Anatomy, University of Nice Sophia-Antipolis, France. Three standard incisions were utilized to expose the perforators in the three vascular systems. For the anterior tibial perforators the incision line was between the anterior margin of the fibular head and the middle point of the intermalleolar line. The pedicles of the fibular artery were approached through an incision going from the posterior margin of the fibular head and the posterior margin of the lateral malleolus. The posterior tibial system was reached through an incision line running along the posterior margin of the tibia. Immediately after the incision of dermis, the dissection of deeper layers was systematically blunt, which avoided damage of the perforating vessels. The depth of dissection at which initially the perforators were sought was the crural fascia.

From the fascial perforation, an accurate dissection of the perforating pedicles was systematically carried out both to vascular origin from the source vessel and to the surface. Vascular branches between the fascial emergence and the skin were visually followed. All phases of dissection were implemented under 2.5 \times magnification.

On the found vessels, the following parameters were taken into account: number of vessels for each major axis, caliber, distance of the fascial hole from the bony landmark (knee joint line), route of the vessels (muscular, septal).

RESULTS

Of the eleven utilized fresh cadavers, seven were men and four women. Mean age was 86.5 with a maximum of 105 and a minimum of 65. Mean leg length, measured from the knee joint line down to malleoli was 37.2 cm, with a maximum of 40 and a minimum of 32.

On a total of 22 legs, 289 perforators vascular pedicles were found and dissected, which consisted of an artery and two venae comitantes. Of the three vascular systems, 107 found pedicles belonged to the anterior tibial system, 91 to the fibular system, and 91 to the posterior tibial.

Arteries taken into account had a caliber of 0.5 mm or greater, with a maximum of 1.7 and a mean of 0.78.

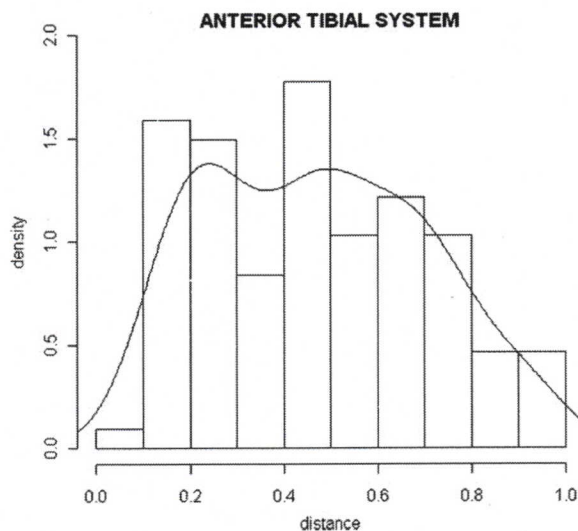


Fig. 1. Distribution of density observed (histogram of frequencies normalized to unitary area) and estimated (continuous diagram) for the anterior tibial perforator vascular system in the leg divided in tenths from the knee (0) to the intermalleolar line (1).

Of the perforator pedicles found, 61/289 (21%) were myocutaneous and 228/289 (79%) were septocutaneous.

Vascular Mapping

Perforator positioning was referred to the knee joint line, considered as the landmark. The anatomic distribution of the perforator arteries was standardized toward the various leg lengths. Considered as one the mean distance from the knee down to malleoli, vessel position was approximated to intervals of one tenth.

Anterior Tibial Vascular System

The anterior compartment of the leg depends on the anterior tibial vascular system, consisting of 6.3 perforator pedicles as average per leg, with a minimum of 1 and a maximum of 8. All arteries of the anterior tibial system are septocutaneous. Vessels run between tibia and tibialis anterior in 11% of cases (12/107), between tibialis anterior and extensor digitorum longus in 14% (15/107) of cases whereas 75% of perforators emerge between extensores and fibulares muscles (anterior intermuscular septum). Distally some 2% (2/107) intertendineous pedicles are present between extensor digitorum longus and extensor hallucis longus. Mean arterial caliber is 0.75 mm with a maximum of 1.6. The distribution of vascular pedicles along the anterior tibial axis is described in Figure 1, where a peak of concentration in the upper third is visible, precisely between the beginning of the second tenth and the end of the third. A further maximal peak of density is

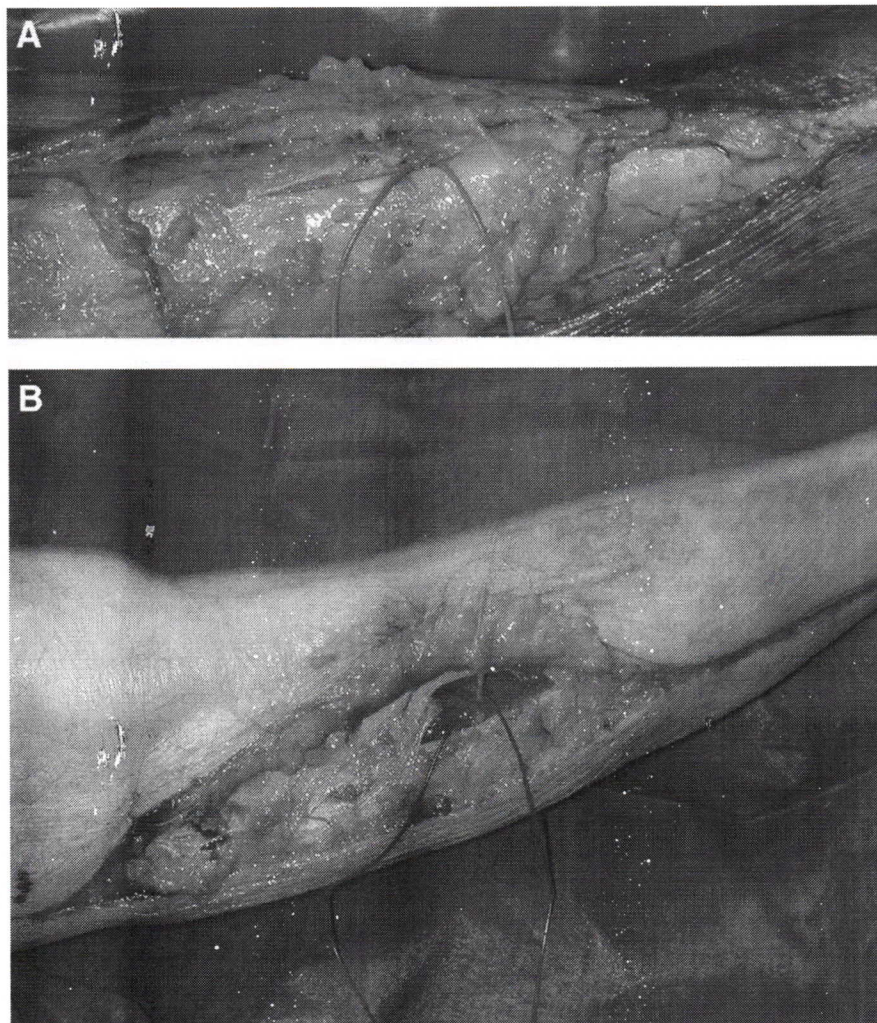


Fig. 2. **A:** Perforator pedicle of the anterior tibial system, running between tibia and tibialis anterior (Septum 1). **B:** Perforator pedicle of the anterior tibial system, running between tibialis anterior and extensor digitorum longus (Septum 2). [Color figure can be viewed in the online issue, which is available at www.interscience.wiley.com.]

present in the middle tenth. Two examples of perforators of each Septum 1 and 2 are shown in Figure 2A and 2B.

Neurovascular Pattern of the Middle Perforators of the Anterior Tibial System and Superficial Fibular (Peroneal) Nerve

A recurrent vascular pattern in the web of anterior tibial perforators was noted in the middle third. Here the superficial fibular (peroneal) nerve appears frequently associated to two or three perforators branching from a common trunk vascularizing the nerve, the superficial peroneal nerve accessory

artery (SPNAA). These branches are usually identified as the third, fourth, fifth, and sixth perforator in a cranial-caudal direction. In nine cadavers out of eleven, a confluence of two to three perforators emerging from the septum between extensor digitorum longus and fibulares (peronei) muscles form a vascular pedicle (superficial peroneal nerve accessory vessels). This pedicle connects to the anterior tibial system through the superior lateral peroneal vessels (Fig. 3A and 3B). Not many in the literature (Morrison and Shen, 1987; Coskunfirat and Ozgenas, 2001; Kim et al., 2008) are the previous descriptions of this neurovascular structure dependent on the anterior tibial artery. The pattern is so frequent that it can be codified as a neurovascular

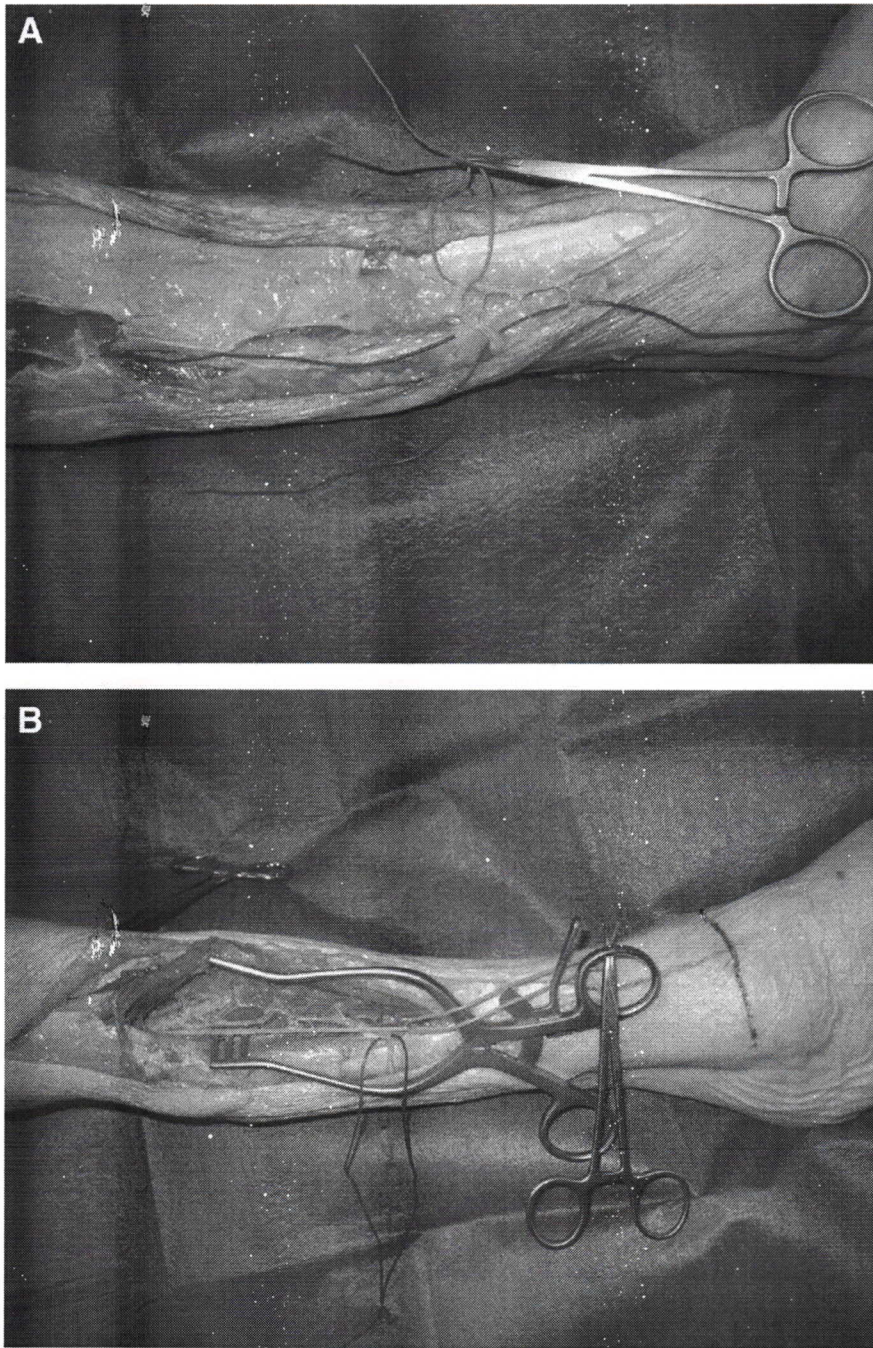


Fig. 3. A,B: Superficial fibular (peroneal) nerve identified at the level of fascial penetration with a blue string (A) together with the system of perforators branching from the superficial fibular (peroneal) neurovascular pedicle (*vasa nervorum*) identified with a red string and running in the sulcus between fibulares

(peronei) and extensor digitorum longus (Septum 3). Complete dissection of the neurovascular axis and its exposition up to the origin of the anterior tibial system through retraction of the muscles (B). [Color figure can be viewed in the online issue, which is available at www.interscience.wiley.com.]

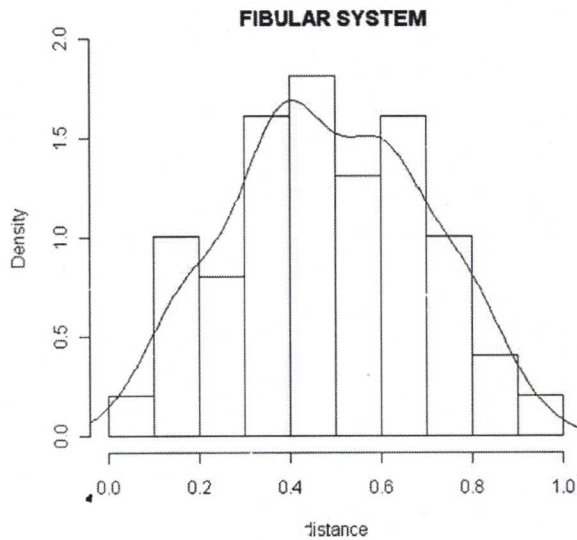


Fig. 4. Distribution of density observed (histogram of frequencies normalized to unitary area) and estimated (continuous diagram) for the perforators of the fibular vascular system in the leg divided in tenths from the knee (0) to the intermalleolar line (1).

pedicle adequate for sensate flaps such as sural or saphenous, according to descriptions of Masquelet et al. (1992) and Hasegawa et al. (1994). The sensi-

tive deficits resulting from the harvest of this flap are described as exiguous and more or less reversible. The superficial fibular (peroneal) nerve, running in the septum between extensor digitorum longus and fibulares muscles, comes from the common fibular (peroneal) nerve (L4, L5, S1, S2) and provides sensate cutaneous innervation to the lower two thirds of the leg and to the dorsal aspect of the foot. This neurovascular structure was not found in two thin and short bodies, presenting a count of perforating pedicles exceptionally low.

Fibular Vascular System

The posterior lateral district of the leg depends on the fibular system, consisting of an average of 3.7 perforating pedicles, with a minimum of 2 and a maximum of 6 per leg. Vessels emerge from the depth running through the soleus muscles in 38% of cases (35/91 pedicles), whereas the 62% (56/91 pedicles) of perforators emerge between the muscles of the posterior compartment (soleus and gastrocnemius) and fibulares muscles (posterior intermuscular septum). The mean caliber of the arteries is 0.84 mm with a maximum of 1.3.

The distribution of vascular pedicles along the fibular axis is illustrated in Figure 4, where a peak of density is observed in the middle third, precisely between the beginning of the fourth and the end of the seventh tenth. An example of fibular perforator is shown in Figure 5.

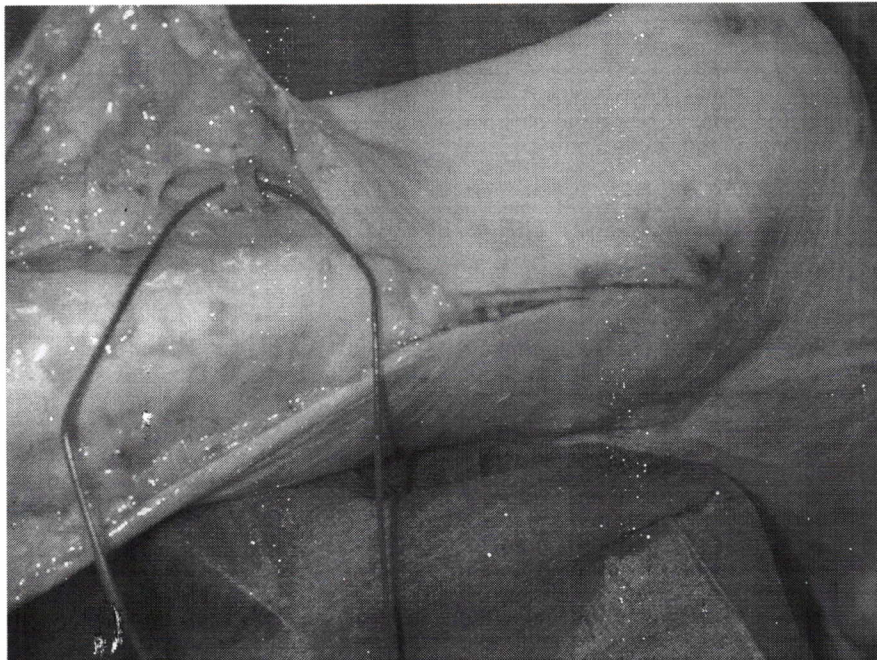


Fig. 5. Perforator pedicle of the fibular system between soleus and fibulares (peronei; Septum 4). [Color figure can be viewed in the online issue, which is available at www.interscience.wiley.com.]

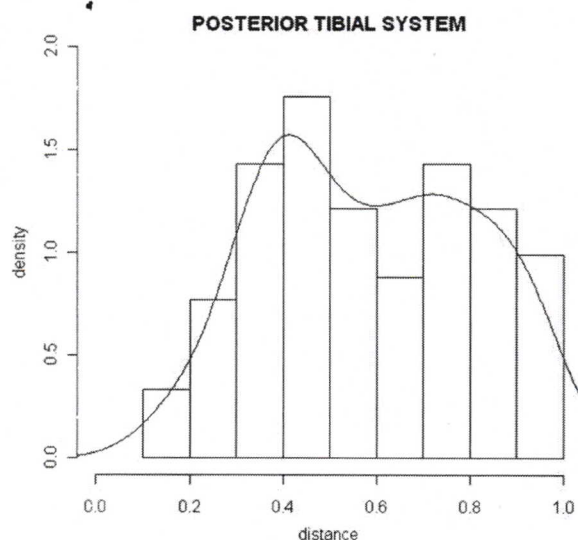


Fig. 6. Distribution of density observed (histogram of frequencies normalized to unitary area) and estimated (continuous diagram), for the perforators of the posterior tibial vascular system in the leg divided in tenths from the knee (0) to the intermalleolar line (1).

Posterior Tibial Vascular System

The medial cutaneous district of the leg relies on the posterior tibial system, presenting 4.1 perforator pedicles as a mean count, with a minimum of 1 and a maximum of 8 per leg.

Vessels come out from the depth between tibia and flexor digitorum longus muscle in 12% of cases. Sixty-four percent of perforators emerge between soleus and flexor digitorum longus (69/91 the total of septo-cutaneous arteries). Twenty-two perforators out of 91 (24%) emerge through the soleus muscle. The perforator pedicles of the posterior tibial system are typically distributed according to two lines: anterior (54/91 pedicles, corresponding to 59%) and posterior (35/91 pedicles, corresponding to 41%). The mean caliber of arteries is 0.82 mm, with a maximum of 1.7.

The distribution of vascular pedicles along the posterior tibial axis is shown in Figure 6, where a maximal peak of density is present between upper and middle third, precisely between the beginning of the fourth tenth and the end of the sixth. A further peak is present at the lower third, particularly at the eighth tenth, therefore in the supramalleolar area. This site corresponds to the exposed portion of the posterior tibial pedicle, which is there covered only by skin, subcutaneous tissue, and fascia. An example of a perforator is shown in Figure 7.

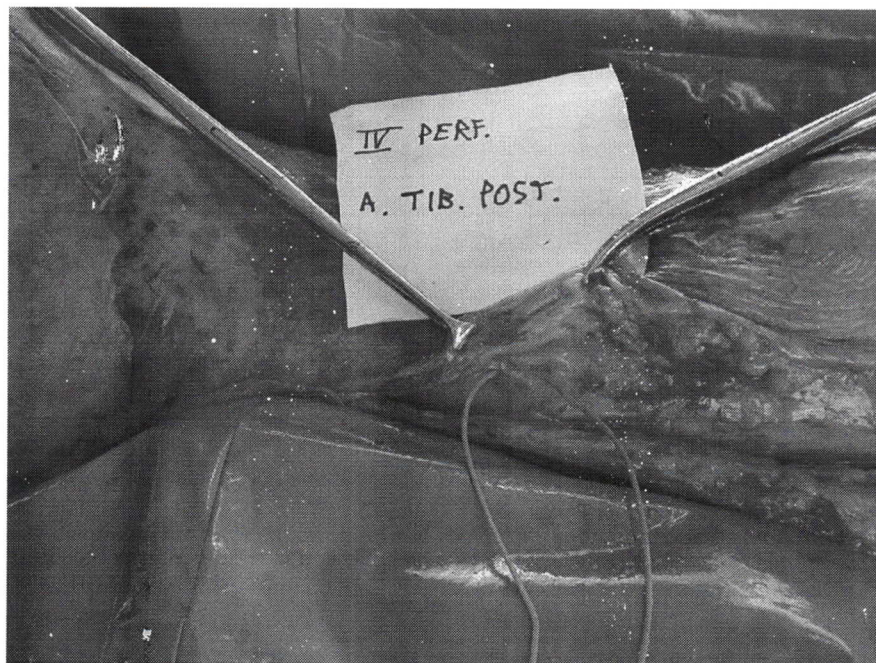


Fig. 7. Perforator pedicle of the posterior tibial system between soleus and flexor digitorum longus (Septum 5). [Color figure can be viewed in the online issue, which is available at www.interscience.wiley.com.]

Analysis of Correlation Between Number of Perforators and Length of Right Leg

As anticipated by Boriani and Bogetti (2009), a relationship was explored between the variable leg length, considered as the predictor and the number of perforators, considered as the outcome. A single leg was adopted for the study, to avoid the obvious concordances existing between the two legs of a single individual, which would have biased the results. In Figures 8–10 the correlation between the number of perforators and the length of the right leg is displayed, for each of the 11 cadavers.

Through a graphical statistical elaboration, a regression line was obtained, synthesizing the pattern of relation between the two variables, for each vascular perforator system. This preliminary descriptive analysis apparently shows an increasing trend of the outcome as a function of the predictor, for the observed data. A possible statistical model was sought to exactly verify the hypothesis of correlation between the two variables. To this aim, a generalized linear Poisson's modeling was utilized. This modeling, generalizing the standard linear regression in which a Gaussian continuous outcome is assumed, is adequate in case of a discrete outcome Y, representing a count datum. In such cases, a Poisson's distribution (P) of outcome is hypothesized with an unknown leg length (λ), i.e.:

$$P(Y = k) = \exp(-\lambda)\lambda^k/k! \quad k = 0, 1, 2, \dots, \dots, \dots$$

Through the standard approach of verification based on a test of hypothesis, the statistic significance of the leg length as a predictor in the aforementioned Poisson's model was verified. As an

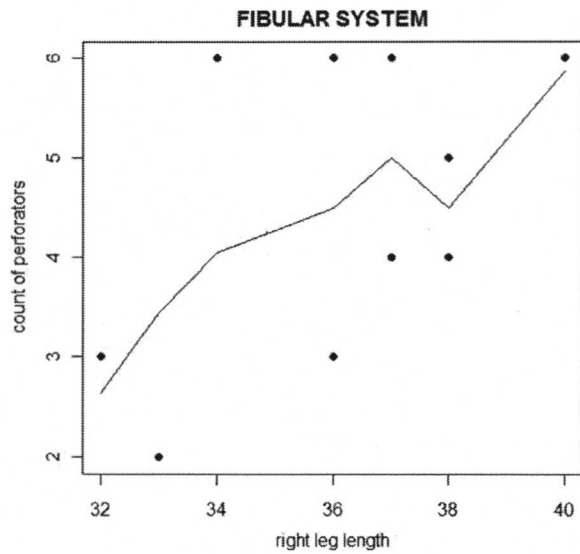


Fig. 9. Fibular system: number of perforators as a function of the right leg length in centimeters, in the examined cadaver population.

empiric rule, a test shows a stronger or less strong evidence of correlation in case of P-value smaller than the sentinel level 0.05 or 0.1, respectively. In case of P-value greater than 0.1, no statistic significance of correlation exists between the variables leg length and count of perforators.

The results obtained from the analysis of the P-value in the chosen modeling follow:

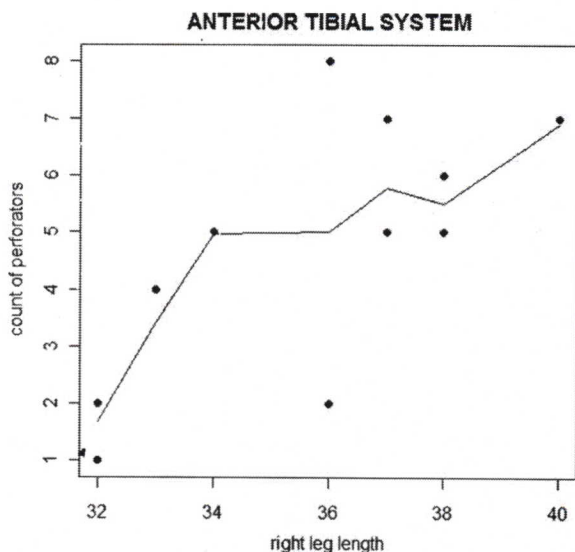


Fig. 8. Anterior tibial system: number of perforators as a function of the right leg length in centimeters, in the examined cadaver population.

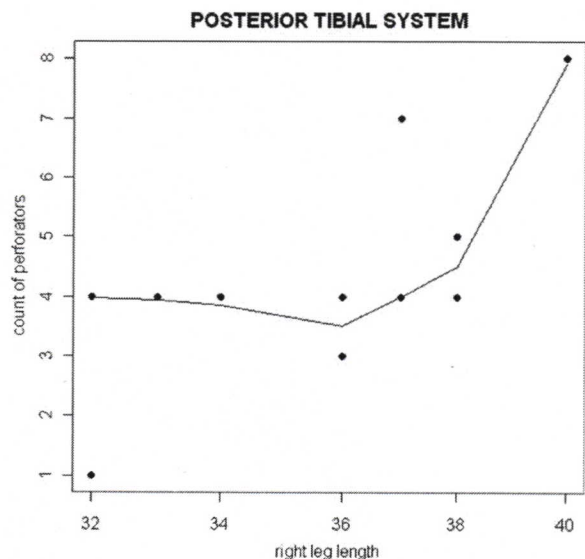


Fig. 10. Posterior tibial system: number of perforators as a function of the right leg length in centimeters, in the examined cadaver population.

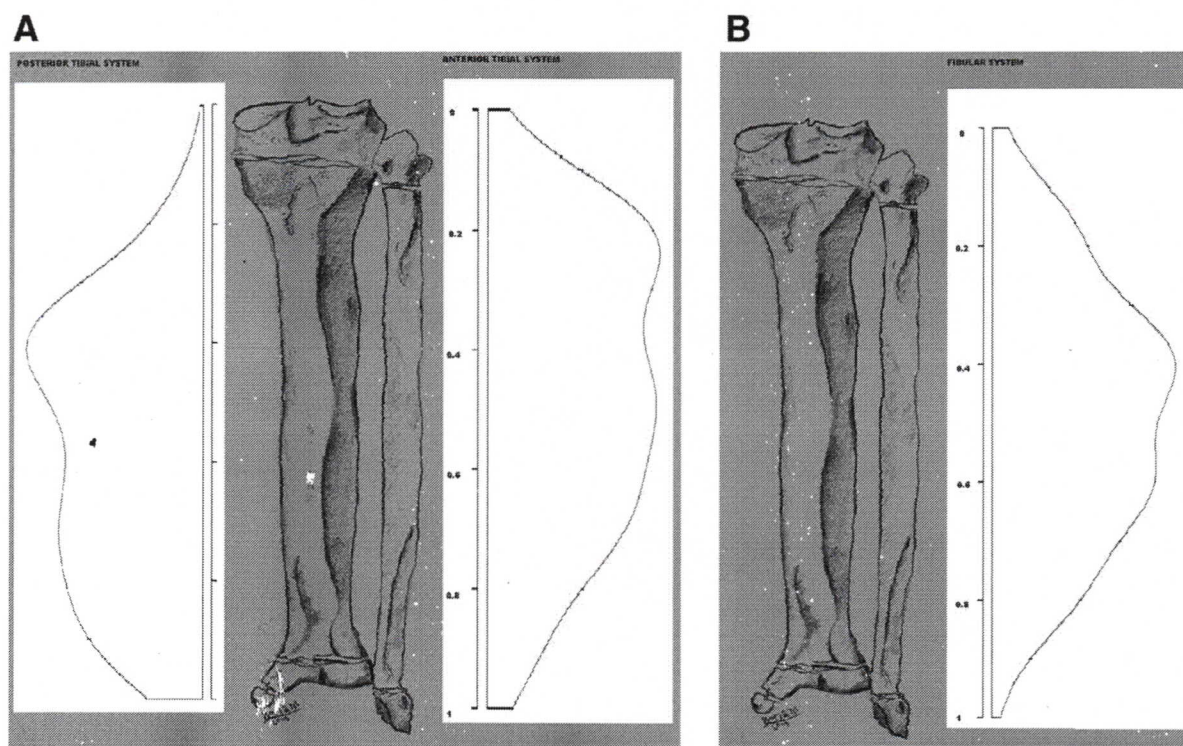


Fig. 11. A,B: Correlation between leg length and number of perforators only exists for the two tibial systems, which are anatomically related to the growth plates.

Anterior tibial system $P = 0.0218 < 0.05$ therefore statistically significant strong evidence of correlation between the two variables leg length and count of perforators.

Fibular system $P = 0.278 > 0.1$ therefore no statistically significant evidence of correlation between the two variables.

Posterior tibial system $P = 0.0531 < 0.1$ therefore statistically significant moderate evidence of correlation between the two variables.

The interpretation of these results could be related to the bioosseous growth of the leg as hypothesized by Boriani and Bogetti (2009). In fact the stretching of soft tissues associated to metaphysis plate might stimulate angiogenesis, thereby increasing the number of perforators situated in correspondence of that growth structure. In the tibial bone the contributions to osseous elongation deriving from the two cartilages are similar: 60% from the proximal cartilage (close to the knee) and 40% from the distal cartilage (close to the ankle).

Instead, with regard to the fibular artery, no correlation between leg length and count of perforators was verified (Fig. 11A and 11B). This finding could be interpreted according to the theory just presented. Being fibular perforators mainly generated in the middle third of the leg, which does not obviously participate to leg growth, their number may well be

unrelated to leg length, differently from the other two vascular systems.

DISCUSSION

As stated by Luiz Vasconez (1997), the discipline of reconstructive surgery is based on anatomy. The anatomic clarification of the leg intermuscular septa and of the arteries occupying them, allows us to plan reconstructions through perforator flaps. From the current study, data emerge which confirm what has been previously discovered regarding the three axial vascular systems of the leg (Tables 1–3).

As previously observed by Taylor and Pan (1998), the most important datum on the localization of the leg perforating pedicles is the relevant anatomic variability, emerging from the comparison of the various researches. Nevertheless some constant clusters are present in all three systems and should be kept in mind when planning perforator flaps (Fig. 11A and 11B).

As more numerous the perforators are in a certain area as smaller is the potential vascular territory belonging to each one. The number of perforators correlates with leg length in the two tibial systems and is instead completely independent in the fibular territory. The clinical-surgical implication of this phenomenon is that with increasing leg lengths and obviously increasing numbers of tibial perforators, safety of a

TABLE 1. Comparison of Topographic Studies on the Anterior Tibial Vascular System

Study (No. of cadavers)	No. of perforators of the anterior tibial system	Mean No. per Septum 1, 2, 3 according to Whetzel			Mean Caliber (mm)	Localization (tenths of leg)
Current study (11)	6.3 (1-8)	2.5	0.8	3.5	0.75	2nd-3rd, 5th and 7th; Septum 3: 2nd-3rd, 5th, 8th-9th; Septum 2: peak at 2nd-3rd; Septum 1: peak at 2nd
Schaverien et al (2008) (20) ²⁷	9.9	5.4	2.1	4.6	0.5-1	Between 2nd and end 8 th -9th Septum 3: 3rd-4th and 9th-10th Septum 2: 3rd-4th Septum 1: 2 ^o and 8th
Whetzel et al. (1997)(15) ⁵	9.8	3.9	1.1	4.7	0.5-1	1st-3rd 5th 7th-8th; Septum 3: all tenths with a peak between 7th and 9th; Septum 1: all tenths with a peak between 1st and 2nd; Septum 2nd: 1st-5th and 9th-10th
Taylor and Pan (1998) (6) ³⁶	6.2	2.5	2	1.5	0.81	
Carrquiry et al (1985) (20) ⁸	8				0.3-0.8	1st-3rd (Septum2) 5th-9th (Septum 3)
Kim (2008) (16) ³⁰	7.5 (of which 4.5 branches from SPNAA)				0.85	Between 2nd and 3rd and 4th (from the SPNAA) and 6th-7th and 8th

single perforator-based flap proportionally decreases. For example the reconstruction of a half leg-long defect with a single perforator-based flap, will rely on fewer vascular territories in a shorter leg (which has less numerous perforators), than in a longer leg, in which the same defect (in terms of proportion to the whole leg) will have to be reconstructed with more numerous vascular territories.

Five or six anterior tibial vascular pedicles emerge from the axial vessels along all the leg length, from the knee down to the lateral ankle. However there is a density peak at the second-third tenths, with contributions from vessels traveling along all three septa, and another distal peak at the fifth tenth. The septum most populated by perforators is Septum 3 in the current research, coherently with Whetzel et al. (1997). In opposition to this, according to Schaverien and Saint-Cyr (2008) and Taylor and Pan (1998), the septum richest of perforators is the first,

that of the tibial periosteal system, where the two tibial systems anastomose. For the anterior tibial system, the table shows that the anatomic-topographical data obtained in the current research agree with the previous studies, including the one by Carrquiry et al. (1985), which has the highest cadaver incidence. The absence of myocutaneous arteries in the anterior tibial compartment is in agreement with Taylor and Pan (1998).

In the fibular system, an average figure of four perforators emerge at the middle third level, with a peak between proximal and middle third and another one between middle third and distal third.

In terms of tenths, the area of highest localization is between fourth and seventh tenth. The pedicles are mainly situated in correspondence of Whetzel's Septum 4, i.e., between flexor hallucis longus (proximally) or soleus (distally) and fibulares (peronei). However some perforators have a variable intramus-

TABLE 2. Comparison of Topographic Studies on the Fibular Vascular System

Study (No. of cadavers)	No. of perforators of the fibular system	Mean caliber (mm)	Localization (tenths of leg)
Current study (11)	3.7 (2-6)	0.84	4 ^o -7 ^o
Schaverien et al. (2008) (10) ²⁷	4.4	0.5	6 ^o e 7 ^o
Yoshimura et al. (1990) (40) ¹⁴	4.8	0.6	4th-8th with peak at 8th
Wolff (1993) (50) ¹⁵	4.2	0.9 (0.6-1.2)	7th-8th
Schustermann et al. (1992) (40) ¹⁶	3.7		4th-9th with peak at 8th-9th
Ozalp et al. (2006) (4) ¹⁷	4-7	0.8-1.1	Inconstant anatomy
Beppu et al. (1992) (35) ¹⁸	4.8	1 (0.5-1.5)	Between half 5th and half 6th
Heitmann et al. (2003) (10) ¹⁹	4.8	0.6	Between 4th and 6th-7th
Whetzel et al. (1997) (15) ⁵	4.8	0.5-1.5	Between 6th and 9th with peak at 7th
Taylor and Pan (1998) (6) ³⁶	4.83	1.03	
Carrquiry et al. (1985) (20) ⁸	4 (3-5)	0.4-1.3	Inconstant
Chō et al. (2001) (12) ³⁹	3.58		4th-6th
Wong et al. (2007) (10) ³⁷		1.1 (0.8-1.5)	5th-7th
Fu Chan-Wei et al. (1986) (10) ³⁸	3.5 (1-4)	0.8-1.7	Between 6th and 9th with peak at 7th

TABLE 3. Comparison of Topographic Studies on the Posterior Tibial Vascular System

Study (No. of cadavers)	Mean No. of perforators of the posterior tibial system	Septum 5, 6, or myocutaneous			Caliber (mm)	Localization (tenths of leg)
Current study (11)	4.1 (1.8)	2.5	0.5	0.8	0.82	4th–6th and 8th–9th; Septum 5: 5th and 8th; Myocutaneous (soleus): 4th–5th, 9th; Septum 6: 4th
Schaverien et al. (2008) (10) ²⁷	4.9				1–1.5	Between 4th and half 5th; Between 6th and begin 7th; Between 8th and 9th
Carriquiry et al. (1985) (20) ⁸	4–5				0.5–1.5	4 ^o ; End 5th–beginning 6th; End 7th–half 8th
Wu et al. (1993) (10) ⁹	2–5				1–1.5	End 6th–end 8th
Liu et al. (1990) (18) ¹⁰	3.3					7th–9th
Satoh et al. (1990) (10) ¹¹						Half 5th–half 9th
Koshima et al. (1992) (12) ⁴⁰	3.1				0.8	7th–9th
Hung et al. (1996) (10) ¹²	5–8				1.5	5th–7th
Amarante et al. (1986) (10) ¹³						Half 8th–half 9th; Half 9th–half 10th
Whetzel et al. (1997) (15) ⁵	5.4 (3–8)	3.2	2.1		0.5–1	5th–10th (Septum 5); 2nd–5th (Septum 6)
Ozdemir et al. (2006) (11) ⁷	6				0.6–1	5th–6th
Tanaka et al. (2006) (10) ²	2.3 (1–4)				0.9	6th–10th

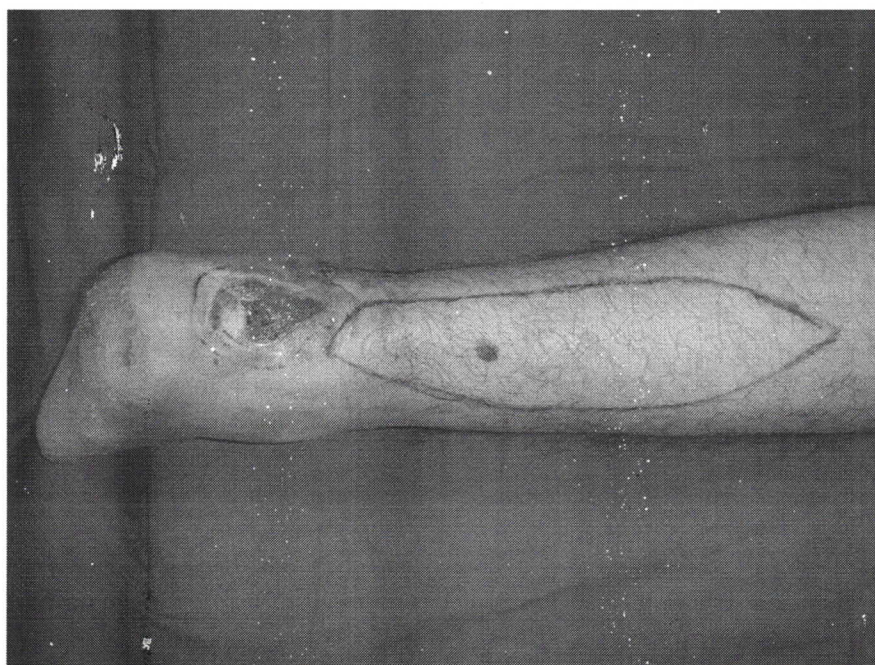

Fig. 12. Posttraumatic ulcer of the calcaneal region in a 35-year-old male. [Color figure can be viewed in the online issue, which is available at www.interscience.wiley.com.]

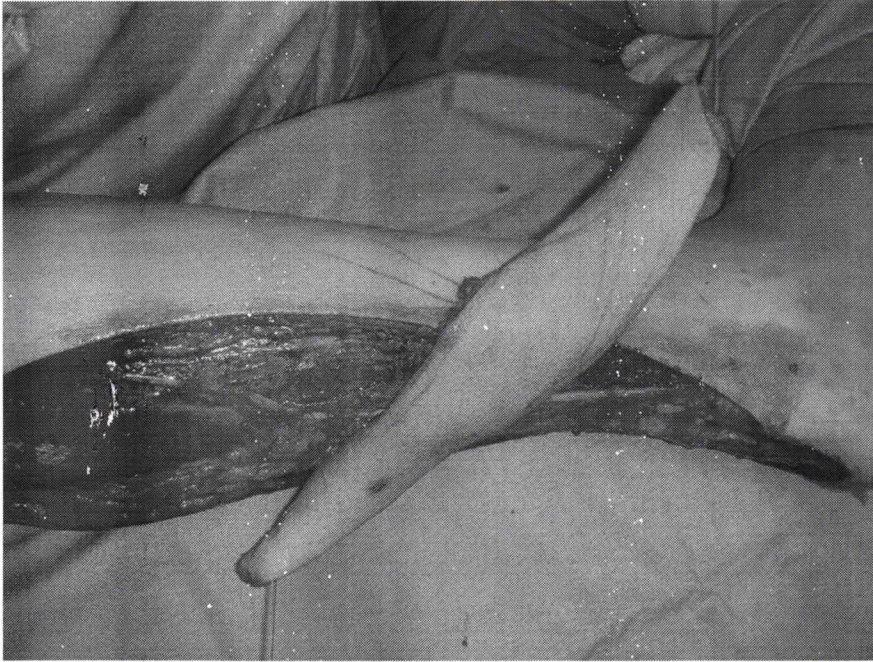


Fig. 13. Propeller flap based on a peroneal perforator rotated by 180°. [Color figure can be viewed in the online issue, which is available at www.interscience.wiley.com.]

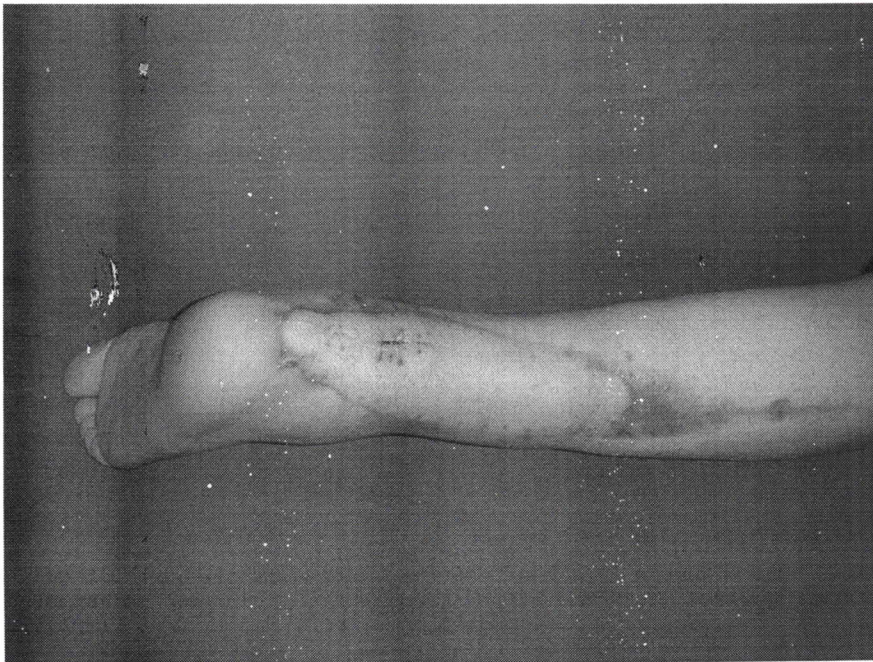


Fig. 14. Postoperative result after 3 months. [Color figure can be viewed in the online issue, which is available at www.interscience.wiley.com.]

cular tract (flexor hallucis longus and/or soleus), in the immediate adjacencies of the septum, as described in the literature by Wong et al. (2007) and Wei et al. (1986). Some anatomic variations exist in which the septocutaneous perforators are absent or the myocutaneous come from the posterior tibial instead of the fibular.

In the posterior tibial system, four perforators as average emerge from the two septa 5 and 6 and through the soleus muscle. Perforators are present in all tenths from the fourth, as the first three belong to the saphenous system. Areas of maximal concentration are fourth and fifth tenth and the boundary between eighth and ninth. Topographic data here reported agree with previous researches, particularly those by Carriquiry et al. (1985), Satoh et al., (1990), and Whetzel et al., (1997), utilizing the highest number of cadaver specimens.

As previously described by Taylor and Pan (1998), the entire medial aspect of the leg from the fourth tenth down to the ankle depends on the posterior tibial vascular system. Vessels of the various septa have two possible destinations: the anterior or the posterior portion of the leg. Liu et al. (1990) described the peculiar part of the posterior tibial system, the "exposed" tract, i.e., the supramalleolar portion of the artery, which is very superficial in the adjacency of the ankle. Moreover in that site there is a relevant recurrence of big perforators, which makes this tract an ideal region for harvesting perforator flaps.

With the correct indications, perforator and propeller flaps represent an optimal method for reconstruction of leg defects (Figs. 12–14). The anatomic variability of the three main vascular systems does not ease the use of these flaps. Not always are the ultrasounds or imaging-based mapping systems available or precise. The highest levels of accuracy are obtained through angio CT, an expensive technique, based on ionizing radiations and not always available. The mastery of the perforator clusters in terms of anatomic localization is best applicable to clinical surgical practice if a proportional standardized division of the leg into tenths is used. In fact this allows an accurate localization of the vessels, with a maximal error of few millimeters, in legs of various lengths, in infants, toddlers, children, and adults of various somatic dimensions.

A correlation exists between leg length and number of perforating vessels for the tibial vascular systems, possibly due to neoangiogenesis during growth, at the level of the metaphyseal plates. On the contrary no relationship of any kind was noticed for the fibular artery, whose perforators concentrate far from the growth cartilages. Despite the anatomic variability, a tendency of perforators to consistently concentrate in some parts of the leg exists. This allows a certain degree of predictability.

ACKNOWLEDGMENTS

Authors are very grateful to Ilaria Brazzoli and Daniele Imparato from Politecnico di Torino for their statistical elaborations.

REFERENCES

- Amarante J, Costa H, Reis J, Soares R. 1986. A new distally based fasciocutaneous flap of the leg. *Br J Plast Surg* 39:338–340.
- Beppu M, Hanel DP, Johnston GH, Carmo JM, Tsai TM. 1992. The osteocutaneous fibula flap: An anatomic study. *J Reconstr Microsurg* 8:215–223.
- Boriani F, Bogetti P. 2009. Lower leg perforators and bone growth. *Plast Reconstr Surg* 123:1134–1135.
- Carriquiry C, Aparecida Costa M, Vasconez LO. 1985. An anatomic study of the septocutaneous vessels of the leg. *Plast Reconstr Surg* 76:354–363.
- Cho BC, Kim SY, Park JW, Baik BS. 2001. Blood supply to osteocutaneous free fibula flap and peroneus longus muscle: Prospective anatomic study and clinical applications. *Plast Reconstr Surg* 108:1963–1971.
- Coskunfirat OK, Ozgentas HE. 2001. Reversed neurofasciocutaneous island flap based on the vascular supply accompanying the superficial peroneal nerve. *Plast Reconstr Surg* 108:1305–1308.
- Hasegawa M, Torii S, Katoh H, Esaki S. 1994. The distally based superficial sural artery flap. *Plast Reconstr Surg* 93:1012–1020.
- Heitmann C, Khan FN, Levin LS. 2003. Vasculature of the peroneal artery: An anatomic study focused on the perforator vessels. *J Reconstr Microsurg* 19:157–162.
- Hung LK, Lao J, Ho PC. 1996. Free posterior tibial perforator flap: Anatomy and a report of 6 cases. *Microsurgery* 17:503–511.
- Kim JS, Son DG, Choi TH, Kim NG, Lee KS, Han KH, Kim JH, Lee SI, Kang D. 2008. An anatomic study of the superficial peroneal nerve accessory artery and its perforators, and clinical application of superficial peroneal nerve accessory artery perforator flaps. *Ann Plast Surg* 60:710–716.
- Koshima I, Moriguchi T, Ohta S, Hamanaka T, Inoue T, Ikeda A. 1992. The vasculature and clinical application of the posterior tibial perforator-based flap. *Plast Reconstr Surg* 90:643–649.
- Liu K, Li Z, Lin Y, Cao Y. 1990. The reverse-flow posterior tibial artery island flap: Anatomic study and 72 clinical cases. *Plast Reconstr Surg* 86:312–316.
- Masquelet AC, Romana MC, Wolf G. 1992. Skin island flaps supplied by the vascular axis of the sensitive superficial nerves: Anatomic study and clinical experience in the leg. *Plast Reconstr Surg* 89:1115–1121.
- Morrison WA, Shen TY. 1987. Anterior tibial artery flap: Anatomy and case report. *Br J Plast Surg* 40:230–235.
- Ozalp T, Masquelet AC, Begue TC. 2006. Septocutaneous perforators of the peroneal artery relative to the fibula: Anatomical basis of the use of pedicled fasciocutaneous flap. *Surg Radiol Anat* 28:54–58.
- Ozdemir R, Kocer U, Sahin B, Oruc M, Kilinc H, Tekdemir I. 2006. Examination of the skin perforators of the posterior tibial artery on the leg and the ankle region and their clinical use. *Plast Reconstr Surg* 117:1619–1630.
- Satoh K, Sakai M, Hiromatsu N, Ohsumi N. 1990. Heel and foot reconstruction using reverse-flow posterior tibial flap. *Ann Plast Surg* 24:318–327.
- Schaverien M, Saint-Cyr M. 2008. Perforators of the lower leg: Analysis of perforator locations and clinical application for pedicled perforator flaps. *Plast Reconstr Surg* 122:161–170.
- Schusterman MA, Reece GP, Miller MJ, Harris S. 1992. The osteocutaneous free fibula flap: Is the skin paddle reliable? *Plast Reconstr Surg* 90:787–793.
- Taylor GI, Pan WR. 1998. Angiosomes of the leg: Anatomic study and clinical implications. *Plast Reconstr Surg* 102:599–616.
- Tanaka K, Matsumura H, Miyaki T, Watanabe K. 2006. An anatomic study of the intermuscular septum of the lower leg: Branches from the posterior tibial artery and potential 59:835–838.
- Vasconez L. 1997. Discussion: Arterial fasciocutaneous vascular territories of the lower leg. *Plast Reconstr Surg* 100:1184–1185.
- Wei FC, Chen HC, Chuang CC, Noordhoff MS. 1986. Fibular osteoseptocutaneous flap: Anatomic study and clinical application. *Plast Reconstr Surg* 78:191–200.

Whetzel TP, Barnard MA, Stokes RB. 1997. Arterial fasciocutaneous vascular territories of the lower leg. *Plast Reconstr Surg* 100:1172-1183.

Wolff KD. 1993. The supramalleolar flap based on septocutaneous perforators from the peroneal vessels for intraoral soft tissue replacement. *Br J Plast Surg* 46:151-155.

Wong CH, Tan BK, Wei FC, Song C. 2007. Use of the soleus musculocutaneous perforator for skin paddle salvage of the fibula

osteoseptocutaneous flap: Anatomical study and clinical confirmation. *Plast Reconstr Surg* 120:1576-1584.

Wu WC, Chang YP, So YC Yip SF, Lam YL. 1993. The anatomic basis and clinical applications of flaps based on the posterior tibial vessels. *Br J Plast Surg* 46:470-479.

Yoshimura M, Shimada T, Hosokawa M. 1990. The vasculature of the peroneal tissue transfer. *Plast Reconstr Surg* 85:917-921.