

AperTO - Archivio Istituzionale Open Access dell'Università di Torino

European Association of Urology Guidelines on Upper Urinary Tract Urothelial Carcinoma: 2023 Update

This is the author's manuscript

Original Citation:

Availability:

This version is available <http://hdl.handle.net/2318/2035409> since 2024-12-09T11:35:07Z

Published version:

DOI:10.1016/j.eururo.2023.03.013

Terms of use:

Open Access

Anyone can freely access the full text of works made available as "Open Access". Works made available under a Creative Commons license can be used according to the terms and conditions of said license. Use of all other works requires consent of the right holder (author or publisher) if not exempted from copyright protection by the applicable law.

(Article begins on next page)

European Association of Urology Guidelines on Upper Urinary Tract Urothelial Carcinoma: 2023 Update

Morgan Rouprêt ^{a*}, Thomas Seisen ^a, Alison J. Birtle ^{b,c}, Otakar Capoun ^{d,e}, Eva M. Compérat ^{d,e,f}, José L. Dominguez-Escrig ^g, Irene Gürses Andersson ^h, Fredrik Liedberg ^{i,j}, Paramanathan Mariappan ^k, A. Hugh Mostafid ^l, Benjamin Pradere ^{m,n}, Bas W.G. van Rhijn ^{o,p}, Shahrokh F. Shariat ^{q,r}, Bhavan P. Rai ^s, Francesco Soria ^t, Viktor Soukup ^{d,e}, Robbert G. Wood ^h, Evangelos N. Xylinas ^u, Alexandra Masson-Lecomte ^v, Paolo Gontero ^t

^a GRC 5 Predictive Onco-Uro, Sorbonne University, AP-HP, Urology, Pitie-Salpetriere Hospital, Paris, France

^b Lancashire Teaching Hospitals NHS Foundation Trust, Preston, UK

^c University of Manchester, Manchester, UK

^d Department of Urology, General Teaching Hospital and 1st Faculty of Medicine, Charles University Praha, Prague, Czechia

^e Department of Pathology, General Hospital of Vienna, Medical University of Vienna, Vienna, Austria

^f Department of Pathology, Sorbonne University, AP-HP, Hôpital Tenon, Paris

^g Department of Urology, Fundación Instituto Valenciano de Oncología, Valencia, Spain

^h Patient advocate, Bladder Cancer Norway, Norway

ⁱ Department of Translational Medicine, Lund University, Malmö, Sweden

^j Department of Urology, Skåne University Hospital, Malmö, Sweden

^k Department of Urology, Edinburgh Bladder Cancer Surgery, Western General Hospital, Edinburgh, UK

^l Department of Urology, The Stokes Centre for Urology, Royal Surrey Hospital, Guildford, UK

^m Department of Urology, Comprehensive Cancer Center, Medical University of Vienna, Vienna, Austria

ⁿ Department of Urology, La Croix Du Sud Hospital, Quint Fonsegrives, France

^o Department of Urology, Caritas St. Josef Medical Center, University of Regensburg, Regensburg, Germany

^p Department of Surgical Oncology (Urology), Netherlands Cancer Institute-Antoni van Leeuwenhoek Hospital, Amsterdam, The Netherlands

^q Department of Urology, Teaching Hospital Motol and 2nd Faculty of Medicine, Charles University Praha, Prague, Czechia

^r Department of Urology, Comprehensive Cancer Center, Medical University Vienna, Vienna General Hospital, Vienna, Austria

^s Department of Urology, Freeman Hospital, The Newcastle upon Tyne Hospitals NHS Foundation Trust, Newcastle upon Tyne, UK

^t Department of Urology, Città della Salute e della Scienza, University of Torino School of Medicine, Torino, Italy

^u Department of Urology, Bichat-Claude Bernard Hospital, AP-HP, Université de Paris, Paris, France

^v Department of Urology, Université de Paris, AP-HP, Saint Louis Hospital, Paris, France

* Corresponding author. Department of Urology, Pitié-Salpêtrière Hospital, AP-HP, Sorbonne University, F-75013 Paris, France. Tel. +33 1 42177297.
E-mail address: morgan.roupret@aphp.fr (M. Rouprêt).

Abstract

Context

The European Association of Urology (EAU) guidelines panel on upper urinary tract urothelial carcinoma (UTUC) has updated the guidelines to aid clinicians in evidence-based management of UTUC.

Objective

To provide an overview of the EAU guidelines on UTUC as an aid to clinicians.

Evidence acquisition

The recommendations provided in these guidelines are based on a review of the literature via a systematic search of the PubMed, Ovid, EMBASE, and Cochrane databases. Data were searched using the following keywords: urinary tract cancer, urothelial carcinomas, renal pelvis, ureter, bladder cancer, chemotherapy, ureteroscopy, nephroureterectomy, neoplasm, (neo)adjuvant treatment, instillation, recurrence, risk factors, metastatic, immunotherapy, and survival. The results were assessed by a panel of experts.

Evidence synthesis

Even though data are accruing, for many areas there is still insufficient high-level evidence to provide strong recommendations. Patient stratification on the basis of histology and clinical examination (including imaging) and assessment of patients at risk of Lynch syndrome will aid management. Kidney-sparing management should be offered as a primary treatment option to patients with low-risk UTUC and two functional kidneys. In particular, for patients with high-risk or metastatic UTUC, new treatment options have become available. In high-risk UTUC, platinum-based chemotherapy after radical nephroureterectomy, and adjuvant nivolumab for unfit or patients who decline chemotherapy, are options. For metastatic disease, gemcitabine/carboplatin chemotherapy is recommended as first-line treatment for cisplatin-ineligible patients. Patients with PD-1/PD-L1–positive tumours should be offered a checkpoint inhibitor (pembrolizumab or atezolizumab).

Conclusions

These guidelines contain information on the management of individual patients according to the current best evidence. Urologists should take into account the specific clinical characteristics of each patient when determining the optimal treatment regimen according to the risk stratification of these tumours.

Patient summary

Cancer of the upper urinary tract is rare, but because 60% of these tumours are invasive at diagnosis, timely and appropriate diagnosis is most important. A number of known risk factors exist.

Keywords: Renal pelvis; Ureter; Urothelial carcinoma; Prognostic factors; Management; Surgery; Genetic screening; (Neo)adjuvant therapy; Chemotherapy; Immunotherapy.

1. Introduction

The European Association of Urology (EAU) guidelines panel on upper urinary tract urothelial carcinoma (UTUC) has compiled these clinical guidelines to provide clinicians with evidence-based information and recommendations for the management of UTUC. This document presents a significant update of the previous version.

1.1. Data identification

For these guidelines, new and relevant evidence has been identified, collated, and appraised via a structured assessment of the literature. Databases searched included PubMed, Ovid, EMBASE, and both the Cochrane Central Register of Controlled Trials and the Cochrane Database of Systematic Reviews for articles published between June 8, 2021 and May 4, 2022. The search history is available online (<https://uroweb.org/guidelines/upper-urinary-tract-urothelial-cell-carcinoma/publications-appendices>).

2. Epidemiology, aetiology, and pathology

2.1. Epidemiology

Urothelial carcinomas (UCs) are the sixth most common tumours in developed countries [1]. They can be localised in the lower (bladder and urethra) and/or the upper (pyelocaliceal cavities and ureter) urinary tract. Bladder cancer (BC) tumours account for 90–95% of UCs [2], whereas upper tract UCs (UTUCs) are uncommon and account for only 5–10% of UCs [1] with an estimated annual incidence in Western countries of almost two cases per 100 000 inhabitants. This rate has risen in the past few decades as a result of improved detection and improved BC survival [3], [4]. Approximately two-thirds of patients who present with UTUC have invasive disease at diagnosis, in comparison to 15–25% of patients presenting with muscle-invasive bladder tumours [5]. UTUCs have a peak incidence in individuals aged 70–90 yr and are twice as common among men [6]. Genomic characterisation of UTUC provides information regarding the risk of bladder recurrence and can identify tumours associated with Lynch syndrome [7]. The majority of tumours develop in *MSH2* and *MSH6* mutation carriers [8]. Germline mutations in DNA mismatch repair (MMR) genes defining Lynch syndrome are found in 9% of patients with UTUC in comparison to 1% of patients with BC, which justifies screening of all patients younger than 60 yr presenting with UTUC and those with a family history of UTUC [9], [10] or a positive reflexive MMR test via immunohistochemistry in sporadic UTUC [11], [12], [13] (Fig. 1).

2.2. Risk factors

A number of environmental factors have been implicated in the development of UTUC [14]. Published evidence in support of a causative role for these factors is not strong, with the exception of smoking and aristolochic acid. Tobacco exposure increases the relative risk of developing UTUC from 2.5 to 7.0 [15], [16]. Aristolochic acid, a nitrophenanthrene carboxylic acid produced by *Aristolochia* plants, which are used worldwide, especially in China and Taiwan [17], exerts multiple effects on the urinary system. However, fewer than 10% of individuals exposed to aristolochic acid develop UTUC [18]. Consumption of arsenic in drinking water and *Aristolochia*-based herbal remedies together appears to have an additive carcinogenic effect [19]. Alcohol consumption is associated with development of UTUC. A large case-control study (1569 cases and 506 797 controls) has evidenced a significantly higher risk of UTUC in ever-drinkers compared to never-drinkers (odds ratio 1.23, 95% confidence interval [CI] 1.08–1.40; $p = 0.001$). A dose-response was observed [20].

A history of BC is associated with higher risk of developing UTUC, and patients who undergo ureteral stenting at the time of transurethral resection of bladder tumour, including before radical cystectomy, are at higher risk of upper urinary tract (UUT) recurrence [21], [22].

2.3. Histology

UUT tumours are almost always UCs, and pure nonurothelial histology is rare [23]. However, histological subtypes are present in approximately 25% of UTUCs [24]. UC with divergent squamous differentiation is present in approximately 15% of cases [25]. Other subtypes, although rare, include sarcomatoid and UCs with inverted growth [26].

Table 1 summarises the guidelines on epidemiology, aetiology, and pathology.

3. Staging and classification systems

3.1. Classification

The classification and morphology are similar for UTUC and BC [2]. However, because of the difficulty in acquiring an adequate sample, it is often hard to distinguish between noninvasive papillary tumours [27], flat lesions (carcinoma in situ [CIS]), and invasive carcinoma. Therefore, histological grade is often used for clinical decision-making, as it is strongly associated with pathological stage [28].

3.2. TNM staging

The TNM classification is shown in Table 2 [29]. The regional lymph nodes (LNs) are the hilar and retroperitoneal nodes, and the pelvic nodes for the mid- and distal ureter.

3.3. Tumour grade

In 2022, an update of the 2004/2016 World Health Organization (WHO) grading classification was published without major changes [30]. These guidelines are still based on both the 1973 and 2004/2016 WHO classifications, since most published data use the 1973 classification [27].

3.4. Molecular classification of UTUCs

A number of studies focusing on molecular classification have demonstrated genetically distinct molecular subtypes of UTUC by evaluating DNA, RNA, and protein expression, but it is still unclear whether these subtypes respond differently to treatment and therefore they have limited use in daily practice [31].

4. Diagnosis

The diagnosis of UTUC may be incidental or symptom-related. The most common symptom is visible or nonvisible haematuria (70–80%) [32], [33]. Flank pain, due to a clot or tumour tissue obstruction or, less often, local growth, occurs in approximately 20–32% of cases [34]. Systemic symptoms denote worse prognosis (including anorexia, weight loss, malaise, fatigue, fever, night sweats, or cough) and should prompt evaluation for metastases [34].

4.1. Imaging

4.1.1. Computed tomography urography

Computed tomography urography (CTU) has the highest diagnostic accuracy of the imaging techniques available [35]. A meta-analysis of 13 studies comprising 1233 patients revealed that CTU had pooled sensitivity for UTUC detection of 92% (95% CI 0.85–0.96) and pooled specificity of 95% (95% CI 0.88–0.98) [36]. Epithelial “flat lesions” without mass effect or urothelial thickening are generally not visible with CT.

4.1.2. Magnetic resonance urography

Magnetic resonance urography (MRU) is indicated in patients who cannot undergo CTU, usually when radiation or iodinated contrast media are contraindicated [37]. The sensitivity of MRU is 75% after contrast injection for tumours <2 cm [37]. CTU is more sensitive and specific for the diagnosis and staging of UTUC in comparison to MRU [38].

4.1.3. ¹⁸F-Fluorodeoxyglucose positron emission tomography/computed tomography

A retrospective multicentre study on the use of ¹⁸F-fluorodeoxyglucose positron emission tomography/computed tomography (FDG-PET/CT) for detection of nodal metastasis in 117 surgically-treated UTUC patients revealed promising sensitivity and specificity of 82% and 84%, respectively [39]. These results warrant further validation and comparison to MRU and CTU.

4.2. Cystoscopy

Urethrocystoscopy is an integral part of UTUC diagnosis to rule out concomitant BC [40].

4.3. Cytology

Abnormal cytology may indicate high-grade UTUC when bladder cystoscopy is normal, and in the absence of CIS in the bladder and prostatic urethra [2], [41]. Cytology is less sensitive for UTUC than for bladder tumours and should be performed selectively in the affected UUT [42]. In one study, barbotage cytology detected up to 91% of cancers [43] but barbotage cytology taken from the renal cavities and ureteral lumina is preferred before application of a contrast agent for retrograde ureteropyelography [44]. Retrograde ureteropyelography remains an option for detect UTUC detection [28], [45].

4.4. Diagnostic ureteroscopy

Flexible ureteroscopy (URS) is used to confirm the diagnosis of UTUC by visualising the ureter, renal pelvis, and collecting system and perform biopsy of suspicious lesions. It is also essential for meticulous tumour mapping before considering kidney-sparing options for UTUC. The presence, appearance, multifocality, and size of tumours can be determined using URS. In addition, URS biopsies can determine tumour grade in more than 90% of cases, with a low false-negative rate, regardless of sample size [46].

URS also facilitates selective ureteral sampling for cytology in situ [47], [48]. Stage assessment using URS biopsy can be inaccurate. Combining URS biopsy grade, imaging findings such as hydronephrosis, and urinary cytology may help in the decision-making process between radical nephroureterectomy (RNU) and kidney-sparing therapy [48], [49]. In a meta-analysis comparing URS versus no URS before RNU, 8/12 studies found a higher risk of intravesical recurrence if URS was performed before RNU [50]. Performing a biopsy during URS was also identified as a risk factor for intravesical recurrence [50].

4.5. Distant metastases

Before any treatment with curative intent, it is essential to rule out distant metastases. CT is the diagnostic technique of choice for lung and abdominal staging for metastases [36].

Table 3 summarises the guidelines for UTUC diagnosis.

5. Prognosis

5.1. Prognostic factors

Many patient- and tumour-related prognostic factors have been identified that can be used to risk-stratify patients in deciding on the most appropriate local treatment (radical vs conservative) and in discussing perioperative systemic

therapy [51], [52], [53], [54], [55], [56], [57], [58], [59], [60], [61], [62], [63], [64], [65], [66], [67], [68] (Table 4).

5.1.1. Molecular markers

Because of the rarity of UTUC, none of the markers investigated have been validated to support their introduction in daily clinical decision-making [69].

5.2. Risk stratification for clinical decision-making

As tumour stage is difficult to assess clinically in UTUC, it is useful to “risk stratify” UTUC between low and high risk of progression to identify patients who are more likely to benefit from kidney-sparing treatment and those who should be treated radically [70]. The factors to consider for risk stratification are presented in Figure 2. Prognostic nomograms based on preoperative factors and postoperative pathological characteristics are also available [71], [72], [73] and may be used when counselling patients.

5.3. Bladder recurrence

A meta-analysis of available data has identified three categories of predictors of bladder recurrence after RNU [74] (level of evidence [LE]: 3):

1. Patient-specific factors such as male sex, previous BC, smoking, and preoperative chronic kidney disease;
2. Tumour-specific factors such as positive preoperative urine cytology, tumour grade, ureteral location, multifocality, tumour diameter, invasive pT stage, and necrosis [75], [76]; and
3. Treatment-specific factors such as laparoscopic approach, extravesical bladder cuff removal, and positive surgical margins [74].

The use of diagnostic URS has been associated with a higher risk of developing bladder recurrence after RNU [77] (LE: 3). On the basis of low-level evidence only, it has been suggested that a single dose of intravesical chemotherapy after diagnostic/therapeutic URS in UTUC reduces the rate of intravesical recurrence to a rate similar to that after RNU [74].

Table 5 summarises the guidelines for UTIC prognosis.

6. Disease management

6.1. Localised low-risk disease

6.1.1. General considerations for kidney-sparing surgery

In low-risk disease, kidney-sparing surgery reduces the morbidity associated with radical surgery (eg, loss of kidney function) without compromising oncological outcomes [78]. It is the preferred approach, as survival is similar to that after RNU, and this option should be discussed in all low-risk cases, irrespective of the status of the contralateral kidney [78].

6.1.2. Ureteroscopy

Endoscopic ablation should be considered in patients with clinically low-risk UTUC, but the patient should be informed of the need and be willing to comply with early second-look URS [79] and stringent surveillance. A risk of disease progression remains with endoscopic management [80].

6.1.3. Percutaneous access

In low-risk UTUC in the renal pelvis, percutaneous management can be considered [81] (LE: 3). This may also be offered for tumours in the lower caliceal system that are inaccessible or difficult to manage via flexible URS. However, a risk of tumour seeding remains with percutaneous access [81].

6.1.4. Ureteral resection

Segmental ureteral resection with wide margins provides adequate pathological specimens for staging and grading while preserving the ipsilateral kidney. Lymphadenectomy can also be performed during segmental ureteral resection [78]. Segmental resection of the proximal two-thirds of the ureter is associated with higher failure rates than for the distal ureter [82], [83] (LE: 3). Distal ureterectomy with ureteroneocystostomy is indicated for low-risk tumours in the distal ureter that cannot be removed completely endoscopically [82] (LE: 3).

6.1.5. Chemoablation

A single-arm phase 3 trial showed that the use of mitomycin-containing reverse thermal gel (UGN-101) instillations in a chemoablation setting via a retrograde catheter in the renal pelvis and calyces was associated with a complete response rate in 42 patients (59%) with biopsy-proven low-grade UTUC (<15 mm). Some 52% of the patients remained in complete response after 12 mo, with Kaplan-Meier-estimated durability of 82% [84].

6.1.6. Adjuvant instillations

6.1.6.1. Upper urinary tract

A systematic review and meta-analysis assessing the oncological outcomes for patients with papillary UTUC or CIS of the UUT treated with kidney-sparing surgery and adjuvant endocavitary treatment found no difference between the drug administration methods (antegrade vs retrograde vs combined approach) in terms of recurrence, progression, cancer-specific survival (CSS), and overall survival (OS). The recurrence rates following adjuvant instillations are comparable to those reported in the literature for untreated patients, calling their efficacy into question [85].

6.1.6.2. Bladder

There are currently no data to support the use of bladder instillation of chemotherapy after kidney-sparing surgery, as the available randomised controlled trials (RCTs) included only patients who underwent RNU.

6.2. Management of localised high-risk disease

6.2.1. Surgical approach

6.2.1.1. Open RNU

Open RNU with bladder cuff excision is the standard treatment for high-risk UTUC, regardless of tumour location [5] (LE: 3). RNU must be performed according to oncological principles to prevent tumour seeding [5].

6.2.1.2. Minimally invasive RNU

Retroperitoneal metastatic dissemination and metastasis along the trocar pathway following manipulation of large tumours in a pneumoperitoneal environment have been reported in few cases [86]. Several precautions may lower the risk of tumour spillage:

1. Avoid entering the urinary tract, except when performing a bladder cuff excision and only after prior clipping of the ureter and complete drainage of the bladder.
2. Avoid direct contact between instruments and the tumour.
3. Perform the procedure in a closed system. Avoid morcellation of the tumour and use an endobag for tumour extraction.
4. The kidney and ureter must be removed en bloc with the bladder cuff.
5. For invasive or large (T3/T4 and/or N+/M+) tumours, an open approach is favoured, as oncological outcomes may be better than with minimally invasive RNU [87].

There is a trend towards equivalent oncological outcomes after laparoscopic and open RNU [88], [89], [90] (LE: 3). Oncological outcomes after RNU have not changed significantly over the past three decades despite staging and surgical refinements [91] (LE: 3). A robot-assisted

laparoscopic approach can be considered, with recent data suggesting oncological equivalence with the other approaches [92], [93].

6.2.1.3. Bladder cuff management

Resection of the distal ureter and its orifice is performed because there is a considerable risk of tumour recurrence in this area and in the bladder [74], [82], [94]. Several techniques have been considered to simplify distal ureter resection, but none of has been convincingly shown to be equal to complete bladder cuff excision [94] (LE: 3).

6.2.1.4. LN dissection

Use of an LN dissection (LND) template is likely to have a greater impact on patient survival than the number of LNs removed [95]. Template-based LND and the degree of completeness improves CSS in patients with muscle-invasive disease and reduce the risk of local recurrence [96]. LND appears to be unnecessary in Ta–T1 UTUC because of the low risk of LN metastasis [97], [98]; however, tumour staging is inaccurate preoperatively. Therefore, template-based LND should be offered to all patients who are scheduled for RNU for high-risk nonmetastatic UTUC.

6.2.2. Distal ureterectomy

Distal ureterectomy for high-risk UTUC may be associated with similar oncological outcomes to those for RNU [78]. This procedure also provides the opportunity to perform a concomitant LND, but only selected high-risk patients with UTUC in the distal ureter can benefit from this procedure.

6.2.3. Kidney-sparing surgery for imperative indications

Kidney-sparing surgery can be considered on a case-by-case basis in high-risk patients with imperative indications such as a solitary kidney, bilateral UTUC, chronic kidney disease, or any other comorbidity compromising the use of RNU, but at the cost of a greater risk of progression and reduced OS [78] (LE: 3).

6.2.4. Perioperative treatments

6.2.4.1. Neoadjuvant treatments

6.2.4.1.1. Chemotherapy

The primary advantage of neoadjuvant chemotherapy (NAC) is the ability to give cisplatin-based regimens when patients still have maximal renal function. A meta-analysis ($n \geq 800$) revealed that NAC was associated with a pathological partial response rate of 43% and a downstaging rate of 33%, and OS and CSS survival benefits in comparison to RNU alone [99]. However, it is important to note that the available evidence is not conclusive, given the significant bias and heterogeneity.

6.2.4.1.2. Immunotherapy

Only a small phase 2 study including ten patients with high-risk UTUC evaluated the efficacy of pembrolizumab in the neoadjuvant setting [100]. No pathological response was observed and one treatment-related death was reported. Thus, there is currently no evidence to support the use of neoadjuvant immunotherapy for high-risk UTUC.

6.2.4.2. Adjuvant treatments

6.2.4.2.1. Bladder instillations

The rate of bladder recurrence after RNU for UTUC is 22–47% [101]. Two prospective randomised trials [102], [103] and two meta-analyses [104], [105] demonstrated that a single postoperative dose of intravesical chemotherapy (mitomycin C, pirarubicin) 2–10 d after surgery reduces the risk of bladder tumour recurrence within the first years after RNU (LE: 2). Intravesical chemotherapy has also been safely given at the time of RNU, obviating the need for a postoperative cystogram, but with low-level data regarding efficacy [106].

On the basis of current evidence, it is unlikely that additional instillations beyond one perioperative instillation of chemotherapy further substantially reduces the risk of intravesical recurrence [107].

6.2.4.2.2. Chemotherapy

A phase 3 multicentre prospective RCT ($n = 261$) evaluating the benefit of four cycles of adjuvant gemcitabine-platinum combination chemotherapy initiated within 90 d after RNU versus surveillance reported a significant improvement in disease-free survival (DFS) in patients with pT2–4, N_{any} or LN-positive (pT any, N1–3) M0 UTUC [108] (LE: 1).

The main potential limitation of using adjuvant chemotherapy is the concern that renal function may deteriorate after RNU. However, fractionated cisplatin may be considered in patients with a glomerular filtration rate (GFR) of 45 ml/min [109]. While histological subtypes of UTUC exhibit different survival rates in retrospective studies, adjuvant chemotherapy should be considered when UC is the dominant pathology.

6.2.4.2.3. Immunotherapy

In a phase 3, multicentre, double-blind RCT involving patients with high-risk muscle-invasive UC who had undergone radical surgery, adjuvant nivolumab improved DFS in comparison to placebo in the intention-to-treat population (20.8 vs 10.8 mo) and among patients with a PD-L1 expression level of $\geq 1\%$ [110]. Median survival free of recurrence outside the urothelial tract in the entire intention-to-treat population was 22.9 mo with nivolumab and 13.7 mo with placebo. On subgroup analysis, patients with UTUC included in this study did not seem to benefit from adjuvant nivolumab, which requires further follow-up and analysis.

The European Medicines Agency approved nivolumab as monotherapy for adjuvant treatment in patients with muscle-invasive UC with tumour cell PD-L1 expression $\geq 1\%$, who are at high risk of recurrence after undergoing radical surgery [111]. A network meta-analysis suggests superior oncological benefit to adjuvant platinum-based chemotherapy over immune checkpoint inhibitors in patients treated with radical surgery [112].

6.2.4.2.4. Radiotherapy

Data on adjuvant radiation therapy remain immature, and its added value to chemotherapy remains questionable [113].

Figure 3 shows a proposed flow chart for UTUC management.

6.3. Metastatic disease

6.3.1. Clinical locoregional LN metastases

Evidence is lacking regarding the optimal management of clinical node-positive disease. Patients with clinically N+ UTUC should be offered first-line chemotherapy. For patients whose cancer responds and those who have stable disease, maintenance avelumab can be offered [114]. Depending on the extent of the nodal disease (ie, cN1/N2), surgical resection with LND can be discussed after initial systemic therapy. For patients whose cancer progresses, second-line treatment can be offered, similar to the approach for metastatic disease [115], [116].

6.3.2. Distant metastases

6.3.2.1. Systemic treatments

6.3.2.1.1. First-line setting

6.3.2.1.1.1. Patients fit for cisplatin-based combination chemotherapy

UTUC and urothelial BC both respond to systemic platinum-based chemotherapy. Therefore, cisplatin-containing combination chemotherapy is the standard treatment for advanced or metastatic UTUC [117]. Use of cisplatin-based chemotherapy is widely considered for patients with an estimated GFR >45 ml/min [118].

The efficacy of immunotherapy using PD1 or PD-L1 inhibitors has been evaluated in the first-line setting for the treatment of cisplatin-/carboplatin-fit patients with metastatic UC, including those

with UTUC [119]. First-line immune checkpoint inhibitors and combinations of platinum-based chemotherapy with immune checkpoint inhibitors have not resulted in positive significant survival advantages and are not currently recommended [120], [121], [122].

6.3.2.1.1.2. Patients unfit for cisplatin-based combination chemotherapy

Carboplatin-based chemotherapy is recommended for patients unfit for cisplatin [117]. Carboplatin with gemcitabine is the preferred regimen [123], irrespective of PD-L1 status [124].

6.3.2.1.1.3. Maintenance therapy after first-line platinum-based chemotherapy

Maintenance avelumab is recommended for patients with a complete/partial response or stable disease after four to six cycles of platinum-based chemotherapy. Data from a phase 3 RCT showed that avelumab maintenance therapy after four to six cycles of gemcitabine plus cisplatin or carboplatin (started within 10 wk of completion of first-line platinum-based chemotherapy) significantly prolonged OS in comparison to best supportive care alone for patients with advanced or metastatic UC who experienced not progression during, or a response to, first-line chemotherapy (hazard ratio [HR] 0.69, 95% CI 0.56–0.86) [114], [125]. An increase in median OS from 14 to 21 mo was observed with avelumab.

6.3.2.1.1.4. Patients unfit for platinum-based combination chemotherapy

Pembrolizumab and atezolizumab are alternative choices for patients who are PD-L1–positive and not eligible or fit for platinum-based chemotherapy. In a single-arm phase 2 trial ($n = 370$) in cisplatin-ineligible UC, pembrolizumab monotherapy was associated with an objective response rate of 26% among 69 patients with metastatic UTUC [126]. In the overall cohort, PD-L1 expression of 10% was associated with a greater response rate to pembrolizumab. In a single-arm phase 2 trial ($n = 119$) in cisplatin-ineligible UC, atezolizumab monotherapy was associated with an objective response rate of 39% among 33 patients (28%) with metastatic UTUC [127]. Median OS in the overall cohort was 15.9 mo. For both studies, treatment-related toxicity was in line with previous reports [121].

6.3.2.1.2. Second-line setting

6.3.2.1.2.1. Immunotherapy

A phase 3 RCT including 542 patients who received prior platinum-based chemotherapy for advanced UC showed that pembrolizumab decreased the risk of death in comparison to second-line chemotherapy (investigator choice of paclitaxel, docetaxel, or vinflunine), with median OS of 10.3 mo for pembrolizumab and 7.4 mo for chemotherapy (HR 0.73, 95% CI 0.59–0.91) [128]. Responses were more frequent and durable with pembrolizumab than with chemotherapy (21% vs 11%). In the UTUC subgroup ($n = 75$, 13.8%), the OS benefit seemed to be greater (50%).

On the basis of single-arm phase 1 or 2 trials only, and with some methodological caveats, immunotherapies such as nivolumab [129], avelumab [130], [131], and durvalumab [132] have shown objective response rates ranging from 17.8% [132] to 19.6% [129] and median OS ranging from 7.7 mo to 18.2 mo for patients with platinum-resistant metastatic UC.

The immunotherapy combination of nivolumab plus ipilimumab showed significant antitumour activity with an objective response rate of up to 38% in a phase 1/2 multicentre trial including 78 patients with metastatic UC progressing after platinum-based chemotherapy [133].

6.3.2.1.2.2. Novel agents

6.3.2.1.2.2.1. FGFFR inhibition

Erdafitinib, a pan-FGFR tyrosine kinase inhibitor of FGFR1–4, was associated with a 40% radiological response rate (Response Evaluation Criteria in Solid Tumours) in a phase 2 trial of 99 patients with locally advanced or metastatic UC who experienced progression after first-line chemotherapy and harboured a genomic *FGFR* alteration (*FGFR2/3* mutations or *FGFR3* fusions) [134].

6.3.2.1.2.2.2. Antibody-drug conjugates

In a phase 3 trial of enfortumab vedotin for the treatment of patients with locally advanced or metastatic UC who had previously received platinum-containing chemotherapy and experienced

disease progression during or after treatment with a PD-1 or PD-L1 inhibitor, enfortumab vedotin significantly prolonged survival in comparison to standard chemotherapy (median OS 12.88 vs 8.97 mo) [135].

6.3.2.1.3. Third-line setting

In an open-label phase 2 trial, 108 patients with disease progression after platinum-based chemotherapy and checkpoint inhibitors were treated with the antibody-drug conjugate sacituzumab govitecan. The objective radiological response rate was 27%, with median duration of response of 7.2 mo, median progression-free survival (PFS) of 5.4 mo, and median OS of 10.9 mo. However, the proportion of patients with UC was not mentioned in the publication [136]. A preplanned subgroup analysis for the phase 3 RANGE trial assessed the impact on outcomes and safety of ramucirumab added to docetaxel after disease progression on both platinum-based chemotherapy and immune checkpoint inhibitors [137]. Median PFS was 3.15 mo with ramucirumab/docetaxel versus 2.73 mo with placebo/docetaxel (HR 0.786, 95% CI 0.404–1.528; $p = 0.4877$).

6.3.2.2. Surgery

6.3.2.2.1. RNU

Although evidence remains very limited, RNU may be associated with better CSS [138], [139] and an OS benefit in selected patients, especially those fit enough to receive cisplatin-based chemotherapy [138], [140]. It is noteworthy that these benefits may be limited to patients with only one metastatic site [138]. Indications for RNU in this setting should mainly be reserved for palliative care aimed at controlling symptomatic disease [141] (LE: 3).

6.3.2.2.2. Metastasectomy

In the absence of data from RCTs, patients should be evaluated on an individual basis and the decision to perform metastasectomy (surgically) should be made following a shared decision-making process with the patient (LE: 3). Table 6 summarises guidelines for the management of UTUC.

7. Follow-up

The aims for follow-up after treatment for UTUC are to comply with patient rehabilitation needs, to detect recurrent or new primary tumours within the urothelium, and to detect regional and distant metastases. Patient, tumour, and treatment characteristics have an impact when designing interval, length, and modalities for follow-up of an individual patient. Bladder recurrence is not considered a distant recurrence.

After RNU for low-risk tumours and a negative cystoscopy at 3 mo postoperatively, a subsequent cystoscopy 9 mo later and yearly cystoscopy for 5 yr are recommended on the basis of follow-up data for low-risk Ta BC [142]. Screening for metastases during follow-up is not mandatory; CTU in cases with a tumour-free bladder during follow-up is also not mandatory owing to the low risk of metachronous UTUC [143].

When RNU has been performed for high-risk tumours, stringent follow-up is mandatory to detect metachronous bladder tumours (probability increases over time [144]), local recurrence, and distant metastases. The risk of bladder recurrences and other-site recurrences decreases at 4 yr after RNU, suggesting that less intensive annual cystoscopy and cross-sectional imaging including CTU is sufficient thereafter [145].

After kidney-sparing management for low-risk UTUC and no upstaging or upgrading after an early second-look ureteroscopy after 6–8 wk [79] or in the resection specimen after segmental ureteric resection, cystoscopy and CT urography should be performed at 3 and 6 mo, and then yearly for 5 yr [146].

In patients treated with a kidney-sparing approach for high-risk tumours, the indication (imperative vs nonimperative) affects the surveillance regimen because of the consequences of recurrent disease. However, the ipsilateral UUT still requires careful and long-term follow-up owing to the high risk of disease recurrence [147] and progression to RNU, even beyond 5 yr [148].

It is not known how patients with Lynch syndrome without and with UTUC should be followed over the long term given the inadequacy of surveillance involving nonvisible haematuria assessment [149] and urine cytology [150], particularly for individuals who are *MSH2* mutation carriers [8] and those who have already developed a UTUC.

Table 7 summarises the guidelines on follow-up for UTUC.

Author contributions: Morgan Rouprêt had full access to all the data in the study and takes responsibility for the integrity of the data and the accuracy of the data analysis.

Study concept and design: Rouprêt.

Acquisition of data: Rouprêt, Birtle, Capoun, Compérat, Dominguez-Escrig, Liedberg, Mariappan, Masson-Lecomte, Mostafid, Pradere, van Rhijn, Seisen, Shariat, Rai, Soria, Soukup, Xylinas, Gontero.

Analysis and interpretation of data: Rouprêt, Birtle, Capoun, Compérat, Dominguez-Escrig, Liedberg, Mariappan, Masson-Lecomte, Mostafid, Pradere, van Rhijn, Seisen, Shariat, Rai, Soria, Soukup, Xylinas, Gontero.

Drafting of the manuscript: Rouprêt.

Critical revision of the manuscript for important intellectual content: Birtle, Capoun, Compérat, Dominguez-Escrig, Gürses Andersson, Liedberg, Mariappan, Masson-Lecomte, Mostafid, Pradere, van Rhijn, Seisen, Shariat, Rai, Soria, Soukup, Wood, Xylinas, Gontero.

Statistical analysis: None.

Obtaining funding: None.

Administrative, technical, or material support: Rouprêt.

Supervision: Rouprêt.

Other: None.

Financial disclosures: Morgan Rouprêt certifies that all conflicts of interest, including specific financial interests and relationships and affiliations relevant to the subject matter or materials discussed in the manuscript (eg, employment/affiliation, grants or funding, consultancies, honoraria, stock ownership or options, expert testimony, royalties, or patents filed, received, or pending), are the following: Morgan Rouprêt has received consultancy fees from Ipsen Pharma, Janssen Cilag, Bristol-Myers Squibb, and Ferring, and speaker honoraria from Astellas, Bayer S.A.S., and Ipsen Pharma. Alison J. Birtle has received advisory board and speaker fees and travel support from Astellas Pharma, AstraZeneca, Bayer, EMD Serono, Janssen, Merck Serono, Pfizer, and Roche. Otakar Capoun has received consultation fees from Janssen, speaker honoraria from Janssen, Ipsen, Astellas, and Bayer, and fellowship/travel grants from Janssen, Ipsen, and Astellas, and participates in trials run by Janssen, Aragon Pharmaceuticals, and Bayer s.r.o. José L. Dominguez-Escrig has participated in clinical trials run by COMBAT BRS, BTS, Ipsen, Storz, Arquer, and Angiodynamics; is the national coordinator and is responsible for design of the CUETO Physion-Arquer trial, and is a proctor for Angiodynamics. Alexandra Masson-Lecomte has received research support from the European Urological Scholarship Program and Ipsen Pharma; has received consultancy fees from Ipsen Pharma, AstraZeneca, Ambu, Ferring, BMS, and Janssen Cilag; has received speaker honoraria from Astellas, Ferring, Janssen, and Ipsen Pharma; and participates in studies run by Janssen Cilag and Roche. A. Hugh Mostafid has received a speaker honorarium from Medac, is a consultant for Bristol-Myers Squibb, and participates in trials run by Merck, and Cepheid. Bas W.G. Van Rhijn has participated in advisory board meetings for AstraZeneca, Ferring, and QED Therapeutics, and is a scientific advisory committee member for QED Therapeutics. Thomas Seisen has received honoraria from Janssen and Astellas and a travel grant from Institut de Recherches Servier (France), and

participates in trials by run CHD La Roche and Janssen. Shahrokh F. Shariat has received honoraria from Astellas, AstraZeneca, BMS, Ferring, Ipsen, Janssen, MSD, Olympus, Pfizer, Roche, and Takeda; has a consulting or advisory role with Astellas, AstraZeneca, BMS, Ferring, Ipsen, Janssen, MSD, Olympus, Pfizer, Pierre Fabre, Roche, and Takeda; and participates in speaker bureaus for Astellas, AstraZeneca, Bayer, BMS, Ferring, Ipsen, Janssen, MSD, Olympus, Pfizer, Richard Wolf, Roche, and Takeda. Francesco Soria is a consultant for Orion Pharma. Paolo Gontero is a consultant for Arquer Diagnostics, Ferring, Ismar Healthcare, Lightpoint, and Photocure; and has received research grants from AB Medica, Astellas, Coloplast, Ipsen, Janssen, and Storz, and speaker honoraria from Cepheid and Medacs. Evanguelos N. Xylinas received honoraria from Astellas, AstraZeneca, Bayer, BMS, Ferring, Ipsen, Janssen-Cilag, MSD, and Pfizer. The remaining authors have nothing to disclose.

References

- [1] Siegel RL, Miller KD, Fuchs HE, Jemal A. Cancer statistics, 2021. *CA Cancer J Clin* 2021;71:7–33.
- [2] Gontero P, Compérat E, Dominguez-Escrig JL, et al. EAU guidelines on non-muscle-invasive bladder cancer (T1, T1 and CIS). Arnhem, The Netherlands: European Association of Urology; 2023.
- [3] Soria F, Shariat SF, Lerner SP, et al. Epidemiology, diagnosis, preoperative evaluation and prognostic assessment of upper-tract urothelial carcinoma (UTUC). *World J Urol* 2017;35:379–87.
- [4] Almås B, Halvorsen OJ, Johannesen TB, Beisland C. Higher than expected and significantly increasing incidence of upper tract urothelial carcinoma. A population based study. *World J Urol* 2021;39:3385–91.
- [5] Margulis V, Shariat SF, Matin SF, et al. Outcomes of radical nephroureterectomy: a series from the Upper Tract Urothelial Carcinoma Collaboration. *Cancer* 2009;115:1224–33.
- [6] Shariat SF, Favaretto RL, Gupta A, et al. Gender differences in radical nephroureterectomy for upper tract urothelial carcinoma. *World J Urol* 2011;29:481–6.
- [7] Audenet F, Isharwal S, Cha EK, et al. Clonal relatedness and mutational differences between upper tract and bladder urothelial carcinoma. *Clin Cancer Res* 2019;25:967–76.
- [8] Therikildsen C, Eriksson P, Höglund H, et al. Molecular subtype classification of urothelial carcinoma in Lynch syndrome. *Mol Oncol* 2018;12:1286–95.
- [9] Pradere B, Lotan Y, Roupert M. Lynch syndrome in upper tract urothelial carcinoma: significance, screening, and surveillance. *Curr Opin Urol* 2017;27:48–55.
- [10] Audenet F, Colin P, Yates DR, et al. A proportion of hereditary upper urinary tract urothelial carcinomas are misclassified as sporadic according to a multi-institutional database analysis: proposal of patient-specific risk identification tool. *BJU Int* 2012;110:E583–9.
- [11] Ju JY, Mills AM, Mahadevan MS, et al. Universal Lynch syndrome screening should be performed in all upper tract urothelial carcinomas. *Am J Surg Pathol* 2018;42:1549–55.
- [12] Gayhart MG, Johnson N, Paul A, et al. Universal mismatch repair protein screening in upper tract urothelial carcinoma. *Am J Clin Pathol* 2020;154:792–801.
- [13] Rasmussen M, Madsen MG, Therikildsen C. Immunohistochemical screening of upper tract urothelial carcinomas for Lynch syndrome diagnostics: a systematic review. *Urology* 2022;165:44–53.
- [14] Colin P, Koenig P, Ouzzane A, et al. Environmental factors involved in carcinogenesis of urothelial cell carcinomas of the upper urinary tract. *BJU Int* 2009;104:1436–40.
- [15] McLaughlin JK, Silverman DT, Hsing AW, et al. Cigarette smoking and cancers of the renal pelvis and ureter. *Cancer Res* 1992;52:254–7.
- [16] Crivelli JJ, Xylinas E, Kluth LA, Rieken M, Rink M, Shariat SF. Effect of smoking on outcomes of urothelial carcinoma: a systematic review of the literature. *Eur Urol* 2014;65:742–54.
- [17] Grollman AP. Aristolochic acid nephropathy: harbinger of a global iatrogenic disease. *Environ Mol Mutagen* 2013;54:1–7.
- [18] Cosyns JP. Aristolochic acid and ‘Chinese herbs nephropathy’: a review of the evidence to date. *Drug Saf* 2003;26:33–48.
- [19] Chen CH, Grollman AP, Huang CY, et al. Additive effects of arsenic and aristolochic acid in chemical carcinogenesis of upper urinary tract urothelium. *Cancer Epidemiol Biomarkers Prev* 2021;30:317–25.
- [20] Zaitso M, Kawachi I, Takeuchi T, Kobayashi Y. Alcohol consumption and risk of upper-tract urothelial cancer. *Cancer Epidemiol* 2017;48:36–40.
- [21] Kiss B, Furrer MA, Wuethrich PY, Burkhard FC, Thalmann GN, Roth B. Stenting prior to cystectomy is an independent risk factor for upper urinary tract recurrence. *J Urol* 2017;198:1263–8.
- [22] Sountoulides P, Pyrgidis N, Brookman-May S, Mykoniatis I, Karasavvidis T, Hatzichristou D. Does ureteral stenting increase the risk of metachronous upper tract urothelial carcinoma in patients with bladder tumors? A systematic review and metaanalysis. *J Urol* 2021;205:956–66.

- [23] Ouzzane A, Ghoneim TP, Udo K, et al. Small cell carcinoma of the upper urinary tract (UUT-SCC): report of a rare entity and systematic review of the literature. *Cancer Treat Rev* 2011;37:366–72.
- [24] Mori K, Janisch F, Kardoust Parizi M, et al. Prognostic value of variant histology in upper tract urothelial carcinoma treated with nephroureterectomy: a systematic review and meta-analysis. *J Urol* 2020;203:1075–84.
- [25] Perez-Montiel D, Wakely PE, Hes O, Michal M, Suster S. High-grade urothelial carcinoma of the renal pelvis: clinicopathologic study of 108 cases with emphasis on unusual morphologic variants. *Mod Pathol* 2006;19:494–503.
- [26] Kim JK, Moon KC, Jeong CW, Kwak C, Kim HH, Ku JH. Variant histology as a significant predictor of survival after radical nephroureterectomy in patients with upper urinary tract urothelial carcinoma. *Urol Oncol* 2017;35:458.e9–e15.
- [27] Soukup V, Čapoun O, Cohen D, et al. Prognostic performance and reproducibility of the 1973 and 2004/2016 World Health Organization grading classification systems in non-muscleinvasive bladder cancer: a European Association of Urology Nonmuscle Invasive Bladder Cancer Guidelines Panel systematic review. *Eur Urol* 2017;72:801–13.
- [28] Subiela JD, Territo A, Mercadé A, et al. Diagnostic accuracy of ureteroscopic biopsy in predicting stage and grade at final pathology in upper tract urothelial carcinoma: systematic review and meta-analysis. *Eur J Surg Oncol* 2020;46:1989–97.
- [29] Brierley JD, Gospodarowicz M, Wittekind C. *TNM classification of malignant tumours*. ed. 8. Chichester, UK: Wiley-Blackwell; 2016.
- [30] WHO Classification of Tumours Editorial Board. *Urinary and male genital tumours*. WHO classification of tumours, volume 8. ed. 5. Lyon, France: IARC; 2022.
- [31] Fujii Y, Sato Y, Suzuki H, et al. Molecular classification and diagnostics of upper urinary tract urothelial carcinoma. *Cancer Cell* 2021;39:793–809.e8.
- [32] Inman BA, Tran VT, Fradet Y, Lacombe L. Carcinoma of the upper urinary tract: predictors of survival and competing causes of mortality. *Cancer* 2009;115:2853–62.
- [33] Cowan NC. CT urography for hematuria. *Nat Rev Urol* 2012;9:218–26.
- [34] Baard J, Cormio L, Cavadas V, et al. Contemporary patterns of presentation, diagnostics and management of upper tract urothelial cancer in 101 centres: the Clinical Research Office of the Endourological Society Global upper tract urothelial carcinoma registry. *Curr Opin Urol* 2021;31:354–62.
- [35] Cowan NC, Turney BW, Taylor NJ, McCarthy CL, Crew JP. Multidetector computed tomography urography for diagnosing upper urinary tract urothelial tumour. *BJU Int* 2007;99:1363–70.
- [36] Janisch F, Shariat SF, Baltzer P, et al. Diagnostic performance of multidetector computed tomographic (MDCTU) in upper tract urothelial carcinoma (UTUC): a systematic review and metaanalysis. *World J Urol* 2020;38:1165–75.
- [37] Takahashi N, Glockner JF, Hartman RP, et al. Gadolinium enhanced magnetic resonance urography for upper urinary tract malignancy. *J Urol* 2010;183:1330–65.
- [38] Razavi SA, Sadigh G, Kelly AM, Cronin P. Comparative effectiveness of imaging modalities for the diagnosis of upper and lower urinary tract malignancy: a critically appraised topic. *Acad Radiol* 2012;19:1134–40.
- [39] Voskuilen CS, Schweitzer D, Jensen JB, et al. Diagnostic value of 18F-fluorodeoxyglucose positron emission tomography with computed tomography for lymph node staging in patients with upper tract urothelial carcinoma. *Eur Urol Oncol* 2020;3: 73–9.
- [40] Cosentino M, Palou J, Gaya JM, Breda A, Rodriguez-Faba O, Villavicencio-Mavrich H. Upper urinary tract urothelial cell carcinoma: location as a predictive factor for concomitant bladder carcinoma. *World J Urol* 2013;31:141–5.
- [41] Wojcik EM, Kurtycz DFI, Rosenthal DL, editors. *The Paris system for reporting urinary cytology*. Cham, Switzerland: Springer Nature; 2022.
- [42] Messer J, Shariat SF, Brien JC, et al. Urinary cytology has a poor performance for predicting invasive or high-grade upper-tract urothelial carcinoma. *BJU Int* 2011;108:701–5.

- [43] Malm C, Grahn A, Jaremko G, Tribukait B, Brehmer M. Diagnostic accuracy of upper tract urothelial carcinoma: how samples are collected matters. *Scand J Urol* 2017;51:137–45.
- [44] Messer JC, Terrell JD, Herman MP, et al. Multi-institutional validation of the ability of preoperative hydronephrosis to predict advanced pathologic tumor stage in upper-tract urothelial carcinoma. *Urol Oncol* 2013;31:904–8.
- [45] Lee KS, Zeikus E, DeWolf WC, Rofsky NM, Pedrosa I. MR urography versus retrograde pyelography/ureteroscopy for the exclusion of upper urinary tract malignancy. *Clin Radiol* 2010;65:185–92.
- [46] Rojas CP, Castle SM, Llanos CA, et al. Low biopsy volume in ureteroscopy does not affect tumor biopsy grading in upper tract urothelial carcinoma. *Urol Oncol* 2013;31:1696–700.
- [47] Ishikawa S, Abe T, Shinohara N, et al. Impact of diagnostic ureteroscopy on intravesical recurrence and survival in patients with urothelial carcinoma of the upper urinary tract. *J Urol* 2010;184:883–7.
- [48] Clements T, Messer JC, Terrell JD, et al. High-grade ureteroscopic biopsy is associated with advanced pathology of upper-tract urothelial carcinoma tumors at definitive surgical resection. *J Endourol* 2012;26:398–402.
- [49] Brien JC, Shariat SF, Herman MP, et al. Preoperative hydronephrosis, ureteroscopic biopsy grade and urinary cytology can improve prediction of advanced upper tract urothelial carcinoma. *J Urol* 2010;184:69–73.
- [50] Sharma V, Miest TS, Juvet TS, et al. The impact of upper tract urothelial carcinoma diagnostic modality on intravesical recurrence after radical nephroureterectomy: a single institution series and updated meta-analysis. *J Urol* 2021;206:558–67.
- [51] Kim HS, Jeong CW, Kwak C, Kim HH, Ku JH. Association between demographic factors and prognosis in urothelial carcinoma of the upper urinary tract: a systematic review and meta-analysis. *Oncotarget* 2017;8:7464–76.
- [52] Mori K, Mostafaei H, Enikeev DV, et al. Differential effect of sex on outcomes after radical surgery for upper tract and bladder urothelial carcinoma: a systematic review and meta-analysis. *J Urol* 2020;204:58–62.
- [53] Collà Ruvolo C, Nocera L, Stolzenbach LF, et al. Incidence and survival rates of contemporary patients with invasive upper tract urothelial carcinoma. *Eur Urol Oncol* 2021;4:792–801.
- [54] Matsumoto K, Novara G, Gupta A, et al. Racial differences in the outcome of patients with urothelial carcinoma of the upper urinary tract: an international study. *BJU Int* 2011;108:E304–9.
- [55] Kaczmarek K, Lemin´ski A, Goła¸b A, Słojewski M. Survival differences of patients with ureteral versus pelvicalyceal tumours: a systematic review and meta-analysis. *Arch Med Sci* 2021;17:603–12.
- [56] Lwin AA, Hsu CH, Chipollini J. Urothelial carcinoma of the renal pelvis and ureter: does location make a difference? *Clin Genitourin Cancer* 2020;18:45–49.e1.
- [57] Foerster B, Abufaraj M, Mari A, et al. The performance of tumor size as risk stratification parameter in upper tract urothelial carcinoma (UTUC). *Clin Genitourin Cancer* 2021;19:272.e1–e7.
- [58] Lindner AK, Schachtner G, Tulchiner G, et al. Lynch syndrome: its impact on urothelial carcinoma. *Int J Mol Sci* 2021;22:531.
- [59] Rink M, Xylinas E, Margulis V, et al. Impact of smoking on oncologic outcomes of upper tract urothelial carcinoma after radical nephroureterectomy. *Eur Urol* 2013;63:1082–90.
- [60] Xylinas E, Kluth LA, Rieken M, et al. Impact of smoking status and cumulative exposure on intravesical recurrence of upper tract urothelial carcinoma after radical nephroureterectomy. *BJU Int* 2014;114:56–61.
- [61] Raza SJ, Miller C, May A, Davaro F, Siddiqui SA, Hamilton Z. Lymph node density for stratification of survival outcomes with node positive upper tract urothelial carcinoma. *Can J Urol* 2019;26:9852–8.
- [62] Nazzani S, Mazzone E, Preisser F, et al. Rates of lymph node invasion and their impact on cancer specific mortality in upper urinary tract urothelial carcinoma. *Eur J Surg Oncol* 2019;45:1238–45.

- [63] Waldert M, Karakiewicz PI, Raman JD, et al. A delay in radical nephroureterectomy can lead to upstaging. *BJU Int* 2010;105:812–7.
- [64] Xia L, Taylor BL, Pulido JE, Guzzo TJ. Impact of surgical waiting time on survival in patients with upper tract urothelial carcinoma: a National Cancer Database study. *Urol Oncol* 2018;36:10.e15– .
- [65] Liu W, Sun L, Guan F, Wang F, Zhang G. Prognostic value of lymphovascular invasion in upper urinary tract urothelial carcinoma after radical nephroureterectomy: a systematic review and meta-analysis. *Dis Markers* 2019;2019:7386140.
- [66] Kluth LA, Xylinas E, Kent M, et al. Predictors of survival in patients with disease recurrence after radical nephroureterectomy. *BJU Int* 2014;113:911–7.
- [67] Aziz A, Fritsche HM, Gakis G. Comparative analysis of comorbidity and performance indices for prediction of oncological outcomes in patients with upper tract urothelial carcinoma who were treated with radical nephroureterectomy. *Urol Oncol* 2014;32:1141–50.
- [68] Colin P, Ouzzane A, Yates DR, et al. Influence of positive surgical margin status after radical nephroureterectomy on upper urinary tract urothelial carcinoma survival. *Ann Surg Oncol* 2012;19:3613–20.
- [69] Scarpini S, Rouprêt M, Renard-Penna R, Camparo P, Cussenot O, Compérat E. Impact of the expression of Aurora-A, p53, and MIB-1 on the prognosis of urothelial carcinomas of the upper urinary tract. *Urol Oncol* 2012;30:182–7.
- [70] Seisen T, Colin P, Hupertan V, et al. Postoperative nomogram to predict cancer-specific survival after radical nephroureterectomy in patients with localised and/or locally advanced upper tract urothelial carcinoma without metastasis. *BJU Int* 2014;114:733–40.
- [71] Yoshida T, Kobayashi T, Kawaura T, et al. Development and external validation of a preoperative nomogram for predicting pathological locally advanced disease of clinically localized upper urinary tract carcinoma. *Cancer Med* 2020;9:3733–41.
- [72] Krabbe LM, Eminaga O, Shariat SF, et al. Postoperative nomogram for relapse-free survival in patients with high grade upper tract urothelial carcinoma. *J Urol* 2017;197:580–9.
- [73] Zhang GL, Zhou W. A model for the prediction of survival in patients with upper tract urothelial carcinoma after surgery. *Dose Response* 2019;17.
- [74] Seisen T, Granger B, Colin P, et al. A systematic review and metaanalysis of clinicopathologic factors linked to intravesical recurrence after radical nephroureterectomy to treat upper tract urothelial carcinoma. *Eur Urol* 2015;67:1122–33.
- [75] Zhang X, Bu R, Liu Z, Wu B, Bai S. Development and validation of a model for predicting intravesical recurrence in organ-confined upper urinary tract urothelial carcinoma patients after radical nephroureterectomy: a retrospective study in one center with long-term follow-up. *Pathol Oncol Res* 2020;26:1741–8.
- [76] Sheu ZL, Huang CP, Chang CH, et al. Tumor distribution affects bladder recurrence but not survival outcome of multifocal upper tract urothelial carcinoma treated with radical nephroureterectomy. *Sci Rep* 2021;11:19059.
- [77] Guo RQ, Hong P, Xiong GY, et al. Impact of ureteroscopy before radical nephroureterectomy for upper tract urothelial carcinomas on oncological outcomes: a meta-analysis. *BJU Int* 2018;121:184–93.
- [78] Seisen T, Peyronnet B, Dominguez-Escrig JL, et al. Oncologic outcomes of kidney-sparing surgery versus radical nephroureterectomy for upper tract urothelial carcinoma: a systematic review by the EAU non–muscle invasive bladder cancer guidelines panel. *Eur Urol* 2016;70:1052–68.
- [79] Villa L, Cloutier J, Letendre J, et al. Early repeated ureteroscopy within 6–8 weeks after a primary endoscopic treatment in patients with upper tract urothelial cell carcinoma: preliminary findings. *World J Urol* 2016;34:1201–6.
- [80] Vemana G, Kim EH, Bhayani SB, Vetter JM, Strobe SA. Survival comparison between endoscopic and surgical management for patients with upper tract urothelial cancer: a matched propensity score analysis using Surveillance, Epidemiology and End Results/Medicare data. *Urology* 2016;95:115–20.

- [81] Roupret M, Traxer O, Tligui M, et al. Upper urinary tract transitional cell carcinoma: recurrence rate after percutaneous endoscopic resection. *Eur Urol* 2007;51:709–13.
- [82] Jeldres C, Lughezzani G, Sun M, et al. Segmental ureterectomy can safely be performed in patients with transitional cell carcinoma of the ureter. *J Urol* 2010;183:1324–9.
- [83] Colin P, Ouzzane A, Pignot G, et al. Comparison of oncological outcomes after segmental ureterectomy or radical nephroureterectomy in urothelial carcinomas of the upper urinary tract: results from a large French multicentre study. *BJU Int* 2012;110:1134–41.
- [84] Marin SF, Pierorazio PM, Kleinmann N, et al. Durability of response to primary chemoablation of low-grade upper tract urothelial carcinoma using UGN-101, a mitomycin-containing reverse thermal gel: OLYMPUS trial final report. *J Urol* 2022;207:779–88.
- [85] Foerster B, D’Andrea D, Abufaraj M, et al. Endocavitary treatment for upper tract urothelial carcinoma: a meta-analysis of the current literature. *Urol Oncol* 2019;37:430–6.
- [86] Roupret M, Smyth G, Irani J, et al. Oncological risk of laparoscopic surgery in urothelial carcinomas. *World J Urol* 2009;27:81–8.
- [87] Peyronnet B, Seisen T, Dominguez-Escrig JL, et al. Oncological outcomes of laparoscopic nephroureterectomy versus open radical nephroureterectomy for upper tract urothelial carcinoma: an European Association of Urology Guidelines systematic review. *Eur Urol Focus* 2019;5:205–23.
- [88] Favaretto RL, Shariat SF, Chade DC, et al. Comparison between laparoscopic and open radical nephroureterectomy in a contemporary group of patients: are recurrence and disease-specific survival associated with surgical technique? *Eur Urol* 2010;58:645–51.
- [89] Walton TJ, Novara G, Matsumoto K, et al. Oncological outcomes after laparoscopic and open radical nephroureterectomy: results from an international cohort. *BJU Int* 2011;108:406–12.
- [90] Ni S, Tao W, Chen Q, et al. Laparoscopic versus open nephroureterectomy for the treatment of upper urinary tract urothelial carcinoma: a systematic review and cumulative analysis of comparative studies. *Eur Urol* 2012;61:1142–53.
- [91] Adibi M, Youssef R, Shariat SF, et al. Oncological outcomes after radical nephroureterectomy for upper tract urothelial carcinoma: comparison over the three decades. *Int J Urol* 2012;19:1060–6.
- [92] Clements MB, Krupski TL, Culp SH. Robotic-assisted surgery for upper tract urothelial carcinoma: a comparative survival analysis. *Ann Surg Oncol* 2018;25:2550–62.
- [93] Aboumohamed AA, Krane LS, Hemal AK. Oncologic outcomes following robot-assisted laparoscopic nephroureterectomy with bladder cuff excision for upper tract urothelial carcinoma. *J Urol* 2015;194:1561–6.
- [94] Xylinas E, Kluth L, Passoni N, et al. Prediction of intravesical recurrence after radical nephroureterectomy: development of a clinical decision-making tool. *Eur Urol* 2014;65:650–8.
- [95] Kondo T, Hashimoto Y, Kobayashi H, et al. Template-based lymphadenectomy in urothelial carcinoma of the upper urinary tract: impact on patient survival. *Int J Urol* 2010;17:848–54.
- [96] Dominguez-Escrig JL, Peyronnet B, Seisen T, et al. Potential benefit of lymph node dissection during radical nephroureterectomy for upper tract urothelial carcinoma: a systematic review by the European Association of Urology guidelines panel on non-muscle-invasive bladder cancer. *Eur Urol Focus* 2019;5:224–41.
- [97] Zareba P, Rosenzweig B, Winer AG, Coleman JA. Association between lymph node yield and survival among patients undergoing radical nephroureterectomy for urothelial carcinoma of the upper tract. *Cancer* 2017;123:1741–50.
- [98] Xylinas E, Kluth L, Rieken M, et al. External validation of the pathological nodal staging score in upper tract urothelial carcinoma: a population-based study. *Urol Oncol* 2017;35:33. e21–e26.
- [99] Leow JJ, Chong YL, Chang SL, Valderrama BP, Powles T, Bellmunt J. Neoadjuvant and adjuvant chemotherapy for upper tract urothelial carcinoma: a 2020 systematic review and metaanalysis, and future perspectives on systemic therapy. *Eur Urol* 2021;79:635–54.
- [100] Necchi A, Martini A, Raggi D, et al. A feasibility study of preoperative pembrolizumab before radical nephroureterectomy in patients with high-risk, upper tract urothelial carcinoma: PURE02. *Urol Oncol* 2022;40:10.e1–e6.

- [101] Xylinas E, Rink M, Cha EK, et al. Impact of distal ureter management on oncologic outcomes following radical nephroureterectomy for upper tract urothelial carcinoma. *Eur Urol* 2014;65:210–7.
- [102] O’Brien T, Ray E, Singh R, Coker B, Beard R. British Association of Urological Surgeons Section of Oncology. Prevention of bladder tumours after nephroureterectomy for primary upper urinary tract urothelial carcinoma: a prospective, multicentre, randomised clinical trial of a single postoperative intravesical dose of mitomycin C (the ODMIT-C Trial). *Eur Urol* 2011;60:703–10.
- [103] Ito A, Shintaku I, Satoh M, et al. Prospective randomized phase II trial of a single early intravesical instillation of pirarubicin (THP) in the prevention of bladder recurrence after nephroureterectomy for upper urinary tract urothelial carcinoma: the THP Monotherapy Study Group Trial. *J Clin Oncol* 2013;31:1422–7.
- [104] Hwang EC, Sathianathen NJ, Jung JH, Kim MH, Dahm P, Risk MC. Single-dose intravesical chemotherapy after nephroureterectomy for upper tract urothelial carcinoma. *Cochrane Database Syst Rev* 2019;2019:CD013160.
- [105] Fang D, Li XS, Xiong GY, Yao L, He ZS, Zhou LQ. Prophylactic intravesical chemotherapy to prevent bladder tumors after nephroureterectomy for primary upper urinary tract urothelial carcinomas: a systematic review and meta-analysis. *Urol Int* 2013;91:291–6.
- [106] Freifeld Y, Ghandour R, Singla N, et al. Intraoperative prophylactic intravesical chemotherapy to reduce bladder recurrence following radical nephroureterectomy. *Urol Oncol* 2020;38:737.e11–e16.
- [107] Harraz AM, El-Shabrawy M, El-Nahas AR, El-Kappany H, Osman Y. Single versus maintenance intravesical chemotherapy for the prevention of bladder recurrence after radical nephroureterectomy for upper tract urothelial carcinoma: a randomized clinical trial. *Clin Genitourin Cancer* 2019;17: e1108–15.
- [108] Birtle A, Johnson M, Chester J, et al. Adjuvant chemotherapy in upper tract urothelial carcinoma (the POUT trial): a phase 3, openlabel, randomised controlled trial. *Lancet* 2020;395:1268–77.
- [109] Kaag MG, O’Malley RL, O’Malley P, et al. Changes in renal function following nephroureterectomy may affect the use of perioperative chemotherapy. *Eur Urol* 2010;58:581–7.
- [110] Bajorin DF, Witjes JA, Gschwend JE, et al. Adjuvant nivolumab versus placebo in muscle-invasive urothelial carcinoma. *N Engl J Med* 2021;384:2102–14.
- [111] European Medicines Agency. European Commission approval for Opdivo (nivolumab) as adjuvant treatment for patients with radically resected, high-risk muscle-invasive urothelial carcinoma with tumor cell PD-L1 expression 1%. Amsterdam, The Netherlands: EMA; 2022.
- [112] Laukhtina E, Motlagh RS, Mori K, et al. Chemotherapy is superior to checkpoint inhibitors after radical surgery for urothelial carcinoma: a systematic review and network meta-analysis of oncologic and toxicity outcomes. *Crit Rev Oncol Hematol* 2022;169:103570.
- [113] Iwata T, Kimura S, Abufaraj M, et al. The role of adjuvant radiotherapy after surgery for upper and lower urinary tract urothelial carcinoma: a systematic review. *Urol Oncol* 2019;37:659–71.
- [114] Powles T, Park SH, Voog E, et al. Avelumab maintenance therapy for advanced or metastatic urothelial carcinoma. *N Engl J Med* 2020;383:1218–30.
- [115] Piontkowski AJ, Corsi N, Morisettey S, et al. Benefit of lymph node dissection in cN+ patients in the treatment of upper tract urothelial carcinoma: analysis of NCDB registry. *Urol Oncol* 2022;40:409.e9–e17.
- [116] Shigeta K, Matsumoto K, Ogihara K, et al. Does neoadjuvant chemotherapy have therapeutic benefit for node-positive upper tract urothelial carcinoma? Results of a multi-center cohort study. *Urol Oncol* 2022;40:105.e19–e26.
- [117] Witjes JA, Bruins HM, Carrión A, et al. EAU guidelines on muscle-invasive and metastatic bladder cancer. Arnhem, The Netherlands: European Association of Urology; 2023.
- [118] Moschini M, Shariat SF, Rouprêt M, et al. Impact of primary tumor location on survival from the European Organization for the Research and Treatment of Cancer advanced urothelial cancer studies. *J Urol* 2018;199:1149–57.

- [119] Gust KM, Resch I, D'Andrea D, Shariat SF. Update on systemic treatment of upper tract urothelial carcinoma: a narrative review of the literature. *Transl Androl Urol* 2021;10:4051–61.
- [120] Powles T, Czoszi T, Özgüroğ } ˘lu M, et al. Pembrolizumab alone or combined with chemotherapy versus chemotherapy as first-line therapy for advanced urothelial carcinoma (KEYNOTE-361): a randomised, open-label, phase 3 trial. *Lancet Oncol* 2021;22:931–45.
- [121] Galsky MD, Arija JÁA, Bamias A, et al. Atezolizumab with or without chemotherapy in metastatic urothelial cancer (IMvigor130): a multicentre, randomised, placebo-controlled phase 3 trial. *Lancet* 2020;395:1547–57.
- [122] Powles T, van der Heijden MS, Castellano D, et al. Durvalumab alone and durvalumab plus tremelimumab versus chemotherapy in previously untreated patients with unresectable, locally advanced or metastatic urothelial carcinoma (DANUBE): a randomised, open-label, multicentre, phase 3 trial. *Lancet Oncol* 2020;21:1574–88.
- [123] De Santis M, Bellmunt J, Mead G, et al. Randomized phase II/III trial assessing gemcitabine/carboplatin and methotrexate/carboplatin/vinblastine in patients with advanced urothelial cancer who are unfit for cisplatin-based chemotherapy: EORTC study 30986. *J Clin Oncol* 2012;30:191–9.
- [124] Richters A, Kiemeny LA, Mehra N, et al. Evidence or prejudice? Critical re-analysis of randomized controlled trials comparing overall survival after cisplatin versus carboplatin-based regimens in advanced urothelial carcinoma. *Clin Genitourin Cancer* 2022;20:e346–52.
- [125] Powles T, Park SH, Voog E, et al. Maintenance avelumab + best supportive care (BSC) versus BSC alone after platinum-based firstline (1L) chemotherapy in advanced urothelial carcinoma (UC): JAVELIN Bladder 100 phase III interim analysis. *J Clin Oncol* 2020;38(18 Suppl):LBA1.
- [126] Vuky J, Balar AV, Castellano D, et al. Long-term outcomes in KEYNOTE-052: phase II study investigating first-line pembrolizumab in cisplatin-ineligible patients with locally advanced or metastatic urothelial cancer. *J Clin Oncol* 2020;38:2658–66.
- [127] Balar AV, Galsky MD, Rosenberg JE, et al. Atezolizumab as first-line treatment in cisplatin-ineligible patients with locally advanced and metastatic urothelial carcinoma: a single-arm, multicentre, phase 2 trial. *Lancet* 2017;389:67–76.
- [128] Bellmunt J, de Wit R, Vaughn DJ, et al. Pembrolizumab as secondline therapy for advanced urothelial carcinoma. *N Engl J Med* 2017;376:1015–26.
- [129] Sharma P, Retz M, Siefker-Radtke A, et al. Nivolumab in metastatic urothelial carcinoma after platinum therapy (CheckMate 275): a multicentre, single-arm, phase 2 trial. *Lancet Oncol* 2017;18:312–22.
- [130] Patel MR, Ellerton J, Infante JR, et al. Avelumab in metastatic urothelial carcinoma after platinum failure (JAVELIN Solid Tumor): pooled results from two expansion cohorts of an openlabel, phase 1 trial. *Lancet Oncol* 2018;19:51–64.
- [131] Apolo AB, Infante JR, Balmanoukian A, et al. Avelumab, an antiprogrammed death-ligand 1 antibody, in patients with refractory metastatic urothelial carcinoma: results from a multicenter, phase Ib study. *J Clin Oncol* 2017;35:2117–24.
- [132] Powles T, O'Donnell PH, Massard C, et al. Efficacy and safety of durvalumab in locally advanced or metastatic urothelial carcinoma: updated results from a phase 1/2 open-label study. *JAMA Oncol* 2017;3:e172411.
- [133] Sharma P, Siefker-Radtke A, de Braud F, et al. Nivolumab alone and with ipilimumab in previously treated metastatic urothelial carcinoma: CheckMate 032 nivolumab 1 mg/kg plus ipilimumab 3 mg/kg expansion cohort results. *J Clin Oncol* 2019;37:1608–16.
- [134] Loriot Y, Necchi A, Park SH, et al. Erdafitinib in locally advanced or metastatic urothelial carcinoma. *N Engl J Med* 2019;381:338–48.
- [135] Powles T, Rosenberg JE, Sonpavde GP, et al. Enfortumab vedotin in previously treated advanced urothelial carcinoma. *N Engl J Med* 2021;384:1125–35.

- [136] Tagawa ST, Balar AV, Petrylak DP, et al. TROPHY-U-01: a phase II open-label study of sacituzumab govitecan in patients with metastatic urothelial carcinoma progressing after platinum-based chemotherapy and checkpoint inhibitors. *J Clin Oncol* 2021;39:2474–85.
- [137] Drakaki A, Kirby CJ, van der Heijden MS, et al. Docetaxel with or without ramucirumab after platinum-based chemotherapy and checkpoint inhibitors in advanced urothelial carcinoma: a prespecified subgroup analysis from the phase 3 RANGE trial. *Bladder Cancer* 2020;6:43–52.
- [138] Moschini M, Xylinas E, Zamboni S, et al. Efficacy of surgery in the primary tumor site for metastatic urothelial cancer: analysis of an international, multicenter, multidisciplinary database. *Eur Urol Oncol* 2020;3:94–101.
- [139] Nazzani S, Preisser F, Mazzone E, et al. Survival effect of nephroureterectomy in metastatic upper urinary tract urothelial carcinoma. *Clin Genitourin Cancer* 2019;17:e602–11.
- [140] Seisen T, Jindal T, Karabon P, et al. Efficacy of systemic chemotherapy plus radical nephroureterectomy for metastatic upper tract urothelial carcinoma. *Eur Urol* 2017;71:714–8.
- [141] Simsir A, Sarsik B, Cureklibatir I, Sen S, Gunaydin G, Cal C. Prognostic factors for upper urinary tract urothelial carcinomas: stage, grade, and smoking status. *Int Urol Nephrol* 2011;43:1039–45.
- [142] Öge O, Erdem E, Atsü N, Sahin A, Özen H. Proposal for changes in cystoscopic follow-up of patients with low-grade pTa bladder tumor. *Eur Urol* 2000;37:271–4.
- [143] Holmäng S, Johansson SL. Bilateral metachronous ureteral and renal pelvic carcinomas: incidence, clinical presentation, histopathology, treatment and outcome. *J Urol* 2006;175:69–72.
- [144] Shigeta K, Kikuchi E, Hagiwara M, et al. The conditional survival with time of intravesical recurrence of upper tract urothelial carcinoma. *J Urol* 2017;198:1278–85.
- [145] Martini A, Lonati C, Nocera L, et al. Oncologic surveillance after radical nephroureterectomy for high-risk upper tract urothelial carcinoma. *Eur Urol Oncol* 2022;5:451–9.
- [146] Holmäng S, Johansson SL. Long-term follow-up of patients with tumours of the renal pelvis and ureter: how often is a bladder tumour diagnosed after five tumour-free years? *Scand J Urol* 2014;48:65–72.
- [147] Mandalapu RS, Remzi M, de Reijke TM, et al. Update of the ICUDSIU consultation on upper tract urothelial carcinoma 2016: treatment of low-risk upper tract urothelial carcinoma. *World J Urol* 2017;35:355–65.
- [148] Mohapatra A, Strobe SA, Liu N, et al. Importance of long-term follow-up after endoscopic management for upper tract urothelial carcinoma and factors leading to surgical management. *Int Urol Nephrol* 2020;52:1465–9.
- [149] Chouhan H, Abbass MA, Hrabe JE, et al. Evaluation of urinalysis-based screening for urothelial carcinoma in patients with Lynch syndrome. *Dis Colon Rectum* 2022;65:40–5.
- [150] Myrhøj T, Andersen MB, Bernstein I. Screening for urinary tract cancer with urine cytology in Lynch syndrome and familial colorectal cancer. *Fam Cancer* 2008;7:303–7.

Table 1. Guidelines on epidemiology, aetiology, and pathology

Recommendation	Strength rating
Evaluate patient and family history according to the Amsterdam criteria to identify patients with upper tract urothelial carcinoma.	Weak
Evaluate patient exposure to smoking and aristolochic acid.	Weak

Table 2. TNM 2017 classification for upper tract urothelial cell carcinoma [29]

T: primary tumour	
TX	Primary tumour cannot be assessed
T0	No evidence of primary tumour
Ta	Noninvasive papillary carcinoma
Tis	Carcinoma in situ
T1	Tumour invades the subepithelial connective tissue
T2	Tumour invades the muscularis
T3	Renal pelvis: Tumour invades beyond the muscularis into peripelvic fat or renal parenchyma Ureter: Tumour invades beyond the muscularis into periureteric fat
T4	Tumour invades adjacent organs or through the kidney into perinephric fat
N: regional lymph nodes	
NX	Regional lymph nodes cannot be assessed
N0	No regional lymph node metastasis
N1	Metastasis in a single lymph node 2 cm or less in greatest dimension
N2	Metastasis in a single lymph node more than 2 cm, or multiple lymph nodes
M: distant metastasis	
M0	No distant metastasis
M1	Distant metastasis

Table 3. Guidelines for UTUC diagnosis

Recommendation	Strength rating
Perform urethroscopy to rule out bladder tumour.	Strong
Perform CT urography for diagnosis and staging.	Strong
Use diagnostic ureteroscopy (preferably without biopsy) if imaging and/or voided urine cytology are not sufficient for the diagnosis and/or risk stratification of patients suspected to have UTUC.	Strong
Magnetic resonance urography or ¹⁸ F-FDG-PET/CT (to assess [nodal] metastasis) may be used when CT is contraindicated.	Weak

CT = computed tomography; ¹⁸F-FDG-PET = ¹⁸F-fluorodeoxyglucose positron emission tomography; UTUC = upper tract urothelial carcinoma.

Table 4. Patient- and tumour-related prognostic factors

Patient-related factors	Tumour-related factors
<i>Age and gender:</i> Older age at the time of RNU is independently associated with lower CSS [51] (LE: 3). Gender has no impact on UTUC prognosis [52].	<i>Tumour stage and grade:</i> The main prognostic factors are tumour stage and grade [53]. UTUCs that invade the muscle wall have poor prognosis.
<i>Ethnicity:</i> One multicentre study in academic centres did not show any difference in outcomes between races [54], but US population-based studies have indicated that African-American patients have worse outcomes than patients of other ethnicities (LE: 3). Whether this is related to access to care or biological and/or patterns of care remains unknown.	<i>Tumour location, multifocality, size, and hydronephrosis:</i> Patients with ureteral and/or multifocal tumours seem to have worse prognosis than patients diagnosed with renal pelvic tumours [55], [56]. Hydronephrosis is associated with advanced disease and poor oncological outcome [44]. Increasing tumour size is associated with a higher risk of muscle-invasive and/or non-organ-confined disease [57].
<i>Genetic predisposition:</i> Patients who test positive for Lynch syndrome on immunohistochemistry (microsatellite instability testing for all 4 markers) have a genetic predisposition to UTUC [58].	<i>Pathological subtypes:</i> Pathological subtypes are associated with worse CSS and overall survival [24] (LE: 3).
<i>Tobacco consumption:</i> Being a smoker at diagnosis increases the risk of disease recurrence, mortality [59], and intravesical recurrence after RNU [60] (LE: 3). Smoking cessation improves cancer control [59].	<i>LN involvement:</i> Patients with nodal metastasis have very poor survival after surgery and LN density (cutoff 30%) and extranodal extension are powerful predictors of survival outcomes in N+ UTUC [61]. LN dissection performed at the time of RNU allows for

Patient-related factors	Tumour-related factors
<p><i>Surgical delay:</i> A delay between diagnosis of an invasive tumour and its removal may increase the risk of disease progression. RNU should be carried out within 12 wk after diagnosis, when possible [63], [64] (LE: 3).</p> <p><i>Other factors:</i> High comorbidity and performance index scores (eg, American Society of Anesthesiologists score, performance status, and Charlson comorbidity index) can point to worse survival outcomes across disease stages [66], [67].</p>	<p>optimal tumour staging, although its curative role remains controversial [62] (LE: 3).</p> <p><i>Lymphovascular invasion:</i> Lymphovascular invasion is present in approximately 20% of invasive UTUCs and is an independent predictor of survival [65] (LE: 3).</p> <p><i>Surgical margins:</i> A positive soft-tissue surgical margin is associated with higher disease recurrence after RNU [68] (LE: 3).</p>

CSS = cancer-specific survival; LE = level of evidence; LN = lymph node; RNU = radical nephroureterectomy; UTUC = upper tract urothelial carcinoma.

Table 5. Guidelines for upper tract urothelial carcinoma prognosis

Recommendation	Strength rating
Use prognostic factors to risk-stratify patients for therapeutic guidance.	Weak

Table 6. Guidelines for the management of UTUC

Recommendation	Strength rating
Low-risk localised disease	
Offer kidney-sparing management as a primary treatment option to patients with low-risk tumours.	Strong
High-risk nonmetastatic disease	
Perform RNU in patients with high-risk nonmetastatic UTUC.	Strong
Perform open RNU in non-organ-confined UTUC.	Weak
Perform a template-based lymphadenectomy in patients with high-risk nonmetastatic UTUC.	Weak
Offer adjuvant platinum-based chemotherapy after RNU to patients with pT2–4 and/or pN+ disease.	Strong

Recommendation	Strength rating
Deliver a postoperative bladder instillation of chemotherapy to lower the intravesical recurrence rate.	Strong
Discuss adjuvant nivolumab with patients unfit for, or who decline, platinum-based adjuvant chemotherapy for \geq pT3 and/or pN+ disease after RNU alone, or \geq ypT2 and/or ypN+ disease after neoadjuvant chemotherapy, followed by RNU.	Weak
Offer distal ureterectomy to selected patients with high-risk tumours limited to the distal ureter.	Weak
Offer kidney-sparing management to high-risk patients with imperative indication on a case-by-case basis, in consultation with the patient.	Strong
Metastatic disease	
<i>First-line treatment for platinum-eligible patients</i>	
Offer platinum combination chemotherapy to platinum-eligible patients.	Strong
Offer cisplatin-based chemotherapy with gemcitabine/cisplatin or HD-MVAC to cisplatin-eligible patients.	Strong
Offer maintenance avelumab to patients who did not have disease progression after 4–6 cycles of gemcitabine plus cisplatin/carboplatin.	Strong
<i>First-line treatment in patients ineligible for cisplatin or carboplatin</i>	
Offer gemcitabine/carboplatin chemotherapy to cisplatin-ineligible patients.	Strong
Offer a checkpoint inhibitor (pembrolizumab or atezolizumab) to patients with PD-L1–positive tumours.	Weak
<i>Second-line treatment</i>	
Offer a checkpoint inhibitor (pembrolizumab) to patients with disease progression during or after platinum-based combination chemotherapy for metastatic disease.	Strong
Offer enfortumab vedotin to patients previously treated with platinum-containing chemotherapy and who had disease progression during or after treatment with a PD-1 or PD-L1 inhibitor.	Strong
Only offer vinflunine to patients for metastatic disease as second-line treatment if immunotherapy or combination chemotherapy is not feasible. Alternatively, offer vinflunine as third- or subsequent-line treatment.	Strong
Offer erdafitinib as subsequent-line therapy to platinum-refractory patients with <i>FGFR</i> DNA genomic alterations (<i>FGFR2/3</i> mutations or <i>FGFR3</i> fusions).	Weak
Offer nephroureterectomy as a palliative treatment to symptomatic patients with resectable locally advanced tumours.	Weak

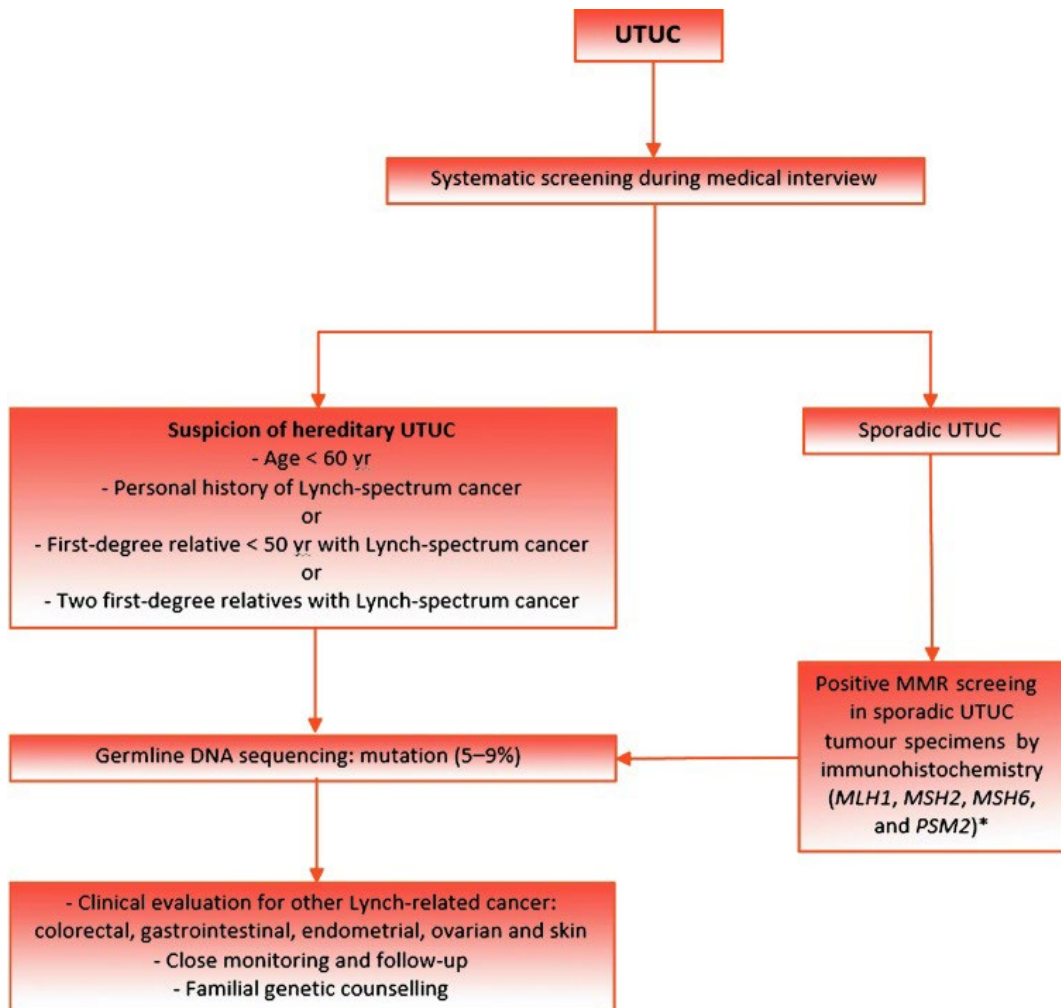
HD-MVAC = high-dose intensity methotrexate, vinblastine, adriamycin, and cisplatin; RNU = radical nephroureterectomy; UTUC = upper tract urothelial carcinoma.

Table 7. Guidelines for follow-up of UTUC

Recommendation	Strength rating
After RNU	
<i>Low-risk tumours</i>	
Perform cystoscopy at 3 mo. If negative, perform subsequent cystoscopy 9 mo later and then yearly for 5 yr.	Weak
<i>High-risk tumours</i>	
Perform cystoscopy and urinary cytology at 3 mo. If negative, repeat subsequent cystoscopy and cytology every 3 mo for a period of 2 yr, and every 6 mo thereafter up to 5 yr, and then yearly.	Weak
Perform CT urography and chest CT every 6 mo for 2 yr, and then yearly.	Weak
After kidney-sparing management	
<i>Low-risk tumours</i>	
Perform cystoscopy and CT urography at 3 and 6 mo, and then yearly for 5 yr.	Weak
Perform URS at 3 mo if no second-look URS was performed.	Weak
<i>High-risk tumours</i>	
Perform cystoscopy, urinary cytology, CT urography, and chest CT at 3 and 6 mo, and then yearly.	Weak

CT = computed tomography; RNU = radical nephroureterectomy; URS = ureteroscopy.

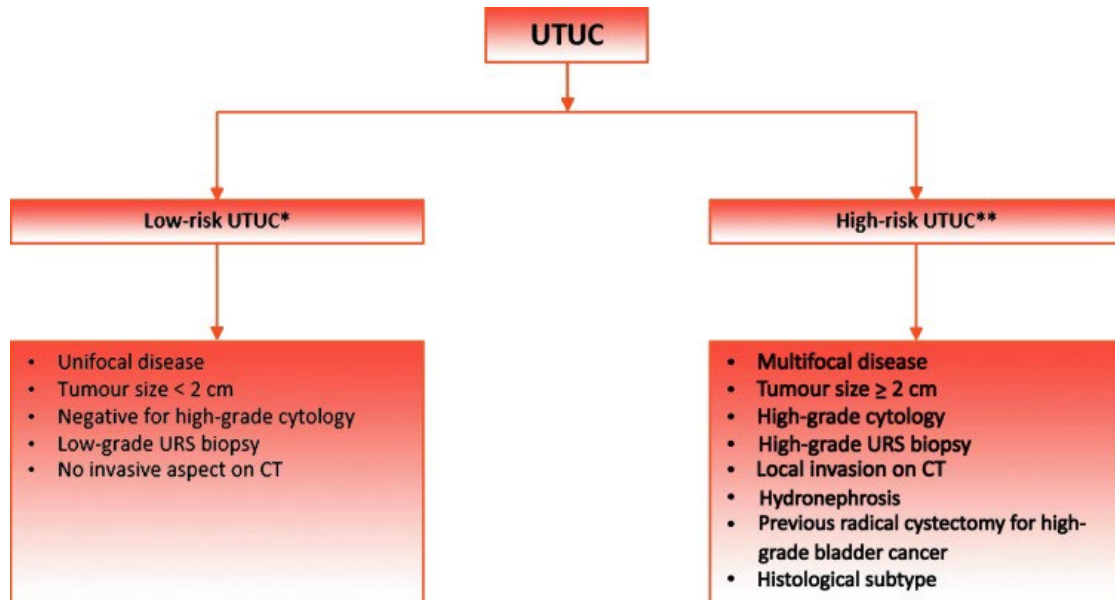
Figure 1. Selection of patients with upper tract urothelial carcinoma (UTUC) for Lynch syndrome screening during the first medical interview. MMR = mismatch repair. *Sporadic UTUC that for any reason has undergone MMR screening with a positive result should prompt subsequent testing for germline DNA sequencing mutations.



* Sporadic UTUC that for any reason has undergone MMR screening with a positive result should prompt subsequent testing for germline DNA sequencing mutations.

MMR = mismatch repair; mismatch repair genes = MLH1, MSH2, MSH6, and PSM2; UTUC = upper urinary tract urothelial carcinoma.

Figure 2. Risk stratification of nonmetastatic upper tract urothelial carcinoma (UTUC).
 CT = computed tomography; URS = ureteroscopy. *All of these factors need to be present. **Any one of these factors needs to be present.

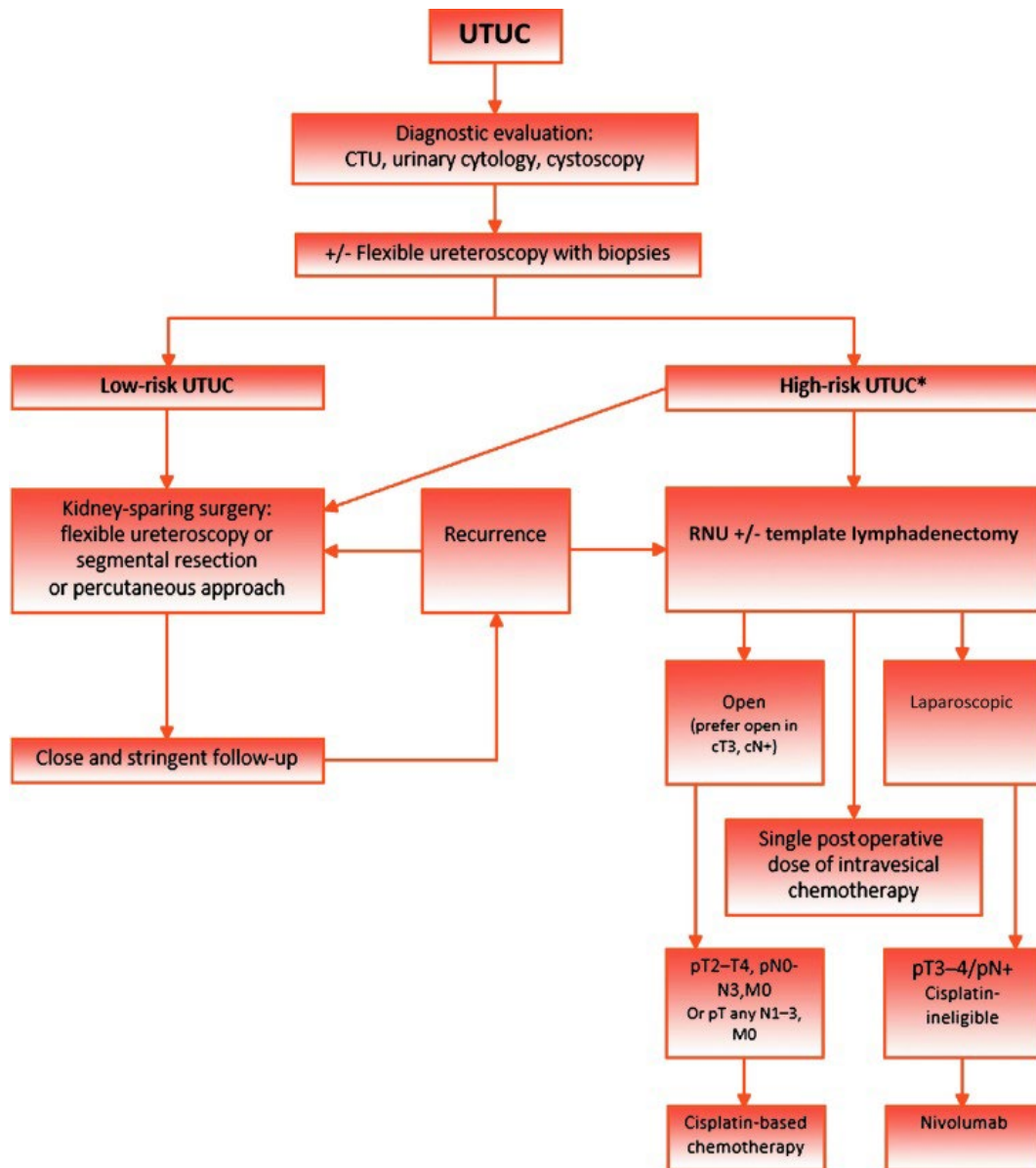


CT = computed tomography; URS = ureteroscopy; UTUC = upper urinary tract urothelial carcinoma.

** All these factors need to be present.*

***Any of these factors need to be present.*

Figure 3. Proposed flowchart for the management of upper tract urothelial carcinoma (UTUC). CTU = computed tomography urography; RNU = radical nephroureterectomy. *In patients with a solitary kidney, consider a more conservative approach.



*In patients with solitary kidney, consider a more conservative approach.
 CTU = computed tomography urography; RNU = radical nephroureterectomy;
 UTUC = upper urinary tract urothelial carcinoma.