

Sirolimus-related Systemic Thrombotic Microangiopathy after Renal Transplantation

Simone Negrini¹, Antoine Durrbach²
and Laurent Becquemont¹

1 Centre de Recherche clinique Paris-Sud, Le Kremlin-Bicêtre, France

2 Service de Néphrologie, Dialyse et Transplantation, IFRNT, Hôpital Bicêtre, Le Kremlin-Bicêtre, France

Text received July 5th, 2013; accepted December 3rd, 2013
The case was notified to the Regional Pharmacovigilance Center (CHU Henri Mondor, Créteil, France) in February 2013 (PC20130057)

Abstract – We describe the case of a renal transplant patient who developed *de novo* biopsy-proven thrombotic microangiopathy (TMA) and deep venous thrombosis after treatment with sirolimus (SRL). We discuss the clinical course, diagnosis and therapeutics of this patient in the context of the literature.

Keywords: sirolimus; venous thrombosis; thrombotic microangiopathy; renal transplantation

Résumé – Microangiopathie thrombotique systémique induite par le sirolimus en post-transplantation rénale. Nous décrivons ici le cas d'un patient greffé rénal qui a développé une microangiopathie thrombotique *de novo* et une thrombose veineuse profonde après traitement par sirolimus. Nous discutons l'évolution clinique, le diagnostic et la thérapie de ce patient dans le contexte de la littérature.

Mots clés : sirolimus ; thrombose veineuse ; microangiopathie thrombotique ; transplantation rénale

Abbreviations: see end of article.

1. Introduction

Sirolimus (SRL), also known as rapamycin, is an immunosuppressive agent commonly administered to renal transplant recipients since it is associated with less long-term nephrotoxicity than calcineurin inhibitors (CNIs).^[1]

SRL has been shown to be a highly effective immunosuppressive drug in preventing renal allograft rejection; nevertheless it may promote the occurrence of different adverse effects, most commonly hyperlipidemia and myelosuppression.^[1] In addition, post-marketing surveillance revealed a number of unpredicted adverse effects,

among which the occurrence of thrombotic events^[2,3] and acute thrombotic microangiopathy (TMA).^[4]

Here we report the case of a renal transplant recipient who developed *de novo* biopsy-proven systemic TMA and deep venous thrombosis following treatment with SRL.

2. Observation

A 65-year-old Caucasian male, with a history of left kidney nephrectomy for renal cell carcinoma (1999), developed end-stage renal disease due to progressive hypertensive nephrosclerosis on residual multicystic dysplastic kidney. The patient was maintained on hemodialysis for nearly 3 years prior to receiving a cadaveric renal transplant in June 2011. Initial immunosuppression therapy consisted of mycophenolate mofetil (MMF), tacrolimus and prednisone. Patient also received valacyclovir and co-trimoxazole for prophylaxis against cytomegalovirus and *Pneumocystis jirovecii* respectively. In December 2011 tacrolimus treatment was switched to SRL to avoid the long-term nephrotoxicity related to CNIs and in consideration of patient's history of malignant neoplasm. At the end of January 2012 patient reported pain, swelling, warmth and redness of the left leg of some days' duration. A deep venous thrombosis of soleal veins was diagnosed by color doppler and anticoagulant therapy was prescribed. Anticoagulant therapy consisted of subcutaneous low-molecular-weight heparin (enoxaparin) followed by warfarin, with the target being the international normalized ratio of 2.5. At the same time a hypercoagulability state was explored but thrombophilia screening (factor V Leiden mutation, antithrombin III, protein C, protein S and antiphospholipid antibodies) was normal. Two weeks later, in concomitance with routine examinations, a mild proteinuria was observed. Proteinuria progressively increased, reaching nephrotic range (5 g/24 hours) at the end of March with hypoalbuminemia (30 g/L) associated to a rise in weight of about 30 kg due to lower limb edema. Moreover serum creatinine gradually rose from 1.7 mg/dL to 3.4 mg/dL, consequently a renal allograft biopsy was performed. Based on histologic findings (figure 1), the patient was diagnosed with TMA which was not related to transplant rejection in the absence of C4d deposition and circulating donor-specific anti-HLA antibodies.

In the same days the patient complained of abdominal pain and hematochezia: a subsequent colonoscopy revealed a severe ischemic pancolitis most likely related to TMA (figure 2). Colon biopsies confirmed the diagnosis of TMA and histological findings included capillary thrombosis and perivascular hemorrhages.

During the evolution of the disease, there were no laboratory signs of mechanical hemolytic anemia: lactate dehydrogenase, bilirubin and haptoglobin values were stable and in the normal range and there was no schistocytosis. Platelet count was within normal limits and SRL levels were not significantly elevated (in the range of 5 to 7 ng/mL) before or at the time of the diagnosis of TMA. Since previous reports have suggested a relationship between SRL

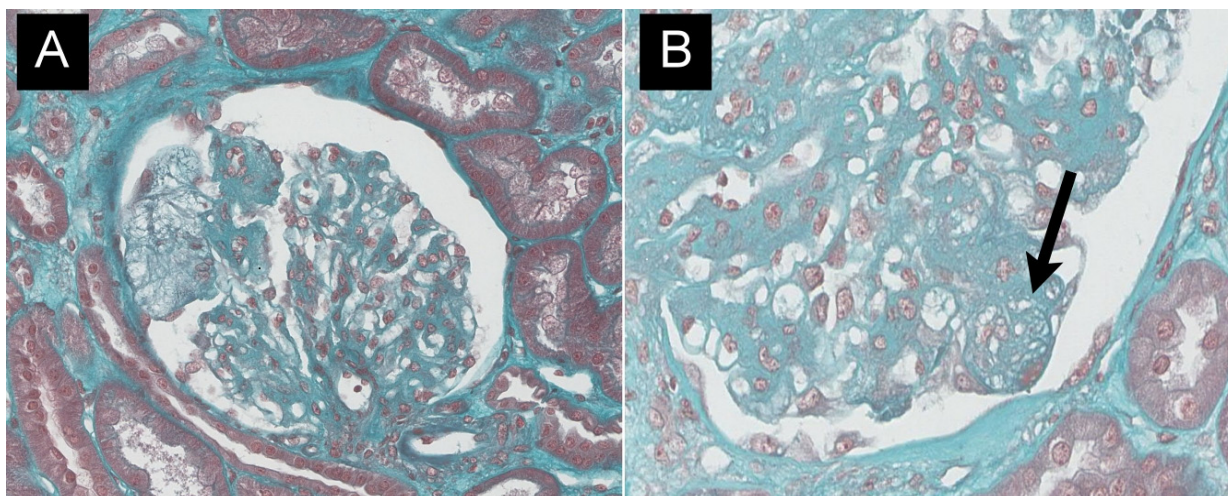


Fig. 1. Kidney biopsy (Masson's trichrome stain) showed mesangial proliferation with mesangiolytic changes (panel A), thickening of the capillary wall and a glomerular capillary occluded by a thrombus (panel B, arrow).

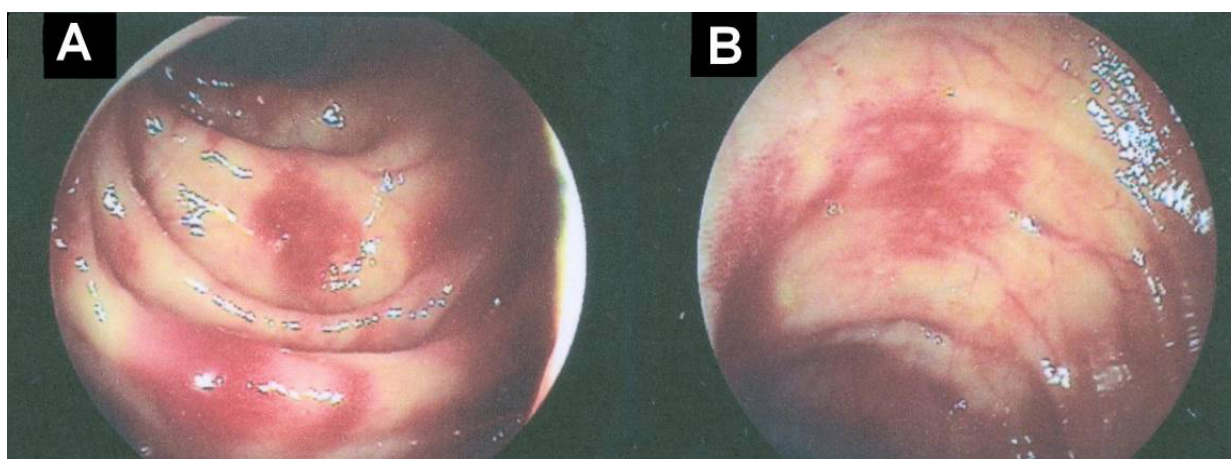


Fig. 2. The findings at colonoscopy showed segmental erythema and congestion interspersed with areas of normal mucosa. No ulcerations or macroscopic bleeding were observed (panel A: left colon; panel B: right colon). Terminal ileum and rectum appeared free from disease.

and TMA, treatment with SRL was discontinued and replaced with belatacept. Prednisone and MMF were continued. This resulted in a rapid and sustained improvement of the clinical picture and a progressive normalization of laboratory values; patient's serum creatinine decreased to 2 mg/dL and proteinuria to 2 g/24 hours.

3. Discussion

SRL is a potent immunosuppressive drug used for the prevention of allograft rejection after solid organ transplantation.^[1] SRL exerts its biologic effects by inhibiting the mammalian target of rapamycin (mTOR), a cytosolic protein kinase that regulates angiogenesis, protein synthesis and cell growth, proliferation and survival. The immunosuppressive effect of SRL is related primarily to

its ability to interfere with IL-2-mediated T-cell proliferation that is critical in cell-mediated immune response.^[1,5] Furthermore SRL exerts direct immunosuppressive effects on other immune cells such as antigen-presenting cells, B cells, natural killer cells and neutrophils.^[5] mTOR inhibitors have also strong anti-proliferative effect on non-immune cells such as fibroblasts, vascular smooth muscle cells, endothelial cells and various tumor cells. Consequently SRL, as well as other mTOR inhibitors (*e.g.* everolimus, temsirolimus), are being tested extensively for several pathologies including malignancies (*e.g.* renal cell carcinoma, neuroendocrine tumors, lymphoma, breast cancer, melanoma and non-melanoma skin cancers), cardiovascular diseases, tuberous sclerosis and lymphangioliomyomatosis.^[2,6]

Although SRL has been shown to be a highly effective immunosuppressive drug in solid organ transplantation, it has several

adverse effects. The most common adverse effects of sirolimus are thrombocytopenia, leukopenia, hypertriglyceridemia and hypercholesterolemia.^[1] Recent data suggest that the use of SRL is associated with an increased risk of thrombotic events^[2,3] and TMA.^[4]

TMA is a rare but severe disease caused by an endothelial injury that results in thrombosis in capillaries and arterioles. It may be seen in association with thrombocytopenia, variable degrees of microangiopathic hemolytic anemia and organ ischemia.^[7] TMA is a well-known serious complication of renal transplantation and the majority of TMA cases observed after renal transplantation are related to CNI therapy. Infections, severe renal ischemia and acute humoral rejection are less frequent causes of TMA. According to a large historical cohort study the incidence of TMA in renal transplant recipients is 4.9 episodes *per* 1 000 person-years for *de novo* TMA.^[8]

The clinical picture of post-transplantation TMA is pleomorphic: systemic TMA manifests itself with renal failure, hemolytic anemia and thrombocytopenia while localized TMA's clinical manifestations include worsening renal function, or delayed graft function, with few or no systemic manifestations, thrombocytopenia and anemia. However localized or systemic TMA represent different ranges of severity of the same syndrome that may initially present as localized but successively evolve to systemic disease.^[7,9]

In our report the close chronological relationship between the development of deep venous thrombosis, renal TMA and ischemic colitis and the onset of treatment with SRL together with the prompt and persistent improvement of the clinical picture following suspension of the drug strongly suggest its causal role in the development of these events. In addition, our patient did not have a history of TMA and, at the time of the events, the patient was administered no other medication known to cause iatrogenic TMA or a prothrombotic state. On the other hand we did not detect dose-dependent toxicity since SRL blood concentrations were always within normal range. In this setting renal biopsy was most likely the only modality to recognize TMA in our SRL-treated patient.

The incidence of proteinuria has been recently reported among patients on SRL-based therapy and attributed to direct SRL toxicity on recipient kidney. This increased proteinuria has been attributed to proximal tubular cell injury or *de novo* focal segmental glomerulosclerosis probably induced by a direct podocyte injury.^[10-12] In this context kidney biopsy showing only TMA typical lesions, permitted to exclude other forms of SRL-induced kidney toxicity on tubular or glomerular structures. In our patient hypoalbuminemia was relatively modest (30 g/L) therefore it can hardly explain the massive weight increase (30 kg) and peripheral edemas observed. One explanation for this finding is that the patient could have developed a simultaneous capillary leak syndrome, as previously reported in patients treated with SRL for psoriasis.^[13]

Although it is still unclear how SRL can trigger TMA, it is possible that the drug decrease vascular endothelial growth factor (VEGF) production and induce endothelial damage leading to platelet aggregation, thrombosis and, consequently, tissue ischemia.^[4,14] A similar pathogenic mechanism, in particular endothelial toxicity,

could also explain the increased incidence of venous thrombosis observed in patients treated with SRL.^[2,3]

In summary, systemic TMA and venous thrombosis are emergent adverse effects of SRL as its therapeutic applications increase; therefore clinicians should beware of these potentially life-threatening complications.

Conflicts of interests. None.

Abbreviations. CNIS: calcineurin inhibitors; MMF: mycophenolate mofetil; mTOR: mammalian target of rapamycin; TMA: thrombotic microangiopathy; VEGF: vascular endothelial growth factor.

References

1. Augustine JJ, Bodziak KA, Hricik DE. Use of sirolimus in solid organ transplantation. *Drugs* 2007; 67(3): 369-91
2. Ahya VN, McShane PJ, Baz MA, *et al.* Increased risk of venous thromboembolism with a sirolimus-based immunosuppression regimen in lung transplantation. *J Heart Lung Transplant* 2011; 30(2): 175-81
3. Thibodeau JT, Mishkin JD, Patel PC, *et al.* Sirolimus use and incidence of venous thromboembolism in cardiac transplant recipients. *Clin Transplant* 2012; 26(6): 953-9
4. Crew RJ, Radhakrishnan J, Cohen DJ, *et al.* De novo thrombotic microangiopathy following treatment with sirolimus: report of two cases. *Nephrol Dial Transplant* 2005; 20(1): 203-9
5. Thomson AW, Turnquist HR, Raimondi G. Immunoregulatory functions of mTOR inhibition. *Nat Rev Immunol* 2009; 9(5): 324-37
6. Gomez-Pinillos A, Ferrari AC. mTOR signaling pathway and mTOR inhibitors in cancer therapy. *Hematol Oncol Clin North Am* 2012; 26(3): 483-505, vii
7. Barbour T, Johnson S, Cooney S, *et al.* Thrombotic microangiopathy and associated renal disorders. *Nephrol Dial Transplant* 2012; 27(7): 2673-85
8. Reynolds JC, Agodoa LY, Yuan CM, *et al.* Thrombotic microangiopathy after renal transplantation in the United States. *Am J Kidney Dis* 2003; 42(5): 1058-68
9. Ardalan MR. Review of thrombotic microangiopathy (TMA), and post-renal transplant TMA. *Saudi J Kidney Dis Transpl* 2006; 17(2): 235-44
10. Schöenberger E, Ehrich JH, Haller H, *et al.* The podocyte as a direct target of immunosuppressive agents. *Nephrol Dial Transplant* 2011; 26(1): 18-24
11. Franco AF, Martini D, Abensur H, *et al.* Proteinuria in transplant patients associated with sirolimus. *Transplant Proc* 2007; 39(2): 449-52
12. Tomlanovich SJ, Vincenti F. Sirolimus: defining nephrotoxicity in the renal transplant recipient. *Clin J Am Soc Nephrol* 2007; 2(2): 198-9
13. Kaplan MJ, Ellis CN, Bata-Csorgo Z, *et al.* Systemic toxicity following administration of sirolimus (formerly rapamycin) for psoriasis: association of capillary leak syndrome with apoptosis of lesional lymphocytes. *Arch Dermatol* 1999; 135(5): 553-7
14. Sartelet H, Toupance O, Lorenzato M, *et al.* Sirolimus-induced thrombotic microangiopathy is associated with decreased expression of vascular endothelial growth factor in kidneys. *Am J Transplant* 2005; 5(10): 2441-7

Correspondence and offprints: Simone Negrini, Centre de Recherche clinique Paris-Sud, Hôpital Bicêtre, 78 rue du Général Leclerc, 94275 Le Kremlin-Bicêtre Cedex, France.
E-mail: simone.negrini@bct.aphp.fr