

Research Report

Neuroendoscopic Management of Intraventricular Hemorrhage

P.L. Longatti, MD; A. Martinuzzi, MD, PhD; A. Fiorindi, MD; L. Maistrello, MD; A. Carteri, MD

Background and Purpose—We reviewed our 7-year experience in neuroendoscopic management of severe intraventricular hemorrhage (IVH) to evaluate its safety, efficiency, and efficacy.

Methods—Thirteen patients with spontaneous primary or secondary tetra-ventricular IVH underwent neuroendoscopy. In all procedures, we used a flexible instrument. CT scans obtained before and after surgery were compared for Graeb score and ventriculocranial ratio. Glasgow Outcome Scale was assessed at 12 months.

Results—In all patients, the procedure resulted in a substantial removal of ventricular blood. Graeb score was reduced by 65%, and ventriculocranial ratio was reduced by 30% ($P < 0.002$). The procedure was carried out safely even in the presence of a vascular malformation, and no rebleeding or delayed hydrocephalus was observed in any case. Mortality at 12 months was 30.7%. Favorable outcome (Glasgow Outcome Scale, 3 to 5) was observed in 61.5% of cases.

Conclusions—Neuroendoscopic management of severe IVH in this cohort of patients was safe, efficiently reduced the amount of ventricular blood and ventricular dilatation, and effectively produced an outcome profile that compares very favorably with other more conventional treatments. (*Stroke*. 2004;35:e35-e38.)

Key Words: endoscopy ■ intraventricular hemorrhage

Spontaneous intraventricular hemorrhage (IVH) is an infrequent but severe complication of hemorrhagic stroke, presenting in $\approx 10\%$ of the cases of intracerebral hemorrhage.¹ When Glasgow coma score (GCS) at admission is low and the volume of blood in the cavities is >20 mL, prognosis is very poor.²⁻⁴ The presence of blood in the ventricular system is a negative predictor of outcome in cerebral hemorrhage. Therefore, aggressive treatment, particularly in the presence of large quantities of blood, must be considered.

Conventional treatment of IVH consists in ventricular drainage with or without fibrinolysis^{5,6} or surgical evacuation.^{7,8} Here, we describe a neuroendoscopic approach to IVH in a group of 13 patients and discuss strengths and weaknesses of this approach.

Subjects and Methods

Thirteen patients were treated for IVH between December 1995 and April 2002. All patients presented with spontaneous primary or secondary tetra-ventricular inundation, ventricular dilatation, coma, or progressive worsening of neurological conditions (Table 1).

All patients were evaluated at 4 hours from onset. CT scan was obtained within 3 hours of hospital admission. Angiography was obtained when vascular malformation (VM) was suspected.

Severity of IVH was graded as proposed by Graeb et al.⁹ The degree of ventricular dilatation was assessed by calculating the ventriculocranial ratio (VCR) from the admission CT scan, measured as the average of the maximum lateral width of the frontal horns divided by the cranial diameter at the same level.

Two types of flexible endoscopes were used with an external diameter of either 2.5 (Karl Storz) or 3.9 (Codman) mm and an

operative length of 53 cm. The internal diameter of the working channel was 1.2 mm. For aspiration procedures, the entire working channel was used as a sucker. Access was precoronal by a 12-mm burr hole.

In the presence of a ventricular VM, the approach from that side was avoided. Once the endoscope reached the inundated ventricle, an energetic intermittent manual aspiration was started with a rigid syringe connected to the operating channel of the endoscope. This action breaks down the clot and allows an initial visual orientation in the ventricle. Aspiration was alternated with irrigation with Ringer's solution and was promptly stopped when the whitish color of the ventricular walls appeared.

Once the choroidal plexus and Monro foramen were identified, the instrument was advanced into the third ventricle, and the procedure was repeated. Evacuation of the third ventricle opened the way to the aqueduct and to the fourth ventricle, where the aspiration-irrigation procedures were done especially carefully because the endoscope fills the entire diameter of the aqueduct and potentially dangerous local hypertension might easily be caused by excessive irrigation with Ringer's solution. Finally, the endoscope was flexed toward the occipital horn and the trigonus to evacuate these sections from the clots.

After ventricle cannulation, systolic blood pressure was kept at 120 mm Hg.

At the end of the procedure, monolateral or bilateral ventriculostomy was performed in all patients by placing a catheter for both intracranial pressure (ICP) monitoring and drainage (with a constant gradient of 15 mm Hg). The external ventricular diversion was kept open for 2 to 3 days, and then it was closed. On pressure stabilization, it was removed.

Within 4 hours after surgery, a CT scan was obtained, and Graeb score and VCR were recalculated. Clinical follow-up was at 12 months (Glasgow Outcome Score [GOS]).

Received August 19, 2003; final revision received October 27, 2003; accepted November 3, 2003.

From the Neurosurgery Unit, Department of Neuroscience, Treviso Hospital, Treviso (P.L.L., A.F., L.M., A.C.), and "E. Medea" Scientific Institute, Conegliano Research Centre, Conegliano (A.M.), Italy.

Correspondence to Andrea Martinuzzi, MD, PhD, "E. Medea" Scientific Institute, Conegliano Research Centre, Via Costa Alta 37, 31015 Conegliano (TV), Italy. E-mail andrea.martinuzzi@cn.lnf.it

© 2004 American Heart Association, Inc.

Stroke is available at <http://www.strokeaha.org>

DOI: 10.1161/01.STR.0000113736.73632.F6

TABLE 1. Patient Demographics and Clinical Data

Patient	Age, y	Sex	Origin	Clinical Features	Pupillary Abnormality	GCS
1	7	F	Basal AVM	Hp, V, H→Co	Anisocoria	5
2	80	F	AcoA An	Hp→Co	None	7
3	53	M	AcoA+MCA An	S	None	11
4	64	M	Hypertension	Co	Bilat. Miosis	4
5	57	F	Cerebellar AVM	H,D,P7,P6→Co	None	8
6	63	F	Not known	Co	Bilat. Midriasis	5
7	19	F	P-O AVM	S→Co	Anisocoria	6
8	76	M	Hypertension	Co	None	7
9	32	F	Frontal AVM	Co	None	5
10	57	F	Hypertension	H,Hp	Anisocoria	10
11	52	M	A2 ACA An	H→Co	Anisocoria	3
12	69	M	Hypertension	Co	None	7
13	66	F	Hypertension	Hp,H,V→Co	None	7
Mean (SD) 53.5 (21.6)						6.5 (2.25)

AVM indicates arteriovenous malformation; ACoA, anterior communicating artery; An, aneurysm; MCA, middle cerebral artery; P-O, parieto-occipital; A2 ACA, A2 portion of anterior cerebral artery; Hp, hemiparesis; V, vomit; H, headache; Co, coma; S, seizures; D, dysarthria; P7, VII cranial nerve palsy; and P6, VI cranial nerve palsy.

Wilcoxon matched-pairs test and the paired *t* test were applied to evaluate the changes in Graeb score and VCR, respectively.

Results

Of the 13 patients, 11 underwent surgical endoscopy within 6 hours of hospital admission. In 2 cases (patients 7 and 12), the initial approach was an external bilateral ventricular drainage that was changed to endoscopy after 24 to 36 hours owing to the patients' clinical worsening and the malfunction of catheters.

In all patients, the procedure resulted in the almost complete removal of intraventricular blood. Graeb score changed significantly, from 10.6 ± 1.2 to 3.8 ± 1.6 ($P < 0.002$). Similarly, VCR decreased from 0.31 ± 0.05 to 0.22 ± 0.04 ($P < 0.0001$) (Table 2).

In all patients, ICP was within normal range (15 mm Hg) at the end of the endoscopic procedure and was normal in 11 patients when the external diversion was removed 4 to 25 days later (12.3 ± 6.3 days). One patient with persistent

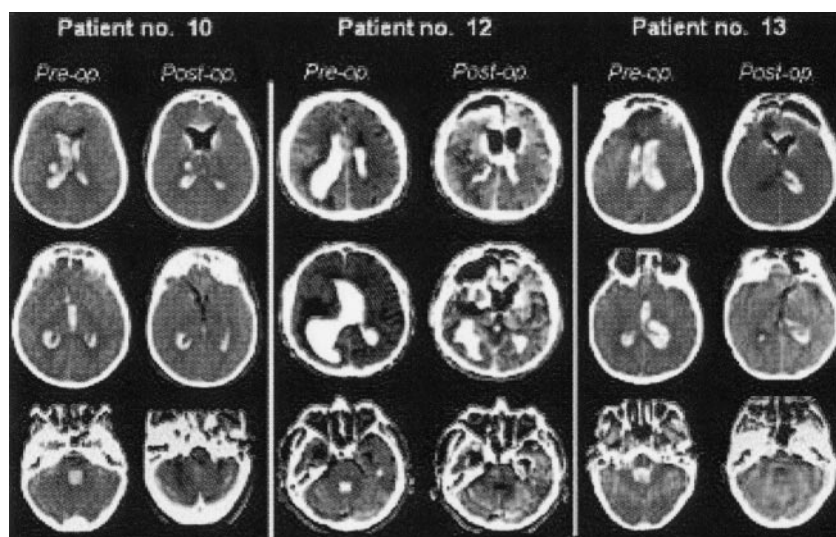
TABLE 2. Individual Outcome Indicators for the Treated Patients

Patients	Graeb Score		VCR		ICU Stay, d	GOS at 1 y
	Pre	Post	Pre	Post		
1	9	1	0.32	0.20	33	5
2	11	1	0.35	0.20	21	1
3	12	5	0.32	0.19	16	5
4	10	4	0.40	0.28	n.a.	1
5	10	4	0.31	0.28	29	5
6	12	6	0.30	0.24	n.a.	1
7	9	4	0.31	0.24	52	2
8	11	5	0.33	0.20	12	1
9	10	4	0.28	0.19	20	5
10	12	4	0.21	0.18	19	4
11	12	2	0.22	0.16	12	3
12	12	2	0.28	0.22	18	3
13	12	1	0.28	0.18	20	3
Mean (SD)	10.6 (1.17)	3.8* (1.62)	0.31 (0.048)	0.22* (0.037)	22.9 (11.3)	

Pre indicates at admission; Post, after operation.

Graeb score compounds the amount of blood in the ventricular system in a nonparametric scale from 0 to 12; 0=no blood, 12=all ventricles filled with blood.⁹ VCR was calculated as described in Materials and Methods. The higher the ratio is, the more severe the ventricular dilatation is. Normal values are <0.155 .

* $P < 0.002$.



Preoperation and postoperation (4 hours) CT scans of patients presenting with severe tetraventricular hemorrhage. Patient identification corresponds to numbers in Table 1. In all patients, amount of intraventricular blood and extent of ventricular enlargement are reduced. Blood filling the fourth ventricle is completely cleared in all cases.

elevation of ICP required permanent ventriculoperitoneal diversion.

In 7 patients, a VM was detected and treated by surgery ($n=3$) or embolization ($n=4$) at various times after the endoscopic procedure. We never observed rebleeding or meningeal infection in the postoperation period. Five patients presented with respiratory infections. Two patients did not show any clinical improvement despite effective clearance of ventricular blood and died within 1 month after endoscopy. One patient died because of respiratory infection 21 days after endoscopy, and 1 died because of acute myocardial infarction 4 months after operation. Overall mortality rate at 1 year was 30.7%. Average intensive care unit stay for surviving patients was 22.9 ± 11.3 days (Table 2).

A summary of the clinical outcome at 12 months is shown in Table 2. Five patients (38.5%) were fully independent: 4 had no residual disability, and 1 presented with moderate disability. Three patients showed significant disabilities requiring assistance in most daily life activities, and 1 patient was in a persistent vegetative state. None of our patients showed delayed hydrocephalus.

Discussion

Prognosis in IVH is affected by several factors, all playing a critical role, especially in the acute phase of the event. The sudden rise in ICP associated with initial bleeding may cause a significant reduction in cerebral blood flow, potentially leading to ischemia.^{10,11} The obstruction of normal cerebrospinal fluid flow and the mass effect associated with clots in the satellite hematoma and within the ventricles produce further damage. Thus, the primary goal of IVH acute management should be the fast removal of intraventricular blood, rapid reversal of ventricular dilatation, and normalization of ICP. All these goals can be achieved with this neuroendoscopic procedure, while complications often observed with other traditional approaches are minimized.

The significant change in Graeb score and VCR observed within 4 hours in all our patients speaks for the efficacy of the endoscopic procedure in positively affecting 2 known predictors of IVH outcome.

The short-term (15%) and long-term (30%) mortality rates in our cohort are comparable to findings of recent studies evaluating urokinase treatment in nonaneurysmal IVH (20% at 1 month and 32% at 6 months).^{5,6} Dichotomization of GOS, as applied in Coplin et al⁵ (favorable outcome; GOS, 3 to 5), showed a favorable outcome, which was higher in our group (62%) than in the group receiving urokinase treatment (36%). Our series included 7 patients with VM, which may complicate comparability. Even after exclusion of those patients, favorable outcome in our series was 50%. The frequency of early and late complications in our group was lower than what was reported in studies with external ventricular diversion.^{3,5} Only 1 patient of the 9 surviving in our series required VP shunting.

We did not observe rebleeding even in patients presenting with IVH resulting from VM (Figure 1b). The careful monitoring of systolic blood pressure may represent the key precaution to avoid rebleeding.

Surgical management of IVH by frontal¹¹ or occipital⁷ craniotomy shows a mortality rate of $\approx 30\%$ and a favorable outcome in 42% of the patient, but these figures change dramatically when patients with tetraventricular inundation are considered because 0 of the 18 patients reported recently had a good outcome, and 7 died.¹¹

Our results confirm previous reports showing positive outcomes in patients with IVH treated with neuroendoscopic approach.¹²⁻¹⁴ In all cases, efficient removal of intraventricular clots was rapidly achieved. However, in 2 of these reports, use of the rigid endoscope required either a cumbersome biportal approach¹² or an ultrasonic aspirator¹³ with a high risk (20%) of postoperative rebleeding. The latter procedure was applied to newborns,¹⁴ a patient category hardly comparable to ours.

The use of a flexible instrument and the free-hand technique, albeit offering a narrower operating channel, allows more complete cleansing of the third ventricle and navigation down to the fourth ventricle through the aqueduct. Persistence of blood in the fourth ventricle is related to poor outcome in IVH patients.⁷ Complete clearing of the aqueduct and the fourth ventricle is thus an important feature of this treatment

because it rapidly reestablishes the physiological cerebrospinal fluid dynamics.

The use of combined endoscopy and intravascular embolization should be considered among the treatment options for intraventricular bleeding resulting from VM as it enables fast and safe management of both the IVH and the malformation.

Our experience with endoscopy treatment of severe primary and secondary IVH shows that, once certain measures are taken to minimize the risk of bleeding resulting from ruptured VMs, this approach can be safe and effective and may favorably compare with more established approaches. The encouraging results of this study should be confirmed on larger populations.

References

1. Coplan LR. Primary intraventricular hemorrhage. In: Case CS, Caplan LR, eds. *Intracerebral Hemorrhage*. London, UK: Butterworth-Heinemann; 1994;383–401.
2. Lampl Y, Gilad R, Eshel Y, Sarova-Pinhas I. Neurological and functional outcome in patients with supratentorial hemorrhage: a prospective study. *Stroke*. 1995;26:2249–2253.
3. Tuhim S, Horowitz DR, Sacher M, Godbold JH. Volume of ventricular blood is an important determinant of outcome in supratentorial intracerebral hemorrhage. *Crit Care Med*. 1999;27:617–621.
4. De Weerd AW. The prognosis of intraventricular hemorrhage. *J Neurol*. 1997;222:45–51.
5. Coplin WM, Vinas FC, Agris JM, Buciu R, Michael DB, Diaz FG, Muizelaar JP. A cohort study of the safety and feasibility of intraventricular urokinase for nonaneurysmal spontaneous intraventricular hemorrhage. *Stroke*. 1998;29:1573–1579.
6. Naff NJ, Carhuapoma R, Williams MA, Bhardwaj A, Ulatowski JA, Bederson J, Bullock R, Schmutzhard E, Pfausler P, Tuhim S, Hanley D. Treatment of intraventricular hemorrhage with urokinase. *Stroke*. 2000;31:841–847.
7. Lagares A, Putman CM, Ogilvy CS. Posterior fossa decompression and clot evacuation for fourth ventricle hemorrhage after aneurysmal rupture: case report. *Neurosurgery*. 2001;49:208–211.
8. Shimoda M, Oda S, Shibata M, Tominaga J, Kittaka M, Tsugane R. Results of early surgical evacuation of packed intraventricular hemorrhage from aneurysm rupture in patients with poor-grade subarachnoid hemorrhage. *J Neurosurg*. 1999;91:408–414.
9. Graeb DA, Robertson WD, Lapointe JS, Nugent RA, Harrison PB. Computed tomographic diagnosis of intraventricular hemorrhage: etiology and prognosis. *Radiology*. 1982;143:91–96.
10. Mayer SA, Kessler DB, Van Hurlum RL, Thomas CE, Fink ME, Brannigan T. Effect of intraventricular blood on global cortical perfusion in acute intracerebral hemorrhage: a single-photon emission computed tomographic study. *Ann Neurol*. 1995;38:288. Abstract.
11. Martí-Fàbregas J, Piles S, Guardia E, Martí-Vilalta JL. Spontaneous primary intraventricular hemorrhage: clinical data, etiology and outcome. *J Neurol*. 1999;246:287–291.
12. Horvath Z, Veto F, Balas I, Kover F, Doczi T. Biportal endoscopic removal of a primary intraventricular hematoma: case report. *Minim Invasive Neurosurg*. 2000;43:4–8.
13. Oka K, Go Y, Yamamoto M, Kumate S, Tomonaga M. Experience with an ultrasonic aspirator in neuroendoscopy. *Minim Invasive Neurosurg*. 1999;42:32–34.
14. Kamikawa S, Inui A, Kobayashi N, Tamaki Nyamadori T. Intraventricular hemorrhage in neonates: endoscopic findings and treatment by the use of our newly developed Yamadori-type 8 ventriculoscope. *Minim Invasive Neurosurg*. 2001;44:74–78.