

AperTO - Archivio Istituzionale Open Access dell'Università di Torino

Hydatidosis of the pelvis: a case report with a 25-year follow-up

This is the author's manuscript

Original Citation:

Availability:

This version is available <http://hdl.handle.net/2318/39908> since

Terms of use:

Open Access

Anyone can freely access the full text of works made available as "Open Access". Works made available under a Creative Commons license can be used according to the terms and conditions of said license. Use of all other works requires consent of the right holder (author or publisher) if not exempted from copyright protection by the applicable law.

(Article begins on next page)

CASE REPORT

Alessandro Massè · Pier Giorgio Parola
Elena Maria Brach del Prever · Paolo Gallinaro

Hydatidosis of the pelvis: a case report with a 25-year follow-up

Received: 16 October 2002 / Published online: 10 February 2004
© Springer-Verlag 2004

Abstract *Introduction:* Hydatid disease involves mainly the liver (66% of the cases) and the lungs (22%), with skeletal involvement being reported in 0.5–2.5% of cases. *Case report:* Herein is reported a case of hydatidosis of the hip and pelvis with a follow-up of 25 years. The diagnosis was first done in April 1975 following the local excision of a single hydatid cyst from the ischium of a 25-year-old man complaining of increasing pain and swelling of the left thigh. Histology confirmed hydatid disease of the bone. Local excision was repeated four more times for recurrence of the hydatid cysts in the bone or soft tissues. Antiparasitic medical therapy (albendazole 10 mg/kg daily) was attempted in 1991 but suspended after 2 days due to systemic adverse effects (abdominal pain, diarrhea). The patient had a 12-year relapse-free period with complete absence of any symptoms. *Conclusion:* Such a long symptom-free period confirms that it is not possible to consider bone hydatidosis as being completely healed without the confirmation of a long term follow-up.

Keywords Hydatidosis · *Echinococcus* · Pelvis · Hip · Albendazole

Introduction

Hydatid disease is caused by a parasitic tapeworm, the *Echinococcus* of which the species *granulosus* is the most common cause of this disease in man, and involves mainly the liver (66% of the cases), the lungs (22%), or other viscera (10%), with skeletal involvement being reported in 0.5–2.5% of cases [2, 3, 5, 6]. With bone involvement, the spine is affected in about 50% of the cases and the pelvis

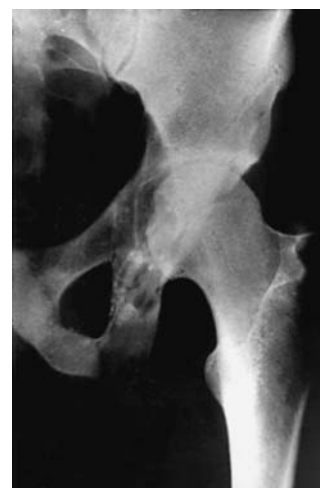in about 30% [2]. As the disease progression is slow, the symptoms become evident usually only in adulthood as pain, swelling, or pathological fracture. The spine involvement can be further complicated by neurological signs.

The radiographic features in their typical appearance are multilocular cysts with a honeycomb aspect: the cortical reaction is usually poor, as the parasite does not elicit any inflammatory reaction [9]. Computed tomography (CT), with and without contrast enhancement, is helpful in the recognition of the disease, allows for a precise evaluation of the extent of the bone disruption, and is mandatory to evaluate the presence and the extent of other extraosseous lesions [5].

Serologic and immunologic tests are most often normal or only slightly modified. As the radiographic findings are not specific, bone hydatidosis may be easily mistaken for aneurysmal bone cyst, giant cell tumor, angioma, fibrous dysplasia, and other cystic lesions.

Herein is reported a case of hydatidosis of the hip and pelvis with a follow-up of 25 years. We are not aware of any published case of this rare disease with such a long follow-up.

Fig. 1 Anteroposterior radiograph of the hip in 1975, showing a multilocular lytic lesion involving the ischium



A. Massè (✉) · P. G. Parola · E. M. B. del Prever · P. Gallinaro
Department of Orthopaedics,
Traumatology and Occupational Medicine, Clinica Ortopedica I,
Università degli Studi di Torino,
via Zuretti 29, 10126 Torino, Italy
Tel.: +39-011-6933573, Fax: +39-011-6963662,
e-mail: alessandro.masse@unito.it

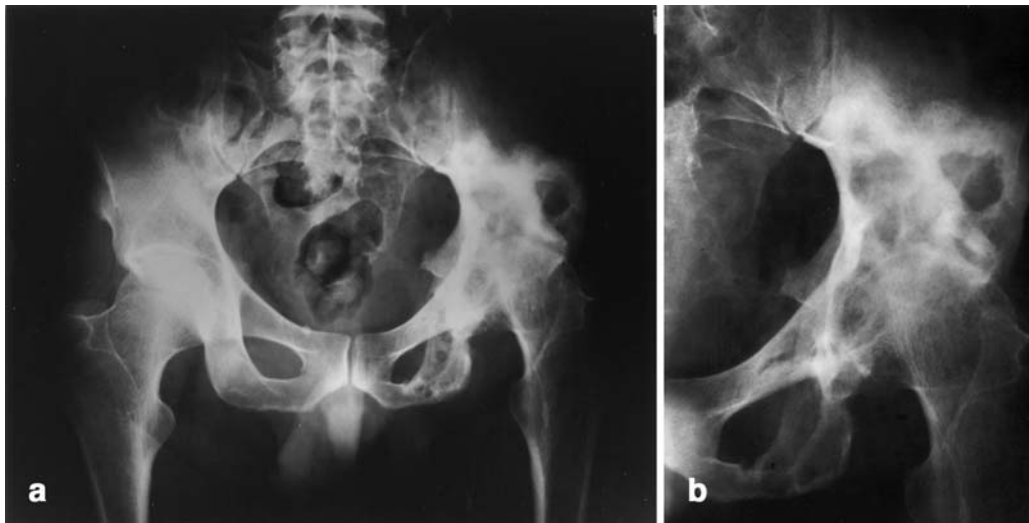


Fig. 2 a, b The anteroposterior appearance in 2000: the lesions have extended to the ileum and the hip joint

Case report

V.P., a 25-year-old man from Sardinia, was admitted in April 1975 for increasing pain and swelling of the left thigh; there was no history of trauma or systemic illness.

A diffuse swelling of the ischiatic region of the left hip was revealed on examination; the range of motion was full in both hip joints. The erythrocyte sedimentation rate was 112 mm/h; the indirect hemagglutination test for hydatid disease was positive. The X-ray of the pelvis showed a multilocular lytic lesion involving the ischium, without apparent involvement of the hip (Fig. 1).

Exploratory surgery was performed, with local excision of a single hydatid cyst, curettage, and washing with 15% formalin solution; histology confirmed hydatid disease of the bone.

In April 1976 the formation of a hydatid cyst in the soft tissues corresponding to the surgical wound was observed and treated with local excision. Bone curettage was then performed in November 1978 for recurrence of the ischial localization.

From 1979 to 1991 the patient was free from symptoms and had a normal working life. In 1991 there was a recurrence of the local symptoms: the X-ray showed an extension of the bone lesions with initial signs of hip arthritis. The patient underwent excision of numerous cysts within the bone and the surrounding soft tissues; at the same time a hepatic cyst was diagnosed and excised. Antiparasitic therapy (albendazole 10 mg/kg daily) was suspended after 2 days due to systemic adverse effects (abdominal pain, diarrhea). In the postoperative period, two fistulas appeared near the surgical wound.

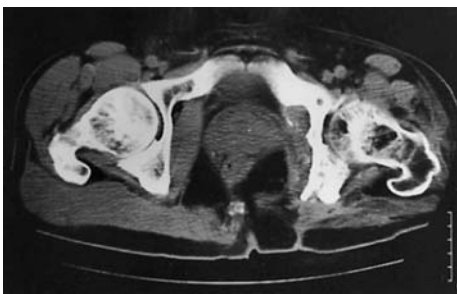


Fig. 3 The CT scan confirms the presence of lytic lesions of the ischial tuberosity and the osteoarthritic appearance of the joint

Microbiological examination revealed the superimposition of *Staphylococcus aureus*, treated with teicoplanin 500 mg + pefloxacin 800 mg daily for 3 months.

In August 1992 there was a recurrence in the soft tissues around the previous surgical wound, treated with local excision and antibiotic therapy; histologic examination confirmed the presence of hydatid cysts.

The last control was performed in April 2000. The laboratory exams performed were as follows: white blood cell count of $6.9 \times 10^9/l$, with 66.8% neutrophils, 26.5% lymphocytes, 5.2% monocytes, and 1.5% eosinophils. The hemoglobin level was 14.5 g/dl; the erythrocyte sedimentation rate was 6 mm/h. The radiographic appearance was almost superimposable on that of 1992, with the exception of a worsening of the radiographic signs of hip osteoarthritis (Fig. 2, Fig. 3). Despite that, the Harris hip score was 77, with remarkable limitation of the articulation but with only mild pain after walking for a long distance. The patient, who has changed his job to a more sedentary activity, refuses any further surgical treatment.

Discussion

The treatment of bone hydatidosis is still controversial and involves both medical and surgical therapy.

The medical therapy of hydatid disease consisted, up until the early 1980s, in a benzimidazole derivative, mebendazole, which encountered a variable success due to its poor absorption and the consequently low concentration in serum and cysts [1, 9]. A relevant step was represented by the introduction of another anthelmintic, albendazole, characterized by a better absorption and higher levels of its active metabolite, albendazole sulphoxide, in the cysts and blood [1, 9]. Albendazole has been shown to be teratogenic and embryotoxic in some animals, and its use should, therefore, be avoided in pregnancy and limited to short periods [1].

Surgical therapy, before the introduction of an efficient medical therapy, consisted in wide surgical excision to treat the sites in the long bones, and a more conservative approach in the treatment of the sites in the axial skeleton [9].

Since the results of both the medical therapy and the surgical therapy seem to be discouraging when applied

singularly, their association seems to represent the most efficient therapeutic solution [1, 9]. Medical therapy with albendazole should ideally be started preoperatively, but this is almost always impossible as the diagnosis is difficult and should have histological confirmation.

Surgical therapy is still a matter of debate as it is not clear if wide margin excision is to be preferred to local excision and curettage. Recently, De Cristofaro et al. suggested that bone hydatidosis should be treated in the same way as a malignant tumor, with wide surgical margin excision associated with medical treatment. They reported a case of hip hydatidosis treated with hemipelvectomy and medical therapy with mebendazole, with no sign of recurrence at 2 years [3]. Ocete [6], Gorun [4], Hèlènon [5], and Wirbel [10] reported similar cases of pelvic hydatidosis treated with wide margin excision (hemipelvectomy [3, 4, 5], extended ileum resection [3], and megaprosthesis replacement [10]). In all of those cases, the surgical treatment was associated with medical therapy employing mebendazole or albendazole. These authors reported absence of recurrence at a maximum follow-up of 5 years [6].

In support of a less aggressive surgical treatment, Agarwal and co-workers [1] reported two cases of pelvic hydatidosis treated with local excision, curettage, and medical therapy (albendazole) without recurrence at 18 months and 6 years. Their report is further supported by Cosco [2], Sapkas [7], and Sakka [8] who described cases of pelvic hydatidosis treated in a similar manner without recurrence at medium-term follow-up. A theoretical risk of the local excision is that of producing an acute anaphylactic reaction, although we ourselves did not come across any case of such a complication in the literature.

The case we report had been treated only with repeated local excision and curettage, without medical therapy due to systemic adverse effects. Despite that, the patient had a 12-year relapse-free period with complete absence of any

symptoms. Such a long symptom-free period confirms that it is not possible to consider bone hydatidosis as being completely healed without the confirmation of a long-term follow-up.

Even if complete eradication was not achieved, the subjective and objective conditions of the patient are satisfying, and the slow extension of the disease leaves the possibility for a hypothetical wide-margin surgical excision.

References

1. Agarwal S, Shah A, Mohammed Kadhi SK, Rooney RJ (1992) Hydatid bone disease of the pelvis: a report of two cases and review of the literature. *Clin Orthop* 280:251–255
2. Cosco S, Calderon JE (1985) Su di un caso di echinococcosi primitiva dell'ileo. *Chir Organi Mov* 70:195–197
3. De Cristofaro R, Ruggieri P, Biagini R, Picci P (1990) Case report 629. *Skeletal Radiol* 19:461–464
4. Gorun N (1992) La désarticulation de hanche de nécessité dans l'échinococcose étendue du fémur. *Rev Chir Orthop Reparatrice Appar Mot* 78:255–257
5. Helenon O, Folinais D, David M, Blangy S, Sibert A, Cornud FR, Benacerraf R (1986) Hydatidose osseuse de la ceinture pelvienne: apport de la tomodynamométrie et de l'échographie. A propos de 3 observations. *J Radiol* 67:515–521
6. Ocete G, Guerrero A, Diaz-Peletier R, Burgos J, Bouza E, De Miguel C (1986) Experience in the treatment of osseous hydatidosis. *Int Orthop* 10:141–145
7. Sapkas GS, Stathakopoulos DP, Babis GC, Tsarouchas JK (1998) Hydatid disease of bones and joints: 8 cases followed for 4–16 years. *Acta Orthop Scand* 69:89–94
8. Sakka SA (1993) Kyste hydatique primitif de la cuisse à manifestation douloureuse au niveau de la hanche. *Rev Chir Orthop Reparatrice Appar Mot* 79:226–228
9. Szypryt EP, Morris DL, Mulholland RC (1987) Combined chemotherapy and surgery for hydatid bone disease. *J Bone Joint Surg BR* 69:141–144
10. Wirbel RJ, Schulte M, Maier B, Mutschler WE (1999) Megaprosthesis replacement of the pelvis. *Acta Orthop Scand* 70:348–352