

AperTO - Archivio Istituzionale Open Access dell'Università di Torino

## Quantitative electroencephalographic findings in beagles anaesthetized with propofol.

### **This is the author's manuscript**

*Original Citation:*

*Availability:*

This version is available <http://hdl.handle.net/2318/56247> since

*Terms of use:*

Open Access

Anyone can freely access the full text of works made available as "Open Access". Works made available under a Creative Commons license can be used according to the terms and conditions of said license. Use of all other works requires consent of the right holder (author or publisher) if not exempted from copyright protection by the applicable law.

(Article begins on next page)

## Quantitative electroencephalographic findings in beagles anaesthetized with propofol

L. Bergamasco <sup>a,\*</sup>, A. Accatino <sup>b</sup>, L. Priano <sup>c</sup>, G. Neiger-Aeschbacher <sup>d</sup>, S. Cizinauskas <sup>e</sup>,  
A. Jaggy <sup>e</sup>

<sup>a</sup> Department of Veterinary Morphology and Physiology, University of Turin, Viale L. Da Vinci 44, 10095 Grugliasco, Torino, Italy

<sup>b</sup> Via Umberto I 9, 10040 Cumiana, Torino, Italy

<sup>c</sup> Saint Andrea Hospital, Corso Abbiate 21, Vercelli, Italy

<sup>d</sup> Royal Veterinary College, University of London, Hawkshead Lane, Hatfield, Herts. AL9 7TA, UK

<sup>e</sup> Department of Clinical Veterinary Medicine, Section of Animal Neurology, University of Bern, Bremgartenstrasse 1091A, 3017 Bern, Switzerland

Accepted 8 August 2002

### Abstract

The purpose of this study was to assess quantitative electroencephalography (q-EEG) in 10 healthy beagle dogs under propofol anaesthesia in order to determine objective guidelines for diagnostic electroencephalographic (EEG) recordings and interpretation. The basic pattern after preliminary visual examination of EEG recordings was characterized by spindles, k-complexes, vertex sharp transients, and positive occipital transients that were superimposed on the slow background activity. The results of the q-EEG were characterized by the prevalence of slow rhythms  $\delta$  and  $\theta$ , both in absolute and relative power spectrum analysis, while fast rhythms ( $\alpha$  and  $\beta$ ) were poorly represented. The distribution of single frequency bands was widespread for  $\delta$ , focal for frontal and central for  $\theta$ , as well as for most  $\alpha$  and  $\beta$  patterns. The present study has shown that the use of quantitative EEG gives information on the frequency content of the bio-electrical activity and defines the distribution of the single frequency bands under a standardized anaesthetic protocol.

© 2003 Elsevier Science Ltd. All rights reserved.

**Keywords:** Electroencephalogram; Propofol; Spectral analysis; Quantitative electroencephalography; Dog

### 1. Introduction

Electroencephalography (EEG) is a useful and non-invasive investigation method in patients with neurological disease and especially epilepsy. In addition, the quantitative EEG could be of clinical assistance in diagnosing various conditions affecting brain function (Duffy et al., 1994). Unfortunately, lack of cooperation, pain, anxiety or even aggressive behaviour often prevents EEG examination in animals, and chemical restraint or anaesthesia is necessary. Whichever agent is used, a dose-related slowing of the dominant frequency of the EEG and the loss of usual individual variability of the EEG activity is usually noted. Moreover, different

drugs can produce widely different dominant EEG frequencies (Clark and Rosner, 1973) and peculiar EEG patterns (Daube et al., 1990). The available information on EEG patterns of normal dogs under anaesthesia is controversial and unclear (Steiss, 1988) and data have been collected under different recording conditions, using various techniques and derived from dogs of different breeds, various ages and often unknown clinical history.

Propofol is an anaesthetic drug widely used in clinical practice to induce and maintain general anaesthesia in dogs (Hall and Chambers, 1987; Short and Bufalari, 1999). Propofol anaesthesia is characterized by rapid onset, rapid hepatic metabolism, lack of accumulation on repeated administration, some respiratory depression, and a rapid and smooth recovery from anaesthesia (Glen, 1980; Watkins et al., 1987), although neurological sequelae have been reported (Davies, 1991; Smedile

\* Corresponding author. Fax: +39-011-6709138.

E-mail address: [bergamas@veter.unito.it](mailto:bergamas@veter.unito.it) (L. Bergamasco).

et al., 1996). The cardiovascular depressant effects of propofol are well tolerated in healthy animals, but these effects must be considered carefully in patients with intrinsic cardiac disease. It has been shown that propofol suppresses seizures and may have anticonvulsant properties in experimental animal models of epilepsy (Lowson et al., 1990). As a result, propofol has been used in the treatment of seizures (Steffen and Grasmueck, 2000) and in diagnostic EEG recordings (Jaggy and Bernardini, 1998) in veterinary medicine. Marked decreased registration of brain activity, as well as artifactual paroxysmal activity, can be avoided in diagnostic EEG recordings under propofol anaesthesia (Jaggy and Heynold, 1998). Since the neural effects of propofol are mediated, at least in part, by the activation of the GABA<sub>A</sub> receptor complex (Trapani et al., 2000) and, unlike barbiturates, propofol does not increase the seizure threshold (Committee on Safety of Medicine, 1989), it has been used in EEG recording of neurological patients (Jaggy and Bernardini, 1998) without suppressing spontaneous epileptiform activity or inducing paroxysmal discharge. In humans, propofol concentration-effect relationships are well established and predictable (Casati et al., 1999), and it has been reported that propofol produces similar dose-dependent effects on EEG activity in patients with or without a history of seizure disorders (Wang et al., 1997). Moreover, propofol in low-dose target concentrations has been used to induce "sleep on demand" and to increase spike activity in patients with mesial temporal lobe epilepsy (Leijten et al., 2001).

The present study was designed to investigate the effect of propofol anaesthesia on quantitative EEG (q-EEG) in healthy dogs in order to determine objective guidelines for diagnostic EEG recordings and interpretation.

## 2. Materials and methods

### 2.1. Dogs

Ten female and ten male intact laboratory beagle dogs were used in this study. The animals were involved in an experiment designed to test immunological reagents and, according to Swiss laws, were required to be euthanased. The study was performed at the Department of Clinical Veterinary Medicine, University of Bern, Bern, Switzerland and in accordance with the "Guide for the Care and Use of Laboratory Animals" [DHEW Publication No. (NIH) 86-21].

The age of the dogs ranged from 13 to 14 months (mean value = 13.7 months) and their body weight (BW) averaged 12.69 kg (range: 10.6–17 kg). All dogs were found to be normal on clinical examination. Twenty-four hours prior to anaesthesia and EEG recording,

venous blood was sampled to evaluate the metabolic and haematological profiles (sodium, chlorine, potassium, calcium, phosphorus, total proteins, albumin, globulin, albumin/globulin, urea nitrogen, creatine phosphokinase [CPK], glucose, cholesterol, lipase, ALT, AST, alkaline phosphatase [ALP], pre- and post-prandial bile acids, total bilirubin, complete blood count, and differential leukocytes count). Urine analyses were not performed. Food, but not water, was withheld for 8–12 h prior to induction of anaesthesia. After EEG recording, cerebrospinal fluid was collected from the cerebellomedullary cistern and analyses were carried out immediately.

### 2.2. Anaesthetic protocol

A 20 gauge over-the-needle catheter was placed in one of the cephalic veins and flushed with saline. Anaesthesia was then induced with propofol (Diprivan, AstraZeneca) given intravenously (IV) as a slow injection (60 s) at a dose of 6 mg/kg until endotracheal intubation was possible. The endotracheal tube was connected to a circle breathing system and oxygen was administered at a flow rate of 1 L/min. The dogs were positioned in sternal recumbency. An oesophageal stethoscope was placed for cardiac auscultation. A pulse oximetry probe (Vet Ox TM 4403 Pro Vet) was applied to the tongue and measured pulse rate and haemoglobin saturation of oxygen (SpO<sub>2</sub>). Arterial blood pressure was determined using a non-invasive method (Datex Cardiocap) with the cuff placed on the foreleg over the metacarpal artery. An electrocardiogram (ECG) (Datex Cardiocap) was continuously monitored using lead II. Respiratory rate and end-tidal carbon dioxide (ETCO<sub>2</sub>) tension were measured from the connection of the endotracheal tube and the circle system (Datex Normocap CO<sub>2</sub> Monitor). ECG and respiratory rate were recorded also via polygraphic electrodes of the electroencephalogram (EEG) (X1: sensitivity = 70 µV/mm, time constant = 0.1 s, Hf = 30 Hz; X2: sensitivity = 20 µV/mm, time constant = 0.3 s, Hf = 30 Hz); the polygraphic electrodes were connected to alligator clips (thin cable for bridge electrode, BIONEN S.a.s.) and a volumetric transducer applied to the chest (thoracic respiratory transducer, BIONEN S.a.s.). Physiological parameters were recorded every 5 min. Rectal temperature was measured throughout the investigation but no attempt was made to maintain pre-anaesthetic values. A light plane of anaesthesia was maintained using a continuous IV infusion of propofol (0.5–0.9 mg/kg/min) administered by a syringe pump (Becton–Dickinson Pilot Anaesthesia CE 0459). The infusion rate was altered depending on clinical judgement (normal recordings for pulse rate, heart rhythm, respiratory rate, end-tidal carbon dioxide tension, systemic arterial blood pressure and saturation of haemoglobin, and the lack of

spontaneous movement and a slight palpebral reflex). Lactated Ringer's solution was administered IV at a rate of 10 ml/kg /h.

### 2.3. Electroencephalographic recordings

After endotracheal intubation, a 17 channel monopolar montage (F7, F3, Fz, F4, F8, T3, C3, Cz, C4, T4, T5, P3, Pz, P4, T6, O1, O2; sensitivity = 5  $\mu$ V/mm; time constant = 0.3 s;  $Hf$  = 30 Hz; Notch and Muscular filters inserted; reference: on the bridge of the nose between the eyes; ground: caudally to the external occipital protuberance) was used to record bio-electrical activity. Intramuscular lidocaine injections were not used. Nineteen EEG needles (thirty-gauge 15 mm monopolar stainless steel needle electrodes, BIONEN S.a.s.) were used as subdermal active, reference, and ground electrodes. A method of standardized placement of EEG electrodes (Fig. 1), similar to the 10–20 international system used for the humans, was used as described by Bergamasco et al. (1999). Five minutes after intubation, EEG recording was started and continued for 20 min. Then EEG data were stored on an optical disk (13.335 cm Optical Disk Cartridge, OC-800 786 Megabytes, Maxtor) in an acquisition station (Sirius Galileo System) for later analyses.

### 2.4. Visual examination

Before performing the quantitative analysis of the bio-electrical activity, visual examination of the EEG traces of all the dogs was done. Special emphasis has been placed on artefact detection and elimination, because they strongly affect frequency analysis of the EEG (q-EEG). Ocular movements, cardiovascular and

muscular activity, physiological rhythmic movements, or artefacts depending on recording environment (i.e., electrical interference of the powered devices connected to the animals, movement of personnel, acoustic interference) can lead to an incorrect interpretation of the quantitative analysis. For these reasons, from the original sample of twenty dogs, we selected 10 subjects (B07, B08, B10, B12, B13, B14, B15, B18, B19, and B20; mean age = 13.8 months; average weight: 12.71 kg) whose EEG recordings were free from any kind of artefacts.

### 2.5. Quantitative analysis

Bio-electrical activity was analysed by a server (Star Galileo System) using an integrated software programme (Fast Fourier Transform, FFT) at the Neurosciences Department of Turin University. Ten replications of sixty, artefact-free 2-s epochs were selected randomly at three different intervals: (a) at the beginning of the recording (B. PROP1 = group P1); (b) after 5 min (B. PROP2 = group P2), and (c) during the last 2 min (B. PROP3 = group P3). FFT was calculated for each channel and averaged. The spectral bands of  $\delta$  (0.5–4.0 Hz),  $\theta$  (4.5–8.0 Hz),  $\alpha$  (8.5–12.0 Hz), and  $\beta$  (12.5–30.0 Hz) were calculated and expressed as absolute power ( $\mu$ V<sup>2</sup>), relative power (%), median frequency. The topography of the absolute power of four different areas (F: frontal electrodes—F7, F3, Fz, F4, F8-; TC: temporo-central electrodes—T3, C3, Cz, C4, T4-; TP: temporo-posterior electrodes—T5, P3, Pz, P4, T6-; O: occipital electrodes—O1, O2-), and of two other groups of electrode sets (a—F without Fz, TC without Cz, TP without Pz and O; b—median sagittal line electrodes: Fz, Cz, and Pz) was compared in the three groups P1–P3.

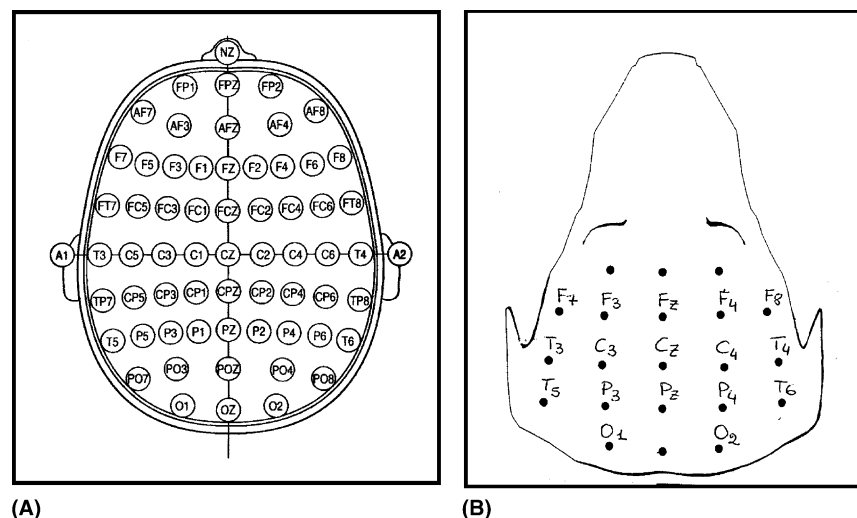


Fig. 1. (A) Electrode nomenclature in the International Federation of Clinical Neurophysiology's 10–20 system with additional electrode site names. (B) Montage used in this study. Numbers indicate the hemispheric site; even numbers, right hemisphere; odd numbers, left hemisphere; F, frontal; C, central; P, parietal; T, temporal; O, occipital; Fz, Cz, Pz, medial sagittal line electrodes.

## 2.6. Statistical analysis

A Kolmogorov–Smirnov test for normality was employed to check the gaussian distribution of q-EEG data and common logarithmic transformation of data was performed in order to obtain the best approximation of normal distribution for the absolute power of spectral analysis (Graph Pad InStat 3). One-way ANOVA in repeated measures was used to value significant differences among the three groups P1, P2, and P3 (Graph Pad InStat 3). The difference between means was considered significant if  $P < 0.05$ .

## 3. Results

The metabolic and haematological profile of the dogs in this study were within normal limits (Willard et al., 1999), as were the results of the cerebrospinal fluid samples (protein  $< 25$  mg/dl; cells/cmm  $< 5$ ; Pandy test: negative). All physiological parameters recorded during the anaesthesia remained within normal ranges (Short, 1987).

For neuropathological evaluation, the selected dogs for q-EEG were euthanased by barbiturates. Brain and spinal cords were processed for routine histopathological evaluation, the results of which were normal.

The preliminary visual examination of EEG recordings from the dogs revealed spindles, k-complexes, vertex sharp transients, and positive occipital sharp transients that were superimposed on a low background activity (Fig. 2). All these features had a different expression in frontal derivations compared to central and posterior derivations. k-Complexes were detectable in all the derivations, although their main expressiveness was located at the vertex (Cz). Spindles were asymmetrically distributed over both hemispheres. Vertex sharp transients were mainly expressed at the vertex (Cz), but were also detected at Fz and at the adjacent electrodes (F3, F4, C3, C4). Positive occipital sharp transients were detectable in O1 and O2, as well as in posterior derivations.

The results of the q-EEG findings of the three groups (P1, P2, P3) are summarized in Figs. 3 and 4. We found a prevalence of slow rhythms  $\delta$  (0.5–4.0 Hz) and  $\theta$  (4.5–8.0 Hz) in all groups, while fast rhythms  $\alpha$  (8.5–12.9 Hz)

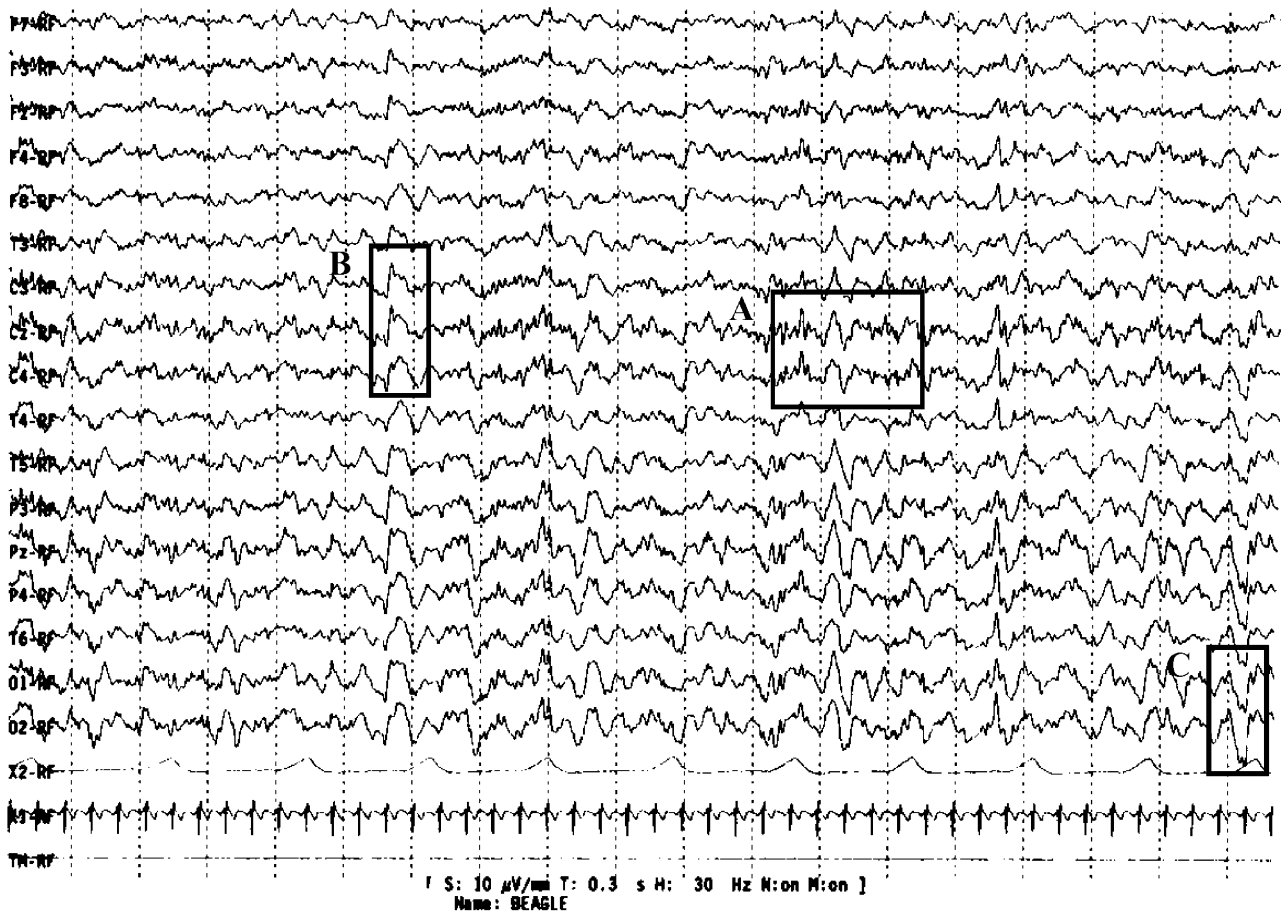


Fig. 2. EEG traces of Beagle 13. Recording features revealed at the visual examination of the EEG, namely spindles and k-complexes (A), vertex sharp waves (B), and positive occipital sharp transients (C) are superimposed on the low background activity.

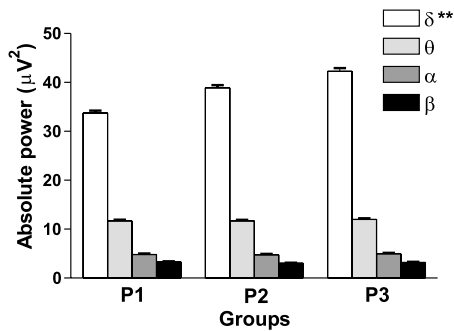


Fig. 3. Absolute ( $\mu\text{V}^2$ ) power data (mean  $\pm$  SEM) recorded from all the electrodes of the four frequency bands ( $\delta$ ,  $\theta$ ,  $\alpha$ , and  $\beta$ ) in the three groups (P1, P2, and P3). \*\* $P < 0.01$  (one-way ANOVA in a repeated measure) for  $\delta$  absolute power data.

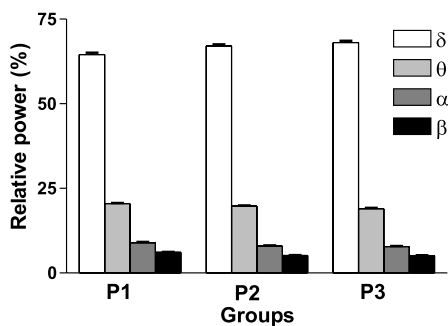


Fig. 4. Relative (%) power data (mean  $\pm$  SEM) recorded from all the electrodes of the four frequency bands ( $\delta$ ,  $\theta$ ,  $\alpha$ , and  $\beta$ ) in the three groups (P1, P2, and P3).

and  $\beta$  (12.5–30.0 Hz) were poorly represented.  $\delta$  rhythms showed a mild progressive increase in both absolute and relative power data for all groups. Absolute power data reported no significant differences for  $\theta$ ,  $\alpha$ , and  $\beta$  frequency bands, but  $\delta$  rhythm showed a significant increase ( $P = 0.0011$ ). We also noted a progressive decrease of the median frequencies (Table 1) and the different power ratios between the three groups that had shown an uniform light plane of the anaesthesia throughout the EEG recording. However, no statistical significance was found. The light plane of the anaesthesia was assessed clinically by lack of spontaneous movement and slight palpebral reflex.

The results on the topographic distribution of the quantitative data recorded from the scalp are summa-

Table 1  
Absolute power ( $\mu\text{V}^2$ ) ratios between  $\theta/\delta$ ,  $\alpha/\delta$ , and  $\beta/\delta$  frequency bands and median frequency (Hz) of the three groups (P1, P2, and P3)

Absolute power ( $\mu\text{V}^2$ ) ratio	P1	P2	P3
$\theta/\delta$	0.328	0.3	0.281
$\alpha/\delta$	0.143	0.122	0.117
$\beta/\delta$	0.099	0.078	0.075
Median frequency (Hz)	6.16	4.07	3.96

rized in Fig. 5. We found a similar distribution of fast  $\alpha$  and  $\beta$  rhythms with a pronounced antero-posterior subdivision. Slow rhythms are more complex. The results on  $\delta$  frequency bands do not show the antero-posterior subdivision, but a dominant localization in O and a minimum value in TC.  $\theta$  frequency bands started with an antero-posterior subdivision, but were less pronounced as fast frequency bands of the anterior (F–TC) and posterior (TP–O) electrode sets.

The results of the electrode set (a) (F without Fz, TC without Cz, TP without Pz and O) shared the same trend and distribution of the signal described above, but did not have a pronounced antero-posterior subdivision. The results of medial sagittal line electrodes ((b) Fz, Cz, and Pz) (Fig. 6) indicate that the maximum values of  $\delta$  rhythm were found in Pz of the posterior electrodes (TP), and the minimum values in Cz of the anterior electrodes (TC).  $\theta$  Rhythm showed a maximum value in Cz and a minimum in Pz, as well as  $\alpha$  and  $\beta$ . No statistical differences of the topographic distribution between the three groups were observed.

#### 4. Discussion

Propofol is alleged to possess both pro- and anti-convulsant properties, leading to controversy regarding its use in human patients with a history of seizures (Committee on Safety of Medicine, 1989). Neurological side effects may be due to the action of propofol on specific areas of the central nervous system that produce seizure-like activity. Hopkins (1988) suggested implication of the dopaminergic pathways, whereas Soar et al. (1990) hypothesized an effect on glycine metabolism in subcortical structures. Fiset et al. (1999) suggested, in a positron emission tomographic study, that propofol acts on the reticulothalamic system and that some cortical areas are more sensitive to the GABAergic inhibition caused by propofol on the basis of their network of corticocortical connections. In addition, they reported an increase in regional cerebral blood flow in the cerebellum that might be related to the initial increase in muscle tone and jerking movements frequently seen in the early stage of propofol-induced general anaesthesia. However, propofol also affects both serotonergic (Shyr et al., 1997) and cholinergic (Flood et al., 1997) neurotransmitter systems. It has been reported (Tung et al., 2001) that low doses of propofol potentiated the effects of GABA on the GABA receptor, while higher doses directly activated the GABA<sub>A</sub> receptor (Hales and Lambert, 1991). It is possible that at low doses propofol has a disinhibitory effect, and at higher doses it has an antiepileptogenic effect by raising the excitatory threshold (Baraka and Aoud, 1997). Conversely, Glowaski and Wetmore (1999) reported that propofol in low dosage did not cause excitement and the authors

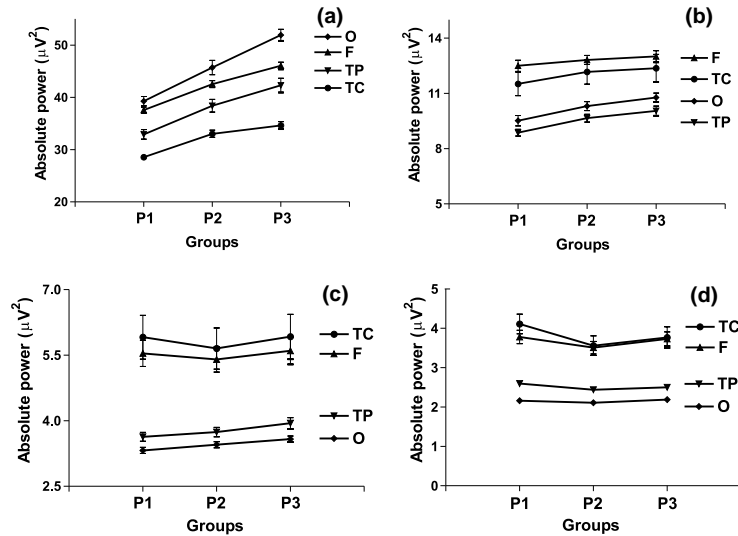


Fig. 5. Topographic distribution of the absolute power ( $\mu V^2$ ) data (mean  $\pm$  SEM) recorded from frontal electrodes (F), temporo-central electrodes (TC), temporo-posterior electrodes (TP), and occipital electrodes (O) of the four frequency bands  $\delta$  (a),  $\theta$  (b),  $\alpha$  (c), and  $\beta$  (d) in the three groups (P1, P2, and P3).

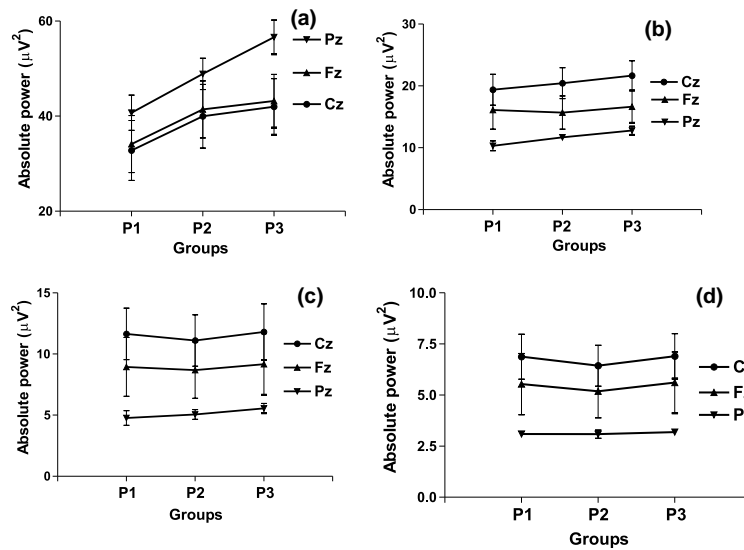


Fig. 6. Topographic distribution of the absolute power ( $\mu V^2$ ) data (mean  $\pm$  SEM) recorded from medial sagittal line electrodes (Fz, Cz, and Pz) of the four frequency bands  $\delta$  (a),  $\theta$  (b),  $\alpha$  (c), and  $\beta$  (d) in the three groups (P1, P2, and P3).

proposed its use for sedation of small animals undergoing non-painful procedures. However, the molecular mechanisms underlying the sleep-inducing effects of propofol as well as its pro-convulsant properties are incompletely understood (Trapani et al., 2000) and controversy on its use are still present in the literature.

In veterinary medicine, propofol has been used successfully to control seizures occurring after surgical treatment of portosystemic shunts in dogs and cats (Heldman et al., 1999) and refractory seizures of intracranial origin (Steffen and Grasmuek, 2000). Dystonic movements in dogs following propofol anaesthesia have

been described (Smedile et al., 1996; Davies, 1991). Both activation of the EEG and burst suppression have been reported in human patients affected by epilepsy under propofol anaesthesia at different dosage regimens (Smith et al., 1996). EEG burst suppression has been reported under propofol anaesthesia in the dog (Kusters et al., 1998) but Soriano et al. (2000) reported that electroencephalogram spikes due to spontaneous activity or cortical stimulation were well detected under propofol anaesthesia during awake craniotomies in children. Samra et al. (1995) reported that they were unable to demonstrate a significant change in epileptiform activity

with sedative doses of propofol in human patients suffering from complex partial epilepsy. Diagnostic EEG recordings under propofol anaesthesia were performed in dogs with idiopathic epilepsy (Jaggy and Bernardini, 1998) and these authors also reported that paroxysmal discharges detected on the EEG can be consistent with the interictal epileptic activity, suggesting that propofol anaesthesia does not suppress spontaneous epileptiform activity.

It would seem that the EEG findings are dose-related and eventual paroxysmal discharges could correlate with low doses of propofol (Leijten et al., 2001). In the present study we did not observe any excitatory phenomena as reported in other studies where propofol was used as the sole anaesthetic agent or in combination with other drugs (Bufalari et al., 1995, 1996); moreover EEG burst-suppression or paroxysmal activity were not observed. The effect of the dosage of propofol used in the present study was associated with an increase in the slow frequency band  $\delta$  on the raw EEG, whereas faster frequency bands  $\alpha$  and  $\beta$  were constant throughout the recording.

Since important EEG transients are overlooked by data processing techniques, EEG data must be examined and interpreted visually along with any computer-based EEG analysis. In addition, EEG visual inspection can identify a variety of artefacts that should be rejected in order to perform an accurate EEG quantitative analysis. Techniques for the automatic detection and rejection or minimization of artefacts have been devised (Barlow, 1986), but none has yet reached an adequate level of reliability.

Spindles in the EEG traces of the present study were most probably induced by the anaesthetic agent (Fiset et al., 1999; Romano et al., 1990), and were comparable to the superimposed low amplitude-fast activity reported in two medetomidine-propofol EEG activity studies (Accatino et al., 1997; Jaggy and Bernardini, 1998) and morphologically similar to those appearing in non-REM (N-REM) sleep of humans (de Feo and Mecarelli, 1995). The localization of spindles is of importance too. They were mainly noted in fronto-central derivations and along the median sagittal electrodes. This distribution pattern is different from the localization of the superimposed low amplitude fast activity reported in dogs with idiopathic epilepsy (Jaggy and Heynold, 1998). Interictal EEG recordings of dogs revealed widespread distribution of abnormal activity. Data from the present study and from that of Jaggy and Heynold (1998) argue a difference between normal, well localized spindle activity in healthy animals, and epileptogenic, widespread activity in epileptic dogs.

The background activity must be also considered when a diagnostic EEG is performed. There are several neurological impairments that are not related to abnormal transients on the raw EEG, but the background

EEG pattern can be affected (d'Onofrio et al., 1996; John et al., 1988). In these cases, q-EEG can offer information about the frequency content that are missed from visual examination. Widespread distribution of  $\delta$  activity noted in this study agrees with data from human literature (Reves et al., 1994; Romano et al., 1990). Data from the veterinary literature indicate a depression of the total amplitude of brain wave activity when propofol is used as an induction drug for inhalant anaesthetic agents in dogs (Bufalari et al., 1998). Good correlation has been shown between the MF and the blood concentrations of propofol in humans (Schüttler et al., 1985). Similar slowing of the EEG (i.e., decrease of the MF) with increasing anaesthetic concentrations was noted in dogs and was enhanced by power ratios (Drummond et al., 1991). Statistical analysis pointed out that the progressive increase in  $\delta$  band along the three groups was significant and probably propofol dose-dependent.

Results on the topographical distribution of the quantitative bio-electrical data correspond well with the human data (Russell, 1995). Faster frequency activity was predominantly noted in the more anterior regions of the scalp of humans under sedation. This observation was independent from the anaesthetic agents which were used for sedation. The data from our dogs were comparable. In addition, slowing in the  $\theta$  and  $\delta$  frequency ranges was initially more prominent in anterior areas but later become generalized. Medial sagittal line electrodes seemed to contribute strongly to the reported topography in our study.

The results of the present study show that propofol anaesthesia induced by a bolus of 6 mg/kg followed by continuous intravenous infusion (0.5–0.9 mg/kg/min) produces a characteristic EEG background activity pattern with prevalence of slow rhythms  $\delta$  and  $\theta$ . No abnormal EEG transients were reported.

Furthermore, spindles appeared to be a constant EEG feature in anaesthetized dogs whether healthy or affected by idiopathic epilepsy (Jaggy and Bernardini, 1998; Srenk and Jaggy, 1996). These findings suggest that spindles are most probably related to propofol anaesthesia, as reported also in humans (Mahla et al., 1992). Differences in the distribution of spindles in the two dog populations suggest this may be of clinical importance in the confirmation of idiopathic epilepsy.

The topographic antero-posterior subdivision provides useful information for the diagnostic examination of the background EEG activity in dogs anaesthetized with propofol. The baseline localization of the different frequency bands should be taken into consideration when a pathological EEG is analysed. Therefore, fast activities observed in epileptic patients or slow rhythms in cases of brain neoplasia should be interpreted in the light of the topographical distribution of the different frequency bands.



## Acknowledgements

The authors thank Dr. Michael Mostert for linguistic revision. This work was supported by the Frauchiger Foundation (Grant No. 42321).

## References

- Accatino, A., Jaggy, A., Gaillard, C., Aeschbacher, G., 1997. Electroencephalographic findings in beagle dogs experimentally infected with canine distemper virus. *Journal of Veterinary Medicine B* 44, 39–48.
- Baraka, A., Aoud, M., 1997. Is propofol anticonvulsant or proconvulsant? *Canadian Journal of Anaesthesia* 44, 1027–1029.
- Barlow, J.S., 1986. Artifact processing (rejection and minimization) in the EEG data processing. In: Lopes da Silva, F.H., Storm van Leeuwen, W., Rémon, A. (Eds.), *Clinical applications of computer analysis of the EEG and other neurophysiological signals. Handbook of Electroencephalography and Clinical Neurophysiology, Revised Series, vol. 2.* Elsevier, Amsterdam, pp. 15–62.
- Bergamasco, L., Accatino, A., Jaggy, A., 1999. Methodical approach to digital electroencephalography and its use in veterinary medicine. *Veterinaria* 13, 7–22.
- Bufalari, A., Nilsson, L.E., Short, C.E., Giannoni, C., 1995. A comparative study of neurologically equivalent propofol anaesthetic combinations in the dog. *Journal of Veterinary Anaesthesiology* 22, 19–24.
- Bufalari, A., Short, C.E., Giannoni, C., Vainio, O., 1996. Comparative responses to propofol anaesthesia alone and with  $\alpha$  2-adrenergic medications in a canine model. *Acta Veterinaria Scandinavia* 37, 187–201.
- Bufalari, A., Miller, S.M., Giannoni, C., Short, C.E., 1998. The use of propofol as an induction agent for halothane and isoflurane anaesthesia in dogs. *Journal of the American Animal Hospital Association* 34, 84–91.
- Casati, A., Fanelli, G., Casaletti, E., Colnaghi, E., Cedrati, V., Torri, G., 1999. Clinical assessment of target-controlled infusion of propofol during monitored anaesthesia care. *Canadian Journal of Anaesthesia* 46, 235–239.
- Clark, D.L., Rosner, B.S., 1973. Neurophysiological effects of general anaesthetic: the electroencephalogram and sensory evoked responses in man. *Anesthesiology* 38, 564–582.
- Committee on Safety of Medicine, 1989. Propofol-convulsions, apnoea and delayed recovery from anaesthesia. *Current Problems* 26, 2–3.
- Daube, J.R., Harper, C.M., Litchy, W.J., Sharbrough, F.W., 1990. Intraoperative monitoring. In: Daly, D.D., Pedley, T.A. (Eds.), *Current Practice of Clinical Electroencephalography*, second ed.. Raven Press, New York, pp. 739–779.
- Davies, C., 1991. Excitatory phenomena following the use of propofol in dogs. *Journal of Veterinary Anaesthesia* 18, 48–51.
- de Feo, M.R., Mecarelli, O., 1995. Electroencefalogramma normale. In: de Feo, M.R., Mecarelli, O. (Eds.), *Testo atlante di elettroencefalografia clinica*, second ed.. Marrapese, Roma, pp. 143–189.
- d'Onofrio, F., Salvia, S., Peretta, V., Bonavita, V., Rodriguez, G., Tedeschi, G., 1996. Quantified-EEG in normal aging and dementias. *Acta Neurologica Scandinavica* 93, 336–345.
- Drummond, J.C., Brann, C.A., Perkins, D.E., Wolfe, D.E., 1991. A comparison of median frequency, spectral edge frequency, a frequency band power ratio, total power, and dominance shift in the determination of depth of anaesthesia. *Acta Anaesthesiologica Scandinavica* 35, 693–699.
- Duffy, F.H., Hughes, J.R., Miranda, F., Bernard, P., Cook, P., 1994. Status of quantitative EEG (QEEG) in clinical practice, 1994. *Clinical Electroencephalography* 4, VI–XXII.
- Fiset, P., Paus, T., Dalozé, T., Plourde, G., Meuret, P., Bonhomme, V., Hajj-Ali, N., Backman, S.B., Evans, A.C., 1999. Brain mechanisms of propofol-induced loss of consciousness in humans: a positron emission tomographic study. *The Journal of Neuroscience* 19, 5506–5513.
- Flood, P., Ramirez, L., Role, L., 1997.  $\alpha$ 2 $\beta$ 2 Neuronal nicotinic acetylcholine receptors in the central nervous system are inhibited by isoflurane and propofol, but  $\alpha$ 7-type nicotinic acetylcholine receptors are unaffected. *Anesthesiology* 86, 859–865.
- Glen, J.B., 1980. Animal studies of the anaesthetic activity of ICI 35868. *British Journal of Anaesthesia* 52, 731–742.
- Glowaski, M.M., Wetmore, L.A., 1999. Propofol: application in veterinary sedation and anaesthesia. *Clinical Techniques in Small Animal Practice* 14, 1–9.
- Hales, T.G., Lambert, J.J., 1991. The actions of propofol on inhibitory amino acid receptors of bovine adrenomedullary chromaffin cells and rodent central neurones. *British Journal of Pharmacology* 104, 619–628.
- Hall, L.W., Chambers, J.P., 1987. A clinical trial of propofol infusion anaesthesia in dogs. *Journal of Small Animal Practice* 28, 623–638.
- Heldman, D.E., Holt, D.E., Brockman, S.J., Brown, D.C., Perkowsky, S.Z., 1999. Use of propofol to manage seizure activity after surgical treatment of portosystemic shunts. *Journal of Small Animal Practice* 40, 590–594.
- Hopkins, C.S., 1988. Recurrent opisthotonus associated with anaesthesia. *Anaesthesia* 43, 904.
- Jaggy, A., Bernardini, M., 1998. Idiopathic epilepsy in 125 dogs: a long-term study. Clinical and electroencephalographic findings. *Journal of Small Animal Practice* 39, 23–29.
- Jaggy, A., Heynold, Y., 1998. Idiopathic epilepsy in the dog. *The European Journal of Companion Animal Practice* VIII, 51–57.
- John, R.E., Prichep, L.S., Friedman, J., Easton, P., 1988. Neurometrics: computer-assisted differential diagnosis of brain dysfunctions. *Science* 239, 162–169.
- Kusters, A.H., Vijn, P.C., Van den Brom, W.E., Haberham, Z.L., Venker-van Haagen, A.J., Hellerbrekers, L.J., 1998. EEG-burst-suppression-controlled propofol anaesthesia in the dog. *Veterinary Quarterly* 20, 105–106.
- Leijten, F.S.S., Teunissen, N.W., Wieneke, G.H., Knape, J.T.A., Schooben, F.A.M., van Huffelen, A.C., 2001. Activation of interictal spiking in mesiotemporal lobe epilepsy by propofol-induced sleep. *Journal of Clinical Neurophysiology* 18, 291–298.
- Lowson, S., Gent, J.P., Goodchild, C.S., 1990. Anticonvulsant properties of propofol and thiopentone: comparison using two tests in laboratory mice. *British Journal of Anaesthesia* 64, 59–63.
- Mahla, M.E., Pashayan, A.G., Grundy, B.L., Mixon, S., Richards, R.K., Day, A.L., 1992. Prolonged anaesthesia with propofol or isoflurane: intraoperative electroencephalographic patterns and postoperative recovery. *Seminars in Anaesthesia* XI (Suppl. 1), 31–32.
- Reves, J.G., Glass, P.S., Lubarsky, D.A., 1994. Nonbarbiturate intravenous anaesthetics. In: Miller, R.D. (Ed.), *Anaesthesia*, fourth ed.. Churchill Livingstone, New York, pp. 247–290.
- Romano, R., de Feo, M.R., Favaro, R., Arcioni, R., Rina, M.F., Mecarelli, O., Fierro, G., 1990. Modificazioni elettroencefalografiche indotte dall'anaesthesia con propofol nell'uomo. *Acta Anestesiologica Italiana* 41, 318–320.
- Russell, G.B., 1995. Basic scalp electroencephalography. In: Rodichok, L.D., Russell, G.B. (Eds.), *Primer of intraoperative neurophysiologic monitoring.* Butterworth-Heinemann, Oxford, pp. 65–80.
- Samra, S.K., Sneyd, J.R., Ross, D.A., Henry, T.R., 1995. Effect of propofol sedation on seizures and intracranially recorded epileptiform activities in patients with partial epilepsy. *Anesthesiology* 82, 843–851.

- Schüttler, J., Stoekel, H., Schwilden, H., 1985. Pharmacokinetic and pharmacodynamic modelling of propofol ('Diprivan') in volunteers and surgical patients. *Postgraduate Medical Journal* 61 (Suppl. 3), 53–54.
- Short, C.E., 1987. *Principle and Practice of Veterinary Anaesthesia*. William and Wilkins, Baltimore, MD.
- Short, C.E., Bufalari, A., 1999. Propofol anaesthesia. *Veterinary Clinic of North America Small Animal Practice* 29, 747–778.
- Shyr, M.H., Tsai, T.H., Yang, C.H., Chen, H.M., Ng, H.F., Tan, P.P., 1997. Propofol anaesthesia increases dopamine and serotonin activities at the somatosensory cortex in rats: a microdialysis study. *Anaesthesia and Analgesia* 84, 1344–1348.
- Smedile, L.E., Duke, T., Taylor, S.M., 1996. Excitatory movements in dog following propofol anaesthesia. *Journal of the American Animal Hospital Association* 32, 365–368.
- Smith, M., Smith, S.J., Scott, C.A., Harkness, W.F.J., 1996. Activation of the electrocorticogram by propofol during surgery for epilepsy. *British Journal of Anaesthesia* 76, 499–502.
- Soar, J., Smith, M.B., Morris, P.J., Dolin, S.J., 1990. Does glycine antagonism underlie the excitatory effects of propofol and methohexitone? *British Journal of Anaesthesia* 66, 398.
- Soriano, S.G., Eldredge, E.A., Wang, F.K., Kull, L., Madsen, J.R., Black, P.Mc.L., Riviello, J.J., Rockoff, M.A., 2000. The effect of propofol on intraoperative electrocorticography and cortical stimulation during awake craniotomies in children. *Paediatric Anaesthesia* 10, 29–34.
- Srenk, P., Jaggy, A., 1996. Interictal electroencephalographic findings in a family of golden retrievers with idiopathic epilepsy. *Journal of Small Animal Practice* 37, 317–321.
- Steffen, F., Grasmuek, S., 2000. Propofol for treatment of refractory seizures in dogs and a cat with intracranial disorders. *Journal of Small Animal Practice* 41, 496–499.
- Steiss, J.E., 1988. A survey of current techniques in veterinary electrodiagnostics: EEG, spinal evoked and brain stem auditory evoked potential recording. *Veterinary Research Communications* 12, 281–288.
- Trapani, G., Altomare, C., Liso, G., Sanna, E., Biggio, G., 2000. Propofol in anaesthesia. Mechanism of action, structure-activity relationships, and drug delivery. *Current Medicinal Chemistry* 7, 249–271.
- Tung, A., Bluhm, B., Mendelson, W.B., 2001. Sleep inducing effects of propofol microinjection into the medial preoptic area are blocked by flumazenil. *Brain Research* 908, 155–160.
- Wang, B., Bai, Q., Jiao, X., Wang, E., White, P.F., 1997. Effect of sedative and hypnotic doses of propofol on the EEG activity of patients with or without a history of seizure disorders. *Journal of Neurosurgical Anaesthesiology* 9, 335–340.
- Watkins, S.B., Hall, L.W., Clarke, K.W., 1987. Propofol as an intravenous anaesthetic agent in dogs. *Veterinary Record* 120, 326–329.
- Willard, M.D., Tvedten, H., Turnwald, G.H., 1999. *Small Animal Clinical Diagnosis by Laboratory Methods*. W.B. Saunders Company, Philadelphia, PA.