

AperTO - Archivio Istituzionale Open Access dell'Università di Torino

Liver transplantation for symptomatic centrohepatic biliary cystadenoma

This is a pre print version of the following article:

Original Citation:

Availability:

This version is available <http://hdl.handle.net/2318/84071> since 2016-11-11T09:56:39Z

Published version:

DOI:10.1016/j.clinre.2011.03.014

Terms of use:

Open Access

Anyone can freely access the full text of works made available as "Open Access". Works made available under a Creative Commons license can be used according to the terms and conditions of said license. Use of all other works requires consent of the right holder (author or publisher) if not exempted from copyright protection by the applicable law.

(Article begins on next page)

Manuscript Number: GCB-D-11-00004R1

Title: Liver transplantation for symptomatic centrohepatic biliary cystadenoma.

Article Type: Clinical challenge

Corresponding Author: Dr. Renato Romagnoli, M.D.

Corresponding Author's Institution: A.O.U. San Giovanni Battista di Torino

First Author: Renato Romagnoli, M.D.

Order of Authors: Renato Romagnoli, M.D.; Damiano Patrono, M.D.; Gianluca Paraluppi, M.D.; Ezio David, M.D.; Francesco Tandoi, M.D.; Paolo Strignano, M.D.; Francesco Lupo, M.D.; Mauro Salizzoni, M.D.

Abstract: ABSTRACT

Biliary cystadenoma is a rare benign cystic tumor of the liver. The mainstay of treatment is complete resection, either by enucleation or by formal hepatectomy, since incomplete removal entails not only constant recurrence but also the risk of malignant transformation to cystadenocarcinoma. A case of symptomatic centrohepatic biliary cystadenoma involving the main vasculo-biliary structures of the liver is reported. After an unsuccessful attempt at resection resulting in an intrahepatic biliary injury, relief of jaundice and radical excision were achieved by total hepatectomy and liver transplantation. The patient is now alive and well 4 years after transplant disease-free, with normal liver and renal function while receiving everolimus monotherapy. This is the first report of liver transplantation performed for the treatment of this tumor. With the case on the background, diagnostic aspects and available therapeutic strategies for biliary cystadenoma are reviewed and discussed.

Suggested Reviewers: Vincenzo Mazzaferro MD
Chief Surgeon, Liver Transplant and Digestive Surgery, Istituto Nazionale Tumori Milano - Italy
vincenzo.mazzaferro@istitutotumori.mi.it
Internationally reknown expert in both transplant and liver surgery for hepatic neoplasms

Opposed Reviewers:

e-component

[Click here to download e-component: Revision Letter.doc](#)

Liver transplantation for symptomatic centrohepatic biliary cystadenoma.

Renato ROMAGNOLI, MD, FEBS, Damiano PATRONO, MD, Gianluca PARALUPPI, MD, Ezio DAVID, MD, Francesco TANDOI, MD, Paolo STRIGNANO, MD, Francesco LUPO, MD, and Mauro SALIZZONI, MD

General Surgery 8 and Liver Transplantation Center,
University of Turin, A.O.U. San Giovanni Battista,
Turin, ITALY

Original article

Category: Clinical Challenges

Running head : liver transplantation for centrohepatic biliary cystadenoma

Key words : symptomatic biliary cystadenoma, unresectable biliary cystadenoma, complete excision, resectional liver surgery, liver transplantation

Disclaimer: nothing to disclose

Word count: 2,584

Address for reprints and correspondence :

Mauro SALIZZONI, MD
Professor of Surgery at the University of Turin
Head of General Surgery 8 and
Liver Transplantation Center
A.O.U. San Giovanni Battista
Corso Bramante 88
10126 Turin - ITALY
Phone : # 39.011.6334374
Fax : # 39.011.6965923
E-mail : mauro.salizzoni@unito.it

LIST OF ABBREVIATIONS

- BCA, biliary cystadenoma
- BCC, biliary cystadenocarcinoma
- LT, liver transplantation
- CA 19-9, carbohydrate antigen 19-9
- α -FP, alpha-fetoprotein
- CEA, carcino-embryonic antigen
- POD, postoperative day

ABSTRACT

Biliary cystadenoma is a rare benign cystic tumor of the liver. The mainstay of treatment is complete resection, either by enucleation or by formal hepatectomy, since incomplete removal entails not only constant recurrence but also the risk of malignant transformation to cystadenocarcinoma. A case of symptomatic centrohepatic biliary cystadenoma involving the main vasculo-biliary structures of the liver is reported. After an unsuccessful attempt at resection resulting in an intrahepatic biliary injury, relief of jaundice and radical excision were achieved by total hepatectomy and liver transplantation. The patient is now alive and well 4 years after transplant, disease-free, with normal liver and renal function while receiving everolimus monotherapy. This is the first report of liver transplantation performed for the treatment of this tumor. With the case on the background, diagnostic aspects and available therapeutic strategies for biliary cystadenoma are reviewed and discussed.

INTRODUCTION

Biliary cystadenoma (BCA) is a rare benign tumor of the liver presenting usually as a large multiloculated cyst containing a variably coloured mucinous fluid. Histological examination reveals a limiting mucus-secreting cuboidal or columnar epithelium of biliary origin, frequently surrounded by a mesenchymal “ovarian-like” stroma [1,2]. When symptomatic, most frequent complaints include abdominal pain, mass effect, nausea and vomiting [3,4]. Occasionally BCAs can determine obstructive jaundice [5]. Owing to their origin and size, BCAs are frequently located close to the main hepatic vascular structures and can involve the bile ducts [1,5,6,7,8,9]. Curative treatment is based on complete excision, by either enucleation or formal hepatic resection, because incomplete removal implies constant recurrence and risk of malignant transformation to biliary cystadenocarcinoma (BCC) [4,6,10].

In this paper, a case of BCA is illustrated in which relief of symptoms and complete excision could eventually be obtained in no other way than total hepatectomy and liver transplantation (LT). To our knowledge, this is the first report of LT performed for this indication. In the light of this case, diagnostic aspects and currently available therapeutic strategies for BCA are reviewed and discussed.

CASE REPORT

A 53-year-old woman was referred to our tertiary care center from a country hospital in October 2006 because of the discovery of a large lesion, 10 cm in diameter, centrally located in the liver across segments 4 and 8. She had a recent history of obstructive jaundice in the absence of abdominal symptoms. Magnetic resonance and computed

tomography imaging revealed a cystic mass with some septations in its caudal portion, lying on the Glissonian bifurcation and causing dislocation of the *porta hepatis* and compression of the main right and left hepatic ducts with peripheral bile duct dilatation (fig.1). On admission, total and conjugated bilirubin were 11.3 and 8.5 mg/dl, respectively, aspartate aminotransferase 77 U/L, alanine aminotransferase 137 U/L, gamma-glutamyltranspeptidase 107 U/L, alkaline phosphatase 357 U/L. Serum chemistries otherwise revealed normal liver function and normal carbohydrate antigen 19-9 (CA 19-9), alpha-fetoprotein (α -FP) and carcino-embryonic antigen (CEA) levels. Serological testing for echinococcal disease was negative and she did not originate from an endemic area. Based on preoperative findings a clinical diagnosis of intrahepatic BCA was made and she was scheduled for open surgical exploration without delay. On operation, a centrohepatic round mass not abutting on the liver surface was observed. Cholecystectomy was performed and intraoperative cholangiography through the cystic duct stump confirmed external compression on both the right and left hepatic ducts (fig.2A). No communication between the cyst and the biliary tree was noted. The hepatic parenchyma covering the lesion was incised for a 2 cm depth on the anterior surface of the liver (segments 4-8) searching for a dissection plane along the cystic wall. The attempt at enucleation immediately failed due to the lack of an obvious anatomical plane between the cyst and the parenchyma, obliterated by the presence of dense fibrous tissue. The cyst was accidentally opened and unroofing of the lesion was carried out using a boundary of sponges to protect the abdomen from dissemination of cystic material. A large centrohepatic cavity eventually appeared with some internal septations arising from the floor, containing a mucinous, straw-coloured fluid. The main Glissonian pedicles imprinted the floor of the cavity, indicating strict anatomical relationship

1
2
3
4 between the cyst and the hilar plate. Results of frozen section examination of fragments
5
6 of cystic wall were consistent with the preoperative diagnosis of BCA. After careful
7
8 drainage and decompression, a second effort to perform enucleation of the lesion
9
10 resulted in an injury to the right hepatic duct at the anterior/posterior bifurcation, as
11
12 evidenced by repeated cholangiography. The irregular morphology of the entire
13
14 intrahepatic biliary tree was patent at this time (fig.2B). A T-tube was inserted into the
15
16 right hepatic duct through the injured wall. A further attempt to find a dissection plane
17
18 between the cystic wall and the vasculo-biliary elements of the left hemi-liver failed, due
19
20 to the ubiquitous presence of dense tissue around the cyst. At that time, continuation of
21
22 surgery was deemed both useless and unsafe, because of the extensive and bilateral
23
24 involvement of the main intrahepatic vasculo-biliary structures making radical excision of
25
26 the BCA technically unfeasible by any type of liver resection (fig.3). The possibility of LT
27
28 was immediately considered and more material from the cystic wall was obtained for
29
30 histological examination in order to rule out malignancy. The T-tube was left in place for
31
32 biliary drainage. Postoperative course was complicated by haemoperitoneum due to
33
34 bleeding from the dissected intrahepatic areas, which required surgical revision and
35
36 haemostasis with thrombin glue and filling of the open cavity with an omental flap on
37
38 postoperative day (POD) 2. Final pathologic examination of the large biopsy samples
39
40 confirmed the diagnosis of BCA; no areas of intestinal metaplasia or malignant
41
42 degeneration were observed. Work-up for LT was rapidly completed. She was placed
43
44 on the waiting list on POD 12, after signing a specific informative consent in which the
45
46 risks of transplantation (morbidity/mortality of the procedure, need of long-term
47
48 immunosuppression) were clearly explained in comparison with its expected benefits
49
50 (complete and permanent relief of jaundice, radical excision of a lesion with a potential
51
52
53
54
55
56
57
58
59
60
61
62
63
64
65

1
2
3
4 **for cancerous transformation**). She was discharged home on POD 16, with the T-tube
5
6 patent for drainage and a total bilirubin level of 2.8 mg/dl. A whole liver allograft from an
7
8 ABO-compatible donor after brain death became available in November 2006, i.e. on
9
10 POD 42 from the first surgery. Abdominal exploration at the time of LT evidenced no
11
12 sign of extrahepatic dissemination of mucinous material. Omentectomy was performed
13
14 *en bloc* with the native liver hepatectomy (fig.3). Transplant surgery was a routine using
15
16 the piggy-back technique without veno-venous by-pass and the post-transplant course
17
18 was uneventful with a discharge 7 days after LT. Explant pathology confirmed a cystic
19
20 lesion lined by a single-layer columnar epithelium lying on a thick mesenchymal
21
22 “ovarian-like” stroma (fig.4). No areas of malignant transformation were detected,
23
24 confirming the pre-transplant diagnosis of BCA. She is now 4 years after LT, free from
25
26 complications and disease recurrence, living a normal life in general good health. Since
27
28 then, liver graft and renal functions have always remained normal, while
29
30 immunosuppressive therapy was tapered from an initial scheme based on tacrolimus
31
32 and mofetil mycophenolate to a current single-drug m-TOR inhibitor regimen (oral
33
34 everolimus, Certican[®], 2 mg bid to keep 5-6 ng/ml trough levels).
35
36
37
38
39
40
41
42
43
44

45 **DISCUSSION OF THE INDICATION**

46
47
48 First reported by Keen in 1892 [11], BCAs are usually large, multiseptated cysts limited
49
50 by a cuboidal or columnar type epithelium. The presence of CA 19-9 in the epithelial
51
52 layer evidenced by immunohistochemical analysis suggests their biliary origin [2]. The
53
54 vast majority of BCAs are mucinous cystadenomas [2] and occur mostly in middle-aged
55
56 females. About 85% of BCAs are surrounded by an “ovarian-like” stroma rich in spindle-
57
58
59
60
61
62
63
64
65

1
2
3
4 shaped cells with prominent nucleoli; such stroma is observed only in females [12].
5
6
7 Reported incidence of BCAs is 5% of all hepatic cysts based on an autopsy series of
8
9 1977 [13]. If for Regev [14] BCAs represent 11% of all large (≥ 4 cm) hepatic cysts
10
11 referred for treatment, their finding remains definitely rare. Over the last 12 years, more
12
13 than 1500 LTs and nearly 1000 liver resections were performed in our tertiary referral
14
15 center in Northern Italy; yet, only 6 cases of BCA were encountered [personal
16
17 unpublished data]. The presence of intestinal metaplasia of the epithelium constitutes
18
19 the first sign of progression towards malignant BCC, which is finally characterized by the
20
21 loss of epithelial architecture and nuclei stratification, cellular pleomorphism and
22
23 infiltration of the underlying stroma [3]. Prevalence of BCC in the published series is
24
25 highly variable ranging from 5 to 40 % of all BCAs [1,2,3,10].
26
27
28
29
30

31 The most frequently referred symptom is abdominal pain, which is reported by 54–80%
32
33 of patients [3,8,10,15,16]. Other symptoms include abdominal fullness or distension,
34
35 anorexia, nausea and vomiting. Less frequently BCAs present with intracystic
36
37 haemorrhage, intraperitoneal rupture or secondary infection. Inferior vena cava
38
39 thrombosis due to mass effect has also been described [15]. Obstructive jaundice can
40
41 result either from external compression or from polypoid protrusion of the lesion into the
42
43 bile ducts [5,17]. Diagnosis is based mainly on radiological studies. BCAs appear
44
45 typically as large multiloculated lesions with internal septations; sometimes a thickened
46
47 wall presenting contrast-enhancement is observed [18,19,20]. Unfortunately, imaging is
48
49 poorly specific in discriminating BCA from BCC, even if the finding of internal papillary
50
51 vegetations may raise the concern for malignant degeneration. Serum α -FP and CEA
52
53 levels are usually within normal values, while CA 19-9 levels can be elevated both in
54
55 BCA and BCC [7]. Percutaneous aspiration and analysis of cyst fluid often reveals a
56
57
58
59
60
61
62
63
64
65

1
2
3
4 marked but variable elevation in CA 19-9 levels, consistent with the biliary origin of the
5
6 cyst epithelium [21,22]. Cyst fluid CA 19-9 levels can help in differential diagnosis
7
8 between BCA and hydatid or simple cysts, as they are usually normal or minimally
9
10 elevated in the latter [21], but cannot help distinguish between BCA and BCC. If cyst
11
12 fluid cytology can reveal the presence of atypical cells, false negative results are
13
14 frequent since the technique often fails to retrieve malignant cells in case of BCC [7].
15
16 Therefore, cyst fluid analysis can be considered in the differential diagnosis with other
17
18 cystic liver lesions, but has no role in discriminating BCA from BCC. Furthermore, it
19
20 presents the theoretical risk of tumour seeding, with one well-documented case of
21
22 pleural carcinomatosis following percutaneous aspiration of a BCC [7]. Finally,
23
24 intraoperative examination of frozen sections was not completely reliable in some series
25
26 [4,23,24,25], in which it resulted negative for a BCC that was discovered afterwards on
27
28 the formalin-fixed specimen. This is why final pathology report is needed before making
29
30 any further prognostic judgement and therapeutic decision.
31
32

33
34
35
36
37
38 Appropriate surgical treatment of BCA, which is the 'cholangiocellular' counterpart of the
39
40 much more frequent 'hepatocellular' adenoma, is based on the same principle of
41
42 complete resection, either by enucleation or hepatectomy [26,27,28]. In fact,
43
44 fenestration, marsupialization, aspiration, sclerosis, internal Roux-en-Y drainage and
45
46 partial resection are followed by constant recurrence [4,6,28,29]. Complete resection is
47
48 mandatory also because diagnosis of BCC can be an incidental one, i.e. made only on
49
50 histological analysis of the surgical specimen [10]. In our experience all the six BCAs
51
52 were excised completely, 5 by resectional surgery (4 partial hepatectomies, 1
53
54 enucleation) and 1 by LT, with no recurrence at current follow-up [personal unpublished
55
56 data]. Radical surgical excision of BCAs involving major bile ducts and determining
57
58
59
60
61
62
63
64
65

1
2
3
4 obstructive jaundice can be technically challenging, requiring a major hepatic resection
5
6 sometimes associated with hepaticojejunostomy. Erdogan [5] described a series of 5
7
8 patients (4 cystadenoma and 1 cystadenocarcinoma) presenting obstructive jaundice.
9
10 Jaundice was intermittent in three patients and constant in two. In two patients
11
12 obstruction was caused by a polypoid protrusion inside the bile ducts, in three by
13
14 external compression. Communication between the cystic lesion and the biliary tree was
15
16 noted in only one patient. All of them were successfully managed by complete resection
17
18 of the lesion which required hepatectomy alone or associated with hepaticojejunostomy.
19
20 In the series reported by Koffron [23] three of 34 patients had jaundice and were
21
22 managed either by hepatic resection alone (2 patients) or by bisegmentectomy
23
24 combined with hepaticojejunostomy. Successful management of large centrohepatic
25
26 BCAs involving main vascular structures by enucleation of the lesion following the plane
27
28 immediately close to its wall has been reported. A dissection plane can often be
29
30 identified after drainage and decompression of the cyst [6,29]. In the absence of such
31
32 plane (making for a BCA unresectable in totality), some Authors have recently published
33
34 good results with partial or nearly-total resection associated with fulguration of the
35
36 remnant inner epithelium with Argon beam coagulator [10,23]. However, outcomes of
37
38 this procedure need further evaluation in the long run because partial resection entails
39
40 not only the risk of recurrence, but also the possibility to leave in place pathologic tissue
41
42 liable to undergo subsequent malignant transformation [4,30]. In this context, the
43
44 existence of a cystadenoma-cystadenocarcinoma sequence can be postulated on the
45
46 basis of the facts that approximately one third of BCCs present areas of benign
47
48 epithelium and that BCC patients are on average 10-15 years older than the BCA ones
49
50 [1,2,3].
51
52
53
54
55
56
57
58
59
60
61
62
63
64
65

1
2
3
4 In the present case, because of the clinical diagnosis of BCA and the peculiar location
5
6 of the lesion, no attempt at preoperative biliary drainage was undertaken before the first
7
8 laparotomy. Preoperative portal vein embolization (in view of the possibility of an
9
10 extended liver resection) was not considered either, not only due to the cholestatic state
11
12 with jaundice but also for the uncertainty of the type of resection potentially needed.
13
14 Unfortunately, at surgical exploration, both enucleation and hepatectomy were not
15
16 feasible. Thick and dense tissue had obliterated the space between the cystic
17
18 epithelium and the main bilateral vasculo-biliary structures, making the efforts to find a
19
20 dissection plane to enucleate BCA result in solely an intrahepatic biliary injury. In
21
22 addition, a partial resection of the cyst with fulguration of the remnant inner epithelium,
23
24 apart from its inherent risks (technical failure, recurrence and malignant transformation),
25
26 would not have likely relieved the jaundice in this patient, in whom massive fibrous
27
28 involvement of the biliary branches was present. These are the reasons why on the first
29
30 operation LT was evoked as the best solution for the difficult situation. Indeed, LT has
31
32 become an accepted therapy for end-stage liver disease with overall 1- and 5-year
33
34 survival rates of 90% and 81%, respectively [31]. LT for benign hepatic lesions has been
35
36 described in cases of adenoma and adenomatosis, focal nodular hyperplasia,
37
38 haemangioma and haemangiomatosis, lymphangiomatosis, mesenchymal hamartoma,
39
40 polycystic, Caroli's and hydatid diseases. Results in terms of 1- and 5-year survival are
41
42 similar to those obtained for other indications [32,33].
43
44
45
46
47
48
49
50
51

52
53 Regarding the final decision to proceed to LT, on the one hand, the risks associated
54
55 with transplant surgery and long term immunosuppression were deemed largely
56
57 "acceptable" for the patient in the lack of any other equally effective treatment. On the
58
59 other hand, the concern about a potential post-LT recurrence in case of discovery of
60
61
62
63
64
65

1
2
3
4 areas of BCC in the explanted liver was counterbalanced by the presence of pre-LT
5
6 arguments in favour of the benign nature of the lesion (i.e. presentation in a middle-
7
8 aged female with large and multiple formalin-fixed biopsy samples showing BCA with
9
10 typical “ovarian-like” stroma, and no area of intestinal metaplasia). Therefore, the risk of
11
12 recurrence of an hypothetical BCC after LT was considered “low” by the transplant
13
14 team, i.e. comparable with that of recurrence of hepatocellular carcinoma after LT
15
16 performed within Milan criteria [34]. Moreover, BCCs arising in association with a
17
18 mesenchymal stroma usually have a less severe clinical course [2] and there are
19
20 several reports of disease-free survival after complete resection [5,7,8,9].
21
22
23
24
25

26 This report highlights once more the paramount importance of mastering the whole
27
28 therapeutic armamentarium in liver surgery within the same institution. In fact, only in
29
30 that setting a correct balance between perioperative risks and expected treatment
31
32 outcomes can be made, and patients can be provided with the most appropriate
33
34 surgical treatment. In other words, for subjects who do not present contraindications to
35
36 LT, it is our conviction that today LT should be preferred to resectional surgery
37
38 whenever the latter implies high risks with very little chance of success.
39
40
41
42

43 In conclusion, the goal to be achieved when treating BCA remains complete excision. In
44
45 the reported case, LT for symptomatic centrohepatic BCA allowed the removal of the
46
47 tumor, relief of symptoms and 4-year disease-free survival. However, the benign nature
48
49 of the lesion and the on-going shortage of organ donors limits the use of LT to the very
50
51 selected cases of BCA not amenable to other forms of radical surgical therapy.
52
53
54
55
56

57 **ACKNOWLEDGMENTS**

58
59 The Authors are indebted to Ms Elizabeth Clarke for her kind assistance.
60
61
62
63
64
65

CONFLICT OF INTEREST DECLARATION

No potential conflict of interest relevant to this article was reported.

1
2
3
4
5
6
7
8
9
10
11
12
13
14
15
16
17
18
19
20
21
22
23
24
25
26
27
28
29
30
31
32
33
34
35
36
37
38
39
40
41
42
43
44
45
46
47
48
49
50
51
52
53
54
55
56
57
58
59
60
61
62
63
64
65

REFERENCES

1. Wheeler DA, Edmondson HA. Cystadenoma with mesenchymal stroma (CMS) in the liver and bile ducts. A clinicopathologic study of 17 cases, 4 with malignant change. *Cancer* 1985; 56: 1434-45
2. Devaney K, Goodman ZD, Ishak KG. Hepatobiliary cystadenoma and cystadenocarcinoma. A light microscopic and immunoistochemical study of 70 patients. *Am J Surg Pathol* 1994; 18: 1078-91
3. Ishak KG, Willis GW, Cummins SD, Bullock AA. Biliary cystadenoma and cystadenocarcinoma: report of 14 cases and review of the literature. *Cancer* 1977; 39: 322-38
4. Delis SG, Touloumis Z, Bakoyannis A, Tassopoulos N, Paraskeva K, Athanassiou K, et al. Intrahepatic biliary cystadenoma: a need for radical resection. *Eur J Gastroenterol Hepatol* 2008; 20: 10-4
5. Erdogan D, Busch ORC, Rauws EAJ, Van Delden OM, Gouma DJ, Van Gulik TM. Obstructive jaundice due to hepatobiliary cystadenoma or cystadenocarcinoma. *World J Gastroenterol* 2006; 12: 5735-8
6. Vogt DP, Henderson JM, Chmielewski E. Cystadenoma and cystadenocarcinoma of the liver: a single center experience. *J Am Coll Surg* 2005; 200: 727-33
7. Hai S, Hirohashi K, Uenishi T, Yamamoto T, Shuto T, Tanaka H, et al. Surgical management of cystic hepatic neoplasm. *J Gastroenterol* 2003; 38: 759-64
8. Oh TH, Kim MH, Lee SK, Seo DW, Lee SS, Kim EY, et al. Thirteen cases of intrahepatic biliary cystadenoma and cystadenocarcinoma: a single center experience. *Korean J Gastroenterol* 2006; 47: 379-88

- 1
2
3
4 9. Kim HG. Biliary cystic neoplasm: biliary cystadenoma and biliary
5
6
7
8
9
10
11
12
13
14
15
16
17
18
19
20
21
22
23
24
25
26
27
28
29
30
31
32
33
34
35
36
37
38
39
40
41
42
43
44
45
46
47
48
49
50
51
52
53
54
55
56
57
58
59
60
61
62
63
64
65
10. Thomas KT, Welch D, Trueblood A, Sulur P, Wise P, Gorden DL, et al. Effective
treatment of biliary cystadenoma. *Ann Surg* 2005; 241: 769-73
11. Henson SW Jr, Gray HK, Dockerty MB. Benign tumors of the liver. VI.
Multilocular cystadenomas. *Surg Gynecol Obstet* 1957; 104: 551-54
12. Goodman ZD, Terraciano LM. Tumours and tumour-like lesions of the liver. In:
Burt AD, Portmann BC, Ferrel LD, eds. "MacSween's Pathology of the Liver".
Philadelphia, PA. Churchill Livingstone, 2007: 789-90
13. Walt AJ. Cysts and benign tumors of the liver. *Surg Clin North Am* 1977; 57:
449-64
14. Regev A, Reddy KR, Berho M, Sleeman D, Levi JU, Livingstone AS, et al. Large
cystic lesions of the liver in adults: a 15-year experience in a tertiary center. *J*
Am Coll Surg 2001; 193: 36-45
15. Lewis WD, Jenkins RL, Rossi RL, Munson L, ReMine SG, Cady B, et al. Surgical
treatment of biliary cystadenoma. A report of 15 cases. *Arch Surg* 1988; 123:
563-8
16. Beuran M, Dan Venter M, Dumitru L. Large mucinous biliary cystadenoma with
"ovarian-like" stroma: a case report. *World J Gastroenterol* 2006; 12: 3779-81
17. Gonzalez M, Majno P, Terraz S, Morel P, Rubbia-Brandt L, Mentha G. Biliary
cystadenoma revealed by obstructive jaundice. *Dig Liver Dis* 2009; 41: e11-e13
18. Mortelé KJ, Ros PR. Cystic focal liver lesions in the adult: differential CT and MR
imaging features. *Radiographics* 2001; 21: 895-910

19. Palacios E, Shannon M, Solomon C, Guzman M. Biliary cystadenoma: ultrasound, CT, and MRI. *Gastrointest Radiol* 1990; 15: 313-6
20. Buetow PC, Buck JL, Pantongrag-Brown L, Ros PR, Devaney K, Goodman ZD, et al. Biliary cystadenoma and cystadenocarcinoma: clinical-imaging-pathologic correlation with emphasis on the importance of ovarian stroma. *Radiology* 1995; 196: 805-10
21. Thomas JA, Scriven MW, Puntis MC, Jasani B, Williams GT. Elevated serum CA 19-9 levels in hepatobiliary cystadenoma with mesenchymal stroma. Two case reports with immunohistochemical confirmation. *Cancer* 1992; 70: 1841-6
22. Lee JH, Chen DR, Pang SC, Lai YS. Mucinous biliary cystadenoma with mesenchymal stroma: expressions of CA 19-9 and carcinoembryonic antigen in serum and cystic fluid. *J Gastroenterol* 1996; 31: 732-6
23. Koffron A, Rao S, Ferrario M, Abecassis M. Intrahepatic biliary cystadenoma: role of cyst fluid analysis and surgical management in the laparoscopic era. *Surgery* 2004; 136: 926-36
24. Manouras A, Lagoudianakis E, Alevizos L, Markogiannakis H, Kafiri G, Bramis C, et al. Laparoscopic fenestration of multiple giant biliary mucinous cystadenoma of the liver. *World J Gastroenterol* 2008; 14: 4257-9
25. Hansman MF, Ryan JA Jr, Holmes JH 4th, Hogan S, Lee FT, Kramer D, et al. Management and long-term follow-up of hepatic cysts. *Am J Surg* 2001; 181: 404-10

26. Dokmak S, Paradis V, Vilgrain V, Sauvanet A, Farges O, Valla D, et al. A single-center surgical experience of 122 patients with single and multiple hepatocellular adenomas. *Gastroenterology* 2009; 137: 1698-705
27. Dagher I, Franco D. Lésions kystiques du foie et des voies biliaires (en dehors du kyste hydatique). Place de la chirurgie. *Gastroenterol Clin Biol* 2005; 29: 875-7
28. Limongelli P, Pai M, Damrah O, Laretta A, Atijosan O, Habib N, et al. Cystic tumors of the biliary tract: a complete excision is crucial. *Int Surg* 2009; 94: 136-40
29. Dixon E, Sutherland FR, Mitchell P, McKinnon G, Najak V. Cystadenomas of the liver: a spectrum of disease. *Can J Surg* 2001; 44: 371-6
30. Teoh AYB, Simon SM, Lee KF, Lai PBS. Biliary cystadenoma and other complicated cystic lesions of the liver: diagnostic and therapeutic challenges. *World J Surg* 2006; 30: 1560-6
31. Salizzoni M, Cerutti E, Romagnoli R, Lupo F, Franchello A, Zamboni F, et al. The first one thousand liver transplants in Turin: a single-center experience in Italy. *Transpl Int* 2005; 18: 1328-35
32. Tepetes K, Selby R, Webb M, Madariaga JR, Iwatsuki S, Starzl TE. Orthotopic liver transplantation for benign hepatic neoplasms. *Arch Surg* 1995; 130: 153-6
33. Moya Herráiz A, Torres-Quevedo R, Mir Pallardó J. Liver transplantation in patients with benign hepatic lesions. *Cir Esp* 2008; 84: 60-6

34. Mazzaferro V, Regalia E, Doci R, Andreola S, Pulvirenti A, Bozzetti, et al. Liver transplantation for the treatment of small hepatocellular carcinomas in patients with cirrhosis. N Engl J Med 1996; 334: 693-9

1
2
3
4
5
6
7
8
9
10
11
12
13
14
15
16
17
18
19
20
21
22
23
24
25
26
27
28
29
30
31
32
33
34
35
36
37
38
39
40
41
42
43
44
45
46
47
48
49
50
51
52
53
54
55
56
57
58
59
60
61
62
63
64
65

LEGENDS TO FIGURES

Figure 1. CT-scan pictures showing the mass effect exerted by the centrohepatic biliary cystadenoma. Note the dislocation of the left (A) and right (B) Glissonian pedicles and the close relationship with the hilar plate (B, C), determining diffuse biliary tree dilatation. Internal septations inside the cystic mass are visible (D).

Figure 2. A. Intraoperative cholangiography obtained by injection of contrast material through the cystic duct after cholecystectomy: external compression of the primary biliary bifurcation and of the intrahepatic bile ducts is patent (arrows).

B. Intraoperative cholangiography obtained by injection through the T-tube inserted into the injured right bile duct after drainage and decompression of the cyst: extravasation of the contrast medium into the residual cavity and irregular morphology of the intrahepatic biliary tree are apparent.

Figure 3. Photograph of the explanted liver showing a hepatic vein (thin arrow) and internal septations (thick arrow) arising on the floor of the cyst. A

dissection plane between the cystadenoma and the hepatic bilio-vascular structures does not appear identifiable (thick arrowhead).

Figure 4. Histological appearance of the lesion in the explant specimen (A, magnification 100 x; B, magnification 400 x). Note that a typical columnar epithelium, with several intracavitary papillary projections (arrows), is lying over a thick “ovarian-like” stroma rich in spindle cells (arrowhead).

Figure 1
[Click here to download high resolution image](#)

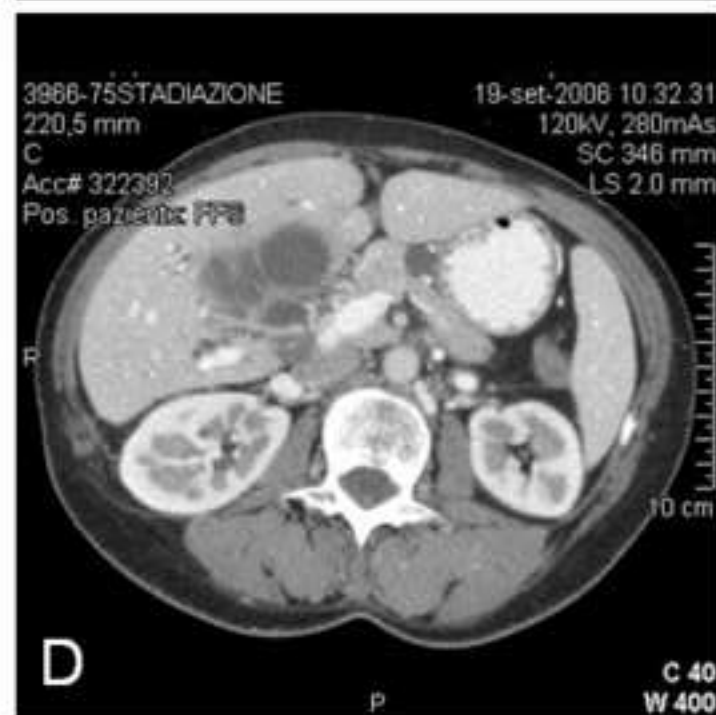
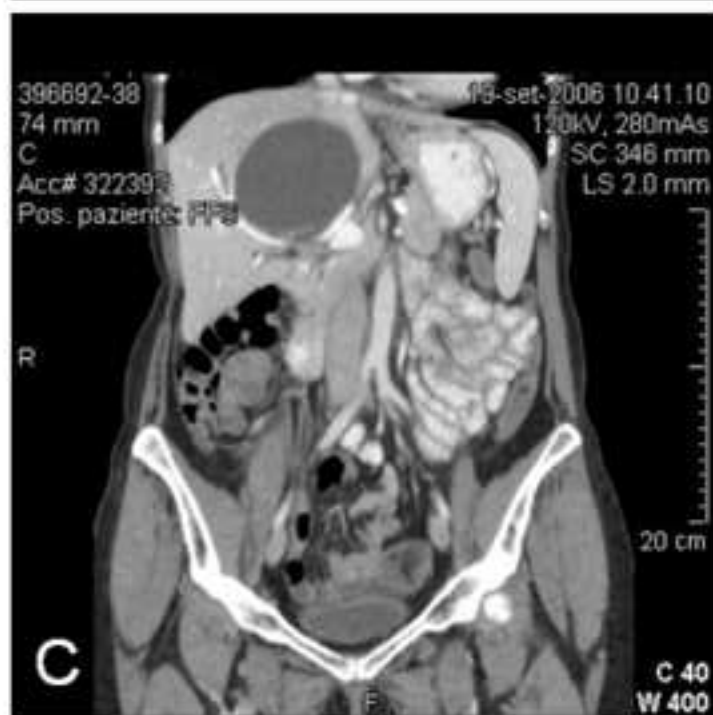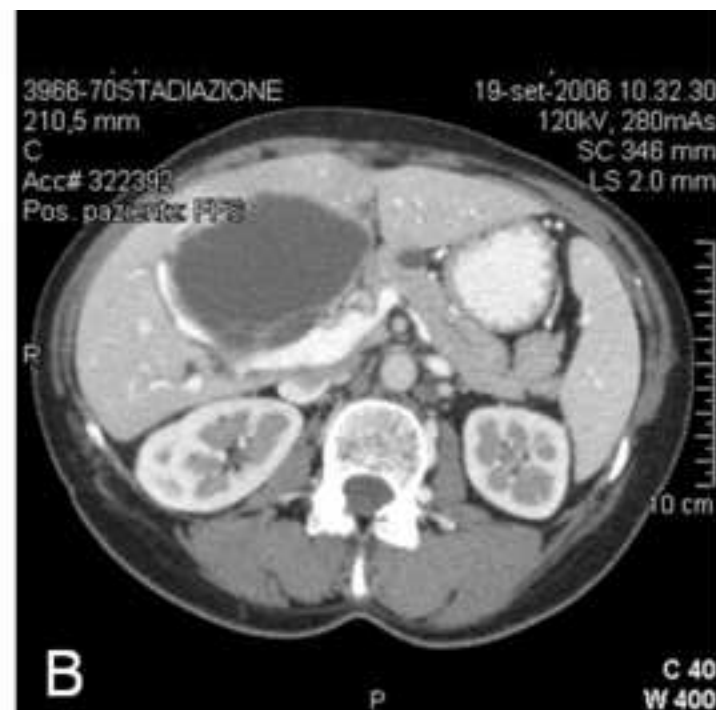
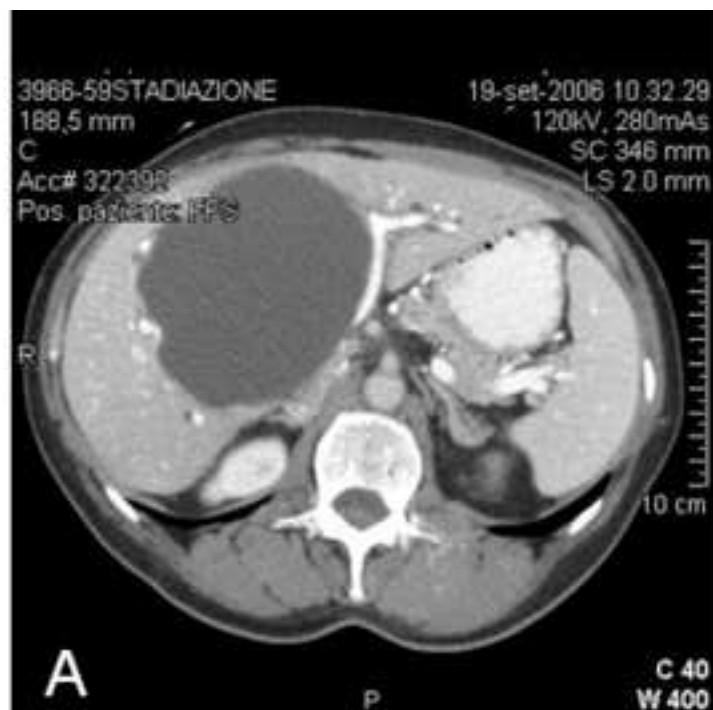


Figure 2
[Click here to download high resolution image](#)

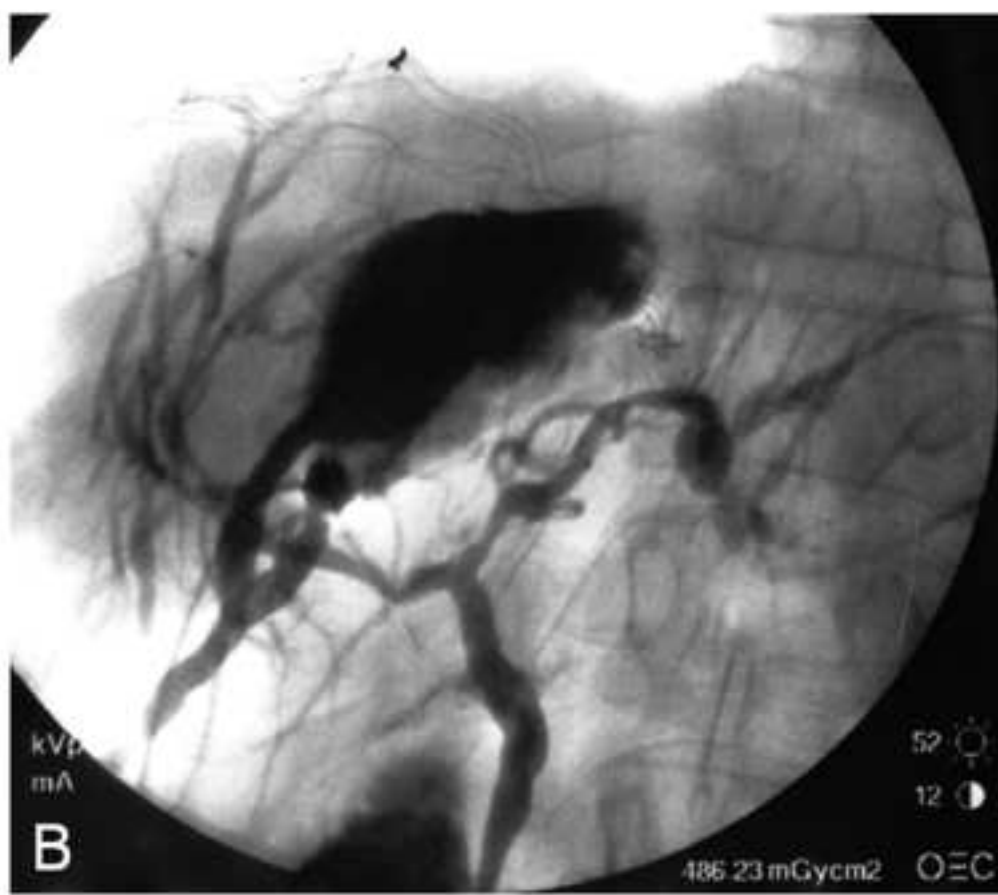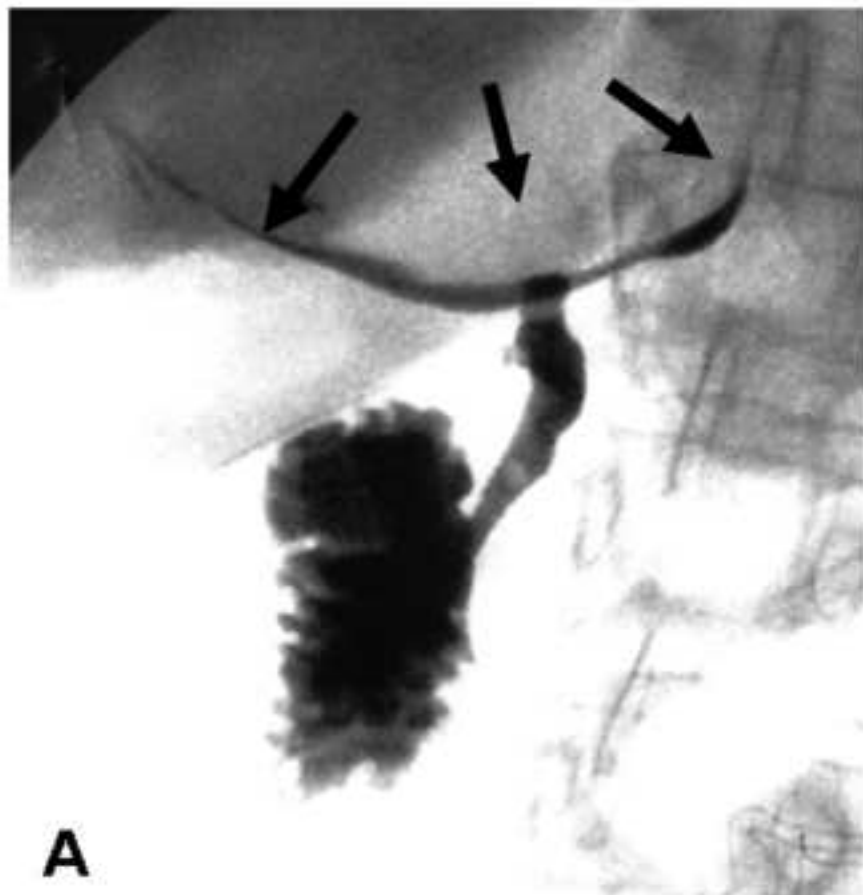


Figure 3
[Click here to download high resolution image](#)

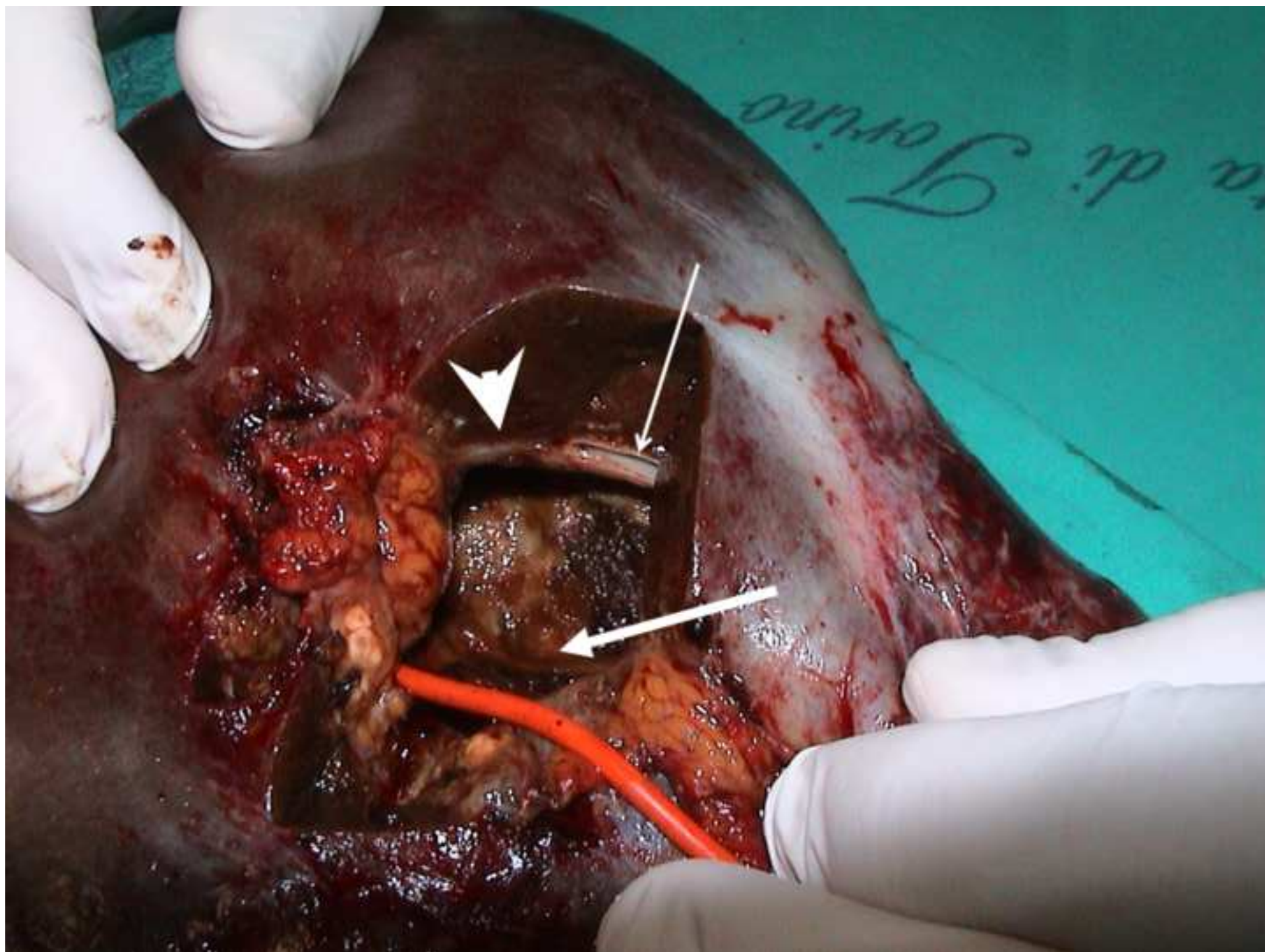


Figure 4
[Click here to download high resolution image](#)

