

RESEARCH

Open Access



Risky anatomical variations of sphenoid sinus and surrounding structures in endoscopic sinus surgery

Gian Luca Fadda^{1*} , Alessio Petrelli², Anastasia Urbanelli¹, Paolo Castelnuovo³, Maurizio Bignami⁴, Erika Crosetti¹, Giovanni Succo⁵ and Giovanni Cavallo¹

Abstract

Purpose: This study aimed to examine the relationship between the sphenoid sinus (SS) and surrounding vital structures such as the internal carotid artery (ICA) and optic nerve canal (ONC) as well as the types of attachment of the sphenoidal septa onto these structures.

Methods: In total, 230 computed tomography (CT) scans were reviewed to study the type of sphenoid sinus pneumatization (SSP), the protrusion and dehiscence of the ICA and ONC, the relationship between the sphenoidal septa and surrounding vital structures as well as pterygoid recess pneumatization (PRP).

Results: The most common SSP was sellar type (58.7%). The rates of protrusion and dehiscence of the ICA were 26.3 and 0.4%, and for the ONC, they were 13 and 1.5%, respectively. The ICA and ONC were most protruded and dehiscent in more extensive SSP. In 21.6% of patients, the intersphenoidal septa (IS) were attached to the wall of the ICA and in 8.6% they were attached to the wall of the ONC. The attachment of IS to the ICA correlated statistically significantly ($p < 0.0001$) with protrusion of the ICA. Accessory septa were detected in 30.4% of cases with various sites of attachment.

Conclusion: To reduce the risk of injury and complications during endoscopic sinus surgery (ESS), surgeons should consider using CT to identify possible bulging and dehiscence of the ICA/ONC and their relationship to the extent of SSP and also to establish the presence of deviation of the sphenoid septum, and the presence of accessory septa.

Keywords: Sphenoid sinus, Internal carotid artery, Optic nerve, Computed tomography, Sellar type, Endoscopic sinus surgery

Introduction

Understanding the anatomic variations of the sphenoid sinus (SS) using computed tomography (CT) of the paranasal sinuses and their relationship to adjacent neurovascular structures such as the internal carotid artery (ICA) and optic nerve (ONC) is essential to reduce the risk of

intraoperative complications during endoscopic sinus surgery (ESS) [1–4].

In the case of extensive sphenoid sinus pneumatization (SSP), these neurovascular structures may be dehiscent or protrude into the air cavities, sometimes without any bone separation. In these cases, they may be susceptible to iatrogenic damage with catastrophic consequences [5]. Moreover, intersphenoidal septa may have attachment points on the bone wall of the ICA and ONC; this represents an anatomical risk factor during ESS, especially in the case of severe fracturing [1, 6].

*Correspondence: dott.fadda@gmail.com

¹ Department of Otorhinolaryngology, University of Turin, San Luigi Gonzaga Hospital, Regione Gonzole 10, Orbassano, 10043 Turin, Italy
Full list of author information is available at the end of the article



An accidental fracture of the intersphenoidal septum that attaches itself on the bone wall of the ICA or ONC during endoscopic sinus surgery may result in an injury of these structures, causing severe intraoperative bleeding or blindness.

To the best of our knowledge, this is the first study to perform a multiparametric statistical correlation analyzing 230 computed tomography (CT) scans (460 sides) to investigate the relationship between different patterns of SSP and the surrounding neurovascular structures. Moreover, we evaluated the possible protrusion and dehiscence of these structures, their relationship to a deviated intersphenoidal septum (IS) and accessory septa (AS), and the identification of pterygoid recess pneumatization (PRP).

Verifying the anatomical characteristics of the SS is crucial to reduce the risk of involuntary injury involving these important structures that may occur during ESS.

Materials and methods

This retrospective study has been performed in accordance with the ethics standards laid down in the 1964 Declaration of Helsinki and informed written consent was obtained from all patients. It included 230 CT scans of paranasal sinuses (460 sides) collected between January 2019 and September 2021. Inclusion criteria were individuals older than 18 years of age with rhinosinusitis symptoms. Exclusion criteria were individuals with facial bone fractures, rhinosinusitis neoplasms or rhinosinusitis of the posterior paranasal sinus and massive polyposis.

Based on the CT images, the following variables were assessed: type of SSP, protrusion and dehiscence of the ICA and/or ONC, position and attachment of IS onto these structures, presence of AS and PRP (Fig. 1).

- SSP was evaluated as conchal, presellar, sellar and postsellar types based on the location of the posterior sinus wall with respect to the position of the sella turcica, on the sagittal plane [7]. In conchal-type SSP, pneumatization is absent as there is no association with the sella turcica. In presellar-type SSP, the sinus cavity remains anterior to a vertical line drawn through the tuberculum sellae. In sellar-type SSP, pneumatization extends beyond a vertical line drawn through the tuberculum sellae, whereas in postsellar SSP, pneumatization extends beyond the posterior wall of the sella.
- The ICA and ONC were classified according to their relationship with the sphenoid sinus wall on the coronal plane [8]:

- protrusion into the air space was defined when the overhang of the neurovascular structure was more than 50% of its circumference [1, 9]
- dehiscence was defined as the absence of a bony wall separating the ICA/ONC from the sphenoid sinus [10–12]
- IS was analyzed for every scan and classified into three subtypes, on the axial and coronal planes [8]:
 - on the midline; deviation to the right side; deviation to the left side
- Presence of AS, on the axial and coronal planes.
- The incidences of attachment of IS and AS onto the ICA and ONC, protruded and dehiscent, were evaluated individually.
- PRP was defined as a measurable indentation of the bone lateral to a line passing through the center of the vidian canal and the foramen rotundum, on the coronal plane [13].

Statistical analysis

The associations between variables of interest were evaluated using the Chi-squared test. If the expected frequencies were less than 5 for more than 25% of the cells in the contingency tables, Fisher's exact test was performed. The analyses were conducted using SAS System 9.4 (SAS Inc., Cary, NC, USA).

Results

In total, paranasal sinus CT scans from 230 adult patients (460 sides) were analyzed retrospectively. The group comprised 120 men (52.2%) and 110 women (47.8%) whose average age was 53.3 ± 17.1 years with a range of 18–89 years.

No statistically significant differences were identified when the CT scans were grouped according to sex of the patients or the distribution of SSP on the right and left sides.

Analysis of SSP identified a predominance of the sellar type (58.7%), followed by the presellar type (27.2%), conchal type (8.5%) and postsellar type (5.6%) (Table 1). The presence of postsellar pneumatization type on one side was statistically significantly associated with the simultaneous presence of the same pneumatization type on the contralateral side (38.5% for the presence on both sides vs 3.7% for the presence only on the left side; p value < 0.0001). Due to the breadth of postsellar sphenoid sinus, the preoperative understanding of this association may represent an advantage in the surgical approach to the pituitary gland.

The ICA was normal in 72.2% and protruded in 26.3% of cases. Isolated ICA dehiscence was detected in only

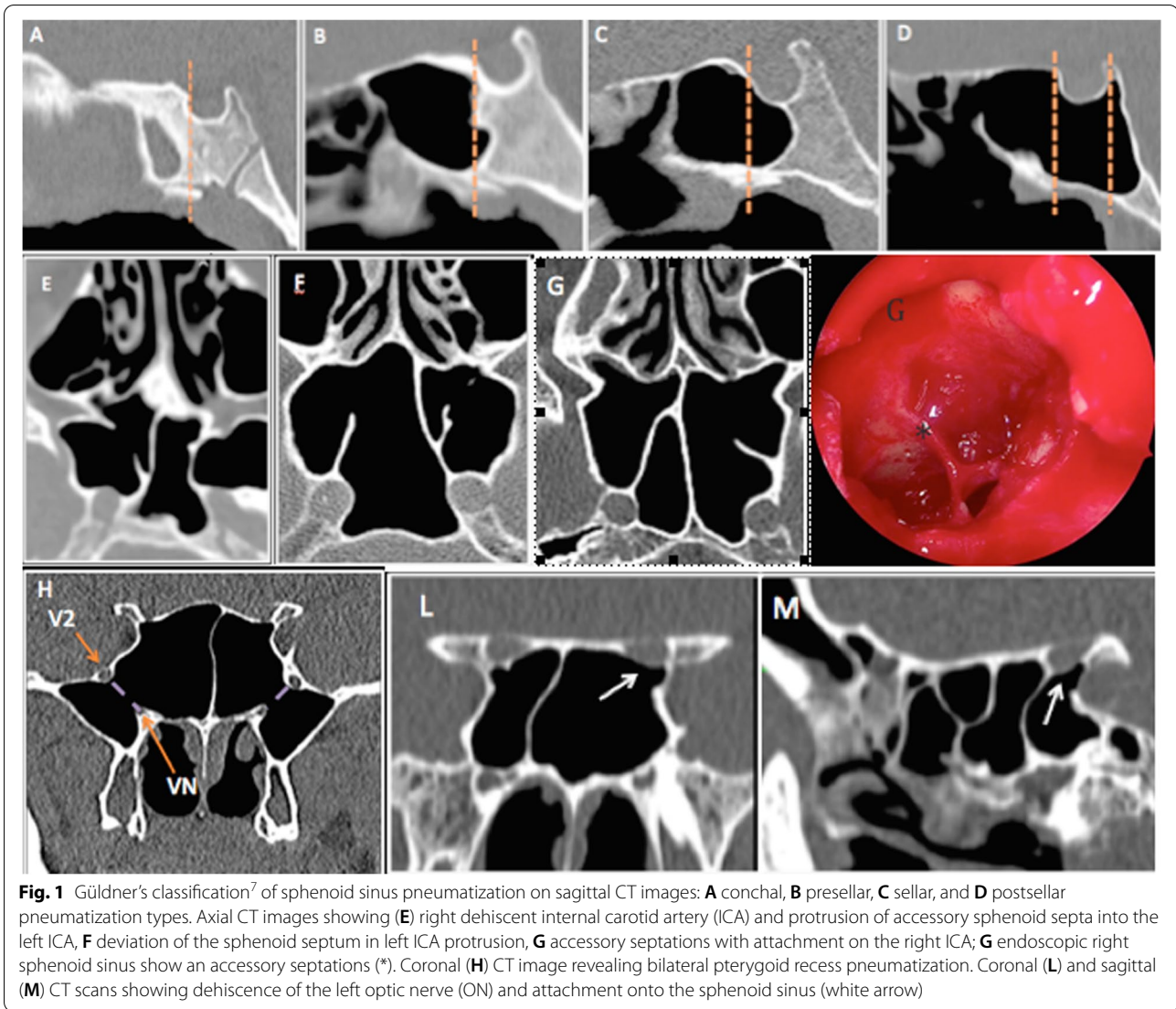


Fig. 1 Guldner's classification⁷ of sphenoid sinus pneumatization on sagittal CT images: **A** conchal, **B** presellar, **C** sellar, and **D** postsellar pneumatization types. Axial CT images showing (**E**) right dehiscent internal carotid artery (ICA) and protrusion of accessory sphenoid septa into the left ICA, **F** deviation of the sphenoid septum in left ICA protrusion, **G** accessory septations with attachment on the right ICA; **G** endoscopic right sphenoid sinus show an accessory septations (*). Coronal (**H**) CT image revealing bilateral pterygoid recess pneumatization. Coronal (**L**) and sagittal (**M**) CT scans showing dehiscence of the left optic nerve (ON) and attachment onto the sphenoid sinus (white arrow)

Table 1 Prevalence of sphenoid pneumatization patterns by classification system⁷

Sphenoid Pneumatization	Right, n 230 (%)			Left, n 230 (%)			TOTAL n 460 (%)	P-value*
	Men	Women	Total	Men	Women	Total		
Sellar	62 (48.8)	65 (51.2)	127 (55.2)	77 (53.8)	66 (46.2)	143 (62.2)	270 (58.7)	ns
Presellar	38 (55.1)	31 (44.9)	69 (30)	27 (48.2)	29 (51.8)	56 (24.3)	125 (27.2)	ns
Conchal	11 (52.4)	10 (47.6)	21 (9.1)	11 (61.1)	7 (38.9)	18 (7.8)	39 (8.5)	ns
Postsellar	9 (69.2)	4 (30.8)	13 (5.7)	5 (38.5)	8 (61.5)	13 (5.6)	26 (5.6)	< 0.0001

P-values are referred to the association between right and left side

two (0.4%) women and occurred on the left side. In five patients (1.1%), the ICA was dehiscent and protruded simultaneously. The ONC was normal in 83.5%, protruded in 13% and dehiscent in 1.5%. It was protruded in Onodi cells in 2% (Table 2). The presence of normal

or protruded ICA (84.4% for the presence on both sides vs 22.8% for the presence only on the left side; *p* value < 0.0001) on one side correlated statistically significantly with a matching presence on the contralateral side (*p* value < 0.0001). The same association was observed

Table 2 Prevalence of neurovascular bulging and dehiscence of surrounding structures

	Right n (%)			Left			Total (n = 460) n (%)	P-values*
	Men n (%)	Women n (%)	Total (n = 230) n (%)	Men n (%)	Women n (%)	Total (n = 230) n (%)		
ICA								
Normal	92 (53.2)	81 (46.8)	173 (75.2)	83 (52.2)	76 (47.8)	159 (69.1)	332 (72.2)	<0.0001
Protrusion	28 (51.8)	26 (48.2)	54 (23.5)	36 (53.7)	31 (46.3)	67 (29.1)	121 (26.3)	<0.0001
Dehiscence	–	–	–	–	2 (100.0)	2 (0.9)	2 (0.4)	<0.0001
P + D	–	3 (100.0)	3 (1.3)	1 (50.0)	1 (50.0)	2 (0.9)	5 (1.1)	<0.0001
ONC								
Normal	98 (50.8)	95 (49.2)	193 (83.9)	102 (53.4)	89 (46.6)	191 (83)	384 (83.5)	<0.0001
Protrusion	17 (60.7)	11 (39.3)	28 (12.2)	16 (50.0)	16 (50.0)	32 (13.9)	60 (13)	<0.0001
Dehiscence	2 (40.0)	3 (60.0)	5 (2.2)	–	2 (100)	2 (0.9)	7 (1.5)	<0.0001
P in Onodi	3 (75.0)	1 (25.0)	4 (1.7)	2 (40.0)	3 (60.0)	5 (2.2%)	9 (2)	<0.0001

ICA internal carotid artery, ONC optic nerve canal, P Protrusion, D Dehiscence

* P-values are referred to the association between right and left side

for ON (89.6% for the presence on both sides vs 48.6% for the presence only on the left side; *p* value <0.0001). These correlations could be useful for the surgeon in the approach to the contralateral site during endoscopic sinus surgery.

ICA and ONC were most frequently protruded in sellar and postsellar types on both sides and were dehiscent in the sellar type (Table 3). We found a statistically significant association between left-sided normal (*p* value <0.001) and protruded (*p* value <0.01) ICA with types

of SS pneumatization, whereas no statistically significant correlation was identified between the ONC and the different types of SS pneumatization. The preoperative knowledge of this correlation should alert the surgeon, since the more pneumatized the sphenoidal sinus, the greater the risk of injuring vital structures.

PRP of the SS was identified in 47 (20.4%) patients. It was seen most frequently in the sellar type (Table 3), although no statistically significant correlation was found.

Table 3 Prevalence of ICA/ONC protrusion and dehiscence and PRP by sphenoid pneumatization

Sphenoid pneumatization n (%)	Right ICA			Right ONC			Right PRP SS n (%) [§]
	Normal n (%) [§]	Protrusion n (%) [§]	Dehiscence n (%) [§]	Normal n (%) [§]	Protrusion n (%) [§]	Dehiscence n (%) [§]	
Sellar 127 (55.2)	90 (70.9)	34 (26.8)	–	101 (79.5)	21 (16.5)	3 (2.4)	13 (10.2)
Presellar 69 (30)	58 (84.1)	11 (15.9)	–	63 (91.3)	3 (4.3)	2 (2.9)	7 (10.1)
Conchal 21 (9.1)	17 (80.9)	4 (19.0)	–	19 (90.5)	2 (9.5)	–	–
Postsellar 13 (5.7)	8 (61.5)	5 (38.5)	–	10 (76.9)	2 (15.4)	–	–
Total 230 (100)	173 (75.2)	54 (23.5)	–	193 (83.9)	28 (12.2)	5 (2.2)	20 (8.7)
	Left ICA			Left ONC			Left PRP SS n (%) [§]
	Normal n (%) ^{§**}	Protrusion n (%) ^{§*}	Dehiscence n (%) [§]	Normal n (%) [§]	Protrusion n (%) [§]	Dehiscence n (%) [§]	
Sellar 143 (62.2)	94 (65.7)	49 (34.3)	2 (1.4)	115 (80.4)	22 (15.4)	2 (1.4)	18 (12.6)
Presellar 56 (24.3)	47 (83.9)	9 (16.1)	–	49 (87.5)	6 (10.7)	–	6 (10.7)
Conchal 18 (7.8)	16 (88.9)	2 (11.1)	–	17 (94.4)	1 (5.6)	–	1 (5.6)
Postsellar 13 (5.7)	6 (46.1)	7 (53.8)	–	10 (76.9)	3 (23.1)	–	2 (15.4)
Total 230 (100%)	159 (69.1)	67 (29.1)	2 (0.9)	191 (83.0)	32 (13.9)	2 (0.9)	27 (11.7)

ICA internal carotid artery, ONC optic nerve canal, PRP pterygoid recess pneumatization, SS Sphenoid Sinus

** *p*-value for the association between sphenoid pneumatization and left ICA normal <0.001

* *p*-value for the association between sphenoid pneumatization and left ICA protrusion <0.01

[§] % of the total sphenoid pneumatization type (sellar, presellar, conchal or postsellar)

A majority of patients (139/230; 60.4%), both men and women, had a single IS deviated to either the right or left side. Of these patients, a bony IS was attached to the wall of the ICA in 30/139 cases (21.6%) and to the wall of the ONC in 12/139 cases (8.6%). ICA protrusion was associated with right-sided IS in 16.9% and with left-sided IS in 13.2% of cases. Attachments of IS onto the ONC protrusion were noted in 14.3% on both sides and 2.8% on ONC dehiscence (Table 4). We found that attachment of the IS onto the ICA correlated statistically significantly (*p* value <0.0001) at a higher percentage when it was protruded, as opposed to normal, for both sides. This correlation should alert the surgeon about possible fracture of IS during ESS, resulting in injuries of vital structures like ICA with catastrophic consequences.

AS, in both men and in women, were detected in 70/230 patients (30.4%) with various sites of attachment. On the right side of the SS, the presence of AS was associated with ICA protrusion in 27.1% of individuals and in 15.7% with ONC protrusion. The same association occurred on the left side in 37.1% of individuals with ICA protrusion and in 14.3% with ONC protrusion. AS originating from ON dehiscence was detected in only one case (1.4%). In 10% of cases, the presence of ONC protrusion attaching to AS was bilateral (Table 4). No statistically significant correlation was found for AS.

Discussion

In advanced ESS, a clear surgical understanding of the anatomic variations in the sphenoid sinus and its pneumatization is helpful since they may place the patient at an increased risk of intraoperative complications with a mortality incidence of about 1% [14].

The Gldner classification defines four types of SSP.⁷ In line with other authors [15–19], the sellar type was

the predominant pattern (58.7%) in our study, followed by the presellar type (27.2%). In previous literature, the sellar type is reported in very high percentages ranging between 78.5 and 93% [16–19]. In our study, the conchal type was detected in 8.5% of cases, greater than reported in the literature (1–2%) [17–19]. No conchal type was detected by Wang et al. [20], Dal Secchi et al. [15], or Anusha et al. [21]. The conchal non-pneumatized sphenoid was always considered to be a contraindication for a transsphenoidal approach to the sella [22].

Preoperative CT scans can help to identify bone protrusion of the ICA and ONC into the SS and their dehiscence to help avoid possible injuries during surgery [20]. In our study, ICA protrusion into the SS occurred in 26.3% of cases, similar to Dal Secchi et al. (26%) [15] and Sirikci et al. (26.1%) [10]. Dehiscence of the ICA was identified in only 2 cases (0.4%). In the literature, ICA protrusion generally has a wide range, from 5.2 to 67.0% [9, 16], while its dehiscence ranges from 1.5–5% [1, 15, 16], to 1.5–30% [8, 9, 21].

The rate of ONC protrusion was 13%, in accordance with the literature (range 2.3–35.6%) [8, 9, 16, 21], while dehiscence was 1.5%, lower than the literature (range 0.7–30.6%) [1, 8, 9, 16, 21]. ONC injury by protrusion or dehiscence can occur as a major complication when the IS is attached to it and has to be removed. The risk of injury may lead to defects in the visual field, visual acuity or blindness [11]. The ONC is at greater risk of injury when Onodi cells are present [23]. We found that 2% of our patients presented with the ON protruding into Onodi cells.

Dehiscence and/or protrusion of neurovascular structures are closely associated in cases with high SSP. This should prompt the surgeon to endeavor to preserve them from accidental injury since the bony wall

Table 4 Prevalence of intersphenoid septum and accessory sphenoidal septa

Intersphenoid septae	Men n (%) ^a	Women n (%) ^a	Total (n = 230) n (%) ^b	Insertion on ICA n (%)		Insertion on ONC n (%)	
				Protusion	Normal	Protusion	Dehiscence
Midline	47 (51.7)	44 (48.3)	91 (39.6)	Protusion	Normal	Protusion	Dehiscence
Deviate R	35 (49.3)	36 (50.7)	71 (30.8)	12/71 (16.9)	5/71 (7.0)	6/71 (8.4)	2/71 (2.8)
Deviate L	38 (55.9)	30 (44.1)	68 (29.6)	9/68 (13.2)	4/68 (5.9)	4/68 (5.9)	–
Accessory septae	30 (13)	40 (17.4)	70 (30.4)	Insertion on ICA			
				R- Protusion 19/70 (27.1)	L- Protusion 26/70 (37.1)	B- Protusion 16/70 (22.8)	
				Insertion on ON			
				R- Protusion 11/70 (15.7)	L- Protusion 10/70 (14.3)	B- Protusion 7/70 (10)	R- Dehiscence 1/70 (1.4)

R right, L left, B bilateral, ONC optic nerve canal

^a row percentages

^b column percentages

over these structures may be very thin. We found frequent ICA and ONC protrusion in the sellar and post-sellar types of SP, similar to earlier studies [15, 24].

Variations in the SS include deviations of the IS and the presence of AS. These are often deviated and attached to the bony wall covering the ICA or ONC. During ESS, care must be taken not to fracture these septa as this may have catastrophic consequences such as uncontrollable bleeding, retrobulbar hematoma, proptosis and diplopia [1, 25]. It has been reported that only one in four IS are located in the midline [26]. In our study, IS was deviated in 60.4% of individuals: in 30.1%, it was attached onto the ICA protuberance and in 14.3% into the ONC protrusion. Poirier et al. [27] reported attachment of the IS onto the ICA in 3.4%, Batra et al. [28] in 37.5% and Dziejczak et al. [26] in 49% of cases. In our work, we identified that 30.4% presented AS similar to levels reported by Anusha et al. [16] Jaworek-Troc et al. [29] reported that AS were present in 78.0% of cases, similar to levels reported by Akgül et al. [17]. Aksoy et al. [25] reported that AS originated in the ICA protuberance in 47.7% of cases while they were associated with the ONC protuberance in 17.5%, comparable to our data. This indicates that deviated IS and AS cause an increased risk of ICA and/or ONC injury; therefore, their presence should be considered during ESS.

The present results and comparison with the relevant literature confirm that risky variants are more likely to occur in the presence of well pneumatized SS. For successful ESS, surgeons should have excellent knowledge of the anatomical relationships present in the sphenoid sinus, and detailed examination of the preoperative CT scans is very important to avoid an increased risk of intraoperative complications. For this purpose, we recommend the use of neuronavigation system in case of important and risky anatomical variations (widely enunciated in this work) of sphenoid sinus and not to use drill and surgical chisel to avoid injuries of vital structures, in particular when approaching IS attaching to protruded ICA or ONC.

Authors' contributions

Gian Luca Fadda: Substantial contributions to the work reported in this manuscript and surgeon. Final approval of the version to be published. Alessio Petrelli: Substantial contribution to the statistical analysis and interpretation of the data. Final approval of the version to be published. Paolo Castelnuovo, Eika Crosetti and Maurizio Bignami: Substantial contributions to the conception or design of the work, revising it critically for important intellectual content, and final approval of the version to be published. Anastasia Urbanelli, Giovanni Succo and Giovanni Cavallo: Substantial contributions to the preparation of patients undergoing surgery, final approval of the version to be published.

Funding

This research received no specific grant from any funding agency, commercial or not-for-profit sectors.

Availability of data and materials

The data used and analyzed during the current study are available from the corresponding author on reasonable request.

Declarations

Ethics approval and consent to participate

This retrospective study has been performed in accordance with the ethics standards laid down in the 1964 Declaration of Helsinki and informed written consent was obtained from all patients. Committee approval was taken from "San Luigi Gonzaga" University Hospital Ethics Committee (Date: 18.03.2022, Number: 4526).

Written informed consent was obtained from the patients for the publication of this manuscript and any accompanying images.

Consent for publication

Not applicable.

Competing interests

The authors declare that they have no conflict of interest.

Author details

¹Department of Otorhinolaryngology, University of Turin, San Luigi Gonzaga Hospital, Regione Gonzole 10, Orbassano, 10043 Turin, Italy. ²National Institute for Health, Migration and Poverty (INMP), Rome, Italy. ³Department of Otorhinolaryngology, University of Insubria, Varese, Italy. ⁴Department of Otorhinolaryngology, Head & Neck Surgery, University of Insubria, Como, Italy. ⁵Oncology Department, Head & Neck Surgery, University of Turin, Turin, Italy.

Received: 20 April 2022 Accepted: 23 August 2022

Published online: 03 September 2022

References

- Unal B, Bademci G, Bilgili YK, et al. Risky anatomic variations of sphenoid sinus for surgery. *Surg Radiol Anat.* 2006;28(2):195–201. <https://doi.org/10.1007/s00276-005-0073-9>.
- Hwang SH, Joo YH, Seo JH, et al. Analysis of sphenoid sinus in the operative plane of endoscopic transsphenoidal surgery using computed tomography. *Eur Arch Otorhinolaryngol.* 2014;271(8):2219–25. <https://doi.org/10.1007/s00405-013-2838-9>.
- Fadda GL, Petrelli A, Martino F, et al. Anatomic variations of ethmoid roof and risk of skull base injury in endoscopic sinus surgery: statistical correlations. *Am J Rhinol Allergy.* 2021;35(6):871–8. <https://doi.org/10.1177/19458924211020549>.
- Fadda GL, D'Eramo A, Grosso A, et al. Isolated sphenoid sinus inflammatory disease – a report of 14 cases. *Iran J Otorhinolaryngol.* 2020;32(109):101–7. <https://doi.org/10.22038/ijorl.2019.39416.2304>.
- Cho JH, Kim JK, Lee JG, et al. Sphenoid sinus pneumatization and its relation to bulging of surrounding neurovascular structures. *Ann Otol Rhinol Laryngol.* 2010;119(9):646–50. <https://doi.org/10.1177/000348941011900914>.
- Valentine R, Wormald PJ. Carotid artery injury after endonasal surgery. *Otolaryngol Clin N Am.* 2011;44:1059–79. <https://doi.org/10.1016/j.otc.2011.06.009>.
- Güldner C, Pistorius SM, Diogo I, et al. Analysis of pneumatization and neurovascular structures of the sphenoid sinus using cone-beam tomography (CBT). *Acta Radiol.* 2012;53(02):214–9. <https://doi.org/10.1258/ar.2011.110381>.
- Asal N, Muluk N, Inal M, et al. Carotid canal and optic canal at sphenoid sinus. *Neurosurg Rev.* 2019;42(2):519–29. <https://doi.org/10.1007/s10143-018-0995-4>.
- Hewaidi G, Omami G. Anatomic variation of sphenoid sinus and related structures in Libyan population: CT scan study. *Libyan J Med.* 2008;3(03):128–33. <https://doi.org/10.4176/080307>.
- Sirikci A, Bayazit YA, Bayram M, et al. Variations of sphenoid and related structures. *Eur Radiol.* 2000;10(5):844–8. <https://doi.org/10.1007/s003300051016>.

11. Sapci T, Derin E, Almac S, et al. The relationship between the sphenoid and the posterior ethmoid sinuses and the optic nerves in Turkish patients. *Rhinology*. 2004;42(1):30–4.
12. Davoodi M, Saki N, Saki G, et al. Anatomical variations of neurovascular structures adjacent sphenoid sinus by using CT scan. *Pak J Biol Sci*. 2009;15:522–5. <https://doi.org/10.3923/pjbs.2009.522.525>.
13. Alam-Eldeen MH, ElTaher MA, Fadle KN. CT evaluation of pterygoid process pneumatization and the anatomic variations of related neural structures. *Egypt J Radiol Nucl Med*. 2018;49(3):658–62.
14. Laws ER Jr. Vascular complications of transsphenoidal surgery. *Pituitary*. 1999;2:163–70. <https://doi.org/10.1023/a:1009951917649>.
15. Dal Secchi MM, Dolci RLL, Teixeira R, et al. An analysis of anatomic variations of the sphenoid sinus and its relationship to the internal carotid artery. *Int Arch Otorhinolaryngol*. 2018;22:161–6. <https://doi.org/10.1055/s-0037-1607336>.
16. Anusha B, Baharudin A, Philip R, et al. Anatomical variants of surgically important landmarks in the sphenoid sinus: a radiologic study in south-east Asian patients. *Surg Radiol Anat*. 2015;37(10):1183–90. <https://doi.org/10.1007/s00276-015-1494-8>.
17. Akgül MH, Muluk NB, Burulday V, et al. Is there a relationship between sphenoid sinus types, septation and symmetry, and septal deviation? *Eur Arch Otorhinolaryngol*. 2016;273:4321–8. <https://doi.org/10.1007/s00405-016-4138-7>.
18. Orhan I, Ormeci T, Nagihan B, et al. Morphometric analysis of sphenoid sinus in patients with nasal septum deviation. *J Craniofac Surg*. 2019;30(5):1605–8. <https://doi.org/10.1097/SCS.0000000000005443>.
19. El Kammash TH, Enaba MM, Awadall AM. Variability in sphenoid sinus pneumatization and its impact upon reduction of complications following sellar region surgeries. *Egypt J Radiol Nucl Med*. 2014;45:705–14.
20. Wang J, Bidari S, Inoue K, et al. Extensions of the sphenoid sinus: a new classification. *Neurosurgery*. 2010;66(04):797–816. <https://doi.org/10.1227/01.NEU.0000367619.24800.B1>.
21. Anusha B, Baharudin A, Philip R. Anatomical variations of the sphenoid sinus and its adjacent structures: a review of existing literature. *Surg Radiol Anat*. 2014;36(5):419–27. <https://doi.org/10.1007/s00276-013-1214-1>.
22. Fatemi N, Dusick JR, de Paiva Neto MA, et al. The endonasal microscopic approach for pituitary adenomas and other parasellar tumors: a 10-year-experience. *Neurosurgery*. 2008;63(4 Suppl 2):244–56. <https://doi.org/10.1227/01.NEU.0000327025.03975.BA>.
23. Driben JS, Bolger WE, Robles HA, et al. The reliability of computerized tomographic detection of the Onodi (sphenothmoid) cell. *Am J Rhinol*. 1998;12:105–11. <https://doi.org/10.2500/105065898781390325>.
24. Raseman J, Guryildirim M, Beer-Furlan A, et al. Preoperative computed tomography imaging of the sphenoid sinus: striving towards safe trans-sphenoidal surgery. *J Neurol Surg B*. 2020;81:251–62. <https://doi.org/10.1055/s-0039-1691831>.
25. Aksoy F, Yenigun A, Goktas SS, et al. Association of accessory sphenoid septa with variations in neighbouring structures. *J Laryngol Otol*. 2017;131(01):51–5. <https://doi.org/10.1017/S0022215116009622>.
26. Dziedzic T, Koczyk K, Gotlib T, et al. Sphenoid sinus septations and their interconnections with parasphenoidal internal carotid artery protuberance: radioanatomical study with literature review. *Minim Invasive Neurosurg*. 2020;15(1):227–33. <https://doi.org/10.5114/wiitm.2019.85837>.
27. Poirier J, Duggai N, Lee D, et al. Sphenoid sinus septations: unpredictable anatomic landmarks in endoscopic pituitary surgery. *J Otolaryngol Head Neck Surg*. 2011;40:489–92.
28. Batra PS, Citardi MJ, Gallivan RP, et al. Software-enabled computed tomography analysis of the carotid artery and sphenoid sinus pneumatization patterns. *Am J Rhinol*. 2004;18(4):203–8.
29. Jaworek-Troc J, Zarzacki M, Mroz I, et al. The total number of septa and antra in the sphenoid sinuses – evaluation before FESS. *Folia Med Cracov*. 2018;3:67–81. <https://doi.org/10.24425/fmc.2018.125073>.

Publisher's Note

Springer Nature remains neutral with regard to jurisdictional claims in published maps and institutional affiliations.

Ready to submit your research? Choose BMC and benefit from:

- fast, convenient online submission
- thorough peer review by experienced researchers in your field
- rapid publication on acceptance
- support for research data, including large and complex data types
- gold Open Access which fosters wider collaboration and increased citations
- maximum visibility for your research: over 100M website views per year

At BMC, research is always in progress.

Learn more biomedcentral.com/submissions

