





# Rechallenge and retreatment with topical imiquimod 5% in transplant recipients: A multicenter experience on actinic keratoses and basal cell carcinomas

Paolo Fava<sup>1</sup>  | Gabriele Rocuzzo<sup>1</sup> | Nicole Macagno<sup>1</sup>  |  
 Francesco Cavallo<sup>1</sup>  | Valentina Celoria<sup>1</sup> | Gianluca Avallone<sup>1</sup> |  
 Elisa Zavattaro<sup>2</sup> | Federica Veronese<sup>3</sup> | Luigi Biancone<sup>4</sup> | Paola Savoia<sup>2</sup> |  
 Pietro Quaglino<sup>1</sup> 

<sup>1</sup>Department of Medical Sciences, Dermatology Section, University of Turin, Turin, Italy

<sup>2</sup>Department of Health Science, University of Eastern Piedmont, Novara, Italy

<sup>3</sup>SCDU Dermatology, Maggiore della Carità Hospital, Novara, Italy

<sup>4</sup>Department of Medical Sciences, Nephrology, Dialysis and Renal Transplant Division, University of Turin, Turin, Italy

## Correspondence

Paolo Fava, Department of Medical Sciences, Dermatologic Clinic, University of Turin, Via Cherasco 23, 10126 Turin, Italy.  
 Email: [fava\\_paolo@yahoo.it](mailto:fava_paolo@yahoo.it)

## Funding information

None

## Abstract

**Background:** Solid organ transplant recipients (SOTRs) have an increased risk of developing non melanoma skin cancers (NMSCs). The use of Imiquimod, a toll-like-receptor agonist, is still debated in SOTRs.

**Objectives:** The aim of this study was to evaluate efficacy and safety of topical Imiquimod in two Dermatology Centres for skin cancers in SOTRs.

**Methods:** All SOTRs with age > 18 and a dermoscopic diagnosis of superficial basal cell carcinoma (BCC) and/or actinic keratose (AK), annually followed up between January 2022 and December 2022 were screened.

**Results:** 80 NMSCs (41 BCC and 39 AK) in 66 SOTRs were identified and treated.

57 (86.4%) were male. The mean age was 66.2 years (30–85). 60 patients (90.1%) had transplanted kidney, 1 (1.5%) lung, 3 (4.5%) liver, and 1 (1.5%) heart.

The average time since first transplant was 17 years (3–40 years). Tacrolimus, steroids, and mycophenolate mofetil were the most frequently used immunosuppressants (71%; 67.7%; 53.2% of cases, respectively).

Responses to the first course of treatment were CR in 64.3% of cases (53.6% in AK; 67.7% in BCC); PR in 28.6% of cases (42.9% in AK; 12.9% in BCC); NR in 12.5% of cases (3.6% in AK; 19.4% in BCC). Fourteen patients received a second course of imiquimod for a persistent lesion (1 AK, 4 BCC) or a new lesion (4 AK, 5 BCC).

Responses to the second course of treatment were observed in 4 (80%) and 7 (78%) cases in the persistent and new lesion, respectively ( $p = 0.34$ ).

Paolo Fava and Gabriele Rocuzzo contributed equally to the paper and share first authorship.

This is an open access article under the terms of the [Creative Commons Attribution-NonCommercial](https://creativecommons.org/licenses/by-nc/4.0/) License, which permits use, distribution and reproduction in any medium, provided the original work is properly cited and is not used for commercial purposes.

© 2024 The Authors. *JEADV Clinical Practice* published by John Wiley & Sons Ltd on behalf of European Academy of Dermatology and Venereology.

No systemic adverse events were noted. The main side effects were mild: erythema, scales, and crusts, itching, or pain.

**Conclusions:** Topical imiquimod represents a viable and safe option in this category of patients.

The response to imiquimod in subjects who have had more than one cycle is not related to the response to previous treatments but rather to the intrinsic characteristics of the lesion.

#### KEYWORDS

imiquimod, immunomodulation, nonmelanoma skin cancer, transplant recipients

## INTRODUCTION

In recent years, the life expectancy of solid organ transplant recipients (SOTRs) has significantly improved.<sup>1</sup> At the same time, this population remains at increased risk of developing different types of tumours, with a reported two to threefold overall risk of cancer-specific mortality compared with the general population.<sup>1,2</sup> Overall, skin cancers such as basal cell carcinoma (BCC) and squamous cell carcinoma represent the most common malignancy,<sup>1</sup> affecting over 50% of Caucasian SOTRs,<sup>3</sup> and being responsible for 5% of deaths in this population.<sup>4</sup>

Similarly, precancerous cutaneous disorders such as actinic keratoses (AKs) have been found to be significantly more frequent in SOTRs, compared with age-matched controls, implying impaired immune elimination of previously damaged keratinocytes.<sup>5</sup> Along with other risk factors, such as light skin, older age, and beta-human papillomavirus infection, the combination of immunosuppression and intense UV exposure plays a crucial role in SOTRs, making periodic dermatologic examinations essential to early diagnosis and cure of any developing skin cancer.<sup>6–8</sup> Remarkably, an early switch to mechanistic target of rapamycin inhibitors has shown to significantly reduce the risk of developing AKs and skin cancers, while azathioprine, ciclosporin and tacrolimus have been found to heighten this risk.<sup>9,10</sup>

As of today, several therapeutic options for BCC and AK have been extensively described, even if the majority of published studies were mainly focused on immunocompetent patients, and the proper management of these conditions in SOTRs has been less investigated.<sup>9</sup> According to the recently published guidelines, Imiquimod 5% cream represents the first choice for noninvasive treatment of most primary BCCs, having shown superiority to both methyl amino levulinate photodynamic therapy (PDT) and 5-fluorouracil cream in terms of efficacy.<sup>11</sup> A single trial underlined the effective role of PDT in achieving AK

clearance in SOTRs as well.<sup>12</sup> Thanks to its ability to activate Toll-like receptors 7 and 8 of mononuclear and dendritic cells, leading to interferon-alpha and NF-kappa B production, Imiquimod exerts its antineoplastic function stimulating apoptosis and inhibiting angiogenesis.<sup>9</sup> However, the potential risk of systemic immune reactions induced by the secretion of interferon alpha, possibly leading to the alteration of the function of the graft, or even its rejection, has limited its use in transplant recipients. Currently, the Food and Drug Administration (FDA) does not recommend the use of Imiquimod in SOTRs, whilst the European Medicines Agency (EMA) limits its use to a maximum area of 60 cm<sup>2</sup>.<sup>9</sup>

To fill the current lack of information, our study aims to retrospectively evaluate the efficacy and safety of Imiquimod 5% in a population of OTRs followed up in two University Hospital Dermatologic Units of Northwestern Italy.

## MATERIALS AND METHODS

This retrospective, observational, multicentric study was carried out at the Dermatology Clinics of the University of Turin and Hospital Maggiore della Carità of Novara, two Italian referral centres in the diagnosis and management of skin cancers in patients with SOTRs. The study was conducted in accordance with the declaration of Helsinki. Data from all SOTRs regularly followed up in the two dermatologic centres between January and December 2022 were collected. Inclusion criteria were age > 18, presence of complete medical records, recorded times of imiquimod treatments, and a well-defined dermoscopic diagnosis of superficial BCC up to a maximum diameter of 15 mm and or Olsen grade I/II AK, according to international criteria.<sup>13,14</sup> In detail, we identify as BCCs' dermoscopic defining features short-fine telangiectasias, multiple small erosions, leaf-like, spoke wheel and concentric structures.<sup>13</sup> AK's dermoscopic defining features were red pseudo-

network and red background, rosettes, white yellow scales and targetoid hair follicles,<sup>14</sup> rhomboidal appearance, inner grey halo, jelly sign and superficial pigmentation.<sup>15</sup>

Patients lacking clear-cut dermoscopic features of BCC and/or AK who required a biopsy before therapy prescription were ruled out from the study.

Topical Imiquimod 5% was administered according to the commonly used schedule, as indicated in EMA guidelines.<sup>16</sup> For superficial BCCs it was applied for 6 consecutive weeks, 5 days a week. For AKs it was applied for 4 weeks, 3 times a week. The healing of AK/BCC was evaluated after the next 4 weeks of withdrawal from treatment. Response to the first cycle of treatment was evaluated 12 weeks afterwards. Accordingly, best overall response was assessed in conformity with dermoscopic evaluation at the end of the prescribed cycle. Complete response (CR) was defined as 100% clearance of skin lesions, partial response (PR) as a dermoscopy-assessed reduction of the primary lesion without complete resolution, nonresponse (NR) as a dermoscopy-assessed persistence of the original lesion despite topical treatment.<sup>17</sup> If signs of non melanoma skin cancer (NMSC) persisted, the treatment was repeated for an additional cycle. Treatments for superficial BCC/AK received by the patients before the Imiquimod cycle in study were also recorded. Local and systemic side effects were assessed.<sup>5,18</sup>

## RESULTS

### Response rate

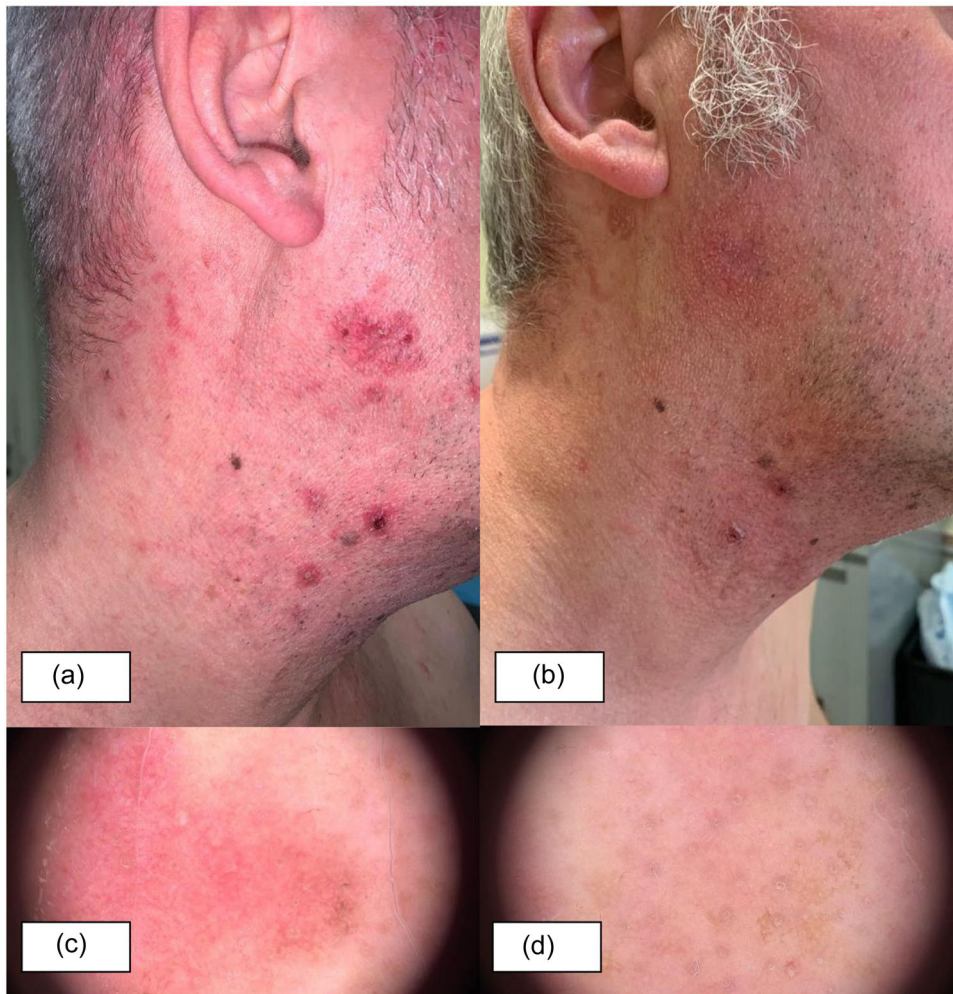A total of 65 patients were initially identified, three of whom lacked complete medical records and were therefore excluded from the evaluation. Overall, 62 patients met the inclusion criteria and were analysed. A male prevalence was recorded (53 men, 85.5% of the cohort) and the mean age was 66.5 years (median 68.5, range 30–77). As for the transplant type, 57 patients underwent kidney (91.9%), 3 liver (4.8%), 1 lung (1.6%), and 1 heart (1.6%) transplantation, while two patients received a combined transplant (one kidney and pancreas, one kidney and heart). The mean time from the transplant procedure was 17 years (range 3–40). Concerning systemic immunosuppressive treatments received by the patients, systemic steroids (66.1%) and tacrolimus (64.5%) accounted for the majority, followed by mycophenolate mofetil (48.4%), cyclosporine (24.2%), sirolimus (9.7%), everolimus (8.1%), and azathioprine (4.8%). Before the Imiquimod cycle in study, the following patients had received a treatment for other BCC/AK lesions: cryotherapy (13), PDT (12), surgery (41), 5-FU (11). Patient's characteristics are reported in Table 1.

**TABLE 1** Patient's characteristics.

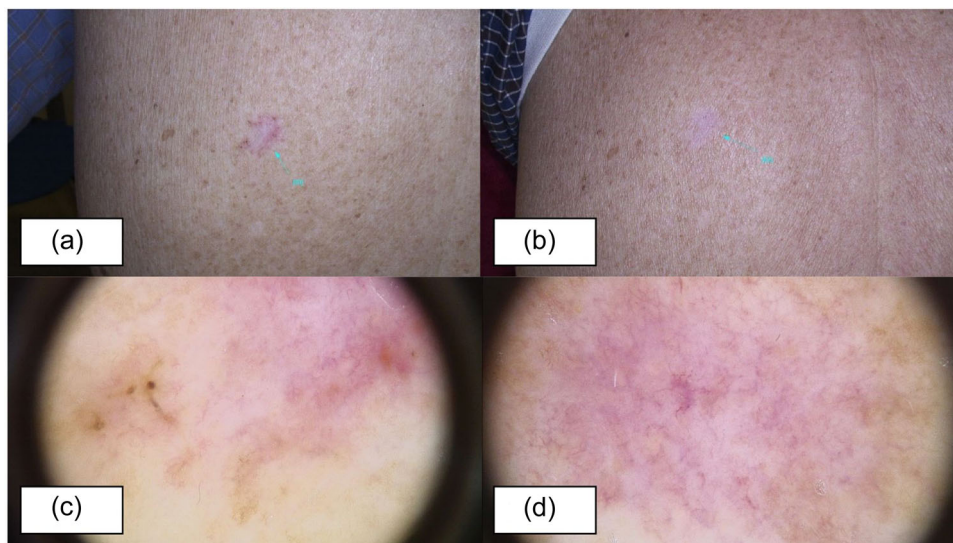
Patients' characteristics	n (%)
Total patients	65
Males	53 (81.5%)
Females	12 (18.5%)
Age (in years)	
Mean	66.5
Range	30–75
Type of transplant	
Kidney	57 (91.9%)
Liver	3 (5.8%)
Lung	1 (1.6%)
Heart	1 (1.6%)
Time from transplant	
Mean	17
Range	3–40
Immunosuppressor	
Steroids	43 (66.1%)
Tacrolimus	35 (64.5%)
Mofetil mycophenolate	31 (48.4%)
Cyclosporine	38 (58.2%)
Sirolimus	6 (9.7%)
Everolimus	5 (8.1%)
Azathioprine	3 (4.8%)

As for the clinical indications for the first Imiquimod cycle in study, 31 patients received it for AK and 31 for BCCs. These lesions were distributed on the trunk and lower limbs. Treatment efficacy was evaluated by analysing clinically and dermoscopically all superficial BCC/AK lesions following treatment. Overall response rates after the first cycle of Imiquimod 5% were CR 62.5%, PR 25%, and NR 12.5%. Regarding AK group, CR 57.7%, PR 38.5%, and NR 3.8% were recorded, whilst for the BCC group, CR 66.7%, PR 13.3%, and NR 20% (Figure 1 and 2). At the follow-up evaluation, a subset of patients ( $n_2 = 14$ ) received a second cycle with Imiquimod 5% for a persistent (i.e., AK  $n = 1$  and BCCs  $n = 4$ ) or a newly detected lesion (i.e., AK  $n = 4$  and BCCs  $n = 5$ ). Overall response rates after the second cycle were CR 40%, PR 40%, and 20% NR for persistent lesions, whilst CR 55.5%, PR 22.5%, and 22.5% NR for newly detected ones (Table 2).

At logistic regression analysis, CR achievement was not related to any of the analysed independent variables, such as duration and the number of lines of immunosuppressive



**FIGURE 1** (a) Clinical image of a superficial BCC on the mandibular right angle before treatment; (b) clinical outcome posttreatment with imiquimod 5% cream (c) pretreatment dermoscopic image of BCC (d) posttreatment dermoscopic image.



**FIGURE 2** (a) Clinical image of a superficial BCC on the back before treatment; (b) clinical outcome posttreatment with imiquimod 5% cream (c) pretreatment dermoscopic image of BCC (d) posttreatment dermoscopic image.

**TABLE 2** Clinical responses after therapy with topical imiquimod.

	OR 1st Cycle					OR 2nd Cycle			
	Patients (n)	CR (n, %)	PR (n, %)	NR (n, %)		Patients (n)	CR (n, %)	PR (n, %)	NR (n, %)
BCC	31	21 (66.7%)	4 (13.3%)	6 (20%)	PL	1 AK, 4 BCC	2 (40%)	2 (40%)	1 (20%)
AK	31	18 (57.7%)	12 (38.5%)	1 (3.8%)	NL	4 AK, 5 BCC	5 (55.5%)	2 (22.5%)	2 (22.5%)
TOT	62	39 (62.5%)	16 (25%)	7 (12.5%)	TOT	14	7 (50%)	4 (29%)	3 (21%)

Abbreviations: AK, actinic keratosis; BCC, basal cell carcinoma; CR, complete response; NL, new lesion; NR, no response; OR, overall response; PL, persistent lesion; PR, partial response.

treatment, patients' demographic characteristics, nor type of transplanted organ ( $p = 0.3294$ ).

## Safety

As for complications related to the topical therapy, no systemic side effects were recorded, and no therapy discontinuation due to toxicity was documented. Local side effects defined as a burning feeling, itching and/or increased redness were reported in 41% of patients. Among them, four patients suspended the treatment for an average of 10 days (range 7–22), after which therapy was resumed and the prescribed cycle completed according to schedule. Scheduled transplant-related follow-up visits were carried out according to clinical practice, with no documented alterations in renal nor hepatic function tests secondary to Imiquimod 5% treatment. During the 1 year of follow-up, no signs of cytokine imbalance requiring further investigations were noticed.

## DISCUSSION

Treatment of AK and NMSC represent a daily clinical challenge in SOTR, due to the frequency and recurrence of these pathological conditions. Whilst several therapy options, both surgical and medical, have been extensively investigated in the general population, data on SOTRs are still lacking. However, this high-risk population carries a 250 increased relative risk of developing skin cancer, with a cumulative incidence of around 35–40% at 5 years.<sup>19–21</sup> Moreover, cutaneous cancers are more likely to be multiple and display an aggressive course, with reported progression rates to invasive forms of 20–30% in 5–10 years,<sup>19–21</sup> making mandatory the prompt treatment of precancerous conditions and early-stage lesions.

The data obtained from the multicenter analysis of this study can provide some elucidation about the role of Imiquimod treatment in SOTR patients. Our data show that Imiquimod 5% cream is a viable option for the

treatment of BCC and AK in this category of patients, showing a high success rate. Overall response rates after the first cycle of Imiquimod 5% were CR 62.5%, specifically a CR of 57.5% in the AK group and a CR of 66.7% in the BCC group.

The open-label study by Vidal et al. had previously proven the efficacy of Imiquimod cream in renal or cardiac transplant patients on 10 nodular or superficial BCCs with a CR in 7 out of 10 cases (70%).<sup>22</sup>

Similarly, recent data from the systematic review by Heppt et al. show a CR rate in the treatment of AK in transplanted patients ranging from 27.5% to 62.1%. This finding is comparable to that obtained in our patient cohort.<sup>23</sup>

Hong-Xia Jia et al. in the review published in 2019 regarding the therapeutic efficacy of Imiquimod on BCC in immunocompetent patients reported a composite clearance rate of 75.2% and a CR rate of 77.8%.<sup>24</sup> Regarding the efficacy of Imiquimod in the treatment of AK in the general population, the systematic review by Hadley et al. reported data from five randomised double-blind trials demonstrating a CR rate of 50%. These data demonstrate that the efficacy of topical Imiquimod used in transplant patients is overlapping with therapeutical results obtained in the general immunocompetent population.<sup>25</sup>

Despite the limitations related to the sample diversity and size, we observed an excellent CR rate in SOTRs treated with Imiquimod, as well as reported in the general population, which allow us to state that immunodepression does not affect the response; moreover, we observed no differences in response in patients with different immunosuppression regimens both in case of kidney, liver, or heart transplantation and therefore in case of treatment with different drugs such as systemic steroids, tacrolimus, mycophenolate mofetil and others.

The present study also analysed the response to a second cycle of Imiquimod on lesions (both AK and BCC) that did not respond to the first cycle of treatment. The second cycle of Imiquimod has also shown to maintain a high safety profile with optimum efficacy in immunocompromised patients; therefore, it could be suggested that some patients may require a longer treatment duration,

which has also been demonstrated to be safe in this category of patients. An overall response rates after the second cycle of CR 40% was reported. These data regarding the second cycle of treatment with Imiquimod for persistent lesions (80%) or new diagnosed lesions (78%) in the same patient are also encouraging. This may have a double implication: first, it authorises the use of Imiquimod on new lesions also in nonresponder patients to a previous Imiquimod treatment. Infact a NR to treatment of one lesion does not necessarily imply another NR in another lesion. Second, it allows a possible therapeutic rechallenge on a lesion that did not completely respond to the first course of treatment as a viable therapeutic strategy.

These findings suggest that the therapeutic success of topical Imiquimod could be more dependent on the intrinsic characteristics of the lesion than on the immune system activation of the patient. This remark can indirectly confirm the observation by Dummer e coll. that T-cell activation seems to be a late step during Imiquimod treatment and probably not the leading factor of the tumour cell elimination.<sup>26</sup>

Regarding the safety profile of topical Imiquimod in SOTRs patients, no severe or systemic side effects resulted from our data. In the literature, a unique case of acute tubular necrosis following Imiquimod for the treatment of diffuse viral warts in a kidney transplant patient is currently reported, despite the cream was applied for more than 40 consecutive days. Moreover, the size of the treated area was not reported.<sup>27</sup>

Accordingly, the real origin of the renal failure remains to be clearly elucidated. Local side effects defined as a burning feeling, itching, and/or increased redness, scaling, and crusting were reported in 41% of our patients. All the side effects that did occur were mild and transient in duration, demonstrating that topical Imiquimod can be considered also in SOTRs a treatment with comparable safety to that in the general population.<sup>28</sup>

## CONCLUSION

SOTRs represent a population at high risk of cancer, particularly NMSC. Even if several therapeutic options are available in the treatment of AK and BCC in immunocompetent patients, less data are available about the clinical management of NMSC in immunocompromised patients, especially regarding the safety in this special population.

Based on the current study, topical Imiquimod can be considered a valid therapeutic option in the management of NMSC in SOTRs with a safety and efficacy profile comparable to that observed in the general population.

Despite the retrospective nature of the study, no safety issues regarding the graft function emerged in our single-centre experience.

Interestingly, in patients with multiple lesions, Imiquimod responses can be achieved in each treated lesion independently.

## AUTHOR CONTRIBUTIONS

The authors confirm contribution to the paper as follows: *Study conception and design*: Paolo Fava. *Data collection*: Paolo Fava, Gianluca Avallone, Nicole Macagno, Francesco Cavallo, Valentina Celoria, Gianluca Avallone, Elisa Zavattaro, Federica Veronese. *Analysis and interpretation of results*: Paolo Fava, Gabriele Rocuzzo, Nicole Macagno, Francesco Cavallo. *Draft manuscript preparation*: Paolo Fava, Gabriele Rocuzzo, Nicole Macagno, Francesco Cavallo. *Final supervision*: Pietro Quaglino, Paola Savoia, Luigi Biancone. All authors reviewed the results and approved the final version of the manuscript.

## CONFLICT OF INTEREST STATEMENT

The authors declare no conflict of interest.

## DATA AVAILABILITY STATEMENT

The data that support the findings of this study are available from the corresponding author upon reasonable request.

## ETHICS STATEMENT

All patients in this manuscript have given written informed consent for participation in the study and the use of their deidentified, anonymized, aggregated data and their case details (including photographs) for publication.

## ORCID

Paolo Fava  <http://orcid.org/0000-0002-8443-7458>

Nicole Macagno  <http://orcid.org/0000-0002-0097-2139>

Francesco Cavallo  <http://orcid.org/0000-0001-9296-826X>

Pietro Quaglino  <http://orcid.org/0000-0003-4185-9586>

## REFERENCES

1. Dharia A, Boulet J, Sridhar VS, Kitchlu A. Cancer screening in solid organ transplant recipients: a focus on screening liver, lung, and kidney recipients for cancers related to the transplanted organ. *Transplantation*. 2022;106(1):e64–5. <https://doi.org/10.1097/TP.0000000000003773>
2. Acuna SA, Fernandes KA, Daly C, Hicks LK, Sutradhar R, Kim SJ, et al. Cancer mortality among recipients of Solid-Organ transplantation in ontario, Canada. *JAMA Oncology*. 2016;2(4):463–9. <https://doi.org/10.1001/jamaoncol.2015.5137>
3. Collins L, Quinn A, Stasko T. Skin cancer and immunosuppression. *Dermatol Clin*. 2019;37:83–94.

4. Jensen A, Sværke C, Farkas D, Pedersen L, Kragballe K, Sørensen H. Skin cancer risk among solid organ recipients: a nationwide cohort study in Denmark. *Acta Dermato Venereologica*. 2010;90:474–9.
5. Ulrich C, Bichel J, Euvrard S, Guidi B, Proby CM, Van De Kerkhof PCM, et al. Topical immunomodulation under systemic immunosuppression: results of a multicentre, randomized, placebo-controlled safety and efficacy study of imiquimod 5% cream for the treatment of actinic keratoses in kidney, heart, and liver transplant patients. *Br J Dermatol*. 2007;157(Suppl 2): 25–31. <https://doi.org/10.1111/j.1365-2133.2007.08269.x>
6. Zavattaro E, Fava P, Veronese F, Cavaliere G, Ferrante D, Cantaluppi V, et al. Identification of risk factors for multiple non-melanoma skin cancers in Italian kidney transplant recipients. *Medicina*. 2019;55(6):279. <https://doi.org/10.3390/medicina55060279>
7. Taniguchi N, Takahara T, Ito T, Yamamoto Y, Satou A, Ohashi A, et al. Clinicopathologic analysis of malignant or premalignant cutaneous neoplasms in Japanese kidney transplant recipients. *Int J Clin Exp Pathol*. 2021;14(12):1138–47.
8. Urso B, Kelsey A, Bordelon J, Sheiner P, Finch J, Cohen JL. Risk factors and prevention strategies for cutaneous squamous cell carcinoma in transplant recipients. *Int J Dermatol*. 2022;61:1218–24. <https://doi.org/10.1111/ijd.16070>
9. Paugam C, Dréno B. Actualités sur la prise en charge des kératoses actiniques chez les patients transplantés d'organes. *Ann Dermatol Venereol*. 2019;146(Suppl 2):IIS31–5. [https://doi.org/10.1016/S0151-9638\(19\)30203-0](https://doi.org/10.1016/S0151-9638(19)30203-0)
10. Campistol JM. Minimizing the risk of posttransplant malignancy. *Transplant Proc*. 2008;40(Suppl 10):S40–3. <https://doi.org/10.1016/j.transproceed.2008.10.015>
11. Jansen MHE, Mosterd K, Arits AHMM, Roozeboom MH, Sommer A, Essers BAB, et al. Five-Year results of a randomized controlled trial comparing effectiveness of photodynamic therapy, topical imiquimod, and topical 5-Fluorouracil in patients with superficial basal cell carcinoma. *J Invest Dermatol*. 2018;138(3):527–33. <https://doi.org/10.1016/j.jid.2017.09.033>
12. Togsverd-Bo K, Halldin C, Sandberg C, Gonzalez H, Wennberg AM, Sørensen SS, et al. Photodynamic therapy is more effective than imiquimod for actinic keratosis in organ transplant recipients: a randomized intraindividual controlled trial. *Br J Dermatol*. 2018;178:903–9.
13. Reiter O, Mimouni L, Dusza S, Halpern AC, Leshem YA, Marghoob AA. Dermoscopic features of basal cell carcinoma and its subtypes: a systematic review. *J Am Acad Dermatol*. 85(Issue 3):653–64.
14. Valdés-Morales KL, Peralta-Pedrero ML, Jurado-Santa Cruz F, Morales-Sanchez MA. Diagnostic accuracy of dermoscopy of actinic keratosis: a systematic review. *Dermatol Pract Concept*. 2020;10(4):e20200121. <https://doi.org/10.5826/dpc.1004a121>
15. Kelati A, Baybay H, Moscarella E, Argenziano G, Gallouj S, Mernissi FZ. Dermoscopy of pigmented actinic keratosis of the face: a study of 232 cases. *Actas Dermosifiliogr*. 2017;108(9): 844–51. <https://doi.org/10.1016/j.ad.2017.05.002>
16. Scientific guidelines. European Medicine Agency. 2023. Aldara-INN Imiquimod
17. Hadley G, Derry S, Moore RA. Imiquimod for actinic keratosis: systematic review and Meta-Analysis. Original Article. 2006;126(6):P1251–5.
18. Avallone G, Merli M, Dell'Aquila C, Quaglino P, Ribero S, Zalaudek I, et al. Imiquimod-side effects in the treatment of periocular skin cancers: a review of the literature. *Dermatol Ther*. 2022;35(4):e15326. <https://doi.org/10.1111/dth.15326>
19. Johnson TM, Rowe DE, Nelson BR, Swanson NA. Squamous cell carcinoma of the skin (excluding lip and oral mucosa). *J Am Acad Dermatol*. 1992;26(3 Pt 2):467–84. [https://doi.org/10.1016/0190-9622\(92\)70074-p](https://doi.org/10.1016/0190-9622(92)70074-p)
20. Ferrándiz C, Fuente MJ, Ribera M, Bielsa I, Fernández MT, Lauzurica R, et al. Epidermal dysplasia and neoplasia in kidney transplant recipients. *J Am Acad Dermatol*. 1995;33(4): 590–6. [https://doi.org/10.1016/0190-9622\(95\)91276-2](https://doi.org/10.1016/0190-9622(95)91276-2)
21. Fuente MJ, Sabat M, Roca J, Lauzurica R, Fernandez-Figueras MT, Ferrandiz C. A prospective study of the incidence of skin cancer and its risk factors in a Spanish Mediterranean population of kidney transplant recipients. *Br J Dermatol*. 2003;149(6):1221–6. <https://doi.org/10.1111/j.1365-2133.2003.05740.x>
22. Vidal D, Alomar A. Efficacy of imiquimod 5% cream for basal cell carcinoma in transplant patients. *Clin Exp Dermatol*. 2004;29(3): 237–9. <https://doi.org/10.1111/j.1365-2230.2004.01456.x>
23. Heppt MV, Steeb T, Niesert AC, Zacher M, Leiter U, Garbe C, et al. Local interventions for actinic keratosis in organ transplant recipients: a systematic review. *Br J Dermatol*. 2019;180(1):43–50. <https://doi.org/10.1111/bjd.17148>
24. Jia HX, He YL. Efficacy and safety of imiquimod 5% cream for basal cell carcinoma: a meta-analysis of randomized controlled trial. *J Dermatol Treat*. 2020;31(8):831–8. <https://doi.org/10.1080/09546634.2019.1638883>
25. Hadley G, Derry S, Moore RA. Imiquimod for actinic keratosis: systematic review and meta-analysis. *J Invest Dermatol*. 2006;126(6):1251–5. <https://doi.org/10.1038/sj.jid.5700264>
26. Dummer R, Urosevic M, Kempf W, Hoek K, Hafner J, Burg G. Imiquimod in basal cell carcinoma: how does it work. *Br J Dermatol*. 2003;149(Suppl 66):57–8. <https://doi.org/10.1046/j.0366-077x.2003.05630.x>
27. Santos-Juanes J, Esteve A, Mas-Vidal A, Coto-Segura P, Salgueiro E, Gómez E, et al. Acute renal failure caused by imiquimod 5% cream in a renal transplant patient: review of the literature on side effects of imiquimod. *Dermatology*. 2011;222:109–12.
28. Olabi B, Tasker F, Williams HC. Efficacy and safety of imiquimod 5% cream for basal cell carcinoma: a meta-analysis of randomized controlled trial: a critical appraisal. *Br J Dermatol*. 2020;183(4):650–4. <https://doi.org/10.1111/bjd.18891>

**How to cite this article:** Fava P, Rocuzzo G, Macagno N, Cavallo F, Celoria V, Avallone G, et al. Rechallenge and retreatment with topical imiquimod 5% in transplant recipients: a multicenter experience on actinic keratoses and basal cell carcinomas. *JEADV Clin Pract*. 2024;1–7. <https://doi.org/10.1002/jvc2.376>