

# Myomucosal island flap in the reconstruction of oral cavity defects: Description of the surgical technique

Chiara Copelli MD<sup>1</sup>  | Alfonso Manfuso MD<sup>2</sup>  | Pasquale Di Maio MD<sup>3</sup>  |  
Paolo Garzino-Demo MD, DDS<sup>4</sup>  | Oreste Iocca MD, DDS<sup>4</sup> 

<sup>1</sup>Division of Maxillofacial Surgery, Department of Interdisciplinary Medicine, University of Bari, Bari, Italy

<sup>2</sup>Operative Unit of Maxillofacial Surgery, Otolaryngology and Dentistry, Fondazione IRCCS Casa Sollievo della Sofferenza, San Giovanni Rotondo (Fg), Italy

<sup>3</sup>Department of Otolaryngology – Head Neck Surgery, Hospital of Magenta, Milano, Italy

<sup>4</sup>Division of Maxillofacial Surgery, Città Della Salute e Della Scienza Hospital, University of Torino, Torino, Italy

## Correspondence

Alfonso Manfuso, Operative Unit of Maxillofacial Surgery, Otolaryngology and Dentistry, Fondazione IRCCS Casa Sollievo della Sofferenza, San Giovanni Rotondo (Fg), Italy.

Email: [a.manfuso@operapadrepio.it](mailto:a.manfuso@operapadrepio.it)

Oreste Iocca, Division of Maxillofacial Surgery, Città Della Salute e Della Scienza Hospital, University of Torino, Torino, Italy.

Email: [oreste.iocca@unito.it](mailto:oreste.iocca@unito.it)

## Abstract

Multiple options are available for the reconstruction of the defects of the oral cavity. Among these, the facial artery myomucosal island flap (FAMMIF) is a pedicled flap composed by cheek mucosa, submucosa, and part of the buccinator muscle. The FAMMIF is ideal for the reconstruction of small-to-moderate defects of the oral cavity and the oropharynx. This is due to low operating time, low morbidity, and good functional and aesthetic results. A step-by-step description of the flap harvesting is presented, with particular attention to flap design, identification of the vessels, harvesting of the myomucosal island, tunnel preparation for its passage in the neck and back to the oral cavity, and closure of the cheek donor site with the buccal fat pad.

## KEYWORDS

head and neck cancer, head and neck reconstruction, local flap, myomucosal island flap, oral cancer, oropharynx cancer, Zhao flap

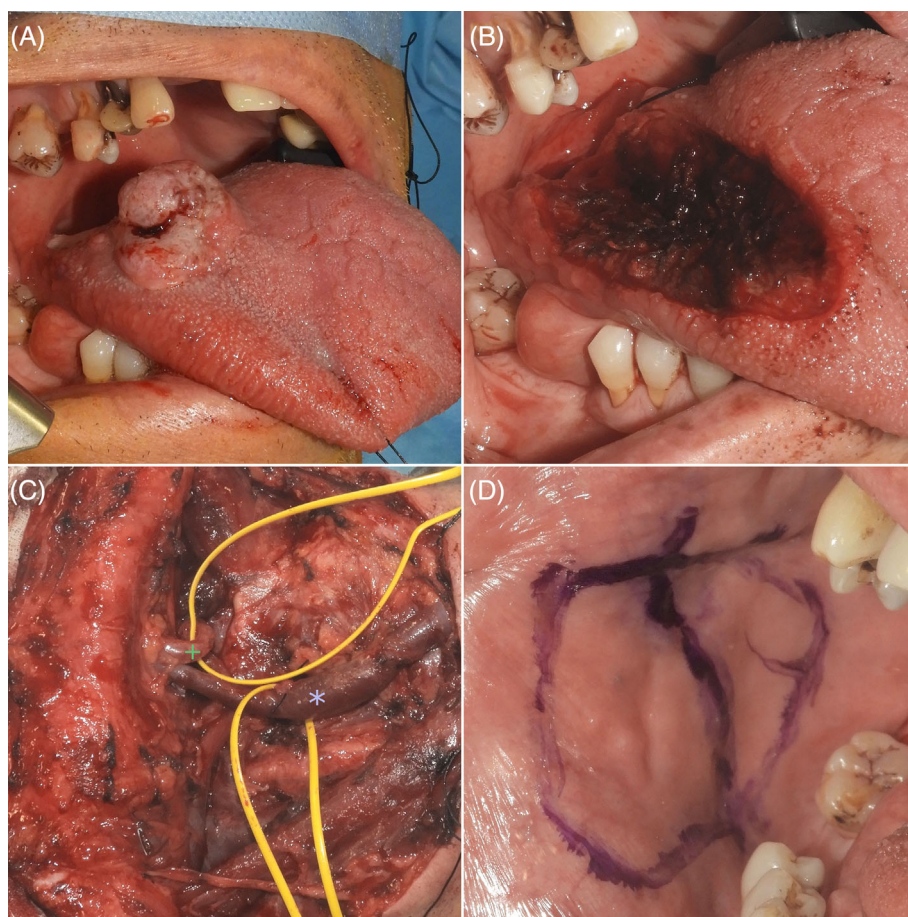
## 1 | INTRODUCTION

The first description of a facial artery musculomucosal (FAMM) flap for head and neck reconstruction purposes was proposed by Pribaz et al.<sup>1</sup> A modification of the flap was later described by Zhao et al.,<sup>2</sup> the facial artery myomucosal island flap (FAMMIF). This is a pedicled flap based on the facial artery, it is sculpted on the internal side of the cheek, passes through a tunnel in the neck, and finally, through a second tunnel, back

in the pharynx or the oral cavity. This type of flap is useful as a reconstructive option for defects of the palate, pharynx, tongue, and floor of the mouth. The tissues included in the flap are the mucosa, submucosa, and part of the buccinator muscle. The FAMMIF is ideal for the reconstruction of small-to-moderate defects of the oral cavity and the oropharynx<sup>3</sup> where it can replace the revascularized free flaps, which remain the first reconstructive option for larger or composite defects.<sup>4</sup> The residual defects after cancer resection of

This is an open access article under the terms of the [Creative Commons Attribution-NonCommercial-NoDerivs](https://creativecommons.org/licenses/by-nc-nd/4.0/) License, which permits use and distribution in any medium, provided the original work is properly cited, the use is non-commercial and no modifications or adaptations are made.

© 2022 The Authors. *Head & Neck* published by Wiley Periodicals LLC.



**FIGURE 1** (A) T2 oral cavity carcinoma of the tongue. (B) Residual defect after resection. (C) After elective neck dissection identification of the facial artery (+) and facial vein (\*) emerging from the anterior jugular vein. (D) Design of the flap, the vertical line outlines the course of the facial artery identified using a Doppler probe [Color figure can be viewed at [wileyonlinelibrary.com](http://wileyonlinelibrary.com)]

the oral cavity or the oropharynx can be variously classified<sup>5,6</sup> and there are multiple reconstructive possibilities that can restore the function and the anatomy. When faced with a reconstruction challenge, the surgeon should consider many variables that can be generally classified in two groups: anatomical and systemic. Large or moderate defects are treated with microvascular revascularized free flaps (RFF)—still the gold standard for many postablative scenarios in head and neck cancer surgery. Also, the patients' specific systemic conditions play an important role in the decision-making process. The presence of advanced systemic compromise, such as severe kidney or liver disease, old age, coagulopathy, among many others, might contraindicate the lengthy and demanding surgeries required to harvest and graft a RFF. At the same time, in patients with a good performance status but a medium-size defect, the RFF can be too big to properly fill the gap.

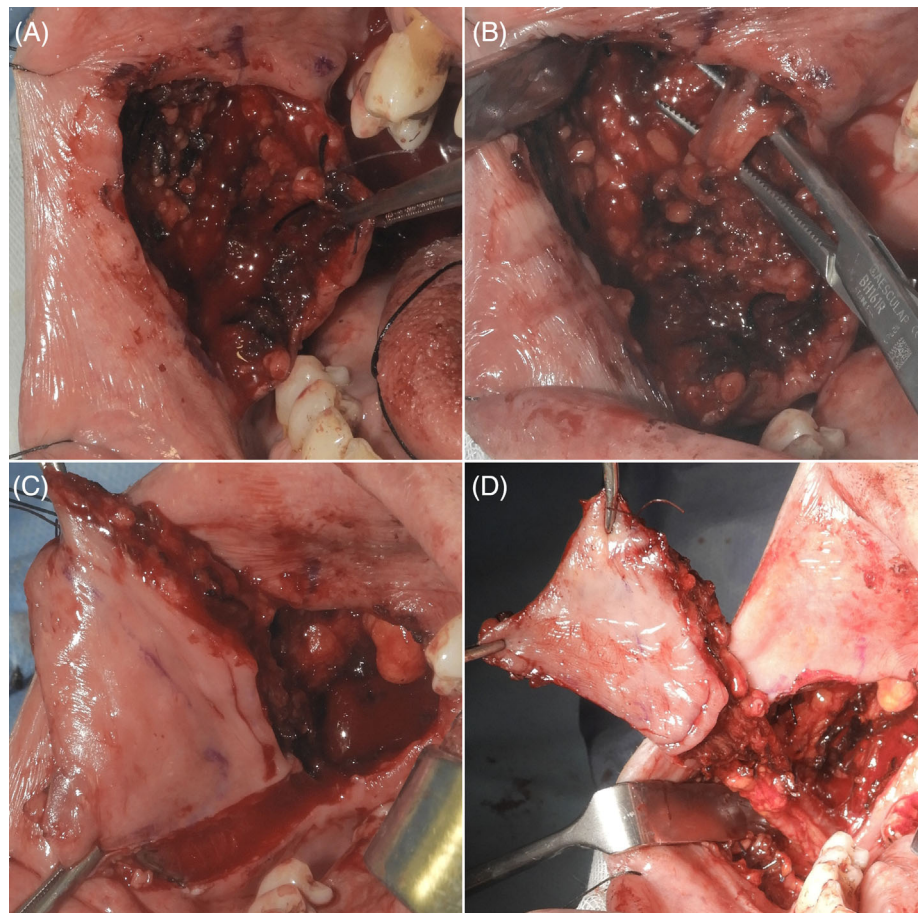
In this context, local flaps can provide a valid reconstructive alternative both as a compromise solution in large defects and as a first choice in small to moderate ones. The FAMMIF is a versatile flap due to its local availability, rapidity of execution, low donor site morbidity, and similarity with the adjacent tissues.<sup>7</sup> The flap passes through the neck and then is repositioned in the

oral cavity. This allows it to overcome the obstacle represented by the teeth and facilitates its use also in dentate patients, which is one of the main strengths of this reconstructive option. In general, the FAMMIF is ideal for defects of 4–10 cm, where there is the need for restoration with thin, pliable mucosa that is similar in color and texture to the excised tissue.

## 2 | TECHNIQUE

The goal of the paper is to detail a step-by-step description of the flap design, the identification of the vessels, the harvesting of the myomucosal island with its passage in the neck and back to the oral cavity, the placement of the flap to reconstruct the defect, and the closure of the donor site with the buccal fat pad. A careful preoperative evaluation is critical to understand if a local flap is the best option. In particular, the following aspects should be considered: dimension of the defect, involvement of multiple functional structures (e.g., tongue and floor of the mouth), patient's dentition, presence of neck metastasis on level I lymph nodes, and previous surgery on the cheek. The case presented was a 55-year-old male with no comorbidities which was referred to our service for a

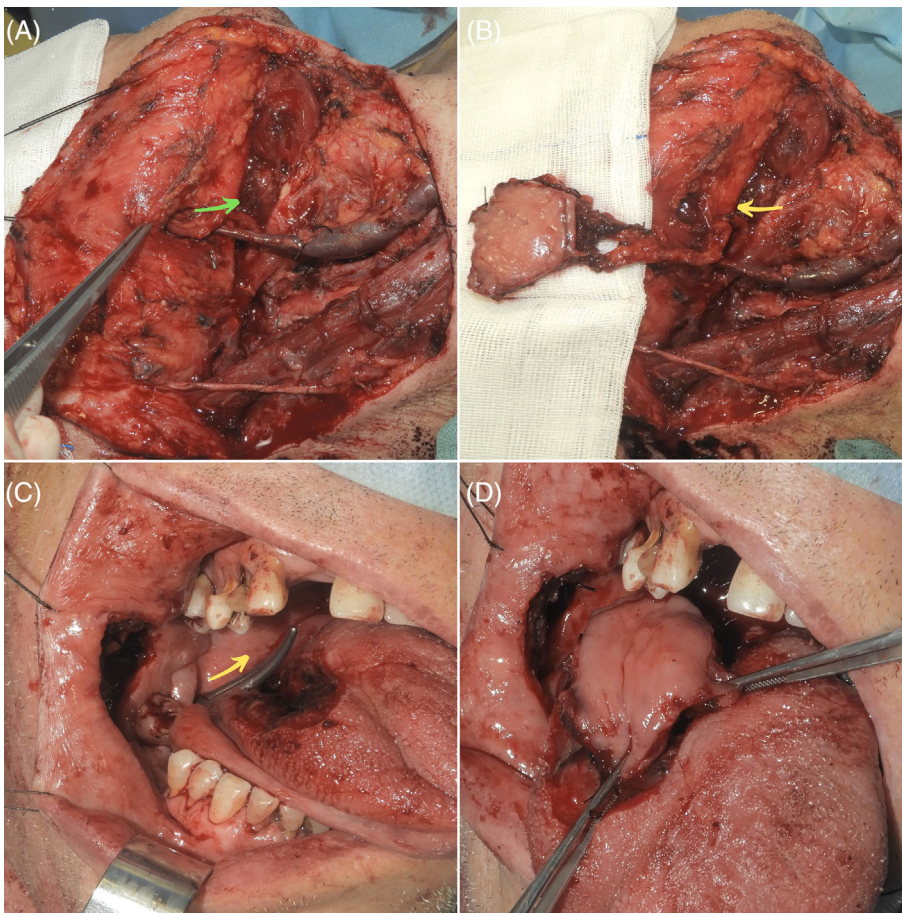
**FIGURE 2** (A) Dissection starts superiorly going inferiorly. (B) Identification and ligation of the superior extremity of the facial artery and vein. (C) Along the inferior border of the flap the buccinator muscle is incised. (D) Isolation of the myomucosal island taking care of isolating the facial artery and vein [Color figure can be viewed at [wileyonlinelibrary.com](http://wileyonlinelibrary.com)]



3 × 2 cm exophytic mass in the right posterolateral dorsum of the tongue. An incisional biopsy was performed, showing the presence of squamous cell carcinoma. Preoperative staging was cT2cN0 disease (Figure 1A). The planned surgical procedure was partial glossectomy, supra-omohyoid elective neck dissection and reconstruction with a local myomucosal flap. The patient was fully dentate and thus the use of a simple axial buccinator flap was not recommended. A FAMMIF was therefore chosen for the possibility to pass the tissues from the mouth to the neck and back in the oral cavity, ensuring the placement of the flap without impediments and risk for pedicle chewing. The patient underwent general anesthesia and was intubated through the nose to have an optimal surgical field. The tumor was excised with 1 cm resection margins (Figure 1B) and an ipsilateral neck dissection involving the levels I-III was performed (Figure 1C). The reconstructive phase then began with the design of the flap. On the right cheek, an oval marking was designed reflecting the size of the defect (Figure 1D). The facial artery and its course were identified with an echo doppler probe and marked with a surgical pen. The Stensen's duct orifice was displayed and excluded from the flap design. A distance of almost 1 cm

should be maintained from the labial commissure anteriorly, and from the vestibular fornix superiorly and inferiorly, to avoid fibrotic retraction and trismus during the healing process. The posterior limit was constituted by the pterygomandibular raphe. The incision started from the superior aspect of the flap and involved the mucosal and muscular plans (Figure 2A). At this level, the distal ends of the facial vessels were then identified via blunt dissection and ligated in their superior extremities (Figure 2B). They can be isolated to the upper portion of the flap by means of one or more monofilament stitches to avoid accidental separation during the dissection. The harvesting proceeded from superior to inferior maintaining as the deep plane the one corresponding to the facial vessels. The inferior margin of the flap was finally incised, taking care to not damage the facial artery and vein (Figure 2C). Once the myomucosal island was isolated, the facial vessels were followed and dissected in the cheek up to the inferior mandibular border (Figure 2D). At this point, the surgeon shifted focus to the neck. Taking care to not damage the marginalis branch of the facial nerve, the cervical portions of the facial artery and vein were isolated (Figures 1C and 3A). Most of the time, the facial vein drains in the internal





**FIGURE 3** (A) In the neck the passage of the facial artery and veins toward the cheek is identified and enlarged (green arrow). (B) The myomucosal island passes through the passage and will be transposed back to the oral cavity through a new passage created along the medial border of the mandible (yellow arrow). (C) The surgical instrument shows the passage in the oral cavity along which the myomucosal island will pass. (D) The myomucosal island in the oral cavity [Color figure can be viewed at [wileyonlinelibrary.com](http://wileyonlinelibrary.com)]

jugular vein. In this patient, instead, the facial vein was draining in the anterior jugular vein, which is a relatively uncommon anatomical variant. Once the vessels were fully isolated, their passage from the oral cavity to the neck was enlarged by the surgeon with the use of a blunt instrument (Figure 3A). The myomucosal island was transposed in the neck (Figure 3B). Following this, a new tunnel was created from the neck to the posterior floor of the mouth, taking care to stay close to medial border of the mandible to avoid damage to the hypoglossal and lingual nerves (Figure 3C). The myomucosal island was transposed back from the neck to the oral cavity via this new tunnel and sutured to cover the defect (Figures 3D and 4A). At the level of the donor site, the buccal fat pad was identified and pulled forward to cover the residual defect (Figure 4B–D).

### 3 | POSTOPERATIVE CARE

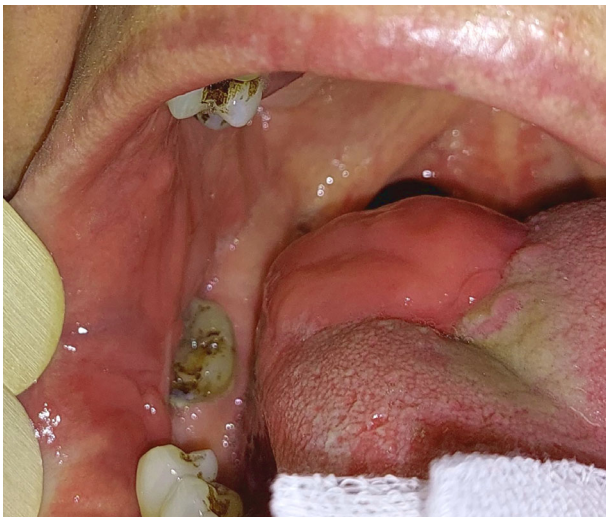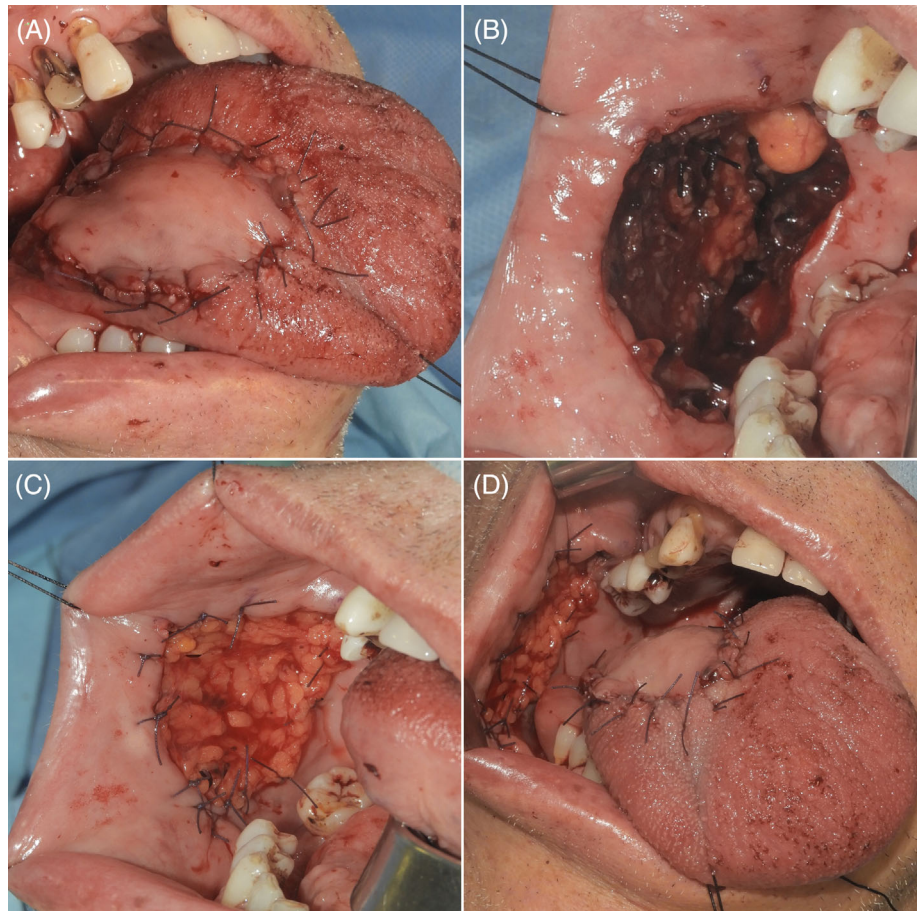
The patient was fed via a nasogastric feeding tube for the first 48 h after surgery and then he transitioned to a soft diet. The postoperative therapy included a standard short course (72 h) antibiotic prophylaxis with amoxicillin/clavulanic acid 875/125 mg, and pain management with

acetaminophen 1 g three times a day together with a rescue therapy of ketorolac 30 mg. The patient was discharged the fifth day postsurgery without complications occurring during the hospital stay. He was visited 6 days after discharge with good healing, good tongue mobility and the ability to speak similarly to the preoperative status. A soft food diet was recommended for the following month. The final histopathology report confirmed the diagnosis of squamous cell carcinoma, G2 pT2pN0. In Figure 5, the surgical outcome is shown at 3 months of follow-up. A routine follow-up basing on the protocols for head and neck tumors was performed and the patient was free from disease at 1 year after treatment.

### 4 | DISCUSSION

The FAMMIF is a good reconstructive option characterized by low operating time, low morbidity, and good functional and aesthetic results.<sup>8,9</sup> This flap reconstructs a surgical defect in a short amount of time, on average between 20 and 60 min,<sup>9,10</sup> excluding the ablation and neck dissection. No specific microvascular training for the head and neck surgeon or preoperative vascular work-up is required. The morbidity is low.

**FIGURE 4** (A) The myomucosal island is sutured to cover the postablative defect. (B) The buccal fat pad is identified in the cheek. (C) The buccal fat pad is used to cover the residual defect were the myomucosal island was harvested. (D) End of surgery [Color figure can be viewed at [wileyonlinelibrary.com](http://wileyonlinelibrary.com)]



**FIGURE 5** Postoperative follow-up at 3 months after surgery [Color figure can be viewed at [wileyonlinelibrary.com](http://wileyonlinelibrary.com)]

The most common postoperative complication is the flap dehiscence. Flap failure is rare and mostly related to damage of the facial vessels during the harvesting phase or to torsion or abnormal kicking of the pedicle during transposition into the oral cavity.<sup>10,11</sup> The complete dissection of the facial vessels and the

creation of a tunnel between the mandible and the cheek, and then between the neck and oral cavity, allow for the independent transposition of the flap from the dentition and avoid the need for secondary procedures to section the pedicle. Conversely, the dissection must be very careful during the tunnel preparation to avoid damaging the marginalis branch of the facial nerve. Regarding the functional results, previous studies<sup>7,10,11</sup> showed a good functional recovery and a satisfactory quality of life. Over the last two decades, the FAMMIF has found multiple useful applications in the reconstruction of defects in the head and neck area. These are not limited to cancer surgery but also to post-traumatic defects and to the rehabilitation of cleft lip and palate patients.<sup>12,13</sup> Undoubtedly, due to its anatomical and tissue characteristics, this flap is ideal for the oropharynx, floor of mouth and tongue reconstruction. In particular, the FAMMIF is indicated in the reconstruction of small to moderate defects (post T1-T2 tumors resection) when single functional units are involved. The FAMMIF can also be used in dentate patients. In fact, when the patient has all the molars on the side of reconstruction, the use of a traditional FAMM is either not possible as the teeth would damage the flap once the patient closes their mouth, or it



mandates the extraction of one or multiple molars for an optimal flap inset. Ibrahim et al.<sup>14</sup> compared FAMM and radial forearm free flap (RFFF) and described the need to extract a molar in three out of nine patients in the FAMM group. Clearly, creating areas of edentulism in the posterior region is a notable downside for patients that are already predisposed to malnutrition due to their underlying disease. The fact that the FAMMIF allows for the preservation of the teeth is one of its greatest advantages. Less satisfactory results are obtained with its use in the restoration of defects involving several functional structures (e.g., tumors involving the floor of the mouth and the tongue at the same time). The limited amount of tissue available does not allow for an independent reconstruction of each structure, leading to a higher risk of ankyloglossia and dehiscence. Though the revascularized free flaps are still considered the gold standard for reconstruction of medium to big defects (post T3-T4 tumors resection), in systemically compromised or elderly patients or in salvage surgery after a free flap failure, the local flaps can serve as a good compromise. Even if the quantity of tissue supplied is lower than the amount of tissue removed, the FAMMIF still creates coverage of the defect, avoiding the formation of dehiscence and fistulas. The elasticity of the mucous tissue also facilitates the recovery of a fair amount of motility. In selected cases, a double FAMMIF could be taken into consideration.<sup>15</sup> Despite the numerous advantages, however, the weaknesses of the described technique must also be acknowledged. First, its harvesting always requires direct access to the neck and dissection and removal of the submandibular gland. This might increase the morbidity and the operating times in patients in which a neck dissection is not necessary, together with an increased risk of marginal mandibular nerve damaging. These relative drawbacks can be overcome by a careful surgical approach and by a continuous growth of the surgeon's skills in head and neck surgical procedures. Moreover, a careful evaluation of the neck status should be done beforehand to plan the reconstruction with a flap based on the facial vessels. The presence of neck metastasis in the level I lymph nodes can make the dissection of the facial vessels impossible or oncologically unsafe. Second, the risk of retraction or fibrosis formation during the donor site healing process is a rare but possible outcome of the procedure. This can be avoided by carefully repositioning the buccal fat pad to cover the entire exposed area, as shown in the present step-by-step report. These minor complications are nonetheless less severe than the ones that might occur when revascularized free flaps are used. For this reason, and for all the above-mentioned

benefits, the FAMMIF is a suitable option for the reconstruction of mucosal defects of the oral cavity. After careful evaluation of the local and systemic characteristics of the patient, the FAMMIF is an excellent option for surgeons dedicated to the reconstruction of defects involving the tongue, the floor of the mouth, the cheek, or the palate.

## ACKNOWLEDGMENT

Open access funding provided by BIBLIOSAN.

## CONFLICT OF INTEREST


The authors declare that there is no conflict of interest that could be perceived as prejudicing the impartiality of the research reported.

## DATA AVAILABILITY STATEMENT

Data are available upon reasonable request.

## ORCID

Chiara Copelli  <https://orcid.org/0000-0003-2992-893X>

Alfonso Manfuso  <https://orcid.org/0000-0002-1560-2069>

Pasquale Di Maio  <https://orcid.org/0000-0003-1364-9223>

Paolo Garzino-Demo  <https://orcid.org/0000-0003-0462-2299>

Oreste Iocca  <https://orcid.org/0000-0002-4444-248X>

## REFERENCES

1. Pribaz J, Stephens W, Crespo L, Gifford G. A new intraoral flap: facial artery musculomucosal (FAMM) flap. *Plast Reconstr Surg*. 1992;90(3):421-429. doi:10.1097/00006534-199209000-00009
2. Zhao Z, Li S, Yan Y, et al. New buccinator myomucosal Island flap: anatomic study and clinical application. *Plast Reconstr Surg*. 1999;104(1):55-64.
3. Woo SH, Jeong HS, Kim JP, Park JJ, Ryu J, Baek CH. Buccinator myomucosal flap for reconstruction of glossectomy defects. *Otolaryngol Head Neck Surg*. 2013;149(2):226-231. doi:10.1177/0194599813487492
4. De Virgilio A, Iocca O, Di Maio P, et al. Head and neck soft tissue reconstruction with anterolateral thigh flaps with various components: development of an algorithm for flap selection in different clinical scenarios. *Microsurgery*. 2019;39(7):590-597. doi:10.1002/micr.30495
5. Brown JS, Barry C, Ho M, Shaw R. A new classification for mandibular defects after oncological resection. *Lancet Oncol*. 2016;17(1):e23-e30. doi:10.1016/S1470-2045(15)00310-1
6. De Virgilio A, Kim SH, Magnuson JS, et al. Anatomical-based classification for transoral lateral oropharyngectomy. *Oral Oncol*. 2019;99:104450.
7. Massarelli O, Vaira LA, Biglio A, Gobbi R, Dell'aversana Orabona G, De Riu G. Sensory recovery of myomucosal flap oral cavity reconstructions. *Head Neck*. 2018;40(3):467-474. doi:10.1002/hed.25000

8. Joshi A, Rajendraprasad JS, Shetty K. Reconstruction of intraoral defects using facial artery musculomucosal flap. *Br J Plast Surg*. 2005;58(8):1061-1066. doi:[10.1016/j.bjps.2005.04.052](https://doi.org/10.1016/j.bjps.2005.04.052)
9. Ahn D, Lee GJ, Sohn JH. Reconstruction of oral cavity defect using versatile buccinator myomucosal flaps in the treatment of cT2-3, N0 oral cavity squamous cell carcinoma: feasibility, morbidity, and functional/oncological outcomes. *Oral Oncol*. 2017;75:95-99. doi:[10.1016/j.oraloncology.2017.11.007](https://doi.org/10.1016/j.oraloncology.2017.11.007)
10. Copelli C, Tewfik K, Cassano L, et al. Functional outcomes in tongue reconstruction with myomucosal buccinator flaps. *Oral Surg Oral Med Oral Pathol Oral Radiol*. 2022;133(6):e163-e169. doi:[10.1016/j.oooo.2021.08.027](https://doi.org/10.1016/j.oooo.2021.08.027)
11. Bianchi B, Ferri A, Ferrari S, Copelli C, Sesenna E. Myomucosal cheek flaps: applications in intraoral reconstruction using three different techniques. *Oral Surg Oral Med Oral Pathol Oral Radiol Endod*. 2009;108(3):353-359. doi:[10.1016/j.tripleo.2009.04.021](https://doi.org/10.1016/j.tripleo.2009.04.021)
12. Choi JM, Park H, Oh TS. Use of a buccinator myomucosal flap and bilateral pedicled buccal fat pad transfer in wide palatal fistula repair: a case report. *Arch Craniofac Surg*. 2021;22(4):209-213. doi:[10.7181/acfs.2021.00269](https://doi.org/10.7181/acfs.2021.00269)
13. Franco D, Rocha D, Arnaut M Jr, Freitas R, Alonso N. Versatility of the buccinator myomucosal flap in atypical palate reconstructions. *J Craniomaxillofac Surg*. 2014;42(7):1310-1314. doi:[10.1016/j.jcms.2014.03.016](https://doi.org/10.1016/j.jcms.2014.03.016)
14. Ibrahim B, Rahal A, Bissada E, Christopoulos A, Guertin L, Ayad T. Reconstruction of medium-size defects of the oral cavity: radial forearm free flap vs facial artery musculo-mucosal flap. *J Otolaryngol Head Neck Surg*. 2021;50(1):67. doi:[10.1186/s40463-021-00523-z](https://doi.org/10.1186/s40463-021-00523-z)
15. Ferrari S, Ferri A, Bianchi B, Copelli C, Sesenna E. Reconstructing large palate defects: the double buccinator myomucosal Island flap. *J Oral Maxillofac Surg*. 2010;68(4):924-926. doi:[10.1016/j.joms.2009.08.009](https://doi.org/10.1016/j.joms.2009.08.009)

**How to cite this article:** Copelli C, Manfuso A, Di Maio P, Garzino-Demo P, Iocca O. Myomucosal island flap in the reconstruction of oral cavity defects: Description of the surgical technique. *Head & Neck*. 2023;45(3):745-751. doi:[10.1002/hed.27251](https://doi.org/10.1002/hed.27251)