

Case and Review

Severe Postoperative Chronic Constipation Related to Anorectal Malformation Managed with Osteopathic Manipulative Treatment

Luca Vismara^{a–c} Vincenzo Cozzolino^d Luca Guglielmo Pradotto^{a, b}
Riccardo Gentile^e Andrea Gianmaria Tarantino^{c, e}

^aDepartment of Neurosciences, University of Turin, Turin, Italy; ^bDivision of Neurology and Neurorehabilitation – IRCCS Istituto Auxologico Italiano, Piancavallo-Verbania, Italy; ^cDepartment of Clinical Pediatrics, Manima Not-for-Profit Healthcare and Assistance, Milan, Italy; ^dDepartment of Clinical Research, Accademia Italiana Osteopatia Tradizionale, Pescara, Italy; ^eDepartment of Clinical Research, SOMA Istituto Osteopatia Milano, Milan, Italy

Keywords

Paediatric osteopathy · Osteopathic medicine · Constipation · Low anorectal malformation · Fascia · Autonomic nervous system · Prokinetic program · Pseudoincontinence

Abstract

Constipation is frequent amongst infants who have undergone surgery for anorectal malformation (ARM). Faecal retention, due to a dysfunctional enteric reflex of defaecation, can cause abdominal cramps, pseudoincontinence and, in the worst cases, megacolon. Prokinetic protocols are used to stimulate at least 1 bowel movement per day, including laxatives, enema, stools softeners and dietary schedules. While osteopathic manipulative treatment is adopted in adults for functional constipation, it has not been described for infants. Herein, we report the case of an infant undergoing anorectoplasty for a low ARM who was referred to the osteopath 2 years after the onset of severe constipation associated with pseudoincontinence and abdominal cramps and was refractory to the prokinetic protocol. In a child with a good ARM prognosis, autonomous daily bowel movements should be achieved. In this child, the imbalanced tension of the pelvic floor and immaturity of the parasympathetic plexus led to a

functional alteration of the defaecation reflex. After adjunction of osteopathic manipulative treatment (OMT) to the therapeutic panel, the constipation showed gradual remission, with acquisition of autonomous defaecation 4 months after the therapy began. This suggests the importance of investigating the efficacy of OMT inclusion in the postsurgical prokinetic protocols for ARM patients with a good prognosis.

© 2020 The Author(s)
Published by S. Karger AG, Basel

Background

Anorectal malformations (ARMs) are common congenital malformations of the pelvic region in the paediatric population. They have a prevalence of 1–3 on 5,000 live births, with a boy-to-girl ratio of 4:1 [1]; 43–71% of ARM cases are associated with other malformations [2]. Despite the efficacy of surgery in restoring the anorectal anatomy, functional alterations such as constipation and incontinence can be long-term complications [3]. In a child with ARM but with a good prognosis, sphincter capacity and no spinal deformities, regular bowel emptying should be restored after surgery [4]. This is functionally based on the combined integrity of bowel movement, a good sphincter seal and the integrity of the anal canal [5]. Therefore, constipation in those children is managed with constipation avoidance protocols that comprise a specific dietary schedule and laxatives.

However, constipation remains a frequent concern, especially in benign forms of ARM [3]. Thus, we report the case of a child who underwent anorectoplasty [6] and experienced severe postoperative constipation managed with a protocol including osteopathic manipulative treatment (OMT).

Case Presentation

A 3,400-g male infant born by vaginal delivery at 40 gestational weeks was diagnosed with low ARM during postnatal screening. The mother was a multipara with no remarkable findings at routine serology and morphologic screening. Both parents denied any family history of ARM or other anatomical malformations. At the delivery room examination, the obstetric personnel revealed an imperforated anus and a rectoperineal fistula. Urinary tract echography showed a 6-mm pyelic ectasia of the left renal pelvis without ureter, kidney and bladder involvement. Cardiological, orthopaedic and neurological examinations were negative.

Hence, at 5 days of life, the infant underwent anorectoplasty, without intraoperative complications, receiving a relocation of the rectus with the sphincters [6]. Hegar probe was used to dilate the sphincter after surgery with a gradual increase in calliper until the conclusion of the program. Six months after surgery, the infant was stable with an increase in normal dietary intake. However, laxative therapy with macrogol (0.7 g/kg macrogol 4000 with gradual increase), and enema if necessary, was administered, since he started suffering from severe constipation. Despite the gradual increase in dosage of macrogol, the baby still had evacuation difficulties associated with abdominal pain, frequent urination and aerophagia. Furthermore, 18 months after surgery, he was admitted to the paediatric department for bowel obstruction due to a faecaloma.

After resolution of the obstruction, the laxative therapy was modified, with daily administration of senna with a gradual increase in dose due to persistence of constipation (3.75–15 mg once daily, adjusted according to response). Then, 21 months after surgery, the baby

started soiling and experiencing intense abdominal pain that made him less active during daytime.

Hence, 24 months after surgery, the child was referred to the osteopath, who examined the functional status of the musculoskeletal apparatus and the pelvic region. The main somatic dysfunctions were in the pelvic floor, which presented with an unbalanced tissue texture between the two sides, as well as in the sacroiliac region, linked with an asymmetric passive movement capacity of the sacrococcygeal region. The child received 4 OMTs that were scheduled once a month, each with a duration of 45 min. Indirect manual techniques were used for management of the somatic dysfunctions. These types of technique are characterized by passive movement of the dysfunctional region in a position of less tissue tension [7]. Along with the pharmacological regimen, the child mainly received balanced ligamentous tension treatment of the sacroiliac joint, balance and hold treatment of the sacrococcygeal ligaments and counter-strain treatment of the pelvic floor (Fig. 1). At the end of each OMT session, a balance treatment between the subdiaphragmatic region and the pelvic floor was administered together with craniosacral therapy. During the entire duration of the OMT, laxative therapy was continuously monitored by the paediatrician and adjusted according to response.

After the first OMT, an intermittent slight increase in the child's defaecation frequency was reported by the parents, who managed the incomplete evacuations with enemas and senna. Moreover, after the third OMT, an increase in defaecation frequency was observed (from 2 to 3), associated with a reduction of the intense colic abdominal pain, which led to interruption of the laxative regimen according to the indication of the paediatrician. Enemas were administered by the parents when needed, decreasing to 2 applications per week. In addition, after the third and fourth OMTs, the discharge frequency improved, together with an increase in frequency from 3 to 4 evacuations per week, respectively, leading to completely autonomous defaecation at the end of the treatment period. The pseudo-incontinence stopped 3 months after the OMTs began, observing a modification on the Bristol Stool Chart from type 6 to type 3. Enema kept being used only sporadically with a time period of 2–3 months between each application (Fig. 2).

Osteopathic care continued after the treatment period with 2 treatments per year, managing the pelvic floor tissue tensions linked to the surgical scar. Currently, at 4 years of age, the child no longer manifests constipation and soiling, and enema use was interrupted 2 years previously.

Discussion and Conclusions

Patients with ARM frequently experience constipation after corrective surgical intervention, showing diminished bowel movements. This mechanism leads to reduced faecal passage and to faecal retention, being experienced by more than 77% of children who have undergone anorectoplasty [8].

Moreover, constipation frequently develops after surgery, independently of the ARM type, with a mean interval after the intervention of 5.2 months but with significant variability (0.2–16.2 months) [8]. Delayed recognition of constipation can be an issue that postpones prokinetic programs (PPs) and exposes the child to a higher morbidity risk. Levitt et al. [3] identified an association between delayed intervention with PPs and long-term reduction of bowel mobility, with soiling, abdominal cramps, nausea and emesis with implications for quality of life. This worsening of patients' conditions shows once more the importance of restoring bowel movements after surgery. In a case-control study, endoanal ultrasonography showed a

significant difference in inferior sphincter thickness between postoperative ARM patients and controls. Moreover, balloon manometry showed a difference in bowel distension between the two groups, with a mild inverse correlation between balloon distension and function anal score [9].

These data mark a possible mismatch of the autonomic visceral plexuses and bowel peristalsis, possibly linked to an incomplete autonomic maturation of the anorectal membrane. The fascial alteration, originating from an interruption or reduced physiological connection between the proctodaeum (ectoderm) and anal canal (endoderm) and re-established by surgery, results in a fascial alteration between the coccyx and pubis, including a neurovegetative alteration with an increase in tone muscle and perineal contraction. In fact, defaecation is managed by intrinsic and extrinsic reflexes that are complementarily activated for faeces expulsion [10]. Their role becomes conscious in the adult, where the external sphincter can voluntarily modulate the rectal inhibitory reflex, stopping the peristaltic wave and defaecation. This reflex is far less voluntary in the child, where rectal distension evokes the rectoanal inhibitory reflex activated by the enteric nervous plexus. Interestingly, in this case, we found an altered pelvic floor tissue tension, denoting an unbalanced myofascial load distribution on the pelvic floor, correlated to a severely difficult start of the defaecation reflex. Furthermore, the upper cervical region and presacral fascia, anatomically linked to the parasympathetic nervous system, were found to be dysfunctional in this child as well.

OMT has shown preliminary efficacy in adults with functional constipation [11], in reducing gastrointestinal symptoms caused by adjuvant chemotherapy [12] and in patients with distal intestinal obstructive syndrome [13]. However, OMT effects have been described only in 1 case of a child with chronic constipation related to Pitt-Hopkins syndrome, showing an increment in defaecation frequency and better Bristol Stool Chart scores during the treatment period [14].

In our patient, the postoperative constipation was rapidly approached with macrogol and senna, helping the child emptying his bowel in the postoperative period. However, due to obstinate constipation, even a higher dosage of senna and enemas were not able to empty his bowel. Introduction of OMT in the therapeutic management enhanced his bowel movements in the short term, and reduced the constipation and its associated symptoms in the long term. This case emphasizes the importance of considering OMT as an adjuvant therapy to PPs for chronic constipation in the postsurgical period, and the possible clinical implication of myofascial system dysfunctions of the pelvic floor in children with ARMs.

Acknowledgments

The authors wish to acknowledge the parents of the child for their willingness and active participation and to thank the Università di Torino PhD Program in Experimental Medicine and Therapy.

Statement of Ethics

Case reports are not required to have institutional review board approval. Our patient and the patient's father signed a written consent form for publication of his clinical data and his pictures according to the Manima organization's internal policies and statutes.

Disclosure Statement

The authors declare that they have no competing interests.

Funding Sources

No funding was obtained for this study.

Author Contributions

L.V. conceptualized and designed the case report, reviewed and revised the manuscript, and approved the final manuscript as submitted; R.G. developed the initial draft and approved the final manuscript as submitted; L.G.P. developed the final draft, revised the manuscript, and approved the manuscript as submitted; V.C. developed the literature review, revised the manuscript, and approved the final manuscript as submitted; A.G.T. developed the final draft, revised the manuscript, and approved the manuscript as submitted.

References

- 1 International Clearinghouse for Birth Defects Surveillance and Research. [Annual report 2011: with data for 2009](#) [accessed 2013 Dec 18]. Available from: www.icbdsr.org/filebank/documents/ar2005/Report2011.pdf.
- 2 Bălănescu RN, Topor L, Moga A. Anomalies associated with anorectal malformations. *Chirurgia (Bucur)*. 2013 Jan-Feb;108(1):38–42.
- 3 Levitt MA, Kant A, Peña A. The morbidity of constipation in patients with anorectal malformations. *J Pediatr Surg*. 2010 Jun;45(6):1228–33.
- 4 Levitt MA, Peña A. Imperforate anus and cloacal malformations. In: Holcomb GW, Murphy JP, editors. *Pediatric surgery*. 5th ed. Philadelphia: Elsevier Saunders; pp. 337–59.
- 5 Levitt M, Peña A. Update on pediatric faecal incontinence. *Eur J Pediatr Surg*. 2009 Feb;19(1):1–9.
- 6 Whyte C, Cauty TG, Smith J, Melody K. Anoplasty for low anorectal malformation. *J Pediatr Surg*. 2016 Oct;51(10):1602–6.
- 7 Tozzi P, Bongiorno D, Vitturini C. Fascial release effects on patients with non-specific cervical or lumbar pain. *J Bodyw Mov Ther*. 2011 Oct;15(4):405–16.
- 8 Chang PC, Duh YC, Fu YW, Hsu YJ, Wei CH, Huang H. How much do we know about constipation after surgery for anorectal malformation? *Pediatr Neonatol*. 2019 Feb;61(1):58–62.
- 9 Wang Z, Hu L, Jin X, Li X, Xu L. Evaluation of postoperative anal functions using endoanal ultrasonography and anorectal manometry in children with congenital anorectal malformations. *J Pediatr Surg*. 2016 Mar;51(3):416–20.
- 10 Shafik A, El-Sibai O, Ahmed I. Parasympathetic extrinsic reflex: role in defecation mechanism. *World J Surg*. 2002 Jun;26(6):737–40.
- 11 Belvaux A, Bouchoucha M, Benamouzig R. Osteopathic management of chronic constipation in women patients. Results of a pilot study. *Clin Res Hepatol Gastroenterol*. 2017 Oct;41(5):602–11.
- 12 Lagrange A, Decoux D, Briot N, Hennequin A, Coudert B, Desmoulins I, et al. Visceral osteopathic manipulative treatment reduces patient reported digestive toxicities induced by adjuvant chemotherapy in breast cancer: a randomized controlled clinical study. *Eur J Obstet Gynecol Reprod Biol*. 2019 Oct;241:49–55.
- 13 Modlin SE, Borofka K, Franzini D, Klene-Bowns AC, Nuño VA. OMT for the Prevention and Management of Chronic Constipation and Distal Intestinal Obstructive Syndrome in Cystic Fibrosis: A Pilot Study. *J Am Osteopath Assoc*. 2019 Jul;119(7):e31–5.
- 14 Aquino A, Perini M, Cosmai S, Zanon S, Pisa V, Castagna C, et al. Osteopathic Manipulative Treatment Limits Chronic Constipation in a Child with Pitt-Hopkins Syndrome. *Case Rep Pediatr*. 2017;2017:5437830.

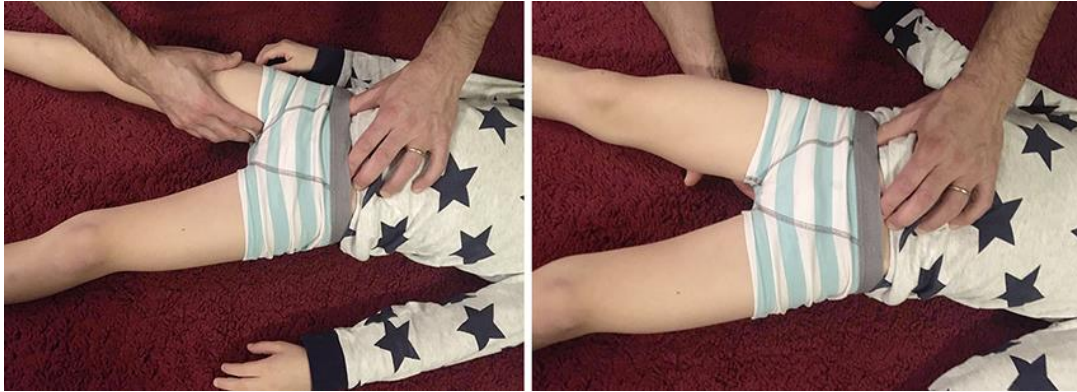

Fig. 1. Osteopathic manipulations including counter-strain treatment of the pelvic floor and balance and hold treatment of the sacrococcygeal ligaments.

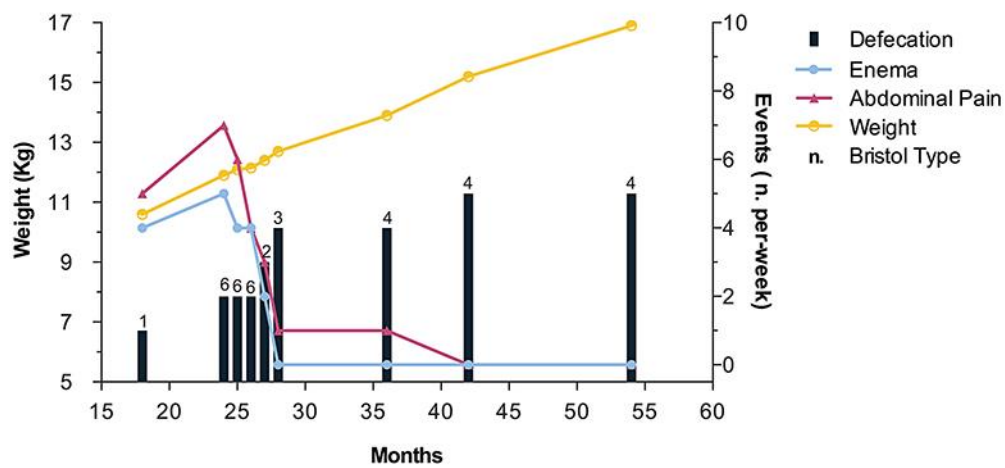


Fig. 2. Relevant clinical findings including the number of defaecations, enema administrations and abdominal cramps as well as weight gain during the treatment phase. Stool type characteristics are reported according to the Bristol Stool Chart.