



## The role of surgery in recurrent endometrial cancer

Valentina Zanfagnin, Annamaria Ferrero, Nicoletta Biglia, Giovanni Aletti, Sarah E. Gill, Peter B. Makdisi, Francesco Multinu & Andrea Mariani

To cite this article: Valentina Zanfagnin, Annamaria Ferrero, Nicoletta Biglia, Giovanni Aletti, Sarah E. Gill, Peter B. Makdisi, Francesco Multinu & Andrea Mariani (2016) The role of surgery in recurrent endometrial cancer, Expert Review of Anticancer Therapy, 16:7, 741-750, DOI: [10.1080/14737140.2016.1190650](https://doi.org/10.1080/14737140.2016.1190650)

To link to this article: <http://dx.doi.org/10.1080/14737140.2016.1190650>



Accepted author version posted online: 08 Jun 2016.  
Published online: 13 Jun 2016.



Submit your article to this journal [↗](#)



Article views: 137



View related articles [↗](#)



View Crossmark data [↗](#)

REVIEW

## The role of surgery in recurrent endometrial cancer

Valentina Zanfagnin<sup>a</sup>, Annamaria Ferrero<sup>b</sup>, Nicoletta Biglia<sup>b</sup>, Giovanni Aletti<sup>c</sup>, Sarah E. Gill<sup>a</sup>, Peter B. Makdisi<sup>a</sup>, Francesco Multinu<sup>a</sup> and Andrea Mariani<sup>a</sup>

<sup>a</sup>Division of Gynecologic Surgery, Mayo Clinic, Rochester, MN, USA; <sup>b</sup>Academic Division of Obstetrics and Gynecology, Maurizio Umberto I Hospital, Turin, Italy; <sup>c</sup>European Institute of Oncology, Milan, Italy

### ABSTRACT

**Introduction:** Endometrial cancer is a common gynecologic malignancy in the United States, and the recurrence rate depends on the disease stage at diagnosis. Recurrence can affect several areas and follow different patterns.

**Areas covered:** The role of surgery at the time of recurrence is not clearly defined. In this review, we fully describe the current evidence available. In particular, we describe how surgical treatment might be recommended for 1) vaginal or pelvic recurrences; 2) retroperitoneal or localized intra-abdominal recurrence, when a maximal cytoreductive effort is more likely to be successful; or 3) isolated distant recurrences when microscopically tumor-free margins can be achieved.

**Expert commentary:** Cases should be evaluated individually, considering factors such as comorbidities, risks of intervention, and impact of treatment on quality of life.

### ARTICLE HISTORY

Received 16 February 2016

Accepted 3 May 2016

Published online

11 June 2016

### KEYWORDS

Endometrial neoplasm; intraoperative radiation therapy; metastases; quality of life; secondary cytoreductive surgery

## 1. Introduction

Neoplasms of the uterine corpus are the fourth most common cancer in women. In 2015, an estimated 54,870 new cases of endometrial cancer were diagnosed and 10,170 women died of this disease. From 2007 through 2011, the incidence rate and death rate increased by 2.4% and 1.9% per year, respectively, probably because of higher life expectancy and increasing incidence of obesity in developed countries [1].

Endometrial cancer generally has a favorable prognosis. At diagnosis, most women have early stage, low-grade disease, which is associated with a 90% 5-year survival rate and an estimated recurrence risk of 10–15%. However, in women with high-risk histologic findings (grade 3 endometrioid adenocarcinoma, papillary serous, clear cell, and carcinosarcoma histologic subtypes) or locally advanced disease, the biological behavior of the cancer is more aggressive and the prognosis is worse, with recurrence rates as high as 50% [2].

Recurrence typically develops within 3 years of primary treatment [3]. After recurrence is diagnosed, the subsequent management strategy depends on the site of recurrence, the duration of the disease-free period, the general medical condition of the patient, and whether prior adjuvant treatment (radiotherapy, chemotherapy, or both) was administered. Patients with local recurrence and no previous radiotherapy often receive radiotherapy, whereas women with disseminated distant metastasis receive systemic treatment (chemotherapy or hormonal therapy). In these settings, the role of surgery is poorly defined and data in the literature are scant. Here, we review the available literature regarding surgical options and their feasibility in recurrent endometrial cancer.

## 2. Primary treatment of endometrial cancer

### 2.1. Diagnosis and staging

Postmenopausal bleeding is the most common symptom of endometrial cancer, and the diagnosis is usually established by endometrial biopsy or dilatation and curettage, with or without hysteroscopy. For clinical staging, preoperative imaging (e.g. computed tomography [CT], magnetic resonance imaging, or positron emission tomography [PET]) is used to determine the presence of extrauterine disease and is generally indicated for patients with symptoms or abnormal clinical findings. Unfortunately, preoperative imaging studies are generally not accurate for detecting microscopic extrauterine metastases [4–6]. Surgical staging is the diagnostic criterion standard for the identification of extrauterine dissemination and is a cornerstone of management of endometrial cancer. According to the International Federation of Gynecology and Obstetrics staging system, complete staging consists of hysterectomy and bilateral salpingo-oophorectomy and may also include pelvic and para-aortic lymphadenectomy.

### 2.2. Surgical approach, special situations, and postsurgical treatment

Traditionally, staging laparotomy is the surgical approach of choice for endometrial cancer, but recently, laparoscopic or robot-assisted approaches are increasingly used. Randomized controlled trials comparing laparoscopic surgery with laparotomy showed similar surgical effectiveness without compromising the degree of oncologic radicality [7,8]. Furthermore, robotic surgery may show outcomes similar to those of

laparoscopy [9,10]. Table 1 shows suggested surgical procedures for primary and recurrent endometrial cancer.

After surgical staging, adjuvant therapy (systemic chemotherapy, radiotherapy, or a combination) may be indicated for patients with advanced-stage disease or those with tumors confined to the uterus but with associated risks factors [11].

### 3. Patterns of dissemination and recurrence

The overall rate of recurrence for endometrial cancer is about 10–15%, with more than half of failures occurring within 3 years of primary treatment [3]. Recurrence rates are higher in patients with advanced-stage disease and those with aggressive histologic subtypes (grade 3 or nonendometrioid) [3]. Most women are symptomatic at the time of recurrence, and the most common symptoms are bleeding (from the vagina, bladder, or rectum), anorexia, weight loss, bone or pelvic pain, cough, shortness of breath, or lower abdominal or extremity swelling [12].

The diagnostic evaluation of suspected recurrent disease includes a pelvic examination with possible biopsies of clinically suspicious areas; a physical examination focused on nodal regions; and radiologic imaging to determine whether metastatic disease is present. CT is often the primary imaging modality used to evaluate potential recurrence; if the scan is equivocal, further evaluation with PET or combined PET-CT may be indicated [11].

Recurrent endometrial cancer disseminates via four main routes: contiguous, lymphatic, peritoneal, and hematogenous (Table 2) [13]. The pattern of metastasis can be attributed to one route alone or a combination. As an example, in an unselected population of 915 patients (without history of other malignancies) who received treatment for endometrial cancer at Mayo Clinic during a 13-year period, the relapse rates were 5% for vaginal, 9% for hematogenous, 6% for lymphatic, and 6% for peritoneal pathways of dissemination [13] (Figure 1).

From a clinical perspective, recurrence can be organized into four patterns:

- (1) Isolated vaginal recurrence (or central recurrence) is defined as an isolated recurrence involving the vaginal vault or cuff.
- (2) Central pelvic recurrence (or locoregional recurrence) is typically recurrent disease affecting pelvic structures

**Table 1.** Surgery in EC.

Type of surgery	Procedure
Primary surgery	
Type 1 endometrioid cancer	Total hysterectomy, bilateral salpingo-oophorectomy, pelvic and para-aortic lymphadenectomy (depending on preoperative and intraoperative findings), biopsy of any suspect lesions
Type 2 EC	Peritoneal cytology (optional) Peritoneal biopsies, total hysterectomy, bilateral salpingo-oophorectomy, pelvic and para-aortic lymphadenectomy, omentectomy, biopsy of any suspect lesions
At recurrence	Total pelvic exenteration (or radical pelvic surgery) Surgical cytoreduction to no gross residual disease Surgical excision of isolated distant metastases

EC: endometrial cancer.

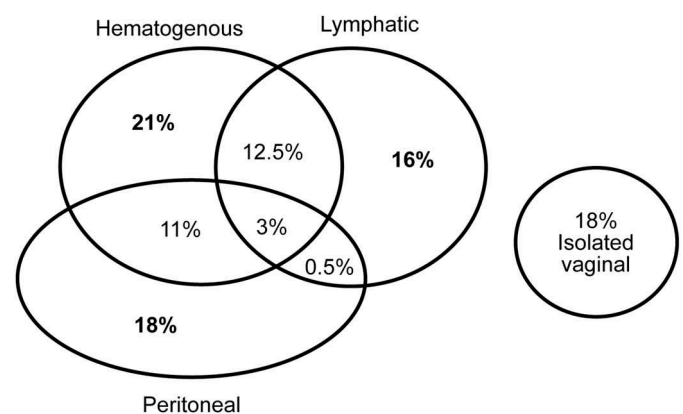
**Table 2.** Patterns of recurrence.

Recurrence type	Affected area
Contiguous	
Isolated	Vaginal vault, vaginal cuff
Local extension beyond the uterus (locoregional)	Vagina, vulva, lower urinary tract, rectosigmoid colon
Lymphatic	
General	Retroperitoneum
Spread through the lymphatic system	Pelvic and para-aortic nodes, inguinal nodes, axillary nodes, supraclavicular nodes, mediastinal nodes
Peritoneal (or spread along the peritoneal cavity)	Intraperitoneal implants, peritoneal carcinomatosis
Hematogenous (or spread through the vascular system)	Most commonly lung, brain, bones, liver

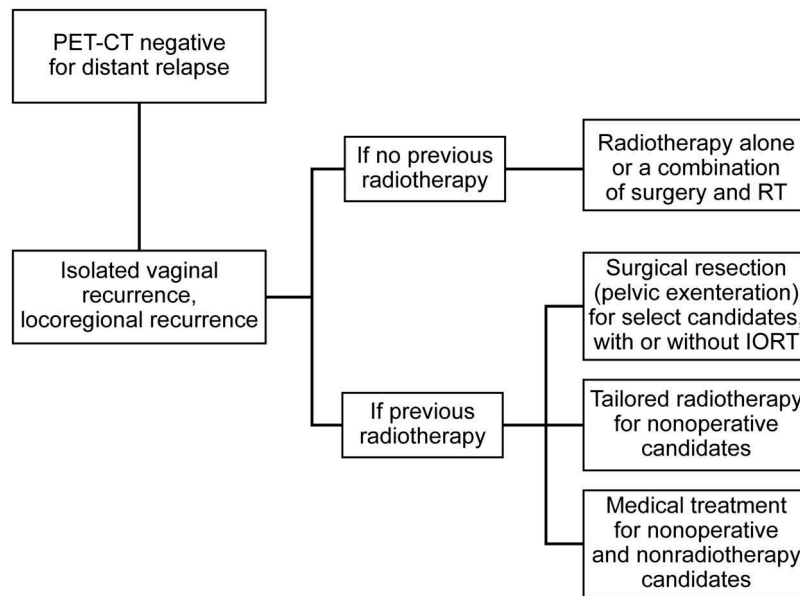
such as the vulva, vagina, lower urinary tract, and rectosigmoid colon.

- (3) Lateral-pelvic recurrence or pelvic sidewall recurrence is a lymphatic recurrence along the major vessels of the pelvic side wall.
- (4) Distant extrapelvic recurrence (e.g. in the abdominal retroperitoneum, lung, brain, or other distant sites) is often multifocal.

The management strategy for patients with recurrence depends on the site of recurrence, the duration of the disease-free period, the general medical condition of the patient (including performance status), and whether prior adjuvant treatment (radiotherapy, chemotherapy, or both) was administered (Figure 2). Women with recurrent disease isolated to the vaginal vault are potentially curable [14]. Options for treatment depend on whether radiotherapy was previously administered. If radiotherapy was not administered previously, it is the treatment of choice. If radiotherapy was administered, radical surgery is an option for selected candidates. Similarly, in women with locally recurrent disease limited to the central pelvis, treatment options potentially are curative and include surgery or radiotherapy (including intraoperative radiotherapy



**Figure 1.** Patterns of recurrences in endometrial cancer. Of all recurrences, 48% had a hematogenous component (21% were isolated hematogenous recurrences), 32% had lymphatic component (16% were isolated lymphatic recurrences), 33% had peritoneal component (18% were isolated peritoneal recurrences), and 18% had isolated vaginal recurrences. Approximately 27% of recurrences had multiple components of recurrence. Adapted with permission from Mariani et al. [13].



**Figure 2.** Treatment options for locoregional recurrences. IORT indicates intraoperative radiotherapy; PET-CT, positron emission tomography–computed tomography; RT, radiotherapy.

[IORT] for lateral recurrences). In women with extrapelvic disease, treatment usually is not curative and the approach should be individualized [11,15].

Despite the above indications, the role of surgery in recurrent endometrial cancer is rarely mentioned in the literature. Current guidelines from the United States (National Comprehensive Cancer Network), Canada (Alberta Provincial Gynecologic Oncology Tumour Team), and Europe (European Society for Medical Oncology) recommend a surgical approach for women with isolated vaginal or pelvic recurrence and a history of radiotherapy, but the recommendation is supported by only low-level evidence [11,15,16]. For distant metastases, available data are from case reports or small series, so indications are only weakly supported. For patients with multiple recurrence sites, surgery usually is not a feasible option. However, in a few selected cases, it could be considered, especially if the patient's performance status is good and the lesions are resectable, with no residual tumor remaining.

Options for surgical management of endometrial cancer, depending on the pattern of recurrence, are described below. We emphasize that the most favorable surgical candidates have a good performance status and a long interval without endometrial cancer or any other systemic disease; additionally, they must have resectable disease with the potential to achieve microscopically tumor-free margins. However, a multidisciplinary approach is mandatory to tailor therapies. Figures 3 through 6 and Table 3 summarize the surgical options for every site of recurrence.

#### 4. Isolated vaginal and locoregional recurrence

Women who have undergone surgery for endometrial cancer are at risk of relapse in the vaginal vault; this 8-year risk of relapse is lower in those who received adjuvant external radiotherapy (2% vs. 8% for radiotherapy vs. no-radiotherapy groups, respectively) or with vaginal brachytherapy [27].

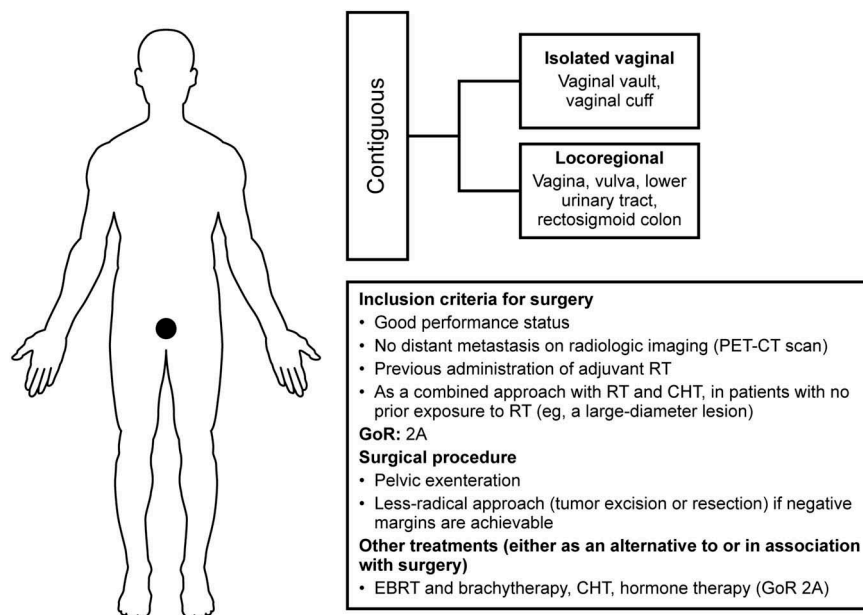
**Table 3.** Patterns of recurrence and surgical procedures.

Recurrence	Surgical procedure	Reference
Contiguous	Pelvic exenteration	Westin et al. 2014 [17]
	Local excision	Foote et al. 1988 [18]
Lymphatic	Excision or gross surgical resection followed by intraoperative radiotherapy when appropriate	Dowdy et al. 2006 [19]
Peritoneal	Cytoreduction to no gross residual disease, followed by hyperthermic intraperitoneal chemotherapy (experimental) in selected cases, if appropriate	Barlin et al. 2010 [20]
		Bakrin et al. 2010 [21] Papadia et al. 2015 [22]
Hematogenous	Brain: resection followed by whole-brain radiotherapy	Tsao et al. 2012 [23]
	Lung: resection or excision	Knowles et al. 2010 [24]
	Liver: hepatic resection	Dowdy et al. 2007 [25]
	Bone: wide resection; intrasiesional curettage followed by internal fixation; palliative decompression of the spinal cord	Uccella et al. 2013 [26]

Prognosis is usually better in patients with isolated vaginal vault recurrence compared with patients with relapse in other pelvic structures (3-year overall survival rate, 73% vs. 8%;  $P < .001$ ) [28].

For patients with a suspected local recurrence (either isolated vaginal or locoregional), radiologic imaging should be performed to exclude other sites of metastasis. The modality considered to be most accurate is integrated PET-CT. If no distant metastases are found, the treatment approach considers whether radiotherapy was previously administered (Figure 3).

Radiotherapy is the standard treatment for women with isolated vaginal recurrence and no history of radiotherapy; the complete response rate is 87% [28]. Chemotherapy and surgery can be used in selected patients with local extension of the disease or a large-diameter recurrence. For women who have previously received adjuvant radiotherapy, the prognosis is poorer and treatment recommendations vary among



**Figure 3.** Summary of surgical options, inclusion criteria, recommendation grade, and other treatments for contiguous recurrences. CHT indicates chemotherapy; EBRT, external beam radiotherapy; GoR, grade of recommendation; HIPEC, hyperthermic intraperitoneal chemotherapy; IORT, intraoperative radiotherapy; PET-CT, positron emission tomography–computed tomography; RT, radiotherapy.

institutions. Repeat radiotherapy might be an option in select cases [29], whereas radical surgical resection, sometimes combined with IORT, might be proposed for appropriate surgical candidates [30].

Historically, in surgery-eligible patients with recurrence limited to the vaginal apex within an irradiated field, the surgical approach is pelvic exenteration [31,32]. Total exenteration refers to removal of the uterus, fallopian tubes, ovaries (if still present), parametrium, bladder, rectum or rectal segment, vagina, urethra, and a portion of the levator muscles. In the anterior exenteration, the rectum is spared, whereas in the posterior exenteration, the bladder and urethra are preserved. A perineal phase, with resection of the anus, urethra, and portions of the vulva, may also be required. Other classifications of pelvic exenteration are supralelevator and infralevator. Supralelevator exenteration includes removal of the bladder, upper vagina, cervix, uterus, and rectosigmoid colon, while preserving the pelvic floor. In infralevator exenteration, removal of the pelvic floor muscles is indicated if the disease involves the lower part of the vagina, vulva, perineum, or anus; reconstruction with myocutaneous flaps, omental flap, or dura mater has been performed to address the large pelvic defect [33].

The choice of procedure depends on the location of the cancer, difficulties that may arise during surgery, type and location of previous radiotherapy, anatomy, and the patient's postoperative goals and expectations. A recent review by Ang et al. [34] indicated that no high-level evidence was available to guide women with recurrent cervical, endometrial, vaginal, or vulvar malignancies in decisions about exenterative surgery. No randomized studies have determined whether exenterative surgery is superior to non-surgical treatment in terms of prolonged survival, treatment-related complications, or quality of life [34].

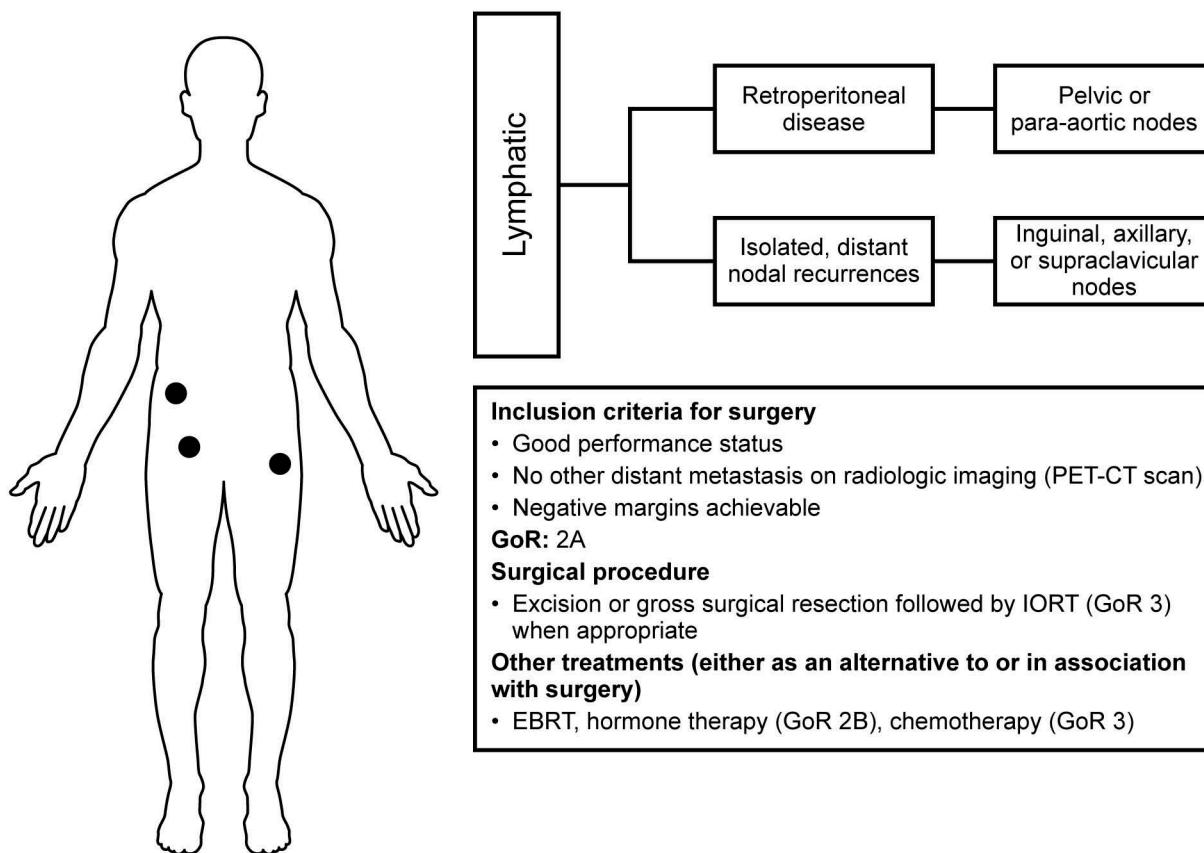
In a retrospective cohort study of patients who underwent pelvic exenteration after recurrent endometrial neoplasm, Westin et al. [17] described a 5-year relapse-free survival rate of 45% and a 5-year overall survival rate of 56%. Other series have described similar 5-year overall survival rates [35–41]. The potential complications associated with pelvic exenteration are numerous and should be considered during the decision-making process. The major early postoperative complications include blood loss, sepsis, wound dehiscence, and anastomotic breakdown at the level of the bowel, urinary pouch, or ureteral sites. Late complications include fistula, ureteral strictures, renal failure, pyelonephritis, and chronic bowel obstruction. Other complications include deep venous thrombosis and pulmonary emboli, flap necrosis, and stomal necrosis [42,43]. Despite improvements in patient selection and surgical techniques, overall survival rates have not changed meaningfully over time, and rates of long-term complications have remained steadily high [17]. Therefore, because short- and long-term sequelae of treatments might have a significant and negative impact on a patient's quality of life, and considering that surgical exenteration is a major procedure, great effort should be made in the preoperative setting to accurately inform the patient and provide psychological support.

## 5. Lymphatic spread

### 5.1. Retroperitoneal disease

Many endometrial cancers recur within the pelvic sidewall or retroperitoneum through lymphatic embolization (Figure 4). Pelvic and para-aortic lymph nodes are most commonly involved in nodal spread. External iliac lymph nodes are the most commonly involved pelvic lymph





**Figure 4.** Summary of surgical options, inclusion criteria, recommendation grade, and other treatments for lymphatic recurrences. Abbreviations are defined in the Figure 3 legend.

nodes, followed by the obturator and common iliac nodes. Lymphatic recurrences, which are generally poorly differentiated, do not respond to hormonal therapy and respond poorly to multiagent chemotherapy [28]. Recurrence in the pelvic sidewall or lymph node-bearing areas is associated with 3-year survival rates of less than 10% after radiotherapy, and local secondary recurrence rates may be as high as 100% [28].

A Mayo Clinic case series of 25 patients with retroperitoneal recurrences reported an aggressive treatment approach with preoperative radiation, radical surgical resection, and intraoperative radiotherapy [19]. The objective was to determine whether this approach maximized tumor control and decreased complications compared with radiotherapy alone. The overall 5-year survival was 47% (median survival, 57 months). Patients with a gross total resection and negative margins had a 5-year survival rate of 71%, which was much better than patients with gross or microscopic residual disease (0% and 40%, respectively). This finding underscores the importance of achieving gross total resection.

The morbidity rate of radical procedures is high (64%) [19]. Possible complications include pulmonary embolism, acute lower-extremity ischemia, small-bowel and functional ureteral obstruction, and fistulas. Nevertheless, given that tumor-related mortality rates in the absence of treatment are nearly 100%, radical procedures should be considered; however, their high rates of morbidity must be discussed preoperatively with the patient.

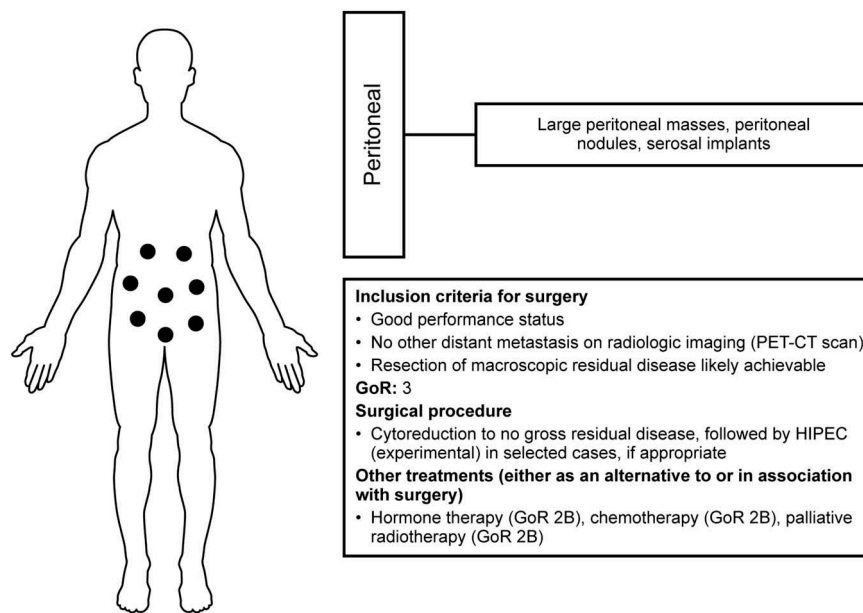
## 5.2. Isolated distant nodal recurrences

First recurrences in an inguinal, axillary, or supraclavicular node as an isolated site are extremely rare. At Mayo Clinic, 22 patients with such a recurrence were reported in a case series; of these, seven were treated with excision and aggressive local irradiation and achieved local control of the nodal recurrence. Although the median survival after isolated peripheral lymph node recurrence was only 19 months, six patients were alive without evidence of cancer at a median follow-up of 27 months [18]. Even if an associated effective systemic adjuvant treatment is usually needed, in patients with isolated peripheral nodal recurrences, this series showed that aggressive local treatment can provide long-term, disease-free survival.

## 6. Peritoneal recurrences

Peritoneal carcinomatosis is a common type of recurrent endometrial carcinoma (Figure 5), accounting for 28% of relapses. This pattern of recurrence is generally associated with a poor prognosis [13,44]. Recurrences may be large peritoneal masses, peritoneal nodules, and serosal implants that may cause extrinsic compression of the bowel.

The meta-analysis by Barlin et al. [20] suggests that among patients with recurrent or advanced endometrial cancer, surgical cytoreduction to no gross residual disease may confer a survival advantage. Papadia et al. [22]



**Figure 5.** Summary of surgical options, inclusion criteria, recommendation grade, and other treatments for peritoneal recurrences. Abbreviations are defined in the Figure 3 legend.

reported complete resection to no visible disease in 42 of 64 cases of EC (66%) that underwent cytoreductive surgery for recurrence, and according to the studies considered in the review by Barlin et al. [20], they reported similar 5-year rates of RFS and OS (34% and 51%, respectively).

Any residual disease (microscopic or gross) after cytoreductive surgery is considered a failed surgical treatment. Some patients with microscopic residual disease have undergone cytoreductive surgery and received hyperthermic intraperitoneal chemotherapy; however, available data are based on only a few patients, and no consistent conclusion about the benefits of this procedure can be drawn [21].

In conclusion, cytoreductive surgery in peritoneal recurrences is indicated if the patient has a good preoperative performance status, no comorbidities that are contraindications for the procedure itself, and the potential for complete resection of macroscopic disease. When complete removal of the disease is not achievable but a maximum extent of surgery will improve the patient's quality of life (e.g. in cases of bowel obstruction), a surgical approach is indicated as a palliative treatment.

## 7. Hematogenous dissemination

Hematogenous recurrence can affect the brain, lungs, liver, and bone (Figure 6).

### 7.1. Lung

The incidence of pulmonary metastasis for patients with endometrial cancer ranges from 2.3% to 7%. Stage IV disease and myometrial invasion exceeding 50% are the strongest predictors of lung failure. Nodules are frequently multiple and bilateral, but a solitary nodule may also occur.

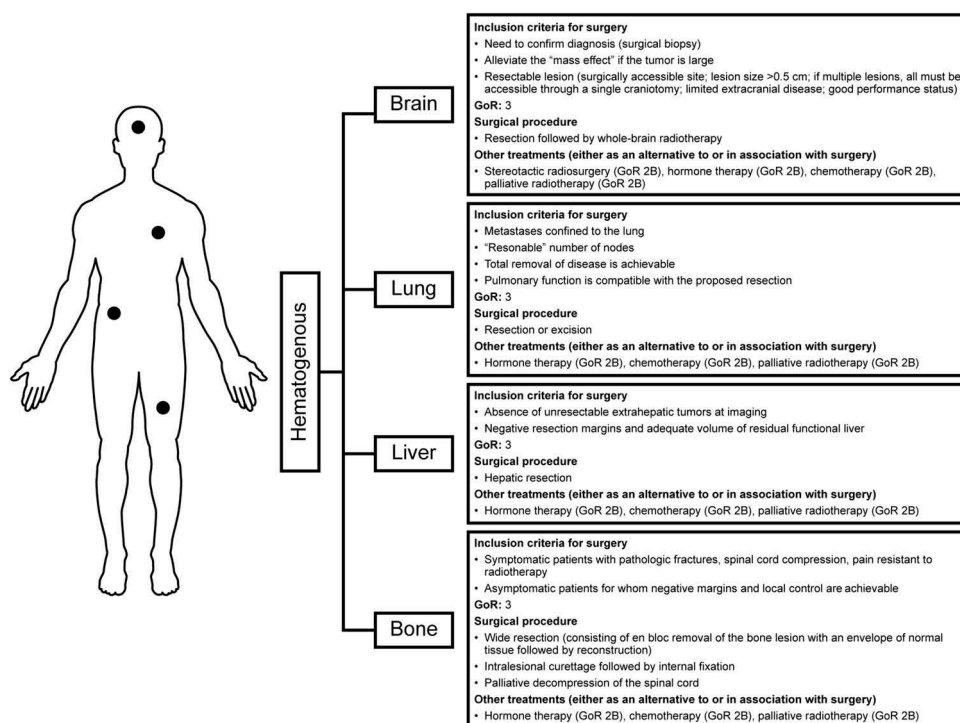
With lung metastases, the prognosis is generally poor. However, hematogenous dissemination to the lungs tends to occur in elderly patients with low-grade tumors; this finding might indicate a spectrum of tumor behavior, with lung metastasis indicating less-aggressive behavior compared with tumors having hematogenous dissemination to other sites [45]. Criteria for determining eligibility for surgical resection of pulmonary metastases are shown in the Box 1.

From the literature, predictors of survival in patients with isolated lung metastases are length of the disease-free interval and number of cancerous pulmonary nodes. In a series of 28 cases from Mayo Clinic, the following characteristics predicted favorable outcome: grade 1 or 2 tumors, greatest diameter of pulmonary nodule  $\leq 2$  cm, nonchemotherapy treatment, and estrogen receptor-positive status. Although chemotherapy was associated with reduced survival, outcomes were similar among patients treated with surgical resection vs. those receiving progestational therapy. Considering the most favorable risk:

**Box 1.** Criteria for determining eligibility for surgical resection of pulmonary metastases.

- (1) The primary tumor site should be free of disease
- (2) Metastases should be confined to the lungs
- (3) Total removal of disease must be feasible (the absolute number of metastases per se is not discriminatory)
- (4) Chemotherapy or hormonal therapy will not be curative, and other more effective therapies are unavailable
- (5) The patient can tolerate surgical therapy, and pulmonary function is compatible with the proposed resection
- (6) Total removal of all disease must be possible

(Adapted from Dresler and Goldberg. Surgical management of lung metastases: selection factors and results. *Oncology* [Williston Park]. 1996 May;10 [5]:649–55. Used with permission.)



**Figure 6.** Summary of surgical options, inclusion criteria, recommendation grade, and other treatments for hematogenous recurrences. Abbreviations are defined in the Figure 3 legend.

benefit ratio of administration of progestational therapy vs. thoracotomy, hormonal therapy is a reasonable consideration, at least as a first-line treatment for patients with low-grade tumors [25]. Little data are available in the literature about the role of stereotactic radiosurgery in primary lung cancer, and even less is available regarding its role in metastatic or recurrent gynecologic cancer. For this reason, no conclusions can be drawn about its efficacy and long-term effects [46].

## 7.2. Bone

Bone metastases in endometrial cancer are less common, with an overall incidence rate less than 1%. The spine and hip are the most common sites of osseous dissemination, and the 5-year survival rate after diagnosis of bone dissemination is extremely poor (1%) in the setting of recurrent disease. However, the prognosis is better when bone metastases are discovered at presentation [26].

No consensus exists on the best elective treatment of bone metastases, and multimodal therapies are usually administered. Surgery can be considered for patients with impending or existing pathologic fractures, spinal cord compression, and pain, especially in the setting of resistance to radiotherapy. Surgical options include (i) wide resection (consisting of en bloc removal of the bone lesion with an envelope of normal tissue, followed by reconstruction); (ii) intralesional curettage followed by internal fixation; and (iii) palliative decompression of the spinal cord [47].

Although surgical excision of the metastasis is an option, little in the literature describes the impact of this treatment on

survival. Thus, no definite conclusions can be drawn, and multimodal therapies are usually required.

## 7.3. Brain

Brain metastases in patients with endometrial cancer are rare (estimated prevalence, 0.86%). Prognosis is poor, and the median overall survival after diagnosis is 6.5 months (Uccella S, Morris JM, Multinu F, Cliby WA, Podratz KC, Gostout BC, Dowdy SC, Ghezzi F, Makdisi PB, Keeney GL, Link MJ, Mariani A, unpublished data). Because of the low prevalence of brain metastasis, radiologic examination of the brain is not universally recommended for patients with endometrial cancer. Diagnosis is usually established by imaging tests after the onset of symptoms (e.g. limb paresis, refractory headache).

During the past decade, we have observed a controversial evolution in the treatment of brain metastasis. Previously, surgical resection followed by whole-brain radiotherapy (WBRT) was considered the best treatment for a solitary metastasis [48]. Moreover, WBRT was used in all patients with brain metastases, independent of the number of metastases. However, because of its detrimental effects on cognition and quality of life, during the past few years, the role of WBRT has been questioned, and some have suggested stereotactic radiosurgery to treat patients with limited brain metastasis [49]. Furthermore, a recent multi-center prospective study concluded that stereotactic radiosurgery alone should be considered in patients with up to 5–10 brain metastases [50]. In contrast, other authors still recommend WBRT with surgical resection in patients with good performance status and limited extracranial disease



[23,51]. Thus, given the recent considerations, the role of the surgery now is limited to two main indications: (i) to confirm the diagnosis when it is in doubt and (ii) to alleviate the mass effect in patients with large tumors. The treatment of brain metastasis should be individualized on the basis of the burden of disease at diagnosis and by considering how to minimize cognitive dysfunction and negative effects on quality of life, without affecting survival outcome.

#### 7.4. Liver and intra-abdominal organs

The most common intra-abdominal organ affected by hematogenous endometrial metastasis is the liver (7%), followed by the adrenal glands and the spleen (1%) [44]. Indications for hepatic resection of gynecologic tumors generally are the same as those for the resection of colorectal metastases: (i) the patient must be medically fit to undergo major abdominal surgery; (ii) unresectable extrahepatic tumors must not be visible with preoperative imaging; and (iii) grossly negative resection margins must be achievable while still leaving an adequate volume of functional liver.

Because most hepatic recurrences are generally associated with other distant disease [45], few reports have described hepatic metastases resection and splenectomy in the setting of recurrent endometrial cancer. Thus, no definitive conclusions can be drawn about the efficacy of the procedure in terms of survival. Also, multimodal therapy should be delivered after the procedure because occult microscopic systemic dissemination of the disease might be present [24].

### 8. Expert commentary

Treatment options for patients with recurrent endometrial cancer include radiotherapy, chemotherapy, hormonal therapy, and surgery, depending on the type and localization of the recurrence, patient functional status, presence of other associated disseminated disease, duration of the disease-free survival period, and the intent of the treatment itself (i.e. curative or palliative). Data from retrospective series suggest that surgery can be considered for select patients with recurrent endometrial cancer. The main factor to consider when evaluating a patient's eligibility for surgery is the feasibility of completely resecting the disease. Even if subsequent systemic treatments are administered after surgery, the prognostic factor with the greatest effect on survival rates is complete resection of the lesions (including resection of associated distant residual disease). Complete cytoreduction can be achieved in many patients with a single isolated metastasis (even at distant sites), but it may be more difficult to achieve in patients with diffuse intraperitoneal or retroperitoneal disease. Furthermore, because patients with recurrent endometrial cancer usually are affected by several comorbidities, an accurate preoperative evaluation must be undertaken to appropriately weigh the possible risks to the patient if radical surgery is planned. Quality of life should also be considered for the more radical procedures.

### 9. Five-year view

Our recommendation for surgery in recurrent endometrial cancer is mostly limited to patients with locoregional relapse, especially those who previously received radiotherapy. The surgical excision of disease located in other areas is often more dependent on physician preference or surgical skill than on evidence-based indications. In fact, some patterns of recurrence are extremely rare, and evidence-based recommendations do not exist. Ideally, the complete eradication of the disease at relapse should be achieved with minimal impact on the patient's quality of life. A multimodal approach that integrates highly skilled surgery, radiotherapy, and medical therapy can be considered; such an approach should also be investigated in future research. Tailoring adjuvant therapies to tumor and patient characteristics, possibly with molecular-based therapy, must be the goal of future research [52].

#### Key issues

- Endometrial cancer has 4 pathways of dissemination (contiguous, lymphatic, hematogenous, and peritoneal).
- The pattern of recurrence, patient functional status, and prior adjuvant treatment status are instrumental for defining the optimal management strategy and determining the need for surgery.
- If surgery is performed for recurrent endometrial cancer, the aim should be macroscopic complete resection.
- After local recurrence, surgical resection (pelvic exenteration) is indicated in operative candidates; usual candidates for exenteration are patients who previously received radiotherapy and present with isolated central local recurrence.
- In patients with retroperitoneal or intraperitoneal recurrence, cytoreductive surgery with maximum effort to no residual disease improves overall survival.
- Intraoperative radiotherapy may be useful in patients with retroperitoneal recurrence; in fact, recurrences affecting the large pelvic or para-aortic vessels are more likely to be excised, leaving microscopic or macroscopic residual disease.
- In distant recurrences (eg, bone, brain, lung, liver), surgical resection is feasible in select patients with limited disease; however, no evidence-based data suggesting improvement of survival are available.
- Morbidity rates and quality of life must always be considered before radical surgery is performed.
- Randomized trials in surgery for recurrent endometrial cancer are certainly needed but are difficult to perform; thus, a homogeneous case series of patients (homogenous in terms of patient characteristics, disease characteristics, and standardized uniform treatment) may help define the best treatment.

#### Acknowledgment

Francesco Multinu is a research fellow supported by the University of Cagliari, Italy.

## Declaration of interest

The authors have no relevant affiliations or financial involvement with any organization or entity with a financial interest in or financial conflict with the subject matter or materials discussed in the manuscript. This includes employment, consultancies, honoraria, stock ownership or options, expert testimony, grants or patents received or pending, or royalties.

## ORCID

Valentina Zanfagnin  <http://orcid.org/0000-0002-7703-7982>

## References

Papers of special interest have been highlighted as:

•of interest

••of special interest

- Siegel RL, Miller KD, Jemal A. Cancer statistics. *CA Cancer J Clin.* 2015 Jan-Feb;65(1):5–29. Epub 2015 Jan 5.
- Doll KM, Tseng J, Denslow SA, et al. High-grade endometrial cancer: revisiting the impact of tumor size and location on outcomes. *Gynecol Oncol.* 2014 Jan;132(1):44–49. Epub 2013 Oct 29.
- Creutzberg CL, Nout RA, Lybeert ML, et al. Fifteen-year radiotherapy outcomes of the randomized PORTEC-1 trial for endometrial carcinoma. *Int J Radiat Oncol Biol Phys.* 2011 Nov 15;81(4):e631–e638. Epub 2011 Jun 2.
  - **Synopsis: Portec 1 Trial, radiotherapy outcomes.**
- Epstein E, Blomqvist L. Imaging in endometrial cancer. *Best Pract Res Clin Obstet Gynaecol.* 2014 Jul;28(5):721–739. Epub 2014 Apr 30.
- Todo Y, Okamoto K, Hayashi M, et al. A validation study of a scoring system to estimate the risk of lymph node metastasis for patients with endometrial cancer for tailoring the indication of lymphadenectomy. *Gynecol Oncol.* 2007;104(3):623–628. Epub 2006 Nov 13.
- Kang S, Todo Y, Odagiri T, et al. A low-risk group for lymph node metastasis is accurately identified by Korean gynecologic oncology group criteria in two Japanese cohorts with endometrial cancer. *Gynecol Oncol.* 2013;129(1):33–37. Epub 2013 Jan 13.
- Zullo F, Falbo A, Palomba S. Safety of laparoscopy vs laparotomy in the surgical staging of endometrial cancer: a systematic review and metaanalysis of randomized controlled trials. *Am J Obstet Gynecol.* 2012 Aug;207(2):94–100. Epub 2012 Jan 13.
- Walker JL, Piedmonte MR, Spiratos NM, et al. Laparoscopy compared with laparotomy for comprehensive surgical staging of uterine cancer: gynecologic oncology group study LAP2. *J Clin Oncol.* 2009 Nov 10;27(32):5331–5336. Epub 2009 Oct 5.
- Wright JD, Burke WM, Wilde ET, et al. Comparative effectiveness of robotic versus laparoscopic hysterectomy for endometrial cancer. *J Clin Oncol.* 2012 Mar 10;30(8):783–791. Epub 2012 Jan 30.
- Yoon A, Yoo HN, Lee YY, et al. Robotic single-port hysterectomy, adnexectomy, and lymphadenectomy in endometrial cancer. *J Minim Invasive Gynecol.* 2015;22(3):322. Epub 2014 Dec 10.
- Koh WJ, Greer BE, Abu-Rustum NR, et al. Uterine neoplasms, version 1.2014. *J Natl Compr Canc Netw.* 2014 Feb;12(2):248–280.
  - **Synopsis: NCCN 2014 guidelines for cancer by site.**
- Del Carmen MG, Boruta DM, Schorge JO 2nd. Recurrent endometrial cancer. *Clin Obstet Gynecol.* 2011 Jun;54(2):266–277.
- Mariani A, Dowdy SC, Keeney GL, et al. High-risk endometrial cancer subgroups: candidates for target-based adjuvant therapy. *Gynecol Oncol.* 2004 Oct;95(1):120–126.
- Huh WK, Straughn JM Jr, Mariani A, et al. Salvage of isolated vaginal recurrences in women with surgical stage I endometrial cancer: a multiinstitutional experience. *Int J Gynecol Cancer.* 2007;17(4):886–889. Epub 2007 Feb 16.
- Colombo N, Preti E, Landoni F, et al. Endometrial cancer: ESMO clinical practice guidelines for diagnosis, treatment and follow-up. *Ann Oncol.* 2013 Oct;24(Suppl 6):vi33–vi38.
- Alberta Provincial Gynecologic Oncology Tumour Team. Endometrial cancer [Internet]. Edmonton (Alberta): CancerControl Alberta; 2013 Sep [cited 2016 Jan 4]. 15 p. (Clinical practice guideline; no. GYNE-002). Available from: <http://www.guideline.gov/content.aspx?id=47834>
- Westin SN, Rallapalli V, Fellman B, et al. Overall survival after pelvic exenteration for gynecologic malignancy. *Gynecol Oncol.* 2014;134(3):546–551. Epub 2014 Jul 9.
- Foot RL, Schray MF, Wilson TO, et al. Isolated peripheral lymph node recurrence of endometrial carcinoma. *Cancer.* 1988 Jun 15;61(12):2561–2565.
- Dowdy SC, Mariani A, Cliby WA, et al. Radical pelvic resection and intraoperative radiation therapy for recurrent endometrial cancer: technique and analysis of outcomes. *Gynecol Oncol.* 2006 May;101(2):280–286.
  - **Synopsis: use of IORT.**
- Barlin JN, Puri I, Bristow RE. Cytoreductive surgery for advanced or recurrent endometrial cancer: a meta-analysis. *Gynecol Oncol.* 2010 Jul;118(1):14–18.
  - **Synopsis: Meta-analysis.**
- Bakrin N, Cotte E, Sayag-Beaujard A, et al. Cytoreductive surgery with hyperthermic intraperitoneal chemotherapy for the treatment of recurrent endometrial carcinoma confined to the peritoneal cavity. *Int J Gynecol Cancer.* 2010 Jul;20(5):809–814.
- Papadia A, Bellati F, Ditto A, et al. Surgical treatment of recurrent endometrial cancer: time for a paradigm shift. *Ann Surg Oncol.* 2015;22(13):4204–4210. Epub 2015 Mar 17.
- Tsao MN, Rades D, Wirth A, et al. Radiotherapeutic and surgical management for newly diagnosed brain metastasis(es): an American Society for Radiation Oncology evidence-based guideline. *Pract Radiat Oncol.* 2012;2(3):210–225. Epub 2012 Jan 30.
- Knowles B, Bellamy CO, Oniscu A, et al. Hepatic resection for metastatic endometrioid carcinoma. *HPB (Oxford).* 2010 Aug;12(6):412–417.
- Dowdy SC, Mariani A, Bakkum JN, et al. Treatment of pulmonary recurrences in patients with endometrial cancer. *Gynecol Oncol.* 2007 Nov;107(2):242–247. Epub 2007 Sep 17.
- Uccella S, Morris JM, Bakkum-Gamez JN, et al. Bone metastases in endometrial cancer: report on 19 patients and review of the medical literature. *Gynecol Oncol.* 2013 Sep;130(3):474–482. Epub 2013 May 15.
- Creutzberg CL, van Putten WL, Koper PC, et al. Surgery and postoperative radiotherapy versus surgery alone for patients with stage-1 endometrial carcinoma: multicenter randomised trial. *Lancet.* 2000 Apr 22;355(9213):1404–1411.
  - **Synopsis: PORTEC 1, original trial.**
- Creutzberg CL, van Putten WL, Koper PC, et al. Survival after relapse in patients with endometrial cancer: results from a randomized trial. *Gynecol Oncol.* 2003 May;89(2):201–209.
- Abusaris H, Hoogeman M, Nuytens JJ. Re-irradiation: outcome, cumulative dose and toxicity in patients retreated with stereotactic radiotherapy in the abdominal or pelvic region. *Technol Cancer Res Treat.* 2012 Dec;11(6):591–597. Epub 2012 May 7.
- Tran PT, Su Z, Hara W, et al. Long-term survivors using intraoperative radiotherapy for recurrent gynecologic malignancies. *Int J Radiat Oncol Biol Phys.* 2007 Oct 1;69(2):504–511. Epub 2007 Jun 8.
- Morris M, Alvarez RD, Kinney WK, et al. Treatment of recurrent adenocarcinoma of the endometrium with pelvic exenteration. *Gynecol Oncol.* 1996 Feb;60(2):288–291.
- Barakat RR, Goldman NA, Patel DA, et al. Pelvic exenteration for recurrent endometrial cancer. *Gynecol Oncol.* 1999 Oct;75(1):99–102.
- Magrina JF, Stanhope CR, Weaver AL. Pelvic exenterations: supravaginal, infralevator, and with vulvectomy. *Gynecol Oncol.* 1997 Jan;64(1):130–135.
  - **Synopsis: Pelvic exenteration: definition and techniques.**
- Ang C, Bryant A, Barton DP, et al. Exenterative surgery for recurrent gynaecological malignancies. *Cochrane Database Syst Rev.* 2014 Feb;4(2):CD010449.
- Symmonds RE, Pratt JH, Webb MJ. Exenterative operations: experience with 198 patients. *Am J Obstet Gynecol.* 1975 Apr 1;121(7):907–918.
- Rutledge FN, Smith JP, Wharton JT, et al. Pelvic exenteration: analysis of 296 patients. *Am J Obstet Gynecol.* 1977 Dec 15;129(8):881–892.
- Goldberg GL, Sukumvanich P, Einstein MH, et al. Total pelvic exenteration: the Albert Einstein College of Medicine/Montefiore

- Medical Center Experience (1987 to 2003). *Gynecol Oncol.* 2006 May;101(2):261–268. Epub 2006 Jan 19.
38. Maggioni A, Roviglione G, Landoni F, et al. Pelvic exenteration: ten-year experience at the European Institute of Oncology in Milan. *Gynecol Oncol.* 2009;114(1):64–68. Epub 2009 May 2.
  39. Sharma S, Odunsi K, Driscoll D, et al. Pelvic exenterations for gynecological malignancies: twenty-year experience at Roswell Park Cancer Institute. *Int J Gynecol Cancer.* 2005 May-Jun;15(3):475–482.
  40. Shingleton HM, Soong SJ, Gelder MS, et al. Clinical and histopathologic factors predicting recurrence and survival after pelvic exenteration for cancer of the cervix. *Obstet Gynecol.* 1989 Jun;73(6):1027–1034.
  41. Benn T, Brooks RA, Zhang Q, et al. Pelvic exenteration in gynecologic oncology: a single institution study over 20 years. *Gynecol Oncol.* 2011;122(1):14–18. Epub 2011 Mar 27.
  42. Penalver MA, Angioli R, Mirhashemi R, et al. Management of early and late complications of ileocolonic continent urinary reservoir (Miami pouch). *Gynecol Oncol.* 1998 Jun;69(3):185–191.
  43. Brown KG, Koh CE, Vasilaras A, et al. Clinical algorithms for the diagnosis and management of urological leaks following pelvic exenteration. *Eur J Surg Oncol.* 2014 Jun;40(6):775–781. Epub 2013 Oct 18.
  44. Sohaib SA, Houghton SL, Meroni R, et al. Recurrent endometrial cancer: patterns of recurrent disease and assessment of prognosis. *Clin Radiol.* 2007 Jan;62(1):28–34.
  45. Mariani A, Webb MJ, Keeney GL, et al. Hematogenous dissemination in corpus cancer. *Gynecol Oncol.* 2001 Feb;80(2):233–238.
  46. Kunos CA, Spelic M. Role of stereotactic radiosurgery in gynecologic cancer. *Curr Opin Oncol.* 2013 Sep;25(5):532–538.
  47. Ji T, Eskander R, Wang Y, et al. Can surgical management of bone metastases improve quality of life among women with gynecologic cancer? *World J Surg Oncol.* 2014 Aug;5(12):250.
  48. Patchell RA, Tibbs PA, Regine WF, et al. Postoperative radiotherapy in the treatment of single metastases to the brain: a randomized trial. *JAMA.* 1998 Nov 4;280(17):1485–1489.
  49. Sahgal A, Larson D, Knisely J. Stereotactic radiosurgery alone for brain metastases. *Lancet Oncol.* 2015 Mar;16(3):249–250.
  50. Yamamoto M, Serizawa T, Shuto T, et al. Stereotactic radiosurgery for patients with multiple brain metastases (JLGK0901): a multi-institutional prospective observational study. *Lancet Oncol.* 2014;15(4):387–395. Epub 2014 Mar 10.
  51. Bhangoo SS, Linskey ME, Kalkanis SN. Congress of Neurologic Surgeons (CNS). Evidence-based guidelines for the management of brain metastases. *Neurosurg Clin N Am.* 2011 Jan;22(1):97–104.
  52. Gadducci A, Tana R, Cosio S, et al. Molecular target therapies in endometrial cancer: from the basic research to the clinic. *Gynecol Endocrinol.* 2008 May;24(5):239–249.