



CASE REPORT

Open Access



Arthrogryposis multiplex congenita with maxillofacial involvement: a case report

Stefano Cirillo¹, Daniele Regge², Umberto Garagiola^{3*} , Alessandro Tortarolo⁴, Giuseppe Carlo Iorio⁵, Orges Spahiu⁴ and Maria Grazia Piancino⁴ 

Abstract

Background Arthrogryposis multiplex congenita is a rare condition that mainly involves the lower limbs, characterized by severe joint deformity and contracture, muscular atrophy, and functional impairment. Its clinical manifestations are heterogenous and may involve the maxillofacial district as well.

Case presentation This case report describes a 20-year-old patient with arthrogryposis multiplex congenita with skeletal crossbite, facial asymmetry, reduced mouth opening and absence of lateral mandibular movement on the left side. After clinical evaluation, the following exams were required: postero-anterior cephalometric tracing, head and neck electromyography, computerized axiography, computed tomography scan, and maxillofacial magnetic resonance imaging. Orthognathodontic evaluation indicated skeletal asymmetry, reduced condylar movements on the left side and abnormally low electromyography activity of the masticatory muscles on the left side. Computed tomography and magnetic resonance imaging revealed unilateral left mandibular hypoplasia, hypotrophy, and fatty infiltration of masticatory muscles on the left side, as well as immobility of the left condyle during mouth opening, and hypoplasia of the left articular disk, which was however not displaced. Surgery was not indicated and conservative orthognathodontic treatment with function generating bite was suggested to balance the occlusal plane, as well as stretching exercises.

Conclusions A rare case of arthrogryposis multiplex congenita with maxillofacial involvement illustrates that a patient-centred, multidisciplinary approach with accurate diagnosis is required to formulate the best treatment plan. Because of the considerable damage to the masticatory muscles, conservative orthognathodontic therapy may be the best treatment option.

Keywords Congenital multiple arthrogryposis, Musculoskeletal abnormality, Spiral computed tomography, Imaging magnetic resonance, Malocclusion, Temporomandibular joint, Craniomandibular disorder, Function generating bite

*Correspondence:

Umberto Garagiola
umberto.garagiola@unimi.it

¹ Department of Radiology, Mauriziano Umberto I Hospital, Turin, Italy

² Department of Surgical Sciences, University of Turin, Turin, Italy

³ Department of Biomedical Surgical and Dental Sciences Maxillo-Facial and Odontostomatology Unit, School of Orthodontics Fondazione IRCCS Ca' Granda Ospedale Maggiore Policlinico, University of Milan, Milan, Italy

⁴ Department of Surgical Sciences, Dental School, University of Turin, Turin, Italy

⁵ Department of Oncology, University of Turin, Turin, Italy

Background

Arthrogryposis multiplex congenita (AMC) is a rare form of arthrogryposis, characterized by congenital, non-progressive, and symmetric joint contractures that involve at least two different body areas; both upper and lower limbs are usually involved [1]. It is a heterogeneous condition, with many different forms described in the literature [2]. In this disease, severe limitation of joint motion is frequently associated with a vicious attitude in flexion or hyperextension. As time goes on, deformities with contractures and dislocations worsen, accompanied by atrophy or absence of muscular mass [3].

The incidence of AMC is variably reported to be between 1/3000 and 1/10000 births. Statistical variability is due to the different criteria adopted in defining the disease, which may be easily confused with other syndromes. Involvement of the cranium and maxillofacial region has been observed in 22–24% of cases of arthrogryposis [4], and a reduction of mandibular opening has been observed in 13–25% of those cases [5].

AMC usually occurs sporadically, but different patterns of inheritance have been described, as well as more than 200 genes associated with this disease; however, the molecular mechanism of AMC is not known [2]. Arthrogryposis may be determined by a reduction of articular mobility during intrauterine life (fetal crowding), general connective tissue disorders, neurological disorders, myopathy, intrauterine vascular accidents, or changes in fetal environment (oligohydramnios) [6]. Reduction and fatty replacement of the muscular mass is frequently encountered in this syndrome, and changes of the corresponding spinal metameres, along with reduced anterior horn cell size and number, have been described [7].

Case presentation

A 20-year-old patient with AMC was referred to the Orthodontics Department, University of Turin, for temporomandibular joint (TMJ) surgical evaluation. Informed consent was obtained from the patient.

Prior to TMJ evaluation, the patient was diagnosed with AMC, involving mainly the lower limbs and the maxillofacial district, with severe mandibular hypomobility. The patient had undergone different surgical procedures, including right knee extension, left hip extension and left achillotenotomy, followed by cycles of physiotherapy and functional re-education. These treatments were partially successful in correcting the lower limb deformities.

At visual inspection, the patient showed macroscopic facial asymmetry, mostly on the left side, and a severe dental and skeletal crossbite of the right hemiarch with relevant functional impairment. Clinical examination showed a reduced maximum opening of the mouth (29 mm) with deviation towards the left side. Lateral excursion of the mandible towards the right side was normal (11 mm), while on the left side it was completely impaired (0 mm).

To investigate the extent of the functional impairment, the following instrumental examinations were performed:

- a) Postero-anterior (PA) cephalometry, showing a severe mandibular asymmetry with deviation of the medial line towards the right side.
 - b) Computerized axiography, performed with a Condylolomp LR3 (Dentron GmbH, Wurzburg, Germany), indicating that the protrusive and the maximal opening paths showed limitation in extension with a good repeatability on the right side, while on the left side there was total movement blockage.
 - c) Electromyography, performed with an electromyograph K6-1 (Myo-Tronics Inc., Seattle, WA-USA). According to Jankelson test I (at rest) an increase of the value of the superior trapezius was observed while the remaining muscles showed physiological values. In test II (maximum clenching) extremely reduced values for the left anterior temporal and masseter muscles were observed and were not modified by the interposition of cotton rolls between the dental arches; the muscles on the right side contracted normally.
- Having found a severe functional impairment on the left side of the mandible, imaging with spiral computed tomography (SCT) and magnetic resonance imaging (MRI) were considered to assess the morphology of the TMJ and the masticatory muscles:
- d) Spiral CT was performed with helical scans in the axial position from the chin tip to the cranium vertex. Slice thickness was 3 mm, reconstruction gap 1 mm. The scans obtained were sent to a Workstation (3.1 Advantage Windows, GE Medical Systems) for 3D reconstruction. Computed tomography (CT) did not show significant anomalies of the condylar structures. On the other hand, significant underdevelopment of the left hemimandible was observed (Fig. 1). Furthermore, there was a serious atrophy with fat substitution of the following muscles: left internal and external pterygoid, left masseter, and left anterior temporalis (Fig. 2).
 - e) MRI was performed with a Sigma 1.5 MR Unit (General Electric Medical, Milwaukee, Wisc.) to evaluate disk morphology and position, and TMJ mobility. Condylar asymmetry was observed, as the left structure appeared smaller and on a different angle compared to the contralateral. On the left side, anterior tubercle of the temporal bone was less pronounced, the articular cavity was shallow and the coronoid process slightly hypertrophic (Fig. 3). Functional impairment with complete absence of movements of the left condyle during the opening was evident. The articular disk was hypotrophic but it was in a physiological position. There was no disk displacement during mouth opening. MRI confirmed the serious atrophy of the left masticatory muscles, associated with

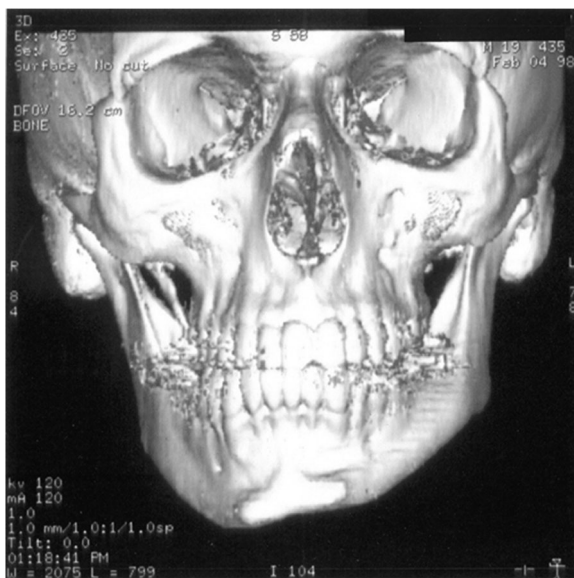


Fig. 1 Computed tomography (CT) with 3D reconstruction. The facial asymmetry is due to the underdevelopment of the left side of the mandible

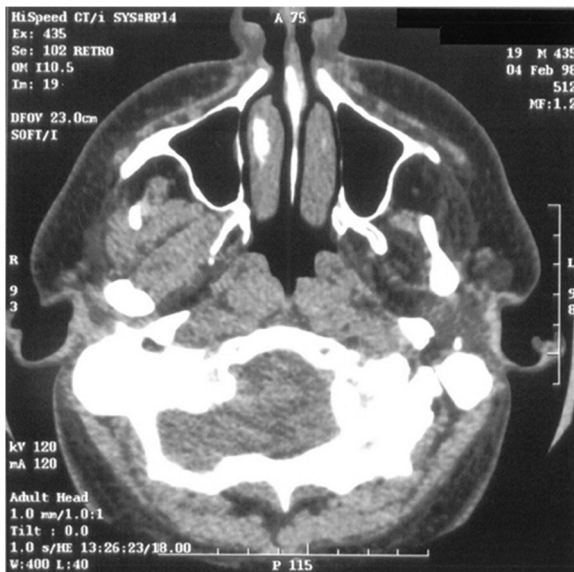

Fig. 2 CT scans. The severe atrophy with fat substitution of the left internal and external pterygoid, left masseter and left anterior temporalis muscles is evident

hyperintense signal in the T1-weighted scans due to fatty infiltration (Fig. 4).

The case of AMC described in this paper is of special interest, due to the rarity of the maxillofacial involvement

in this disease. The MRI and Spiral CT with 3D reconstruction underlined the value of imaging techniques in the diagnosis and the evaluation of the extent of damage in this disease [8–10]. The treatment of AMC with facial involvement is still controversial. Options include forcible stretching of the hypoplastic masticatory muscles, aimed at improving articular function, and TMJ surgery with bilateral coronoidectomy [11, 12]. Table 1 reports a summary of previously published case-reports of AMC with oral involvement and their treatments [4, 11, 13–16].

To assess the most appropriate therapeutical strategy, the patient was evaluated with both orthognathodontic examinations and imaging. Cephalometry, axiography, and electromyography were able to clearly identify the functional impairment but could not give an explanation for the immobility of the left TMJ. Therefore, orthognathodontic evaluation alone would not have been sufficient to formulate a treatment plan.

A more sophisticated investigation of mandibular morphology and masticatory muscles condition was obtained with both CT with 3D reconstruction and MRI of the maxillofacial region. CT showed significant hypoplasia of the left hemimandible (Fig. 1). Both CT and MRI were able to clearly indicate muscular damage on the left side: indeed, the anterior temporalis, masseter, internal and external pterygoid muscles appeared seriously atrophic with almost complete fat substitution (Figs. 2 and 4). Furthermore, maxillofacial MRI confirmed complete immobility of the left condyle (Fig. 3). The articular disk appeared hypoplastic but collocated in a physiological position.

Imaging with CT and MRI made it possible to establish that the left TMJ locking and hypoplasia of the left hemimandible were due to severe muscular pathology, information that was crucial to choose the correct treatment plan. In such conditions, the patient would not have benefited from surgery [17–20]. A more conservative treatment was suggested with functional appliances as function generating bite (FGB) to balance as much as possible the occlusal plane [21–24], knowing that it was not possible to correct the crossbite due to the absence of muscular force on the left side resulting in bone hypoplasia. Some benefits could come from stretching exercises, knowing again that it could not be a resolving therapy [25–28].

Conclusions

Diagnosis of arthrogyposis is based on clinical examination and molecular studies. Instrumental investigations generally do not show any significant alterations.

Long-term orthopedic management and physiotherapy is required. Physiotherapy soon after birth is helpful in mobilizing joints and preventing disuse atrophy. Sometimes surgical procedures are required.

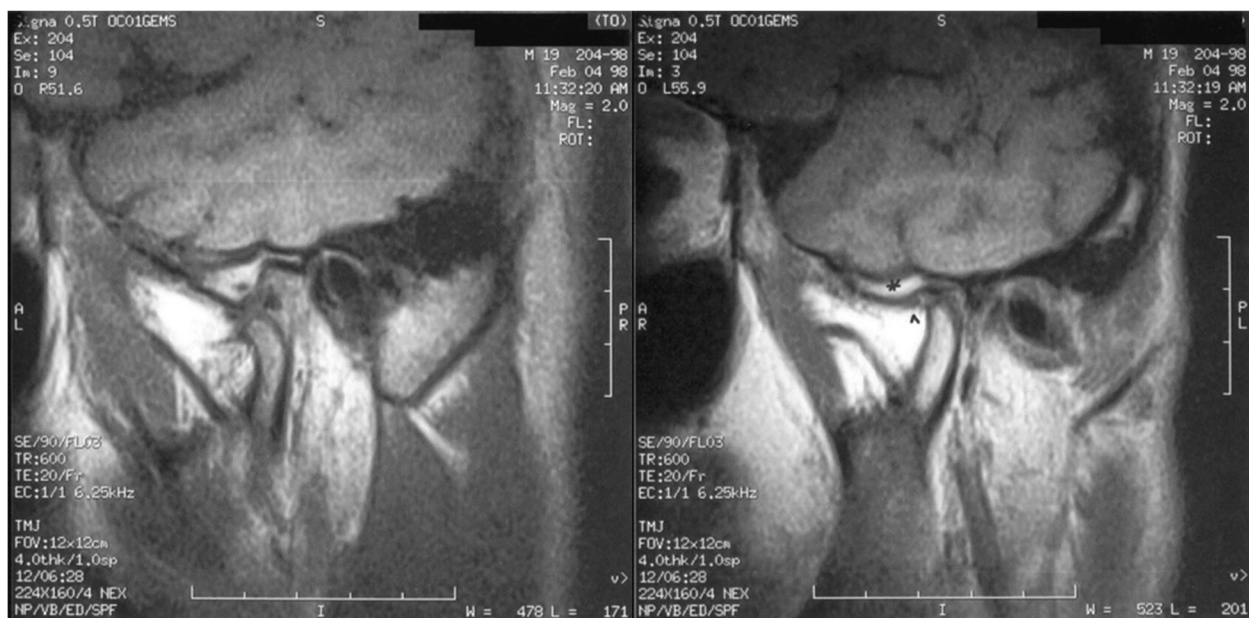


Fig. 3 Magnetic resonance imaging (MRI) sagittal T1 weighted scans. **a** right temporomandibular joint (TMJ), open mouth: physiologic joint with normal condylar excursion. **b** left TMJ, open mouth: notice a less pronounced anterior tubercle of the temporal bone and a shallow articular cavity (*); the articular disk is hypoplastic (^); complete condyle immobility is evident

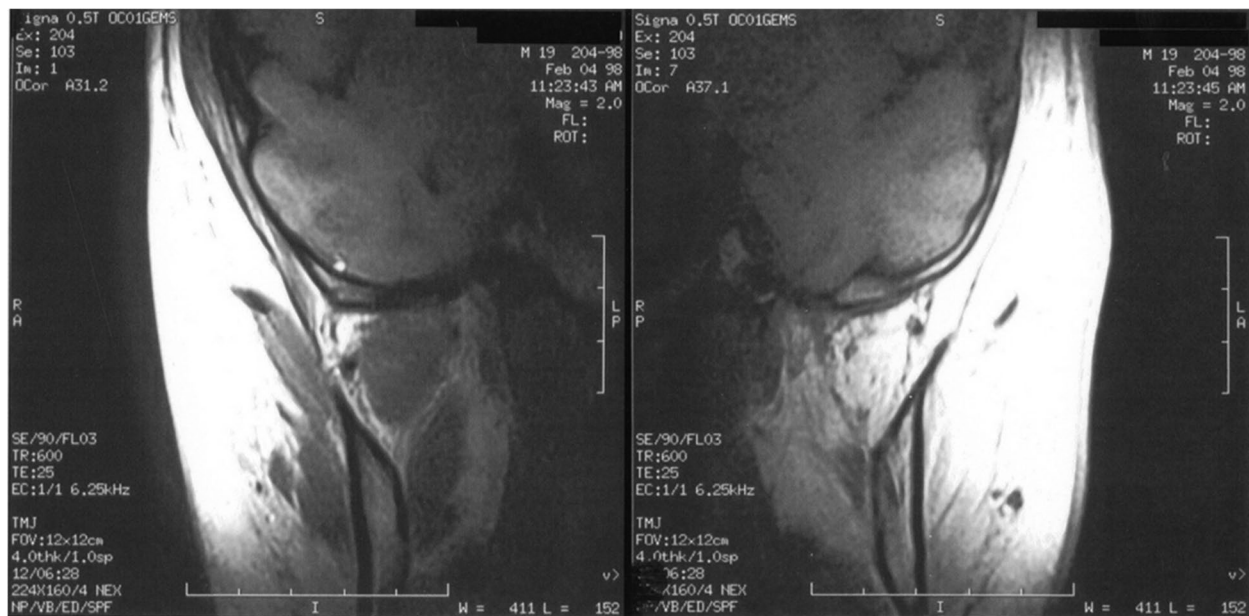

Fig. 4 MRI coronal T1-weighted scans. **a** Right side: the masticatory muscles appear normal. **b** Left side: masticatory muscles appear severely hypotrophic

Treatment of AMC is multidisciplinary and patient-specific, aimed at restoring mobility, ambulation, and the ability to care for oneself. However, in the case of severe maxillofacial involvement, steps should be taken

in order to fully investigate the extent of the limitations imposed by the disease on orofacial functions, and to choose the therapeutic means best suited to the specific clinical situation.

Table 1 Previously published case-reports of maxillo-facial management of adult AMC patients with TMJ involvement and reduced mouth opening (adapted from Bénard et al. 2021 [13])

Reference	Clinical presentation	Treatment	Outcome
Epstein et Wittenberg, 1987 [11]	Reduced mouth opening; right TMJ pain	Surgical (bilateral coronoidectomy and left condylectomy); physical therapy	Improved mouth opening; reduced pain
Hodgson et al. 1988 [4]	Reduced mouth opening (22mm); no protrusion or lateral excursion	Surgical (left condylectomy); physical therapy	Improved mouth opening (+ 8 mm)
Thomas et al. 2001 [14]	Reduced mouth opening (9mm)	Surgical (bilateral coronoidectomy and meniscectomy, lateral pterygoid myotomy, capsular release); physical therapy	Improved mouth opening (+ 9 mm)
Kargel et al. 2007 [15]	Reduced mouth opening (25mm), anterior open bite	Surgical (bilateral coronoidectomy, orthognathic surgery); orthodontic	Improved mouth opening (+ 6 mm), correction of anterior open bite
Nordone et al. 2010 [16]	Reduced mouth opening (15mm), no protrusion or lateral excursion	Physical therapy; surgical (bilateral coronoidectomy, condylectomy, TMJ arthroplasty and arthrotomy with osteodistraction)	Improved mouth opening (+ 10 mm)
Bénard et al. 2021 [13]	Reduced mouth opening (3mm)	Surgical (bilateral coronoidectomy and TMJ arthroplasty); physical therapy	Improved mouth opening (+ 14 mm)

TMJ temporomandibular joint

This case report highlights the importance of a multi-disciplinary approach to the treatment of rare diseases, especially when presenting with unusual features. The treatment of choice should be tailored to the individual patient, after a meticulous diagnostic process. In selected cases, AMC patients with maxillofacial involvement may benefit from conservative orthognathodontic therapy.

Competing interests

The authors declare that they have no competing interests.

Received: 12 November 2022 Accepted: 25 January 2023
Published online: 08 February 2023

Abbreviations

- AMC Arthrogryposis multiplex congenita
- CT Computed tomography
- FGB Function generating bite
- MRI Magnetic resonance imaging
- PA Postero-anterior
- SCT Spiral computed tomography
- TMJ Temporomandibular joint

Authors' contributions

MGP and GCI conceptualization, supervision, writing—reviewing, and editing; UG supervision, writing—reviewing, and editing; SC and DR investigation, resources, visualisation, and writing—original draft preparation; AT and OS methodology and writing—original draft preparation. All authors read and approved the final manuscript.

Funding

Not applicable.

Availability of data and materials

Not applicable.

Declarations

Ethics approval and consent to participate

Not applicable.

Consent for publication

Written informed consent was obtained from the participant.

References

1. Hall JG (1997) Arthrogryposis multiplex congenita: etiology, genetics, classification, diagnostic approach, and general aspects. *J Pediatric Orthop B* 6:159–166
2. Ma L, Xuerong Y (2017) Arthrogryposis multiplex congenita: classification, diagnosis, perioperative care, and anesthesia. *Frontiers Med* 11:48–52. <https://doi.org/10.1007/s11684-017-0500-4>
3. Hageman G, Willemse J (1983) Arthrogryposis multiplex congenita - review with comment. *Neuropediatrics* 14:6–11. <https://doi.org/10.1055/s-2008-1059546>
4. Hodgson P, Weinberg S, Consky C (1988) Arthrogryposis multiplex congenita of the temporomandibular joint. *Oral Surg Oral Med Oral Pathol* 65:289–291. [https://doi.org/10.1016/0030-4220\(88\)90111-9](https://doi.org/10.1016/0030-4220(88)90111-9)
5. Steinberg B, Nelson VS, Feinberg FE, Calhoun C (1996) Incidence of maxillofacial involvement in arthrogryposis multiplex congenita. *J Oral Maxillofac Surg* 54:956–959. [https://doi.org/10.1016/s0278-2391\(96\)90391-2](https://doi.org/10.1016/s0278-2391(96)90391-2)
6. Wynne-Davies R, Williams PF, O'Connor JC (1981) The 1960's epidemic of arthrogryposis multiplex congenita: a survey from the United Kingdom, Australia, and the United States of America. *J Bone Joint Surg (Br)* 63-B:76–82. <https://doi.org/10.1302/0301-620X.63B1.7204479>
7. Horopian DS, Yoon JJ (1988) Neuropathic arthrogryposis multiplex congenita and intrauterine ischemia of anterior horn cells: a hypothesis. *Clin Neuropathol* 7:285–293
8. Hageman G, Vette JK, Willemse J (1983) A case of asymmetrical arthrogryposis—a clinical study and a preliminary report on the value of CT-scanning. *Brain Dev* 5:407–413. [https://doi.org/10.1016/s0387-7604\(83\)80046-1](https://doi.org/10.1016/s0387-7604(83)80046-1)
9. Roscam Abbing PJ, Hageman G, Willemse J (1985) CT-scanning of skeletal muscle in arthrogryposis multiplex congenita. *Brain Dev* 7:484–491. [https://doi.org/10.1016/s0387-7604\(85\)80114-5](https://doi.org/10.1016/s0387-7604(85)80114-5)

10. Termote JL, Baert A, Crolla D, Palmers Y, Bulcke JA (1980) Computed tomography of the normal and pathologic muscular system. *Radiology* 137:439–444. <https://doi.org/10.1148/radiology.137.2.7433677>
11. Epstein JB, Wittenberg GJ (1987) Maxillofacial manifestation and management of arthrogryposis: literature review and case report. *J Oral Maxillofac Surg* 45:274–279. [https://doi.org/10.1016/0278-2391\(87\)90129-7](https://doi.org/10.1016/0278-2391(87)90129-7)
12. Thompson GH, Bilenker RM (1985) Comprehensive management of arthrogryposis multiplex congenita. *Clin Orthop Relat Res* 194:6–14
13. Bénard M, Sesqué A, Barthélémy I, Depeyre A (2021) Arthrogryposis multiplex congenita and limitation of mouth opening: presentation of a case and review of the literature. *J Stomatol Oral Maxillofac Surg* 122:101–106. <https://doi.org/10.1016/j.jormas.2020.05.017>
14. Thomas JA, Chiu-Yeh M, Moriconi ES (2001) Maxillofacial implications and surgical treatment of arthrogryposis multiplex congenita. *Compend Contin Educ Dent* 22:588–592
15. Kargel JS, Dimas VM, Chang P (2007) Orthognathic surgery for management of Arthrogryposis multiplex Congenita: case report and review of the literature. *Can J Plast Surg* 15:53–55. <https://doi.org/10.1177/229255030701500109>
16. Nordone TP, Li P (2010) Arthrogryposis multiplex congenita in association with bilateral temporomandibular joint hypomobility: report of a case and review of literature. *J Oral Maxillofac Surg* 68:1197–1204. <https://doi.org/10.1016/j.joms.2008.12.016>
17. Frongia G, Ramieri G, De Biase C, Bracco P, Piacino MG (2013) Changes in electric activity of masseter and anterior temporalis muscles before and after orthognathic surgery in skeletal class III patients. *Oral Surg Oral Med Oral Pathol Oral Radiol* 116:398–401. <https://doi.org/10.1016/j.oooo.2013.06.008>
18. Piacino MG, Cannavale R, Dalmaso P, Tonni I, Filipello F, Perillo L et al (2015) Condylar asymmetry in patients with juvenile idiopathic arthritis: could it be a sign of a possible temporomandibular joints involvement? *Semin Arthritis Rheum* 45:208–213. <https://doi.org/10.1016/j.semarthrit.2015.04.012>
19. Kim D-W, Jo Y-Y, Garagiola U, Choi J-Y, Kang Y-J, Oh J-H et al (2020) Increased level of vascular endothelial growth factors by 4-hexylresorcinol is mediated by transforming growth factor- β 1 and accelerates capillary regeneration in the burns in diabetic animals. *Int J Mol Sci* 21:3473. <https://doi.org/10.3390/ijms21103473>
20. Moro A, Gasperini G, Foresta E, Saponaro G, Falchi M, Cardarelli L et al (2017) Alveolar ridge split technique using piezosurgery with specially designed tips. *Biomed Res Int* 2017:4530378. <https://doi.org/10.1155/2017/4530378>
21. Piacino MG, Talpone F, Dalmaso P, Debernardi C, Lewin A, Bracco P (2006) Reverse-sequencing chewing patterns before and after treatment of children with a unilateral posterior crossbite. *Eur J Orthod* 28:480–484. <https://doi.org/10.1093/ejo/cjl014>
22. Piacino MG, Falla D, Merlo A, Vallelonga T, de Biase C, Dalessandri D et al (2016) Effects of therapy on masseter activity and chewing kinematics in patients with unilateral posterior crossbite. *Arch Oral Biol* 67:61–67. <https://doi.org/10.1016/j.archoralbio.2016.03.013>
23. Piacino MG, Comino E, Talpone F, Vallelonga T, Frongia G, Bracco P (2012) Reverse-sequencing chewing patterns evaluation in anterior versus posterior unilateral crossbite patients. *Eur J Orthod* 34:536–541. <https://doi.org/10.1093/ejo/cjr109>
24. Piacino MG, Cordero-Ricardo M, Cannavale R, Vallelonga T, Garagiola U, Merlo A (2017) Improvement of masticatory kinematic parameters after correction of unilateral posterior crossbite: reasons for functional retention. *Angle Orthod* 87:871–877. <https://doi.org/10.2319/020917-98.1>
25. Guimarães AS, Nagahashi Marie SK (2005) Dominant form of arthrogryposis multiplex congenita with limited mouth opening: a clinical and imaging study. *J Orofac Pain* 19:82–88
26. Farronato G, Garagiola U, Carletti V, Cressoni P, Bellintani C (2010) Psoriatic arthritis: temporomandibular joint involvement as the first articular phenomenon. *Quintessence Int* 41:395–398
27. Sidebottom Andrew J (2013) Management of recurrent ankylosis in arthrogryposis: new solutions to a rare problem. *Br J Oral Maxillofac Surg* 51:256–258. <https://doi.org/10.1016/j.bjoms.2012.05.002>
28. Naini FB, Cobourne MT, Garagiola U, McDonald F, Wertheim D (2016) Nasofacial angle and nasal prominence: a quantitative investigation of

idealized and normative values. *J Craniomaxillofac Surg* 44:446–452. <https://doi.org/10.1016/j.jcms.2016.01.010>

Publisher's Note

Springer Nature remains neutral with regard to jurisdictional claims in published maps and institutional affiliations.

Submit your manuscript to a SpringerOpen[®] journal and benefit from:

- Convenient online submission
- Rigorous peer review
- Open access: articles freely available online
- High visibility within the field
- Retaining the copyright to your article

Submit your next manuscript at ► [springeropen.com](https://www.springeropen.com)
