Hypoxia-associated markers in the prognosis of oral canine melanoma

Veterinary Pathology

Hypoxia-associated prognostic markers in oral canine melanoma

Journal:	*Veterinary Pathology*
Manuscript ID	VET-23-FLM-0054.R4
Manuscript Type:	Full Length Manuscript
Date Submitted by the Author:	n/a
Complete List of Authors:	Gola, Cecilia; University of Turin, Veterinary Sciences Maniscalco, Lorella; University of Turin, Veterinary Sciences Iussich, Selina; University of Turin, Veterinary Sciences Olimpo, Matteo; University of Turin, Veterinary Sciences Martignani, Eugenio; University of Turin, Veterinary Sciences Accornero, Paolo; University of Turin, Veterinary Sciences MODESTO, PAOLA; ISTITUTO ZOOPROFILATTICO SPERIMENTALE DEL PIEMONTE, LIGURIA E VALLE D'AOSTA, Genetics and Immunobiochemistry Laboratory Morello, Emanuela; University of Turin, Veterinary Sciences Giacobino, Davide; University of Turin, Veterinary Sciences Mazzone, Eugenio; University of Turin, Veterinary Sciences Varello, Katia; ISTITUTO ZOOPROFILATTICO SPERIMENTALE DEL PIEMONTE, LIGURIA E VALLE D'AOSTA, Aresu, Luca; University of Turin, Veterinary Science DE MARIA, RAFFAELLA; University of Turin, Veterinary Sciences
Keywords:	mucosal melanomas, prognosis, canine, in vitro assay, cobalt chloride, hypoxia
Abstract:	Canine oral malignant melanoma (COMM) is the most common neoplasm in the oral cavity characterized by local invasiveness and high metastatic potential. Hypoxia represents a crucial feature of the solid tumor microenvironment promoting cancer progression and drug resistance. Hypoxia-inducible factor-1α (HIF-1α) and its downstream effectors vascular endothelial growth factor A (VEGF-A), GLUT1, C-X-C chemokine receptor type 4 (CXCR4) and carbonic anhydrase IX (CAIX) are the main regulators of the adaptive response to low oxygen availability. The prognostic value of these markers was evaluated in 36 COMMs using immunohistochemistry. Additionally, the effects of cobalt chloride-mediated hypoxia were evaluated in one primary COMM cell line. HIF-1α expression was observed in the nucleus, and this localization correlated with the presence or enhanced expression of HIF-1α -regulated genes at the protein level. Multivariate analysis revealed that in dogs given chondroitin sulfate proteoglycan-4 (CSPG4) DNA vaccine, COMMs expressing HIF-1α, VEGF-A, and CXCR4 were associated with a shorter disease-free intervals (DFI) compared to tumors that were negative for these markers (p=0.03), suggesting hypoxia can influence immunotherapy response. Western blotting showed that under

	chemically induced hypoxia, COMM cells accumulate HIF-1 α and smaller amounts of CAIX . HIF-1α induction and stabilization triggered by hypoxia was corroborated by immunofluorescence showing its nuclear translocation. These findings reinforce the role of a hypoxic microenvironment in tumor progression and patient outcome in COMM, as previously established in several human and canine cancers. Additionally, hypoxic markers may represent promising prognostic markers, highlighting opportunities for their use in therapeutic strategies for COMMs.

Hypoxia-associated markers in the prognosis of oral canine melanoma

Cecilia Gola[1,2], Lorella Maniscalco[2*], Selina Iussich[2], Emanuela Morello[2], Matteo Olimpo[2], Eugenio Martignani [2], Paolo Accornero[2], Davide Giacobino[2], Eugenio Mazzone[2], Paola Modesto[3], Katia Varello[3], Luca Aresu[2], Raffaella De Maria[2]

[1] Department of Pathology and Infectious Diseases, University of Surrey, Guildford, UK.

[2] Department of Veterinary Science, University of Turin, Grugliasco (TO), Italy

[3] Istituto Zooprofilattico del Piemonte Liguria e Valle d'Aosta (Italy)

*Corresponding author

lorella.maniscalco@unito.it

phone number +0039-011-6708968

fax number +0039-011-6709031

Address: Largo Braccini 2 10095 Grugliasco (Torino), Italy

ABSTRACT

Canine oral malignant melanoma (COMM) is the most common neoplasm in the oral cavity characterized by local invasiveness and high metastatic potential. Hypoxia represents a crucial feature of the solid tumor microenvironment promoting cancer progression and drug resistance. Hypoxia-inducible factor-1α (HIF-1α) and its downstream effectors vascular endothelial growth factor A (VEGF-A), GLUT1, C-X-C chemokine receptor type 4 (CXCR4) and carbonic anhydrase IX (CAIX) are the main regulators of the adaptive response to low oxygen availability. The prognostic value of these markers was evaluated in 36 COMMs using immunohistochemistry. Additionally, the effects of cobalt chloride-mediated hypoxia were evaluated in one primary COMM cell line. HIF-1α expression was observed in the nucleus, and this localization correlated with the presence or enhanced expression of HIF-1α - regulated genes at the protein level. Multivariate analysis revealed that in dogs given *chondroitin sulfate proteoglycan-4* (*CSPG4*) DNA vaccine, COMMs expressing HIF-1α, VEGF-A, and CXCR4 were associated with a shorter disease-free intervals (DFI) compared to tumors that were negative for these markers (p=0.03), suggesting hypoxia can influence immunotherapy response. Western blotting showed that under chemically induced hypoxia, COMM cells accumulate HIF-1 α and smaller amounts of CAIX . HIF-1α induction and stabilization triggered by hypoxia was corroborated by immunofluorescence showing its nuclear translocation. These findings reinforce the role of a hypoxic microenvironment in tumor progression and patient outcome in COMM, as previously established in several human and canine cancers. Additionally, hypoxic markers may represent promising prognostic markers, highlighting opportunities for their use in therapeutic strategies for COMMs.

Keywords: canine, cell culture, cobalt chloride, hypoxia, immunohistochemistry, oral melanoma , prognosis

Canine oral malignant melanoma (COMM) is the most frequent malignant oral tumor in dogs, accounting for 30-40% of all oral malignancies.[4] COMM is a solid tumor arising from neoplastic transformation of mucosal melanocytes, and is characterized by aggressive behavior, extensive local invasiveness, and metastatic potential, resulting in poor prognosis.[3,54]

Hypoxia represents one of the most crucial microenvironmental features in solid tumors[50] and has been associated with invasiveness, angiogenesis, vasculogenic mimicry, and response to therapy in several cancer types, including melanoma.[10,19] Hypoxia and subsequent acidification of the tumoral microenvironment are reported to promote cancer progression and drug resistance,[38] and contribute to immunotolerance of cancer cells, conferring resistance to immunotherapy.[1,11,15,24,48] Hypoxia-inducible factor-1α (HIF-1α) is the primary regulator of the adaptive response to low oxygen availability.[20,27] Upon stabilization and migration to the nucleus, HIF-1α acts as transcription factor for several hypoxia-regulating elements.Hypoxia-regulating elements, in turn, induce and modulate various processes, including glycolysis, angiogenesis, cell migration, invasion, metastasis, and chemoresistance.[11,43,49,50] Vascular endothelial growth factor A (VEGF-A) is a key effector of the hypoxic response, which stimulates angiogenesis that provides nutrients and oxygen to proliferating cancer cells.[35] Moreover, hypoxia stimulates cell homing and migration via chemokine-mediated stimuli. C-X-C chemokine receptor type 4 (CXCR4) is overexpressed in various

67 human cancers, including melanoma, and primarily contributes to tumor growth,
68 angiogenesis, metastasis, and therapeutic resistance.[8,31]
69 Cancer cells undergo metabolic reprogramming, exhibiting a highly glycolytic
70 phenotype, which is associated with elevated expression of glucose transporter
71 isoform 1 (GLUT1).[12] The metabolic shift increases lactate production. Lactate is
72 then exported into the extracellular space leading to microenvironment acidification
73 and carbonic anhydrase IX (CAIX) induction.
74 Hypoxic biomarkers have been extensively investigated in human cancers
75 and have been associated with prognosis and therapy resistance.[18,28] Despite the
76 increasing knowledge on the role of hypoxia in tumors, to date only a few studies are
77 available in dogs.[30] Hypoxia has been reported as a frequent condition occurring in
78 COMMs, in which HIF-1α activation induces the transcription of GLUT1 and CAIX.[30]
79 A recent study showed that the hypoxia-regulated miRNAs, miR-210 and miR-301,
80 are differentially expressed in primary and metastatic canine melanoma cell lines,
81 and metastatic cells are more resistant to hypoxia stimuli than primary tumor
82 cells.[17,51] Additionally, it has been demonstrated, by the expression of HIF-1α, that
83 COMM tumor cells invading the bone are under hypoxic conditions, and this may
84 explain a poorer efficacy of radiotherapy in dogs with bone lysis.[33]
85 Based on these premises, and considering the aggressiveness and therapy
86 resistance of COMM, [37] the aim of this study was to unveil the prognostic value of
87 HIF-1α and the associated hypoxia-response proteins, GLUT 1, CXCR4, CAIX, and
88 VEGF-A, in COMM. Additionally, the study aimed to examine the activation of HIF-1α
89 and its biological alterations after inducing a hypoxic state in a metastatic COMM cell
90 line.
91

92 **Material and Methods**

93 **Sample collection and clinical data**

94 A retrospective study was performed on 36 COMMs diagnosed at the
95 Department of Veterinary Sciences of the University of Turin in the period between
96 2005 and 2018. The cases were retrieved through a data base search using the
97 following keys words: “canine”, “oral cavity”, and “malignant melanomas”. Pre-
98 operative clinical tumor staging [4,54] was assessed by means of total body computed
99 tomography in 24 cases, or skull and three views chest radiographs and abdominal
100 ultrasound in 12 cases. The primary tumor was removed by *en-bloc* excision
101 (mandibulectomy, maxillectomy, or lip-cheek excision followed by reconstruction)
102 with regional (ipsilateral or bilateral) lymphadenectomy.

103 Dogs were clinically staged based on tumor size, regional lymph node
104 involvement, and metastasis (TNM) according to Bergman et al 2007.[3,4] Sixteen out
105 of the 36 COMMs with a chondroitin sulfate proteoglycan-4 (CSPG4)
106 immunohistochemical score ≥ 3/8 received *CSPG4* DNA electro-vaccination
107 according to the Good Clinical Practice guidelines for animal clinical studies.[29,40,45,59]
108 The remaining 20 cases were treated with surgery alone. Both the Ethics Committee
109 of the University of Turin and the Italian Ministry of Health approved the trial
110 (0004230-20/02/2018-DGSAF-MDS-P).

111 Follow-up for the non-vaccinated dogs consisted of clinical evaluation and
112 thoracic radiographs performed every 3 months during the first year and then every 6
113 months for a minimum of 2 years. Dogs receiving *CSPG4* DNA electro-vaccination
114 were clinically evaluated monthly with thoracic computed tomography .

115 **Histological and Immunohistochemical analysis**

116 Formalin fixed and paraffin-embedded histologic sections of the tumors were
117 stained with hematoxylin and eosin. Diagnoses were performed independently by
118 three observers (LM, SI, CG). In case of disagreements, a consensus was reached
119 using a multi-headed microscope.
120 Specimens were classified according to the World Health Organization (WHO)
121 guidelines[56] and evaluated for prognostic parameters in canine melanocytic
122 neoplasia according to the current literature. Briefly, nuclear atypia was assessed
123 according to what has been described by Spangler and Kass.[58] A threshold value of
124 30% atypical nuclei was considered. Mitotic count was obtained by counting the
125 number of mitoses in 2.37 mm^2, considering the regions of highest mitotic activity
126 and avoiding areas of ulceration, necrosis, and inflammation. The mitotic count cut-
127 off value was ≥4 according to Smedley et al.[56] Pigmentation was assessed
128 subjectively as described by Smedley and colleagues[56] evaluating all available
129 sections and dividing cases into those with ≥50% and those with < 50% pigmented
130 cells. Ki67 was determined as the average number of positive neoplastic cell nuclei
131 per 1 cm^2 optical grid reticle at 400x magnification/40x objective (5 grid areas
132 counted) in the highest labelling area with a cut- off value of 19.5.
133 Immunohistochemistry was performed on 4 µm thick paraffin sections. After blocking
134 peroxidase activity (0.3% hydrogen peroxide in deionized water for 30 min) and heat-
135 induced antigen retrieval (30 min with citrate buffer at 98°C, pH 6.0), sections were
136 incubated with primary antibodies Ki-67, HIF-1α, CAIX, CXCR4, GLUT-1, and VEGF-

137 A overnight at 4°C (Table 1); the detection was performed using the Vectastain
138 Universal Quick Kit (Vector Laboratories). Immunolabelled slides were randomized
139 and masked for blinded examination, which was performed by three independent
140 pathologists (SI, ML, LA). In case of disagreements, a consensus was reached using
141 a multi-headed microscope.

142 Antibodies specificity for HIF-1α, CXCR4, VEGFA, GLUT1, and CAIX was
143 assessed on positive and negative tissues (canine mammary carcinomas, renal
144 carcinoma, skin, and testis) as shown in Supplemental Figure S1.

145 Immunohistochemical evaluation was performed by a semi- quantitative method
146 evaluating both the intensity and the percentage of positive cells using scoring
147 systems previously published (Supplemental Table S2).[25,29,30,39,44,54]

148 **Cell line and CoCl2 treatment**

149 A canine malignant melanoma cell line (OLGA), previously established by the
150 authors,[46] was cultured in Dulbecco's modified Eagle's medium supplemented with
151 10% fetal bovine serum, 1% glutamine, 100 µg/mL penicillin, and 100 µg/mL
152 streptomycin at 37°C and 5% CO2. The OLGA cell line was cultured in chemically
153 induced hypoxia for 12, 24, and 48 hours using a concentration of 200 µM cobalt
154 chloride ($CoCl_2$; Sigma Aldrich, 15862-1ML-F).[42]

155 **Western blot analysis**

156 Proteins from the OLGA cell line, treated with 200 µM of $CoCl_2$ for 12, 24, and
157 48 hours or untreated (DMSO alone), were extracted in lysis buffer (1% Triton X-100,
158 10% glycerol, 50mM Tris, 150mM sodium chloride, 2mM EDTA, pH 8.0, and 2mM
159 magnesium chloride) containing Protease Inhibitor Cocktail (P8340 Sigma). Twenty
160 micrograms of total proteins were separated on a 10% SDS-PAGE gel and

161 transferred onto a 0.2 μm pore-size nitrocellulose membrane (Cytiva; Thermo Fisher
162 Scientific). After washing, membranes were incubated in Tris-buffered saline with
163 10% bovine serum albumin at room temperature for 1 hour and then incubated
164 overnight at 4°C with HIF1-α and CAIX antibodies; α-tubulin was used as a
165 housekeeping protein (Supplemental Table S1). Horseradish peroxidase -
166 conjugated secondary antibodies were diluted at 1:15 000. The chemiluminescence
167 substrate (Clarity ECL Substrate; BIO-RAD Laboratories) was used to produce the
168 light signal, acquired with CL-XPosure films (Thermo Fisher Scientific Inc).

169 **Immunofluorescence**

170 To investigate the effects of $CoCl_2$ on HIF1-α nuclear translocation and CAIX
171 expression, immunofluorescence against HIF1-α and CAIX was performed on OLGA
172 cells exposed to the highest $CoCl_2$ concentration (200 μM) for 12, 24, and 48 hours.
173 Briefly, $2x10^4$ cells were plated in eight-well chamber slides (Lab-Tek II Chamber
174 Slide System; Nalge Nunc International) until 70% confluence. After treatment, cells
175 were fixed with methanol:acetone (1:1 proportion) for 30 seconds. After washing
176 three times with Tris-HCl (0.1M, pH 7.6), cells were blocked with 10% normal goat
177 serum for 1 hour at room temperature and then incubated overnight at 4°C with
178 antibodies to HIF-1α (1:100) and CAIX (1:200). After washing with Tris-HCl, cells
179 were incubated with a fluorescent secondary Alexa488-conjugated goat anti-rabbit
180 IgG antibody (1:500 dilution, ThermoFisher) and anti-mouse IgG (1:500) for 1 hour
181 in the dark. Subsequently, cell nuclei were stained with DAPI (0.5μg/ml in Tris-HCl,
182 Sigma–Aldrich, USA) for 10 minutes, washed three times with Tris-HCl, and then the
183 sections were covered with mounting medium (PermaFluor, Thermo Scientific) and
184 kept overnight in the dark. Fields were randomly selected by microscope TCS SP8
185 (Leica Microsystems CMS GmbH Mannehim, Germany) and z-stacks of 10 nm were

acquired. Z-stacks were then processed directly with the Leica LAS-X software to produce maximum projection images of each field. To detect co-localization of different fluorochromes, fluorescent signals in different channels were merged to produce multi-color images. Image acquisitions were performed with a resolution of 1024 x 1024 pixels with a 200 Hz sampling frequency.

Statistical analyses

Fisher's exact test or the chi-squared test was used to test possible associations among immunohistochemical marker expression and clinical and histopathological data. Disease -free interval (DF) was calculated as the time between surgery and the first detection of metastases and/or local recurrence, while overall survival (OS) was defined as the period from the day of surgery to the patient's death due to a cancer -related cause. The survival functions of the DFI and OS were estimated with the Kaplan-Meier method, and the comparison of survival function was done by means of the log-rank test. Dogs that died from unrelated causes, were lost to follow-up, or were still alive at the end of the study were right-censored. Univariate and multivariate Cox models were fitted to verify the effects of hypoxia biomarkers on DFI or OS. In multivariate analysis, we considered the following parameters: HIF-1α, CXCR4, VEGFA, GLUT1, and CAIX immunohistochemical expression. Statistical significance was set at a 0.05 level. Because the clinical samples belonging to stage I were censored, this stage was omitted. GraphPad Prism 8 (GraphPad Software, San Diego, California) and R statistical software (R Core Team, 2018) were used for statistical analysis.

210 **RESULTS**

211 ***Patient and tumor characteristics***

212 A total of 36 dogs with COMM met the inclusion criteria. Clinical and follow-up
213 data, and histopathological and immunohistochemical diagnostic features are
214 provided in Tables 1 and 2, respectively. Survival analysis (Fig.1) showed that dogs
215 with clinical stage IV had a worse prognosis compared to dogs with clinical stages II
216 and III (p=0.002). Similarly, vaccinated dogs had a significantly higher OS time
217 compared to non-vaccinated dogs (p<0.001) (Fig. 2). Although not significant, we
218 found that COMMs with a total absence of melanin or less than 25% pigmented
219 neoplastic cells were associated with a lower DFI when compared to tumors with >
220 50% pigmented neoplastic cells (median DFI: days 180 vs 210 days, respectively, p
221 = 0.06). The OS was not significantly associated with the amount of pigmentation
222 (median OS: 235 days vs 778 days, p = 0.08), and none of the other
223 histopathological parameters showed prognostic significance.

224 ***Overexpression of hypoxic markers negatively affects prognosis in dogs***
225 ***receiving immunotherapy.***

226 The immunohistochemical scores for HIF-1α, CAIX, GLUT-1, CXCR4, and
227 VEGF-A are summarized in Table 3. Representative images are shown in Figure 3.
228 The CAIX score was associated with the HIF-1α score (p = 0.001). Additionally, we
229 found a statistical association between CXCR4 and Ki-67 index (p= 0.046) (Table 4).
230 Multivariate analysis revealed that dogs receiving immunotherapy and
231 overexpressing HIF-1α, VEGF-A, and CXCR4 had a significantly shorter DFI
232 (median = 111 days) compared to dogs with the same treatment that were negative

233 for all three markers or only positive for 1 or 2 markers (median = 204 days; p =
234 0.03) (Fig. 4), while no significant differences were observed for OS.

235 Multivariate analysis in non-vaccinated patients revealed no statistically
236 significant differences in OS or DFI between dogs with concomitant overexpression
237 of HIF-1α, VEGF-A, and CXCR4 and dogs negative for the markers or expressing
238 only one or two markers.

239 ***CoCl2 treatment induces HIF-1α accumulation and nuclear translocation***

240 Distinct bands corresponding to HIF-1α (120 kDa) and CAIX (58 kDa)
241 proteins were more pronounced in the Olga cell line treated with $CoCl_2$ at 12 and 24
242 hours (Fig. 5). In contrast, the expression of these proteins was either negative (HIF-
243 1α) or very low (CAIX) in untreated cells (Fig. 5).

244 A mild increase of CAIX protein was also present in chemically-induced
245 hypoxic conditions after 24 hours. Under normoxic conditions, HIF-1α was primarily
246 localized to the cytoplasm, with nuclear localization becoming evident only after
247 $CoCl_2$ treatment (Fig. 6). In contrast, chemically induced hypoxia did not yield
248 noticeable effects on CAIX protein.

249

250 **DISCUSSION**

251 COMM is the most commonly diagnosed malignant tumor occurring in the oral
252 cavity of dogs,[16,54] and it has a high and rapid metastatic rate, resulting in a poor
253 prognosis.[3] Recently, a consensus working group was founded to identify potential
254 prognostic markers in this neoplasm and to give accurate recommendations for the
255 diagnosis and histopathologic prognostication of canine melanocytic tumors. [55]
256 Although nuclear atypia,mitotic count, and Ki-67 index are considered the most
257 prognostic factors for COMM, the identification of new markers may improve the ability
258 to prognosticate these neoplasms, as well as aiding in the selection of specific
259 therapies.

260 In this study, we observed that patients with advanced clinical stages (III and
261 IV) had a shorter OS compared to stage II patients, which is consistent with existing
262 literature.[3] Furthermore, our data confirmed that *CSPG4* vaccination significantly
263 increased the overall survival of COMM patients.[40,46]

264 Interestingly, smaller amounts of melanin in COMMs seem to be weakly
265 associated with shorter DFI, suggesting a close association between loss of melanin
266 pigment and tumor dedifferentiation, which may be associated with a more aggressive
267 behavior. This finding doesn't represent a novelty because in 2011, Smedley et al.
268 suggested that a lower level of pigmentation (<50% of pigmented cells) is an
269 unfavorable factor.[54] In human cutaneous melanoma, decreased pigmentation has
270 also been linked to an aggressive phenotype with implications for prognosis and
271 response to therapy.[6,53]

272 As previously reported in a number of canine tumor histotypes, a correlation
273 between CAIX and HIF-1α positivity has been observed, suggesting hypoxia may

274 trigger microenvironment acidosis with metabolic changes in cancer cells growth.[36]
275 Our findings reinforce the close interaction between these molecules and highlight the
276 strong HIF-1α-dependent regulation of CAIX as an adaptation of COMM cells to
277 extracellular acidosis.[61] This adaptation may enhance the tumor's ability to survive and
278 grow under adverse conditions.

279 We found that CXCR4 expression was associated with an increased Ki-67
280 index, which is consistent with previous reports in human renal carcinomas[9] and
281 multicentric lymphoma.[63] However, in human cutaneous melanomas, these markers
282 have not been significantly associated.[31,32,60]

283 Univariate data analysis for the hypoxic markers did not show any statistical
284 significance for DFI or OS. However, these markers are interconnected in the hypoxic
285 cellular pathway signaling. Hence, we investigated the prognostic value of their co-
286 expression**.** Multivariate data analysis revealed that concurrent expression of HIF-1α,
287 VEGF-A and CXCR4 in COMMs treated with a *CSPG4* vaccine is associated with a
288 lower DFI compared to COMMs negative for these markers. This suggests a lower
289 efficacy of *CSPG4* vaccination in tumors displaying hypoxic features. This finding is in
290 line with the literature, in which hypoxia is known to induce immune-resistance and
291 negatively interferes with immune surveillance of tumors, as well as adoptive
292 immunotherapy.[2,24,62] Likewise, co-expression of hypoxic markers and hypoxia-related
293 signatures have been documented in several human cancer as predictive of a poor
294 outcome.[7,26,64] This co-expression triggers the activation of HIF-1α-dependent
295 pathways, which can lead to tumor growth, angiogenesis, and metastasis.[8] Regarding
296 the relationship between hypoxic microenvironments and CSPG4 expression, it's very
297 interesting to underscore that in human melanomas, CSPG4 is regulated by hypoxia
298 in vitro and its expression confers resistance to immunotherapy.[23,41] On the basis of

299 the preliminary data obtained by the authors, we can hypothesize that in dogs, CSPG4
300 is regulated by hypoxia, strengthening COMM as a good model for comparative
301 oncology.[34]

302 To gain insight into the mechanisms of hypoxia in COMM, the OLGA cell line
303 was treated with $CoCl_2$ to mimic a hypoxic stimulus.[13] We found that *in vitro* hypoxia
304 induction caused an accumulation of HIF-1α protein after treatment. HIF-1α induction
305 and stabilization triggered by hypoxia was further corroborated by
306 immunofluorescence, in which nuclear translocation under $CoCl_2$ treatment to avoid
307 proteasomal degradation was demonstrated.[50] In the nucleus, HIF-1α is known to
308 directly coordinate the transcription of hypoxia-regulating elements.[49] Consistent with
309 the immunohistochemical results, CAIX protein levels were also mildly increased
310 under chemically induced hypoxia. Its accumulation was delayed as compared to HIF-
311 1α, thus supporting the direct role of HIF-1α in the upregulation of this protein.[21]

312 In conclusion, our results reinforce the crucial role of a hypoxic
313 microenvironment and acidification in tumor aggressiveness and outcome in COMM,
314 as extensively established in other canine[14,57] and human cancers.[5] It becomes critical
315 to develop novel therapeutic strategies considering the hypoxic status of the tumors,
316 and future studies should address the *in vitro* effects of hypoxia in COMM cells and
317 investigate the inhibition of hypoxia-related signaling pathways as potential
318 therapeutic targets. Notably, as shown in this study, it is crucial to consider the
319 interdependent actions of the molecular mechanisms triggered by HIF-1α and its
320 transcriptional cascade.

321

REFERENCES

1. Abou Khouzam R, Brodaczewska K, Filipiak A, et al. Tumor Hypoxia Regulates Immune Escape/Invasion: Influence on Angiogenesis and Potential Impact of Hypoxic Biomarkers on Cancer Therapies. *Front Immunol*. 2020;**11**:613114.

2. Barsoum IB, Smallwood CA, Siemens DR, Graham CH. A mechanism of hypoxia-mediated escape from adaptive immunity in cancer cells. Vol. 74, *Cancer Res*. 2014:665–674.

3. Bergman PJ. Canine oral melanoma. 2007;**22**(2):55–60.

4. Bergman PJ. Melanoma. In: *Clinical Small Animal Internal Medicine*. John Wiley & Sons, Ltd 2020:1347–1352.

5. Bhandari V, Hoey C, Liu LY, et al. Molecular landmarks of tumor hypoxia across cancer types. *Nat Genet*. 2019;**51**(2):308–318.

6. Cabaço LC, Tomás A, Pojo M, Barral DC. The Dark Side of Melanin Secretion in Cutaneous Melanoma Aggressiveness. *Front Oncol*. 2022;**12**:887366.

7. Cangelosi D, Morini M, Zanardi N, et al. Hypoxia Predicts Poor Prognosis in Neuroblastoma Patients and Associates with Biological Mechanisms Involved in Telomerase Activation and Tumor Microenvironment Reprogramming. *Cancers (Basel)*. 2020;**12**(9):2343.

8. Chatterjee S, Azad BB, Nimmagadda S. The Intricate Role of CXCR4 in Cancer. *Adv Cancer Res*. 2014;**124**:31–82.

9. Czajkowski M, Kaemmerer D, Sänger J, et al. Comparative evaluation of somatostatin and CXCR4 receptor expression in different types of thyroid carcinoma using well-characterised monoclonal antibodies. *BMC Cancer*. 2022;**22**(1):740.

10. D'Aguanno S, Mallone F, Marenco M, Del Bufalo D, Moramarco A. Hypoxia-dependent drivers of melanoma progression. *J Exp Clin Cancer Res*. 2021;**40**(1):159.

11. Devarajan N, Manjunathan R, Ganesan SK. Tumor hypoxia: The major culprit behind cisplatin resistance in cancer patients. Vol. 162, *Crit Rev Oncol Hematol*. 2021:103327.

12. Dratkiewicz E, Simiczyjew A, Mazurkiewicz J, Ziętek M, Matkowski R, Nowak D. Hypoxia and Extracellular Acidification as Drivers of Melanoma Progression and Drug Resistance. *Cells*. 2021;**10**(4):862.

13. Gola C, Giannuzzi D, Rinaldi A, et al. Genomic and Transcriptomic Characterization of Canine Osteosarcoma Cell Lines: A Valuable Resource in Translational Medicine. 2021/06/04 ed. 2021;**8**:666838.

14. Gola C, Iussich S, Noury S, et al. Clinical significance and in vitro cellular regulation of hypoxia mimicry on HIF-1α and downstream genes in canine appendicular osteosarcoma. Vol. 264, *Vet J*. 2020:105538.

15. Graham K, Unger E. Overcoming tumor hypoxia as a barrier to radiotherapy, chemotherapy and immunotherapy in cancer treatment. 20181004th ed. 2018;**13**:6049–6058.

358 16. Hernandez B, Adissu HA, Wei BR, Michael HT, Merlino G, Simpson RM. Naturally Occurring
359 Canine Melanoma as a Predictive Comparative Oncology Model for Human Mucosal and Other
360 Triple Wild-Type Melanomas. Vol. 19, *Int J Mol Sci*. 2018:

361 17. Hino Y, Rahman MM, Lai YC, et al. Hypoxic miRNAs expression are different between primary
362 and metastatic melanoma cells. Vol. 782, *Gene*. 2021:145552.

363 18. Infantino V, Santarsiero A, Convertini P, Todisco S, Iacobazzi V. Cancer Cell Metabolism in
364 Hypoxia: Role of HIF-1 as Key Regulator and Therapeutic Target. Vol. 22, *Int J Mol Sci*. 2021:

365 19. Jing X, Yang F, Shao C, et al. Role of hypoxia in cancer therapy by regulating the tumor
366 microenvironment. Vol. 18, *Mol Cancer*. 2019:157.

367 20. Jun JC, Rathore A, Younas H, Gilkes D, Polotsky VY. Hypoxia-Inducible Factors and Cancer.
368 2017/09/26 ed. 2017;**3**(1):1–10.

369 21. Kaluz S, Kaluzová M, Liao S-Y, Lerman M, Stanbridge EJ. Transcriptional control of the tumor-
370 and hypoxia-marker carbonic anhydrase 9: A one transcription factor (HIF-1) show? *Biochim*
371 *Biophys Acta*. 2009;**1795**(2):162–172.

372 22. Ke Q, Costa M. Hypoxia-inducible factor-1 (HIF-1). 20060803rd ed. 2006;**70**(5):1469–1480.

373 23. Keleg S, Titov A, Heller A, et al. Chondroitin sulfate proteoglycan CSPG4 as a novel hypoxia-
374 sensitive marker in pancreatic tumors. *PLoS One*. 2014;**9**(6):e100178.

375 24. Kopecka J, Salaroglio IC, Perez-Ruiz E, et al. Hypoxia as a driver of resistance to
376 immunotherapy. Vol. 59, *Drug Resist Updat*. 2021:100787.

377 25. Liu Y, Zhang F, Zhang Z, et al. High expression levels of Cyr61 and VEGF are associated with
378 poor prognosis in osteosarcoma. Vol. 213, *Pathol Res Pract*. 2017:895–899.

379 26. Luan L, Dai Y, Shen T, et al. Development of a novel hypoxia-immune–related LncRNA risk
380 signature for predicting the prognosis and immunotherapy response of colorectal cancer. *Front*
381 *Immunol*. 2022;**13**:951455.

382 27. Majmundar AJ, Wong WJ, Simon MC. Hypoxia-inducible factors and the response to hypoxic
383 stress. Vol. 40, *Mol Cell*. 2010:294–309.

384 28. Malekan M, Ebrahimzadeh MA, Sheida F. The role of Hypoxia-Inducible Factor-1alpha and its
385 signaling in melanoma. Vol. 141, *Biomed Pharmacother*. 2021:111873.

386 29. Mayayo SL, Prestigio S, Maniscalco L, et al. Chondroitin sulfate proteoglycan-4: a biomarker
387 and a potential immunotherapeutic target for canine malignant melanoma. Vol. 190, *Vet J*.
388 2011:e26-30.

389 30. Meier V, Guscetti F, Roos M, Ohlerth S, Pruschy M, Rohrer Bley C. Hypoxia-Related Marker
390 GLUT-1, CAIX, Proliferative Index and Microvessel Density in Canine Oral Malignant Neoplasia.
391 Vol. 11, *PLoS One*. 2016:e0149993.

392 31. Mitchell B, Mahalingam M. The CXCR4/CXCL12 axis in cutaneous malignancies with an
393 emphasis on melanoma. *Histol Histopathol*. 2014;**29**(12):1539–1546.

394 32. Murakami T, Cardones AR, Hwang ST. Chemokine receptors and melanoma metastasis. *J*
395 *Dermatol Sci*. 2004;**36**(2):71–78.

396 33. Noguchi S, Yagi K, Okamoto N, Wada Y, Tanaka T. Prognostic Factors for the Efficiency of
397 Radiation Therapy in Dogs with Oral Melanoma: A Pilot Study of Hypoxia in Intraosseous
398 Lesions. 2023;**10**(1):4.

399 34. Paoloni M, Khanna C. Translation of new cancer treatments from pet dogs to humans. Vol. 8,
400 *Nat Rev Cancer*. 2008:147–156.

401 35. Parks SK, Cormerais Y, Marchiq I, Pouyssegur J. Hypoxia optimises tumour growth by
402 controlling nutrient import and acidic metabolite export. Vols. 47–48, *Mol Aspects Med*.
403 2016:3–14.

404 36. Parks SK, Cormerais Y, Pouyssegur J. Hypoxia and cellular metabolism in tumour
405 pathophysiology. Vol. 595, *J Physiol*. 2017:2439–2450.

406 37. Pazzi P, Steenkamp G, Rixon AJ. Treatment of Canine Oral Melanomas: A Critical Review of the
407 Literature. Vol. 9, *Vet Sci*. 2022:

408 38. Petrova V, Annicchiarico-Petruzzelli M, Melino G, Amelio I. The hypoxic tumour
409 microenvironment. 2018;**7**(1):1–13.

410 39. Petty JC, Lana SE, Thamm DH, et al. Glucose transporter 1 expression in canine osteosarcoma.
411 Vol. 6, *Vet Comp Oncol*. 2008:133–140.

412 40. Piras LA, Riccardo F, Iussich S, et al. Prolongation of survival of dogs with oral malignant
413 melanoma treated by en bloc surgical resection and adjuvant CSPG4-antigen
414 electrovaccination. Vol. 15, *Vet Comp Oncol*. 2017:996–1013.

415 41. Pucciarelli D, Lengger N, Takacova M, et al. Anti-chondroitin sulfate proteoglycan 4-specific
416 antibodies modify the effects of vemurafenib on melanoma cells differentially in normoxia and
417 hypoxia. *Int J Oncol*. 2015;**47**(1):81–90.

418 42. Rana NK, Singh P, Koch B. CoCl2 simulated hypoxia induce cell proliferation and alter the
419 expression pattern of hypoxia associated genes involved in angiogenesis and apoptosis. Vol.
420 52, *Biol Res*. 2019:12.

421 43. Rankin EB, Nam JM, Giaccia AJ. Hypoxia: Signaling the Metastatic Cascade. Vol. 2, *Trends*
422 *Cancer*. 2016:295–304.

423 44. Ren Z, Liang S, Yang J, et al. Coexpression of CXCR4 and MMP9 predicts lung metastasis and
424 poor prognosis in resected osteosarcoma. Vol. 37, *Tumour Biol*. 2016:5089–5096.

425 45. Riccardo F, Iussich S, Maniscalco L, et al. CSPG4-specific immunity and survival prolongation in
426 dogs with oral malignant melanoma immunized with human CSPG4 DNA. 2014/05/31 ed.
427 2014;**20**(14):3753–3762.

428 46. Riccardo F, Iussich S, Maniscalco L, et al. CSPG4-specific immunity and survival prolongation in
429 dogs with oral malignant melanoma immunized with human CSPG4 DNA. 2014/05/31 ed.
430 2014;**20**(14):3753–3762.

431 47. Sánchez-Céspedes R, Accornero P, Miretti S, et al. In vitro and in vivo effects of toceranib
432 phosphate on canine osteosarcoma cell lines and xenograft orthotopic models. Vol. 18, *Vet*
433 *Comp Oncol*. 2020:117–127.

434 48. Satija S, Kaur H, Tambuwala MM, et al. Hypoxia-Inducible Factor (HIF): Fuel for Cancer
435 Progression. Vol. 14, *Curr Mol Pharmacol*. 2021:321–332.

436 49. Schito L, Semenza GL. Hypoxia-Inducible Factors: Master Regulators of Cancer Progression. Vol.
437 2, *Trends Cancer*. 2016:758–770.

438 50. Semenza GL. Oxygen sensing, hypoxia-inducible factors, and disease pathophysiology. Vol. 9,
439 *Annu Rev Pathol*. 2014:47–71.

440 51. Serocki M, Bartoszewska S, Janaszak-Jasiecka A, Ochocka RJ, Collawn JF, Bartoszewski R.
441 miRNAs regulate the HIF switch during hypoxia: a novel therapeutic target. 20180127th ed.
442 2018;**21**(2):183–202.

443 52. Singleton DC, Macann A, Wilson WR. Therapeutic targeting of the hypoxic tumour
444 microenvironment. *Nat Rev Clin Oncol*. 2021;**18**(12):751–772.

445 53. Slominski RM, Zmijewski MA, Slominski AT. The role of melanin pigment in melanoma. *Exp*
446 *Dermatol*. 2015;**24**(4):258–259.

447 54. Smedley RC, Spangler WL, Esplin DG, et al. Prognostic markers for canine melanocytic
448 neoplasms: a comparative review of the literature and goals for future investigation. Vol. 48,
449 *Vet Pathol*. 2011:54–72.

450 55. Smedley RC, Bongiovanni L, Bacmeister C, et al. Diagnosis and histopathologic prognostication
451 of canine melanocytic neoplasms: A consensus of the Oncology-Pathology Working Group. *Vet*
452 *Comp Oncol*. 2022;**20**(4):739–751.

453 56. Smedley RC, Sebastian K, Kiupel M. Diagnosis and Prognosis of Canine Melanocytic Neoplasms.
454 *Vet Sci*. 2022;**9**(4):175.

455 57. Snyder SA, Dewhirst MW, Hauck ML. The role of hypoxia in canine cancer. *Vet Comp Oncol*.
456 2008;**6**(4):213–223.

457 58. Spangler WL, Kass PH. The histologic and epidemiologic bases for prognostic considerations in
458 canine melanocytic neoplasia. *Vet Pathol.* 2006 Mar;**43**(2):136-49.

459 59. Tarone L, Barutello G, Iussich S, et al. Naturally occurring cancers in pet dogs as pre-clinical
460 models for cancer immunotherapy. Vol. 68, *Cancer Immunol Immunother*. 2019:1839–1853.

461 60. Torres-Cabala C, Li-Ning-Tapia E, Hwu W-J. Pathology-based Biomarkers Useful for Clinical
462 Decisions in Melanoma. *Arch Med Res*. 2020;**51**(8):827–838.

463 61. Trojan SE, Piwowar M, Ostrowska B, Laidler P, Kocemba-Pilarczyk KA. Analysis of Malignant
464 Melanoma Cell Lines Exposed to Hypoxia Reveals the Importance of PFKFB4 Overexpression for
465 Disease Progression. 2018;**38**(12):6745–6752.

466 62. Wang B, Zhao Q, Zhang Y, et al. Targeting hypoxia in the tumor microenvironment: a potential
467 strategy to improve cancer immunotherapy. *J Exp Clin Cancer Res*. 2021;**40**(1):24.

468 63. Weber TS. Cell Cycle-Associated CXCR4 Expression in Germinal Center B Cells and Its
469 Implications on Affinity Maturation. 2018;**9**.

470 64. Yang X, Weng X, Yang Y, et al. A combined hypoxia and immune gene signature for predicting
471 survival and risk stratification in triple-negative breast cancer. *Aging (Albany NY)*.
472 2021;**13**(15):19486–19509.

473

474

475 **LEGEND OF THE FIGURES**

476

477 **Figure 1**

478 Kaplan-Meier survival curves for stage II, III, and IV canine oral malignant
479 melanomas. (a) Disease-free interval (DFI). (b) Overall survival (OS) . Stage II
480 (median DFI = 187 days, median OS = 397 days); Stage III (median DFI = 209 days,
481 median OS = 260 days); Stage IV (median DFI = 36 days, median OS= 76). DFI: p =
482 0.06 , OS: p = 0.002

483

484 **Figure 2**

485 Kaplan-Meier survival curves of dogs with canine oral malignant melanomas treated
486 with or without *chondroitin sulfate proteoglycan-4* (*CSPG4*) DNA vaccination. (a)
487 Disease-free interval (DFI). Vaccinated median DFI = 205 days, not vaccinated
488 median DFI = 187 days (p > 0.05). (b) Overall survival (OS). Vaccinated median OS
489 = 972 days, not vaccinated median OS = 215 days (p<0.001) .

490

491 **Figure 3**

492 Immunohistochemistry (IHC) for hypoxia-associated factors in canine oral
493 malignant melanomas, dog. (a) Diffuse moderate cytoplasmic immunolabeling for
494 vascular endothelial growth factor A (VEGFA) in amelanotic melanoma. VEGFA IHC.
495 (b) Diffuse strong cytoplasmic and membrane immunolabeling for C-X-C chemokine
496 receptor type 4 (CXCR4) in spindle amelanotic melanoma. CXCR4 IHC. (c)
497 Multifocal nuclear immunolabeling for hypoxia-inducible factor-1α (HIF-1α) in poorly

498 melanotic melanoma. HIF-1α IHC. (d) Multifocal moderate cytoplasmic
499 immunolabeling for glucose transporter 1 (GLUT1) in poorly melanotic melanoma.
500 GLUT1 IHC. (e) Diffuse weak cytoplasmic immunolabeling for carbonic anhydrase IX
501 (CAIX) in poorly melanotic melanoma. CAIX IHC. (f) Negative reagent control.
502 diaminobenzidine chromogen hematoxylin counterstain.

503 **Figure 4**

504 Kaplan-Meier survival curves of dogs with canine oral malignant melanomas treated
505 with chondroitin sulfate proteoglycan-4 DNA vaccination that either co-express
506 hypoxia-inducible factor-1α (HIF-1α), C-X-C chemokine receptor type 4 (CXCR4),
507 and vascular endothelial growth factor A (VEGFA) or lack the expression of at least
508 one of protein (others). (a) Disease-free interval (DFI). Patients overexpressing HIF-
509 1α, CXCR4, and VEGFA had significant shorter DFIs ($p < 0.05$) compared to dogs
510 that were negative for all three markers, as well as those positive to only 1 or 2
511 markers (others).
512 (b) Overall survival (OS). There were no statistically significant differences in OS (p
513 > 0.05).

514 **Figure 5**

515 Western blot analysis of Olga cells that were untreated (Ctrl) or cells that were
516 treated for 12, 24, or 48 hours with cobalt chloride ($CoCl_2$) to induce hypoxic
517 conditions. HIF-1α, hypoxia-inducible factor-1α; CAIX, carbonic anhydrase IX .

518 **Figure 6**

519 Representative immunofluorescence of primary canine oral malignant melanoma
520 OLGA cell line, either (a-d) untreated or (e-h) treated with 200 μm cobalt chloride
521 ($CoCl_2$) for 24 hours. (a, e) DAPI nuclear staining, blue (b, f) hypoxia-inducible

522 factor-1α (HIF1-α), green. (c, g) carbonic anhydrase IX (CAIX), red .(d, h) merged
523 fluorescent signals of DAPI, HIF1-α, and CAIX.

524

525

526

527 **Authors' Contributions**

528

529 RDM, CG, designed and performed the experimental design. SI, LM, performed
530 histological diagnosis; LM, PM, KV performed IHC evaluations; EM, DG, MO
531 enrolled and surgically treated COMMs

532 EM* performed statistical analysis.

533 PA EM** performed in vitro assay, western blot and immunofluorescence.

534 The manuscript was written by RDM, CG, LM with contribution of LA.

535

536

Table 1.

Clinical features of dogs included in the study

Clinical features			Values
Age (years)		Mean	11.4
		Median	12
		Range	6-16
Gender, n (%)		Female	14 (38.9)
		Male	22 (61.1)
Breed, n (%)		Crossbreed	15 (41.7)
		Golden retriever	3 (8.3)
		Yorkshire terrier	3 (8.3)
		Cocker spaniel	3 (8.3)
		Schnauzer	2 (5.6)
		Others breeds	10 (27.8)
Weight (kg) n (%)		Mean	19
		Median	14
		Range	2-43
Location, n (%)		Mandible	16 (44.4)
		Cheek	8 (22.2)
		Maxilla	6 (16.7)
		Lip	3 (8.3)
		Gingiva	1 (2.8)
		Soft palate	1 (2.8)
		Tongue	1 (2.8)
Lymphadenectomy, n (%)		Unilateral	28 (77.8)
		Bilateral	8 (22.2)
Histological evaluation of surgical margins, n (%)[a]		Non infiltrated	16 (64)
		Infiltrated	9 (36)
Local recurrence n (%)		No	17 (47.2)
		Yes	19 (52.8)
Pulmonary metastasis n (%)		no	18 (50)
		yes	18 (50)
Clinical stage n (%)		I	3 (8.3)
		II	19 (52.8)
		III	10 (27.8)
		IV	4 (11.1)
Follow-up (days)	DFI	Mean	292
		Median	197
		Range	21-1629
	OS	Mean	506
		Median	283
		Range	41-1951
CSPG4 positivity n (%)			31 (86)

[a]Excision margins data are not available for the remaining samples
Abbreviations: DFI, disease-free interval; OS, overall survival.

Table 2

Histopathological and immunohistochemical diagnostic features of Canine Oral Malignant Melanomas

Histological findings		***n (%)***
Histotype	Epithelioid	11 (30.5)
	Fusiform	10 (27.8)
	Mixed	15 (41.7)
Mitotic count in 2.37 mm^2	< 4/10	6 (16.7)
	≥4/10	30 (83.3)
Pigmentation	< 50% of cells	34 (94.4)
	≥ 50% of cells	2 (5.6)
Nuclear atypia	< 30%	8 (22.2)
	> 30%	28 (77.8)
Ki67 index[a]	< 19.5	5 (14.7)
	≥ 19.5	29 (85.3)

[a]Immunohistochemistry not available in the remaining samples

Table 3.
Immunohistochemical scoring of hypoxia-related markers

Marker	IHC Labelling	*n (%)*	Total
HIF-1α	Negative	20 (55.6)	36
	Positive	16 (44.4)	
CAIX	Score 0	9 (29)	31[a]
	Score 1	7 (22.6)	
	Score 2	15 (48.4)	
GLUT-1	Score 0	1 (2.8)	36
	Score 1	12 (33.3)	
	Score 2	23 (63.9)	
CXCR4	Negative	17 (42.2)	36
	Positive	19 (47.2)	
VEGF-A	Score 0	3 (8.3)	36
	Score 1	27 (75)	
	Score 2	6 (16.7)	

[a]Immunohistochemical scoring not assessable in the remaining samples

Table 4
Contingency tables of significantly associated hypoxia immunohistochemical markers

		HIF-1α		*Total* *n (%)*
		Negative	**Positive**	
CAIX	**0-30%**	14	2	16 (51.6)
	>30%	4	11	15 (48.4)
	Total *n (%)*	18 (58.1)	13 (41.9)	
	p-value	***0.001***		

		Ki67		*Total* *n (%)*
		<19.5	**≥19.5**	
CXCR4	**Negative**	0	16	16 (47.1)
	Positive	5	13	18 (52.9)
	Total *n (%)*	5 (14.7)	29 (85.3)	
	p-value	***0.046***		

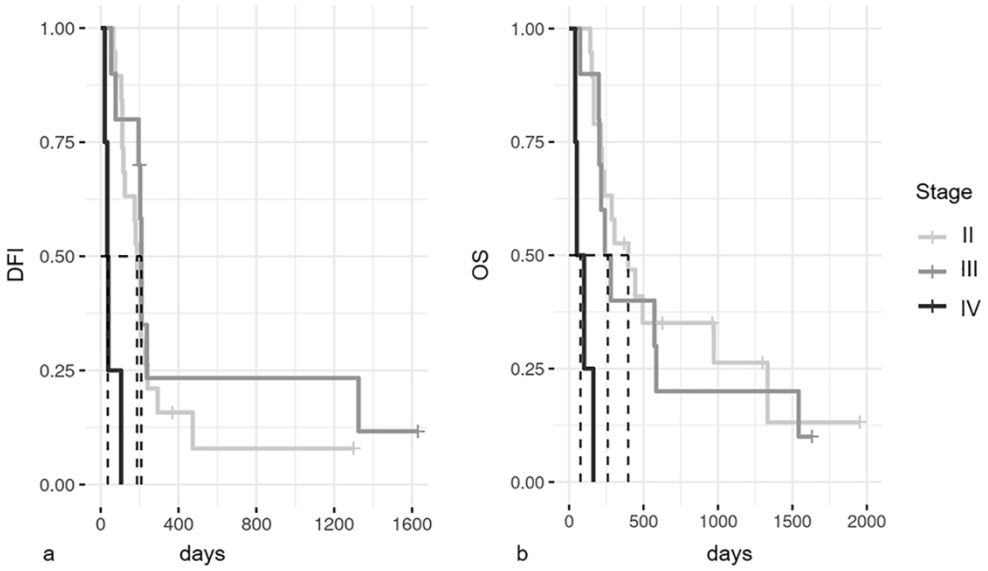

180x101mm (300 x 300 DPI)

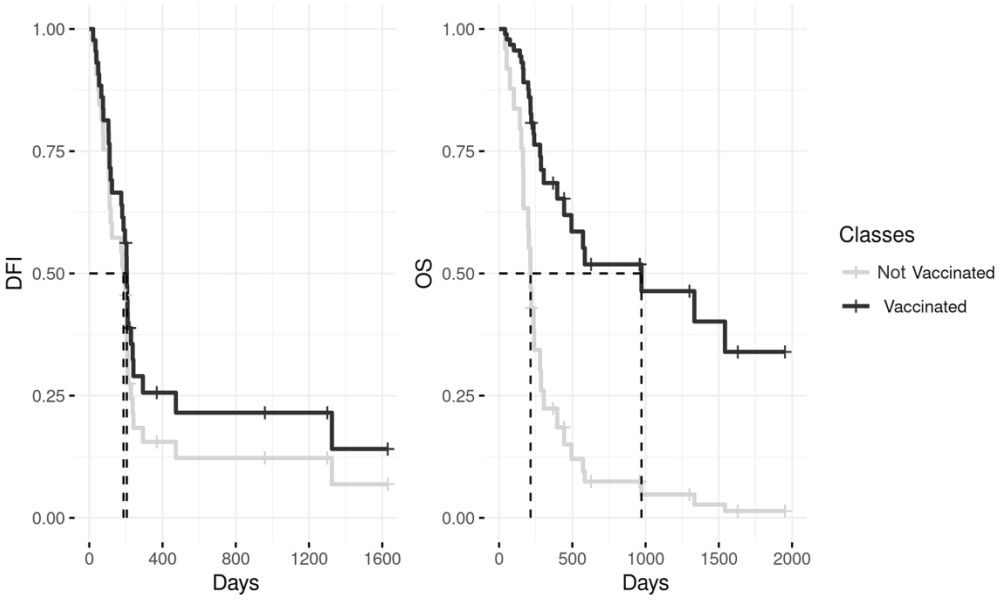

180x119mm (300 x 300 DPI)

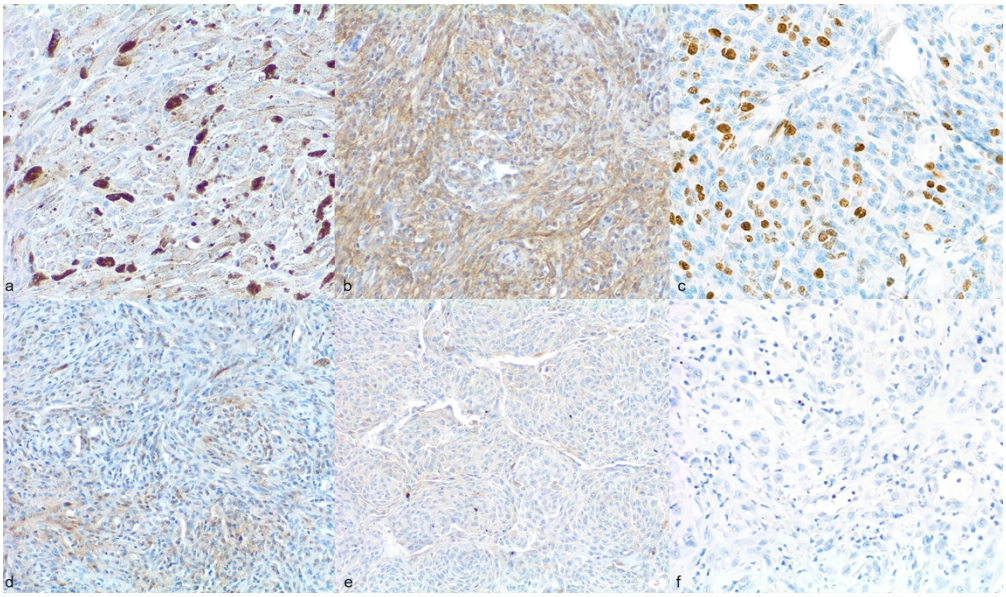

180x105mm (300 x 300 DPI)

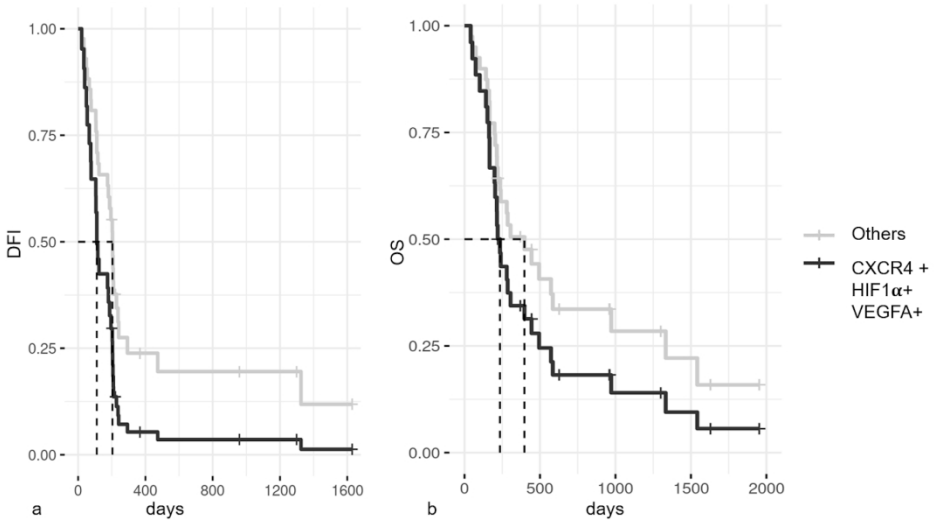

180x99mm (300 x 300 DPI)

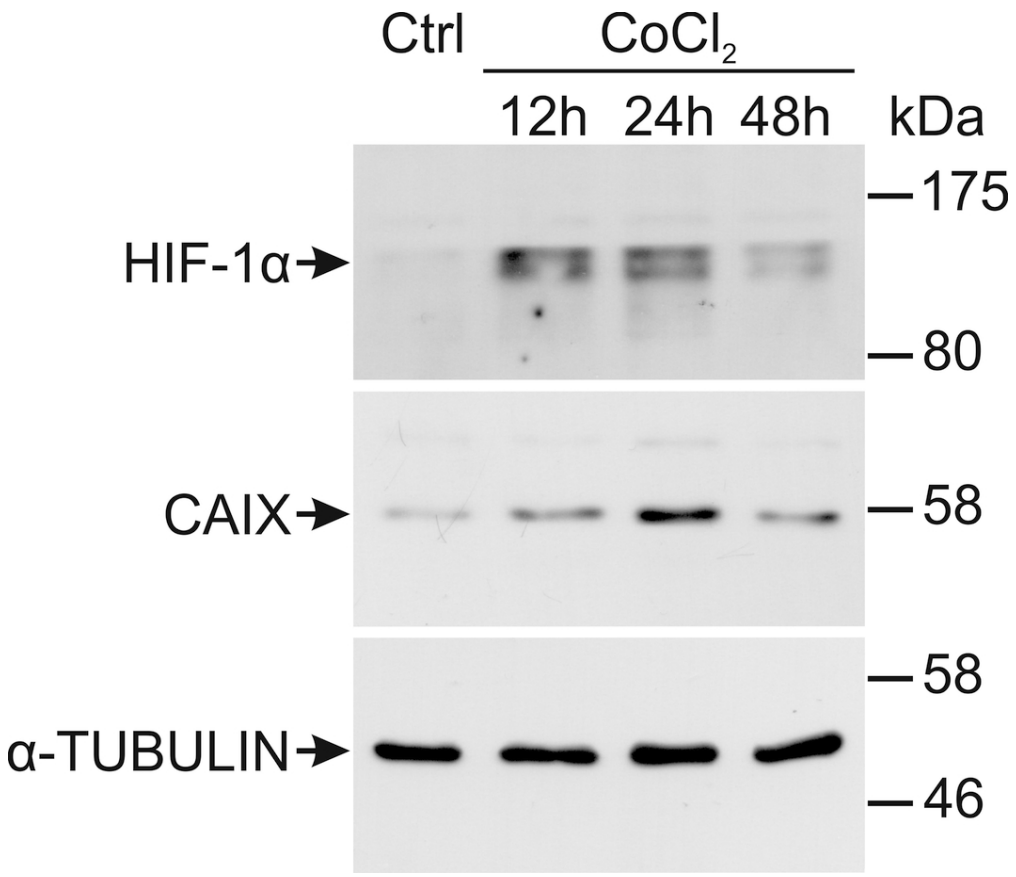

90x77mm (300 x 300 DPI)

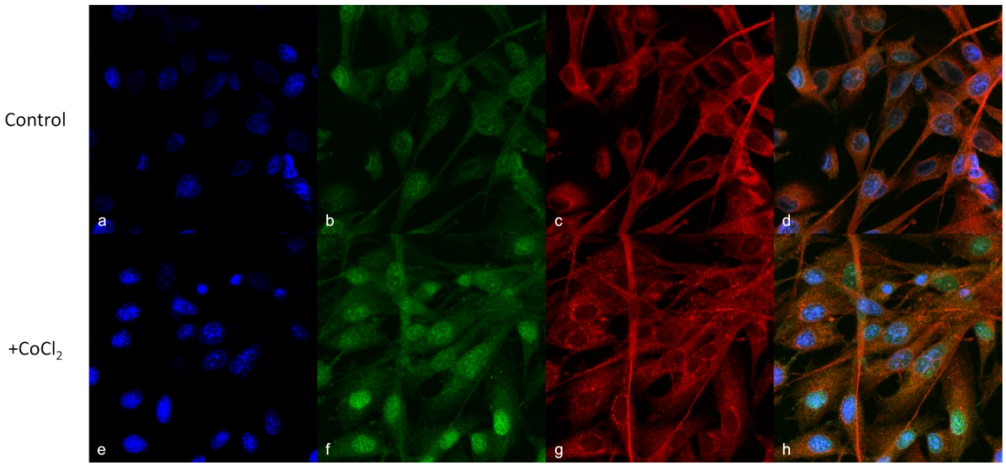

180x82mm (300 x 300 DPI)

Supplementary Table 1.
Primary antibodies used in this study.

Antibody	Application	Dilution	Code	Source
CAIX	IHC	1:1000	AB15086	Abcam
CSPG4	IHC	1:40	SAB4200621	Sigma Aldrich
CXCR4	IHC	1:300	NB100-56437	Novus Biologicals
GLUT-1	IHC	1:80	NB120-15309	Novus Biologicals
HIF-1α	IHC	1:100	A300-286A	Bethyl Laboratories
	WB	1:1,000	610959	Becton and Dickinson Biosciences
	IF	1:100		
Ki67	IHC	1:200	A-047	Dako
VEGF-A	IHC	1:25	SC-65617	Santa Cruz Biotechnology
α-tubulin	WB	1:10,000	T-5168	Sigma Aldrich

Supplementary Table 2.
Scoring system used for immunohistochemical evaluations.

Antibody	Scoring			Reference
CAIX	*% of positive cells* 0 = < 1% 1 = 1-30% 2 = > 30%			Meier et al. (2016)[30]
CSPG4	*% of positive cells* 0 = none 1 = < 1% 2 = 1-10% 3 = 10-33% 4 = 33-66% 5 = > 66%	*Intensity* 0 = negative 1 = weak 2 = intermediate 3 = strong	*Total score [% + Int]* Negative = 0-2 Positive = ≥3	Mayayo et al. (2011)[29]
CXCR4	*% of positive cells* 0 = up to 5% 1 = 10-20% 2 = 21-40% 3 = >40%	*Intensity* 0 = negative 1 = weak 2 = moderate 3= strong	*Total score [% + Int]* Negative = 0-2 Positive = >3	Ren et al. (2016)[44]
GLUT-1	*% of positive cells* 0 = none 1 = up to 50% 2 = > 50%	*Intensity* 0 = negative 1 = weak 2 = strong	*Total score [% x Int]* Negative = 0 Moderate = 1-2 Strong = 4	Petty et al. (2008)[39]
HIF-1α	Negative = only cytoplasmatic staining Positive= cytoplasmatic and nuclear staining			Noguchi et al. (2022)[33]
Ki67	Negative = none or cytoplasmatic staining Positive= nuclear staining			Smedley et al.[55] (2022)
VEGF-A	*% of positive cells* 0 = 0-10% 1 = 10-30% 2 = 31-50% 3 = 51-75% 4 = >75%	*Intensity* 0 = negative 1 = yellow 2 = light brown 3= dark brown	*Total score [% x Int]* Negative = 0 Moderate = 1-8 Strong = 9-12	Liu et al. (2017)[25]

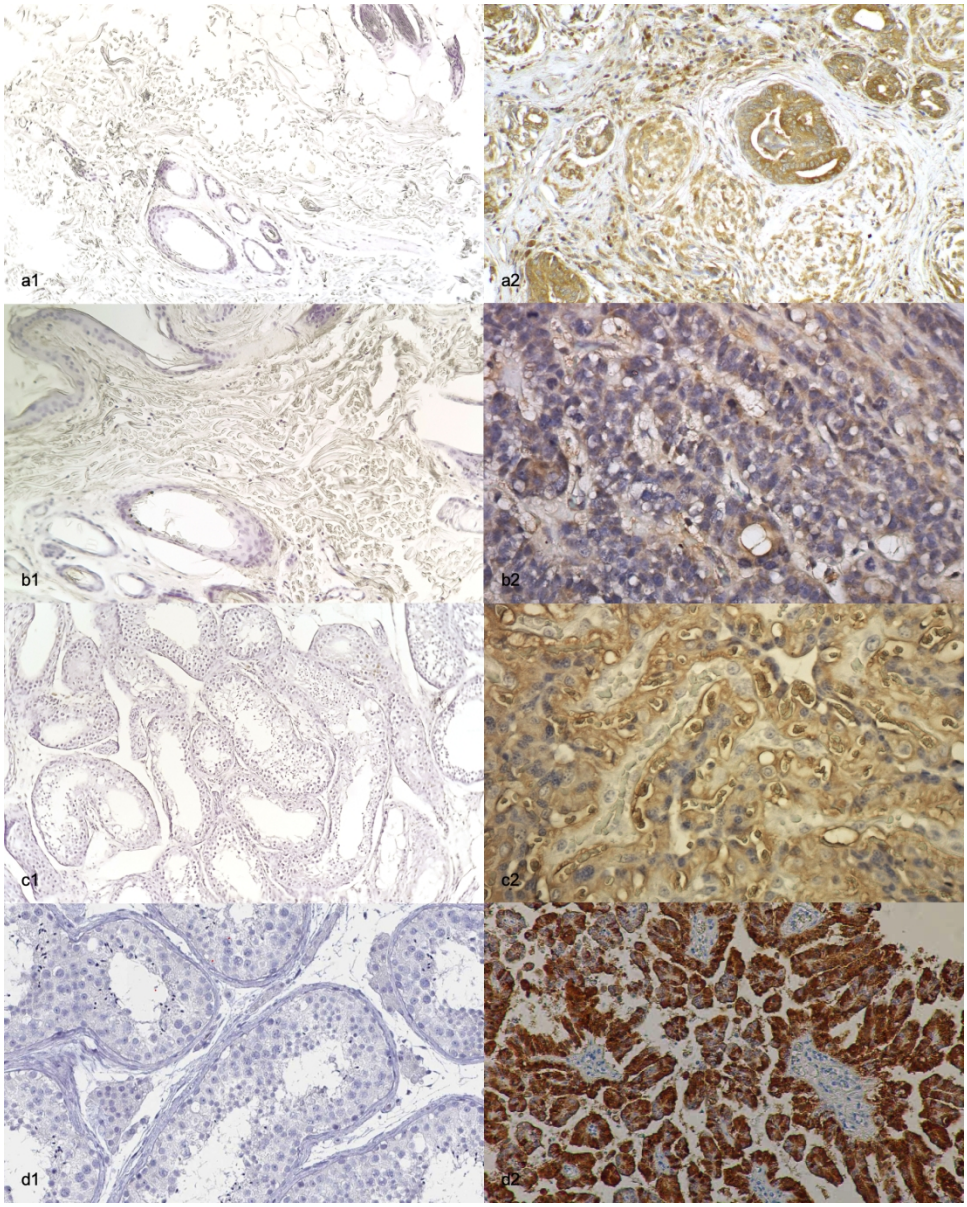

500x624mm (96 x 96 DPI)

Supplementary Figure 1

Validation of immunohistochemistry (IHC) antibodies on canine tissues. (a, b) Hypoxia-inducible factor-1α (HIF-1α) IHC. (a) Haired skin, negative tissue control. (b) Mammary carcinoma, positive tissue control. (c-d) C-X-C chemokine receptor type 4 IHC. (c) Haired skin, negative tissue control. (d) Mammary carcinoma, positive tissue control. (e, f) glucose transporter 1 IHC. (e) Testis, negative tissue control. (f) Placenta, positive tissue control. (g, h) Carbonic anhydrase IX. (g) Testis, negative tissue control. (h) Renal cell carcinoma, positive tissue control.

Hypoxia-associated markers in the prognosis of oral canine melanoma

Cecilia Gola[1,2], Lorella Maniscalco[2*], Selina Iussich[2], Emanuela Morello[2], Matteo Olimpo[2], Eugenio Martignani [2], Paolo Accornero[2], Davide Giacobino[2], Eugenio Mazzone[2], Paola Modesto[3], Katia Varello[3], Luca Aresu[2], Raffaella De Maria[2]

[1] Department of Pathology and Infectious Diseases, University of Surrey, Guildford, UK.

[2] Department of Veterinary Science, University of Turin, Grugliasco (TO), Italy

[3] Istituto Zooprofilattico del Piemonte Liguria e Valle d'Aosta (Italy)

*Corresponding author

lorella.maniscalco@unito.it

phone number +0039-011-6708968

fax number +0039-011-6709031

Address: Largo Braccini 2 10095 Grugliasco (Torino), Italy

ABSTRACT

Canine oral malignant melanoma (COMM) is the most common neoplasm in the oral cavity characterized by local invasiveness and high metastatic potential. Hypoxia represents a crucial feature of the solid tumor microenvironment promoting cancer progression and drug resistance. Hypoxia-inducible factor-1α (HIF-1α) and its downstream effectors ~~VEGF-A (Vascular~~ vascular endothelial growth factor A (VEGF-A), GLUT1)~~(Glucose transporter 1)~~, C-X-C chemokine receptor type 4 (CXCR4)~~(C-X-C chemokine receptor type 4)~~, and carbonic anhydrase IX (CAIX) ~~(Carbonic anhydrase IX)~~ are the main regulators of the adaptive response to low oxygen availability. ~~In this study, the~~ The prognostic value of these markers was evaluated in 36 COMMs using immunohistochemistry. Additionally, the ~~in vitro~~ effects of cobalt chloride-mediated hypoxia were evaluated in one primary COMM cell line. HIF-1α expression was observed in the nucleus, and this ~~subcellular~~ localization ~~appeared to~~ correlated with the presence or enhanced expression of HIF-1α -regulated genes at the protein level. Multivariate ~~data~~ analysis revealed that in dogs given *chondroitin sulfate proteoglycan-4* (*CSPG4*) DNA vaccine, COMMs expressing HIF-1α, VEGF-A, and CXCR4 were associated with a shorter disease-free intervals (DFI) ~~(disease free interval)~~ compared to tumors that were negative for these markers (p=0.03), suggesting hypoxia can influence immunotherapy response. Western blotting ~~analysis~~ showed that under chemically induced hypoxia, COMM cells ~~line~~ accumulate~~s~~ HIF-1-α and smaller amounts of CAIX ~~proteins~~. HIF-1α induction and stabilization triggered by hypoxia was ~~further~~ corroborated by immunofluorescence showing its nuclear translocation. These findings reinforce the ~~crucial~~ role of a hypoxic microenvironment in tumor progression and patient outcome in COMM, as previously established in several human and canine cancers.

Commented [1]: Please note that I removed some words so that the abstract meets the 250 word limit.

Commented [2R2]: Ok

Commented [3]: ok

Additionally, ~~the~~ hypoxic markers may represent promising prognostic markers, highlighting opportunities for their use in therapeutic strategies for COMMs.

Keywords: canine, cell culture, cobalt chloride, hypoxia, ~~in vitro assay~~immunohistochemistry, oral melanomas, prognosis

Canine oral malignant melanoma (COMM) is the most frequent malignant oral tumor in dogs, accounting for 30-40% of all oral malignancies.[4] COMM is a solid tumor arising from neoplastic transformation of mucosal melanocytes, and is characterized by aggressive behavior, extensive local invasiveness, and metastatic potential, resulting in poor prognosis.[3,54]

Hypoxia represents one of the most crucial microenvironmental features in solid tumors[50] and has been associated with invasiveness, angiogenesis, vasculogenic mimicry, and response to therapy in several cancer types, including melanoma.[10,19] Hypoxia and subsequent acidification of the tumoral microenvironment are reported to promote cancer progression~~,~~ and drug resistance,[38] and contribute to immunotolerance of cancer cells, conferring resistance to immunotherapy.[1,11,15,24,48] Hypoxia-inducible factor-1α (HIF-1α) is the primary regulator of the adaptive response to low oxygen availability.[20,27] Upon stabilization and migration to the nucleus, HIF-1α acts as transcription factor for several hypoxia-regulating elements ~~(HREs)~~. ~~HREs~~Hypoxia-regulating elements, in turn, induce and modulate various processes, including glycolysis, angiogenesis, cell migration, invasion, metastasis, and chemoresistance.[11,43,49,50] Vascular ~~Endothelial~~ endothelial ~~Growth~~ growth ~~Factor~~ factor A (VEGF-A) is a key effector of the hypoxic response, which stimulates angiogenesis ~~and~~ that provides nutrients and oxygen to

Commented [4]: I reformatted the paragraphs so hypoxia is covered in one paragraph and metabolic shift is covered in a second paragraph.

Commented [RD5R5]: ok

Commented [6]: Please limit abbreviations to terms used 5 or more times in the main text.

Commented [RD7R7]: ok

proliferating cancer cells.[35] ~~In addition, cancer~~ Moreover, hypoxia stimulates cell homing and migration via chemokine-mediated stimuli. C-X-C chemokine receptor type 4 (CXCR4) is overexpressed in various human cancers, including melanoma, and primarily contributes to tumor growth, angiogenesis, metastasis, and therapeutic resistance.[8,31]

Cancer cells undergo metabolic reprogramming, exhibiting a highly glycolytic phenotype, which is associated with elevated expression of glucose transporter isoform 1 (GLUT1).[12] The metabolic shift increases lactate production. ~~The lactate~~ Lactate is then exported into the extracellular space leading to microenvironment acidification and carbonic anhydrase IX (CAIX) induction. ~~Moreover, hypoxia stimulates cell homing and migration via chemokine-mediated stimuli. C-X-C chemokine receptor type 4 (CXCR4) is overexpressed in various human cancers, including melanoma, and primarily contributes to tumor growth, angiogenesis, metastasis, and therapeutic resistance.[8,31]~~

Hypoxic biomarkers have been extensively investigated in human cancers and have been associated with prognosis and therapy resistance.[18,28] Despite the increasing knowledge on the role of hypoxia in tumors, to date only a few studies are available in dogs.[30] Hypoxia has been reported as a frequent condition occurring in COMMs, in which HIF-1α activation induces the transcription of GLUT1 and CAIX.[30] A recent study showed that the hypoxia-regulated miRNAs, miR-210 and miR-301, are differentially expressed in primary and metastatic canine melanoma cell lines, and metastatic cells are more resistant to hypoxia stimuli than primary tumor cells.[17,51] Additionally, it has been demonstrated, ~~that~~ by the expression of HIF-1α,

that ~~in~~ COMM tumor cells invading the bone are under hypoxic conditions, and this may explain a poorer efficacy of ~~RT (~~radiotherapy~~)~~ in dogs with bone lysis.[33]

Based on these premises, and considering the aggressiveness and therapy resistance of COMM, [37] the aim of this ~~research~~ study was to unveil the prognostic value of HIF-1α and the associated hypoxia-response ~~genes~~proteins, GLUT 1, CXCR4, CAIX, and VEGF-A, in COMM. Additionally, the study aimed to examine the activation of HIF-1α and its biological alterations after inducing a hypoxic state in a metastatic COMM cell line.

Material and Methods

Sample collection and clinical data

A retrospective study was performed on 36 COMMs diagnosed at the Department of Veterinary Sciences of the University of Turin in the period between 2005 and 2018. The cases were retrieved through a data-base ~~re~~search using the following keys words: “canine”, “oral cavity”, and “malignant melanomas”. Pre-operative clinical tumor staging [4,54] was assessed by means of total body computed tomography ~~(CT scan)~~ in 24 cases, or skull and three views chest radiographs and abdominal ultrasound in 12 cases. The primary tumor was removed by *en-bloc* excision (mandibulectomy, maxillectomy, or lip-cheek excision followed by reconstruction) with regional (ipsilateral or bilateral) lymphadenectomy.

Dogs were clinically staged based on tumor size, regional lymph node~~s~~ involvement, and metastasis (TNM) according to Bergman et al 2007.[3,4] Sixteen out of the 36 COMMs with a chondroitin sulfate proteoglycan-4 (CSPG4)

Commented [8]: Please confirm this edit is correct.

Commented [RD9R9]: ok

immunohistochemical score ≥ 3/8 received *CSPG4* DNA ~~electro~~ electro-vaccination according to the Good Clinical Practice guidelines for animal clinical studies.[29,40,45,59] The remaining 20 cases were treated ~~-~~with surgery alone. Both the Ethics Committee of the University of Turin and the Italian Ministry of Health approved the trial (0004230-20/02/2018-DGSAF-MDS-P).

Follow-up for the non-vaccinated dogs consisted of clinical evaluation and thoracic radiographs performed every 3 months during the first year and then every 6 months for a minimum of 2 years. Dogs receiving *CSPG4* DNA ~~electro~~ electro-vaccination were clinically evaluated monthly with thoracic ~~CT~~ computed tomography~~scan~~.

Histological and Immunohistochemical analysis

Formalin~~-~~-fixed and paraffin~~-~~ embedded histologic sections of the tumors were stained with hematoxylin and eosin. ~~Diagnosis~~ Diagnoses ~~was~~ were performed independently by three observers (LM, SI, CG). In case of disagreements, a consensus was reached using a multi-headed microscope.
Specimens were classified according to the World Health Organization (WHO) guidelines[56] and evaluated for prognostic parameters in canine melanocytic neoplasia according to the current literature. Briefly, nuclear atypia was assessed according to what has been described by Spangler and Kass.[58] A t~~T~~hreshold value of 30% atypical nuclei ~~evaluating almost 200 cells~~ was considered. ~~MC (m~~Mitotic count~~)~~ was obtained by counting the ~~absolute~~ number of mitoses in ~~the area~~ 2.37 mm^2, considering the regions of highest mitotic activity and avoiding areas of ulceration, necrosis, and inflammation ~~when counting mitoses~~. The ~~MC~~mitotic count~~C~~ cut~~-~~-off value was ≥4 according to Smedley et al.[56]

Pigmentation was assessed subjectively as described by Smedley and colleagues[56] evaluating all available sections and dividing cases into those with ≥50% and those with < 50% ~~of~~ pigmented cells. Ki67 was determined as the average number of positive neoplastic cell nuclei per ~~area of a~~ 1 cm^2 optical grid reticle at 400x magnification/40x objective (5 grid areas counted) in the highest~~r~~ labelling area with a cut-off value of 19.5.

Immunohistochemistry was performed on 4 µm~~-~~ thick paraffin sections. After blocking peroxidase activity (0.3% ~~H2O2~~ hydrogen peroxide in deionized water for 30 min) and heat-induced antigen retrieval (30 min with citrate buffer at 98°C, pH 6.0), sections were incubated with primary antibodies Ki-67, HIF-1α, CAIX, CXCR4, GLUT-1, and VEGF-A overnight at 4°C (Table 1); the detection was performed using the Vectastain Universal Quick Kit® (Vector Laboratories). Immunolabelled slides were randomized and masked for blinded examination, which was performed by three independent pathologists (SI, ML, LA). In case of disagreements, a consensus was reached using a multi-headed microscope.

Antibodies specificity for HIF-1α, CXCR4, VEGFA, GLUT1, and CAIX was assessed on positive and negative tissues (canine mammary carcinomas, renal carcinoma, skin, and testis) as shown in ~~supplementary~~ Supplemental Figure S1.

Immunohistochemical evaluation was performed by a semi-quantitative method evaluating both the intensity and the percentage of positive cells using scoring systems previously published (~~Supplementary~~ Supplemental Table S2).[25,29,30,39,44,54]

Cell line and CoCl2 treatment

A canine malignant melanoma cell line (OLGA), previously established by the authors,[46], was cultured in ~~DMEM~~ Dulbecco's modified Eagle's medium

Commented [10]: Please remove the vertical lines surrounding the table and separating the columns. Please change the asterisk to a superscript "a". Details about formatting tables are provided in the Instructions to Authors.

Commented [11R11]: Please define all abbreviations in the footnotes in the following format: abbreviation 1, definition 1; abbreviation 2, definition 2

Commented [RD12R11]: ok

Commented [13]: Please either provide the citation number for the papers listed in Supplemental Table S2 or provide the full citations in the footnotes.

Please format this table as described for the other tables.

Commented [RD14R14]: ok

supplemented with 10% fetal bovine serum ~~(FBS)~~, 1% glutamine, 100 µg/mL penicillin, and 100 µg/mL streptomycin at 37°C and 5% CO2. The OLGA cell line was cultured in chemically induced hypoxia for 12, 24, and 48 hours using a concentration of 200 µM cobalt chloride ($CoCl_2$; Sigma Aldrich, 15862-1ML-F).[42]

Western blot analysis

Proteins from the OLGA cell line, treated with 200 µM of $CoCl_2$ for 12, 24, and 48 ~~h~~ hours or untreated (DMSO alone), were extracted in lysis buffer (1% Triton X-100, 10% glycerol, 50mM Tris, 150mM sodium chloride, 2mM EDTA, pH 8.0, and 2mM magnesium chloride) containing Protease Inhibitor Cocktail (P8340 Sigma). Twenty micrograms of total proteins were separated ~~in~~ on a 10% SDS-PAGE ~~(10%)~~gel and transferred onto a 0.2 µm pore-size nitrocellulose membrane (Cytiva; Thermo Fisher Scientific). After washing, membranes were incubated in ~~TBS/BSA~~Tris-buffered saline with 10% ~~(~~bovine serum albumin~~)~~ at room temperature for 1 hour and then incubated overnight at 4°C with HIF1-α and CAIX antibodies; α-tubulin was used as a housekeeping protein (~~Supplementary~~ Supplemental Table S1). Horseradish peroxidase ~~(HRP)~~-conjugated secondary antibodies were diluted at 1:15.000. The chemiluminescence substrate (Clarity ECL Substrate; BIO-RAD Laboratories) was used to produce the light signal, acquired with CL-XPosure films (Thermo Fisher Scientific Inc).

Commented [15]: Please format the supplemental tables in an identical manner to the requested formatting of the main tables

Commented [RD16R16]: ok

Commented [17]: Is this supposed to be 1 to fifteen or 1 to fifteen thousand? If it is fifteen thousand, there should not be a period included.

Commented [RD18R18]: ok

Commented [RD19R18]: 1:15000

Immunofluorescence

To investigate the effects of $CoCl_2$ on HIF1-α nuclear translocation and CAIX expression, immunofluorescence against HIF1-α and CAIX was performed on OLGA cells exposed to the highest $CoCl_2$ concentration (200 µM) for 12, 24, and 48 hours. Briefly, $2x10^4$ cells were plated in eight-well chamber slides (Lab-Tek II Chamber

Slide System; Nalge Nunc International) until 70% confluence. After treatment, cells were fixed with methanol:acetone (1:1 proportion) for 30 seconds. After washing three times with Tris-HCl (0.1M, pH 7.6), cells were blocked with 10% normal goat serum for 1 hour at room temperature and then incubated overnight at 4°C with antibodies to HIF-1α (1:100) and CAIX (1:200). After washing with Tris-HCl, cells were incubated with a fluorescent secondary Alexa488-conjugated goat anti-rabbit IgG antibody (1:500 dilution, ThermoFisher) and anti-mouse IgG (1:500) for 1 hour ~~at~~ in the dark. Subsequently, cell nuclei were stained with DAPI (0.5μg/ml in Tris-HCl, Sigma–Aldrich, USA) for 10 minutes, washed three times with Tris-HCl, and then the sections were covered with mounting medium (PermaFluor, Thermo Scientific) and kept overnight in the dark. Fields were randomly selected by Leica TCS SP8 (Leica Microsystems CMS GmbH, Mannehim, Germany) and z-stacks of 10 nm were acquired. Z-stacks were then processed directly with the Leica LAS-X software to produce maximum projection images of each field. To detect co-localization of different fluorochromes, fluorescent signals in different channels were merged to produce multi-color images. Image acquisitions were performed with a resolution of 1024 x 1024 pixels with a 200 Hz sampling frequency.

Commented [20]: Please state what type of microscope the images were captured on

Commented [RD21R21]: Leica TCS SP8 (Leica Microsystems CMS GmbH, Mannehim, Germany)

Statistical analyses

Fisher's ~~Exact~~ exact test or the chi-squared test was used to test possible associations among immunohistochemical markers expression and~~,~~ clinical and histopathological data. Disease -free interval ~~DFI~~ (DFI ~~disease -free interval~~) was calculated as the time ~~elapsing~~ between surgery and the first detection of metastases and/or local recurrence, while overall survival (OS) ~~(overall survival)~~ was

defined as the period from the day of surgery to the patient's death due to a cancer-related cause. The survival functions of the DFI and OS were estimated with the Kaplan-Meier method, and the comparison of survival function was done by means of the log-rank test. Dogs that died from unrelated causes, were lost to follow-up, or were still alive at the end of the study were right-censored. Univariate and multivariate Cox models were fitted to verify the effects of hypoxia biomarkers on DFI or OS. In multivariate analysis, we considered the following parameters: HIF-1α, CXCR4, VEGFA, GLUT1, and CAIX immunohistochemical expression. Statistical significance was set at a 0.05 level. Because the clinical samples belonging to stage I were censored, this stage was omitted. GraphPad Prism 8 (GraphPad Software, San Diego, California) and R statistical software (R Core Team, 2018) were used for statistical analysis.

RESULTS

Patient and tumor characteristics

A total of 36 dogs with COMM met the inclusion criteria. Clinical and follow-up data, and histopathological and immunohistochemical diagnostic features are provided in Tables 1 and Table 2, respectively. Survival analysis (Fig.1) showed that dogs with clinical stage IV had a worse prognosis compared to dogs with clinical stages II and III (p=0.002). Similarly, as shown in Figure 2, vaccinated dogs had a significantly higher OS time compared to non-vaccinated dogs (p<0.001) (Fig. 2). Although not significant, we found that COMMs with a total absence of melanin pigment or less than 25% pigmented neoplastic cells were associated with a lower DFI when compared to tumors with > 50% pigmented neoplastic cells (median DFI:

Commented [22]: Please write-out COMMs in the title of Table 2.

Please remove the vertical lines surrounding the table and separating the columns.

Please change the asterisk to a superscript 'a'

Commented [RD23R23]: Ok

days 180 vs 210 days, respectively, p = 0.06). ~~There~~ The OS was ~~also~~ not significantly ~~association~~ associated ~~with OS~~the amount of pigmentation (median OS: 235 days vs 778 days, p = 0.08), and none of the other histopathological parameters showed prognostic significance.

Overexpression of hypoxic markers negatively affects prognosis in dogs receiving immunotherapy.

The immunohistochemical scores for HIF-1α, CAIX, GLUT-1, CXCR4, and VEGF-A are summarized in Table 3. Representative images are shown in Figure 3. ~~Interestingly, t~~The CAIX score was associated with the HIF-1α score (p = 0.001). Additionally, we found a statistical association between CXCR4 and Ki-67 index (p= 0.046) (Table 4). Multivariate analysis revealed that dogs receiving immunotherapy and overexpressing HIF-1α, VEGF-A, and CXCR4 had a significantly shorter DFI (median = 111 days) compared to dogs with the same treatment ~~but~~ that were negative for all three markers or only positive ~~to~~ for 1 or 2 markers (median = 204 days; p = 0.03) (Fig. 4), while no significant differences were observed for OS.

Multivariate analysis in non-vaccinated patients revealed no statistically ~~significance~~ significant differences in OS ~~and~~ or DFI between dogs with concomitant overexpression of HIF-1α, VEGF-A, and CXCR4 and dogs negative ~~to~~ for the markers or expressing only one or two markers.

CoCl2 treatment induces HIF-1α accumulation and nuclear translocation

~~As illustrated in Figure 5, distinct~~ Distinct bands corresponding to HIF-1α (120 kDa) and CAIX (58 kDa) proteins were more pronounced in the Olga cell line treated with $CoCl_2$ at 12 and 24 hours (Fig. 5). In contrast, the expression of these proteins was either negative (HIF-1α) or very low (CAIX) in untreated cells (Fig. 5).

Commented [24]: Please remove the vertical lines surrounding the table and separating the columns. Please change the asterisk to a superscript "a". Details about formatting tables are provided in the Instructions to Authors. Please define all abbreviations in the footnotes as described above.

Commented [25R25]: Please change "Staining" in the title of the second column to "Labeling" or "immunolabeling"

Commented [RD26R25]: Ok

Commented [27]: Please remove the lines from the table and define abbreviations as described in the comments for Table 1

Commented [RD28R28]: Ok

A mild increase of CAIX protein was also present in chemically-induced hypoxic conditions after 24 hours. ~~As depicted in Figure 6, under~~ Under normoxic conditions, HIF-1α was primarily localized to the cytoplasm, with nuclear localization becoming evident only after $CoCl_2$ treatment (Fig. 6). In contrast, chemically induced hypoxia did not yield noticeable effects on CAIX protein.

DISCUSSION

COMM is the most commonly diagnosed malignant tumor occurring in the oral cavity of dogs,[16,54] and it has a high and rapid metastatic rate, resulting in a poor prognosis.[3] Recently, a consensus working group was founded[55] to identify potential prognostic markers in this neoplasm and to give accurate recommendations for the diagnosis and histopathologic prognostication of canine melanocytic tumors.[55] Although nuclear atypia, MC (mitotic count,) and Ki-67 index are considered the most prognostic factors for COMM, the identification of new markers may improve the ability to prognosticate these neoplasms, as well as aiding in the selection of specific therapies.

In this study, we observed that patients with advanced clinical stages (III and IV) had a shorter overall survivalOS compared to stage II patients, which is consistent with existing literature.[3] Furthermore, our data confirmed that anti-*CSPG4* vaccination significantly increased the overall survival of COMM patients.[40,46]

Interestingly, smaller amounts of melanin in the COMMs seem to be weakly associated with shorter DFI, suggesting a close association between loss of melanin pigment and tumor dedifferentiation, which may be associated with a more aggressive behavior. This finding doesn't represent a novelty because in 2011, Smedley et al. suggested that a lower level of pigmentation (<50% of pigmented cells) is an unfavorable factor.[54] In human cutaneous melanoma, decreased pigmentation has also been linked to an aggressive phenotype with implications for prognosis and response to therapy.[6,53]

As previously reported in a number of canine tumor histotypes, a correlation between CAIX and HIF-1α positivity has been observed, suggesting hypoxia may

trigger microenvironment acidosis with metabolic changes in cancer cells growth.[36] Our findings reinforce the close interaction between these molecules and highlight the strong HIF-1α-dependent regulation of CAIX as an adaptation of COMM cells to extracellular acidosis.[61] This adaptation may enhance the tumor's ability to survive and grow under adverse conditions.

We found that CXCR4 expression was associated with an increased Ki-67 index, which is consistent with previous reports in human renal carcinomas[9] and multicentric lymphoma.[63] However, in human cutaneous melanomas, these markers ~~were~~ have not been significantly associated.[31,32,60]

Univariate data analysis for the hypoxic markers did not show any statistical significance for DFI or OS. However, these markers are interconnected in the hypoxic cellular pathway signaling. Hence, we investigated the prognostic value of their co-expression**.** Multivariate data analysis revealed that concurrent expression of HIF-1α, VEGF-A and CXCR4 in COMMs treated with ~~anti-~~a *CSPG4* vaccine is associated with a lower DFI compared to COMMs negative for these markers. This suggests a lower efficacy of ~~anti-~~*CSPG4* vaccination in tumors displaying hypoxic features. This finding is in line with the literature, in which hypoxia is known to induce immune-resistance and negatively interferes with immune surveillance of tumors, as well as adoptive immunotherapy.[2,24,62] Likewise, co-expression of hypoxic markers and hypoxia-related signatures have been documented in several human cancer as predictive of a poor outcome.[7,26,64] This co-expression triggers the activation of HIF-1α-dependent pathways, which can lead to tumor growth, angiogenesis, and metastasis.[8] Regarding the relationship between hypoxic microenvironments and CSPG4 expression, it's very interesting to underscore that in human melanomas, CSPG4 is regulated by hypoxia in vitro and its expression confers resistance to immunotherapy.[23,41] On the basis of

the preliminary data obtained by the authors, we can hypothesize that in dogs, CSPG4 is regulated by hypoxia, strengthening COMM as a good model for comparative oncology.[34]

To gain insight into the mechanisms of hypoxia in COMM, the OLGA cell line was treated with $CoCl_2$ to mimic~~king~~ a hypoxic stimulus.[13] We found that *in vitro* hypoxia induction caused an accumulation of HIF-1α protein after treatment. HIF-1α induction and stabilization triggered by hypoxia was further corroborated by ~~the results of~~ immunofluorescence, in which nuclear translocation under $CoCl_2$ treatment to avoid proteasomal degradation was demonstrated.[50] In the nucleus, HIF-1α is known to directly coordinate the transcription of ~~HRE~~hypoxia-regulating elements.[49] Consistent with the immunohistochemical results, CAIX protein levels were also mildly increased under chemically induced hypoxia. Its accumulation was delayed as compared to HIF-1α, thus supporting the direct role of HIF-1α in the upregulation of this protein.[21]

In conclusion, our results reinforce the crucial role of a hypoxic microenvironment and acidification in tumor aggressiveness and outcome in COMM, as extensively established in other canine[14,57] and human cancers.[5] It becomes critical to develop novel therapeutic strategies considering the hypoxic status of the tumors, and future studies should address the *in vitro* effects of hypoxia in COMM cells and investigate the inhibition of hypoxia-related signaling pathways as potential therapeutic targets. Notably, as shown in this study, it is crucial to consider the interdependent actions of the molecular mechanisms triggered by HIF-1α and its transcriptional cascade.

REFERENCES

1. Abou Khouzam R, Brodaczewska K, Filipiak A, et al. Tumor Hypoxia Regulates Immune Escape/Invasion: Influence on Angiogenesis and Potential Impact of Hypoxic Biomarkers on Cancer Therapies. *Front Immunol*. 2020;**11**:613114.

2. Barsoum IB, Smallwood CA, Siemens DR, Graham CH. A mechanism of hypoxia-mediated escape from adaptive immunity in cancer cells. Vol. 74, *Cancer Res*. 2014:665–674.

3. Bergman PJ. Canine oral melanoma. 2007;**22**(2):55–60.

4. Bergman PJ. Melanoma. In: *Clinical Small Animal Internal Medicine*. John Wiley & Sons, Ltd 2020:1347–1352.

5. Bhandari V, Hoey C, Liu LY, et al. Molecular landmarks of tumor hypoxia across cancer types. *Nat Genet*. 2019;**51**(2):308–318.

6. Cabaço LC, Tomás A, Pojo M, Barral DC. The Dark Side of Melanin Secretion in Cutaneous Melanoma Aggressiveness. *Front Oncol*. 2022;**12**:887366.

7. Cangelosi D, Morini M, Zanardi N, et al. Hypoxia Predicts Poor Prognosis in Neuroblastoma Patients and Associates with Biological Mechanisms Involved in Telomerase Activation and Tumor Microenvironment Reprogramming. *Cancers (Basel)*. 2020;**12**(9):2343.

8. Chatterjee S, Azad BB, Nimmagadda S. The Intricate Role of CXCR4 in Cancer. *Adv Cancer Res*. 2014;**124**:31–82.

9. Czajkowski M, Kaemmerer D, Sänger J, et al. Comparative evaluation of somatostatin and CXCR4 receptor expression in different types of thyroid carcinoma using well-characterised monoclonal antibodies. *BMC Cancer*. 2022;**22**(1):740.

10. D'Aguanno S, Mallone F, Marenco M, Del Bufalo D, Moramarco A. Hypoxia-dependent drivers of melanoma progression. *J Exp Clin Cancer Res*. 2021;**40**(1):159.

11. Devarajan N, Manjunathan R, Ganesan SK. Tumor hypoxia: The major culprit behind cisplatin resistance in cancer patients. Vol. 162, *Crit Rev Oncol Hematol*. 2021:103327.

12. Dratkiewicz E, Simiczyjew A, Mazurkiewicz J, Ziętek M, Matkowski R, Nowak D. Hypoxia and Extracellular Acidification as Drivers of Melanoma Progression and Drug Resistance. *Cells*. 2021;**10**(4):862.

13. Gola C, Giannuzzi D, Rinaldi A, et al. Genomic and Transcriptomic Characterization of Canine Osteosarcoma Cell Lines: A Valuable Resource in Translational Medicine. 2021/06/04 ed. 2021;**8**:666838.

14. Gola C, Iussich S, Noury S, et al. Clinical significance and in vitro cellular regulation of hypoxia mimicry on HIF-1α and downstream genes in canine appendicular osteosarcoma. Vol. 264, *Vet J*. 2020:105538.

15. Graham K, Unger E. Overcoming tumor hypoxia as a barrier to radiotherapy, chemotherapy and immunotherapy in cancer treatment. 20181004th ed. 2018;**13**:6049–6058.

16. Hernandez B, Adissu HA, Wei BR, Michael HT, Merlino G, Simpson RM. Naturally Occurring Canine Melanoma as a Predictive Comparative Oncology Model for Human Mucosal and Other Triple Wild-Type Melanomas. Vol. 19, *Int J Mol Sci*. 2018:

17. Hino Y, Rahman MM, Lai YC, et al. Hypoxic miRNAs expression are different between primary and metastatic melanoma cells. Vol. 782, *Gene*. 2021:145552.

18. Infantino V, Santarsiero A, Convertini P, Todisco S, Iacobazzi V. Cancer Cell Metabolism in Hypoxia: Role of HIF-1 as Key Regulator and Therapeutic Target. Vol. 22, *Int J Mol Sci*. 2021:

19. Jing X, Yang F, Shao C, et al. Role of hypoxia in cancer therapy by regulating the tumor microenvironment. Vol. 18, *Mol Cancer*. 2019:157.

20. Jun JC, Rathore A, Younas H, Gilkes D, Polotsky VY. Hypoxia-Inducible Factors and Cancer. 2017/09/26 ed. 2017;**3**(1):1–10.

21. Kaluz S, Kaluzová M, Liao S-Y, Lerman M, Stanbridge EJ. Transcriptional control of the tumor- and hypoxia-marker carbonic anhydrase 9: A one transcription factor (HIF-1) show? *Biochim Biophys Acta*. 2009;**1795**(2):162–172.

22. Ke Q, Costa M. Hypoxia-inducible factor-1 (HIF-1). 20060803rd ed. 2006;**70**(5):1469–1480.

23. Keleg S, Titov A, Heller A, et al. Chondroitin sulfate proteoglycan CSPG4 as a novel hypoxia-sensitive marker in pancreatic tumors. *PLoS One*. 2014;**9**(6):e100178.

24. Kopecka J, Salaroglio IC, Perez-Ruiz E, et al. Hypoxia as a driver of resistance to immunotherapy. Vol. 59, *Drug Resist Updat*. 2021:100787.

25. Liu Y, Zhang F, Zhang Z, et al. High expression levels of Cyr61 and VEGF are associated with poor prognosis in osteosarcoma. Vol. 213, *Pathol Res Pract*. 2017:895–899.

26. Luan L, Dai Y, Shen T, et al. Development of a novel hypoxia-immune–related LncRNA risk signature for predicting the prognosis and immunotherapy response of colorectal cancer. *Front Immunol*. 2022;**13**:951455.

27. Majmundar AJ, Wong WJ, Simon MC. Hypoxia-inducible factors and the response to hypoxic stress. Vol. 40, *Mol Cell*. 2010:294–309.

28. Malekan M, Ebrahimzadeh MA, Sheida F. The role of Hypoxia-Inducible Factor-1alpha and its signaling in melanoma. Vol. 141, *Biomed Pharmacother*. 2021:111873.

29. Mayayo SL, Prestigio S, Maniscalco L, et al. Chondroitin sulfate proteoglycan-4: a biomarker and a potential immunotherapeutic target for canine malignant melanoma. Vol. 190, *Vet J*. 2011:e26-30.

30. Meier V, Guscetti F, Roos M, Ohlerth S, Pruschy M, Rohrer Bley C. Hypoxia-Related Marker GLUT-1, CAIX, Proliferative Index and Microvessel Density in Canine Oral Malignant Neoplasia. Vol. 11, *PLoS One*. 2016:e0149993.

31. Mitchell B, Mahalingam M. The CXCR4/CXCL12 axis in cutaneous malignancies with an emphasis on melanoma. *Histol Histopathol*. 2014;**29**(12):1539–1546.

32. Murakami T, Cardones AR, Hwang ST. Chemokine receptors and melanoma metastasis. *J Dermatol Sci*. 2004;**36**(2):71–78.

33. Noguchi S, Yagi K, Okamoto N, Wada Y, Tanaka T. Prognostic Factors for the Efficiency of Radiation Therapy in Dogs with Oral Melanoma: A Pilot Study of Hypoxia in Intraosseous Lesions. 2023;**10**(1):4.

34. Paoloni M, Khanna C. Translation of new cancer treatments from pet dogs to humans. Vol. 8, *Nat Rev Cancer*. 2008:147–156.

35. Parks SK, Cormerais Y, Marchiq I, Pouyssegur J. Hypoxia optimises tumour growth by controlling nutrient import and acidic metabolite export. Vols. 47–48, *Mol Aspects Med*. 2016:3–14.

36. Parks SK, Cormerais Y, Pouyssegur J. Hypoxia and cellular metabolism in tumour pathophysiology. Vol. 595, *J Physiol*. 2017:2439–2450.

37. Pazzi P, Steenkamp G, Rixon AJ. Treatment of Canine Oral Melanomas: A Critical Review of the Literature. Vol. 9, *Vet Sci*. 2022:

38. Petrova V, Annicchiarico-Petruzzelli M, Melino G, Amelio I. The hypoxic tumour microenvironment. 2018;**7**(1):1–13.

39. Petty JC, Lana SE, Thamm DH, et al. Glucose transporter 1 expression in canine osteosarcoma. Vol. 6, *Vet Comp Oncol*. 2008:133–140.

40. Piras LA, Riccardo F, Iussich S, et al. Prolongation of survival of dogs with oral malignant melanoma treated by en bloc surgical resection and adjuvant CSPG4-antigen electrovaccination. Vol. 15, *Vet Comp Oncol*. 2017:996–1013.

41. Pucciarelli D, Lengger N, Takacova M, et al. Anti-chondroitin sulfate proteoglycan 4-specific antibodies modify the effects of vemurafenib on melanoma cells differentially in normoxia and hypoxia. *Int J Oncol*. 2015;**47**(1):81–90.

42. Rana NK, Singh P, Koch B. CoCl2 simulated hypoxia induce cell proliferation and alter the expression pattern of hypoxia associated genes involved in angiogenesis and apoptosis. Vol. 52, *Biol Res*. 2019:12.

43. Rankin EB, Nam JM, Giaccia AJ. Hypoxia: Signaling the Metastatic Cascade. Vol. 2, *Trends Cancer*. 2016:295–304.

44. Ren Z, Liang S, Yang J, et al. Coexpression of CXCR4 and MMP9 predicts lung metastasis and poor prognosis in resected osteosarcoma. Vol. 37, *Tumour Biol*. 2016:5089–5096.

45. Riccardo F, Iussich S, Maniscalco L, et al. CSPG4-specific immunity and survival prolongation in dogs with oral malignant melanoma immunized with human CSPG4 DNA. 2014/05/31 ed. 2014;**20**(14):3753–3762.

46. Riccardo F, Iussich S, Maniscalco L, et al. CSPG4-specific immunity and survival prolongation in dogs with oral malignant melanoma immunized with human CSPG4 DNA. 2014/05/31 ed. 2014;**20**(14):3753–3762.

47. Sánchez-Céspedes R, Accornero P, Miretti S, et al. In vitro and in vivo effects of toceranib phosphate on canine osteosarcoma cell lines and xenograft orthotopic models. Vol. 18, *Vet Comp Oncol*. 2020:117–127.

48. Satija S, Kaur H, Tambuwala MM, et al. Hypoxia-Inducible Factor (HIF): Fuel for Cancer Progression. Vol. 14, *Curr Mol Pharmacol*. 2021:321–332.

49. Schito L, Semenza GL. Hypoxia-Inducible Factors: Master Regulators of Cancer Progression. Vol. 2, *Trends Cancer*. 2016:758–770.

50. Semenza GL. Oxygen sensing, hypoxia-inducible factors, and disease pathophysiology. Vol. 9, *Annu Rev Pathol*. 2014:47–71.

51. Serocki M, Bartoszewska S, Janaszak-Jasiecka A, Ochocka RJ, Collawn JF, Bartoszewski R. miRNAs regulate the HIF switch during hypoxia: a novel therapeutic target. 20180127th ed. 2018;**21**(2):183–202.

52. Singleton DC, Macann A, Wilson WR. Therapeutic targeting of the hypoxic tumour microenvironment. *Nat Rev Clin Oncol*. 2021;**18**(12):751–772.

53. Slominski RM, Zmijewski MA, Slominski AT. The role of melanin pigment in melanoma. *Exp Dermatol*. 2015;**24**(4):258–259.

54. Smedley RC, Spangler WL, Esplin DG, et al. Prognostic markers for canine melanocytic neoplasms: a comparative review of the literature and goals for future investigation. Vol. 48, *Vet Pathol*. 2011:54–72.

55. Smedley RC, Bongiovanni L, Bacmeister C, et al. Diagnosis and histopathologic prognostication of canine melanocytic neoplasms: A consensus of the Oncology-Pathology Working Group. *Vet Comp Oncol*. 2022;**20**(4):739–751.

56. Smedley RC, Sebastian K, Kiupel M. Diagnosis and Prognosis of Canine Melanocytic Neoplasms. *Vet Sci*. 2022;**9**(4):175.

57. Snyder SA, Dewhirst MW, Hauck ML. The role of hypoxia in canine cancer. *Vet Comp Oncol*. 2008;**6**(4):213–223.

58. Spangler WL, Kass PH. The histologic and epidemiologic bases for prognostic considerations in canine melanocytic neoplasia. *Vet Pathol.* 2006 Mar;**43**(2):136-49.

59. Tarone L, Barutello G, Iussich S, et al. Naturally occurring cancers in pet dogs as pre-clinical models for cancer immunotherapy. Vol. 68, *Cancer Immunol Immunother*. 2019:1839–1853.

60. Torres-Cabala C, Li-Ning-Tapia E, Hwu W-J. Pathology-based Biomarkers Useful for Clinical Decisions in Melanoma. *Arch Med Res*. 2020;**51**(8):827–838.

61. Trojan SE, Piwowar M, Ostrowska B, Laidler P, Kocemba-Pilarczyk KA. Analysis of Malignant Melanoma Cell Lines Exposed to Hypoxia Reveals the Importance of PFKFB4 Overexpression for Disease Progression. 2018;**38**(12):6745–6752.

62. Wang B, Zhao Q, Zhang Y, et al. Targeting hypoxia in the tumor microenvironment: a potential strategy to improve cancer immunotherapy. *J Exp Clin Cancer Res*. 2021;**40**(1):24.

483 63. Weber TS. Cell Cycle-Associated CXCR4 Expression in Germinal Center B Cells and Its
484 Implications on Affinity Maturation. 2018;**9**.

485 64. Yang X, Weng X, Yang Y, et al. A combined hypoxia and immune gene signature for predicting
486 survival and risk stratification in triple-negative breast cancer. *Aging (Albany NY)*.
487 2021;**13**(15):19486–19509.

488

489

LEGEND OF THE FIGURES

Figure 1

Kaplan-Meier survival curves for stage II, III, and IV canine oral malignant melanomas. (a) ~~Disease~~ Disease-free interval (DFI) ~~and~~. (b) ~~Overall~~ Overall ~~Survival~~ survival (OS) ~~curves of COMMs patients with respect to clinical stages II, III and IV~~. Stage II (median DFI = 187 days, ~~Median~~ median OS~~:~~ = 397 days); Stage III~~3~~ (median DFI = 209 days, median OS = 260 days); Stage IV4 (median DFI = 36 days, median OS= 76). ~~p values:~~ DFI: p = 0.06 ~~and~~, OS: p = 0.002

Figure 2

Kaplan-Meier survival curves of dogs with canine oral malignant melanomas treated with or without *chondroitin sulfate proteoglycan-4* (*CSPG4*) DNA vaccination. (a) ~~Disease~~ Disease-free interval (DFI). Vaccinated median DFI = 205 days, not vaccinated median DFI = 187 days (p > 0.05). ~~and~~ (b) Overall ~~Survival~~ survival (OS). Vaccinated median OS = 972 days, not vaccinated median OS = 215 days (p<0.001)~~curves of COMMs (canine oral malignant melanomas) patients treated with CSPG4 (chondroitin sulfate proteoglycan-4)/DNA vaccination with respect to COMMs patients treated with *en- bloc* surgery alone, (median OS: 972 days versus 215 days p<0,001); (median DFI 205 days versus 187 days (p>0.05)~~.

Commented [29]: Please capitalize 'not' in the key for Figure 2.

Commented [RD30R30]: Ok

Figure 3

~~Melanomas~~Immunohistochemistry (IHC) for hypoxia-associated factors in canine oral malignant melanomas, dog. (a) ~~diffuse~~ Diffuse moderate cytoplasmic immunolabeling for ~~VEGFA (Vascular~~ vascular endothelial growth factor A (VEGFA) in amelanotic melanoma. VEGFA IHC. (b) ~~diffuse~~ Diffuse strong cytoplasmic and membrane immunolabeling for ~~CXCR4 (~~C-X-C chemokine receptor type 4 (CXCR4) in spindle amelanotic melanoma. CXCR4 IHC. (c) ~~multifocal~~ Multifocal nuclear immunolabeling for ~~HIF-1 α (Hypoxia~~hypoxia-inducible factor-1α (HIF-1α) in poorly melanotic melanoma. HIF-1α IHC. (d) ~~multifocal~~ Multifocal moderate cytoplasmic immunolabeling for ~~GLUT1 (Glucose~~ glucose transporter 1 (GLUT1) in poorly melanotic melanoma. GLUT1 IHC. (e) ~~diffuse~~ Diffuse weak cytoplasmic immunolabeling for ~~CAIX (Carbonic~~ carbonic anhydrase IX (CAIX) in poorly melanotic melanoma. CAIX IHC. (f) ~~negative~~ Negative reagent control. ~~DAB~~ diaminobenzidine chromogen~~.~~, hematoxylin counterstain.

Figure 4

Kaplan-Meier survival curves of dogs with canine oral malignant melanomas treated with chondroitin sulfate proteoglycan-4 DNA vaccination that either co-express hypoxia-inducible factor-1α (HIF-1α), C-X-C chemokine receptor type 4 (CXCR4), and vascular endothelial growth factor A (VEGFA) or lack the expression of at least one of protein (others). (a) ~~Disease~~ Disease-free interval (DFI). Patients overexpressing HIF-1α, CXCR4, and VEGFA had significant shorter DFIs ($p < 0.05$) compared to dogs that were negative for all three markers, as well as those positive to only 1 or 2 markers (others). ~~and~~ (b) Overall ~~Survival~~ survival (OS). There were no statistically significant differences in OS ($p > 0.05$). ~~curves of COMMs (canine oral malignant melanomas) patients vaccinated with CSPG4 (chondroitin sulfate proteoglycan 4). As shown in the figure, patients overexpressing HIF-1α (hypoxia-~~

Commented [31]: Nuclear staining is not evident in this image. While there are darkly labeled areas, it is not clear where those areas are. The recognizable nuclei are not staining.

Commented [32R32]: One approach to address the AE's concern is to provide an image where the signal is less saturated and the chromatin pattern of the nucleus is more apparent.

Commented [RD33R32]: According to suggestions the figure 3 C has been replaced with nuclear staining is more evident

537 inducible factor-1α), CXCR4 (C-X-C chemokine receptor type 4) and VEGFA
538 (vascular endothelial growth factor A) showed a significant shorter DFI (p<0.05) with
539 respect to negative COMMs for all three markers, as well as those positive to only 1
540 or 2 markers. OS (p>0.05)

541 **Figure 5**

542 Western- blot analysis of Olga cells that were untreated (Ctrl) or cells that were
543 treated for 12, 24, or 48 hours with cobalt chloride ($CoCl_2$) to induce hypoxic
544 conditions. HIF-1α, (hypoxia-inducible factor-1α),; CAIX, c(Carbonic anhydrase IX)
545 and α-tubulin. 20 µg total proteins were run on a 10% polyacrylamide-gel and
546 transferred to a nitrocellulose membrane. Visualization was performed by exposing
547 X-ray films on membranes incubated with secondary HRP-conjugated antibodies.
548 CTRL (not treated sample control)

549 **Figure 6**

550 Representative immunofluorescence staining of primary canine oral malignant
551 melanoma COMMs (canine oral malignant melanomas) OLGA cell line, either (a-d)
552 untreated (panels a-d) or (e-h) treated with 200 µm cobalt chloride ($CoCl_2$) (panel e-
553 h) for 24 hours. (a, e) Panel a and e show DAPI nuclear staining, in blue,. (b, f)
554 panel b and f HIF1-α (hypoxia-inducible factor-1α (HIF1-α), staining in green,. panel
555 c and g(c, g) CAIX (carbonic anhydrase IX (CAIX), staining in red,. and panel d and
556 h show the(d, h) merged fluorescent signals of DAPI, HIF1-α, and CAIX.

557

558 **Supplementary Figure 1**

559 Validation of IHC immunohistochemistry (IHC) antibodies on canine tissues. (a, b)
560 Hypoxia-inducible factor-1α (HIF-1α:) IHC. (a) haired Haired skin as, negative

tissue control. (a1) and (b) Mmammary carcinoma as, positive tissue control. (c-d) (a2); CXCR4C-X-C chemokine receptor type 4 IHC.: (c) Hhaired skin as, negative tissue control. (b1d) and mammary Mammary carcinoma as, positive tissue control. (b2); (e, f) glucose transporter 1 IHC. GLUT-1: (e) testis Testis,as negative tissue control. (f) (c1) and placenta Placenta,as positive tissue control (c2); . (g, h) Carbonic anhydrase IX.CAIX: (g) Ttestis, as negative tissue control. (h) (d1) and renal Renal cell carcinoma as, positive tissue control. (d2) - DAB chromogen, hematoxylin counterstain.

Commented [34]: Please submit the supplemental figure legend as a separate Word file.

Commented [35R35]: Please label the supplemental figure in the same manner other figures are labeled. I have adjusted the legend accordingly, but please change the letters on the figure.

Commented [RD36R35]: Done in the MAIN DOCUMENT (CLEAN COPY)

Authors' Contributions

RDM, CG, designed and performed the experimental design. SI, LM, performed histological diagnosis; LM, PM, KV performed IHC evaluations; EM, DG, MO enrolled and surgically treated COMMs

EM* performed statistical analysis.

PA EM** performed in vitro assay, western blot and immunofluorescence.

The manuscript was written by RDM, CG, LM with contribution of LA.