

## OPEN

# Absence of IL-6 Receptor Blockade Effect on the Outcomes of Transplant Glomerulopathy in the Absence of Anti-HLA Donor-specific Antibodies

Alberto Mella, MD, PhD,<sup>1</sup> Antonio Lavacca, MD,<sup>1</sup> Diana Teodora Dodoi, MD,<sup>1</sup> Roberto Presta, MD,<sup>1</sup> Fabrizio Fop, MSc,<sup>1</sup> Marco Campagna, MD<sup>1</sup> Ana Maria Manzione, MD,<sup>1</sup> Caterina Dolla, MD, PhD,<sup>1</sup> Ester Gallo, MD,<sup>1</sup> Isabella Abbasciano, MD,<sup>1</sup> Chiara Gai, PhD,<sup>2</sup> Giovanni Camussi, MD,<sup>2</sup> Antonella Barreca, MD, PhD,<sup>3</sup> Cristiana Caorsi, PhD,<sup>4</sup> Gloria Giovinazzo, MD,<sup>1</sup> and Luigi Biancone<sup>1</sup> MD, PhD<sup>1</sup>

**Background.** Transplant glomerulopathy (TG) is the hallmark of chronic antibody-mediated rejection but often occurs without anti-HLA donor-specific antibodies (DSAs) in the assumption that other DSAs may be the effectors of the tissue injury. Recently, we reported a positive effect of interleukin-6 (IL-6) receptor blocker tocilizumab (TCZ) in TG/DSA<sup>+</sup>. In the present study, we investigate the effect of TCZ in a cohort of TG cases without detectable anti-HLA DSAs. **Methods.** Single-center retrospective analysis of TG cases without anti-HLA DSAs (TG/DSA) treated with TCZ for chronic antibody-mediated rejection as first-line therapy evaluated through clinical, protocol biopsies, and gene expression analyses was included. **Results.** Differently from TG/DSA<sup>+</sup>, TG/DSA<sup>-</sup> showed a progressive reduction in the estimated glomerular filtration rate at 12 mo and after that with no significant modification in microvascular inflammation or C4d<sup>+</sup>. No upregulation in tight junction protein-1, aldo-keto reductase family 1 member C3, and calcium/calmodulin-dependent serine protein kinase, documented in TG/DSA<sup>+</sup>, was noted in post-TCZ biopsies. The reduction of microvascular inflammation was associated with natural killer-cell reduction in TG/DSA<sup>+</sup>, whereas TG/DSA<sup>-</sup> tends to maintain or increase periglomerular/interstitial infiltration. **Conclusions.** In the absence of anti-HLA DSAs, TG behavior seems not to be modified by IL-6 receptor blockade. These results are at variance with observational studies and previous trials with IL-6 inhibitors in TG associated with anti-HLA DSAs. These data may fuel the hypothesis of different mechanisms underlying TGs (including the potentially different roles of natural killer cells) and suggest carefully selecting patients with TG for clinical trials or off-label treatment based on their antidonor serologic status.

(*Transplantation Direct* 2024;10: e1638; doi: 10.1097/TXD.0000000000001638.)

Transplant glomerulopathy (TG) is a histological lesion characterized by reduplication/multilamination of the glomerular basement membrane in the absence of immune deposits.<sup>1</sup> Although the exact pathogenetic mechanism is currently unknown, TG is now considered the hallmark

of “chronic” antibody-mediated damage because of the interaction at the endothelial level between donor-specific antibodies (DSAs) and some non-self-antigens (primarily HLA).<sup>1,2</sup> This assumption is confirmed by the updated BANFF classification, which includes TG in chronic and

Received 22 August 2023. Revision received 3 March 2024.  
Accepted 7 March 2024.

<sup>1</sup> Renal Transplantation Center, “A. Vercellone,” Division of Nephrology Dialysis and Transplantation, Città Della Salute e Della Scienza Hospital and Department of Medical Sciences, University of Turin, Turin, Italy.

<sup>2</sup> Department of Medical Sciences, University of Turin, Turin, Italy.

<sup>3</sup> Division of Pathology, “Città Della Salute e Della Scienza” Hospital, Department of Medical Sciences, University of Turin, Turin, Italy.

<sup>4</sup> Immunogenetic and Transplant Biology Center, “Città Della Salute e Della Scienza” Hospital and Department of Medical Sciences, University of Turin, Turin, Italy.

Correspondence: Luigi Biancone, MD, PhD, Renal Transplantation Unit “A. Vercellone,” Division of Nephrology Dialysis and Transplantation, Città Della Salute e Della Scienza Hospital, and Department of Medical Sciences, University of Turin, Corso Bramante 88, 10126 Turin, Italy. (luigi.biancone@unito.it).

A.M. and A.L. participated in concept design, data collection, analysis, interpretation, and drafting the article. D.T.D. and R.P. participated in data collection, analysis, interpretation, and drafting the article. M.C., A.M.M., C.D.,

E.G., I.A., and G.G. participated in critical revision. C.G. and G.C. participated in gene expression analysis and drafting the article. A.B. participated in histological analysis and drafting the article. C.C. participated in donor-specific antibody analysis and drafting the article. F.F. participated in statistics and drafting the article. L.B. participated in concept design, analysis and interpretation, critical revision, and drafting the article.

The authors declare no funding or conflicts of interest.

Supplemental digital content (SDC) is available for this article. Direct URL citations appear in the printed text, and links to the digital files are provided in the HTML text of this article on the journal’s Web site ([www.transplantationdirect.com](http://www.transplantationdirect.com)).

Copyright © 2024 The Author(s). *Transplantation Direct*. Published by Wolters Kluwer Health, Inc. This is an open-access article distributed under the terms of the Creative Commons Attribution-Non Commercial-No Derivatives License 4.0 (CCBY-NC-ND), where it is permissible to download and share the work provided it is properly cited. The work cannot be changed in any way or used commercially without permission from the journal.

ISSN: 2373-8731

DOI: 10.1097/TXD.0000000000001638

chronic active antibody-mediated rejection (cAMR) definitions.<sup>3</sup> However, TG may also occur early after kidney transplantation<sup>4</sup> or be observed under different conditions or without documented DSAs,<sup>5</sup> posing the question of whether this lesion, despite an identical feature, suggests different pathological mechanisms and outcomes. Alternatively, several studies have suggested the presence of DSA other than anti-HLA antibodies,<sup>6</sup> with many different antigens as their targets.<sup>7</sup>

Treatment of cAMR is an unmet need, considering that late allograft dysfunction is predominantly related to this condition, and no specific treatment has been approved to date.<sup>1,8</sup> The anti-interleukin (IL)-6 receptor antibody tocilizumab (TCZ) has been used in cAMR with promising results in reducing alloantibodies, ameliorating rejection lesions, and slowing renal function deterioration,<sup>9</sup> as also documented by our group.<sup>10</sup> The extension of Choi et al<sup>11</sup> case series, additional reports, and a multicenter randomized controlled trial (RCT) with the anti-IL-6 monoclonal antibody clazakizumab suggests similar and positive findings<sup>12,13</sup> despite the fact that no RCT is to date available for TCZ and some side effects (eg, increased severe infection and bowel perforation, especially in patients with a history of diverticulosis) were observed.<sup>13</sup> Together, these results propose IL-6-directed therapies as a promising strategy for antibody-mediated late allograft damage, but data for patients without anti-HLA DSAs are still lacking.

We, therefore, evaluated the effect of TCZ in our cohort of TG cases with undetectable anti-HLA DSAs, analyzing clinical and histological data and gene expression analysis.

## MATERIALS AND METHODS

### Patients and Study Design

We performed a single-center, open-label, nonsponsored observational analysis at the Division of Nephrology, Dialysis and Transplantation of “Città Della Salute e Della Scienza di Torino” University Hospital. The local Ethical Committee approved this study (Comitato Etico Interaziendale A.O.U. Città Della Salute e Della Scienza di Torino – A.O. Ordine Mauriziano – A.S.L. Città di Torino, resolution number 1449/2019 on November 8, 2019—“TGT observational study”).

Between 2016 and 2019, 32 patients with TG (including all 15 kidney transplant recipients [KTRs] described in our previous report<sup>10</sup>) were treated with TCZ as first-line therapy for cAMR (diagnosed in all patients through an allograft biopsy performed for unexplained deterioration of renal function or persistent proteinuria, and analyzed according to the BANFF 2019 criteria<sup>3</sup>). The last follow-up was 01/12/2023. All patients had a g+ptc score  $\geq 1$ . TCZ was offered to every patient with these lesions because of the absence of registered drugs. Patients with cAMR who do not receive the drug because of preexisting clinical conditions are reported in Table S1 (SDC, <http://links.lww.com/TXD/A653>). As requested for this “off-label” use (approved for every patient by our internal pharmacological panel), all patients provided written informed consent after describing the potential risks and benefits of the drug; TCZ was continuously administered monthly at a dose of 8 mg/kg (maximum of 800 mg) and stopped only in case of severe adverse events or drug shortage (see below).

Security measures taken before initiation of TCZ are listed in Supplemental Material (SDC, <http://links.lww.com/TXD/A653>; Page 2).

A protocol graft biopsy was performed to analyze histological modifications and gene expression in all patients without clinical contraindications.

All TG patients received maintenance immunosuppression mainly composed of calcineurin inhibitors, mycophenolate mofetil (MMF)/mycophenolic acid, and steroids at the time of diagnosis. After TG documentation, the therapy was cautiously modified by introducing MMF/mycophenolic acid or steroids (with the suspension of mammalian target of rapamycin inhibitor, if used) or switching from cyclosporine A to tacrolimus in patients who were not already on tacrolimus/MMF/steroids.

All available sera were tested using a Luminex platform and commercially available SAB kits (LABScreen, One Lambda Inc, Canoga Park, CA) to identify HLA class I and II IgG DSAs (mean fluorescence intensity [MFI] cutoff value 1000).

### Gene Expression Analysis

In gene expression analysis, we evaluated the baseline and available protocol biopsy, also including 4 patients with normal histology and similar clinical characteristics (control group). For each sample, total RNA was extracted from 3 pieces of 10  $\mu\text{m}$  sections of Serra’s fluid-fixed, paraffin-embedded samples by PureLink FFPE Total RNA Isolation Kit (Invitrogen, Thermo Fisher Scientific) according to the manufacturer’s instructions. RNA concentration was assessed using a MySpec instrument (VWR), and cDNA was produced from 400 ng of total RNA using the Super Script IV VILO Master Mix with ezDNase enzyme (Invitrogen, Thermo Fisher Scientific). In addition, the expression profile of a panel of 43 endothelial, mesangial, and podocyte genes directly involved in antibody-mediated rejection or glomerulonephritis (Table S2, SDC, <http://links.lww.com/TXD/A653>) was also tested. Gene expression for each target gene and 5 endogenous controls (CTRs) was measured using a specific TaqMan Gene Expression Assay (Thermo Fisher Scientific) spotted on a custom TaqMan Array microfluidic card (Thermo Fisher Scientific). The samples were mixed with TaqMan Fast Advanced Master Mix (Thermo Fisher Scientific), and TaqMan Array microfluidic cards were prepared according to the manufacturer’s instructions and run using the QuantStudio 12K Flex Real-Time PCR System (Thermo Fisher Scientific). Each sample was run in duplicate. Retrotranscription negative CTRs (no retrotranscription enzyme) were run for 4 samples. A no-template control (no cDNA) was run once on a TaqMan Array microfluidic card. Both negative CTRs showed no amplification at Ct  $< 37$ . ExpressionSuite Software version 1.0.3 (Thermo Fisher Scientific) was used to calculate relative quantification values by the  $2^{-\Delta\Delta\text{Ct}}$  method. Values of Ct  $> 37$  or Cq conf  $< 0.6$  were excluded from the analysis. 18S and NPHS2 were set as endogenous CTRs for multiple endogenous control analyses. Data were normalized to the expression level of healthy CTRs.

### Histological Analysis of Frozen Sections for Natural Killer-cell Evaluation

Serial separated available sections of frozen tissue pre- and post-TCZ were fixed in cold acetone for 10 min, washed with 0.1% PBS-bovine serum albumin, blocked with 1%

PBS-bovine serum albumin, and subsequently incubated with anti-human monoclonal CD56 (NCAM1) FITC-conjugated (MiltenyiBiotec; 1:50) and anti-human CD335 (NKp46) PE-conjugated (MiltenyiBiotec; 1:50) for 1 h at room temperature. The sections were washed again, nuclear stained with 4',6-diamidino-2-phenylindole, mounted, and observed under a confocal microscope (Leica SP5, Leica Microsystems). Digital images were processed using Fiji-ImageJ software.<sup>14</sup>

### Statistical Analysis

Statistical analyses were performed using SPSS (IBM SPSS Statistics, version 25.0.0). According to their distribution, continuous variables were presented as mean  $\pm$  SD or median and interquartile range. Normal distribution was analyzed using the Kolmogorov-Smirnov test. The differences between before and after observations were analyzed using a paired Student *t* test or Wilcoxon test. Categorical variables were presented as fractions.

We additionally used a general linear model to evaluate the homogeneity of the slope of the estimated glomerular filtration rate (eGFR) trend before and after TCZ therapy.

The significance level was set to alpha of <0.05 for all tests.

## RESULTS

### Baseline Characteristics of TG TCZ-treated Population

Among the 32 KTRs with cAMR who received TCZ treatment, 15 of 32 showed TG without detectable anti-HLA DSAs (TG/DSA<sup>-</sup>). All clinical and donor characteristics, including eGFR and proteinuria at discharge, were reported in Table 1, whereas histological features according to BANFF scores are included in Table 2. As expected, patients with TG/DSA<sup>-</sup> have low C4d positivity 3 of 15 (20%) but documented microvascular inflammation (MVI; medium score pre-TCZ 3 [1–4]).

### TCZ Appears not to Improve Functional, Histological, or Gene Expression Parameters in TG/DSA<sup>-</sup>

During this analyzed period, TG/DSA<sup>+</sup> showed similar baseline characteristics apart from high C4d<sup>+</sup> (12/17 [70.6%] versus 3/15 [20%] in TG/DSA<sup>-</sup>; *P* = 0.049) with histological amelioration (MVI from 3 [2–4] to 2 [1–3], *P* = 0.019 and C4d<sup>+</sup> from 70.6% to 52.9%, *P* = 0.049, respectively) and functional stabilization ( $\Delta$ eGFR  $-13.7$  mL/min/1.73 m<sup>2</sup> [–23 to 3.3] pre-TCZ versus  $-4$  mL/min/1.73 m<sup>2</sup> [–8.8 to 5.6] post-TCZ; *P* = 0.407) after TCZ.

In TG/DSA<sup>-</sup>, a protocol graft biopsy was performed at a median of 10.8 mo (9.6–13.4) after TCZ initiation in 9 of 15 patients.

After TCZ treatment started at a median time of 2.9 mo (1.1–5.9) after the baseline biopsy, g<sub>+</sub>ptc score (3 [1–4] versus 2 [0.25–4]; *P* = 0.129) and C4d<sup>+</sup> (*P* = 0.129) remained unchanged in TG/DSA<sup>-</sup> with a combined increase in vascular fibrointimal thickening (*P* = 0.014; Figure 1).

Additionally, TG/DSA<sup>-</sup> maintained the trajectory of a significant eGFR reduction (from 40.7 mL/min/1.73 m<sup>2</sup> [27.0–44.4] to 26.6 [13.9–37] with  $\Delta$ eGFR  $-9.8$  mL/min/1.73 m<sup>2</sup> [–22.3 to –3.7] pre-TCZ versus  $-10$  mL/min/1.73 m<sup>2</sup> [–25 to

**TABLE 1.**

### Baseline characteristics of the studied population

	TG/DSA <sup>-</sup> (N = 15)
Recipient characteristics	
Age at transplant, y, median (IQR)	43 (36.9–46.2)
Sex male, n (%)	10 (66.7)
Previous kidney transplantation, n (%)	2 (11.8)
HCV positivity, n (%)	2 (15.4)
ESRD cause	
Glomerulonephritis, n (%)	5 (33.3)
Genetic diseases, n (%)	1 (6.7)
ADPKD/cystic nephropathy, n (%)	3 (20)
Diabetes, n (%)	0 (0)
Hypertensive nephropathy, n (%)	1 (6.7)
Others, n (%)	2 (13.3)
Unknown, n (%)	3 (20)
Time between dialysis and transplant, y, median (IQR)	6.8 (0.9–11.5)
Donor characteristics	
Age, y, median (IQR)	38.5 (21.25–65.25)
Deceased donor, n (%)	13 (86.7)
Living donor, n (%)	2 (13.3)
Cold ischemia time, h, median (IQR)	13.3 (9.7–18)
Delayed graft function, <sup>a</sup> n (%)	4 (26.7)
Immunology at the time of transplantation	
HLA mismatches, median (IQR)	4 (3–5)
vPRA (%), median (IQR)	13 (0–41.75)
Functional data at discharge	
sCr, mg/dL, median (IQR)	1.8 (1.3–2.1)
eGFR, mL/min/1.73 m <sup>2</sup> , median (IQR)	41.4 (30.5–67)
Proteinuria, g/d, median (IQR)	0.5 (0.3–1.0)
Time from transplantation to treatment, y, median (IQR)	6.0 (2.0–10.2)
Immunosuppressive therapy at the time of cAMR diagnosis	
Tacrolimus, n (%)	15 (100)
Mycophenolate mofetil/mycophenolic acid, n (%)	14 (93.3)
Steroids, n (%)	11 (73.3)
Immunosuppressive therapy at the follow-up biopsy <sup>b</sup>	
Tacrolimus, n (%)	15 (100)
Mycophenolate mofetil/mycophenolic acid, n (%)	15 (100)
Steroids, n (%)	12 (80)

<sup>a</sup>Intended as use of dialysis in the first week after kidney transplantation.

<sup>b</sup>At 10 mo after TCZ for patients without a follow-up biopsy.

ADPKD, autosomal dominant polycystic kidney disease; cAMR, chronic antibody-mediated rejection; DSA, donor-specific antibody; ESRD, end-stage renal disease; HCV, hepatitis C virus; IQR, interquartile range; sCr, serum creatinine; TCZ, tocilizumab; TG, transplant glomerulopathy; vPRA, virtual panel-reactive antibody.

+3.3] post-TCZ; *P* = 0.019; *P* = 0.999 for the slope analysis of eGFR pre- and post-TCZ; Table 2; Figure 2).

We also analyzed the trajectory of eGFR at the last available follow-up; patients received TCZ for a median time of 24 mo (10.5–46.5), and many experienced periods of TCZ interruption primarily because of drug shortage during the first wave of the COVID-19 pandemic (from March to October 2020). However, we noted that all patients have a progressive eGFR reduction, also in the limited subjects with relative eGFR stabilization at 12 mo and irrespective of TCZ maintenance/interruption, with graft loss because of TG/DSA<sup>-</sup> in 6 of 15 KTRs at a median time after diagnosis of 20 mo (15.5–22.5; **Figure S1, SDC**, <http://links.lww.com/TXD/A653>).

We previously documented a specific pattern (increased endothelial transcript [ENDAT] expression plus upregulation of tight junction protein-1, calcium/calmodulin-dependent

**TABLE 2.**  
**Analysis of functional changes pre- and post-TCZ treatment**

	TG/DSA <sup>-</sup> (n = 15)		P
	Pre-TCZ	Post-TCZ <sup>a</sup>	
sCr, mg/dL, median (IQR)	1.8 (1.6–2.6)	2.4 (1.9–4.4)	<b>0.011</b>
eGFR, mL/min/1.73 m <sup>2</sup> , median (IQR)	40.7 (27.0–44.4)	26.6 (13.9–37.0)	<b>0.019</b>
Proteinuria, g/d, median (IQR)	1.65 (0.8–2.4)	1.6 (1.2–3.6)	0.767

Bold values denote statistical significance at the  $P < 0.05$  level.

<sup>a</sup>Data at 12 mo for sCr and eGFR, at 6 mo for proteinuria.

DSA, donor-specific antibody; eGFR, estimated glomerular filtration rate; IQR, interquartile range; sCr, serum creatinine; TCZ, tocilizumab; TG, transplant glomerulopathy. Bold values denote statistical significance at the  $p < 0.05$  level.

serine protein kinase, and aldo-keto reductase family 1 member C3 after TCZ treatment) associated with clinical eGFR stabilization in TG/DSA<sup>+</sup>. Despite a similar upregulation in ENDATs, the TG/DSA<sup>-</sup> demonstrated no significant gene modifications in tight junction protein-1, calcium/calmodulin-dependent serine protein kinase, and aldo-keto reductase family 1 member C3 after TCZ treatment (Figure 3).

### Documentation of Natural Killer-Cell Infiltration in Kidney Biopsies in TG/DSA<sup>+</sup> and TG/DSA<sup>-</sup> With Marked Persistence After TCZ Treatment in TG/DSA<sup>-</sup>

Available slides of 12 patients (4 TG/DSA<sup>+</sup> with eGFR stabilization and 8 TG/DSA<sup>-</sup>) were analyzed to estimate natural killer (NK)-cell infiltration. NK cells with similar density were documented with a prevalent periglomerular and interstitial pattern in TG/DSA<sup>+</sup> and TG/DSA<sup>-</sup> (Figure S2, SDC, <http://links.lww.com/TXD/A653>).

However, after TCZ treatment (slides available for 3/4 TG/DSA<sup>+</sup> and 4/8 TG/DSA<sup>-</sup>), as for MVI, the reduction in NK cells was mainly noted in TG/DSA<sup>+</sup>, whereas TG/DSA<sup>-</sup> tends to maintain or increase periglomerular/interstitial infiltrate (Figures S3 and S4, SDC, <http://links.lww.com/TXD/A653>).

### Adverse Events

During the extended follow-up, 2 patients (13.3%) experienced bacterial infections (both in the urinary tract), promptly resolved with medical therapy, and no cessation of TCZ therapy was needed. One patient with a combined liver-kidney transplant developed cholangitis needing surgical revision and a temporary stop of TCZ. Four patients (26.7%) developed significant leukopenia, but the drug was temporarily suspended only in 1 patient. One patient had asymptomatic mild alterations in liver enzymes; TCZ was maintained, and tests were repeated with no further deterioration. One patient died of unspecified sepsis in another hospital 2 mo after TCZ suspension; in 1 patient, the TCZ was precautionarily stopped after evidence of severe diverticulosis in a routine colonoscopy but without any occurrence of diverticulitis or intestinal perforation.

### CONCLUSIONS

This study extended recent findings about differential profiles in cAMR with positive or negative DSA, suggesting a possible differential response to anti-IL-6 drugs. In our experience, TG/DSA<sup>+</sup> effectively expresses clinical and histological response to IL-6 blockade with histological amelioration (reduction of MVI and C4d<sup>+</sup>) and favorable gene expression

pattern with upregulation of genes involved in podocyte and tubular restoration. In contrast, TG/DSA maintains their negative eGFR slope despite TCZ treatment, with limited effect on their histological picture and no modification of gene expressions (apart from an increase in ENDATs).

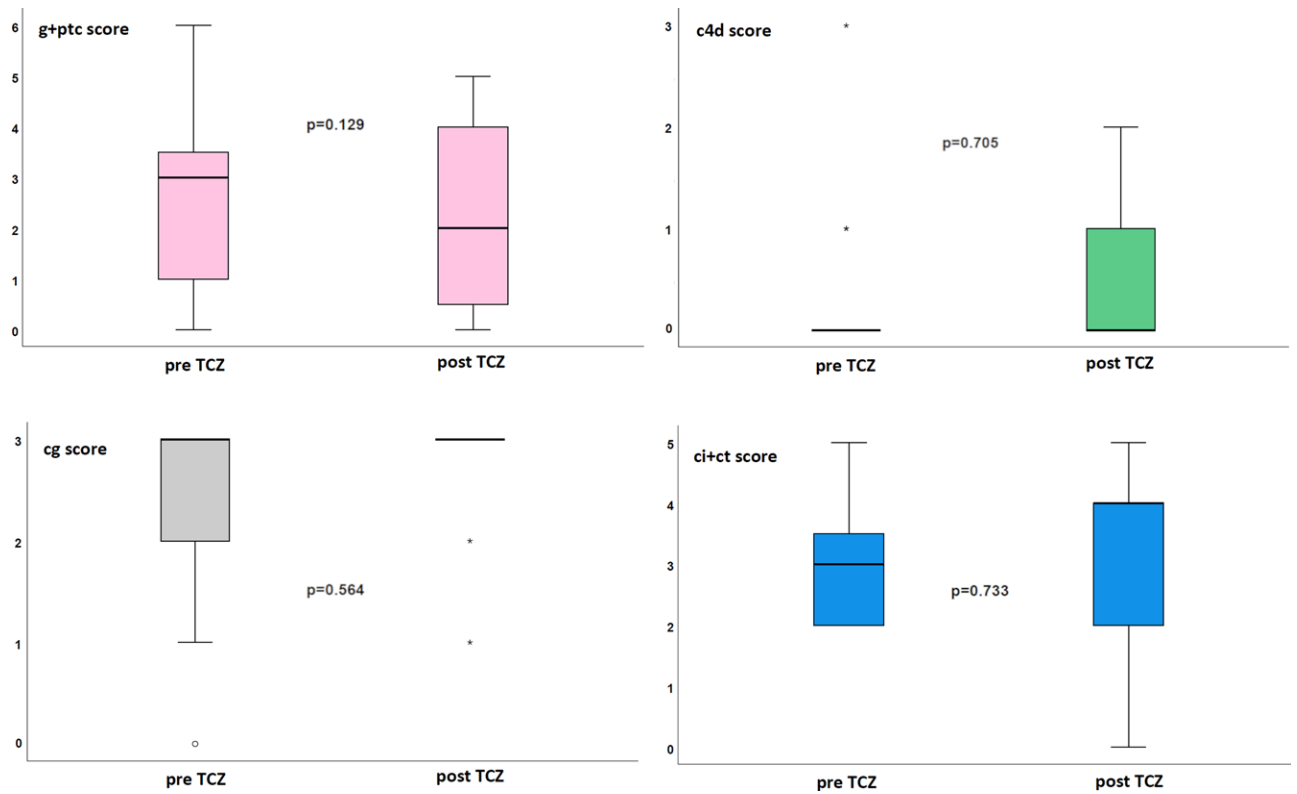
TG determined a profound negative impact on allograft survival<sup>1,8</sup>; however, differences in disease phenotypes are a matter of debate. Sablik et al<sup>15</sup> showed similar outcomes between cAMR with or without anti-HLA DSAs. Aubert et al<sup>16</sup> described different archetypes characterized by distinct functional, immunologic, and histologic features with different allograft survival profiles. A recent report by Senev et al<sup>5</sup> performed an in-depth evaluation using high-resolution HLA genotyping and sensitive Luminex technology. Although TG had a detrimental effect, no difference was found between the archetypes. However, DSA<sup>+</sup> patients express significantly higher MVI and reduced allograft survival than DSA<sup>-</sup>. A subsequent retrospective analysis of the same group showed that patients with pretransplant HLA-DSA were more prone to develop active AMR, TG, and cAMR. In contrast, DSA<sup>-</sup> patients experienced reduced graft function only when evolving to TG.<sup>17</sup>

More recently, Halloran et al<sup>18</sup> described molecular profiles of DSA<sup>+</sup> and DSA<sup>-</sup> antibody-mediated lesions, suggesting that despite DSA<sup>-</sup> having reduced C4d<sup>+</sup> and inflammation, outcomes and pathogenetic transcripts define common characteristics. As for all considerations in this research area, these data generate active discussion and opposite views.<sup>19,20</sup>

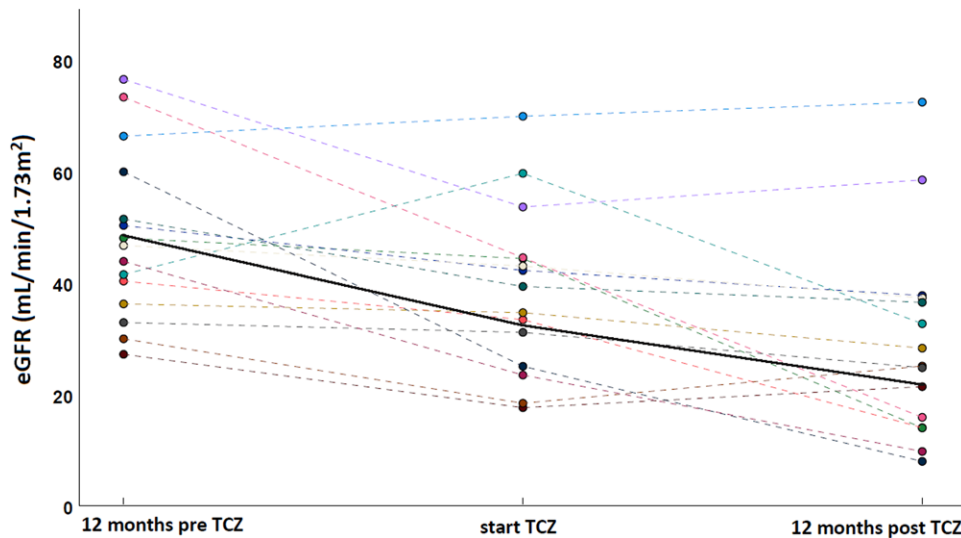
Reported discrepancies may derive from different classification systems, the sensibility of the immunological screening platform, and the time/indication of graft biopsy (protocol/for cause).

We performed our analysis in a real-life setting with for-cause biopsies and a high-sensitivity Luminex platform: in our experience, TG/DSA<sup>+</sup> and TG/DSA<sup>-</sup> expressed similar MVI scores and ENDAT expression but with different peculiar patterns previously described (low rate of C4d<sup>+</sup> at diagnosis and a trend toward high proteinuria in TG/DSA<sup>-</sup>). More importantly, we suggest for the first time that the response to IL-6-interfering treatment may diverge between DSA<sup>+</sup> and DSA<sup>-</sup>.

IL-6-mediated effects appear to be crucial for antibody-mediated damage.<sup>21</sup> Our case series and previous experiences suggested a positive effect of IL-6 blockade in reducing MVI and the MFI of immunodominant DSAs.<sup>9-11,22</sup> This positive effect of IL-6 blockade could also involve regulatory T-cell expansion,<sup>23</sup> as recently hypothesized in a pivotal trial where TCZ was administered with donor bone marrow infusion to induce living transplant tolerance.<sup>24</sup> The RCT of Doberer et



**FIGURE 1.** Histological evaluation in the studied population. In 6-mo protocol biopsies, no microvascular inflammation or C4d reduction was noted in TG/DSA<sup>+</sup> after TCZ. DSA, donor-specific antibody; TCZ, tocilizumab; TG, transplant glomerulopathy.

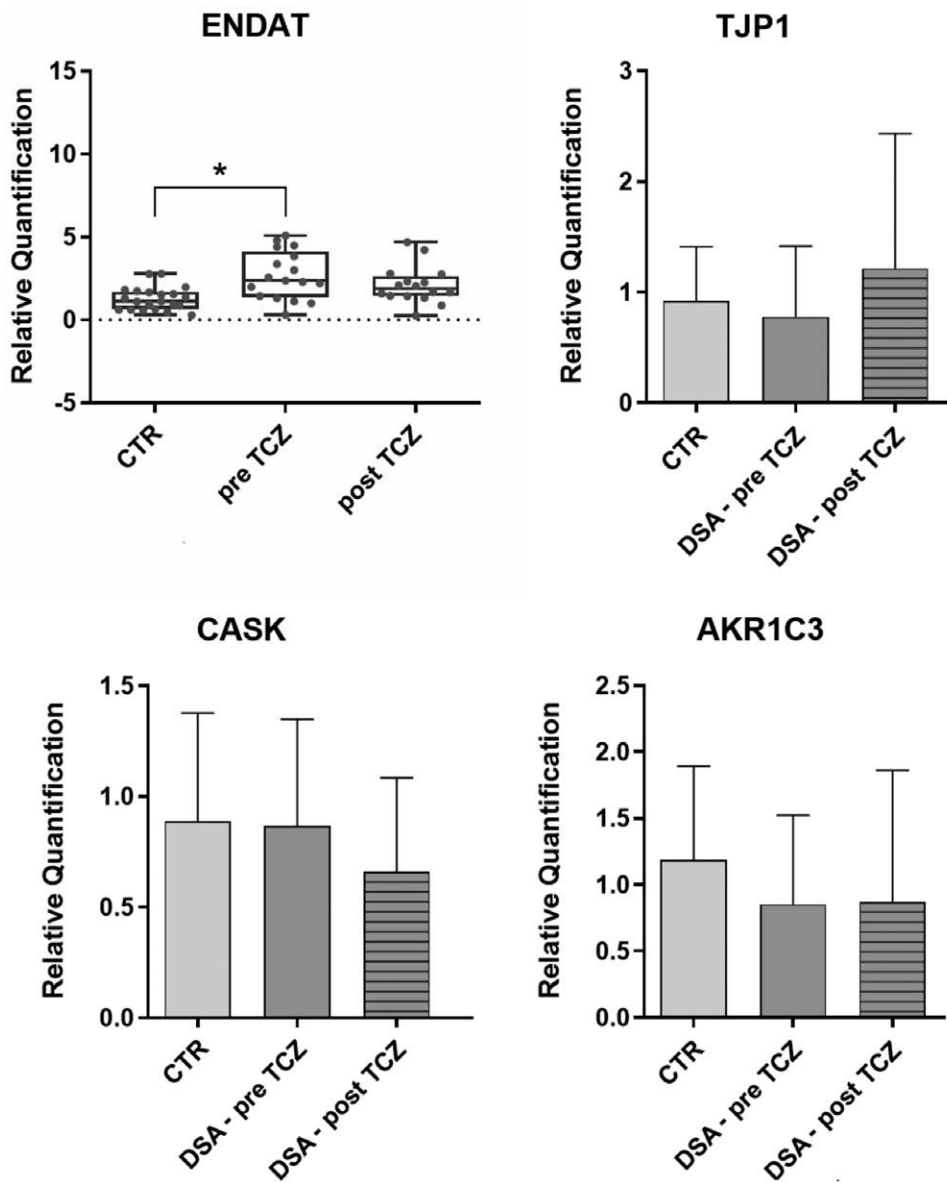


**FIGURE 2.** Renal function pre- and post-TCZ treatment. eGFR was evaluated 12 mo before and after TCZ treatment (CKD-EPI equation). TG/DSA<sup>-</sup> maintain their decline in eGFR during TCZ therapy ( $P = 0.015$  for eGFR  $-12$  mo vs  $t_0$  with  $\Delta$ eGFR  $-9.8$  mL/min/1.73 m<sup>2</sup> [IQR,  $-22.3$  to  $-3.7$ ];  $P = 0.019$  for eGFR  $t_0$  vs 12 mo with  $\Delta$ eGFR  $-10$  mL/min/1.73 m<sup>2</sup> [IQR,  $-25$  to 3.3];  $P = 0.999$  for the slope analysis of eGFR pre- and post-TCZ). CKD-EPI, Chronic Kidney Disease Epidemiology Collaboration; DSA, donor-specific antibody; eGFR, estimated glomerular filtration rate; TCZ, tocilizumab; TG, transplant glomerulopathy.

al<sup>13</sup> recently boosted the potential benefit of IL-6 inhibition in TG: in this analysis, besides MFI reduction, the use of clazakizumab (a direct IL-6 inhibitor) reduced histological inflammation (negativization of molecular signs of AMR in 7/18 [38.9%], disappearance of C4d<sup>+</sup> in 5/18 [27.8%], and resolution of AMR activity scores in 4/18 [22.2%]). These results were associated with a reduction in eGFR decline compared

with placebo, with subsequent normalization after converting the placebo group to clazakizumab,<sup>13</sup> and no effect on donor-derived cell-free DNA or CXCL10.<sup>25</sup> At the same time, 2 patients withdrew because of diverticular disease complications, and serious infections occurred in 5 subjects, highlighting the need for careful monitoring in patients treated with IL-6/IL-6 receptor-interfering drugs.

Downloaded from http://journals.lww.com/transplantationdirect by BMDMfsePHKav12Eoum11QIN4a+kLlhezgbsIH04XMI0hCjwCX1AWNtQpIIQIHID3I3D00DRY7TTSF14C13VC1y0abgqZXdImHKZBYtws= on 06/10/2024



**FIGURE 3.** Gene expression analysis pre- and post-TCZ treatment. Relative quantification ( $2^{-\Delta\Delta Ct}$ ) of the expression of ENDAT genes and 3 mesangial and podocyte marker genes in healthy CTRs compared with patients before and after treatment with TCZ. The upper box and whiskers plots show the distribution of all values from minimum to maximum and the mean for the group of analyzed ENDAT genes. The bar graphs represent geometric mean  $\pm$  95% CI. ENDATs were upregulated pre-TCZ vs CTR. TJP-1, AKR1C3, and CASK showed no significant modification in TG/DSA<sup>-</sup>. AKR1C3, aldo-keto reductase family 1 member C3; CASK, calcium/calmodulin-dependent serine protein kinase; CI, confidence interval; CTR, control; DSA, donor-specific antibody; ENDAT, endothelial transcript; TCZ, tocilizumab; TG, transplant glomerulopathy; TJP-1, tight junction protein 1. \* $P < 0.05$ .

Massat et al<sup>26</sup> showed instead a “standard” eGFR reduction in a limited cohort of cAMR TCZ treated after the failure of conventional therapies; however, the pre-TG trajectory of eGFR was not available, and 3 of 9 patients were DSA<sup>-</sup>. Based on these data, a multicenter international RCT to investigate the safety and efficacy of IL-6 inhibition with clazakizumab in AMR (IMAGINE trial, NCT0374491) is ongoing, and its results are highly awaited.

Like Doberer et al,<sup>13</sup> we previously observed that the TG/DSA<sup>+</sup> TCZ-treated group experienced histological improvement with stabilization of kidney function and proteinuria. In contrast, TG/DSA<sup>-</sup> patients seem to maintain their eGFR decline without modifications in MVI scores and C4d<sup>+</sup>.

Our results may corroborate the idea that distinct phenotypes with different pathogeneses may occur in patients with TG. Considering the ability of TCZ to reduce all antibodies,<sup>22</sup> its lack of efficacy in TG/DSA<sup>-</sup> suggests the activation of antibody-independent mechanisms to drive tissue injury and progression in these cases. Alternatively, other IL-6-independent damage pathways may be involved, as some authors propose. A role for NK cells has been suggested in both TG/DSA<sup>+</sup> and TG/DSA<sup>-</sup> with potential non-DSA-mediated direct NK cell activation through “missing self.”<sup>27</sup> Recently, Cristoferi et al<sup>28</sup> showed that TG/DSA<sup>+</sup>/C4d<sup>+</sup> expressed a higher glomerular abundance of NK cells and macrophages transcripts with increased expression of complement-related genes, whereas

TG/DSA<sup>-</sup>/C4d<sup>-</sup> with MVI mainly displayed T cells presence and activation. Our limited analysis suggests persistence of NK-cell infiltration in TG/DSA<sup>-</sup> and a little reduction in TG/DSA<sup>+</sup> associated with the response on MVI; despite all these studies needing further confirmation, it may indicate an effect of TCZ on NK cells as previously shown in different context<sup>29,30</sup> confirming a prevalent role of NK cells in this subset.

The lack of detection of C4d deposition within biopsies from the TG/DSA<sup>-</sup> group may further fuel the hypothesis of non-antibody-mediated effector mechanisms in this rejection profile.

We are aware that nonrandomization may limit the interpretation of disease-modifying drug effects; however, considering the severity of TG in determining allograft failure and the absence of effective drugs, since 2016, we have offered TCZ treatment for every TG with histological signs of immunological activation and without documented clinical contraindication. Despite the small number of analyzed patients, which already affects all the studies for potential cAMR therapies,<sup>13,26</sup> our study results suggest the possible existence of different TG phenotypes with distinct susceptibility to IL-6 blockade, hypothesizing the need for a careful selection of TG patients before TCZ treatment and paving the way for future research to confirm these data, investigate the cause of different susceptibilities to IL-6 blockade, and elaborate specific therapeutic protocols for TG/DSA<sup>-</sup>.

## REFERENCES

- Filippone EJ, McCue PA, Farber JL. Transplant glomerulopathy. *Mod Pathol*. 2018;31:235–252.
- Van Loon E, Lerut E, Naesens M. The time dependency of renal allograft histology. *Transplant Int*. 2017;30:1081–1091.
- Haas M, Loupy A, Lefaucheur C, et al. The Banff 2017 kidney meeting report: revised diagnostic criteria for chronic active T cell-mediated rejection, antibody-mediated rejection, and prospects for integrative endpoints for next-generation clinical trials. *Am J Transplant*. 2018;18:293–307.
- Haas M, Mirocha J. Early ultrastructural changes in renal allografts: correlation with antibody-mediated rejection and transplant glomerulopathy. *Am J Transplant*. 2011;11:2123–2131.
- Senev A, Van Loon E, Lerut E, et al. Risk factors, histopathological features, and graft outcome of transplant glomerulopathy in the absence of donor-specific HLA antibodies. *Kidney Int*. 2021;100:401–414.
- Delville M, Lamarthe B, Pagie S, et al. Early acute microvascular kidney transplant rejection in the absence of anti-HLA antibodies is associated with preformed IgG antibodies against diverse glomerular endothelial cell antigens. *J Am Soc Nephrol*. 2019;30:692–709.
- Bussolino S, Dolla C, Ariaudo C, et al. Detection of angiotensin II type I-receptor antibodies in transplant glomerulopathy. *Clin Transplant*. 2018;32:e13407.
- Loupy A, Hill GS, Jordan SC. The impact of donor-specific anti-HLA antibodies on late kidney allograft failure. *Nat Rev Nephrol*. 2012;8:348–357.
- Choi J, Aubert O, Vo A, et al. Assessment of tocilizumab (anti-interleukin-6 receptor monoclonal) as a potential treatment for chronic antibody-mediated rejection and transplant glomerulopathy in HLA-sensitized renal allograft recipients. *Am J Transplant*. 2017;17:2381–2389.
- Lavacca A, Presta R, Gai C, et al. Early effects of first-line treatment with anti-interleukin-6 receptor antibody tocilizumab for chronic active antibody-mediated rejection in kidney transplantation. *Clin Transplant*. 2020;34:1–11.
- Noble J, Giovannini D, Laamech R, et al. Tocilizumab in the treatment of chronic antibody-mediated rejection post kidney transplantation: clinical and histological monitoring. *Front Med*. 2021;8:1–8.
- Choi J, Huang E, Aubert O, et al. Long term outcomes using tocilizumab for the treatment of chronic antibody mediated rejection [abstract]. *Am J Transplant*. 2019;19:454–455.suppl 3):454–455.
- Doberer K, Duerr M, Halloran PF, et al. A randomized clinical trial of anti-IL-6 antibody clazakizumab in late antibody-mediated kidney transplant rejection. *J Am Soc Nephrol*. 2021;32:708–722.
- Schindelin J, Arganda-Carrera I, Frise E, et al. Fiji—an open platform for biological image analysis. *Nat Methods*. 2009;9:241.
- Sablik KA, Clahsen-van Groningen MC, Looman CWN, et al. Chronic-active antibody-mediated rejection with or without donor-specific antibodies has similar histomorphology and clinical outcome—a retrospective study. *Transpl Int*. 2018;31:900–908.
- Aubert O, Higgins S, Bouatou Y, et al. Archetype analysis identifies distinct profiles in renal transplant recipients with transplant glomerulopathy associated with allograft survival. *J Am Soc Nephrol*. 2019;30:625–639.
- Coemans M, Senev A, Van Loon E, et al. The evolution of histological changes suggestive of antibody-mediated injury, in the presence and absence of donor-specific anti-HLA antibodies. *Transplant Int*. 2021;34:1824–1836.
- Halloran PF, Madill-Thomsen KS, Pon S, et al; INTERCOMEX Investigators. Molecular diagnosis of ABMR with or without donor-specific antibody in kidney transplant biopsies: differences in timing and intensity but similar mechanisms and outcomes. *Am J Transplant*. 2022;22:1976–1991.
- Naesens M, Thauinat O, Mengel M. Microvascular inflammation: gene expression changes do not necessarily reflect pathogenesis. *Am J Transplant*. 2022;22:3180–3181.
- Halloran PF, Madill-Thomsen KS. Letter to the Editor Re: letter by Naesens et al. microvascular inflammation: gene expression changes do not necessarily reflect pathogenesis. *Am J Transplant*. 2022;22:3182–3183.
- Jordan SC, Choi J, Kim I, et al. Interleukin-6, A cytokine critical to mediation of inflammation, autoimmunity and allograft rejection: therapeutic implications of IL-6 receptor blockade. *Transplantation*. 2017;101:32–44.
- Shin BH, Everly MJ, Zhang H, et al. Impact of tocilizumab (anti-IL-6R) treatment on immunoglobulins and anti-HLA antibodies in kidney transplant patients with chronic antibody-mediated rejection. *Transplantation*. 2020;104:856–863.
- Chandran S, Leung J, Hu C, et al. Interleukin-6 blockade with tocilizumab increases Tregs and reduces T effector cytokines in renal graft inflammation: a randomized controlled trial. *Am J Transplant*. 2021;21:2543–2554.
- Oberbauer R, Edinger M, Berlakovich G, et al. A prospective controlled trial to evaluate safety and efficacy of in vitro expanded recipient regulatory T cell therapy and tocilizumab together with donor bone marrow infusion in HLA-mismatched living donor kidney transplant recipients (Trex001). *Front Med*. 2021;7:1–11.
- Mayer KA, Doberer K, Halloran PF, et al. Anti-interleukin-6 antibody clazakizumab in antibody-mediated kidney transplant rejection: effect on donor-derived cell-free DNA and C-X-C motif chemokine ligand 10. *Transplant Direct*. 2022;8:e1406.
- Massat M, Congy-Jolivet N, Hebrat AL, et al; Toulouse Acquired Immune Deficiency, Infection (TAIDI) Study Group. Do anti-IL-6R blockers have a beneficial effect in the treatment of antibody-mediated rejection resistant to standard therapy after kidney transplantation? *Am J Transplant*. 2021;21:1641–1649.
- Koenig A, Chen CC, Marçais A, et al. Missing self triggers NK cell-mediated chronic vascular rejection of solid organ transplants. *Nat Commun*. 2019;10:5350.
- Cristoferi I, Varol H, van Baardwijk M, et al. Multiomic profiling of transplant glomerulopathy reveals a novel T-cell dominant subclass. *Kidney Int*. 2023;105:812–823.
- Shin B-H, Ge S, Mirocha J, et al. Tocilizumab (anti-IL-6R) suppressed TNF $\alpha$  production by human monocytes in an in vitro model of anti-HLA antibody-induced antibody-dependent cellular cytotoxicity. *Transplant Direct*. 2017;3:e139.
- Sligar C, Cuthbertson P, Miles NA, et al. Tocilizumab increases regulatory T cells, reduces natural killer cells and delays graft-versus-host disease development in humanized mice treated with post-transplant cyclophosphamide. *Immunol Cell Biol*. 2023;101:639–656.