

AperTO - Archivio Istituzionale Open Access dell'Università di Torino

Lung ultrasound in acute and chronic heart failure: a clinical consensus statement of the European Association of Cardiovascular Imaging (EACVI)

This is a pre print version of the following article:

Original Citation:

Availability:

This version is available <http://hdl.handle.net/2318/1957231> since 2024-02-22T22:33:58Z

Published version:

DOI:10.1093/ehjci/jead169

Terms of use:

Open Access

Anyone can freely access the full text of works made available as "Open Access". Works made available under a Creative Commons license can be used according to the terms and conditions of said license. Use of all other works requires consent of the right holder (author or publisher) if not exempted from copyright protection by the applicable law.

(Article begins on next page)

Lung ultrasound in acute and chronic heart failure. A Clinical Consensus Statement of the European Association of Cardiovascular Imaging (EACVI)

Luna Gargani¹, Nicolas Girerd², Elke Platz³, Pierpaolo Pellicori⁴, Ivan Stankovic⁵, Alberto Palazzuoli⁶, Emanuele Pivetta⁷, Marcelo Haertel Miglioranza⁸, Hatem Soliman-Aboumarie⁹, Eustachio Agricola¹⁰, Giovanni Volpicelli¹¹, Susanna Price¹², Erwan Donal¹³, Bernard Cosyns¹⁴, Aleksandar N. Neskovic⁵.

Reviewers: This document was reviewed by members of the 2020-2022 EACVI Scientific Documents Committee: Magnus Bäck, Philippe B. Bertrand, Marc Dweck, Niall Keenan, Leyla Elif Sade.

¹ Department of Surgical, Medical and Molecular Pathology and Critical Care Medicine, University of Pisa, Italy.

² Université de Lorraine, Centre d'Investigations Cliniques Plurithématique 1433, Institut Lorrain du Cœur et des Vaisseaux Louis Mathieu, CHRU de Nancy, INSERM DCAC, F-CRIN INI-CRCT, Nancy, France.

³ Cardiovascular Division, Brigham and Women's Hospital and Harvard Medical School, Boston, USA.

⁴ Robertson Centre for Biostatistics and Glasgow Clinical Trials Unit, University of Glasgow, University Avenue, Glasgow, UK.

⁵ Clinical Hospital Centre Zemun, Faculty of Medicine, University of Belgrade, Serbia.

⁶ Cardiovascular Diseases Unit, Cardio-thoracic and vascular Department Le Scotte Hospital University of Siena Italy.

⁷ Medicina d'Urgenza-MECAU, Presidio Molinette, A.O.U. Città della Salute e della Scienza di Torino, Italy.

⁸ Institute of Cardiology, University Foundation of Cardiology, Porto Alegre, Brazil.

⁹ Department of Cardiothoracic Anaesthesia and Critical Care, Harefield Hospital, Royal Brompton and Harefield Hospitals, Guy's and St Thomas NHS Foundation Trust, London, UK. School of Cardiovascular Medicine and Sciences, King's College London.

¹⁰ Cardiovascular Imaging Unit, Cardio-Thoracic-Vascular Department, San Raffaele Hospital, Milan, Italy, Vita-Salute University.

¹¹ Department of Emergency Medicine, San Luigi Gonzaga University Hospital, Torino, Italy.

¹² Departments of Cardiology & Intensive Care, Royal Brompton & Harefield Hospitals, part of Guy's and St Thomas NHS Foundation Trust, and National Heart and Lung Institute, Imperial College London, London, UK.

¹³ University of Rennes, CHU Rennes, Inserm, Rennes, France.

¹⁴ Department of Cardiology, Universitair Ziekenhuis Brussel, Jette, Brussels, Belgium.

Corresponding author:

Luna Gargani, MD, PhD

Department of Surgical, Medical and Molecular Pathology and Critical Care Medicine
University of Pisa, Italy.

Introduction

Lung ultrasound (LUS) was introduced to intensive care units and emergency departments more than 20 years ago, primarily as a tool for the assessment of patients with acute dyspnoea ^{1,2}. Since then, it has gained popularity as a quick point-of-care examination enabling clinicians to answer crucial clinical questions. Over the last decade, the cardiology community has acknowledged the potential of LUS and expanded its use further, to assist with the diagnosis and management of patients with heart failure (HF) ³⁻⁵.

The importance of recognizing and treating pulmonary congestion is a cornerstone in the management of patients with HF ⁶. LUS is a versatile, high sensitivity point of care examination to detect pulmonary deaeration due to increased extravascular lung water. It has many advantages to the extent that an integrated cardiopulmonary ultrasound exam is likely to become the reference standard in HF care. This approach allows the aetiology of HF to be defined, through the assessment of cardiac structure and function by echocardiography, at the same time as the assessment of pulmonary congestion provided by LUS. In addition, it facilitates the exclusion of other highly prevalent conditions that may mimic/overlap with HF (e.g., pneumonia, acute lung injury/acute respiratory distress syndrome [ALI/ARDS], pneumothorax).

Lung ultrasound in heart failure: the findings

B-lines and pleural effusions

In a fully aerated lung, the only anatomical structure that can be visualized is the pleura, which appears as a smooth, hyperechoic horizontal line that moves synchronously with respiration. This line is called *pleural line* and its movement is the *lung sliding*, providing visual assessment of lung excursion during ventilation. The sonographic pattern of the aerated lung also includes parallel, hyperechoic, horizontal lines that can be seen at regular intervals from the pleural line (*A-lines*, Figure 1, Video 1) ⁷. When the air content in the lung decreases and lung density increases, vertical reverberation artifacts appear (*B-lines*, Figure 2, Video 2). B-lines originate from the pleural line and move synchronously with respiration, are laser-like in shape and extend towards the bottom of the US sector as displayed on the screen ⁸. B-lines are present in patients with HF and pulmonary oedema ⁹ where an increasing number of visualized B-lines is associated with a decreasing air/water content ratio ¹⁰⁻¹².

B-lines are not specific for cardiogenic pulmonary oedema and can be detected in patients with non-cardiogenic pulmonary oedema, including those with end stage renal disease and in ALI/ARDS ¹³, but also in pulmonary fibrosis (interstitial lung disease) ¹⁴ and interstitial pneumonia. Certain sonographic characteristics can help differentiate these various causes of B-lines ⁵ (Table 1).

Pleural effusion can be easily detected by LUS, placing the phased array transducer on the surface of the chest wall in an intercostal space, and is displayed as an anechoic space above the diaphragm. Pleural effusion is advised to be sought at first in the dependent zones, i.e. lateral and posterior chest wall (e.g. posterior axillary line) at the level of costophrenic angles (Figure 3, Video 3), which also allows other causes of chest X-ray radio-opacity, such as consolidation, mass, or an elevated hemidiaphragm to be ruled out (Figure 4, Video 4). LUS is more sensitive than chest X-ray in detecting pleural effusions, when using computed tomography (CT) as the reference standard^{15,16}, and can determine the volume of pleural effusion and monitor its evolution. LUS can also provide information on its likely nature by differentiating between simple and complex effusions, and can help guide the optimal site for needle thoracentesis.

Other sonographic features of congestion

The pathophysiology of congestion in HF includes the different stages of hemodynamic, pulmonary and systemic congestion¹⁷, that can be all assessed by ultrasound. Traditional echocardiography provides indicators of hemodynamic congestion, including a dilated left atrium, a high E/e', elevated pulmonary artery systolic pressure, and dilated inferior vena cava (IVC). B-lines on LUS are a sign of pulmonary congestion (increased extravascular lung water) due to left sided HF, independent of - yet closely related with hemodynamic congestion. Chronically elevated left-sided filling pressures eventually result in a rise in right atrial pressures and IVC distension. An IVC smaller than 21 mm that collapses >50% during inspiration suggests normal right atrial pressures¹⁸, although this measurement should be interpreted in the context of the overall patient's underlying pathophysiological and hemodynamic status and integrated with other echocardiographic findings; an increased IVC diameter can identify intravascular volume expansion prior to changes in symptoms or body weight, and predicts a high risk of rehospitalization for HF or death in patients with acute or chronic HF^{19,20}.

Using a high-frequency linear transducer, the internal jugular vein (IJV) diameter can be measured. When congestion is severe, IJV distensibility, provoked by Valsalva manoeuvre, is markedly reduced, indicating a poor prognosis²¹. Congestion in other organs can be also assessed by ultrasound, such as the kidneys. A comprehensive review of these novel techniques and their potential clinical utility can be found elsewhere²². Recently, the VExUS score (venous excess ultrasound), including Doppler evaluation of the IVC, hepatic veins, portal vein, and renal venous flow has been proposed to assess presence and severity of venous congestion²³. Whereas systemic venous congestion (as assessed by IVC, IJV, hepatic veins, portal veins, renal veins) can be present in both right and left-sided HF, LUS B-lines indicate pulmonary congestion due to left-sided HF.

Other sonographic features of deaeration

When the pulmonary air content is completely dissipated in areas of pulmonary consolidation (a potential precipitant of acute HF), the lung parenchyma can be directly visualized (Figure 5, Video 5) with a hypoechoic or tissue-like pattern. Different aetiologies of consolidations may have also different sonographic appearance (Figure 5). Compression atelectasis is frequent in patients with HF; here, a large cardiogenic pleural effusion causes direct compression of the pulmonary parenchyma⁴.

On occasion, a focal interstitial syndrome (i.e. multiple B-lines localized only in a single area of the chest 'zone') can suggest pneumonia. These are thought to represent either the very early phases of pneumonia with the partial deaeration LUS pattern (B-lines) preceding the total deaeration LUS pattern (consolidation), or the focal oedema surrounding any consolidation.

Lung ultrasound in heart failure: the technique

Whenever possible, it is advised to perform LUS exams with a standardized approach, to facilitate interpretation and monitoring, as well as reproducibility²⁴. Several LUS protocols have been described, with a variable number of examination areas of the chest (*zones*) to be examined, ranging from 4 to 28^{25–27} (Figure 6). Currently, the 8-zone scanning protocol is the most widely used, balancing the need for a simplified, rapid protocol, and good accuracy;⁸ with studies suggesting it the most appropriate approach across multiple settings, including the diagnosis of HF (with the 8-zone C-index non-inferior to the 28-zone C-index)²⁸, and for risk stratification²⁹.

When integrating LUS during stress echocardiography, a simplified 4-zone scanning protocol is often used, placing the probe at the third intercostal space along the anterior axillary and mid-axillary lines^{30,31}.

In adult patients, both phased-array or convex transducers are sufficient to assess B-lines. If available, the abdominal preset (for the convex transducer) and the cardiac preset (for the phased-array transducer) usually provide adequate image quality. Some machines have also a dedicated lung preset. The transducer should be placed in the intercostal space either perpendicular (longitudinal, sagittal) or in parallel orientation (transverse) to the ribs. Imaging depth depends on the size of the patient, but is usually set at ~15–18 cm²². Once the transducer position and gain settings are optimised for visualization of the pleural line and B-lines, it is advised to keep the transducer in the same location for at least one respiratory cycle. When a movie clip is recorded, the suggested length is of about 6 seconds^{32,33}. In each chest zone, the operator should scan all accessible chest surface to increase sensitivity.

During the examination, patients can be positioned either sitting upright, semi-recumbent or supine; however, it is preferred to scan patients should be scanned in the same position if serial examinations are being performed³⁴. In those thoracic zones where a pleural effusion is visualized,

B-lines cannot be assessed, and the presence of pleural effusion should be described in the LUS report instead.

There are two main approaches to quantify B-lines: score- or count-based methods. Score-based methods consider a minimum number of B-lines in one thoracic zone as a 'positive' zone (typically at least 3 B-lines) ⁸, then the number of positive zones are added up ²⁵. Count-based methods entail that B-lines are counted to obtain a number for each thoracic zone: B-lines can be counted one by one ^{27,34} or, when confluent and overlapping, their number can be estimated from the percentage of space they occupy on the screen below the pleural line, divided by 10 (i.e. if about 60% of the screen below the pleural line is occupied by B-lines, it would conventionally count as 6 B-lines, up to a maximum of 10 per zone) (Figure 7). It is advised to count B-lines in the worst (less aerated/with more B-lines) point of each thoracic zone, then the number of B-lines in each zone can be summed up to obtain a total B-line count ^{4,8,35,36}. All these methods have demonstrated good intra- and inter-observer agreement ^{37,38}. A schematic overview of LUS approach in patients with suspected or established HF is shown in Table 2.

Key points: To evaluate pulmonary congestion in patients with suspected or established HF, using a phased-array or convex probe may be appropriate (including handheld ultrasound devices), in sagittal or transverse orientations (transducer perpendicular or parallel to the intercostal space), ideally following the 8-zone protocol and maintaining the patient in the same position during serial examinations.

Clinical applications

Acute heart failure

Diagnosis: Ruling in/out acute cardiogenic dyspnoea

The typical LUS pattern of a patient with acute HF and pulmonary oedema is the presence of *multiple* (at least 3 B-lines in one chest zone), *diffuse* (at least two positive zones per hemithorax) and *bilateral* B-lines. It is important to distinguish this pattern from the presence of a few patchy B-lines, especially when located at the lung bases, that can be seen even in healthy subjects, and which therefore do not qualify as *multiple*, *diffuse* and *bilateral*.

LUS is a rapid diagnostic test, which takes less than 5 minutes. Among patients hospitalized with acute dyspnoea, LUS has demonstrated high diagnostic accuracy for acute HF, with a sensitivity of 94-97% and a specificity of 97% ^{25,26} that has been shown to be superior to both clinical assessment (i.e. history, physical examination, electrocardiogram, and arterial blood gas) and the chest X-ray, even when there is superimposed pneumonia ^{25,39,40}. Indeed, LUS is superior to chest X-ray alone (sensitivity of 91.8% vs. 76.5% and a specificity of 92.3% vs. 87.0%) ⁴¹, and has higher

accuracy than clinical assessment even when integrated with “traditional” diagnostic test (i.e. natriuretic peptides and chest X-ray) to diagnose acute HF ^{25,26}.

Monitoring: Assessing decongestion

A higher number of B-lines on admission for an episode of acute HF is associated with greater risk, regardless of left ventricular ejection fraction (LVEF) and presence of HF signs and symptoms ⁴². This suggests that B-lines might be a potential target for treatment but also useful to monitor response to decongestive therapies.

Changes in B-lines are very dynamic and, for those who respond to diuretic therapy and other treatments, the number of B-lines decreases rapidly ^{27,43,44}, regardless of the aetiology of acute HF ⁴⁵. Serial LUS can guide titration of diuretic therapy, leading to more rapid relief of congestion and, potentially, shortening the length of hospital stay ^{46–48}. Resolution of pulmonary congestion detected by ultrasound during HF hospitalisation is associated with improved survival (combined endpoint of 6 month all-cause death or AHF re-hospitalization) ^{48,49}. However, at the moment, there is no evidence that titrating diuretic therapy based on B-lines can improve morbidity and mortality in patients hospitalized with HF ⁴⁷.

Although pleural effusions are typically monitored by chest X-ray in patients with acute HF, serial ultrasound scans are also effective in quantifying changes in the size of pleural effusion associated with decongestive therapy without exposing patients to radiation ⁵⁰.

Prognosis: Determining the timing of discharge

Up to 45% of patients hospitalized with acute HF are either readmitted for HF or die within 12 months of discharge ⁵¹. Those with a higher degree of residual congestion, including pulmonary congestion, at the time of discharge, are at particularly high risk ^{51,52}. The importance of optimizing decongestion during a HF hospitalisation is consequently highlighted in the 2021 ESC Guidelines ⁶. Patients with a high number of B-lines at discharge are at higher risk of readmission or premature death than those discharged without or with only mild pulmonary congestion ^{36,53–56}. Prior studies investigating the prevalence and prognostic value of B-lines at discharge in patients hospitalized with HF have employed 4, 8 or 28-zone LUS protocols; specific cut-off values for these protocols are summarized in Table 3. Collectively, these findings suggest that LUS may detect subclinical pulmonary congestion pre-discharge in patients with acute HF, irrespective of ejection fraction, and identify those at greater risk for subsequent adverse outcomes. In addition to B-lines, pleural effusions can be detected with ultrasound in approximately half of the patients discharged after an acute HF episode ²⁷, but it is unclear whether this finding is associated with an increased risk of cardiovascular events post-discharge ⁵⁷.

Key points: The LUS pattern of pulmonary oedema in acute left- sided HF consists of the presence of multiple (at least 3 B-lines), diffuse (in at least 2 zones per hemithorax),

bilateral B-lines. Using LUS may be appropriate in patients with acute dyspnoea to rule-in or rule-out pulmonary oedema in suspected acute left-sided HF. Using LUS may be appropriate to detect persistent pulmonary congestion prior to discharge in patients hospitalized with acute HF, to identify those at higher risk of readmission for HF or death.

Chronic heart failure

During follow-up: guidance of diuretic therapy

The 2021 ESC Guidelines do not recommend serial echocardiography or assessment of B-lines in ambulatory patients with HF unless clinical deterioration is suspected. Indeed, many of those with HF who attend routine clinical appointments usually feel well, do not report any symptoms and are free of congestion at clinical examination⁵⁸. However, decompensation is clinically silent in most patients and is often only recognized late, at a point when congestion demands urgent action. Thus, LUS could potentially be implemented in the routine clinical evaluation of outpatients, to facilitate early detection of subclinical congestion. In a single-centre, single-blind, randomized clinical trial, a LUS-guided strategy significantly improved the combined endpoint of urgent visit, re-hospitalisation and death at 6 months after an acute HF episode⁵⁹. Subsequently, the CLUSTER-HF trial also showed that LUS-guided treatment was associated with a 45% risk reduction in the primary end point (a composite of urgent HF visits, rehospitalization for worsening HF, and death from any cause), mainly driven by a reduction in urgent HF visits⁶⁰. Another trial that randomised outpatients with chronic HF, demonstrated a substantial reduction in hospitalizations for acute HF (by 56% at 90 days), as well as decreasing NT-proBNP concentrations and improving quality-of-life in those patients whose treatment was guided by LUS⁶¹. A summary of the clinical utility of LUS in acute and chronic heart failure is shown in Table 4.

Key points: Integrating LUS into the routine evaluation of ambulatory patients with HF may be appropriate, to titrate diuretic therapy and reduce HF-related adverse outcomes, in particular the need for urgent visits.

During stress echocardiography

LUS can be easily performed during exercise testing, including stress echocardiography^{31,62,63}. The number of B-lines increases during exercise in patients with HF more than in control subjects^{64,65}. In patients with HFrEF, peak B-lines are closely associated with resting NT-proBNP, peak VO₂, and stress PASP⁶². In patients with heart failure with preserved ejection fraction (HFpEF), the development of pulmonary congestion as measured by B-lines upon exercise correlates with exercise-induced worsening of diastolic function (particularly with peak E/e' and global strain rate during late diastole)⁶⁶. Hemodynamic studies further suggest that the acute development of pulmonary congestion during stress is related to an increase in pulmonary capillary hydrostatic

pressure and systemic venous hypertension ⁶⁷. Therefore, LUS during exercise can quantify the pulmonary congestion secondary to the raise in stress-induced intracardiac/pulmonary pressures.

Detecting a higher number of B-lines at peak exercise is associated with a greater risk of HF hospitalization and death in patients with both HFrEF ⁶² and HFpEF. Overall, these findings suggest that LUS may complement standard exercise testing to improve HF diagnosis and risk stratification ^{68,69}.

In patients with chest pain and acute myocardial infarction

Patients with acute coronary syndrome may develop pulmonary congestion, especially during or soon after an ST-elevation myocardial infarction (STEMI). A recent systematic review suggests that a high number of B-lines is a common finding in patients hospitalized with an acute coronary syndrome and identifies patients more likely to have adverse in-hospital and long-term outcomes ⁷⁰. Whether assessment of B-lines might guide use of therapies that reduce pulmonary congestion after a myocardial infarction and improve morbidity and mortality in the short and long term, remains to be determined.

In patients with shock/hypotension

LUS can provide vital information when integrated with echocardiography in the assessment of hypotension and various types of shock, with the potential of detecting the underlying cause, and improving the quality of care delivered to critically ill patients.

In hypovolaemic shock, the presence of a normal LUS pattern confirms the presence of 'dry' lungs which has a very high negative predictive value in ruling out a cardiogenic cause of hypotension ^{71,72} (Figure 8). Patients in cardiogenic shock due to LV failure or mitral/aortic valvular heart disease, eventually develop pulmonary congestion which would appear by LUS as multiple, diffuse bilateral B-lines, associated with a regular pleural line ¹³ (Figure 8).

In patients with a pneumothorax, LUS has superior diagnostic sensitivity (88% vs. 52%) and similar specificity (99% vs. 100%) to chest X-ray ⁷³. The combination of the absence of lung sliding (generating the barcode sign on M-mode), absence of B-lines, and the presence of a lung point (the transition point between a LUS pattern with lung sliding and without lung sliding) would suggest a pneumothorax as the cause of hypotension/shock (Figure 8) ⁸. The visualization of a normal LUS pattern along with non-compressible peripheral deep veins due to a thrombus would suggest pulmonary embolism, especially when coupled with RV dilatation and dysfunction ⁷⁴. Moreover, triangular/polygonal hypoechogenic peripheral consolidations with sharp margins may be detected, as the sonographic appearance of pulmonary infarctions (Figure 8) ⁷⁵.

In septic shock, the lungs are a frequent source of sepsis, due to lobar pneumonia which can be diagnosed with LUS with high sensitivity, through the visualization of consolidations often with dynamic air bronchograms, commonly at the most dependant zones of the lungs, with or without adjacent pleural effusion. The presence of punctiform echoes within an otherwise anechogenic pleural effusion could indicate exudative pleural effusion/empyema ⁷⁶. The lungs can develop B-lines due to ARDS because of septic shock of extrapulmonary origin. LUS can be very useful in monitoring areation/deareation, assessing disease progression and recruitment in ALI/ARDS (including COVID-19 pneumonia) ⁷⁷. LUS can be performed also during transoesophageal echocardiography through dedicated views of the posterior regions of the lungs where lung consolidations and pleural effusions are most often seen, with promising preliminary results ⁷⁸.

Key points: In patients with shock/hypotension, LUS can complement the standard clinical evaluation to improve diagnostic accuracy.

Integrated cardiopulmonary ultrasound

How to integrate echocardiography and lung ultrasound

Transthoracic echocardiography is guidelines-recommended as a key investigation in HF ⁶ for the assessment of cardiac structure and function, defining HF phenotype based on LVEF measurement, as well identifying potential underlying aetiologies and mechanisms, and guiding the introduction of treatment. The 2021 ESC Guidelines also mention the use of LUS in acute settings to confirm a diagnosis of HF, especially when natriuretic peptide testing is not available ⁶, since pulmonary congestion is one of the main causes of hospital admission in patients with HF ¹⁷.

Integrating cardiac and pulmonary assessments on ultrasound can help understand and identify earlier the pulmonary consequences of structural or functional cardiac pathology, and potentially individualise patient management. Real-time interpretation of B-lines, together with the non-invasive hemodynamic signs that can be measured by echocardiography, can provide simultaneous assessments of the cardiac and pulmonary situation, leading to more accurate diagnosis and earlier treatment initiation ^{79,80}. The number of B-lines is related to invasive left ventricular end-diastolic pressure (LVEDP) measurements ⁸¹, to E/e' ⁸², to tricuspid regurgitation velocity ⁴², to right ventricular (RV) function and RV–pulmonary artery coupling ⁸³. However, in patients with the same hemodynamic profile, the degree of pulmonary congestion as detected by B-lines can vary markedly. Therefore, echocardiography is useful to understand the aetiology of HF, whereas LUS B-lines are especially useful to detect the degree of pulmonary congestion. The routine assessment of B-lines may be particularly appropriate when either a high-end ultrasound machine or the expertise for more complex echocardiographic analyses is not readily available or when cardiac image quality is poor and initial diagnosis difficult. Therefore, whenever possible, these two

aspects of the patient's compensation status – hemodynamic congestion and pulmonary congestion - ¹⁷ can be evaluated in an integrated ultrasound cardiopulmonary examination (Table 5). This approach can also provide concomitant information regarding perfusion (by the LV outflow tract time-velocity integral as a non-invasive index of cardiac output) and pulmonary congestion (by B-lines), in a less invasive way compared to right heart catheterization. The integration of B-lines with IVC is also valuable and integrates different information, since IVC diameter and collapsibility index is a proxy for right atrial pressure, but also reflects intravascular volume status, whereas B-lines reflect extravascular lung water, which can be present in patients with either a normal or a dilated IVC ¹⁹.

Key points: When evaluating patients with known or suspected HF, it is advised to integrate LUS B-lines in the echocardiographic assessment to provide information about the degree of pulmonary congestion, in both acute and chronic settings.

Lung ultrasound in FoCUS

Focus cardiac ultrasound (FoCUS) is a point-of-care cardiac ultrasound examination performed according to a standardized, but restricted, scanning protocol in patients presenting with circulatory or respiratory compromise, chest pain or trauma, dyspnoea, syncope or cardiac arrest ⁸⁴. The FoCUS scanning protocol comprises five echocardiographic views sufficient for crude assessment of left and right ventricular size and function, pericardial effusion, and intravascular volume status.

Since cardiovascular and pulmonary diseases frequently coexist and may share clinical presentations, LUS may help in the differential diagnosis of acute dyspnoea and hemodynamic instability and is therefore an integral part of the FoCUS examination ⁸⁴. The presence of multiple, diffuse, bilateral B-lines in a dyspnoeic patient with LV dysfunction is almost unequivocally consistent with HFrEF. In the presence of left atrial dilation and/or visually-detected LV hypertrophy, multiple, diffuse, bilateral B-lines may indicate HFpEF, and natriuretic peptide measurement and a comprehensive echocardiography should be ordered for further evaluation ⁸⁴. Figure 8 summarizes the main situations of respiratory and circulatory failure, where LUS integrated with FoCUS can be of particular value.

Key points: Whenever possible, it is advised to integrate assessment of B-lines and pleural effusion into the FoCUS examination since it may help in the differential diagnosis of acute dyspnoea and hemodynamic instability.

Pitfalls

As with every diagnostic technique, there are some limitations with LUS examinations, which should be acknowledged to master this tool. There are still uncertainties about the exact physical origin of B-lines ¹¹, although they are clearly related to a partial deaeration of the pulmonary

parenchyma. LUS is an easy to learn ultrasound technique, with a short learning curve that can be limited to about 20 exams^{85,86}, but some training is needed to ensure reproducibility and the correct interpretation of findings. Initiatives that would ensure quality standards and safe patient care, for instance an LUS certification program, could facilitate the standardisation of this procedure for both clinicians and other healthcare professionals involved in the care of patients with HF, who can successfully assess B-lines^{87,88}. B-lines are artifacts: although no clinically significant differences have been reported by using different machines and settings, attention should be paid to avoid magnification or deletion of artefactual images. Different LUS scanning protocols have been proposed and used, in research and in clinical practice, as previously discussed.

Probably, the main pitfall is the clinical interpretation of B-lines in the absence of an established diagnosis. B-lines are not specific for cardiogenic pulmonary oedema: being a sign of partial pulmonary deaeration, they can be present in patients with interstitial lung disease, such as pulmonary fibrosis, as well as ALI/ARDS, and interstitial pneumonia (including COVID-19 pneumonia). As highlighted in Table 1, there are some LUS features that can help differentiate these conditions, taking into account that a strong integration with clinical and other routine diagnostic findings is mandatory. This point further reinforces the need for LUS training, to ensure that healthcare providers will not categorize every patient with B-lines as having HF.

Importantly, the absence of substantial pulmonary congestion on ultrasound does not exclude HF, particularly in the context of severe obesity or isolated right-sided HF; therefore, clinicians should not forget to evaluate systemic/venous congestion⁸⁹.

Gaps in current evidence

In recent years major advances have been made in our understanding of the utility of LUS as an imaging tool in the diagnosis, monitoring and risk stratification of patients with HF, but areas with lack of evidence remain. Table 6 lists selected topics that deserve to be addressed in future clinical research.

Whilst waiting for additional evidence regarding the clinical utility of LUS, especially in titrating diuretic therapy, we already have solid data supporting the use of this tool in daily clinical practice to complement either FoCUS or comprehensive echocardiography in the assessment and management of patients with HF.

Conclusions

LUS is an easy to learn, rapid and versatile point-of-care diagnostic method. B-lines on LUS are the sonographic sign of a partially deaerated lung, that can be detected in patients with HF, providing a semiquantitative evaluation of pulmonary interstitial oedema.

Sonographic B-lines are useful for the diagnosis, monitoring and prognostic assessment of patients with HF. Therefore, it would be useful too integrate routine evaluation of B-lines and pleural effusions into standard transthoracic echocardiographic protocols in patients with suspected or confirmed HF, as well as in the FoCUS examination. This integrated cardiopulmonary ultrasound approach has the potential to improve clinical management and potentially patient outcomes with further research required.

Legend of figures and videos

Figure 1

The sonographic pattern of a normally aerated lung with the pleural line (dotted yellow line) and A-lines (dotted orange lines).

Figure 2

B-lines indicated by dotted white lines.

Figure 3

The left costophrenic angle with pleural effusion.

Figure 4

Pleural effusion with compression atelectasis

Figure 5

Different patterns of consolidation at LUS: A) pneumonia; B) pulmonary infarction; C) compression atelectasis; D) obstructive atelectasis.

Figure 6

Different LUS scanning protocols, ranging from 4 to 28 zones. The imaging protocol should be performed upon both hemithoraxes. In the 28-zone protocol the left hemithorax does not include the fifth intercostal space.

Figure 7

How to quantify B-lines

Figure 8

Integrated cardiopulmonary ultrasound for the differential diagnosis of respiratory and circulatory failure

Video 1

The sonographic pattern of a normally aerated lung with the pleural line and A-lines

Video 2

Multiple B-lines in a patient with acute cardiogenic pulmonary oedema

Video 3

The right costophrenic angle in a patient with pleural effusion and ascites

Video 4

Pleural effusion with compression atelectasis

Video 5

Sonographic appearance of pneumonia with air bronchogram

References

1. Lichtenstein D, Mezière G. A lung ultrasound sign allowing bedside distinction between pulmonary edema and COPD: the comet-tail artifact. *Intensive Care Medicine*. 1998;24(12):1331-1334. doi:10.1007/s001340050771
2. Lichtenstein DA, Mezière GA. Relevance of Lung Ultrasound in the Diagnosis of Acute Respiratory Failure*: The BLUE Protocol. *Chest*. 2008;134(1):117-125. doi:10.1378/chest.07-2800
3. Picano E, Frassi F, Agricola E, Gligorova S, Gargani L, Mottola G. Ultrasound lung comets: A clinically useful sign of extravascular lung water. *Journal of the American Society of Echocardiography*. 2006;19(3). doi:10.1016/j.echo.2005.05.019
4. Gargani L. Ultrasound of the Lungs: More than a Room with a View. *Heart Failure Clinics*. 2019;15(2). doi:10.1016/j.hfc.2018.12.010
5. Gargani L. Lung ultrasound: a new tool for the cardiologist. *Cardiovascular ultrasound*. 2011;9:6.
6. McDonagh TA, Metra M, Adamo M, et al. 2021 ESC Guidelines for the diagnosis and treatment of acute and chronic heart failure. *European heart journal*. 2021;42(36):3599-3726. doi:10.1093/eurheartj/ehab368
7. Gargani L, Volpicelli G. How I do it: Lung ultrasound. *Cardiovascular ultrasound*. 2014;12(1):1-10. doi:10.1186/1476-7120-12-25
8. Volpicelli G, Elbarbary M, Blaivas M, et al. International evidence-based recommendations for point-of-care lung ultrasound. *Intensive care medicine*. 2012;38(4):577-591. doi:10.1007/s00134-012-2513-4
9. Lichtenstein D, Mezière G, Biderman P, et al. The comet-tail artifact. An ultrasound sign of alveolar-interstitial syndrome. *American journal of respiratory and critical care medicine*. 1997;156(5):1640-1646. doi:10.1164/ajrccm.156.5.96-07096
10. Jambrik Z, Gargani L, Adamicza Á, et al. B-lines quantify the lung water content: A lung ultrasound versus lung gravimetry study in acute lung injury. *Ultrasound in Medicine and Biology*. 2010;36(12). doi:10.1016/j.ultrasmedbio.2010.09.003
11. Soldati G, Inchingolo R, Smargiassi A, et al. Ex Vivo Lung Sonography: Morphologic-Ultrasound Relationship. *Ultrasound in Medicine and Biology*. 2012;38:1169-1179. doi:10.1016/j.ultrasmedbio.2012.03.001
12. Gargani L, Lionetti V, Di Cristofano C, Bevilacqua G, Recchia FA, Picano E. Early detection of acute lung injury uncoupled to hypoxemia in pigs using ultrasound lung comets. *Critical Care Medicine*. 2007;35(12). doi:10.1097/01.CCM.0000287525.03140.3F
13. Copetti R, Soldati G, Copetti P. Chest sonography: a useful tool to differentiate acute cardiogenic pulmonary edema from acute respiratory distress syndrome. *Cardiovascular ultrasound*. 2008;6:16. doi:10.1186/1476-7120-6-16
14. Gargani L, Bruni C, Romei C, et al. Prognostic Value of Lung Ultrasound B-Lines in Systemic Sclerosis. *Chest*. 2020;158(4):1515-1525. doi:10.1016/j.chest.2020.03.075
15. Balik M, Plasil P, Waldauf P, et al. Ultrasound estimation of volume of pleural fluid in mechanically ventilated patients. *Intensive care medicine*. 2006;32(2):318-321. doi:10.1007/s00134-005-0024-2
16. Roch A, Bojan M, Michelet P, et al. Usefulness of ultrasonography in predicting pleural effusions > 500 mL in patients receiving mechanical ventilation. *Chest*. 2005;127(1):224-232. doi:10.1378/chest.127.1.224
17. Gheorghide M, Follath F, Ponikowski P, et al. Assessing and grading congestion in acute heart failure: A scientific statement from the acute heart failure committee of the heart failure association of the European society of cardiology and endorsed by the European society of intensive care medicine. *European Journal of Heart Failure*. 2010;12:423-433. doi:10.1093/eurjhf/hfq045
18. Rudski LG, Lai WW, Afilalo J, et al. Guidelines for the echocardiographic assessment of the right heart in adults: a report from the American Society of Echocardiography endorsed by the European Association of Echocardiography, a registered branch of the European Society of Cardiology, and t. *J Am Soc Echocardiogr*. 2010;23:685-713. doi:10.1016/j.echo.2010.05.010
19. Pellicori P, Carubelli V, Zhang J, et al. IVC diameter in patients with chronic heart failure:

- relationships and prognostic significance. *JACC Cardiovascular imaging*. 2013;6(1):16-28. doi:10.1016/j.jcmg.2012.08.012
20. Pellicori P, Shah P, Cuthbert J, et al. Prevalence, pattern and clinical relevance of ultrasound indices of congestion in outpatients with heart failure. *European journal of heart failure*. 2019;21(7):904-916. doi:10.1002/ejhf.1383
 21. Pellicori P, Kallvikbacka-Bennett A, Dierckx R, et al. Prognostic significance of ultrasound-assessed jugular vein distensibility in heart failure. *Heart*. 2015;101(14):1149. doi:10.1136/heartjnl-2015-307558
 22. Pellicori P, Platz E, Dauw J, et al. Ultrasound imaging of congestion in heart failure: examinations beyond the heart. *Eur J Heart Fail*. 2021;23(5):703-712. doi:10.1002/ejhf.2032
 23. Beaubien-Souligny W, Rola P, Haycock K, et al. Quantifying systemic congestion with Point-Of-Care ultrasound: development of the venous excess ultrasound grading system. *Ultrasound J*. 2020;12(1):16. doi:10.1186/s13089-020-00163-w
 24. Platz E, Jhund PS, Girerd N, et al. Expert consensus document: Reporting checklist for quantification of pulmonary congestion by lung ultrasound in heart failure. *European journal of heart failure*. 2019;21(7):844-851. doi:10.1002/ejhf.1499
 25. Pivetta E, Goffi A, Lupia E, et al. Lung ultrasound-implemented diagnosis of acute decompensated heart failure in the emergency department - a simeu multicenter study. *Chest*. 2015;148(1). doi:10.1378/chest.14-2608
 26. Pivetta E, Goffi A, Nazerian P, et al. Lung ultrasound integrated with clinical assessment for the diagnosis of acute decompensated heart failure in the emergency department: a randomized controlled trial. *European journal of heart failure*. 2019;21(6):754-766. doi:10.1002/ejhf.1379
 27. Platz E, Campbell RT, Claggett B, et al. Lung Ultrasound in Acute Heart Failure: Prevalence of Pulmonary Congestion and Short- and Long-Term Outcomes. *JACC Heart failure*. 2019;7(10):849-858. doi:10.1016/j.jchf.2019.07.008
 28. Buessler A, Chouihed T, Duarte K, et al. Accuracy of Several Lung Ultrasound Methods for the Diagnosis of Acute Heart Failure in the ED: A Multicenter Prospective Study. *Chest*. 2020;157(1):99-110. doi:10.1016/j.chest.2019.07.017
 29. Rastogi T, Bozec E, Pellicori P, et al. Prognostic Value and Therapeutic Utility of Lung Ultrasound in Acute and Chronic Heart Failure: A Meta-Analysis. *JACC Cardiovasc Imaging*. 2022;15(5):950-952. doi:10.1016/j.jcmg.2021.11.024
 30. Scali MC, Zagatina A, Simova I, et al. B-lines with Lung Ultrasound: The Optimal Scan Technique at Rest and During Stress. *Ultrasound in Medicine and Biology*. 2017;43(11):2558-2566. doi:10.1016/j.ultrasmedbio.2017.07.007
 31. Merli E, Ciampi Q, Scali MC, et al. Pulmonary Congestion During Exercise Stress Echocardiography in Ischemic and Heart Failure Patients. *Circulation: Cardiovascular Imaging*. 2022;15(5):e013558. doi:10.1161/CIRCIMAGING.121.013558
 32. Pivetta E, Baldassa F, Masellis S, Bovaro F, Lupia E, Maule MM. Sources of Variability in the Detection of B-Lines, Using Lung Ultrasound. *Ultrasound in medicine & biology*. 2018;44(6):1212-1216. doi:10.1016/j.ultrasmedbio.2018.02.018
 33. Platz E, Pivetta E, Merz AA, Peck J, Rivero J, Cheng S. Impact of device selection and clip duration on lung ultrasound assessment in patients with heart failure. *The American journal of emergency medicine*. 2015;33(11):1552-1556. doi:10.1016/j.ajem.2015.06.002
 34. Frasure SE, Matilsky DK, Siadecki SD, Platz E, Saul T, Lewiss RE. Impact of patient positioning on lung ultrasound findings in acute heart failure. *European heart journal Acute cardiovascular care*. 2015;4(4):326-332. doi:10.1177/2048872614551505
 35. Coiro S, Rossignol P, Ambrosio G, et al. Prognostic value of residual pulmonary congestion at discharge assessed by lung ultrasound imaging in heart failure. *European Journal of Heart Failure*. 2015;17(11):1172-1181. doi:10.1002/ejhf.344
 36. Gargani L, Pang PSS, Frassi F, et al. Persistent pulmonary congestion before discharge predicts rehospitalization in heart failure: a lung ultrasound study. *Cardiovascular Ultrasound*. 2015;13(1):40. doi:10.1186/s12947-015-0033-4
 37. Jambrik Z, Monti S, Coppola V, et al. Usefulness of ultrasound lung comets as a nonradiologic sign of extravascular lung water. *The American Journal of Cardiology*. 2004;93(10):1265-1270. doi:10.1016/j.amjcard.2004.02.012

38. Gargani L, Sicari R, Raciti M, et al. Efficacy of a remote web-based lung ultrasound training for nephrologists and cardiologists: a LUST trial sub-project. *Nephrology Dialysis Transplantation*. 2016;31(12):gfw329. doi:10.1093/ndt/gfw329
39. Cibinel GA, Casoli G, Elia F, et al. Diagnostic accuracy and reproducibility of pleural and lung ultrasound in discriminating cardiogenic causes of acute dyspnea in the Emergency Department. *Internal and Emergency Medicine*. 2012;7:65-70. doi:10.1007/s11739-011-0709-1
40. Mazzola M, Pugliese NR, Zavagli M, et al. Diagnostic and Prognostic Value of Lung Ultrasound B-Lines in Acute Heart Failure With Concomitant Pneumonia. *Front Cardiovasc Med*. 2021;8:693912. doi:10.3389/fcvm.2021.693912
41. Chiu L, Jairam MP, Chow R, et al. Meta-Analysis of Point-of-Care Lung Ultrasonography Versus Chest Radiography in Adults With Symptoms of Acute Decompensated Heart Failure. *Am J Cardiol*. 2022;174:89-95. doi:10.1016/j.amjcard.2022.03.022
42. Gargani L, Pugliese NR, Frassi F, et al. Prognostic value of lung ultrasound in patients hospitalized for heart disease irrespective of symptoms and ejection fraction. *ESC Heart Fail*. 2021;8(4):2660-2669. doi:10.1002/ehf2.13206
43. Volpicelli G, Caramello V, Cardinale L, Mussa A, Bar F, Frascisco MF. Bedside ultrasound of the lung for the monitoring of acute decompensated heart failure. *The American journal of emergency medicine*. 2008;26(5):585-591. doi:10.1016/j.ajem.2007.09.014
44. Cortellaro F, Ceriani E, Spinelli M, et al. Lung ultrasound for monitoring cardiogenic pulmonary edema. *Internal and Emergency Medicine*. 2016:1-7.
45. Martindale JL, Secko M, Kilpatrick JF, et al. Serial Sonographic Assessment of Pulmonary Edema in Patients With Hypertensive Acute Heart Failure. Published online 2017. doi:10.1002/jum.14336
46. Mozzini C, Di M, Perna D, et al. Lung ultrasound in internal medicine efficiently drives the management of patients with heart failure and speeds up the discharge time Inferior Cave Vein Collapsability index. *Internal and Emergency Medicine*. Published online 2017. doi:10.1007/s11739-017-1738-1
47. Pang PS, Russell FM, Ehrman R, et al. Lung Ultrasound-Guided Emergency Department Management of Acute Heart Failure (BLUSHED-AHF): A Randomized Controlled Pilot Trial. *JACC Heart failure*. 2021;9(9):638-648. doi:10.1016/j.jchf.2021.05.008
48. Öhman J, Harjola VP, Karjalainen P, Lassus J. Focused echocardiography and lung ultrasound protocol for guiding treatment in acute heart failure. *ESC heart failure*. 2018;5(1):120-128. doi:10.1002/ehf2.12208
49. Öhman J, Harjola VP, Karjalainen P, Lassus J. Assessment of early treatment response by rapid cardiothoracic ultrasound in acute heart failure: Cardiac filling pressures, pulmonary congestion and mortality. *European heart journal Acute cardiovascular care*. 2018;7(4):311-320. doi:10.1177/2048872617708974
50. Brogi E, Gargani L, Bignami E, et al. Thoracic ultrasound for pleural effusion in the intensive care unit: A narrative review from diagnosis to treatment. *Critical Care*. 2017;21(1). doi:10.1186/s13054-017-1897-5
51. Ambrosy AP, Pang PS, Khan S, et al. Clinical course and predictive value of congestion during hospitalization in patients admitted for worsening signs and symptoms of heart failure with reduced ejection fraction: findings from the EVEREST trial. *European heart journal*. 2013;34(11):835-843. doi:10.1093/eurheartj/ehs444
52. Chioncel O, Mebazaa A, Maggioni AP, et al. Acute heart failure congestion and perfusion status - impact of the clinical classification on in-hospital and long-term outcomes; insights from the ESC-EORP-HFA Heart Failure Long-Term Registry. *Eur J Heart Fail*. 2019;21(11):1338-1352. doi:10.1002/ehf.1492
53. Al Coiro et S, Coiro S, Rossignol P, et al. Prognostic value of residual pulmonary congestion at discharge assessed by lung ultrasound imaging in heart failure. *European Journal of Heart Failure*. 2015;17(11):1172-1181. doi:10.1002/ehf.344
54. Cogliati C, Casazza G, Ceriani E, et al. Lung ultrasound and short-term prognosis in heart failure patients. *International Journal of Cardiology*. 2016;218. doi:10.1016/j.ijcard.2016.05.010
55. Palazzuoli A, Ruocco G, Beltrami M, Nuti R, Cleland JG. Combined use of lung ultrasound, B-type natriuretic peptide, and echocardiography for outcome prediction in patients with acute

- HFrEF and HFpEF. *Clinical research in cardiology : official journal of the German Cardiac Society*. 2018;107(7):586-596. doi:10.1007/s00392-018-1221-7
56. Coiro S, Porot G, Rossignol P, et al. Prognostic value of pulmonary congestion assessed by lung ultrasound imaging during heart failure hospitalisation: A two-centre cohort study. *Scientific Reports*. 2016;6:39426. doi:10.1038/srep39426
57. Lindner M, Thomas R, Claggett B, et al. Quantification of pleural effusions on thoracic ultrasound in acute heart failure. *Eur Heart J Acute Cardiovasc Care*. 2020;9(5):513-521. doi:10.1177/2048872620901835
58. Pellicori P, Cleland JGF, Zhang J, et al. Cardiac Dysfunction, Congestion and Loop Diuretics: their Relationship to Prognosis in Heart Failure. *Cardiovascular drugs and therapy*. 2016;30(6):599-609. doi:10.1007/s10557-016-6697-7
59. Rivas-Lasarte M, Álvarez-García J, Fernández-Martínez J, et al. Lung ultrasound-guided treatment in ambulatory patients with heart failure: a randomized controlled clinical trial (LUS-HF study). *European journal of heart failure*. 2019;21(12):1605-1613. doi:10.1002/ejhf.1604
60. Araiza-Garaygordobil D, Gopar-Nieto R, Martínez-Amezcuca P, et al. A randomized controlled trial of lung ultrasound-guided therapy in heart failure (CLUSTER-HF study). *American heart journal*. 2020;227:31-39. doi:10.1016/j.ahj.2020.06.003
61. Marini C, Fragasso G, Italia L, et al. Lung ultrasound-guided therapy reduces acute decompensation events in chronic heart failure. *Heart*. 2020;106(24):1934. doi:10.1136/heartjnl-2019-316429
62. Scali MC, Cortigiani L, Simionuc A, Gregori D, Marzilli M, Picano E. Exercise-induced B-lines identify worse functional and prognostic stage in heart failure patients with depressed left ventricular ejection fraction. *European Journal of Heart Failure*. <http://doi.wiley.com/10.1002/ejhf.776>. Published February 2017.
63. Agricola E, Picano E, Oppizzi M, et al. Assessment of Stress-induced Pulmonary Interstitial Edema by Chest Ultrasound During Exercise Echocardiography and its Correlation with Left Ventricular Function. *Journal of the American Society of Echocardiography*. 2006;19:457-463. doi:10.1016/j.echo.2005.11.013
64. Simonovic D, Coiro S, Carluccio E, et al. Exercise elicits dynamic changes in extravascular lung water and haemodynamic congestion in heart failure patients with preserved ejection fraction. *European journal of heart failure*. 2018;20(9):1366-1369. doi:10.1002/ejhf.1228
65. Pugliese NR, Mazzola M, Fabiani I, et al. Haemodynamic and metabolic phenotyping of hypertensive patients with and without heart failure by combining cardiopulmonary and echocardiographic stress test. *Eur J Heart Fail*. 2020;22(3):458-468. doi:10.1002/ejhf.1739
66. Simonovic D, Coiro S, Deljanin-Ilic M, et al. Exercise-induced B-lines in heart failure with preserved ejection fraction occur along with diastolic function worsening. *ESC heart failure*. 2021;8(6):5068-5080. doi:10.1002/ehf2.13575
67. Reddy YN V, Obokata M, Wiley B, et al. The haemodynamic basis of lung congestion during exercise in heart failure with preserved ejection fraction. *European heart journal*. 2019;40(45):3721-3730. doi:10.1093/eurheartj/ehz713
68. Coiro S, Simonovic D, Deljanin-Ilic M, et al. Prognostic Value of Dynamic Changes in Pulmonary Congestion During Exercise Stress Echocardiography in Heart Failure With Preserved Ejection Fraction. *Circulation Heart failure*. 2020;13(6):e006769. doi:10.1161/CIRCHEARTFAILURE.119.006769
69. Pugliese NR, De Biase N, Gargani L, et al. Predicting the transition to and progression of heart failure with preserved ejection fraction: a weighted risk score using bio-humoral, cardiopulmonary, and echocardiographic stress testing. *Eur J Prev Cardiol*. 2021;28(15):1650-1661. doi:10.1093/eurjpc/zwaa129
70. Lindner M, Lindsey A, Bain PA, Platz E. Prevalence and prognostic importance of lung ultrasound findings in acute coronary syndrome: A systematic review. *Echocardiography*. 2021;38(12):2069-2076. doi:10.1111/echo.15262
71. Lichtenstein D a, Mezière G a. Relevance of lung ultrasound in the diagnosis of acute respiratory failure: the BLUE protocol. *Chest*. 2008;134(1):117-125. doi:10.1378/chest.07-2800
72. Lancellotti P, Price S, Edvardsen T, et al. The use of echocardiography in acute cardiovascular care: recommendations of the European Association of Cardiovascular Imaging

- and the Acute Cardiovascular Care Association. *European heart journal cardiovascular Imaging*. 2015;16(2). doi:10.1093/ehjci/jeu210
73. Ding W, Shen Y, Yang J, He X, Zhang M. Diagnosis of pneumothorax by radiography and ultrasonography: a meta-analysis. *Chest*. 2011;140(4):859-866. doi:10.1378/chest.10-2946
74. Nazerian P, Vanni S, Volpicelli G, et al. Accuracy of point-of-care multiorgan ultrasonography for the diagnosis of pulmonary embolism. *Chest*. Published online 2013. doi:10.1378/chest.13-1087
75. Copetti R, Cominotto F, Meduri S, Orso D. The “Survived Lung:” An Ultrasound Sign of “Bubbly Consolidation” Pulmonary Infarction. *Ultrasound Med Biol*. 2020;46(9):2546-2550. doi:10.1016/j.ultrasmedbio.2020.04.036
76. Lichtenstein DA. Ultrasound in the management of thoracic disease: *Critical Care Medicine*. 2007;35(Suppl):S250-S261. doi:10.1097/01.CCM.0000260674.60761.85
77. Gargani L, Soliman-Aboumarie H, Volpicelli G, Corradi F, Pastore MC, Cameli M. Why, when, and how to use lung ultrasound during the COVID-19 pandemic: enthusiasm and caution. *Eur Heart J Cardiovasc Imaging*. 2020;21(9):941-948. doi:10.1093/ehjci/jeaa163
78. Cavayas YA, Girard M, Desjardins G, Denault AY. Transesophageal lung ultrasonography: a novel technique for investigating hypoxemia. *Canadian Journal of Anesthesia/Journal canadien d'anesthésie*. 2016;63(11):1266-1276. doi:10.1007/s12630-016-0702-2
79. Russell FM, Ehrman RR, Cosby K, et al. Diagnosing acute heart failure in patients with undifferentiated dyspnea: A lung and cardiac ultrasound (LuCUS) protocol. *Academic Emergency Medicine*. 2015;22(2). doi:10.1111/acem.12570
80. Čelutkienė J, Lainscak M, Anderson L, et al. Imaging in patients with suspected acute heart failure: timeline approach position statement on behalf of the Heart Failure Association of the European Society of Cardiology. *European Journal of Heart Failure*. 2020;22(2):181-195. doi:10.1002/ejhf.1678
81. Hubert A, Girerd N, Le Breton H, et al. Diagnostic accuracy of lung ultrasound for identification of elevated left ventricular filling pressure. *Int J Cardiol*. 2019;281:62-68. doi:10.1016/j.ijcard.2019.01.055
82. Miglioranza MH, Gargani L, Sant'anna RT, et al. Lung Ultrasound for the Evaluation of Pulmonary Congestion in Outpatients: A Comparison With Clinical Assessment, Natriuretic Peptides, and Echocardiography. *JACC Cardiovascular imaging*. Published online September 2013. doi:10.1016/j.jcmg.2013.08.004
83. Kobayashi M, Gargani L, Palazzuoli A, et al. Association between right-sided cardiac function and ultrasound-based pulmonary congestion on acutely decompensated heart failure: findings from a pooled analysis of four cohort studies. *Clin Res Cardiol*. 2021;110(8):1181-1192. doi:10.1007/s00392-020-01724-8
84. Neskovic AN, Skinner H, Price S, et al. Focus cardiac ultrasound core curriculum and core syllabus of the European Association of Cardiovascular Imaging. *Eur Heart J Cardiovasc Imaging*. 2018;19(5):475-481. doi:10.1093/ehjci/jey006
85. Bedetti G, Gargani L, Corbisiero A, Frassi F, Poggianti E, Mottola G. Evaluation of ultrasound lung comets by hand-held echocardiography. *Cardiovascular Ultrasound*. 2006;4. doi:10.1186/1476-7120-4-34
86. Noble VE, Lamhaut L, Capp R, et al. Evaluation of a thoracic ultrasound training module for the detection of pneumothorax and pulmonary edema by prehospital physician care providers. *BMC medical education*. 2009;9:3-3. doi:10.1186/1472-6920-9-3
87. Zisis G, Yang Y, Huynh Q, et al. Nurse-Provided Lung and Inferior Vena Cava Assessment in Patients With Heart Failure. *J Am Coll Cardiol*. 2022;80(5):513-523. doi:10.1016/j.jacc.2022.04.064
88. de Souza LAM, Paredes RG, Giraldo T, et al. Implementation and Assessment of Lung Ultrasound Training Curriculum for Physiotherapists With a Focus on Image Acquisition and Calculation of an Aeration Score. *Ultrasound Med Biol*. 2022;48(10):2119-2127. doi:10.1016/j.ultrasmedbio.2022.06.002
89. Palazzuoli A, Ruocco G, Franci B, et al. Ultrasound indices of congestion in patients with acute heart failure according to body mass index. *Clin Res Cardiol*. 2020;109(11):1423-1433. doi:10.1007/s00392-020-01642-9

Figure 1

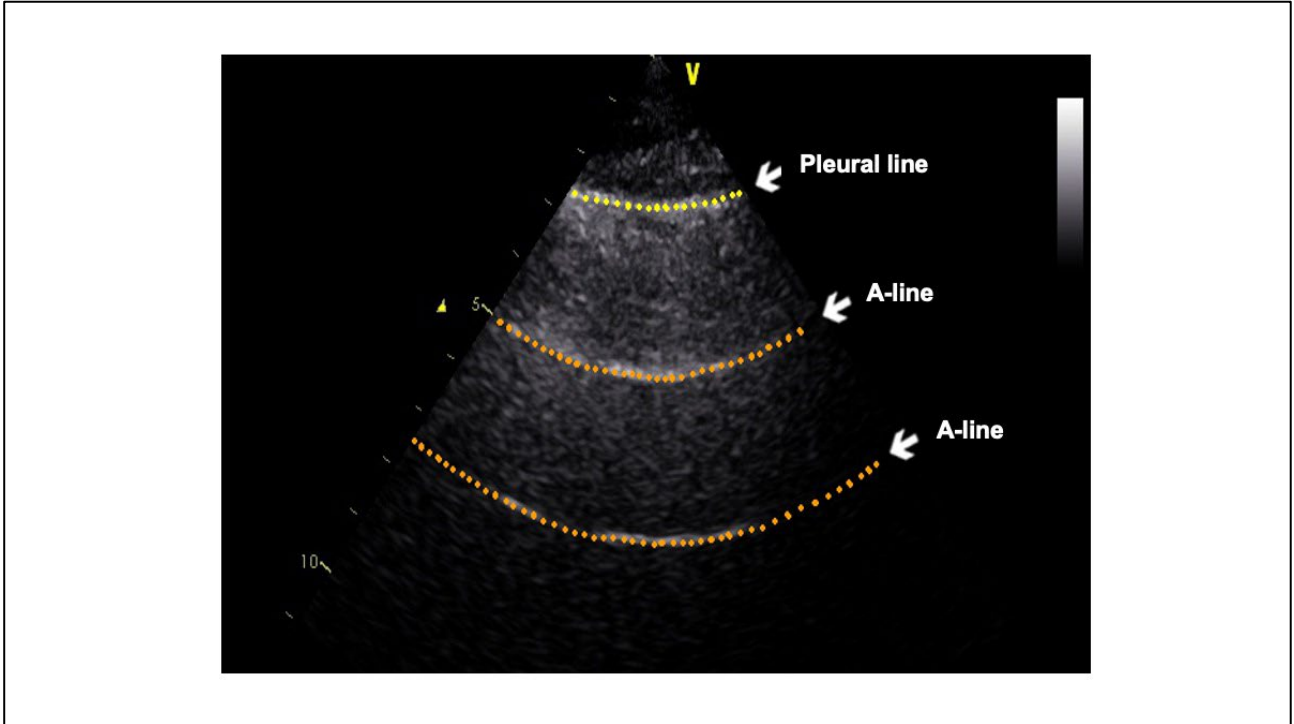


Figure 2

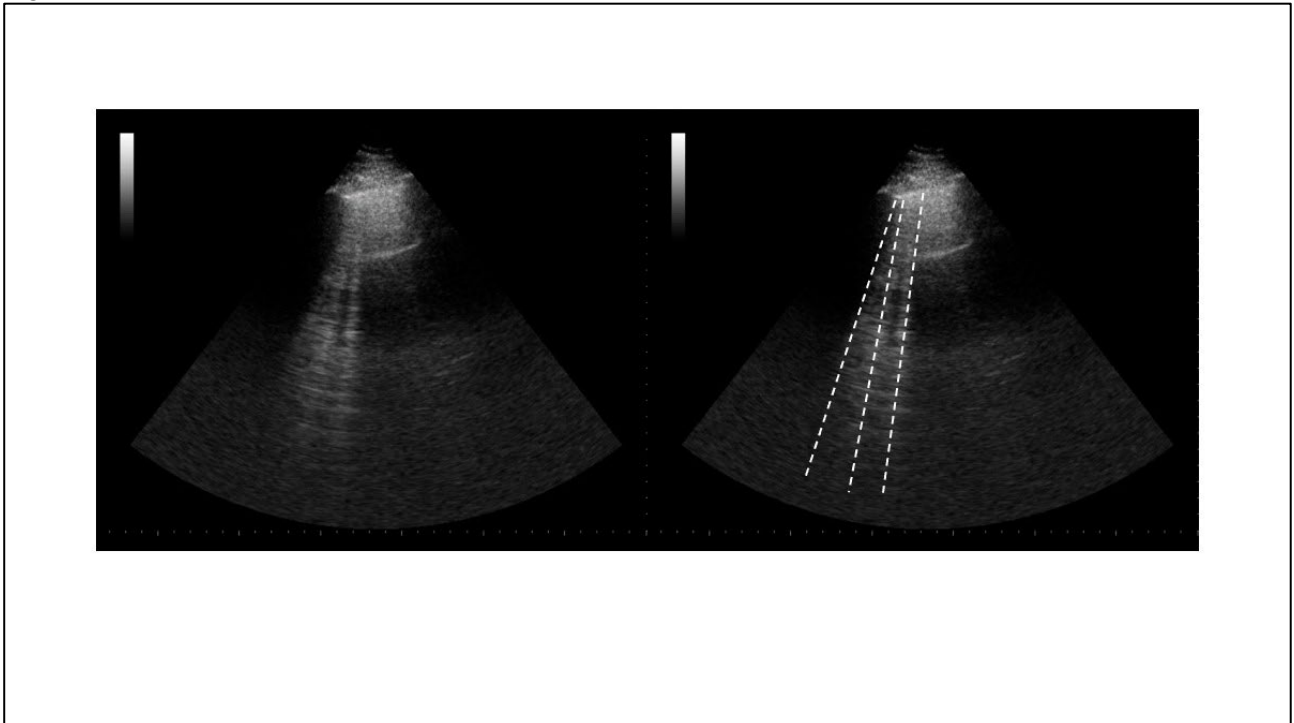


Figure 3

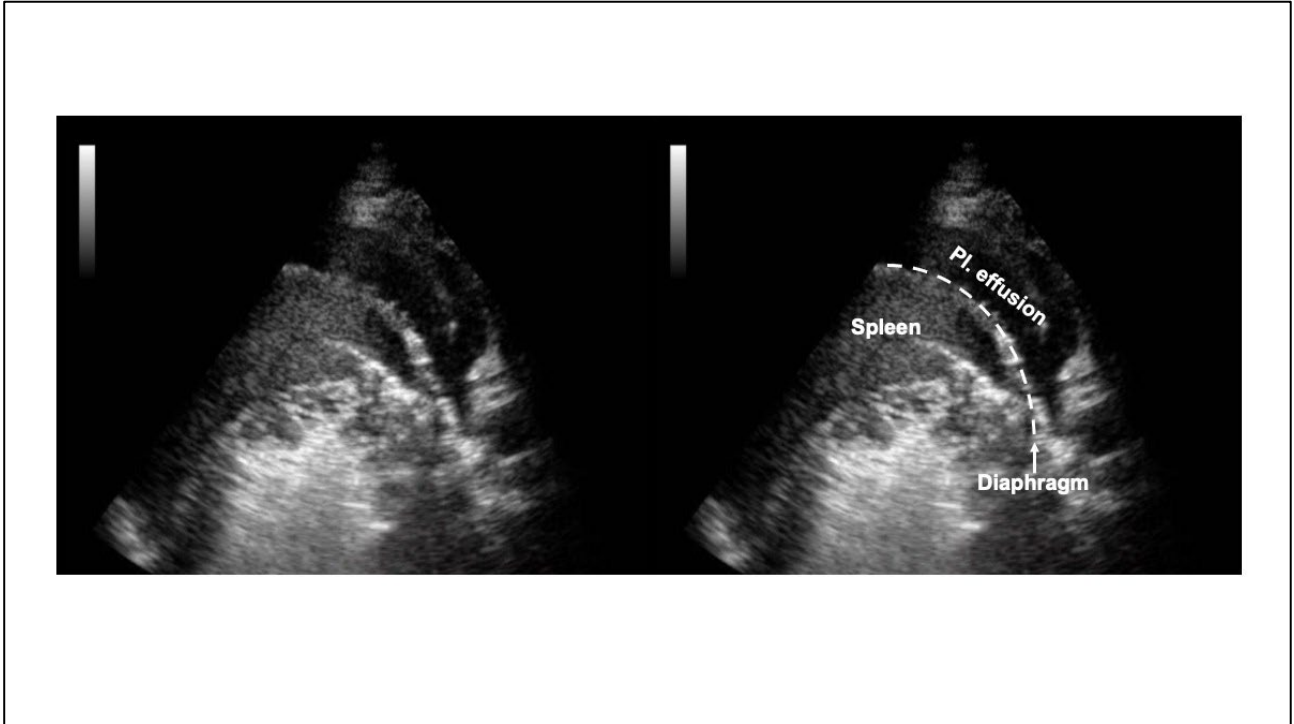


Figure 4

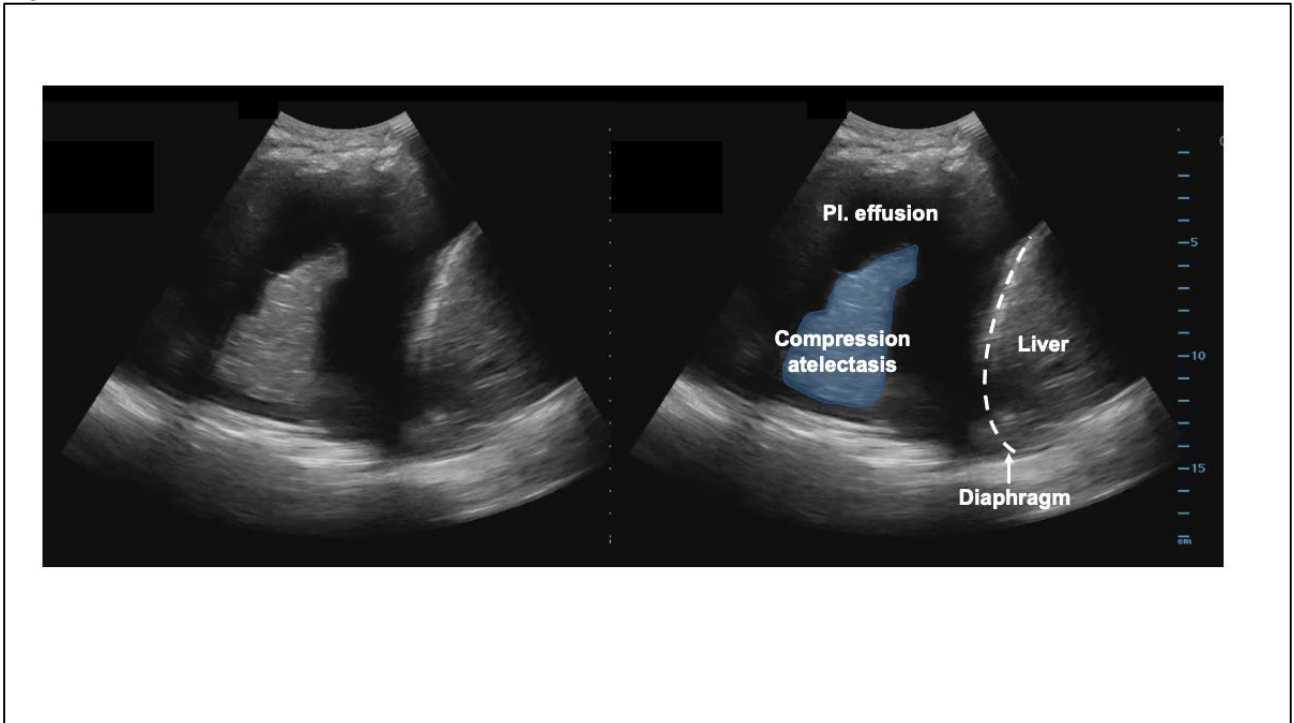


Figure 5

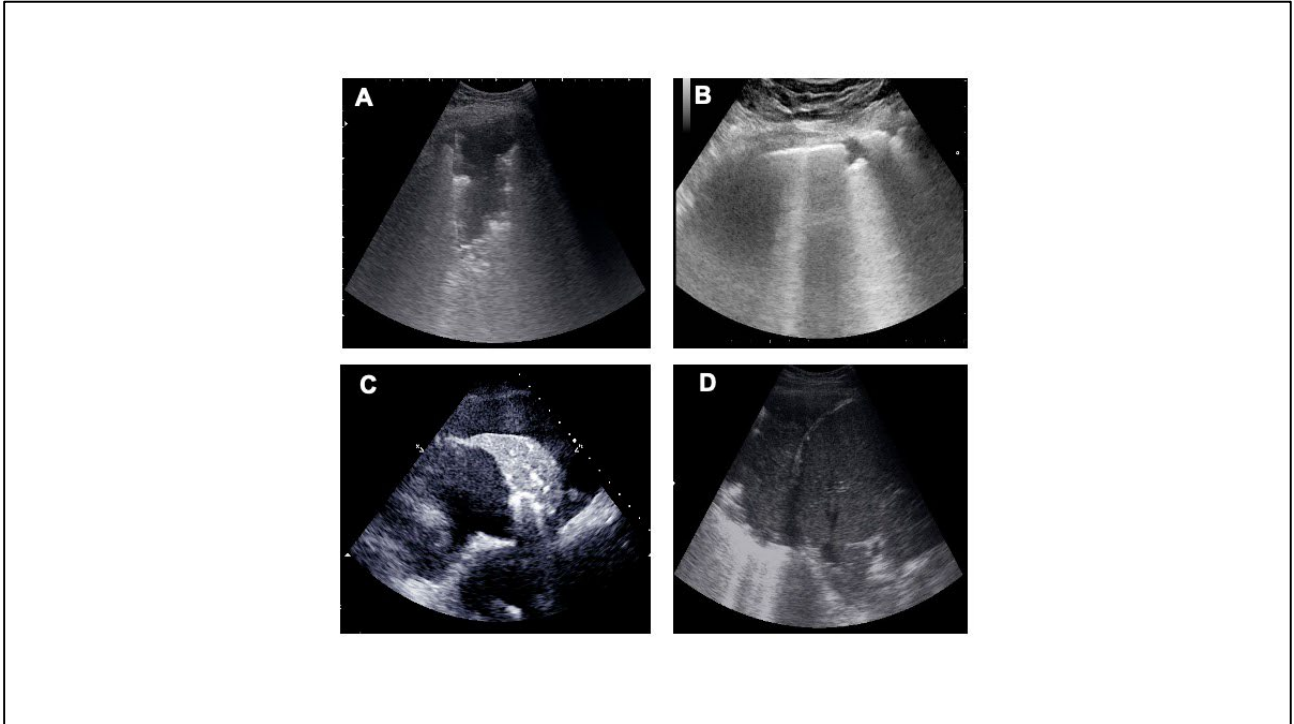


Figure 6

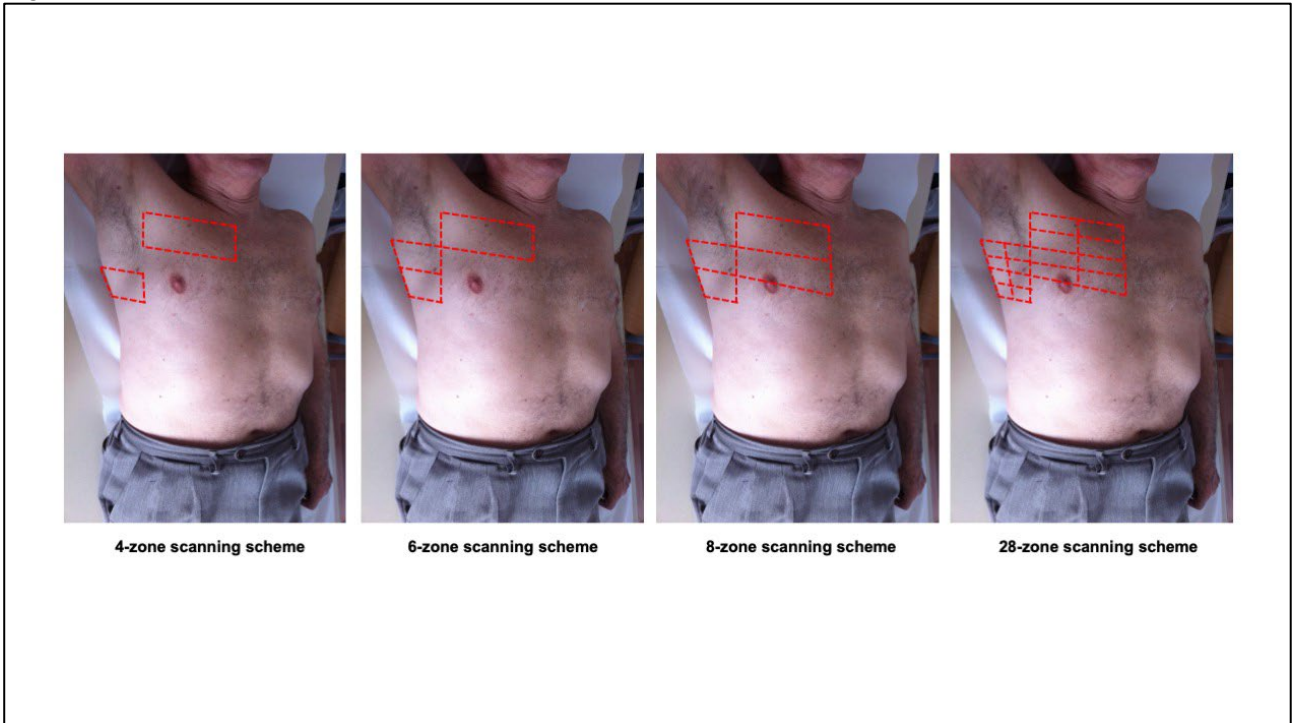


Figure 7

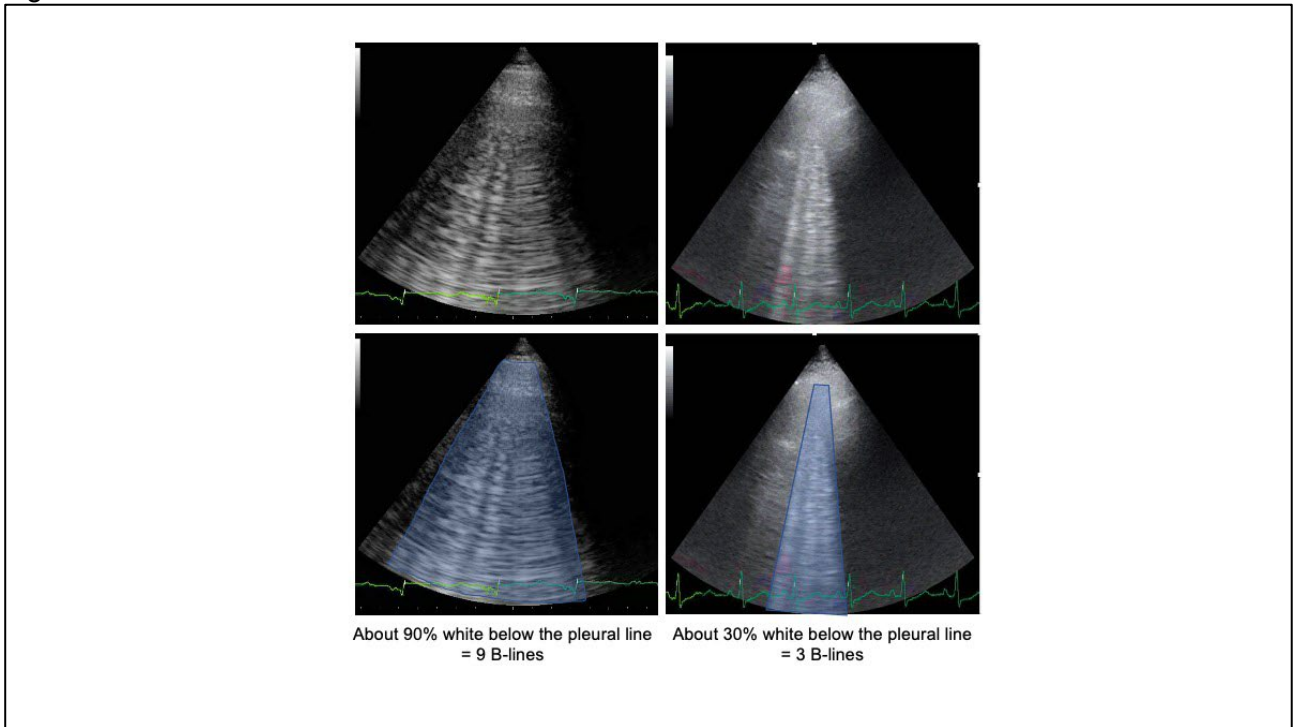


Figure 8

