

available at www.sciencedirect.com
journal homepage: www.eu-openscience.europeanurology.com



European Association of Urology



Case Report

Robotic Vena Cava Thrombectomy with Three-dimensional Augmented Reality Guidance

Daniele Amparore^{a,†}, Enrico Checcucci^{b,†,*}, Federico Piramide^a, Giovanni Busacca^a, Gabriele Volpi^b, Sabrina De Cillis^a, Michele Sica^a, Paolo Verri^a, Alberto Piana^c, Michele Di Dio^d, Cristian Fiori^a, Francesco Porpiglia^a

^a Department of Oncology, Division of Urology, University of Turin, San Luigi Gonzaga Hospital, Orbassano, Italy; ^b Department of Surgery, Candiolo Cancer Institute, FPO-IRCCS, Candiolo, Turin, Italy; ^c Romolo Hospital, Rocca di Neto, Italy; ^d Division of Urology, Department of Surgery, SS Annunziata Hospital, Cosenza, Italy

Article info

Article history:

Accepted February 2, 2024

Associate Editor:

M. Carmen Mir

Keywords:

Kidney cancer
Caval thrombus
Robotic surgery
Augmented reality
Three-dimensional models

Abstract

Robotic surgery has recently been used for treatment of renal cell carcinoma (RCC) and neoplastic thrombus located in the renal vein or inferior vena cava (IVC). Accurate identification of the thrombus location is crucial, and three-dimensional augmented reality (3D AR) may be valuable in achieving this. We enrolled patients with nonmetastatic RCC and level 0–I venous thrombus (Mayo Clinic classification) for robot-assisted radical nephrectomy and thrombectomy with 3D AR guidance. Five patients were prospectively enrolled; three had a level 0 thrombus and two had a level I thrombus. The mean operative time was 123 ± 15 min, mean IVC clamping time was 9.4 ± 6.8 min, and mean estimated blood loss was 750 ± 150 ml. The AR system allowed precise estimation of the thrombus location in all cases. No intraoperative complications or postoperative Clavien-Dindo grade >2 complications occurred. Use of 3D AR guidance allowed correct estimation of the limits of the thrombus and guided the surgeon in selecting an appropriate surgical strategy.

© 2024 The Authors. Published by Elsevier B.V. on behalf of European Association of Urology. This is an open access article under the CC BY-NC-ND license (<http://creativecommons.org/licenses/by-nc-nd/4.0/>).

1. Case series

Renal cell carcinoma (RCC) with inferior vena cava (IVC) thrombus accounts for 4–10% of all renal cancer cases. According to the European Association of Urology guidelines, surgical excision of nonmetastatic RCC with IVC thrombus is recommended for patients with an acceptable

performance status. This recommendation is supported by the latest National Comprehensive Cancer Network clinical guidelines [1].

Among the classifications available for renal vein/IVC thrombi, the Mayo Clinic scheme is one of the most frequently used, which classifies a thrombus at a level from 0 to IV according to its extent, starting from the renal vein [1].

[†] These authors contributed equally to first authorship.

* Corresponding author. Department of Surgery, Candiolo Cancer Institute, FPO-IRCCS, Strada Provinciale 142, km 3,95 10060 Candiolo, Turin, Italy. E-mail address: checcu.e@hotmail.it (E. Checcucci).



Specific surgical techniques have been recommended to address the challenges posed by RCC with tumor thrombus. While minor adjustments to the standard surgical approach for radical nephrectomy (RN) are typically required for level I thrombi, management of renal masses with level II–IV thrombi necessitates specific technical steps and skills.

In recent years, minimally invasive surgery has been proposed as a viable option for nonmetastatic RCC with IVC thrombus with promising outcomes, although this strategy is still subject to debate [2–5].

In this context, a key challenge for minimally invasive surgery is the ability to translate the fundamental principles of open RN and IVC thrombectomy to the laparoscopic and robotic environment. Successful robotic IVC thrombectomy requires extensive knowledge of the surgical anatomy, meticulous preoperative planning, and precise robotic techniques, as well as both technical and nontechnical skills.

One of the critical steps in thrombectomy is precise identification of the cranial and caudal limits of the thrombus before and during the procedure. This step is even more challenging in robotic surgery because of the lack of tactile feedback. To overcome this limitation, real-time intraoperative ultrasound imaging has been introduced for precise positioning and visualization of the target tissue during surgery via the TilePro technology, which displays images on the robotic console [6].

In recent years, the use of three-dimensional virtual models (3DVMs) has increased in popularity for minimally invasive kidney cancer surgery because of promising intraoperative advantages [7]. These models can faithfully reproduce the surgical anatomy with high-quality details to guide the surgeon during the intervention. Furthermore, the virtual images can be overlaid on the real anatomy in real time, so 3DVMs can be used in an augmented reality (AR) fashion [8], allowing surgeons to identify hidden anatomic structures. However, their role in robotic surgery for renal tumors with a renal vein or IVC thrombus has never been explored.

Our aim was to explore the feasibility of 3D AR guidance during robot-assisted RN (RARN) for renal tumors with a neoplastic thrombus in the renal vein or IVC (level 0–I).

In brief, DICOM format multiphase computed tomography (CT) images were processed by Medics (Turin, Italy; www.medics3d.com) to generate a highly accurate 3DVM of the patient-specific clinical case via hyperaccuracy 3D reconstruction techniques. Specific algorithms and software packages were used to segment the kidney, tumor, arterial and venous branches, collecting system, and thrombus. The final output was a 3DVM available for use during surgery, as previously described [8] (Fig. 1).

The kidney 3DVM was integrated in the ICON platform (Fig. 2) and a software video mixer application was used to combine the rendered video with the endoscopic camera footage. The resulting stream was transmitted back to the surgeon's da Vinci console monitor in real time, where it was used as necessary with the help of TilePro multi-input display technology. The RARN procedures were conducted by a single experienced robotic surgeon (F.P., >4000 robotic procedures previously performed). The kidney boundaries, renal pedicle, and isolated IVC were used

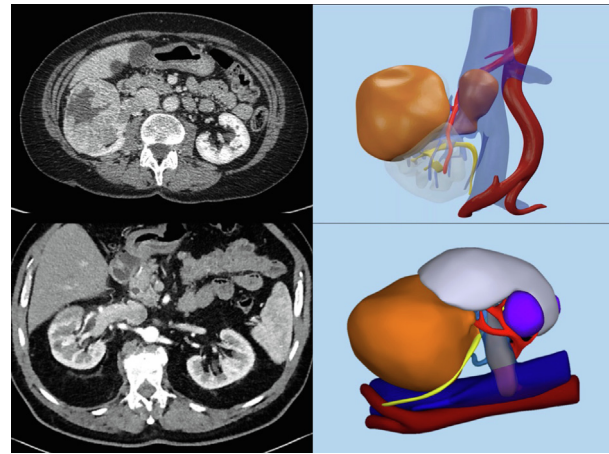


Fig. 1 – Hyperaccuracy three-dimensional models were generated from preoperative computed tomography scans.

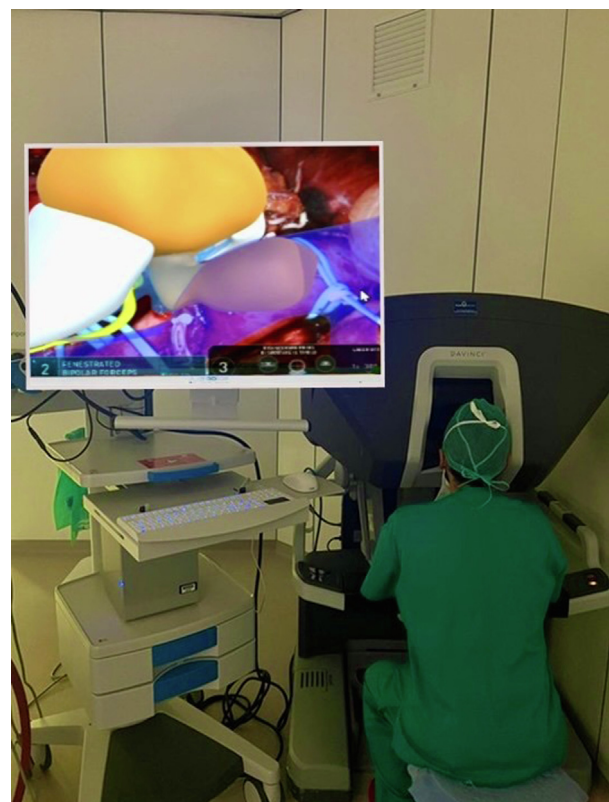


Fig. 2 – The three-dimensional models can be uploaded onto an ICON system to obtain augmented reality images.

as reference points for precise manual alignment of the 3DVMs. The thrombus was visualized inside the renal vein or IVC, and its extent and relationship to other structures, such as the contralateral renal vein, were investigated by adjusting the transparency of the 3DVMs.

After correct identification of the thrombus, cavotomy with thrombectomy and subsequent RARN were performed according to the surgical principles previously described [1] (Figs. 3 and 4).

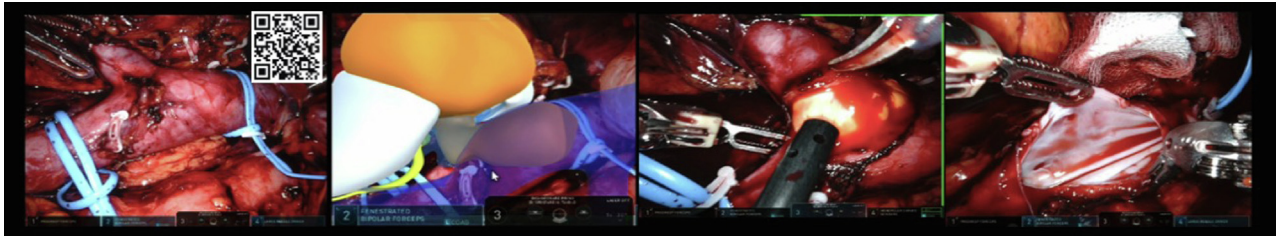


Fig. 3 – The three-dimensional models are overlaid on the real anatomy during the intervention in an augmented reality manner, allowing the surgeon to correctly identify the thrombus and perform bloodless cavotomy and thrombectomy. The QR code provides a link to the accompanying video.

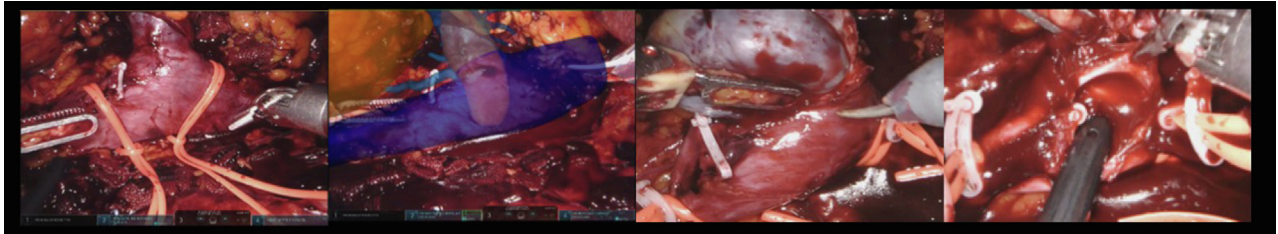


Fig. 4 – Example of thrombectomy performed under three-dimensional augmented reality guidance for a level I thrombus.

Table 1 – Clinical data for the five patients who underwent robot-assisted radical nephrectomy and vena cava thrombectomy with three-dimensional augmented reality guidance

Parameter	Result
Perioperative variables	
Median age, yr (interquartile range)	64 (57–71)
Median body mass index, kg/m ² (interquartile range)	25.6 (22.6–27.2)
Median Charlson comorbidity index (interquartile range)	4 (2–5)
American Society of Anesthesiologists score, n (%)	
≤2	2 (40)
>2	3 (60)
Mean lesion size on computed tomography, mm (standard deviation)	75.6 (21.3)
Side, n (%)	
Right	3 (60)
Left	2 (40)
Clinical T stage, n (%)	
cT3a	2 (40)
cT3b	3 (60)
Thrombus level, n (%)	
Level 0	3 (60)
Level I	2 (40)
Mean operative time, min (standard deviation)	123 (15)
Mean inferior vena cava clamping time, min (standard deviation)	9.4 (6.8)
Mean estimated blood loss, ml (standard deviation)	750 (150)
Postoperative variables	
Mean length of stay, d (standard deviation)	7 (2)
Intraoperative complications, n (%)	0 (0)
Postoperative complications, n (%)	2 (20)
Postoperative Clavien-Dindo grade >2 complications, n (%)	0 (0)
Pathological variables	
Pathological T stage, n (%)	
pT3a	3 (60)
pT3b	2 (40)
Mean pathological tumor size, mm (standard deviation)	73 (21)
Positive surgical margin, n (%)	0 (0)
Clear cell carcinoma histopathology, n (%)	5 (100)
International Society of Urological Pathology grade group, n (%)	
Grade group 1	0 (0)
Grade group 2	1 (20)
Grade group 3	4 (80)
Grade group 4	0 (0)

Five patients were enrolled, of whom three presented with right-sided RCC and two with left-sided RCC. The caval thrombus level was classified as 0 in three cases and I in two cases. The mean operative time was 123 ± 15 min, the mean IVC clamping time was 9.4 ± 6.8 min, and the median estimated blood loss was 750 ± 150 ml (Table 1).

In all five cases, the thrombus extent was correctly identified: once the cranial and caudal vessel loops were in place, the entire thrombus was included in the IVC segment. This vessel-loop enclosure allowed the surgeon to avoid direct clamping of the thrombus and guaranteed adequate closure of the IVC during cavotomy.

2. Discussion

We present the first application of 3D AR guidance for surgical treatment of RCC with caval thrombus. Our results demonstrate the suitability of this new technology in assisting the surgeon in correct identification of the thrombus location and in guiding IVC clamping.

A systematic review and meta-analysis by Garg et al [9] highlighted ongoing advances in surgical techniques for RN with IVC thrombectomy. Innovations include endovascular control of the proximal portion of the IVC and use of a single-dock approach. Nonetheless, adoption of RN with IVC thrombectomy and thus experience with this procedure remain limited in comparison to other complex surgeries such as radical cystectomy. A possible explanation for this disparity may lie in the low prevalence of RCC with tumor thrombus and the substantial complexity associated with robotic thrombectomy, which requires manipulation of major blood vessels and carries a significant risk of hemodynamic compromise due to bleeding.

With the goal of expanding indications for RARN with IVC thrombectomy, we applied the principles used for

robotic kidney transplantation surgery, for which 3D AR images facilitate intraoperative identification of atheromatous plaques in the iliac artery, allowing the surgeon to perform safe and precise clamping and arteriotomy [10]. Correct identification of a caval thrombus facilitates efficient clamping and visualization of the relationship of the thrombus to surrounding anatomic structures such as lumbar veins, which can be selectively resected, or the contralateral renal vein, for which clamping might be eventually avoided.

The main limitations for this technology are the need for expert human assistance during overlapping of 3D images and, most importantly, the different patient position during the intervention in comparison to CT scan acquisition. The latter issue may potentially be responsible for the disparities in dimensions and organ shape between the virtual model and the intraoperative field. In addition, this was a feasibility study with a small sample size and no comparative group, and we included only level 0–I thrombi. Therefore, further studies are needed to explore the feasibility, safety, and efficacy of this technology. Nevertheless, our case series may represent an important starting point for studies on 3DVMs and AR in this challenging scenario. In the near future, artificial intelligence algorithms might allow simulation of organ deformation and automatic AR overlapping, which could overcome some of the limitations identified.

In conclusion, our preliminary experience shows that 3D AR images can play a role in real-time identification of caval thrombus during RARN, although their comparability or superiority to standard ultrasound imaging has yet to be demonstrated.

Conflicts of interest: The authors have nothing to disclose.

Acknowledgments: We would like to thank Dr. Andrea Bellin and Dr. Simona Barbuto for their contribution to this work.

References

- [1] Campi R, Tellini R, Sessa F, et al. Techniques and outcomes of minimally-invasive surgery for nonmetastatic renal cell carcinoma with inferior vena cava thrombosis: a systematic review of the literature. *Minerva Urol Nefrol* 2019;71:339–58. <https://doi.org/10.23736/S0393-2249.19.03396-4>.
- [2] Wang B, Li H, Ma X, et al. Robot-assisted laparoscopic inferior vena cava thrombectomy: different sides require different techniques. *Eur Urol* 2016;69:1112–9. <https://doi.org/10.1016/j.eururo.2015.12.001>.
- [3] Chopra S, Simone G, Metcalfe C, et al. Robot-assisted level II–III inferior vena cava tumor thrombectomy: step-by-step technique and 1-year outcomes. *Eur Urol* 2017;72:267–74. <https://doi.org/10.1016/j.eururo.2016.08.066>.
- [4] Shi T, Huang Q, Liu K, et al. Robot-assisted cavectomy versus thrombectomy for level II inferior vena cava thrombus: decision-making scheme and multi-institutional analysis. *Eur Urol* 2020;78:592–602. <https://doi.org/10.1016/j.eururo.2020.03.020>.
- [5] Gill IS, Cacciamani GE, Duddalwar V, Thangathurai D, Cunningham M. Renal cancer with extensive level IV intracardiac tumour thrombus removed by robot. *Lancet* 2020;396:e88. [https://doi.org/10.1016/S0140-6736\(20\)32291-1](https://doi.org/10.1016/S0140-6736(20)32291-1).
- [6] Li Q, Li N, Luo Y, et al. Role of intraoperative ultrasound in robotic-assisted radical nephrectomy with inferior vena cava thrombectomy in renal cell carcinoma. *World J Urol* 2020;38:3191–8. <https://doi.org/10.1007/s00345-020-03141-y>.
- [7] Piramide F, Kowalewski KF, Cacciamani G, et al. Three-dimensional model-assisted minimally invasive partial nephrectomy: a systematic review with meta-analysis of comparative studies. *Eur Urol Oncol* 2022;5:640–50. <https://doi.org/10.1016/j.euo.2022.09.003>.
- [8] Porpiglia F, Checcucci E, Amparore D, et al. Three-dimensional augmented reality robot-assisted partial nephrectomy in case of complex tumours (PADUA ≥ 10): a new intraoperative tool overcoming the ultrasound guidance. *Eur Urol* 2020;78:229–38. <https://doi.org/10.1016/j.eururo.2019.11.024>.
- [9] Garg H, Psutka SP, Hakimi AA, et al. A decade of robotic-assisted radical nephrectomy with inferior vena cava thrombectomy: a systematic review and meta-analysis of perioperative outcomes. *J Urol* 2022;208:542–60. <https://doi.org/10.1097/JU.0000000000002829>.
- [10] Piana A, Gallioli A, Amparore D, et al. Three-dimensional augmented reality-guided robotic-assisted kidney transplantation: breaking the limit of atheromatic plaques. *Eur Urol* 2022;82:419–26. <https://doi.org/10.1016/j.eururo.2022.07.003>.