

Aortic arch rupture after multiple multilayer stent treatment of a thoracoabdominal aneurysm

Emanuele Ferrero, MD, Lorenzo Gibello, MD, Michelangelo Ferri, MD, Andrea Viazzo, MD, and Franco Nessi, MD, *Turin, Italy*

Despite the improvement in diagnostic and therapeutic strategies, the treatment of thoracoabdominal aneurysms is still burdened with a high incidence of peri/postoperative morbidity and mortality. The multilayer flow modulator is a new and promising technique for the treatment of such disease; however, some limits are still evident. We report the case of a 76-year-old woman affected by a symptomatic thoracoabdominal aneurysm treated with multiple Cardiatix multilayer flow modulators complicated by aortic arch rupture on the fifth postoperative day, with subsequent patient death. (*J Vasc Surg* 2014;60:1348-52.)

We report the case of a 76-year-old female affected by thoracoabdominal aneurysm (TAA) type II (Crawford's classification). The patient's history revealed mild arterial hypertension, chronic obstructive pulmonary disease, and moderate renal failure. In February 2011, the patient presented to our clinic; the computed tomography angiography (CTA) scan showed a maximum diameter of the descending aorta of 75 mm and a dilatation in abdomen of 60 mm. Despite our indication to treat the descending TAA, the patient refused any kind of surgical/hybrid repair. Three months later, the patient was referred to us for the sudden onset of interscapular pain. The CTA revealed an increased dilatation of 6 to 7 mm in 3 months at the proximal third of the TAA without images of dissection or imminent rupture (Fig 1). The patient, despite the symptomatic aneurysm (persistent pain) and its rapid growth, rejected again any surgical/hybrid repair; the only treatment she would accept was an endovascular approach. Branched and fenestrated endovascular options were preventively excluded due to the amount of time needed to obtain the devices, while the chimney technique was excluded due to its inadequacy. After receiving informed consent from the patient and the hospital ethical committee and Italian Public Health Ministry authorization, an endovascular procedure with multiple Cardiatix

multilayer flow modulators (CMFMs; Crossmed, Isnes, Belgium) was planned. The CMFM, by virtue of its three-dimensional geometry, slows down and laminates blood flow inside the aneurysm sac with immediate pressure reduction (reducing the risk of aneurysm rupture), generating stasis and formation of an organized thrombus (in few months), while improving laminar flow in the main artery and surrounding vital branches.^{1,2} The main limit of the CMFM is determined by the fact that it cannot be used in a ruptured aneurysm because it cannot stop bleeding, not being a covered stent. The CTA images were reconstructed on a three-dimensional workstation (3Mensio Vascular, Bilthoven, Netherlands), and vessel diameters and lengths were calculated. We planned to use three CMFMs (three pieces of 35-150 mm), releasing them into the descending aorta by telescopic deployment from the aortic bifurcation to the origin of the left subclavian artery with a 4-cm overlap and an oversize of 10% in the proximal landing zone and of 30% in the distal landing zone. The procedure was performed by vascular surgeons in an operating room equipped with a C-arm brilliance (Eurocolumbus, Milan, Italy). The fluoroscopic control images after the deployment of the modules and the ballooning maneuver showed stent shortening with loss of both central overlapping regions (Fig 2). To obviate this, a fourth CMFM (40-120 mm) was positioned and ballooned. It was also decided to balloon the proximal end point due to a fluoroscopic image of infolding (Fig 2). During the procedure, the stent retracted and dislocated with the loss of proximal sealing. We finally deployed a fifth CMFM (40-150 mm), covering the whole aortic arch and landing in the ascending aorta (Fig 2). The first 4 postoperative days were characterized by difficulties on respiratory exchanges without any neurological/visceral complication. On the 5th postoperative day, the situation dramatically collapsed; the patient became

From the Vascular and Endovascular Surgery Unit, Mauriziano Umberto I Hospital.

Author conflict of interest: none.

Reprint requests: Emanuele Ferrero, MD, Vascular and Endovascular Surgery Unit, Mauriziano Umberto I Hospital, Largo Turati 62, 10128 Turin, Italy (e-mail: emaferro@libero.it).

The editors and reviewers of this article have no relevant financial relationships to disclose per the JVS policy that requires reviewers to decline review of any manuscript for which they may have a conflict of interest.

0741-5214/\$36.00

Copyright © 2014 by the Society for Vascular Surgery.

<http://dx.doi.org/10.1016/j.jvs.2013.08.006>

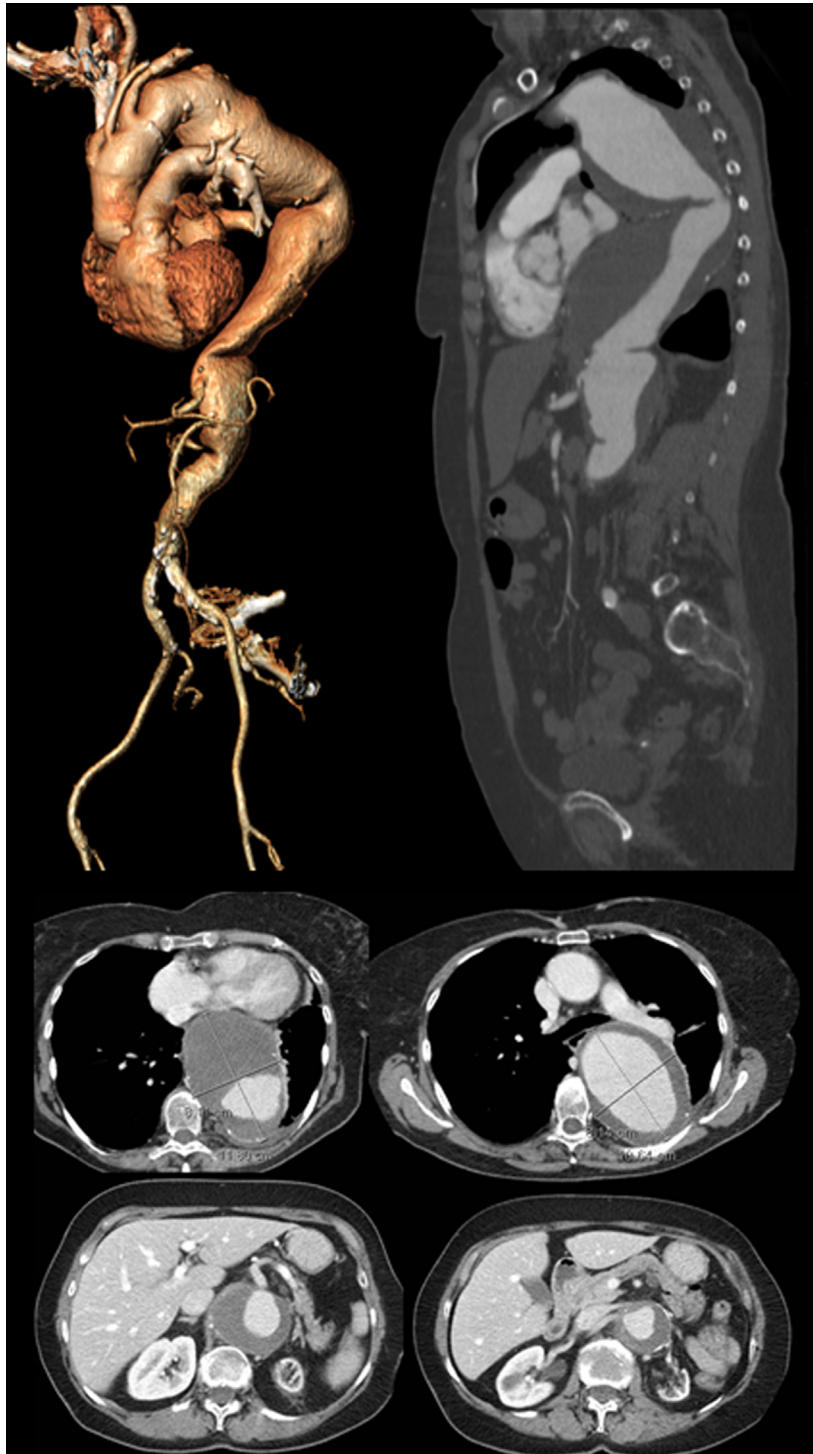

Fig 1. The computed tomography angiography (CTA) showed the maximum increased dilatation of 81 mm at vertebral T4-T6 and a dilatation of infrarenal abdominal aortic aneurysm of 60 mm. The size of the aortic arch at the common carotid artery was 32 mm, at the subclavian artery was 30 mm, and the length between the common carotid artery and the subclavian artery was 15 mm. The distal sealing zone, at the abdominal aortic artery, had a diameter of 26.5 mm and a length of sealing zone of 40 mm.

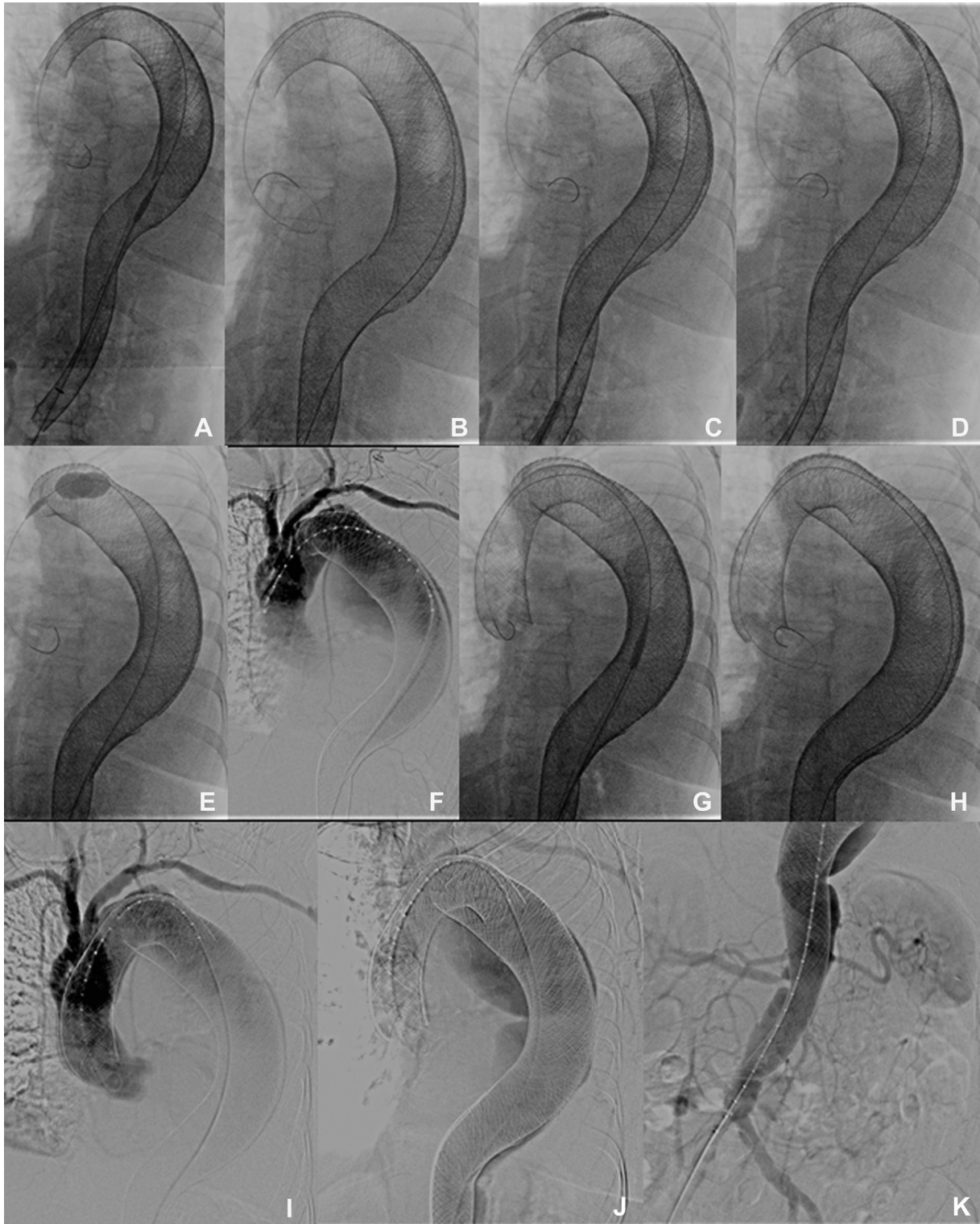

Fig 2. **A,** Fluoroscopic images of Cardiatris multilayer flow modulator (CMFM) deployment. **B,** Modules and the ballooning maneuver showed CMFMs shortening with loss of both central overlapping regions. **C-D,** A fourth CMFM was positioned and ballooned. Presence of an infolding in the proximal end point. **E-H,** After the proximal end point ballooning, the CMFM retracted and dislocated, so a fifth CMFM was deployed, covering the whole aortic arch and landing in the ascending aorta. **I-K,** Fluoroscopic images of final control after CMFMs' deployment.

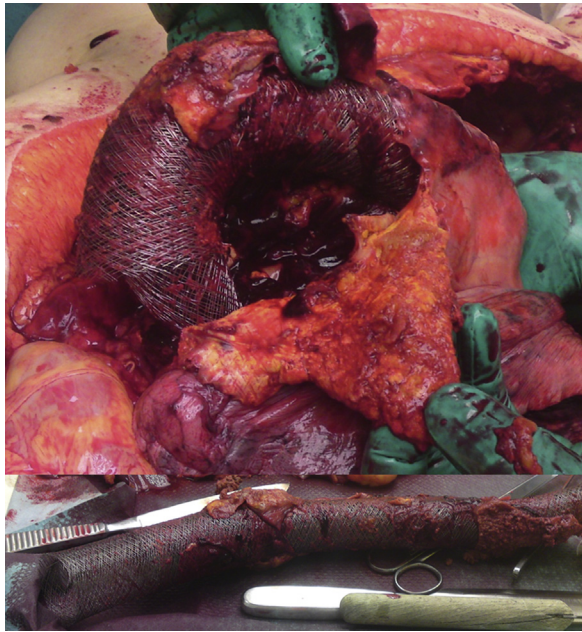


Fig 3. The autopsy images revealed the rupture of the aortic arch in proximity of the descending tract.

hemodynamically unstable and died of hemorrhagic shock. The autopsy revealed a 6-cm tear of the aortic arch wall with a conspicuous left hemothorax (Fig 3) and pointed out that the CMFMs' overlapping zone was too rigid to accommodate the degree of aortic arch angulation, leading to rupture.

DISCUSSION

The treatment of a TAA represents a high-risk surgical and endovascular procedure with a perioperative mortality rate of up to 50% in emergency cases.⁵ In the last decade, new technologies have expanded the applicability of endovascular aneurysm treatment to cases with anatomical adverse conditions and in patients with poor overall medical status.⁴ Despite improvements, the complexity and often necessary customization of the prosthesis limits the use of this method in emergency situations.⁴ Multilayer stents have been successfully used for the treatment of visceral and popliteal aneurysms with a cumulative primary and secondary patency rate of 86.9% and 90.7% at 1 year.^{1,5,6} In 2009, the CE Mark approved the use of CMFM for the treatment of aortic aneurysms (TAAs and abdominal aortic aneurysms [AAAs]).⁶⁻¹¹ Currently, few data on the reliability of the method are available, but short-term outcome of asymptomatic TAA and AAA repair with CMFM are encouraging, with a survival rate after 1 year from intervention at 92.4%.⁹⁻¹¹ However, it has been demonstrated that various complications including endoleaks, limb occlusion, and device failure can develop during follow-up.^{10,12,13} Ruptured aneurysms are considered to be the main contraindication to the use of CMFM since the thrombosis process of the aneurysmal

sac could require some months.^{5,9,14} Our case differs from others in the literature because, for the first time, multiple CMFMs have been used in a symptomatic TAA. Considering the procedure failure and the patient's death, it is questionable if it was the case of treating the patient, if the patient's own choices (no surgery) influenced the outcome, and if it was an aggressive treatment. There are some reasons that led us to use multiple CMFMs: the patient refused any surgical/hybrid treatment but endovascular; the symptomatic TAA without rupture; the impossibility of waiting for the customization of a fenestrated or branched device; and the fast aneurysm growth (6-7 mm in 3 months that likely suggested a high risk of short-/middle-term rupture). If the patient had accepted a surgical approach, we would have chosen the hybrid treatment by a carotid-subclavian bypass graft and thoracic endovascular aneurysm repair (TEVAR) deploying from the common carotid artery to the celiac artery (without a perfect seal zone in the thrombus), with a complete exclusion of thoracic aneurysm, and then a delay to a second stage with the treatment of visceral/infrarenal aortic aneurysm by fenestrated or hybrid treatment. Therefore, due to these reasons, we decided to treat the TAA by using three CMFMs, but we found some difficulties: low compliance of the device to fit the size of the vessel after its deployment with stent shortening and loss of overlapping in some tracts, stent stretching in other tracts and consequent infolding; dislodgment after ballooning maneuvers with consequent loss of overlapping regions and distal end points; and low operator experience in the treatment of TAAs with CMFM. For these reasons, we were forced to use two more CMFMs. Even if the short postoperative observation did not show any complications related to cerebral, spinal, visceral, or renal ischemia, the final result was a failure due to aortic arch rupture with subsequent patient death.

CONCLUSIONS

In the literature, the CMFM is an arising and promising device for the treatment of asymptomatic TAAs and AAAs. However, our experience points out that the use of this device in symptomatic TAAs did not have good results, leading to aneurysm rupture and patient death. Moreover, the CMFM poses some technical aspects that should be known and debated, including the remarkable deformation in diameters and length after balloon stretching and the extreme rigidity of the system of multiple CMFMs. The CMFM is not a conventional stent, and we still need to understand when and how to use it. Much more experience is needed to validate the effectiveness of the CMFM in symptomatic TAAs.

REFERENCES

1. Ferrero E, Ferri M, Viazzo A, Nessi F. Endovascular treatment of hepatic artery aneurysm by multilayer stents: two cases and one-year follow-up. *Interact Cardiovasc Thorac Surg* 2011;13:545-7.

2. Sfyroeras GS, Dalainas I, Giannakopoulos TG, Antonopoulos K, Kakisis JD, Liapis KD. Flow-diverting stents for the treatment of arterial aneurysms. *J Vasc Surg* 2012;56:839-46.
3. Rigberg DA, McGory ML, Zingmond DS, Maggard MA, Agustin M, Lawrence PF, et al. Thirty-day mortality statistics underestimate the risk of repair of thoracoabdominal aortic aneurysms: a statewide experience. *J Vasc Surg* 2006;43:217-22.
4. Moon MC, Morales JP, Greenberg RK. The aortic arch and ascending aorta: are they within the endovascular realm? *Senim Vasc Surg* 2007;20:97-107.
5. Ruffino MA, Rabbia C; Italian Cardiatists Investigators Group. Endovascular repair of peripheral and visceral aneurysms with the Cardiatist multilayer flow modulator: one-year results from the Italian Multicenter Registry. *J Endovasc Ther* 2012;19:599-610.
6. Ferrero E, Ferri M, Viazzo A, Robaldo A, Carbonatto P, Pecchio A, et al. Visceral artery aneurysms, an experience on 32 cases in a single center: treatment from surgery to multilayer stent. *Ann Vasc Surg* 2011;25:923-35.
7. Henry M, Benjelloun A, Henry I. TCT-591: a new concept of stent: the multilayer stent. First human study in TAAA & AAA. *J Am Coll Cardiol* 2011;58:B159.
8. Natrella M, Castagnola M, Navaretta F, Cristoferi M, Fanelli G, Meloni T, et al. Treatment of juxtarenal aortic aneurysm with the Multilayer stent. *J Endovasc Ther* 2012;19:121-4.
9. Sultan S, Hynes N. Disruptive endovascular technology with multilayer flow modulator stents in the management of thoraco-abdominal aortic aneurysms. *J Vasc Endovasc Surg* 2012;19:215-28.
10. Euringer W, Südkamp M, Rylski B, Blanke P. Endovascular treatment of multiple HIV-related aneurysms using multilayer stents. *Cardiovasc Intervent Radiol* 2012;35:945-9.
11. Tolva VS, Bianchi PG, Cireni LV, Lombardo A, Keller GC, Parati G, et al. Multiple multilayer stents for thoracoabdominal aortic aneurysm: a possible new tool for aortic endovascular surgery. *Int J Gen Med* 2012;5:629-32.
12. Lazaris AM, Maheras AN, Vasdekis SN. A multilayer stent in the aorta may not seal the aneurysm, thereby leading to rupture. *J Vasc Surg* 2012;56:829-31.
13. Zhang Y, LU Q, Jing Z. Multilayer stents, a new progress in the endovascular treatment of aneurysms. *Chin Med J* 2013;126:536-41.
14. Balderi A, Antonietti A, Ferro L, Peano E, Pedrazzini F, Fonio P, et al. Endovascular treatment of visceral artery aneurysms and pseudoaneurysms: our experience. *Radiol Med* 2012;117:815-30.

Submitted Jun 7, 2013; accepted Aug 9, 2013.