














# Reliability and Diagnostic Accuracy of Radiography for the Diagnosis of Calcium Pyrophosphate Deposition: Performance of the Novel Definitions Developed by an International Multidisciplinary Working Group

Silvia Sirotti,<sup>1</sup>  Fabio Becce,<sup>2</sup>  Luca M. Sconfienza,<sup>3</sup>  Lene Terslev,<sup>4</sup>  Esperanza Naredo,<sup>5</sup> Pascal Zufferey,<sup>6</sup> Carlos Pineda,<sup>7</sup>  Marwin Gutierrez,<sup>8</sup>  Antonella Adinolfi,<sup>9</sup> Teodora Serban,<sup>10</sup> Daryl MacCarter,<sup>11</sup> Gael Mouterde,<sup>12</sup> Anna Zanetti,<sup>13</sup> Anna Scanu,<sup>14</sup> Ingrid Möller,<sup>15</sup> Ulrike Novo-Rivas,<sup>16</sup> Raquel Largo,<sup>17</sup>  Piercarlo Sarzi-Puttini,<sup>1</sup> Abhishek Abhishek,<sup>18</sup> Hyon K. Choi,<sup>19</sup> Nicola Dalbeth,<sup>20</sup>  Tristan Pascart,<sup>21</sup>  Sara K. Tedeschi,<sup>22</sup>  Maria-Antonietta D'Agostino,<sup>23</sup> Annamaria Iagnocco,<sup>24</sup> Helen I. Keen,<sup>25</sup>  Carlo A. Scirè,<sup>26</sup>  and Georgios Filippou<sup>27</sup> 

**Objective.** To assess the reliability and diagnostic accuracy of new radiographic imaging definitions developed by an international multidisciplinary working group for identification of calcium pyrophosphate deposition (CPPD).

**Methods.** Patients with knee osteoarthritis scheduled for knee replacement were enrolled. Two radiologists and 2 rheumatologists twice assessed radiographic images for presence or absence of CPPD in menisci, hyaline cartilage, tendons, joint capsule, or synovial membrane, using the new definitions. In case of disagreement, a consensus decision was made and considered for the assessment of diagnostic performance. Histologic examination of postsurgical specimens under compensated polarized light microscopy was the reference standard. Prevalence-adjusted bias-adjusted kappa values were used to assess reliability, and diagnostic performance statistics were calculated.

**Results.** Sixty-seven patients were enrolled for the reliability study. The interobserver reliability was substantial in most of the assessed structures when considering all 4 readers ( $\kappa$  range 0.59–0.90), substantial to almost perfect among radiologists ( $\kappa$  range 0.70–0.91), and moderate to almost perfect among rheumatologists ( $\kappa$  range 0.46–0.88). The intraobserver reliability was substantial to almost perfect for all the observers ( $\kappa$  range 0.70–1). Fifty-one patients were included in the accuracy study. Radiography demonstrated an overall specificity of 92% for CPPD, but sensitivity remained low for all sites and for the overall diagnosis (54%).

**Conclusion.** The new radiographic definitions of CPPD are highly specific against the gold standard of histologic diagnosis. When the described radiographic findings are present, these definitions allow for a definitive diagnosis of CPPD, rather than other calcium-containing crystal depositions; however, a negative radiographic finding does not exclude the diagnosis.

## INTRODUCTION

Calcium pyrophosphate deposition (CPPD) disease is the umbrella term used to describe all instances of calcium

pyrophosphate (CPP) crystal deposition in tissues (1). It can present with heterogeneous phenotypes ranging from an asymptomatic form to acute or chronic arthritis, or can overlap with other rheumatic diseases (1), making the diagnosis challenging and

Supported by the Italian Ministry of Health: Ricerca Corrente. Dr. Tedeschi's work was supported by the NIH (grants K23-AR-075070 and L30-AR-070514).

<sup>1</sup>Silvia Sirotti, MD, Piercarlo Sarzi-Puttini, MD: Rheumatology Department, Luigi Sacco University Hospital and Department of Clinical Sciences and Community Health, Università degli Studi di Milano, Milan, Italy; <sup>2</sup>Fabio Becce, MD: Department of Diagnostic and Interventional Radiology, Lausanne University Hospital and University of Lausanne, Lausanne, Switzerland; <sup>3</sup>Luca M. Sconfienza, MD, PhD: Department of Biomedical Sciences for Health, Università Degli Studi di Milano, and IRCCS Istituto Ortopedico Galeazzi, Milan, Italy; <sup>4</sup>Lene Terslev, MD, PhD: Center for Rheumatology and Spine Diseases, Rigshospitalet, Copenhagen University, Copenhagen, Denmark; <sup>5</sup>Esperanza

Naredo, MD, PhD: Rheumatology Department, Joint and Bone Research Unit, Hospital Universitario Fundación Jiménez Díaz, Universidad Autónoma, Madrid, Spain; <sup>6</sup>Pascal Zufferey, MD: Rheumatology Department, University of Lausanne, CHUV, Lausanne, Switzerland; <sup>7</sup>Carlos Pineda, MD, PhD: Division of Rheumatology, Instituto Nacional de Rehabilitación, Mexico City, Mexico; <sup>8</sup>Marwin Gutierrez, MD: Division of Rheumatology, Instituto Nacional de Rehabilitación, Mexico City, Mexico; <sup>9</sup>Antonella Adinolfi, MD: Rheumatology Unit, ASST Grande Ospedale Metropolitano Niguarda, Milan, Italy; <sup>10</sup>Teodora Serban, MD, PhD: Rheumatology Department, Ospedale La Colletta, ASL3 Genovese, Genoa, Italy; <sup>11</sup>Daryl MacCarter, MD: Rheumatology Department, North Valley Hospital, Whitefish, Montana; <sup>12</sup>Gael Mouterde, MD: Rheumatology Department, CHU Montpellier, Montpellier University, Montpellier,

raising questions about attribution of symptoms to CPPD versus other arthropathies. CPPD disease appears to be the third most common form of inflammatory arthritis (2), and its prevalence increases with age. In selected populations, prevalence may reach 13% when defined as radiographic chondrocalcinosis (3,4). However, due to the nature of the disease and the lack of a noninvasive reference test, the estimated prevalence is probably minimizing the real occurrence of the disease in the general population. Furthermore, CPPD is an understudied and underdiagnosed condition, and there are still major unmet needs, as its pathogenesis is not fully understood, validated classification criteria have not been published to date, specific and effective therapies are lacking, and validated and reliable imaging techniques that may provide an accurate diagnosis have not been established (3,5–7).

The definitive diagnosis of CPPD has required visualization of CPP crystals (8) in synovial fluid analysis (1). However, synovial fluid analysis is not always feasible in clinical practice, is operator dependent, and only has ~70% sensitivity, meaning that ~30% of patients with CPPD could be missed (9–11). For this reason, a series of advanced imaging modalities are under investigation for use in CPPD diagnosis such as ultrasonography, computed tomography (CT), dual-energy CT (DECT), multi-energy spectral photon-counting CT (SPCCT), and spectral photon-counting radiography, showing promising results (12–18). However, to date, validation of these techniques as possible outcome instruments in CPPD is still in progress. Among these imaging modalities, ultrasonography has had the most progress and has been assessed for construct, content, and criterion validity within the Outcome Measures in Rheumatology (OMERACT) Ultrasound Working Group (12,13), but its availability and the need for specific training limit its use.

Radiography is still considered an important diagnostic method for detecting chondrocalcinosis (i.e., the presence of any calcium deposition within articular cartilage), given its widespread use and low cost. Furthermore, a major advantage of radiography is that it provides an overview of the entire joint, allowing assessment of the differential diagnosis or coexisting diseases. However, there are very few studies that examine its diagnostic

performance in CPPD (19), and there are no studies on its reliability, making this imaging technique inappropriate for use as an outcome measure or for clinical use to differentiate CPP crystals from basic calcium phosphate (BCP) crystals.

The need to reconsider imaging techniques as outcome measures in CPPD is remarkably relevant given the current and ongoing development of the American College of Rheumatology (ACR)/EULAR CPPD classification criteria (20). In parallel to this project, an international working group including members of the ACR/EULAR CPPD Classification Criteria Working Group (9 rheumatologists and 1 musculoskeletal radiologist) and 5 external musculoskeletal radiologists, developed definitions of imaging features of CPPD on a variety of imaging modalities, including radiography (20). These definitions attempted to define characteristic features that differentiate CPP crystal deposits from other types of calcium crystals to increase specificity for CPPD (21). While these definitions were developed for the purpose of classification criteria for CPPD research, they may also have broader application for CPPD diagnosis.

The aim of this ancillary study (12), conducted by the CPPD subgroup of the OMERACT Ultrasound Working Group, is to evaluate the reliability and accuracy (criterion validity) of the new radiographic definitions for CPPD in the knee.

## PATIENTS AND METHODS

**Patient enrollment.** This study follows the design and methods of a previously published multicenter cross-sectional study for the validation of ultrasonography in CPPD (13). Briefly, consecutive patients with knee osteoarthritis (OA) requiring total joint replacement were prospectively enrolled in 8 centers from Italy (22 patients from the University of Siena and University of Turin), Spain (11 patients from the Hospital Universitario Fundación Jimenez Diaz, Madrid), Switzerland (10 patients from the University of Lausanne), Mexico (8 patients from the Instituto Nacional de Rehabilitación, Mexico City), Romania (7 patients from the Carol Davila University, Bucharest), the US (6 patients from North Valley Hospital, Whitefish, Montana), and France (3 patients from the University of Montpellier). All investigators of

France; <sup>13</sup>Anna Zanetti, PhD: Società Italiana di Reumatologia, Epidemiology Research Unit, Milan, Italy; <sup>14</sup>Anna Scanu, PhD: Department of Neurosciences, Physical Medicine and Rehabilitation School, University of Padova, Padova, Italy; <sup>15</sup>Ingrid Möller, MD, PhD: Instituto Poal de Reumatologia, University of Barcelona, Barcelona, Spain; <sup>16</sup>Ulrike Novo-Rivas, MD: Department of Radiology, Hospital Universitario Fundación Jiménez Díaz, Universidad Autónoma, Madrid, Spain; <sup>17</sup>Raquel Largo, PhD: Joint and Bone Research Unit, Rheumatology Department, IIS-Fundación Jiménez Díaz, Universidad Autónoma, Madrid, Spain; <sup>18</sup>Abhishek Abhishek, MD, PhD: Academic Rheumatology, University of Nottingham, Nottingham, UK; <sup>19</sup>Hyon K. Choi, MD, PhD: Division of Rheumatology, Allergy, and Immunology, Massachusetts General Hospital and Harvard Medical School, Boston; <sup>20</sup>Nicola Dalbeth, MD: Bone and Joint Research Group, Department of Medicine, Faculty of Medical and Health Sciences, University of Auckland, Auckland, New Zealand; <sup>21</sup>Tristan Pascart, MD, PhD: Rheumatology Department, Groupe Hospitalier de l'Institut Catholique de Lille, Lille Catholic University, Lille, France; <sup>22</sup>Sara K. Tedeschi, MD, MPH: Division of Rheumatology, Inflammation and Immunity, Brigham and

Women's Hospital and Harvard Medical School, Boston; <sup>23</sup>Maria-Antonietta D'Agostino, MD, PhD: Rheumatology Department, Università Cattolica del Sacro Cuore, Policlinico Universitario Agostino Gemelli IRCSS, Rome, Italy; <sup>24</sup>Annamaria Iagnocco, MD: Academic Rheumatology Centre, Department of Clinical and Biological Sciences, Università degli Studi di Torino, Turin, Italy; <sup>25</sup>Helen I. Keen, MD: School of Medicine, The University of Western Australia, Murdoch, Perth, Australia; <sup>26</sup>Carlo A. Scirè, MD, PhD: Società Italiana di Reumatologia, Epidemiology Research Unit, and School of Medicine, University of Milano-Bicocca, Milan, Italy; <sup>27</sup>Georgios Filippou, MD, PhD: IRCCS Istituto Ortopedico Galeazzi, Rheumatology Department, Milan, Italy.

Author disclosures are available at [https://onlinelibrary.wiley.com/action/downloadSupplement?doi=10.1002%2Fart.42368&file=art42368-sup-0001-Disclosureform.pdf](https://onlinelibrary.wiley.com/action/downloadSupplement?doi=10.1002%2Fart.42368&file=art42368-sup-0001- Disclosureform.pdf).

Address correspondence via email to Georgios Filippou, MD, at [g.f.filippou@gmail.com](mailto:g.f.filippou@gmail.com).

Submitted for publication April 11, 2022; accepted in revised form September 13, 2022.

each contributing site were members of the CPPD subgroup of the OMERACT Ultrasound Working Group.

Patients were recruited continuously from January 2019 to September 2019. Patients with other inflammatory joint disease or who were unable to sign the informed consent were excluded. Radiographs of patients' knees were obtained before surgery. After knee replacement, menisci and tibiofemoral hyaline cartilage, the same samples obtained in the previous validation study, were collected for histologic examination.

All participants provided written informed consent for participation in the study. This study was approved by the institutional ethics committee of the University of Ferrara (approval no. 171190, approved December 2017), which was the principal investigator site, and this study was subsequently approved by local ethics committees of all the participating centers.

**Radiographic assessment.** All patients underwent radiography of both knees  $\leq 6$  months prior to surgery, and anteroposterior, weight-bearing, and lateral radiographs were obtained using a standard protocol. For anteroposterior radiographs, right and left knees were imaged together on 14 × 17-inch film using a source-to-object distance of 72 inches, with the x-ray beam parallel to the ground. Files of the preoperative radiographs were saved in Digital Imaging and Communication in Medicine (DICOM) format, anonymized, retrieved, and read independently by 2 musculoskeletal radiologists with 15 and 16 years' experience reviewing crystal arthropathies, 1 rheumatologist with >30 years' experience reviewing crystal arthropathies, and 1 trainee rheumatologist with 4 years of experience who received specific training in the detection of CPP crystals on radiography. The radiologists assessed images on their workstations (Carestream [version 12.2; Carestream Health] or Sectra [version 23.1; Sectra]) and image archive and communication systems equipped with a mammography-certified medical monitor; the 2 rheumatologists assessed images on their personal computers equipped with at least a 24" high-definition display. For each knee, the examiners assessed the presence or absence of CPP crystal deposits using a dichotomic score evaluated at the medial and lateral menisci, tibiofemoral hyaline cartilage, quadriceps and patellar tendons, synovial membrane, and joint capsule.

The novel definitions developed by an international working group were used for the identification of CPPD (21). According to these definitions, CPPD appears on radiography as "linear or punctate opacities" that are distinctive from the "denser, nummular radio-opaque deposits" seen in BCP crystal deposition, and can be located in the fibrocartilage or hyaline articular cartilage region, synovial membrane or joint capsule region, or within tendons or entheses (Table 1; see ref. 21 for more details). The examiners were all asked to strictly apply the definitions to avoid any influence from personal experience and were provided with reference images to minimize variability in assessing CPPD (22). Investigators were blinded with regard to clinical and histologic data of the patients.

**Table 1.** Consensus definitions of imaging items indicating calcification created by an international working group for the use of conventional radiography in the diagnosis of CPPD\*

Item	Definition
Calcification in fibrocartilage or hyaline cartilage on conventional radiograph	Linear or punctate opacities in the region of fibrocartilage or hyaline articular cartilage that are distinct from denser, nummular radio-opaque deposits due to BCP deposition
Calcification of synovial membrane or joint capsule on conventional radiograph	Linear or punctate opacities in the region of synovial membrane or joint capsule that are distinct from denser, nummular radio-opaque deposits due to BCP deposition
Calcification of tendon on conventional radiograph	Linear or punctate opacities within tendons or entheses that are distinct from denser, nummular radio-opaque deposits due to BCP deposition

\* Reproduced from Table 1 in ref. 21. CPPD = calcium pyrophosphate deposition; BCP = basic calcium phosphate.

**Reliability.** Each reader performed 2 evaluations of the DICOM files, the first evaluation to assess the interreader agreement, and the second evaluation, performed 3 weeks after the first evaluation, to calculate the intrareader agreement. The order of the DICOM files was different between the 2 rounds of evaluations, and the knee to be scored was clearly indicated in the scoring sheet. The interreader agreement was assessed among all 4 readers, between the 2 radiologists, and between the 2 rheumatologists.

**Diagnostic accuracy.** After the 2 rounds of image evaluations, in case of disagreement on the presence of CPPD, a consensus decision was made by the 2 radiologists after discussion of the case on a virtual platform, and this decision was used for the assessment of accuracy. CPPD diagnosis was based on histologic examination of knee tissues. Histology provides a direct visualization of crystals within the structures of interest, allowing a comparison with what is seen in imaging in the same structures, while synovial fluid analysis (frequently used as the reference standard in other studies) provides only indirect evidence of the presence of crystals and does not allow for a direct comparison with imaging. Moreover, according to the pathogenetic mechanism of CPPD, crystals are primarily formed in cartilage and subsequently shed into the synovial space due to damage or cartilage degeneration. This suggests the importance of using histology as the reference standard because crystals could be detected in tissue specimens before they are released in synovial fluid (23).

Accuracy assessment was carried out only at the menisci and hyaline cartilage of the knee, as the joint capsule, synovial



membrane, and tendons were not retrieved during surgery. The diagnostic accuracy study was conducted according to the Standards for Reporting Diagnostic accuracy (STARD) 2015 guidelines (24).

**Histologic examination.** Menisci and femoral condyles of each patient were retrieved after knee replacement surgery, washed with phosphate buffered saline or physiologic saline solution to remove blood, put in a sterile container with a unique ID code, and stored in a refrigerator at  $-80^{\circ}\text{C}$ . Then the samples were delivered in dry ice to the University of Padua, Italy or analyzed on site following the same protocol described previously in detail (13). Briefly, menisci were cut into 10 segments of approximately the same dimensions and scraped with a curette or a spatula. Femoral condyles were sectioned in 10 different regions, and each section was scraped. The resulting material was placed directly in a slide rinsed with 70% ethanol and then with a drop of water, and the material was observed at  $400\times$  magnification using compensated polarized light microscopy. Observation was focused on the detection of CPP crystals by morphology and birefringence (Figure 1). Patients were considered positive for CPPD based on the presence of CPP crystals in  $\geq 1$  of their tissue specimens. Examiners were blinded with regard to other findings.

**Statistical analysis.** Prevalence-adjusted bias-adjusted kappa was used to measure agreement between the readers. The strength of agreement for kappa was interpreted according to the methodology described by Landis and Koch (25) as follows: kappa values ranging 0.01–0.20 were considered poor to slight agreement, 0.21–0.40 as fair agreement, 0.41–0.60 as moderate agreement, 0.61–0.80 as substantial agreement, and 0.81–1.00 as almost perfect agreement. Readers were asked to score images as absence or presence of CPP crystals, and no indeterminate data were expected. If patients had missing histology data, they were excluded from the accuracy analysis. To reach an expected kappa value of 0.85, with an expected

confidence interval lower bound of 0.75, 4 readers and 67 patients were sufficient.

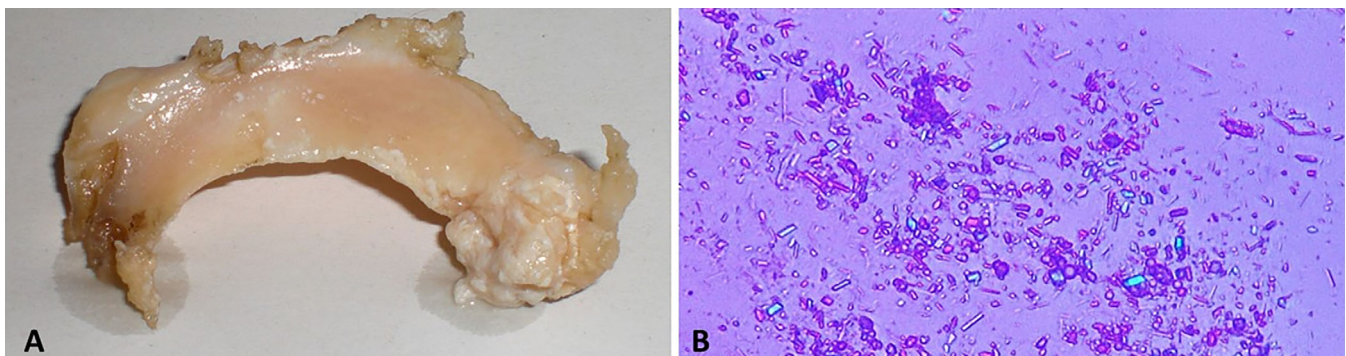
Sensitivity, specificity, positive predictive value (PPV), negative predictive value (NPV), and diagnostic accuracy were calculated; these diagnostic indexes were calculated for all the knee structures analyzed at histology (medial and lateral meniscus and tibiofemoral hyaline cartilage). The sample size necessary for estimating sensitivity and specificity was calculated as 47 patients for an expected prevalence of CPPD in these patients of 50% (12), an expected sensitivity of 75% and specificity of 90%, and an accuracy of 18% and 95% confidence level.

Statistical analyses were performed using Stata/SE version 17.0 (StataCorp).

## RESULTS

**Reliability study.** Sixty-seven patients with OA awaiting total knee replacement surgery were enrolled for the reliability study, of whom 65% were female with a mean  $\pm$  SD age of  $71 \pm 8$  years. According to Kellgren/Lawrence scale scoring (26), 1 patient had grade 1 OA, 8 patients had grade 2 OA, 31 patients had grade 3 OA, and 11 patients had grade 4 OA.

Interreader agreement among all 4 readers was substantial in most of the assessed structures, including the medial meniscus ( $\kappa = 0.70$ ), lateral meniscus ( $\kappa = 0.79$ ), quadriceps tendon ( $\kappa = 0.80$ ), patellar tendon ( $\kappa = 0.90$ ), joint capsule ( $\kappa = 0.74$ ), and synovial membrane ( $\kappa = 0.76$ ). However, assessment of hyaline cartilage had only moderate interrater reliability ( $\kappa = 0.59$ ). The overall evaluation of the knee joint proved to be moderately reliable when all anatomic structures were included for assessment ( $\kappa = 0.53$ ), and substantially reliable when only menisci and hyaline cartilage were considered ( $\kappa = 0.61$ ). Among radiologists, interreader agreement was substantial to almost perfect in all the knee structures assessed, in particular the medial meniscus ( $\kappa = 0.82$ ), lateral meniscus ( $\kappa = 0.76$ ), hyaline cartilage ( $\kappa = 0.70$ ), quadriceps tendon ( $\kappa = 0.91$ ), patellar tendon ( $\kappa = 0.88$ ), joint capsule ( $\kappa = 0.82$ ), and synovial membrane ( $\kappa = 0.79$ ). Among



**Figure 1.** A, Representative histology sample of a meniscus from a patient with knee osteoarthritis, showing superficial calcium pyrophosphate (CPP) crystal deposits. B, Polarized light microscopy analysis of a CPP deposition disease–positive meniscus sample confirming the presence of CPP crystals with the typical parallelepiped shape and weak positive birefringence.

**Table 2.** Kappa values for interreader and intrareader agreement among 2 radiologists and 2 rheumatologists when assessing knee radiographs of osteoarthritis patients for the presence of calcium pyrophosphate crystals\*

	Interreader agreement			Intrareader agreement			
	Among all readers	Between radiologists	Between rheumatologists	First radiologist	Second radiologist	Expert rheumatologist	Trainee rheumatologist
Medial meniscus	0.70	0.82	0.52	0.88	1	0.94	0.97
Lateral meniscus	0.79	0.76	0.79	0.91	0.91	0.88	0.91
Hyaline cartilage	0.59	0.70	0.46	0.88	0.97	0.79	0.94
Quadriceps tendon	0.80	0.91	0.64	0.94	1	0.85	0.94
Patellar tendon	0.90	0.88	0.88	0.97	1	1	0.94
Joint capsule	0.74	0.82	0.64	0.85	0.97	0.85	0.91
Synovial membrane	0.76	0.79	0.79	0.85	1	0.70	0.94
Menisci and cartilage	0.61	0.61	0.52	0.76	0.97	0.70	0.97
Entire joint	0.53	0.49	0.43	0.73	0.94	0.67	0.91

\* Kappa values ranging 0.01–0.20 were considered as none to slight agreement, 0.21–0.40 as fair, 0.41–0.60 as moderate, 0.61–0.80 as substantial, and 0.81–1.00 as almost perfect agreement.

rheumatologists, interreader agreement ranged from moderate to almost perfect as follows: medial meniscus ( $\kappa = 0.52$ ), lateral meniscus ( $\kappa = 0.79$ ), hyaline cartilage ( $\kappa = 0.46$ ), quadriceps tendon ( $\kappa = 0.64$ ), patellar tendon ( $\kappa = 0.88$ ), joint capsule ( $\kappa = 0.64$ ), synovial membrane ( $\kappa = 0.79$ ).

Intrareader kappa values were substantial or higher in all sites for all the observers ( $\kappa$  range 0.85–0.97 for the first radiologist,  $\kappa$  range 0.91–1 for the second radiologist,  $\kappa$  range 0.70–1 for the expert rheumatologist,  $\kappa$  range 0.91–0.97 for the trainee rheumatologist).

Kappa values for interreader and intrareader agreement of the various sites of the knee and of the overall evaluation are presented in Table 2.

**Diagnostic accuracy study.** Of the 67 enrolled patients, 51 patients (63% female; mean  $\pm$  SD age 74  $\pm$  8 years) had complete data for the histologic analysis and were included for the accuracy study. Not all specimens were retrieved during surgery; therefore, 16 of 67 patients were excluded from the accuracy study. Table 3 and Figure 2 show the relationship between the radiography and tissue histology analyses.

The prevalence of CPPD according to the reference standard (tissue histology) was 51%, and 26 of 51 patients were positive in  $\geq 1$  examined tissue sample on histology (Table 3), with 20 patients positive at the medial meniscus, 21 patients positive at the lateral meniscus, and 22 patients positive in tibiofemoral hyaline cartilage. Furthermore, 20 patients were positive at both menisci and hyaline cartilage, 3 patients at the medial and lateral meniscus, 1 patient at the medial meniscus and hyaline cartilage, and 1 patient at the lateral meniscus and hyaline cartilage. No patients were positive in only 1 structure.

On radiography analysis, 16 (31%) of 51 patients were positive for CPPD ( $\geq 1$  positive structure), with 8 patients positive at the medial meniscus, 11 patients positive at the lateral meniscus, and 13 patients positive in hyaline cartilage (Figure 2). Moreover, 5 patients were positive only in 1 structure (2 patients positive only

at the lateral meniscus, 3 patients only in hyaline cartilage), 6 patients were positive in 2 structures (1 patient at the medial and lateral menisci, 2 patients at the medial meniscus and hyaline cartilage, and 3 patients at the lateral meniscus and hyaline cartilage), and 5 patients were positive in all 3 analyzed structures.

Using histology as the reference standard, the overall accuracy of radiography was 67% for the medial meniscus, 69% for the lateral meniscus, 73% for hyaline cartilage, and 73% when considering all sites evaluated. Depending on the site, the sensitivity ranged from 32% to 48%, with an overall sensitivity of 54%; the specificity for different sites ranged from 93% to 100%, with an overall specificity of 92%. Overall PPV was 88%, and overall NPV was 66%, as shown in Table 4.

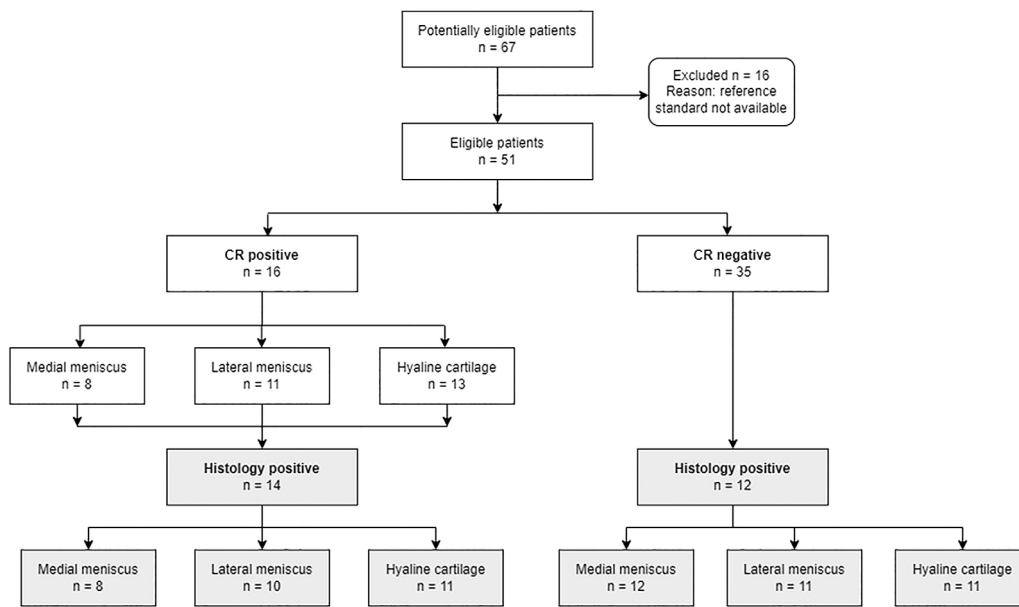
## DISCUSSION

Why should we use radiography for detecting CPPD? This question is not easy to answer as, to date, the only available data on the utility of radiography in assessing CPPD are its diagnostic accuracy, which in a recent meta-analysis was estimated at 60% sensitivity and 96% specificity (19). Undoubtedly, this estimated sensitivity is quite low for an imaging technique, especially when compared with advanced imaging such as ultrasonography, which in the same meta-analysis had an estimated 81% sensitivity and 90% specificity using pooled values. Furthermore,

**Table 3.** CPPD diagnostic status according to radiography versus tissue histology in patients with knee osteoarthritis (N = 51)\*

	Histology		Total assessed
	Positive for CPPD	Negative for CPPD	
Radiography			
Positive for CPPD	14	2	16
Negative for CPPD	12	23	35
Total assessed	26	25	51

\* Tissue histology was the reference standard. CPPD = calcium pyrophosphate deposition.



**Figure 2.** Flow chart showing the number of included osteoarthritis patients determined to be positive or negative for calcium pyrophosphate deposition (CPPD) by conventional radiography (CR) followed by confirmation of radiographic findings using tissue histology (reference standard) and stratified by specific CPPD-positive knee structure.

ultrasonography is harmless, can be performed directly by a rheumatologist during the visit, can also assess inflammation and joint damage, and has been validated for all these uses by the OMERACT Ultrasound Working Group (11,12,27). Nevertheless, radiography is still considered useful in guidelines for CPPD diagnosis (1) and is generally the first-line diagnostic test used by most rheumatologists for assessing joints with pain, especially when degenerative disease is suspected. Indeed, radiography is able to identify joint damage, provides a panoramic view of the joint, and is widely available and cheap. But its main advantage is that the technique is standardized and performed by trained personnel, and interpretation of findings is quite simple. On the contrary, ultrasonography requires a longer training period for learning the necessary skills, correct scanning technique, and interpretation of ultrasound findings.

Given these premises, an international working group including members of the ACR/EULAR CPPD Classification Criteria Working Group and external musculoskeletal radiologists developed specific definitions for identification of CPPD on radiography

(21). Until now, the presence of calcifications in joints on radiography was defined as chondrocalcinosis, a Greek term meaning the presence of calcium crystals in cartilage; however, chondrocalcinosis is not necessarily due exclusively to CPPD but also to other calcium crystals such as BCP (1,28). The international working group attempted to differentiate between CPPD and other calcium crystal deposition by describing specific characteristics of CPP deposition in contrast to BCP deposition. Therefore, the new definitions must be validated for reliability and diagnostic performance before they can be used for research purposes or in clinical practice.

In this study, we decided to assess the agreement not only between radiologists but also between rheumatologists, including a trainee with brief experience in imaging to simulate the real-life scenario in which radiographs are often read directly by a clinician. The kappa values between the radiologists demonstrated that, when assessed by experts, the reliability of the international working group definitions was always high ( $\kappa \geq 0.70$ ) in the sites examined. The intrareader reliability of the 2 radiologists was also

**Table 4.** Performance of radiography for identification of CPPD positivity at evaluated knee structures of osteoarthritis patients using the definitions developed by an international working group\*

	Diagnostic performance at specific knee structure			Overall performance
	Medial meniscus	Lateral meniscus	Hyaline cartilage	
Sensitivity	32 (15–54)	40 (21–61)	48 (27–69)	54 (33–73)
Specificity	100 (87–100)	96 (80–100)	93 (76–99)	92 (74–99)
Positive predictive value	100	91 (58–99)	85 (58–96)	88 (64–97)
Negative predictive value	60 (54–67)	63 (55–70)	68 (59–76)	66 (55–75)
Accuracy	67 (52–79)	69 (54–81)	73 (58–84)	73 (58–84)

\* Values are the percentage (95% confidence interval). CPPD = calcium pyrophosphate deposition.

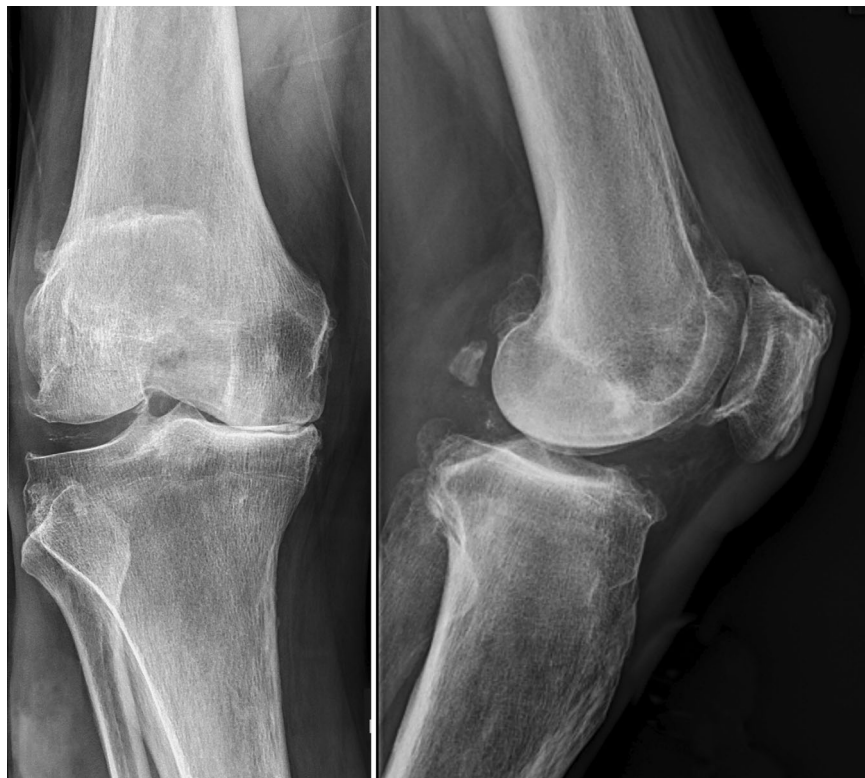substantial or perfect, meaning that both radiologists applied the definitions easily and that both of them perceived the definitions in a similar way. On the other hand, interreader agreement between rheumatologists was lower (kappa values ranging from 0.46 to 0.88 depending on the site), meaning that perception of the definitions was different between the 2 investigators, but the definitions were consistently applied by each investigator, as intrareader agreement was substantial or optimal in all sites.

The highest kappa differences between radiologists and rheumatologists were observed when investigators evaluated the medial meniscus and hyaline cartilage. Considering that most of the patients included in the study were affected by knee OA in advanced stages, the anatomic changes at the medial compartment characterized by joint rim reduction, osteophytes, cartilage thinning, and meniscal protrusion, could make exact localization of the deposition difficult and explain the difference between the readers, with the rheumatologists probably less experienced in identification of changes in advanced OA (Figure 3). Furthermore, the different skills between the trainee and the expert rheumatologist could also be a reason for the discordance between the rheumatologists. Reliability was good to substantial in all other sites, including tendons, joint capsule, and synovial membrane, probably

because of the relative ease of localizing deposition in these structures on radiography, even in advanced grades of OA.

With regard to the criterion validity, radiography demonstrated an overall accuracy of 73%, PPV of 88%, NPV of 66%, sensitivity of 54%, and specificity of 92%. The highest specificity was observed when evaluating the medial meniscus (100%) while the highest sensitivity was observed when evaluating the hyaline cartilage (48%). A reason for the low sensitivity could be the advanced OA of our patients that made the identification and exact localization of the deposits challenging.

This study is the first to use ad hoc definitions created by a panel of experts for radiographic identification of CPPD and confirms the results of previous studies regarding specificity, but showed a lower sensitivity than previous studies that compared radiography with synovial fluid analysis (pooled radiography sensitivity of 59%) (19) and with histology (radiography sensitivity of 75%) (9). Considering that 1 of the readers (LMS) rated the images in both studies that used histology as the reference standard (9), it is reasonable to conclude that the application of the new definitions seems to be stricter regarding the identification of CPPD than the “experience-based” identification, but this did not affect the already high specificity of radiography.



**Figure 3.** Representative radiographic images of a knee joint of an osteoarthritis patient which had divergent evaluation between readers. There was disagreement between readers on the exact location of calcium pyrophosphate crystal deposition, especially in the medial compartment. This could be due to the patient’s advanced grade of osteoarthritis involving reduction of the joint rim and dislocation of the meniscus, which generates overlap of the anatomic structures in the radiograph.



Globally, the menisci had the most reliable radiographic evaluation, independent of the experience of the reader, and the overall highest specificity for CPPD diagnosis. Radiographs of the hyaline cartilage were challenging for rheumatologists to score, with a lower specificity than menisci and only slightly higher sensitivity. Furthermore, considering that CPPD positivity in the hyaline cartilage alone was only present in <20% of radiographs and in none of the histologic specimens, whereas  $\geq 1$  meniscus was positive for CPPD in all CPPD patients, hyaline cartilage could be considered as a “second choice” site to score in case of doubts about assessment at the menisci.

This study, which attempts to validate radiography for identification of CPPD in terms of reliability and criterion validity, has several strengths. The radiographic imaging definitions used in this study were produced by a group of experts, including members of the ACR/EULAR CPPD Classification Criteria Working Group and external musculoskeletal radiologists with expertise in CPPD, with the intent to allow for a uniform diagnosis of patients with CPPD at radiography so that radiography could be included in the classification criteria (21). The definitions were tested by radiologists and rheumatologists, which yielded good or substantial agreement, and criterion validity confirmed the high specificity of the definitions for CPPD identification.

However, this study has some limitations. We enrolled very few patients with early OA or without OA (1 patient with Kellgren/Lawrence grade 1 and 8 patients with Kellgren/Lawrence grade 2), whose radiographs were less challenging to score. By adding more patients with mild OA, we would probably increase the observed diagnostic accuracy of radiography. Furthermore, synovial membrane and tendons were not retrieved during knee replacement surgery, so diagnostic accuracy at those sites could not be evaluated. Moreover, samples were not assessed for the presence of BCP crystals as optical microscopy is not sensitive enough for their identification even when alizarin red staining is used (29). However, identification of BCP crystals would not affect the results as the aim was to assess the diagnostic accuracy of radiography for CPPD. So, even in the case of false positives on radiography, it would make no difference on the assessment of diagnostic accuracy if the calcifications were due to BCP. Another limitation was the lack of standardization of radiographic protocols between different institutions of this multicenter study, and moreover, another source of variability was the use of different imaging workstations for radiograph interpretation between radiologists and rheumatologists. While these may lead to some variation, they are both strengths and limitations of the study. The variations in technical parameters and in imaging workstations contribute to the generalizability of the results and applicability of the study in rheumatology practice. Finally, some DICOM files were of low quality, creating some difficulties in the correct identification and location of deposits.

In conclusion, our study suggests that radiography has a useful role in CPPD detection. By using the new definitions,

radiography was demonstrated to be a reliable diagnostic test with an overall high specificity, which in a patient's perspective means a high positive predictive value. The exact value of radiography in the diagnostic algorithm in clinical practice and its use for research purposes is still to be defined, but for the first time, an evidenced-based approach on the utility of radiography in CPPD diagnosis can be adopted.

## ACKNOWLEDGMENT

Open access funding provided by BIBLIOSAN.

## AUTHOR CONTRIBUTIONS

All authors were involved in drafting the article or revising it critically for important intellectual content, and all authors approved the final version to be published. Dr. Sirotti had full access to all of the data in the study and takes responsibility for the integrity of the data and the accuracy of the data analysis.

**Study conception and design.** Sirotti, Filippou.

**Acquisition of data.** Sirotti, Becce, Sconfienza, Terslev, Naredo, Zufferey, Pineda, Gutierrez, Adinolfi, Serban, MacCarter, Mouterde, Zanetti, Scanu, Möller, Novo-Rivas, Largo, Sarzi-Puttini, Abhishek, Choi, Dalbeth, Pascart, Tedeschi, D'Agostino, Iagnocco, Keen, Scirè, Filippou.

**Analysis and interpretation of data.** Sirotti, Becce, Sconfienza, Terslev, Filippou.

## REFERENCES

- Zhang W, Doherty M, Bardin T, et al. European League Against Rheumatism recommendations for calcium pyrophosphate deposition. Part I: terminology and diagnosis. *Ann Rheum Dis* 2011;70:563–70.
- Salaffi F, De Angelis R, Grassi W, et al. Prevalence of musculoskeletal conditions in an Italian population sample: results of a regional community-based study. I. The MAPPING study. *Clin Exp Rheumatol* 2005;23:819–28.
- Abhishek A, Neogi T, Choi H, et al. Unmet needs and the path forward in joint disease associated with calcium pyrophosphate crystal deposition [review]. *Arthritis Rheumatol* 2018;70:1182–91.
- Abhishek A. Calcium pyrophosphate deposition disease: a review of epidemiologic findings [review]. *Curr Opin Rheumatol* 2016;28:133–9.
- Filippou G, Filippucci E, Mandl P, et al. A critical review of the available evidence on the diagnosis and clinical features of CPPD: do we really need imaging? *Clin Rheumatol* 2021;2581–92.
- Becce F. Diagnosis of calcium pyrophosphate deposition by imaging—current state and challenges remaining. *Osteoarthritis Cartilage* 2019;27:545–6.
- Becce F, Viry A, Stamp LK, et al. Winds of change in imaging of calcium crystal deposition diseases. *Joint Bone Spine* 2019;86:665–8.
- McCarty DJ. Calcium pyrophosphate dihydrate crystal deposition disease: nomenclature and diagnostic criteria. *Ann Intern Med* 1977;87:241–2.
- Filippou G, Adinolfi A, Cimmino MA, et al. Diagnostic accuracy of ultrasound, conventional radiography and synovial fluid analysis in the diagnosis of calcium pyrophosphate dihydrate crystal deposition disease. *Clin Exp Rheumatol* 2016;34:254–60.
- Sirotti S, Gutierrez M, Pineda C, et al. Accuracy of synovial fluid analysis compared to histology for the identification of calcium



- pyrophosphate crystals: an ancillary study of the OMERACT US Working Group-CPPD subgroup. *Reumatismo* 2021;73:106–10.
11. Swan A, Amer H, Dieppe P. The value of synovial fluid assays in the diagnosis of joint disease: a literature survey. *Ann Rheum Dis* 2002; 61:493–8.
  12. Filippou G, Scirè CA, Adinolfi A, et al. Identification of calcium pyrophosphate deposition disease (CPPD) by ultrasound: reliability of the OMERACT definitions in an extended set of joints—an international multiobserver study by the OMERACT Calcium Pyrophosphate Deposition Disease Ultrasound Subtask Force. *Ann Rheum Dis* 2018;77:1194–99.
  13. Filippou G, Scanu A, Adinolfi A, et al. Criterion validity of ultrasound in the identification of calcium pyrophosphate crystal deposits at the knee: an OMERACT ultrasound study. *Ann Rheum Dis* 2021;80: 261–7.
  14. Pascart T, Norberciak L, Legrand J, et al. Dual-energy computed tomography in calcium pyrophosphate deposition: initial clinical experience. *Osteoarthritis Cartilage* 2019;27:1309–14.
  15. Pascart T, Falgayrac G, Norberciak L, et al. Dual-energy computed-tomography-based discrimination between basic calcium phosphate and calcium pyrophosphate crystal deposition in vivo. *Ther Adv Musculoskelet Dis* 2020;12:1759720X20936060.
  16. Budzik JF, Marzin C, Legrand J, et al. Can dual-energy computed tomography be used to identify early calcium crystal deposition in the knees of patients with calcium pyrophosphate deposition? *Arthritis Rheumatol* 2021;73:687–92.
  17. Stamp LK, Anderson NG, Becce F, et al. Clinical utility of multi-energy spectral photon-counting computed tomography in crystal arthritis. *Arthritis Rheumatol* 2019;71:1158–62.
  18. Huber FA, Becce F, Gkoumas S, et al. Differentiation of crystals associated with arthropathies by spectral photon-counting radiography: a proof-of-concept study. *Invest Radiol* 2021;56:147–52.
  19. Cipolletta E, Filippou G, Scirè CA, et al. The diagnostic value of conventional radiography and musculoskeletal ultrasonography in calcium pyrophosphate deposition disease: a systematic literature review and meta-analysis. *Osteoarthritis Cartilage* 2021;29:619–32.
  20. Tedeschi SK, Pascart T, Latourte A, et al. Identifying potential classification criteria for calcium pyrophosphate deposition disease: item generation and item reduction [review]. *Arthritis Care Res (Hoboken)* 2022;74:1649–58.
  21. Tedeschi SK, Becce F, Pascart T, et al. Imaging features of calcium pyrophosphate deposition disease: consensus definitions from an international multidisciplinary working group. *Arthritis Care Res (Hoboken)* 2022. doi: <https://doi.org/10.1002/acr.24898>. Epub ahead of print.
  22. Maxwell LJ, Beaton DE, Boers M, et al. The evolution of instrument selection for inclusion in core outcome sets at OMERACT: Filter 2.2. *Semin Arthritis Rheum* 2021;51:1320–30.
  23. Ryan LM, McCarty DJ. Calcium pyrophosphate crystal deposition disease, pseudogout and articular chondrocalcinosis. In: *Arthritis and Allied Conditions. A Textbook of Rheumatology*. 13th ed. Philadelphia: Lea & Febiger; 1997:2013–25.
  24. Bossuyt PM, Reitsma JB, Bruns DE, et al. STARD 2015: an updated list of essential items for reporting diagnostic accuracy studies. *BMJ* 2015;351:h5527.
  25. Landis JR, Koch GG. The measurement of observer agreement for categorical data. *Biometrics* 1977;33:159–74.
  26. Kellgren JH, Lawrence JS. Radiological assessment of osteo-arthrosis. *Ann Rheum Dis* 1957;16:494–502.
  27. Bruyn GA, Naredo E, Damjanov N, et al. An OMERACT reliability exercise of inflammatory and structural abnormalities in patients with knee osteoarthritis using ultrasound assessment. *Ann Rheum Dis* 2016;75: 842–6.
  28. Misra D, Guermazi A, Sieren JP, et al. CT imaging for evaluation of calcium crystal deposition in the knee: initial experience from the Multi-center Osteoarthritis (MOST) study. *Osteoarthritis Cartilage* 2015;23: 244–8.
  29. Gordon C, Swan A, Dieppe P. Detection of crystals in synovial fluids by light microscopy: sensitivity and reliability. *Ann Rheum Dis* 1989; 48:737–42.